


FIBULA

Dr. Untika Singh

Junior Resident

Department of Anatomy King George's Medical University, UP, Lucknow



DISCLAIMER:

- The presentation includes images which are either hand drawn or taken from Google images or books.
- They are being used in the presentation only for educational purpose.
- The author of the presentation claims no personal ownership over images taken from books or Google images.
- However, the hand drawn images are the creation of the author of the presentation.



LEARNING OBJECTIVES

By the end of this teaching session on tibia, all the students must be able to correctly:-

- ❖ Identify fibula.
- ❖ Demonstrate the different parts, borders and surfaces of fibula.
- ❖ Determine the side of the fibula
- ❖ Hold the fibula in its anatomical position.
- ❖ Demonstrate attachment of joint capsule ,ligaments and muscles on the fibula.
- ❖ Describe ossification of the fibula.



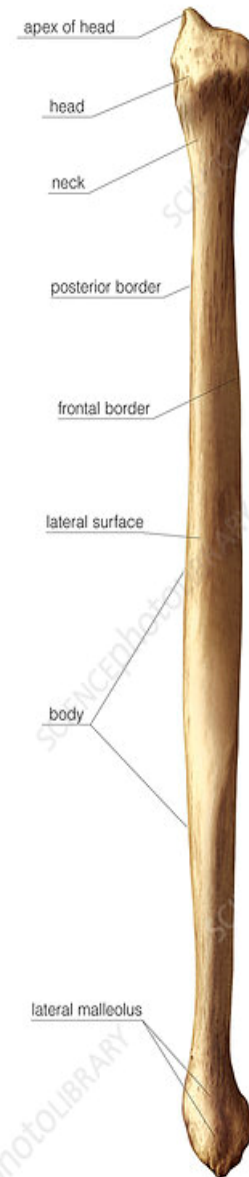FIBULA

- Lies laterally
- Is smaller bone of leg.
- Very thin bone compared to ulna.
- Homologous to ulna of upper limb.
- Is not a weight bearing bone.
- It forms a mortice of the ankle joint.



FEATURES

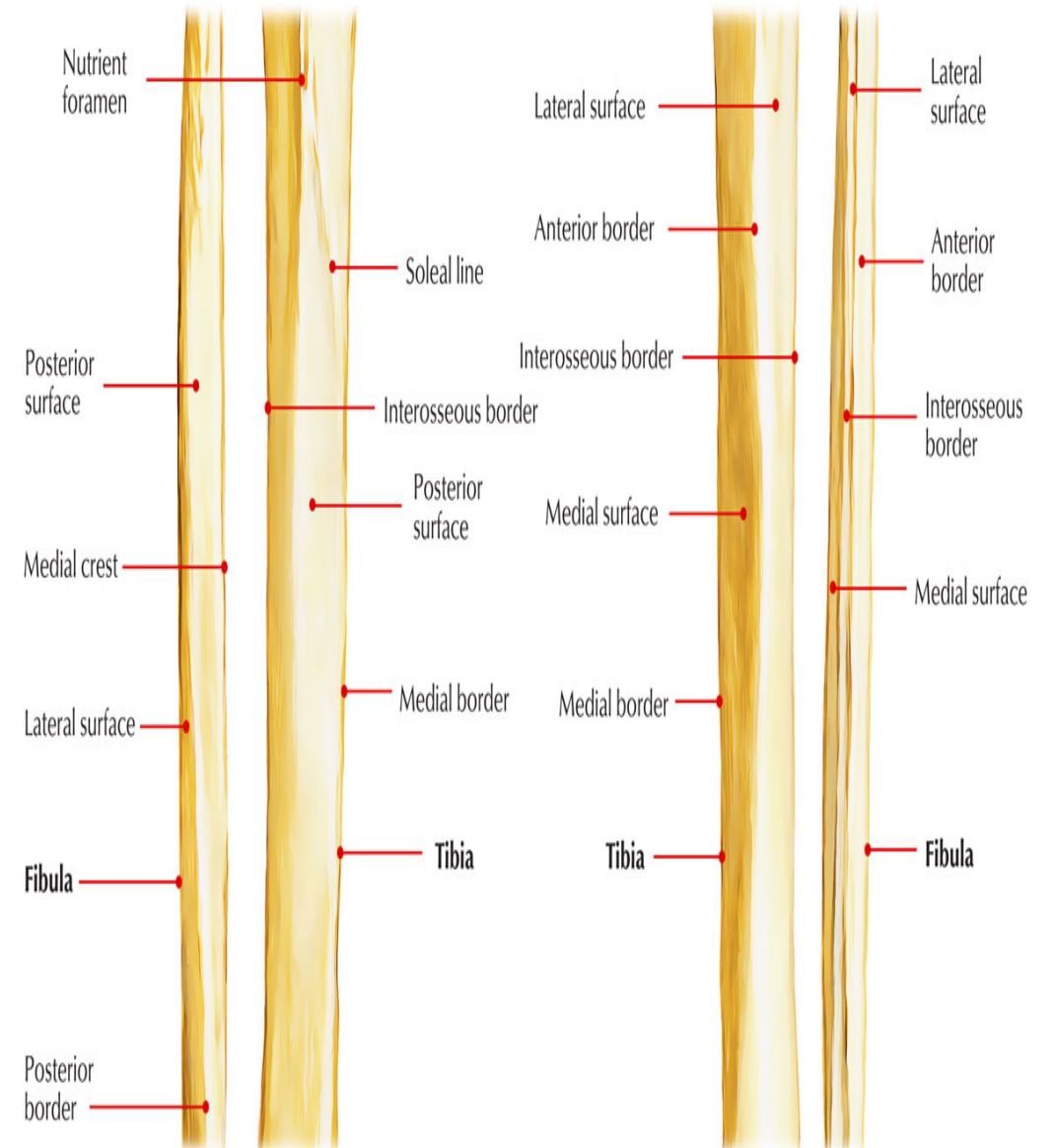
- Upper end/head- expanded in all direction, circular articular facet(for lateral condyle of tibia), styloid process.
- Neck – constriction below the head.
- Shaft- 3 borders and 3 surfaces.



Borders

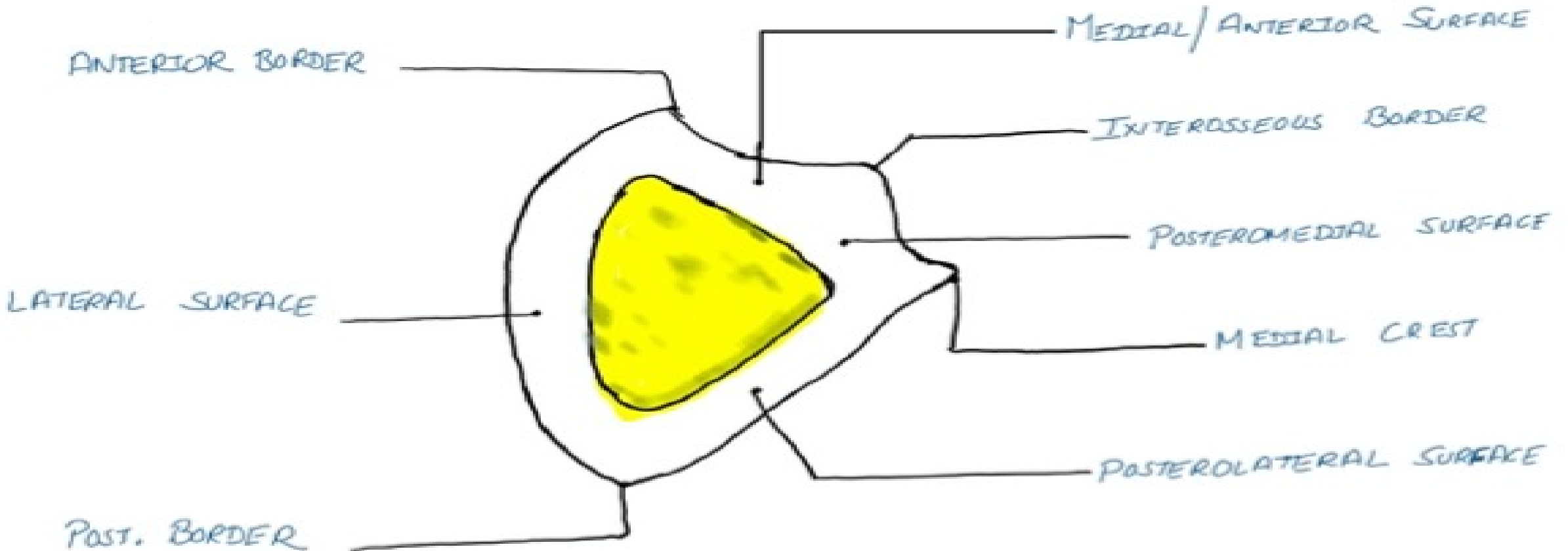
- **1. Anterior border-**
- **Above** –just below ant. Aspect of head.
- **Below**-divide to enclose triangular area(cont. lateral surface of lateral malleolus)

- **2. Posterior border-**
- **Above**-in line with styloid process.
- **Below**-continue with medial margin of groove on back of lateral malleolus.



3. Medial/interosseous border-

- Lies just medial to ant. Border.
- Terminates-below at roughened area above talar facet.
- Upper 2/3rd -lies very close(indistinguishable) to ant. border



Surfaces

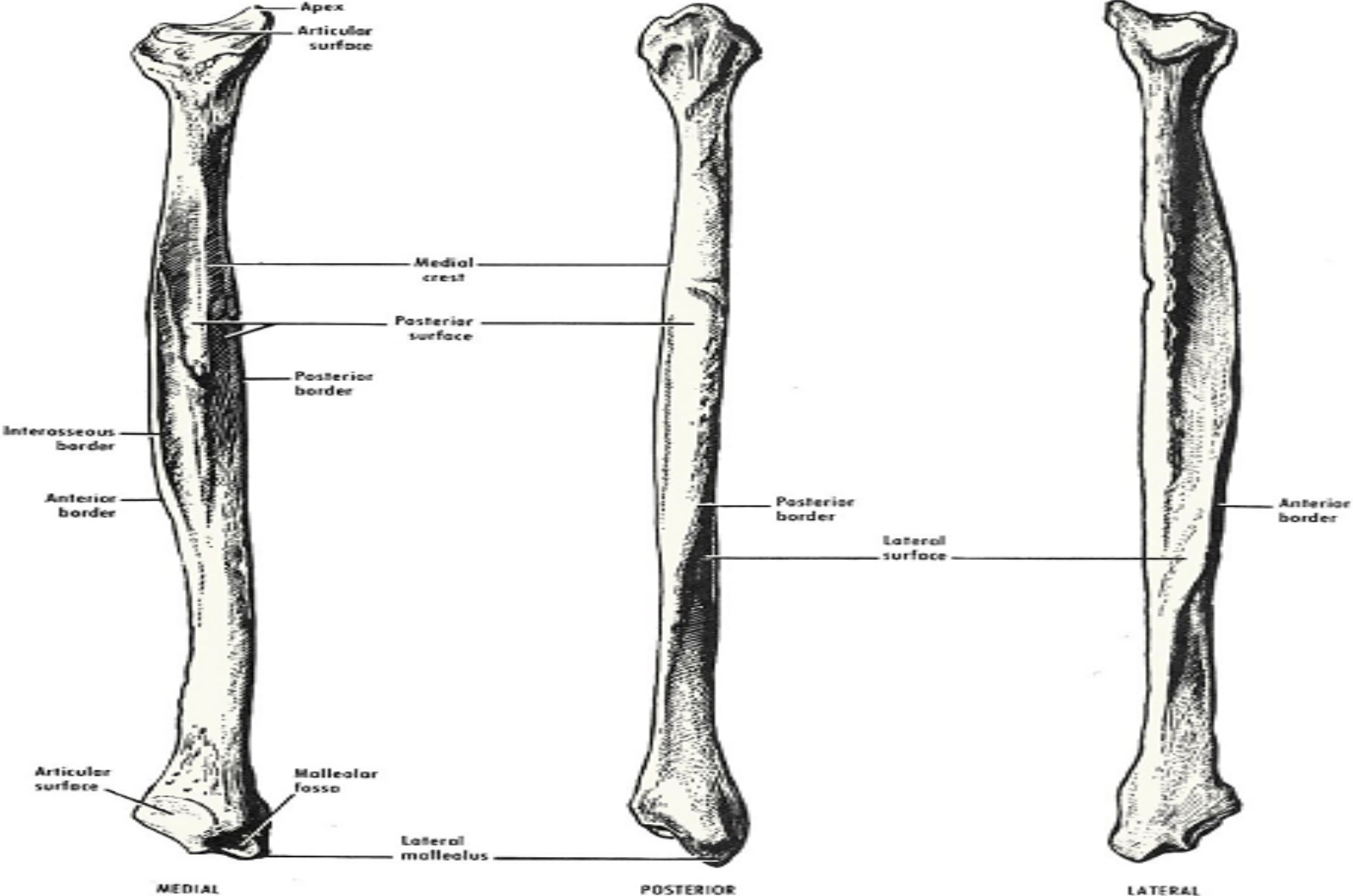
- Medial surface
- Lateral surface
- Posterior surface

Lies between and features

- Anterior and medial border
- Its upper 2/3rd very narrow (1mm or less)
- Anterior and posterior border
- Twisted backward in lower part
- Interosseous and post. Border
- Upper 2/3rd divide by vertical ridge called medial crest.



BORDERS AND SURFACES

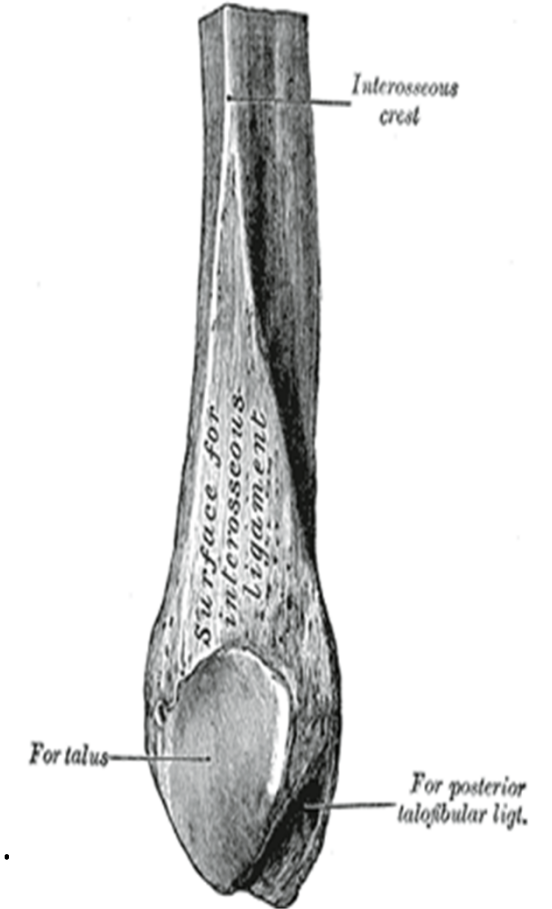


LOWER END / LATERAL MALLEOLUS

1. Anterior surface- rough and rounded.
2. Posterior surface- have a groove.
3. Lateral surface- subcutaneous.
4. Medial surface- have triangular facet for talus (anteriorly)
& malleolar fossa (posteriorly)

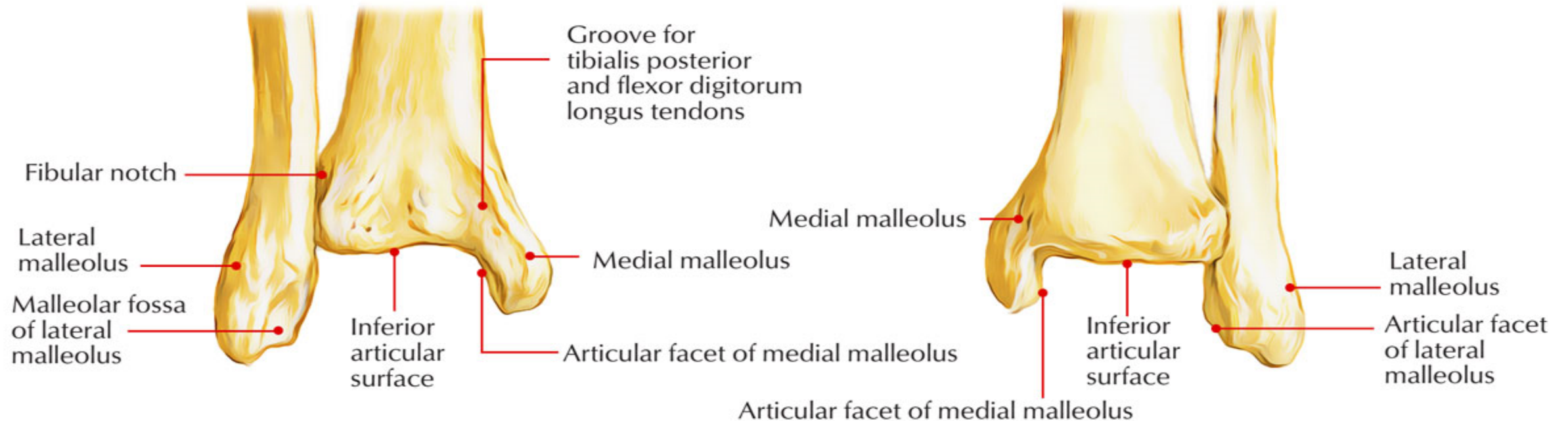
Special features of lateral malleolus-

- ❑ Tip of lateral malleolus 0.5 cm lower than that of medial malleolus.
- ❑ Ant. Surface of lateral malleolus 1.5 cm posterior to that of medial malleolus



Special features of lateral malleolus-

- ❑ Tip of lateral malleolus 0.5 cm lower than that of medial malleolus.
- ❑ Ant. Surface of lateral malleolus 1.5 cm posterior to that of medial malleolus

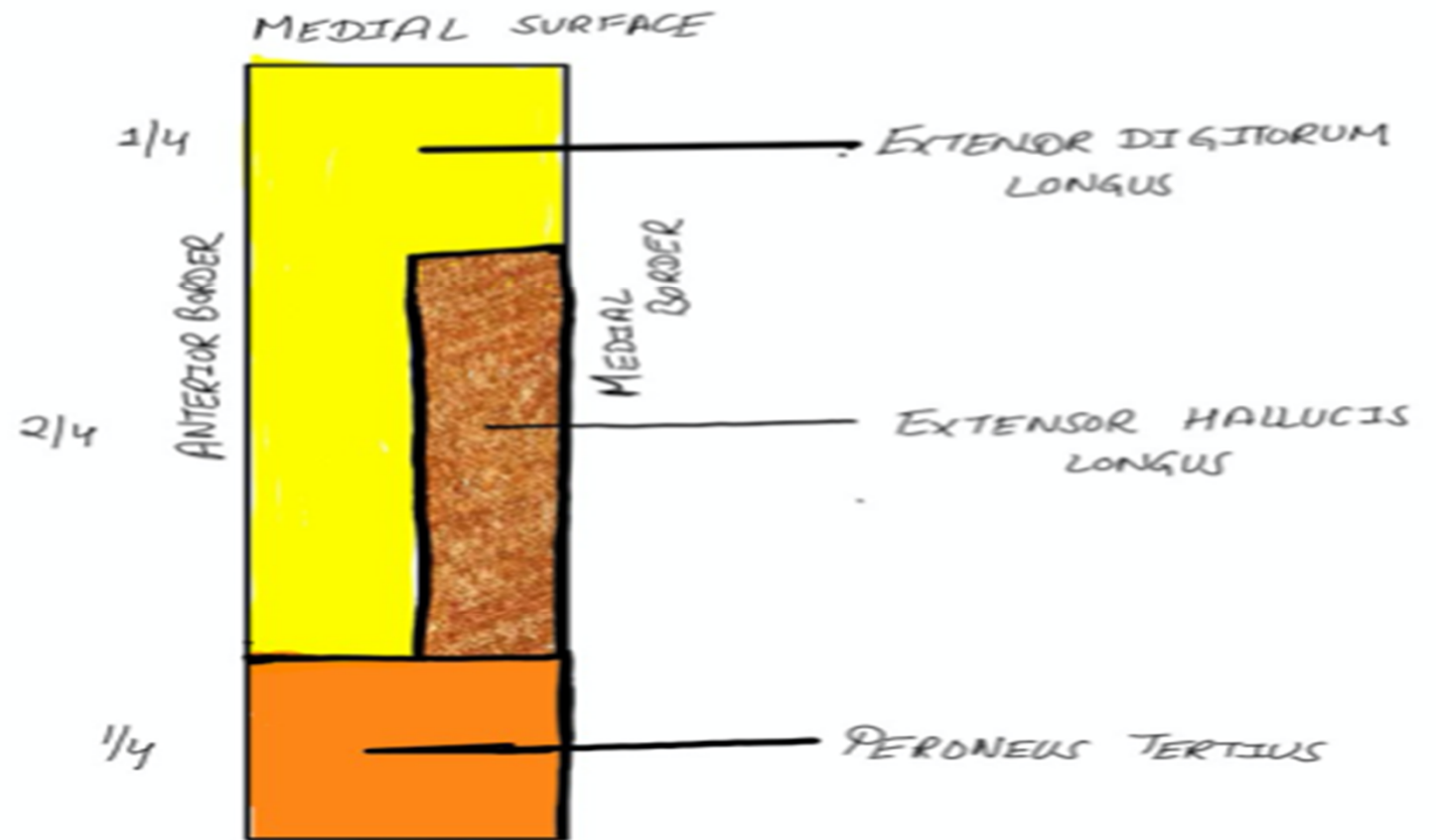


ATTACHMENTS AND RELATIONS OF FIBULA

Surfaces and borders

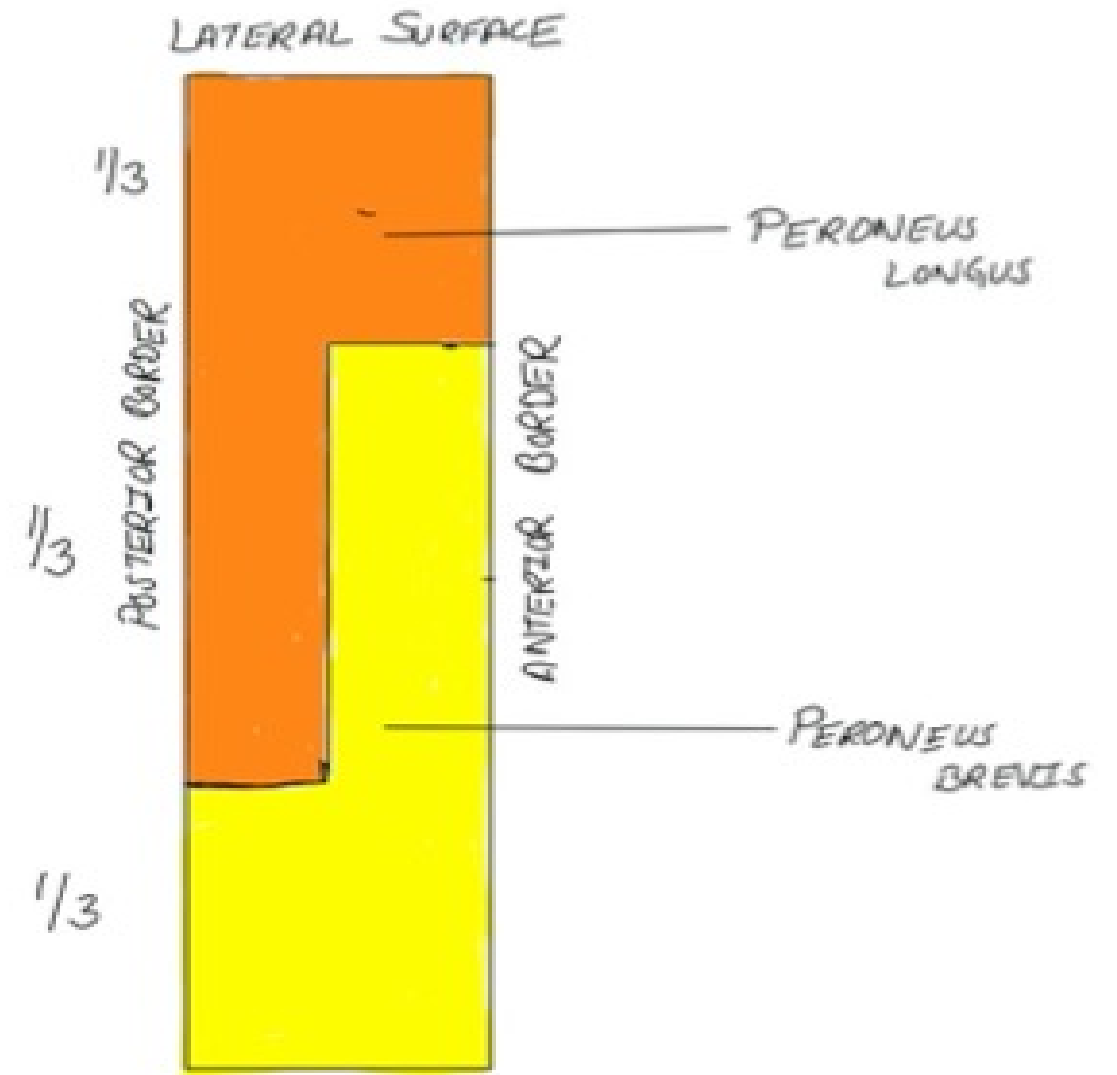
Attachments and relations

Medial surface



ATTACHMENTS ON MEDIAL SURFACE OF FIBULA

Lateral surface



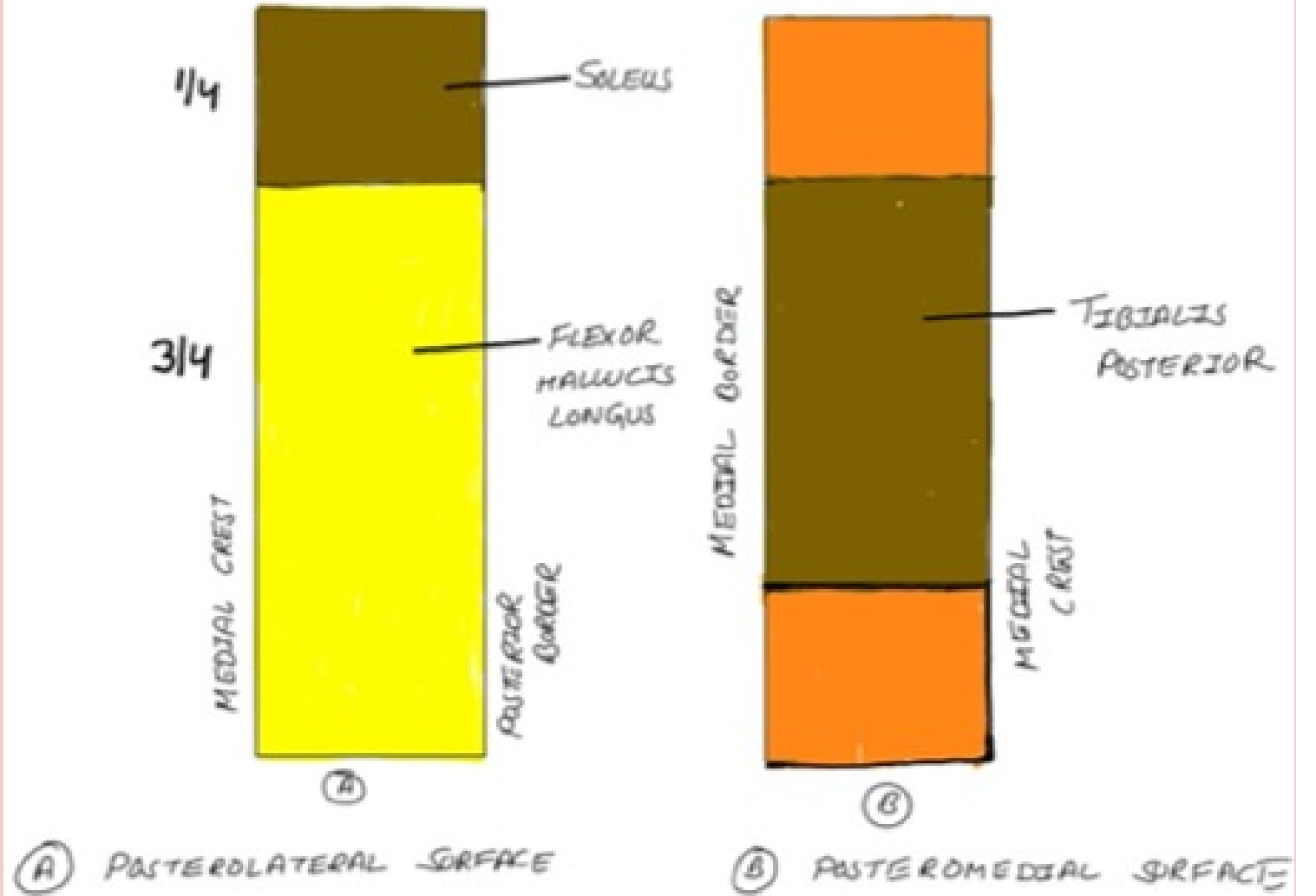
ATTACHMENTS ON LATERAL SURFACE OF FIBULA



Neck

Common peroneal nerve

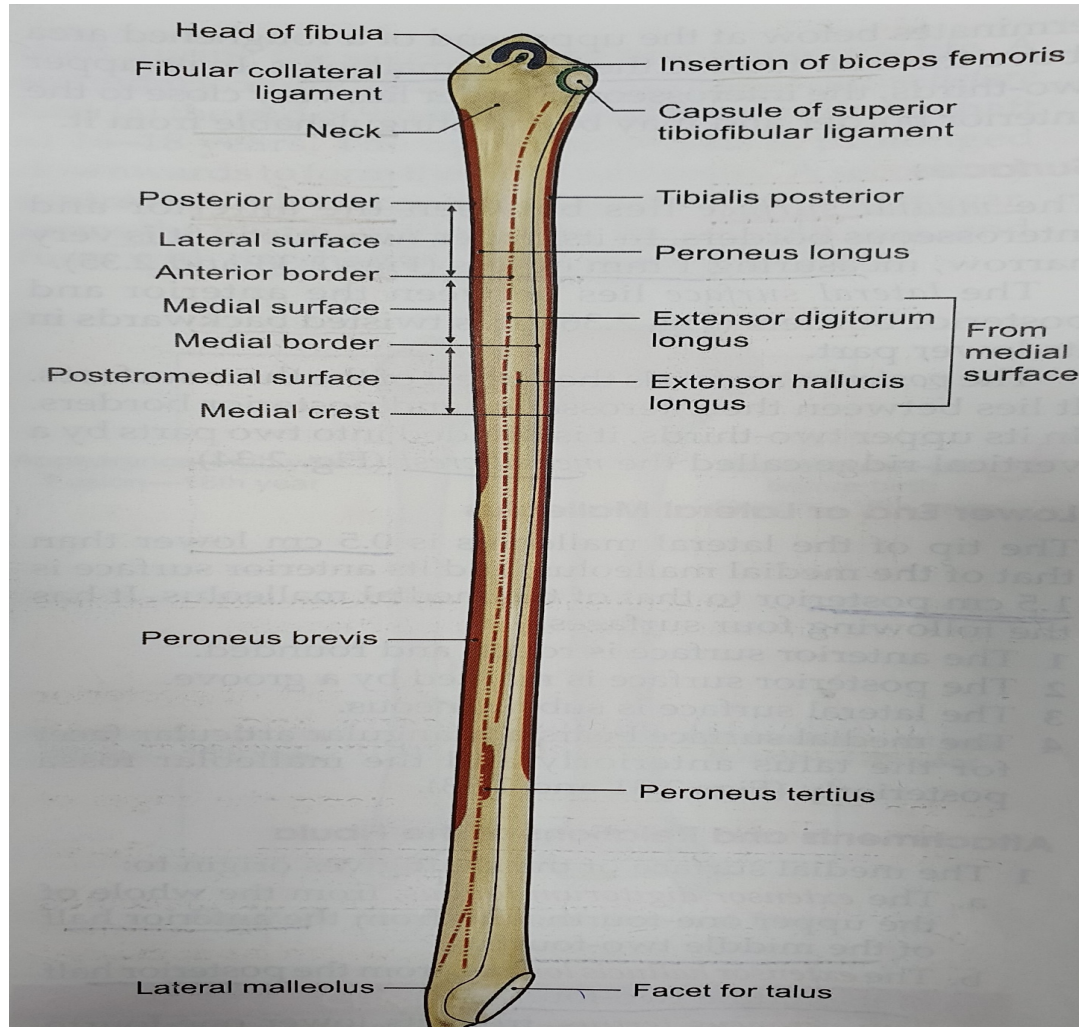
Posterior surface



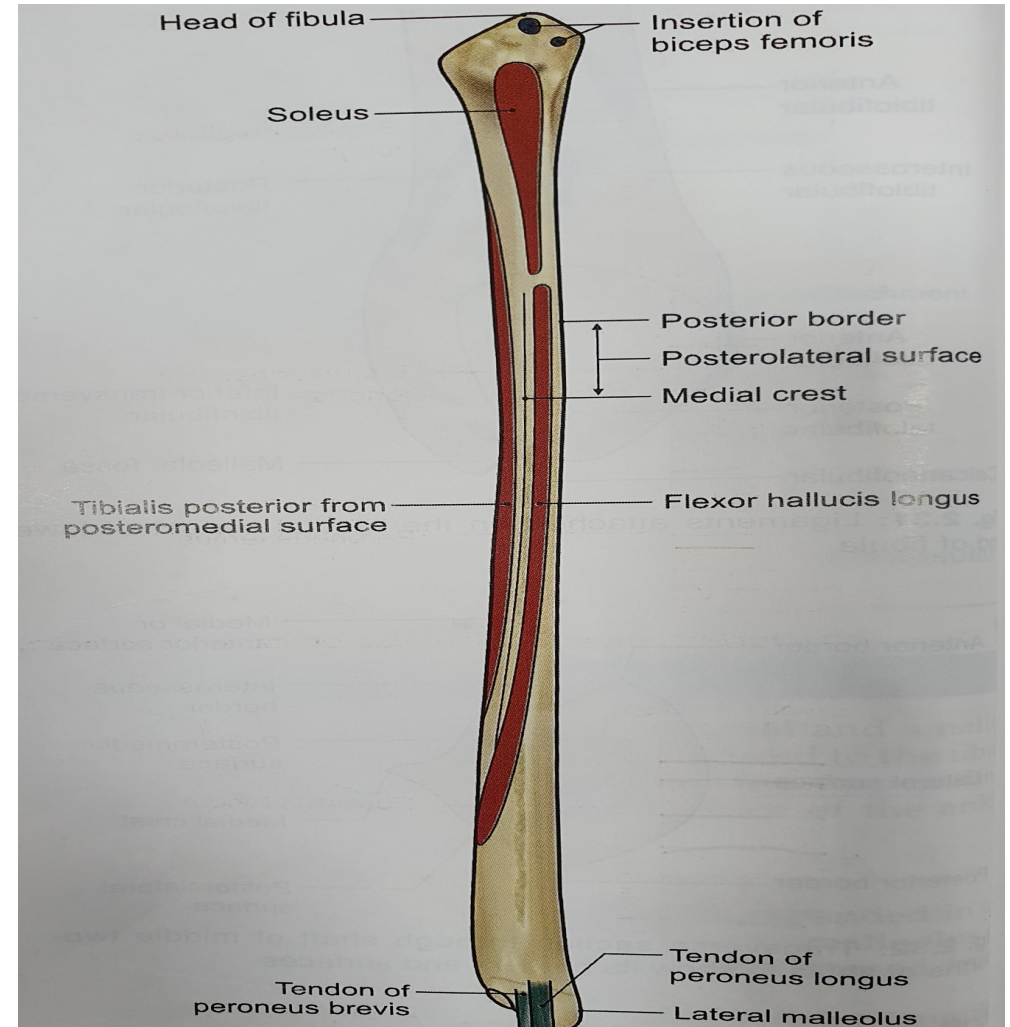
| | |
|---------------------|--|
| Head | Biceps femoris Fibular collateral ligament Capsular ligament of the superior tibiofibular joint |
| Anterior border | Ant. intermuscular septum, Sup. Extensor retinaculum Sup. peroneal retinaculum |
| Posterior border | Post. intermuscular septum |
| Interosseous border | Interosseous I membrane Gap(at upper end) -Ant. tibial vessels Gap(at lower end) -perforating branch of peroneal artery. |



ANTERIOR ASPECT



POSTERIOR ASPECT



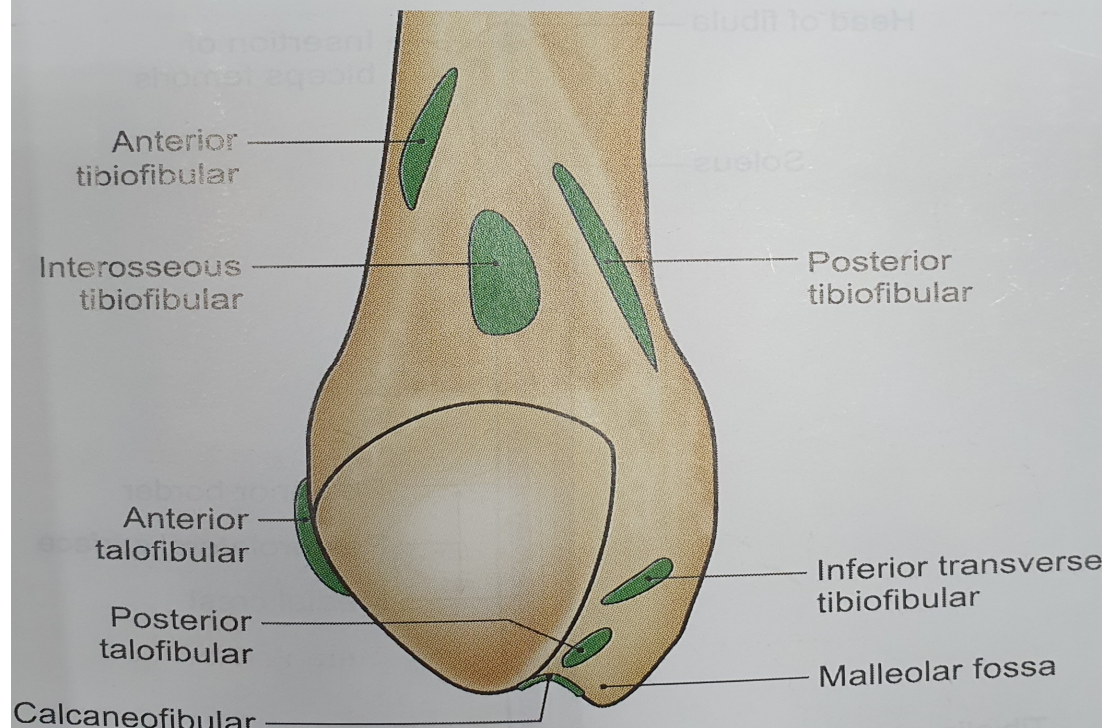
Surfaces and borders

Triangular area above medial surface of Lateral malleolus

Attachments and realation

Interosseous tibiofibular ligament
Ant. tibiofibular ligament
Post. tibiofibular ligament

Lateral malleolus



Ant. talofibular ligament
post. tibiofibular ligament
inf. Transverse tibiofibular ligament
Capsule of ankle joint
Calcaneofibular ligament
Tendon of Peroneus longus (in groove of post. Surface)
Tendon Peroneus brevis (in groove of post. Surface)



1 primary and 2
secondary centres

Primary centre- for shaft-appear 8th week

1st secondary centre -
for lower end-appear
1st yr. of life
fuses with shaft -16 yr.

2nd secondary centre –
for upper end-
appears 4th yr. of life
fuses with shaft -18 yr.

OSSIFICATION-

Fibula violates the
law of ossification-

Secondary centre
which appears first in
the lower end fuses
earlier and not later.

