

# Back of Leg I

**Dr. Garima Sehgal**  
**Associate Professor**  
**King George's Medical University**  
**UP, Lucknow**



**“Only those who risk going  
too far, can possibly find  
out how far one can go.”**

**— T.S. Elliot**

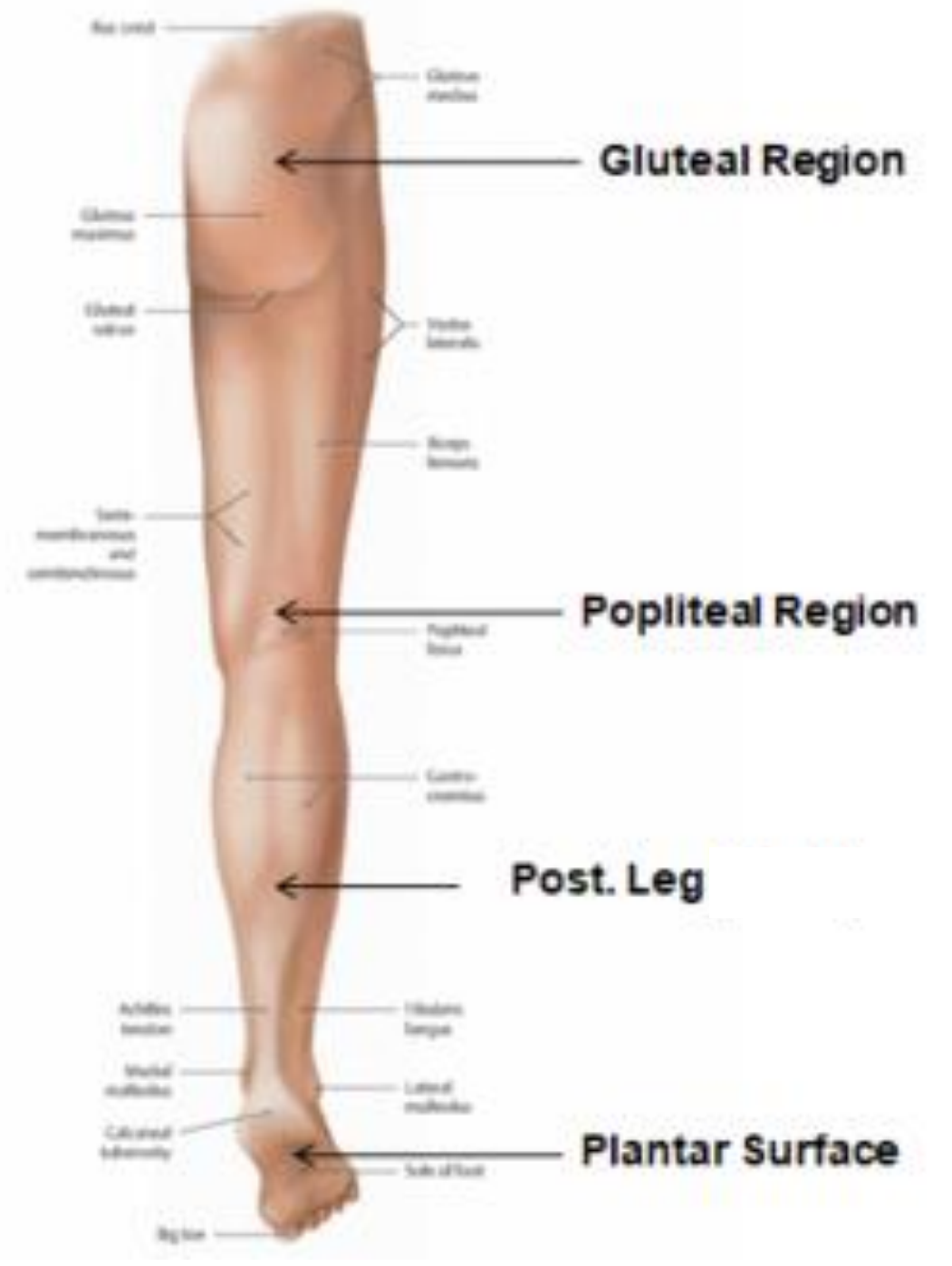
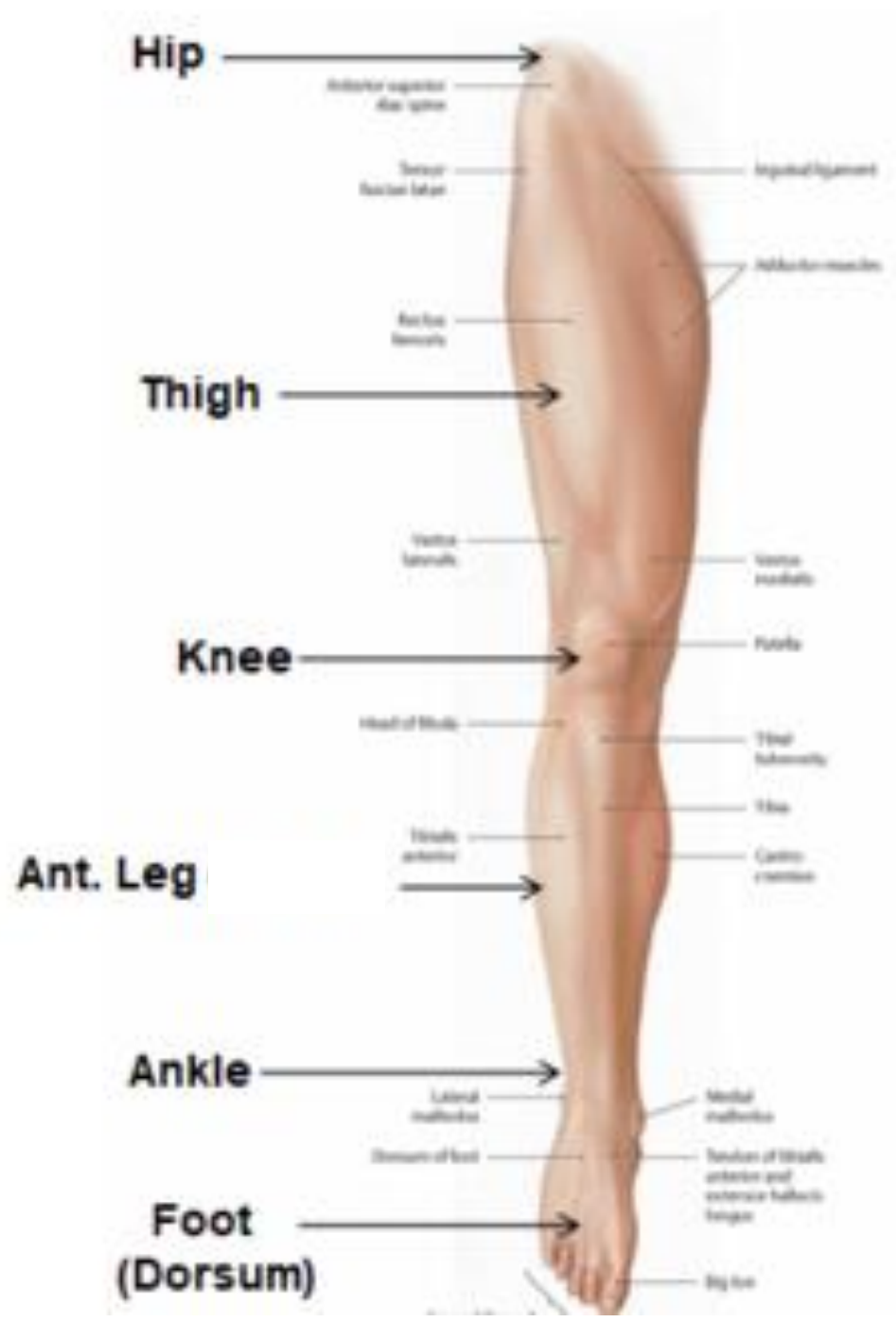# DISCLAIMER

**Presentation has been made only for educational purpose  
Images and data used in the presentation have been taken  
from various textbooks and other online resources  
Author of the presentation claims no ownership for this  
material**

# **Learning Objectives**

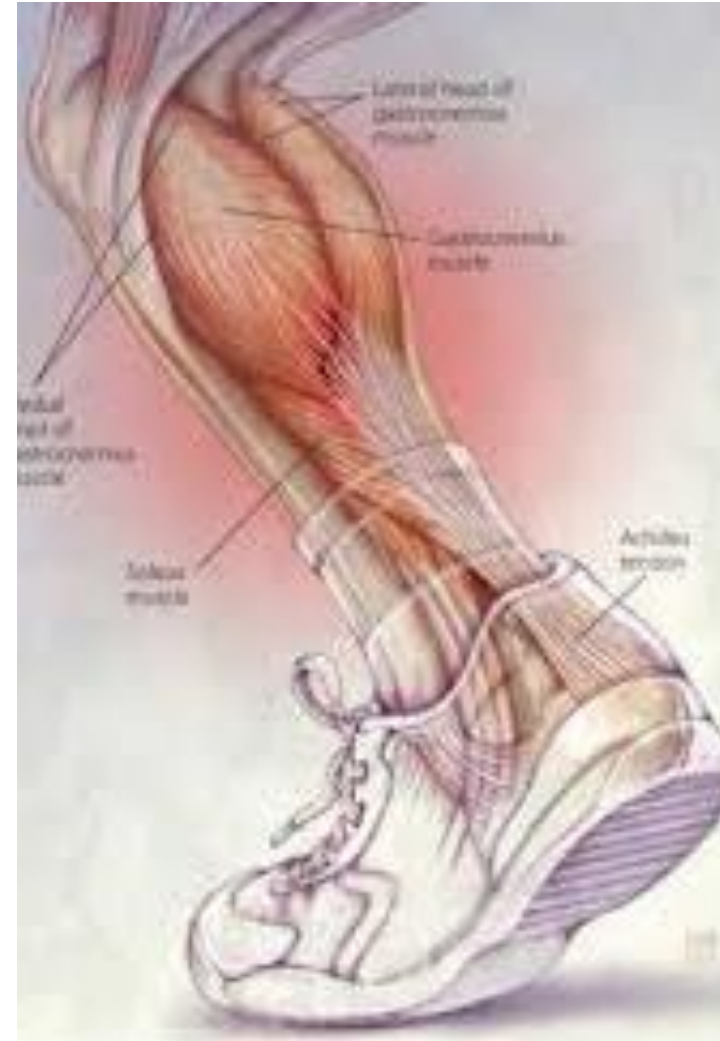**By the end of this teaching session on Back of leg – I all the MBBS 1<sup>st</sup> year students must be able to:**

- **Enumerate the contents of superficial fascia of back of leg**
- **Write a short note on small saphenous vein**
- **Describe cutaneous innervation in the back of leg**
- **Write a short note on sural nerve**
- **Enumerate the boundaries of posterior compartment of leg**
- **Enumerate the fascial compartments in back of leg & their contents**
- **Write a short note on flexor retinaculum of leg- its attachments & structures passing underneath**
- **Describe the origin, insertion nerve supply and actions of superficial muscles of the posterior compartment of leg**



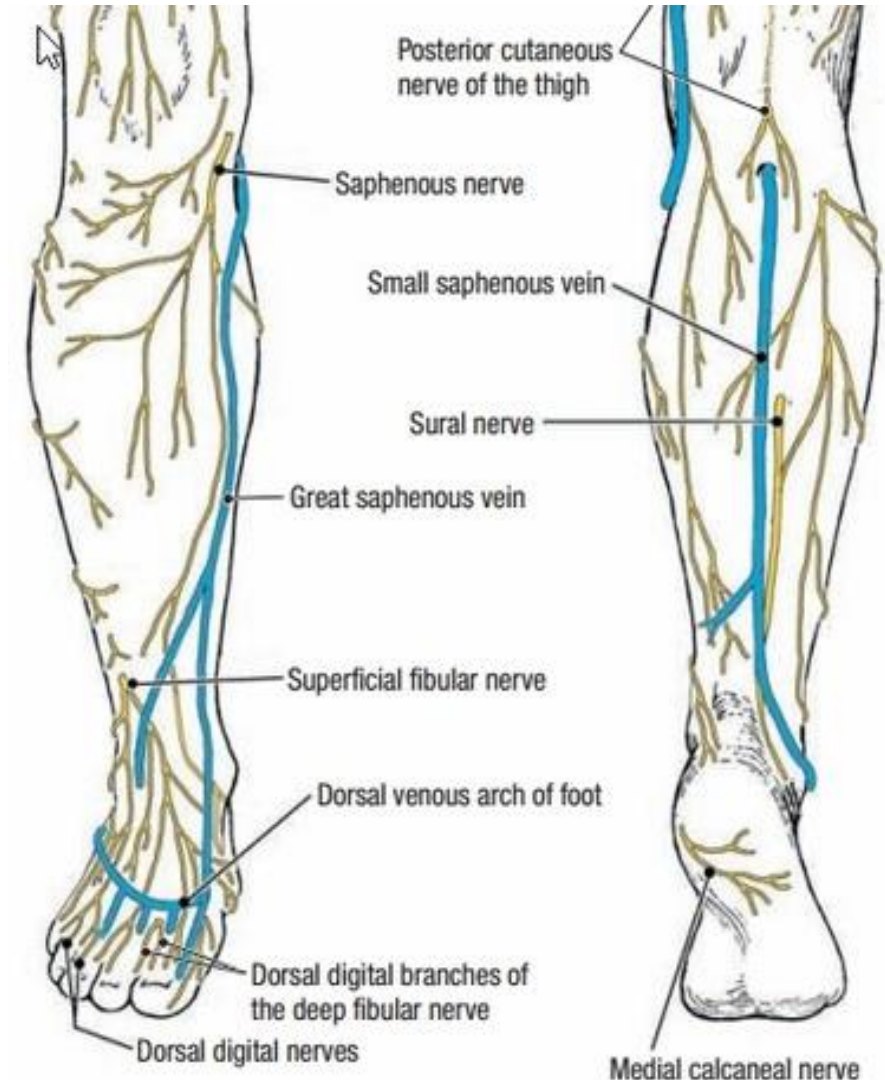
# Introduction- Back of Leg / Calf

- **Powerful superficial antigravity muscles**
  - (gastrocnemius, soleus)
- **Muscles are large in size**
- **Inserted into the heel**
- **Raise the heel during walking**



# Superficial fascia of Back of leg

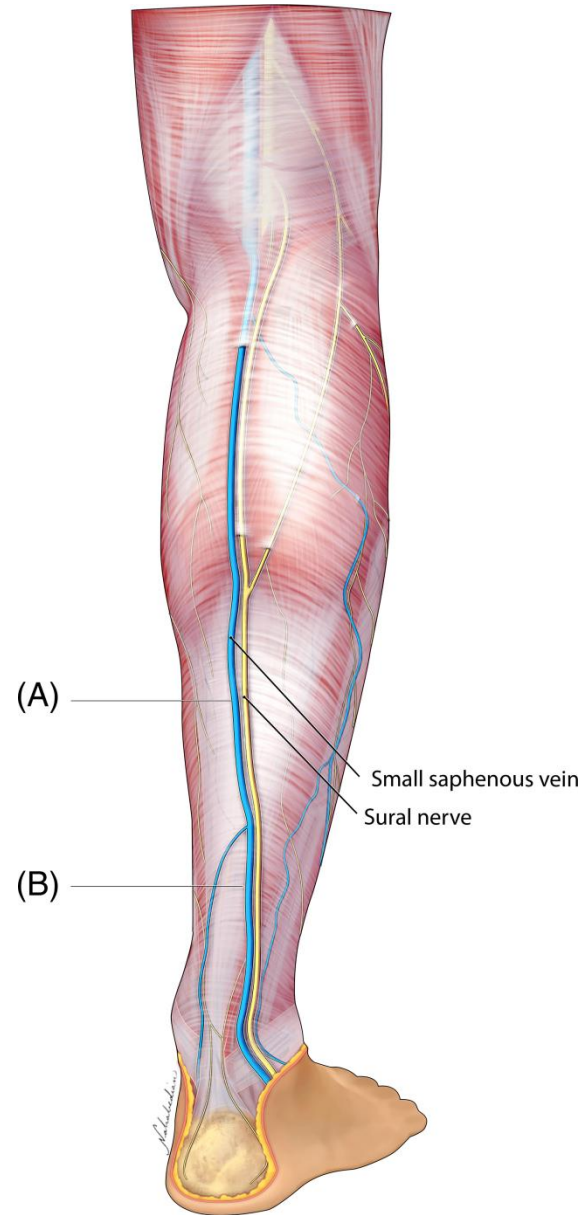
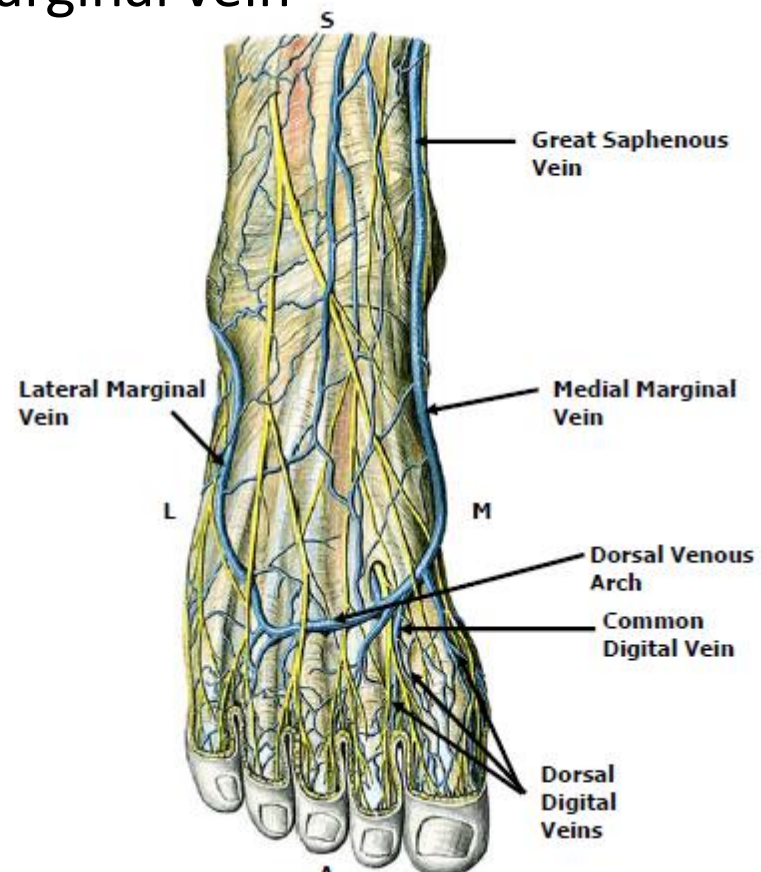
- Contains superficial veins-
  - small saphenous vein with its tributaries
  - part of course of great saphenous vein
- Cutaneous nerves in the back of leg-
  1. Saphenous nerve
  2. Posterior division of medial cutaneous nerve of thigh
  3. Posterior cutaneous nerve of thigh
  4. Sural nerve
  5. Lateral cutaneous nerve of calf
  6. Peroneal / Sural communicating nerve



# Short saphenous Vein

## • Formation:

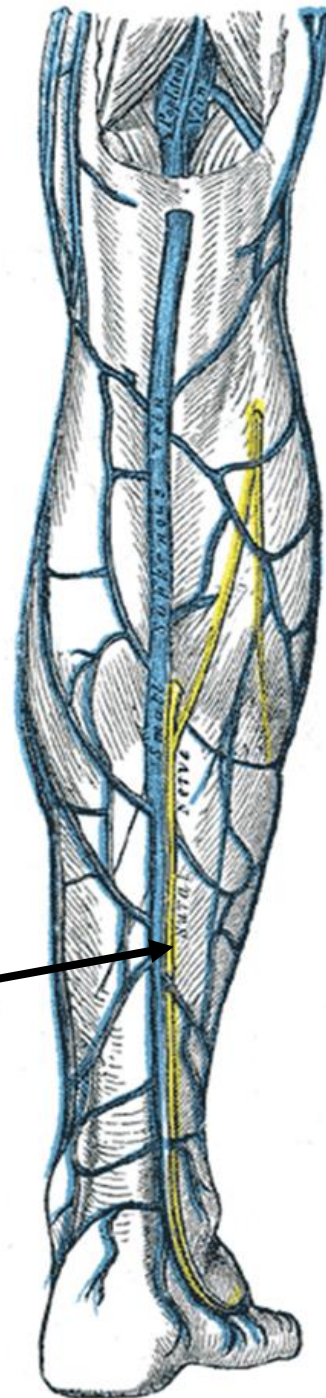
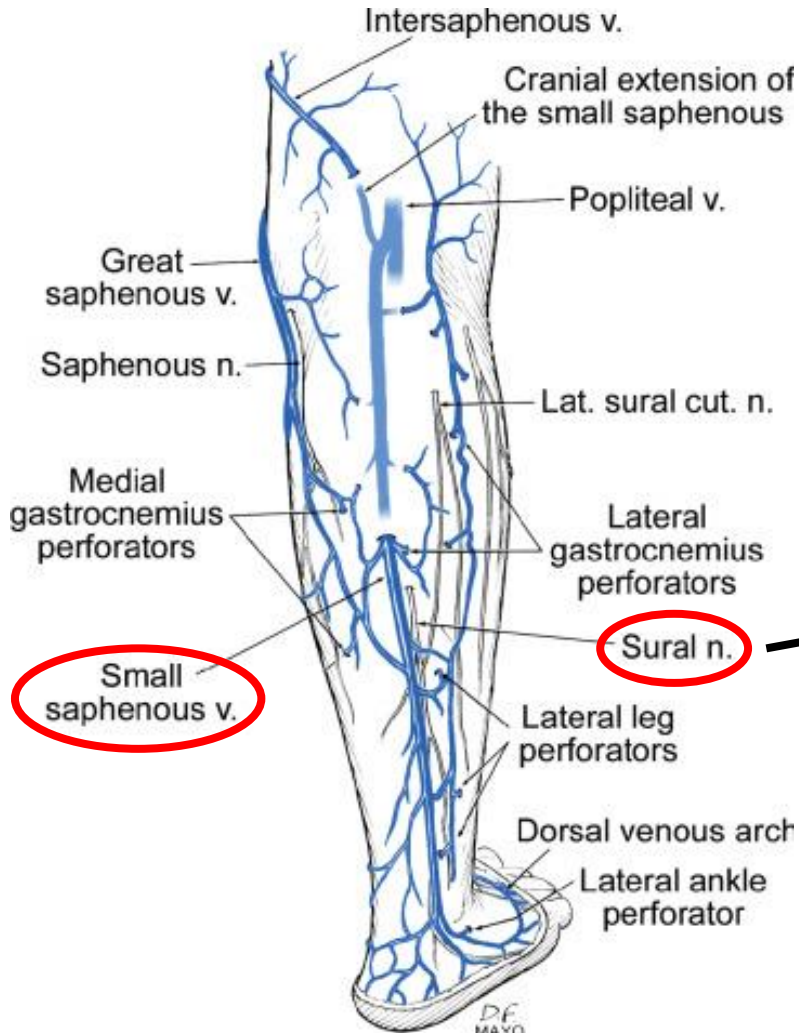
- On dorsum of foot
- By union of lateral end of dorsal venous arch with lateral marginal vein



## Course:

- Passes behind lateral malleolus (**with sural nerve**)
- Lateral to Tendo- Achilles
- Ascends in subcutaneous fat on the back of leg along midline of calf
- Reaches lower part of popliteal fossa
- Pierces deep fascia
- Drains into popliteal vein
- Communicates with great saphenous through several channels

## Short saphenous vein contd.....



- **Termination:**

- Drains into popliteal vein

- **Drainage Territory:**

- Lateral border of foot
- Heel
- Back of leg

- **Relations:**

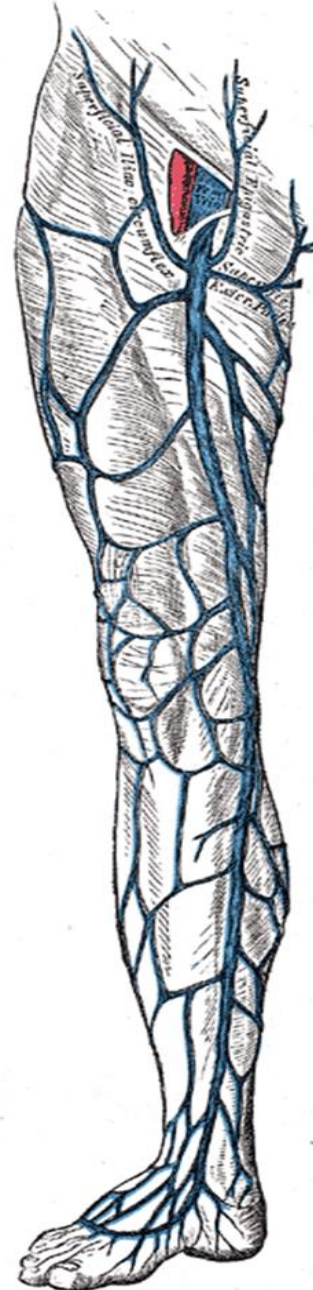
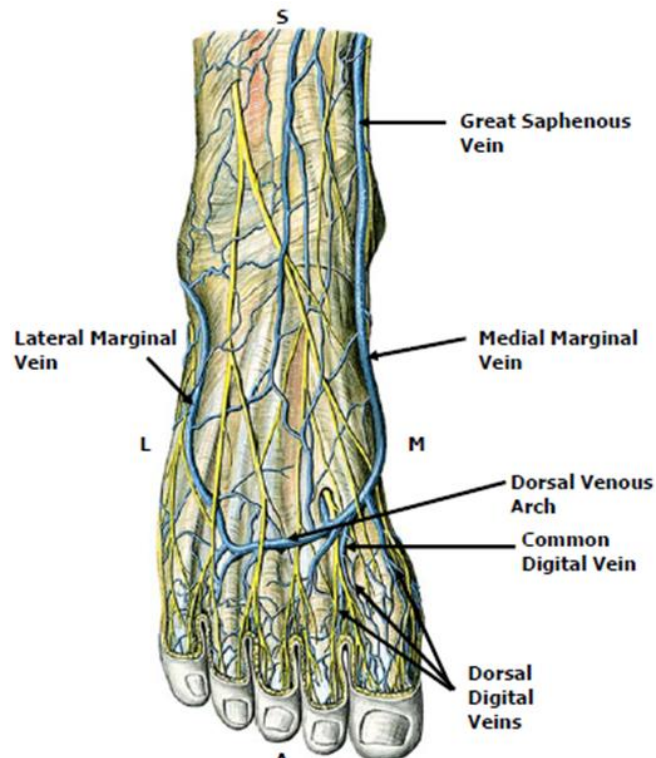
- Accompanied by sural nerve



# Great Saphenous vein (Recap)

- **Formation:**

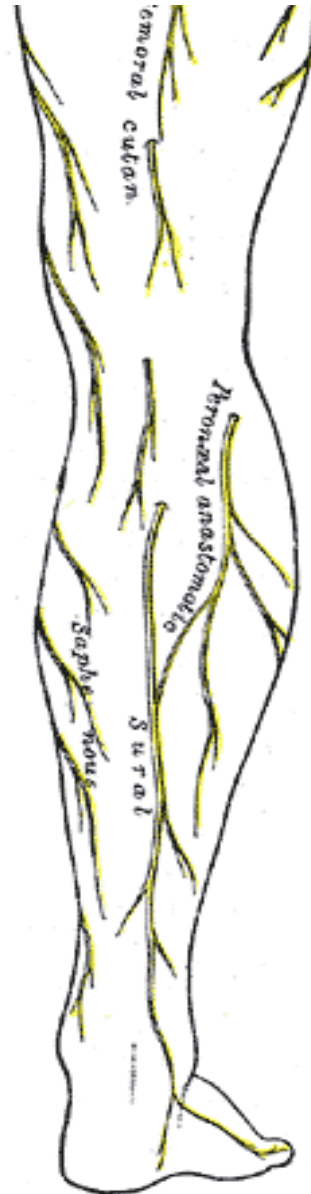
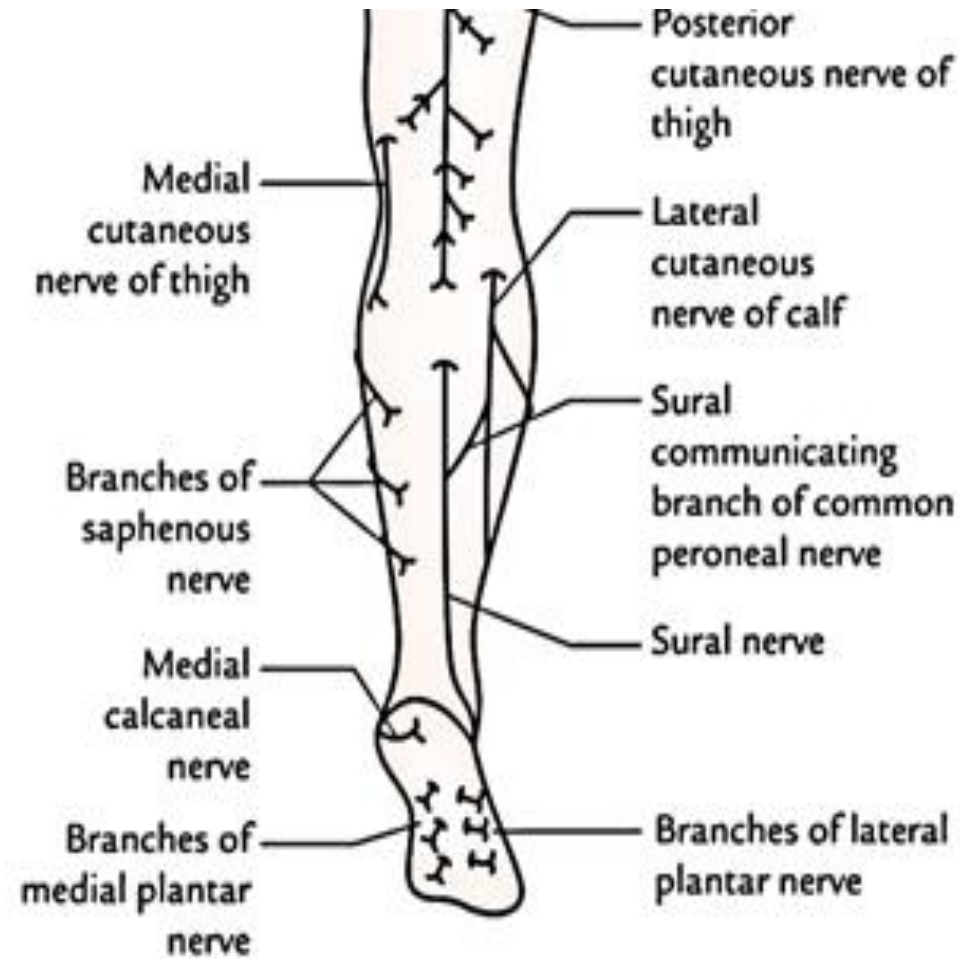
- On dorsum of foot
- By union of medial end of dorsal venous arch with medial marginal vein



- **Course:**

- Passes in front of medial malleolus
- Enters back of leg
- In lower 1/3<sup>rd</sup> leg- obliquely across medial surface of tibia
- In upper 2/3<sup>rd</sup> – along medial border of tibia
- Reaches posteromedial knee
- In thigh – inclines forwards
- Reaches saphenous opening

# Cutaneous Innervation of Back of Leg



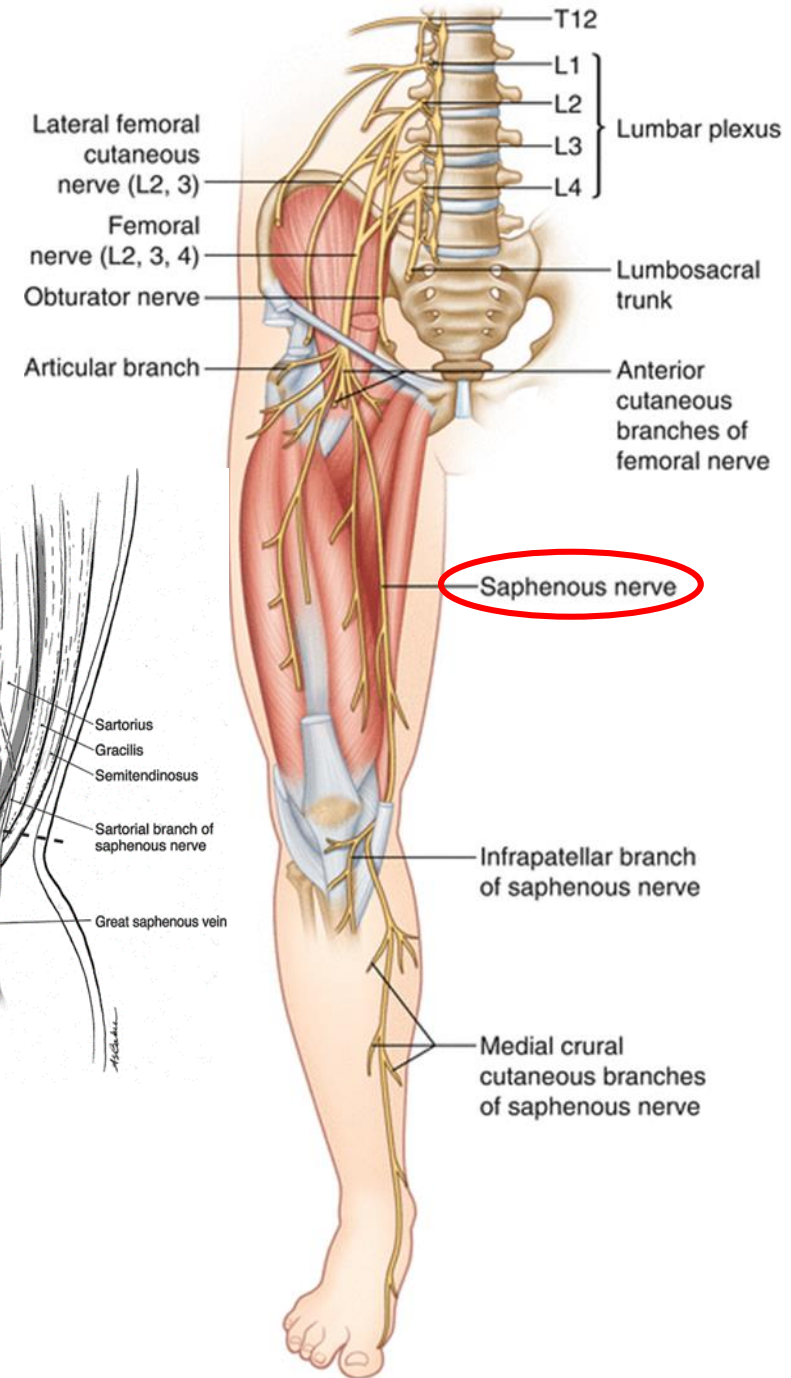
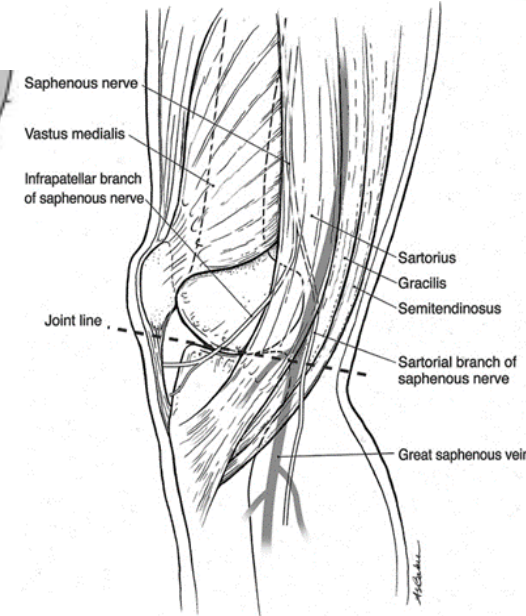
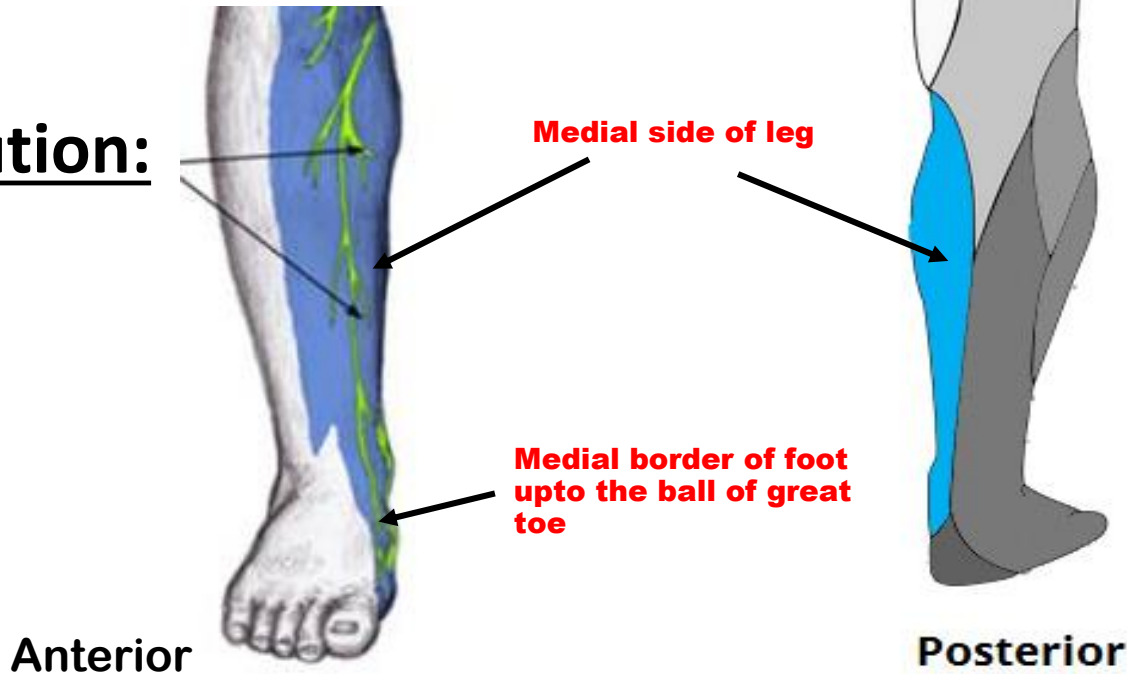
- Region of skin – 3 vertical areas
- Each by 2 nerves
- **Medial area** –
  - Posterior branch of medial cutaneous nerve of thigh
  - Saphenous nerve
- **Central area** –
  - Posterior cutaneous nerve of thigh
  - Sural nerve
- **Lateral area** –
  - Lateral cutaneous nerve of calf
  - Peroneal communicating nerve

# Saphenous nerve

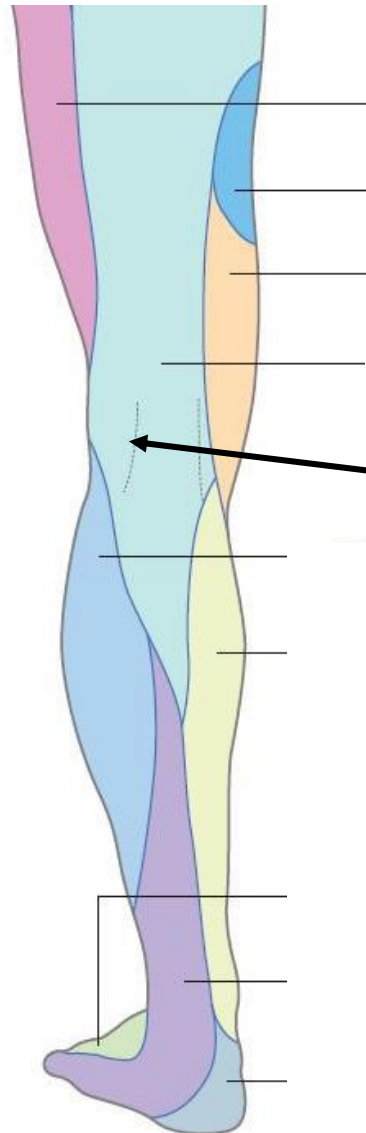
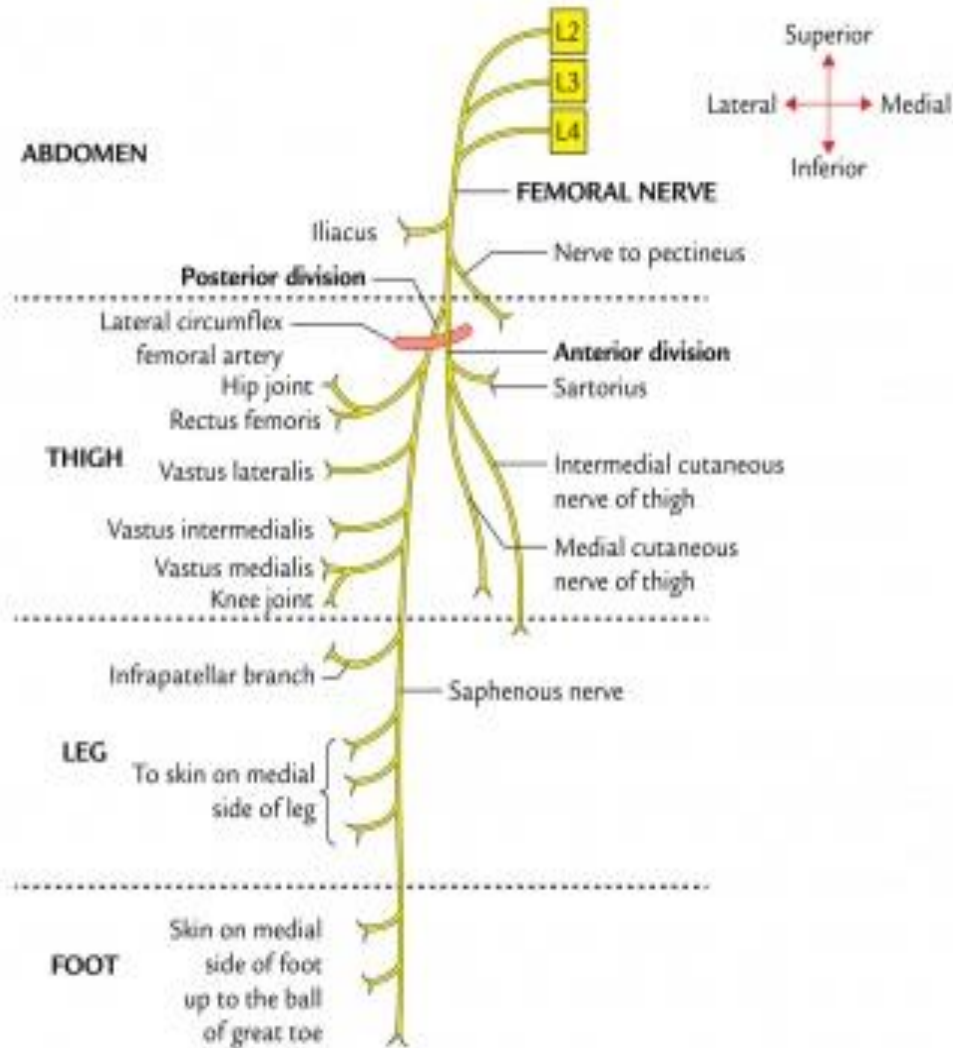
(L3,L4 – posterior division of femoral nerve)

- Originates in femoral triangle
- Descends, pierces fascia on medial knee between Sartorius & gracilis
- Accompanies GSV

## Distribution:

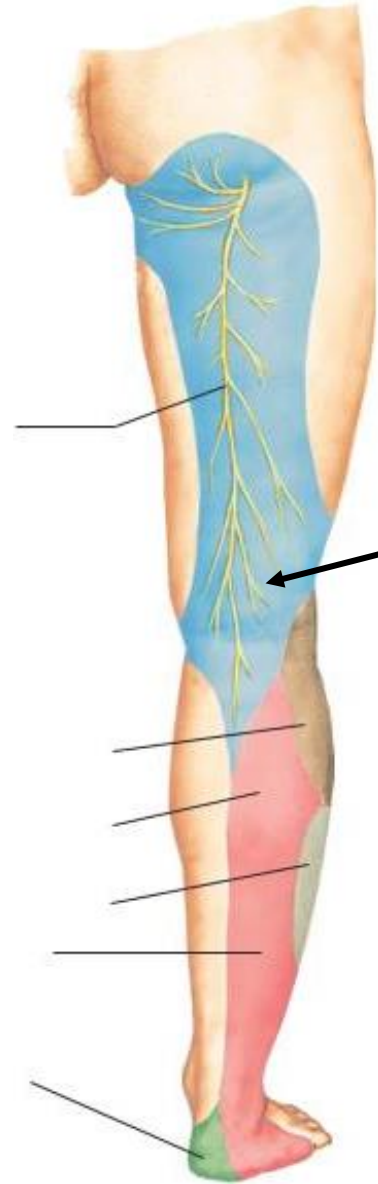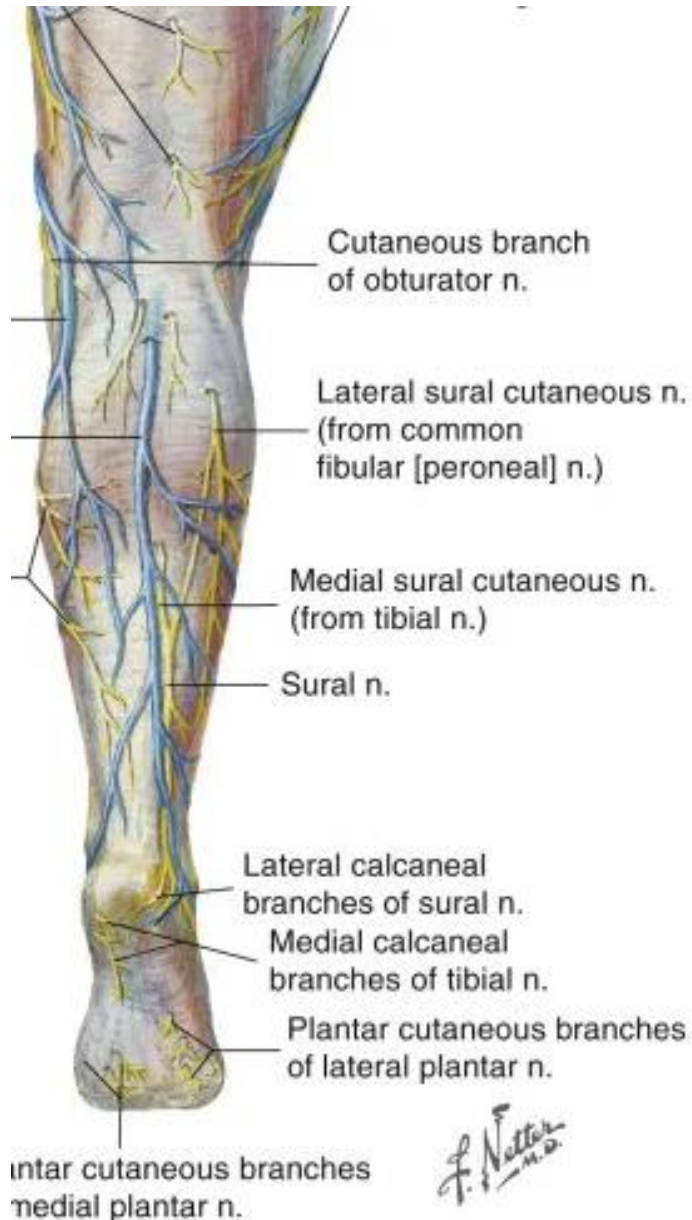


# Posterior division of medial cutaneous nerve of thigh (L2,L3 – branch of anterior division of femoral nerve)



**Skin of uppermost part of medial area of calf**

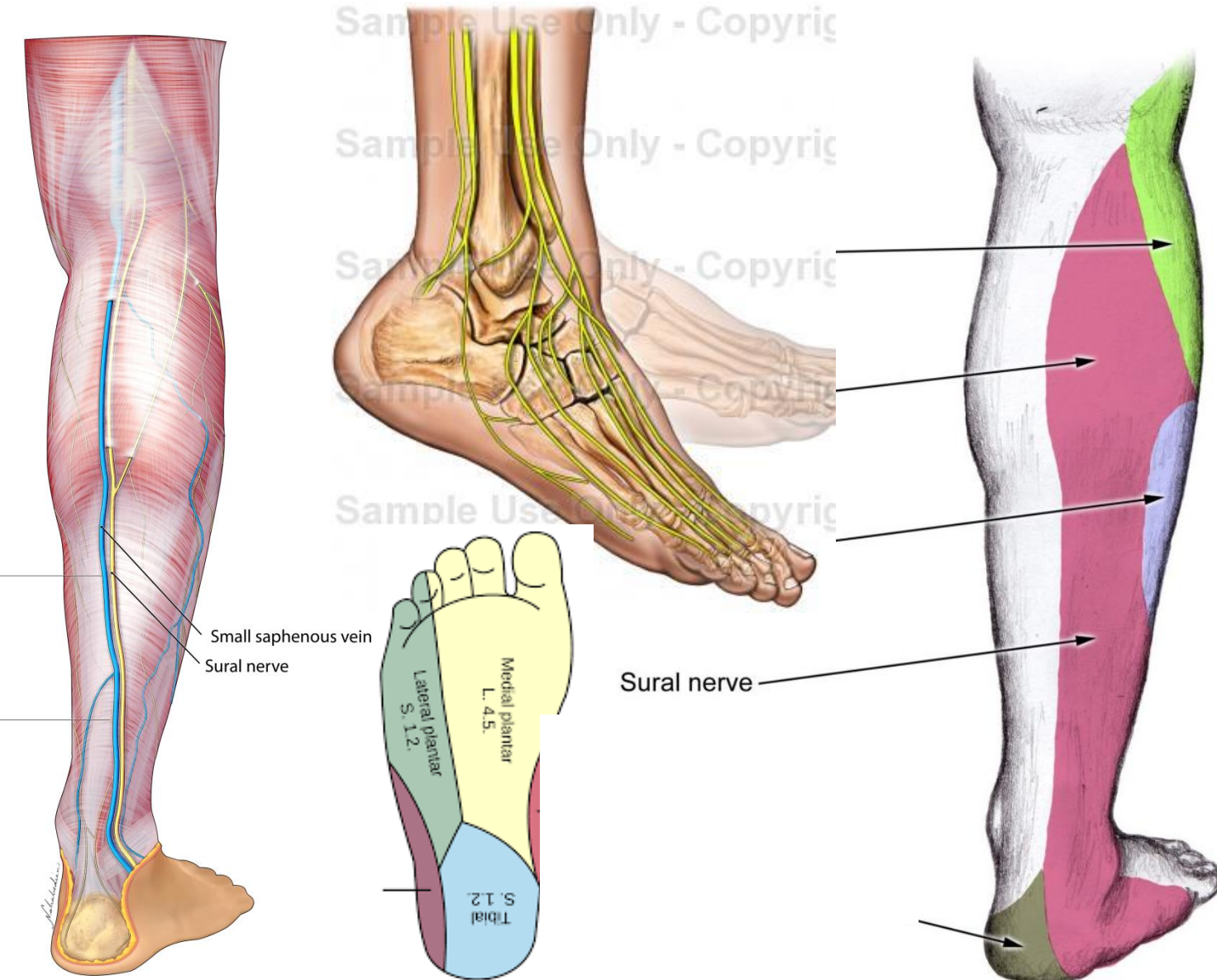
# Posterior cutaneous nerve of thigh (S1,S2,S3 – a branch of sacral plexus)



- Descends along small saphenous vein
- Supplies skin of upper half of calf (the back of leg)

# Sural nerve

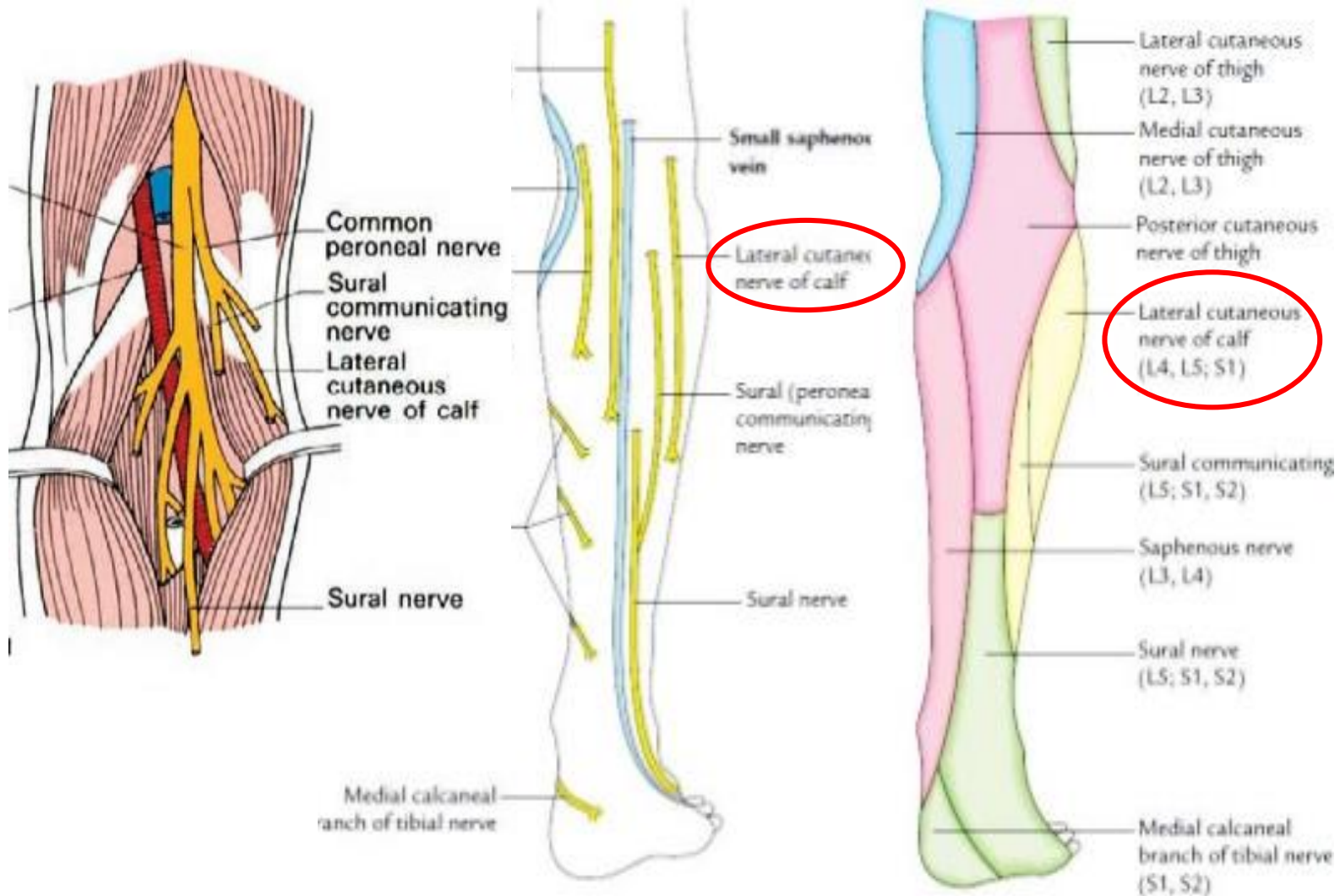
(L5, S1,S2- branch of tibial nerve in popliteal fossa)



- Descends between the two heads of gastrocnemius
- Accompanies small saphenous vein
- Peroneal communicating nerve joins it 5 cm above heel
- Passes behind lateral malleolus
- Runs forwards towards lateral border of foot
- Ends near lateral side of little toe

# Lateral cutaneous nerve of calf

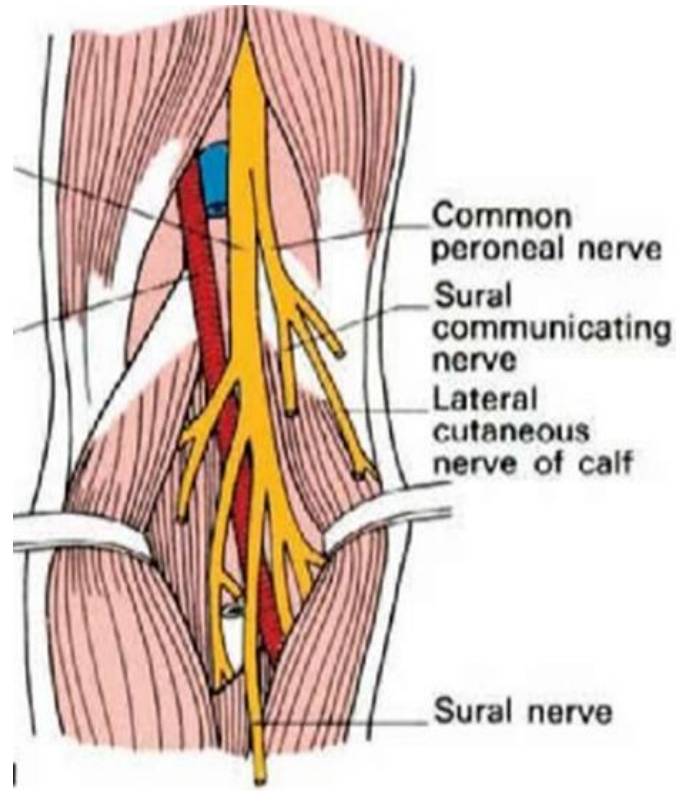
(L4,L5,S1-branch of common peroneal nerve in popliteal fossa)



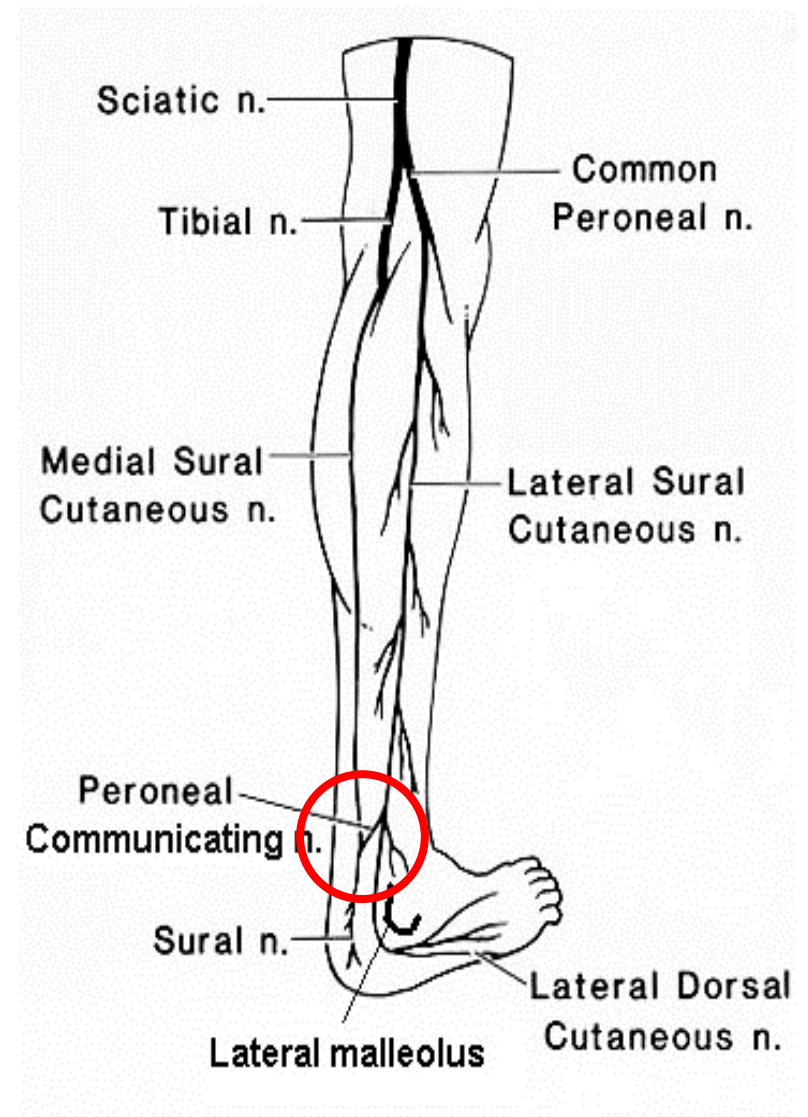
- Supplies skin of upper 2/3<sup>rd</sup> of lateral part of leg (in front & back)

# Peroneal / Sural communicating nerve

(L5,S1,S2-branch of common peroneal nerve)



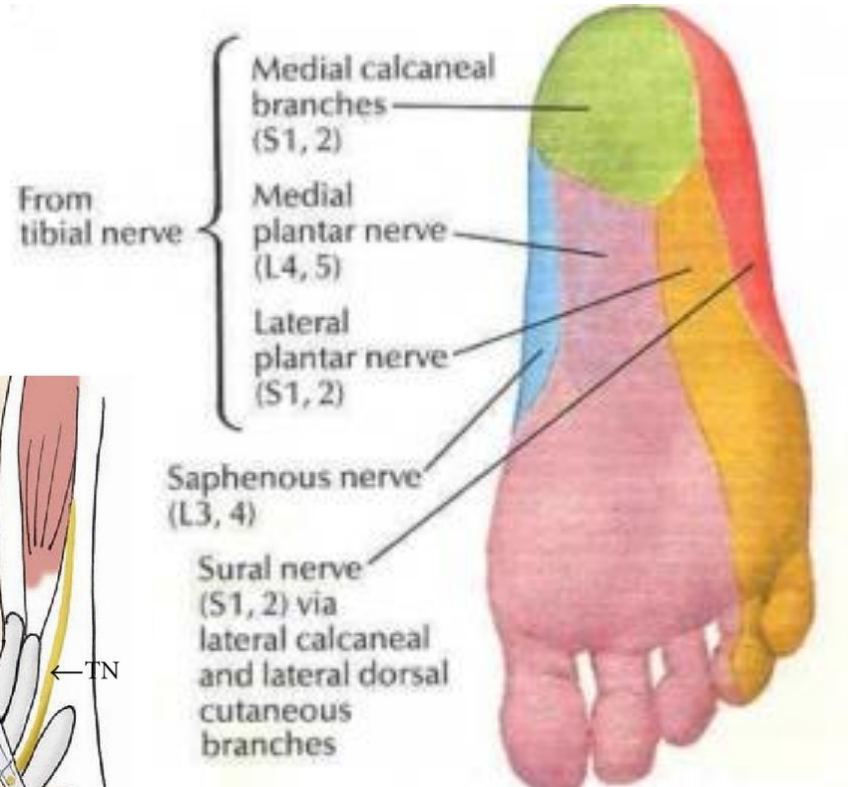
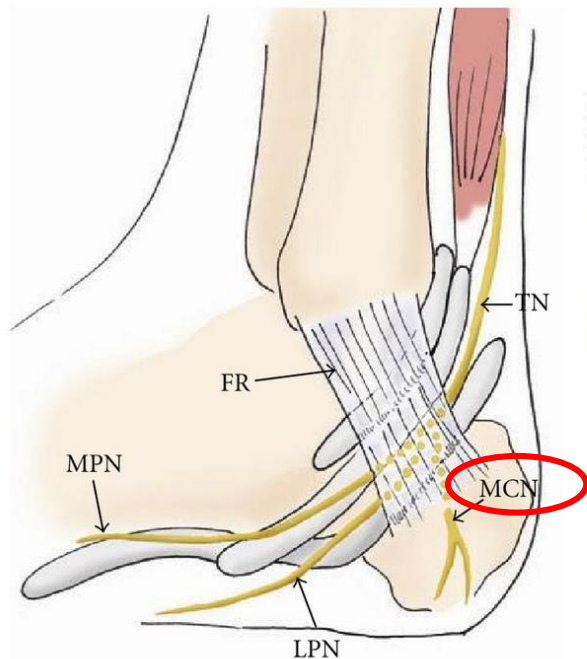
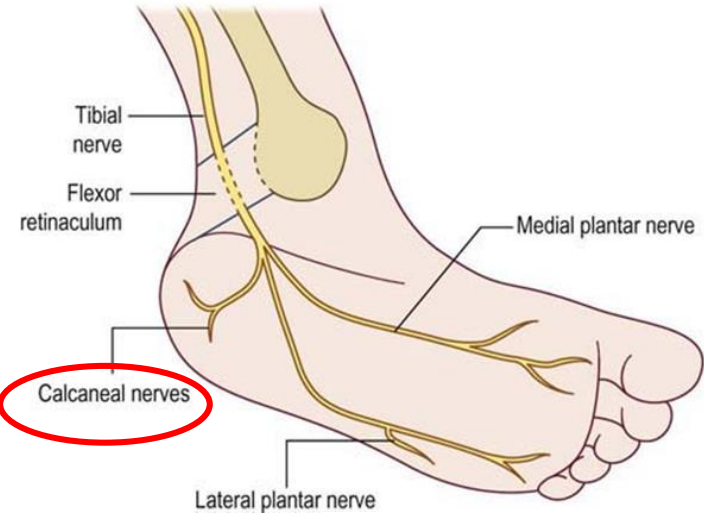
- Origin from common peroneal nerve
- Descends in back of leg
- Joins sural nerve 5cm above heel





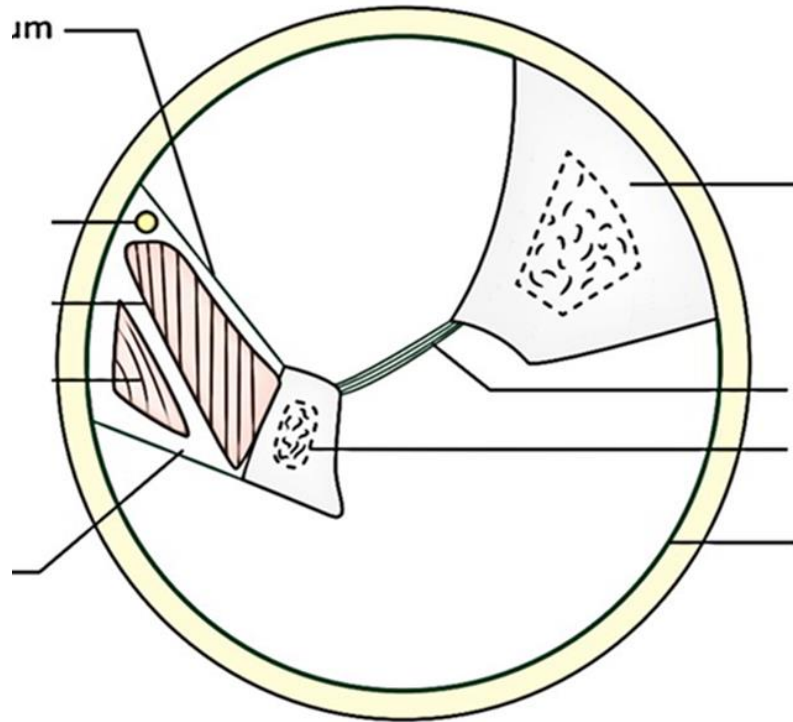
# Calcanean branches of tibial nerve

(S1, S2 –medial calcanean branches of tibial nerve)



- Given off from the tibial nerve close to heel
- Branches pierce the flexor retinaculum
- Supply the skin of
  - Heel
  - Medial side of sole of foot

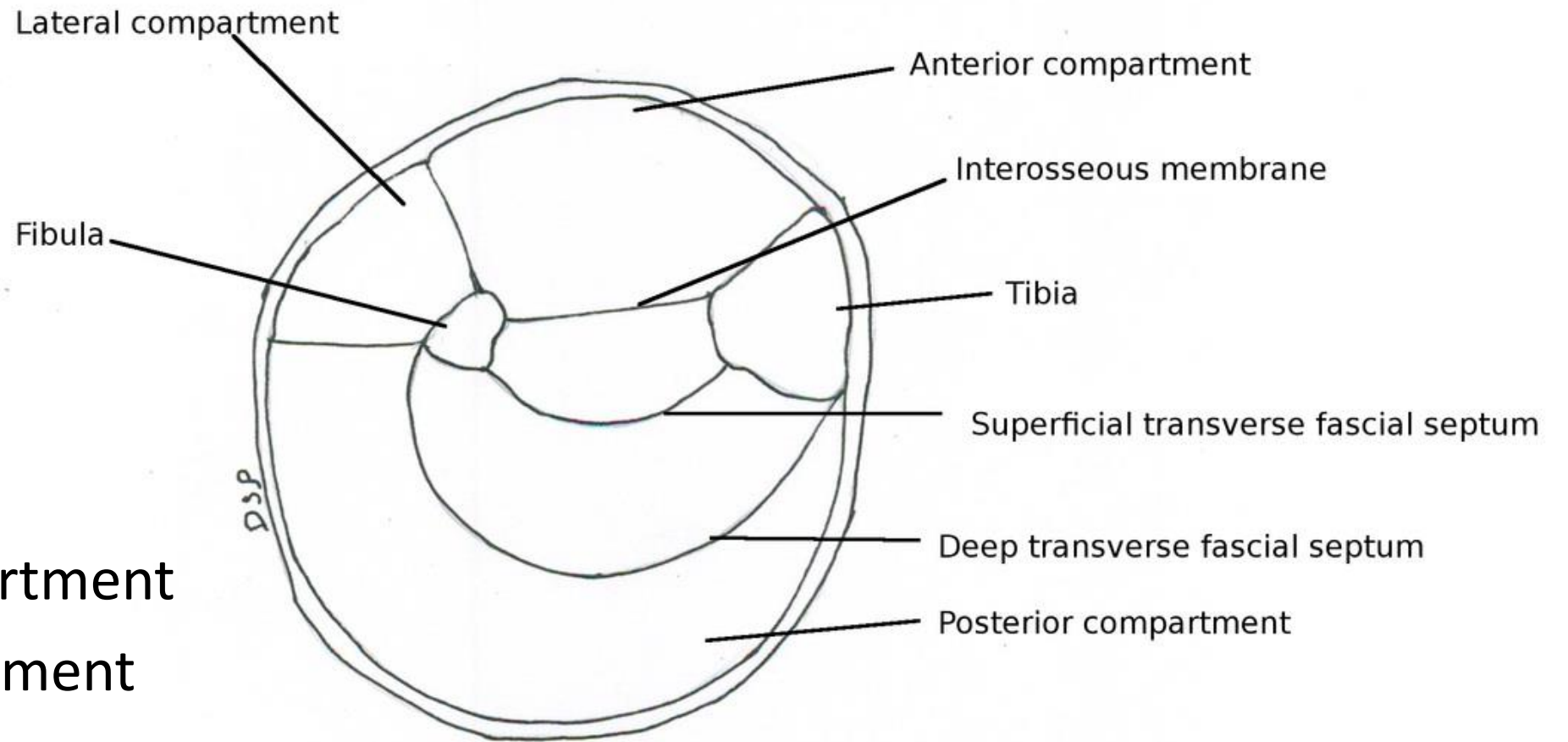
# Deep fascia of leg



**Sleeve of deep fascia**

- Downward continuation of popliteal fascia
- Attached to medial border of tibia
- Surrounds the calf, peroneal compartment then extensor compartment
- Attached to anterior border of tibia
- Attached to lower end of fibula (where it is subcutaneous)
- Forms intermuscular septae
- Posterior intermuscular septum separates lateral from posterior compartment

# Compartments of Leg

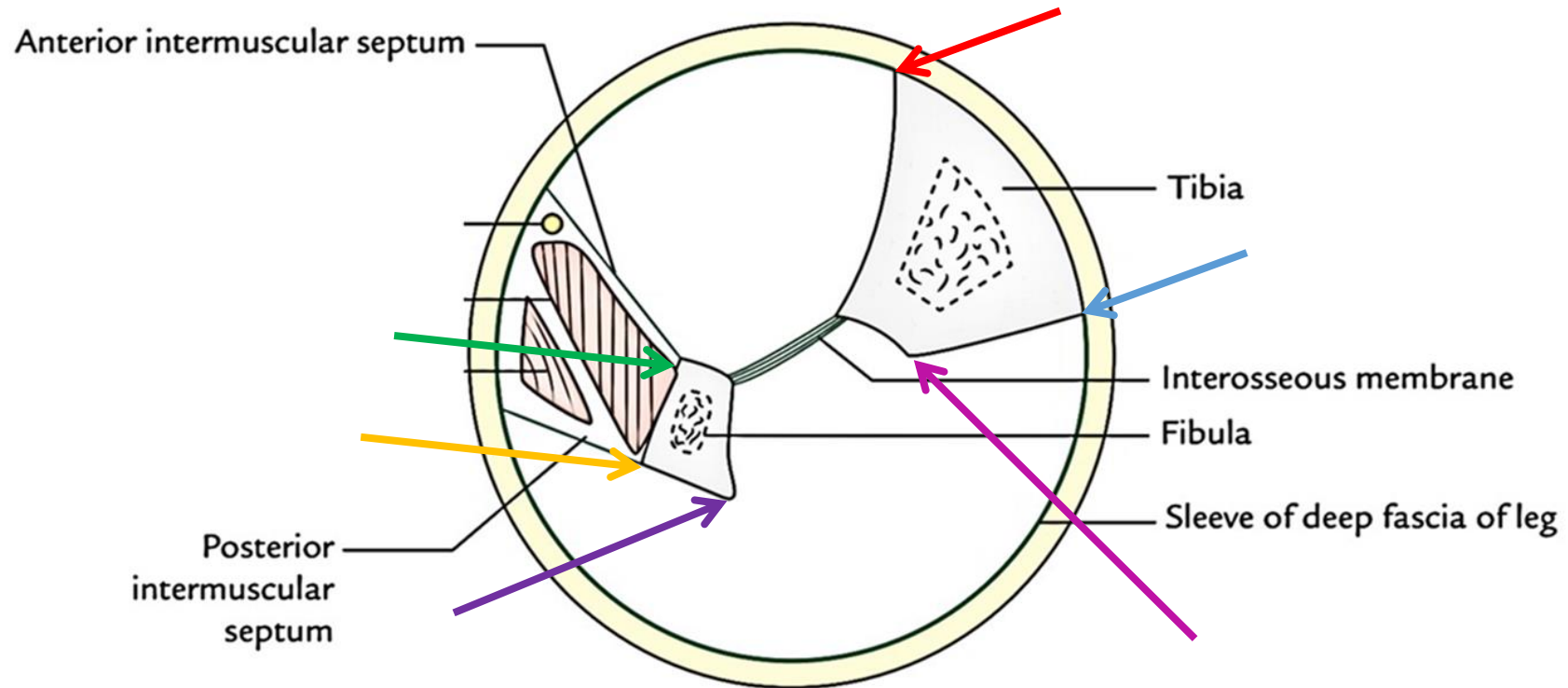


- Anterior compartment
- Lateral compartment
- **Posterior compartment**

# Boundaries



# Boundaries of posterior compartment of leg



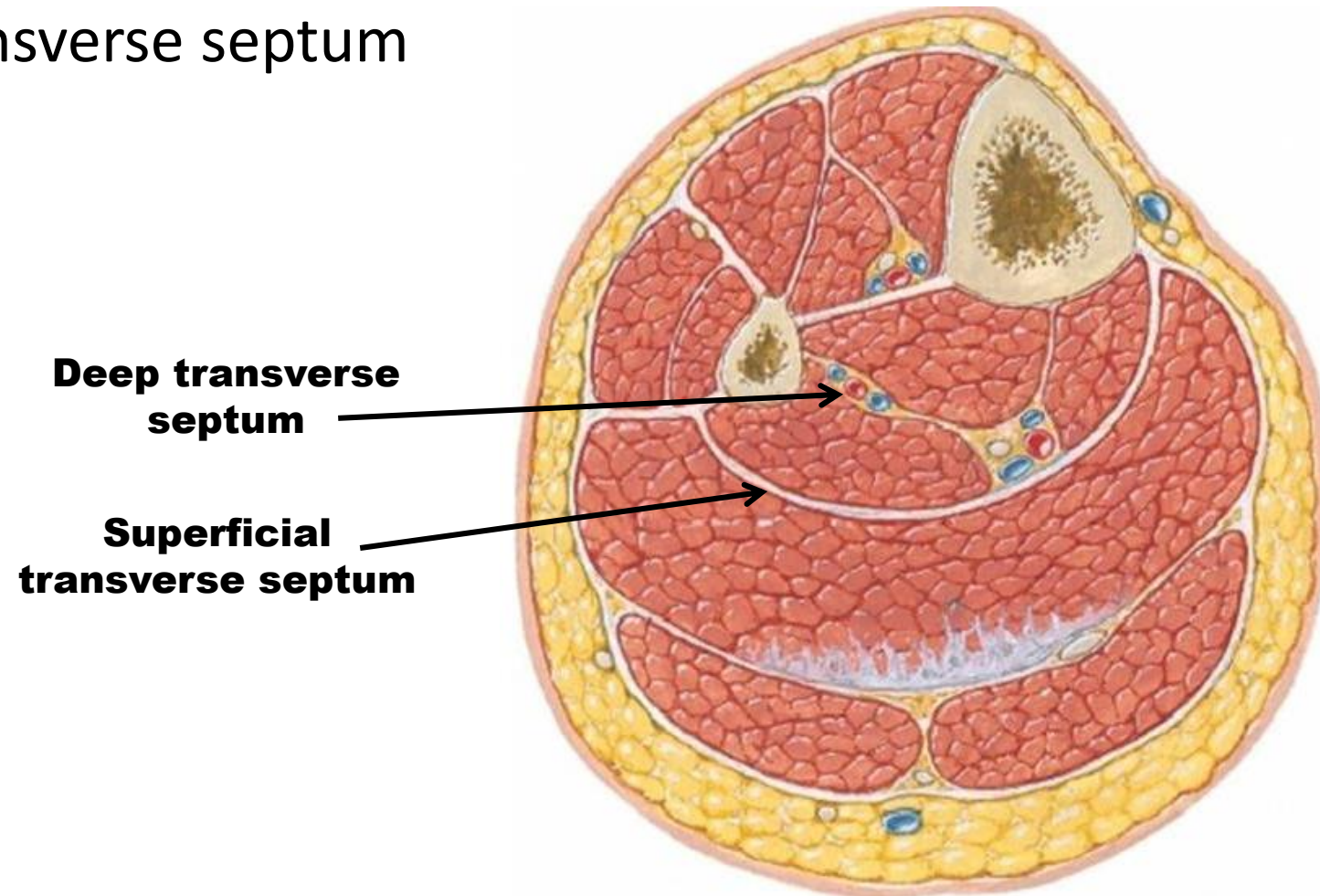
**ANTERIORLY:** Tibia, interosseous membrane, fibula, posterior intermuscular septum

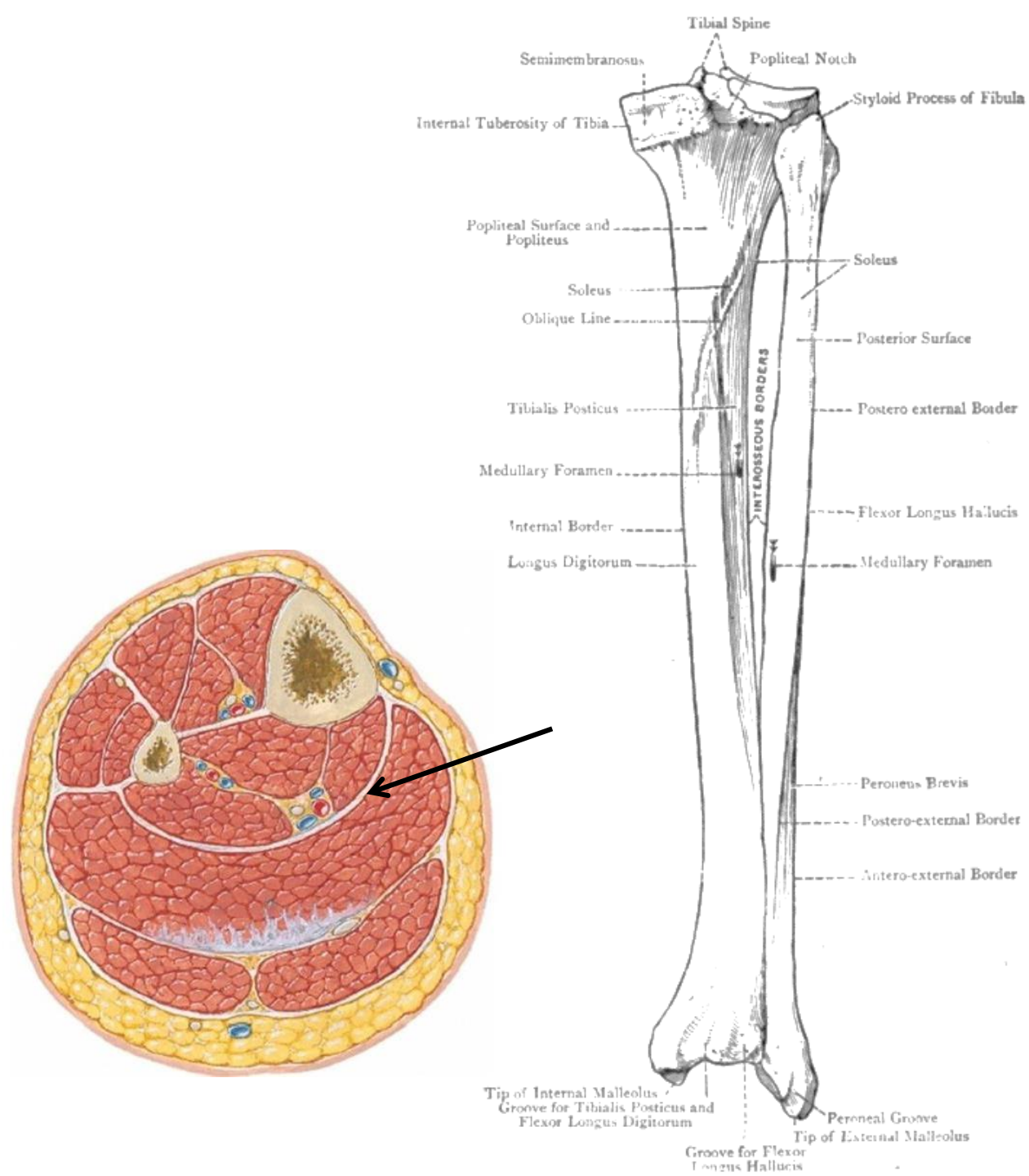
**POSTERIORLY:** Deep fascia of leg

# Deep fascia and modifications in leg

The posterior compartment is divided into **3 subdivisions-** by **2 strong fascial septa** which are:

- Superficial transverse septum
- Deep transverse septum





## Superficial transverse fascial septum

- Separates superficial & deep muscles of back of leg
- Encloses posterior tibial vessels & tibial nerve

### ATTACHMENTS:

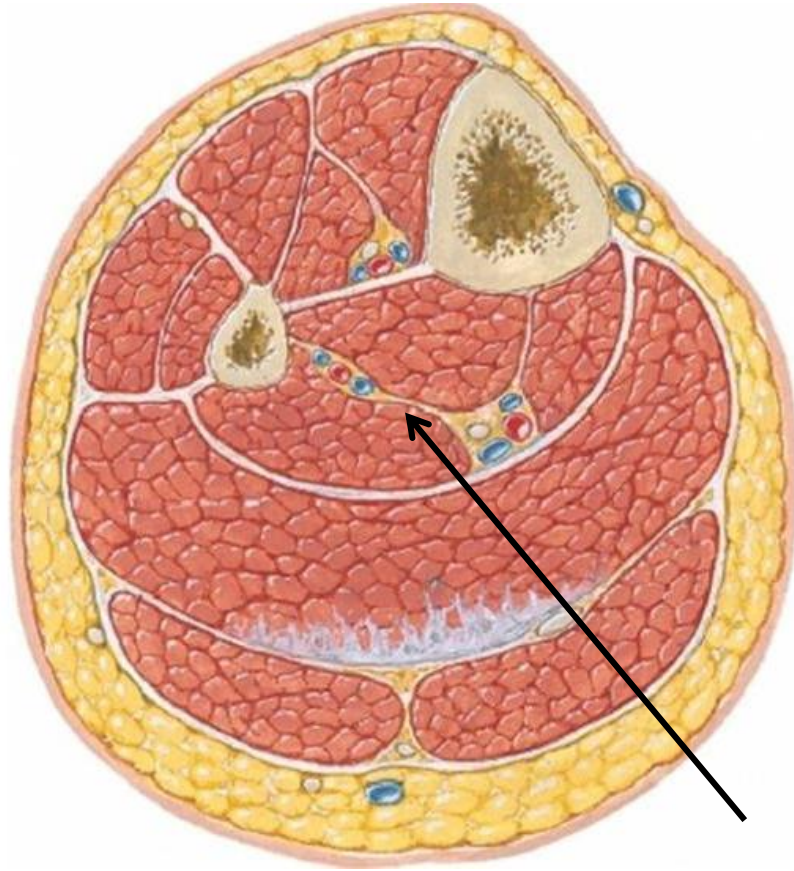
Above- soleal line of tibia & back of fibula

Below- continuous with flexor & peroneal retinacula

Medially – medial border of tibia

Laterally – posterior border of fibula





## Deep transverse septum

Separates tibialis posterior from long flexors of toes

### ATTACHMENTS:

Above- Interosseus membrane

Below- superficial fascial septum

Medially – vertical ridge on posterior surface of tibia

Laterally- Medial crest of fibula

# Flexor retinaculum

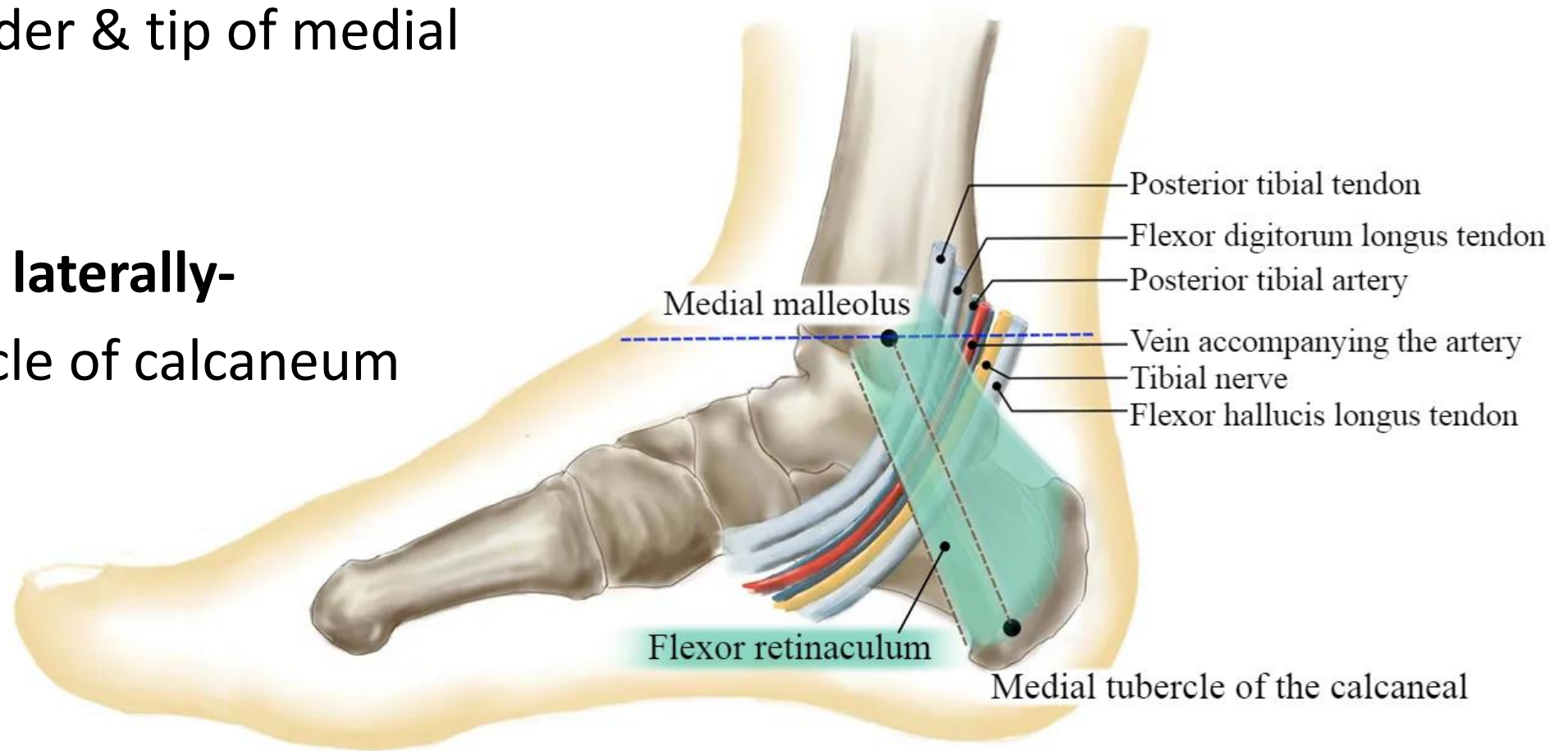
- ATTACHMENTS:

## Anteriorly-

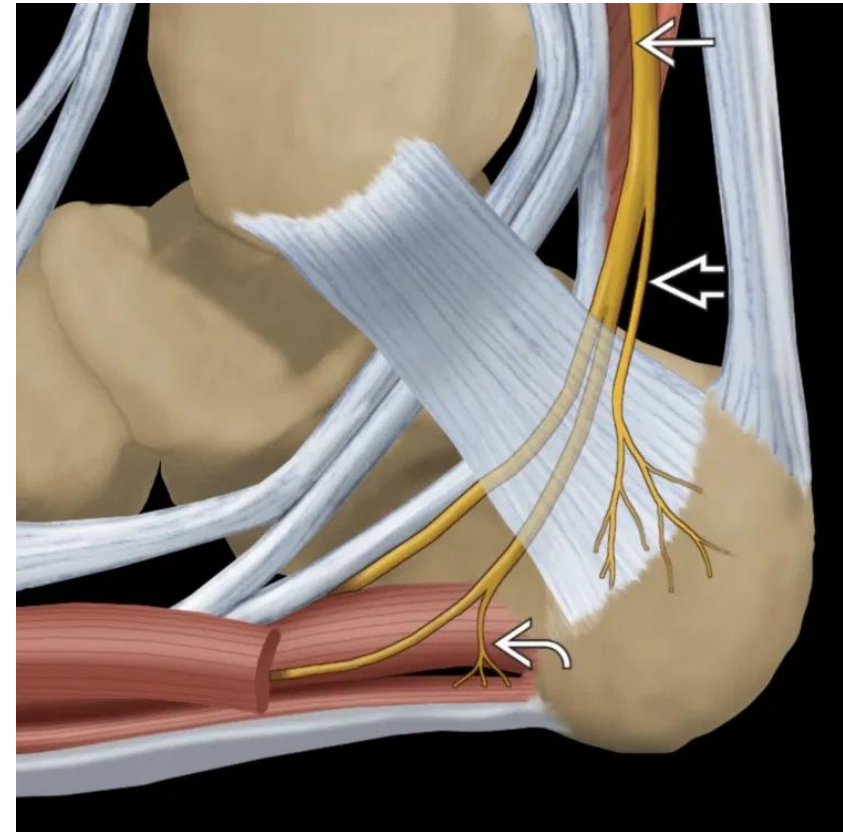
posterior border & tip of medial malleolus

## Posteriorly & laterally-

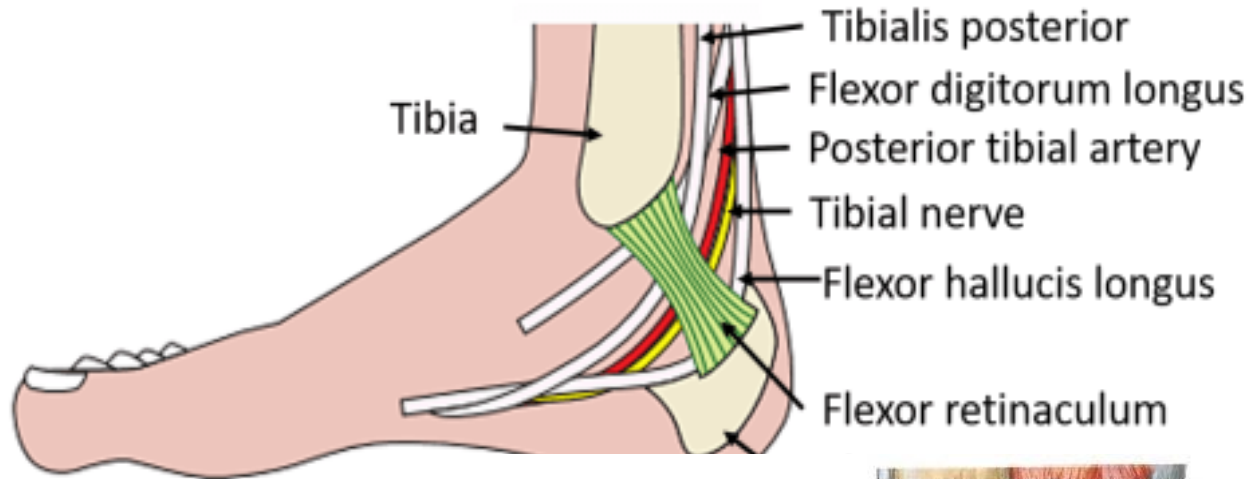
medial tubercle of calcaneum



# Tarsal Tunnel



# Structures passing deep to flexor retinaculum (Medial to Lateral)

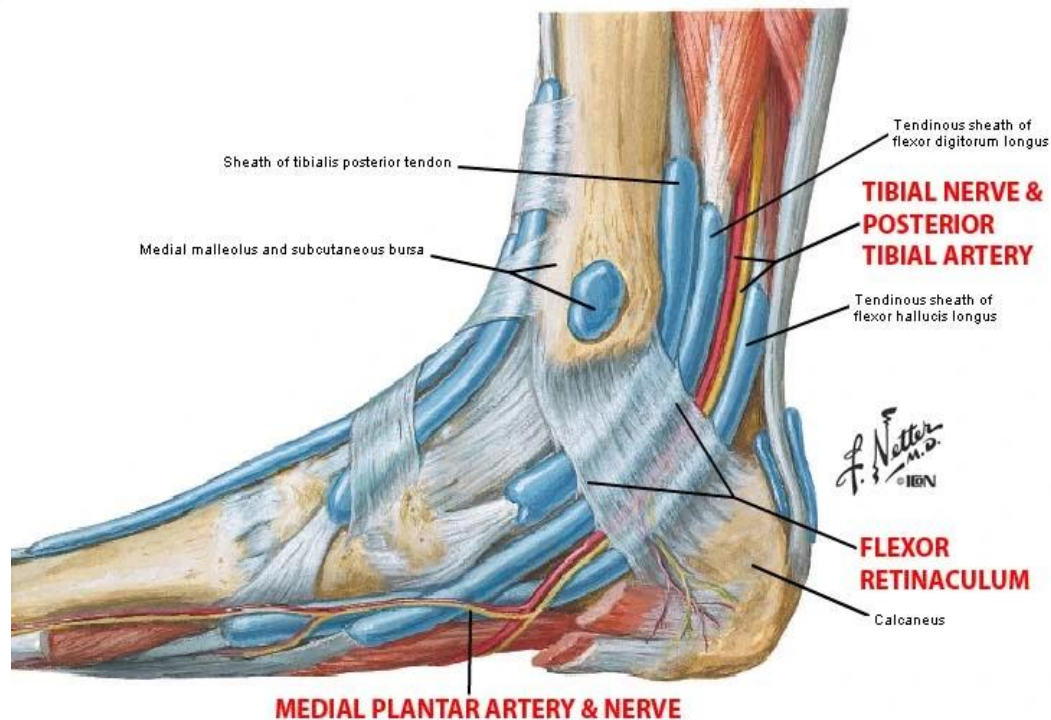


- Tendon of Tibialis Posterior
- Tendon of Flexor Digitorum Longus
- Posterior Tibial artery with its branches & accompanying veins
- Tibial nerve & its terminal branches
- Tendon of Flexor Hallucis Longus

**Each tendon is surrounded by its own synovial sheath**

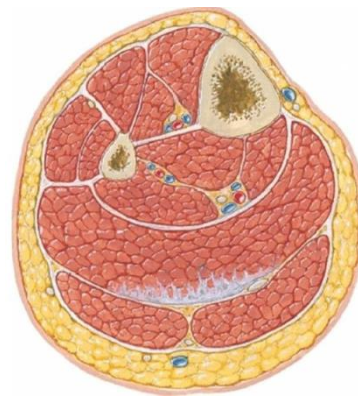
**FR is Pierced by medial calcanean vessels & nerves close to calcaneum**

**Lower part of deep surface gives origin to abductor hallucis muscle**



# Muscles of Back of Leg

# Muscles of Back of leg



## Superficial

1. Gastrocnemius- **Top gear muscle**
2. Soleus- **Bottom gear muscle**
3. Plantaris – **Rudimentary muscle**

Large Gastrosoleus due to erect posture


Divorced tendon of gastrocnemius- long plantar ligament  
Divorced distal part of soleus- FDB

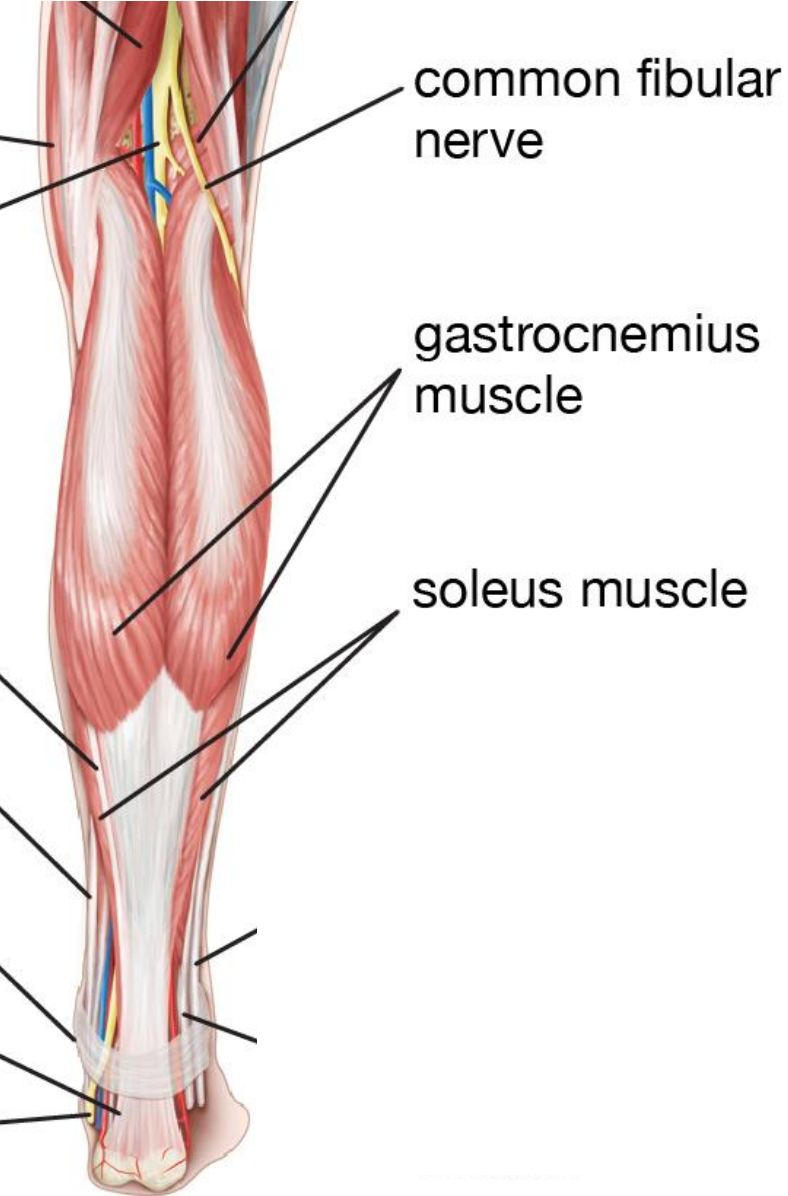
Tendo Calcaneus -strongest tendon

Soleus acts as peripheral heart

## Deep

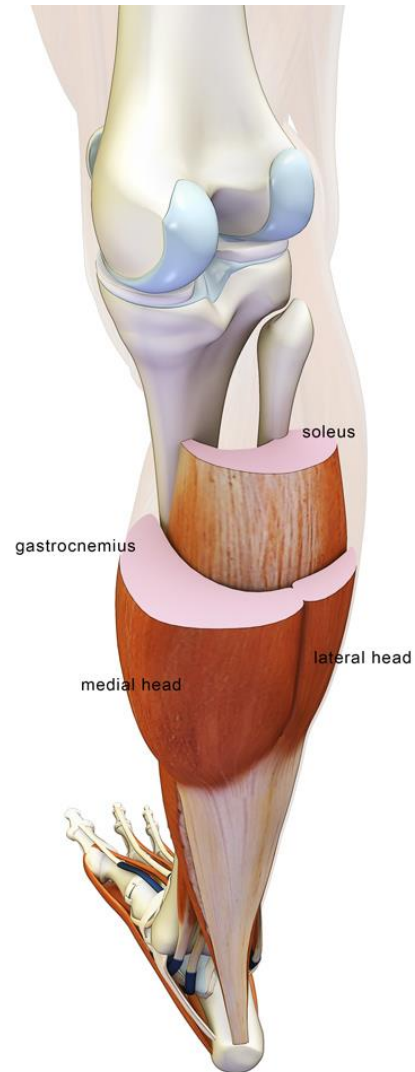
1. Popliteus- **Unlocks the knee joint**
2. Flexor digitorum longus
3. Flexor Hallucis longus
4. Tibialis posterior (**Deepest**)





# Gastrocnemius

(Muscle of top gear)



- Large muscle
- Superficial to soleus
- Has 2 heads
  - Medial head
  - Lateral head
- 2 heads of gastrocnemius & soleus- combine to form- **Triceps Surae**

# Gastrocnemius contd.....

## Origin:

### Medial Head: tendinous origin from-

1. Medial condyle behind adductor tubercle
2. Adjoining popliteal surface
3. Capsule of knee joint

### Lateral Head: tendinous origin from-

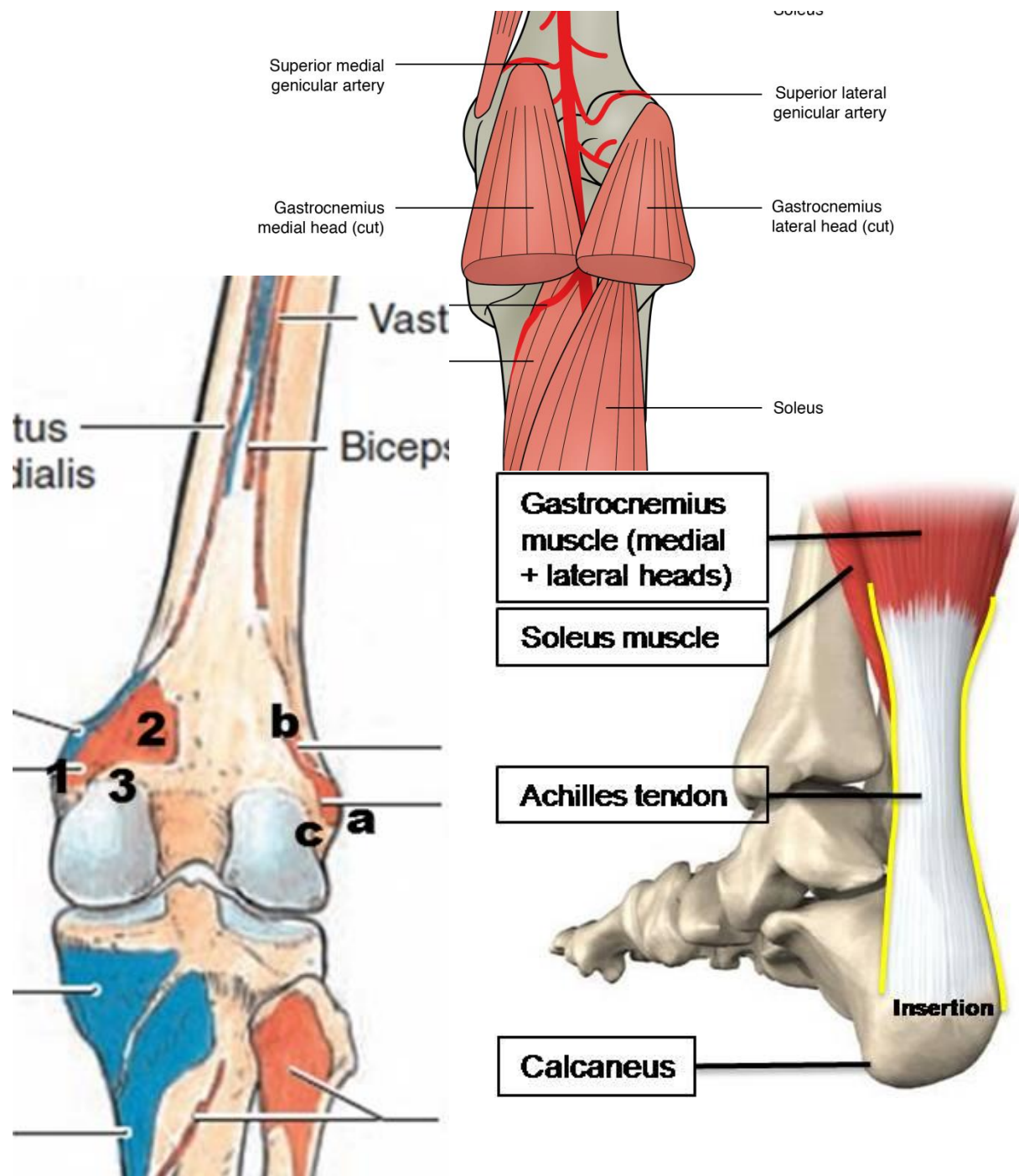
- a. Lateral surface of lateral condyle
- b. Lateral supracondylar line
- c. Capsule of knee joint

## Insertion:

tendon joins tendon of soleus – forms

**Tendo - Achilles** which is

Inserted on middle 1/3rd of posterior surface of calcaneum

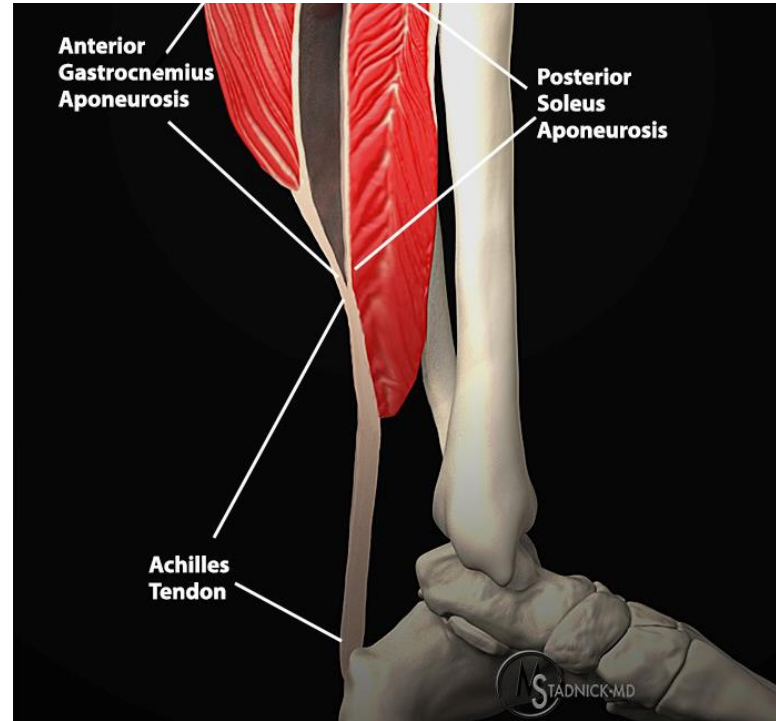
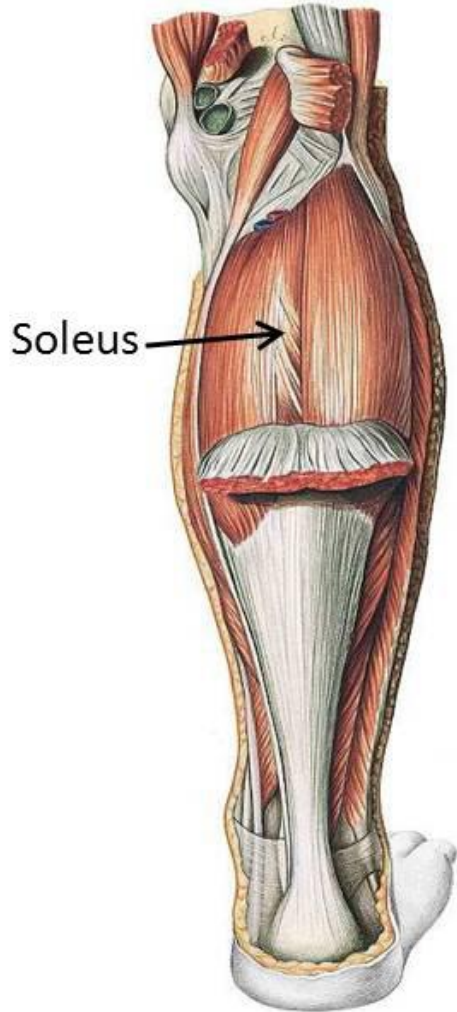






# Soleus

(Muscle of bottom gear)



- **Soleus** is the Latin word for a flat sort of sandal
- Sole shaped muscle
- Deep to gastrocnemius
- Multipennate muscle (power)

## Soleus contd.....

### Origin:

**Dome shaped** origin from-

#### 1. FIBULA

- Back of head
- Upper 1/4<sup>th</sup> of posterior surface

#### 2. TIBIA

- Soleal line
- Middle 1/3<sup>rd</sup> of medial border

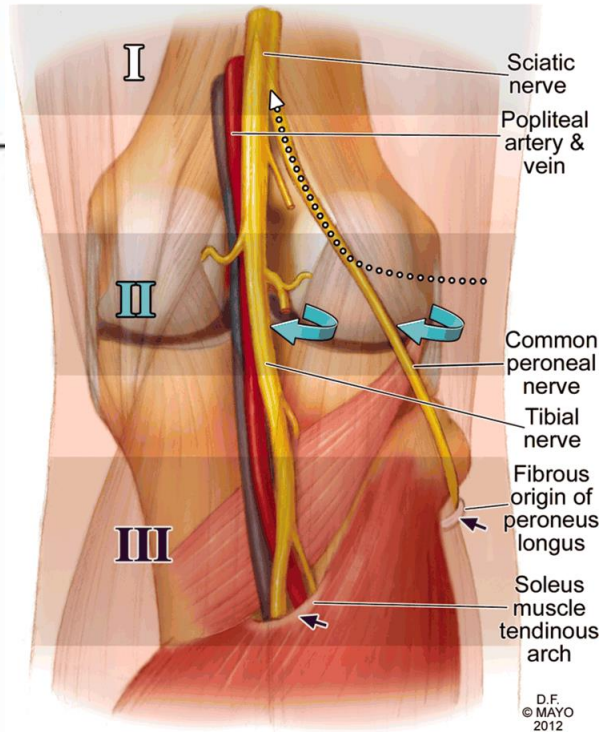
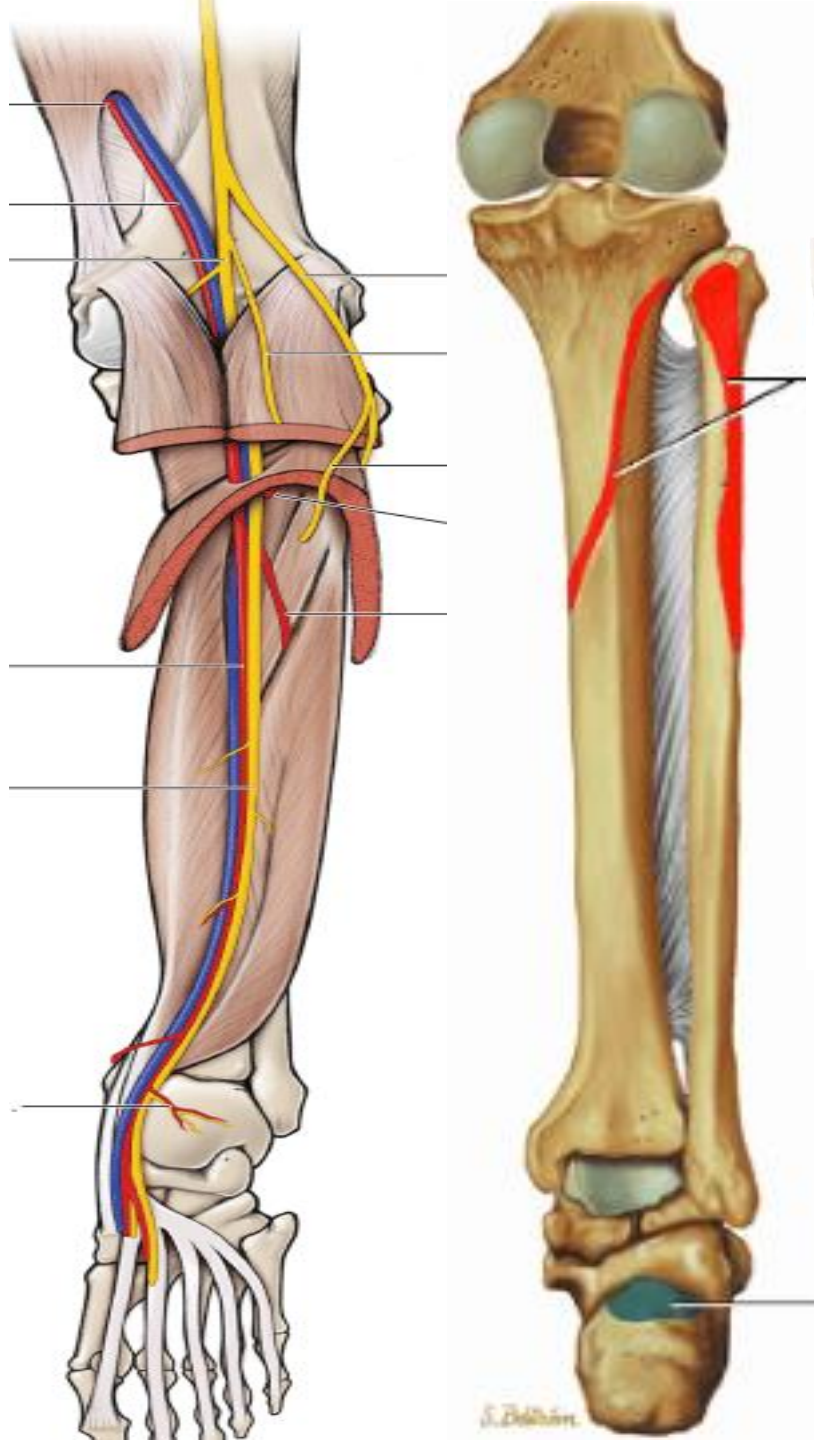
#### 3. SOLEAL ARCH

### Insertion:

tendon joins tendon of gastrocnemius – forms

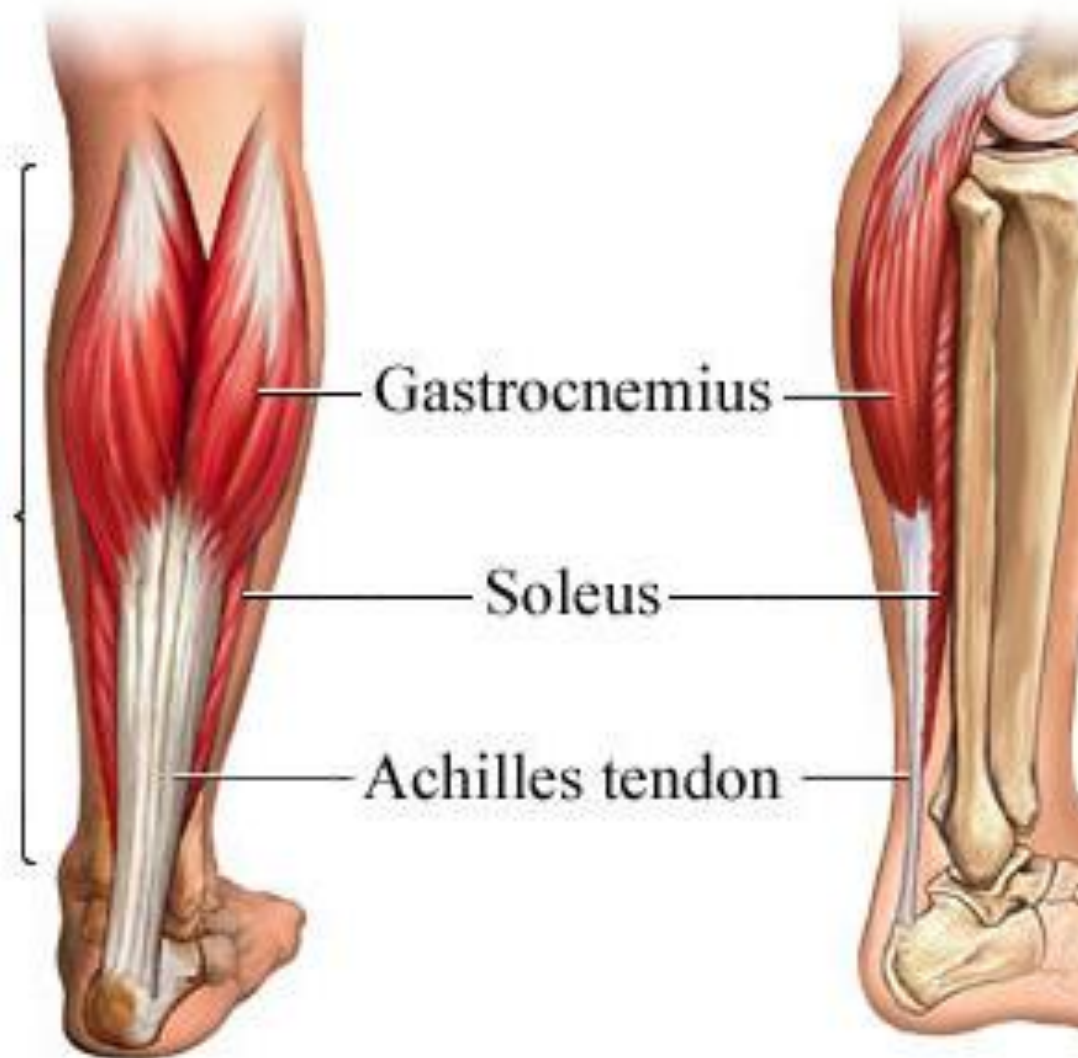**Tendo - Achilles** which is

Inserted on middle 1/3rd of posterior surface of calcaneum



D.F.  
© MAYO  
2012

# Tendo Achilles



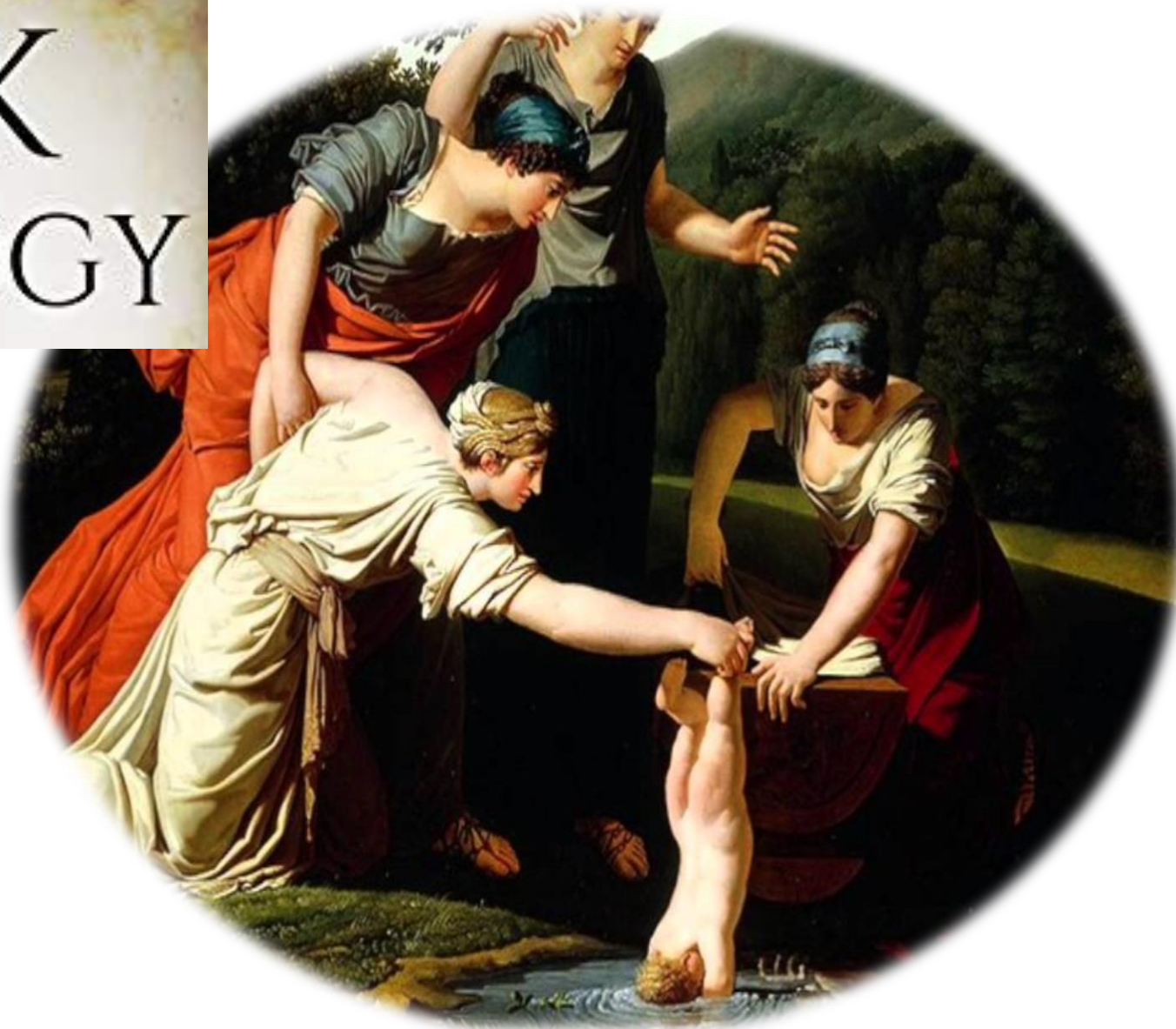- Thickest and strongest tendon
- 15 cm long

## Begins:

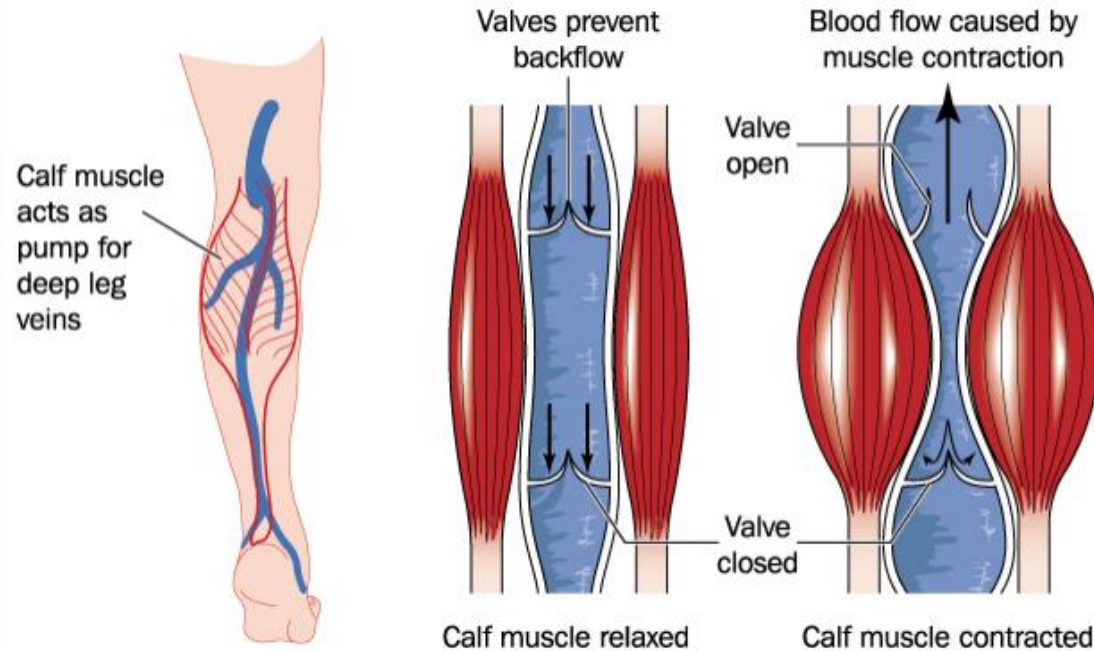
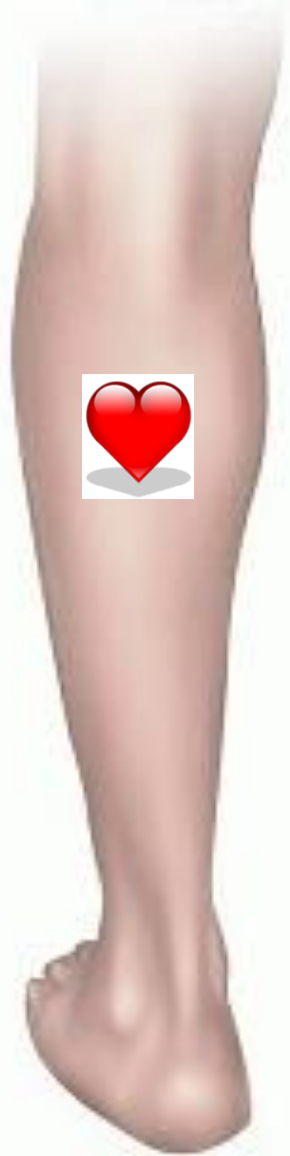- Middle of leg
- Receives fibres of soleus on deeper aspect almost upto its end

## **Naming of Tendo Achilles?**

GREEK  
MYTHOLOGY



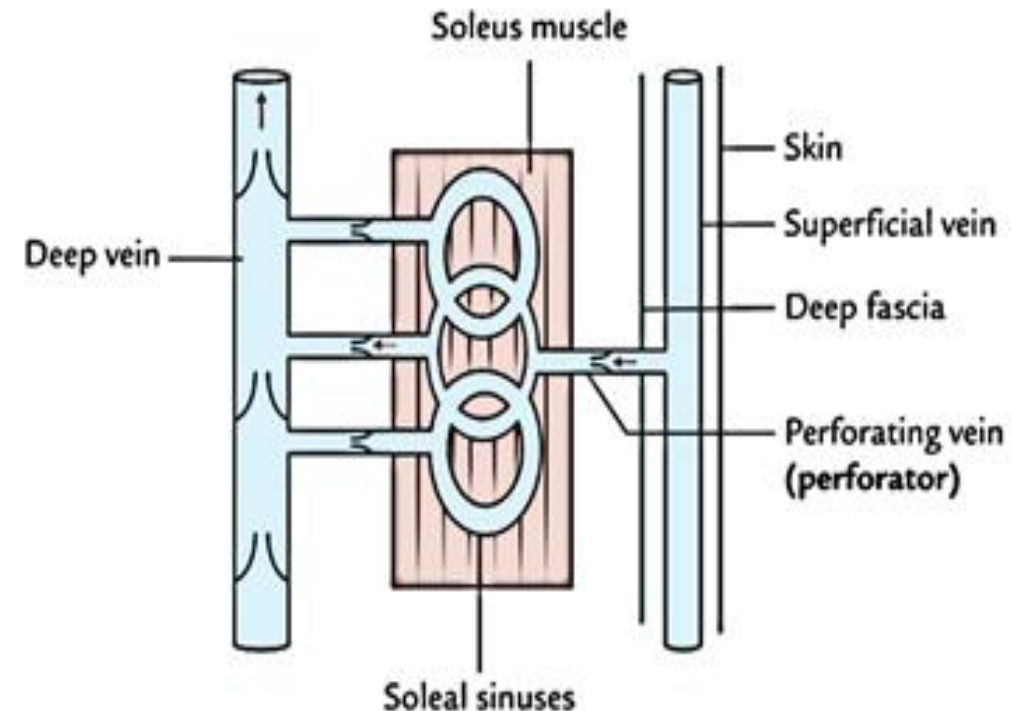
# Soleus- peripheral heart



Calf muscle acts as pump for deep leg veins

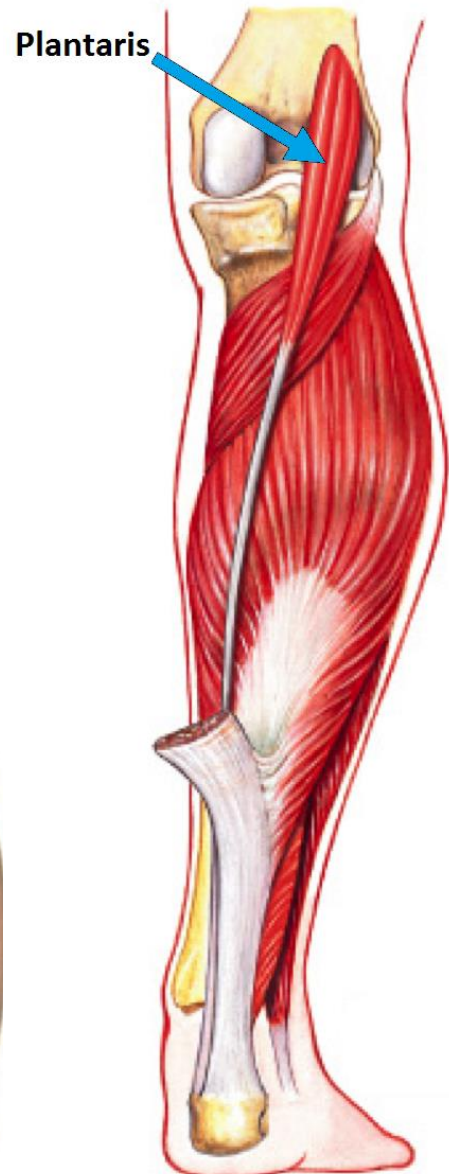
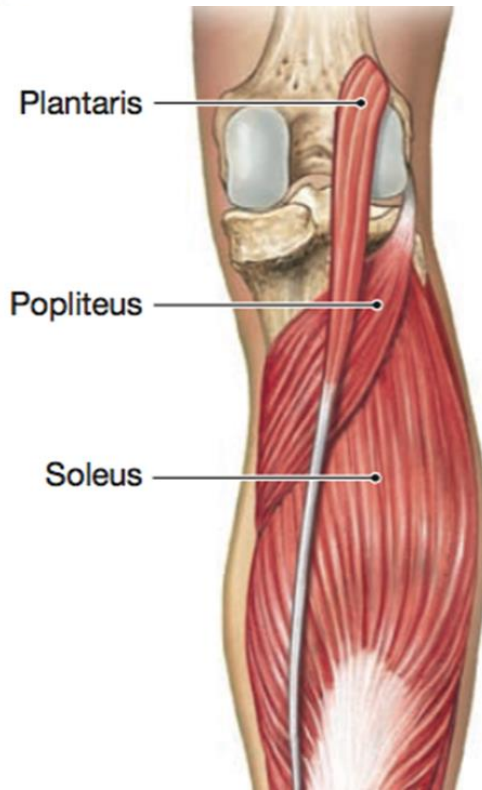
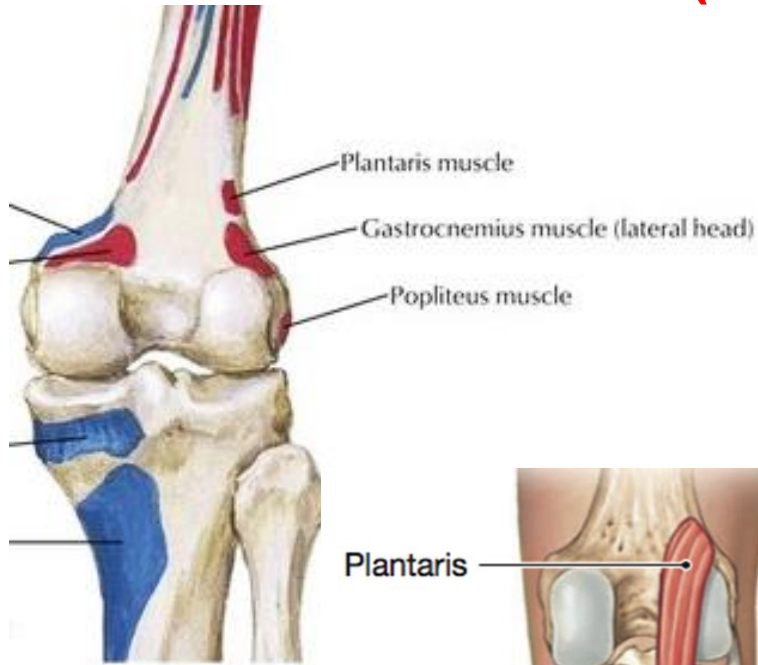
Large valveless venous sinuses in soleus  
Blood in sinuses pushed upwards on muscle contraction  
When the muscle relaxes the sinuses suck in blood through perforating veins

- Muscles of calf play an important role in circulation
- Contraction helps in venous return
- Specially soleus- **peripheral heart**



# Plantaris

(vestigial muscle - short belly, long tendon)



## Origin:

1. Lower part of lateral supracondylar line of femur
2. Oblique popliteal ligament

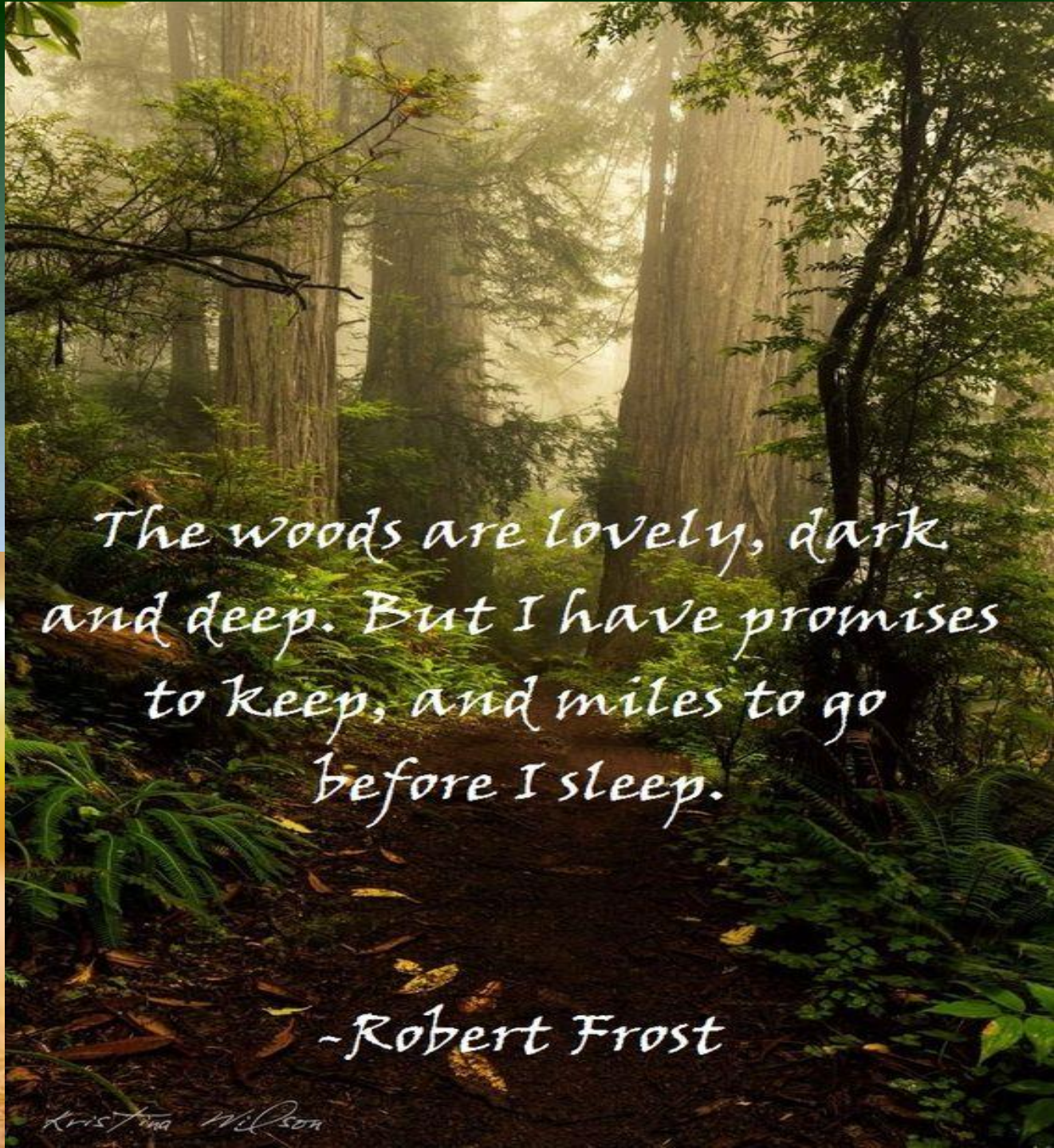
## Insertion:

tendon lies between gastrocnemius & soleus

Inserted on posterior surface of calcaneum, medial to tendo - calcaneus

# Superficial muscles- nerve supply & actions

Muscles	Nerve Supply	Actions
<b>Gastrocnemius</b>	Tibial nerve (S1,S2)	Gastrocnemius & soleus – Strong plantar flexors of foot Help in walking & running Gastrocnemius- also flexor of knee
<b>Soleus</b>	Tibial nerve (S1,S2)	Soleus- more powerful ( <b>initiates movement – 1<sup>st</sup> gear muscle</b> ) Gastrocnemius- faster acting ( <b>provides speed – top gear</b> )
<b>Plantaris</b>	Tibial nerve (S1,S2)	Rudimentary muscle Accessory to gastrocnemius <b>Importance- transplantation of its tendon for tendon repair</b>



*The woods are lovely, dark  
and deep. But I have promises  
to keep, and miles to go  
before I sleep.*

*-Robert Frost*

*Kristina Wilson*