

Costovertebral angle tenderness | encyclopedia article by TheFreeDictionary

https://encyclopedia.thefreedictionary.com/Costovertebral+angle+tenderness

Correct all you're your grammar errors instantly. Try it now.

REVIEWED

By Chris at 10:40 am, Oct 29, 2020

Costovertebral angle tenderness

Also found in: [Acronyms](#).

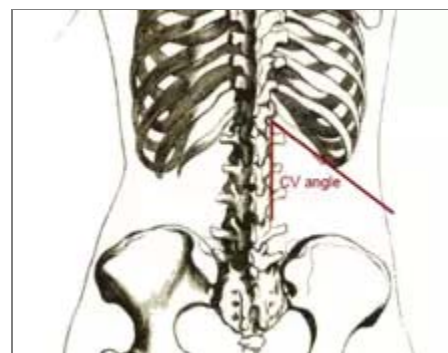
Not to be confused with [Murphy's sign](#), pain on inspiration when the gallbladder is pressed on.

Costovertebral angle tenderness (CVAT), also known as **Murphy's punch sign** or **Pasternacki's sign** or **Goldflam's sign** (Latin: *succusio renalis*), is a medical test in which pain is elicited by **percussion** of the area of the back overlying the **kidney** (the costovertebral angle, an angle made by the vertebral column and the **costal margin**). The test is positive in people with an infection around the kidney (**perinephric abscess**), **pyelonephritis**, hemorrhagic fever with renal syndrome or renal stone. Because the kidney is directly anterior to this area, known as the costovertebral angle, tapping disturbs the inflamed tissue, causing pain.

This medical test was first described by the American surgeon John Benjamin Murphy in 1884, but in the **Post-Soviet states** and **Eastern Europe**, it is often called Pasternacki's sign, after **Belorussian** internist Fiodor Ignatjevich Pasternacki (1845–1902), who described it during his rounds in a regional hospital in **Minsk** in 1888. In Poland it is often called Goldflam's sign, after Polish neurologist **Samuel Goldflam**, who described it in 1900.^{[1][2][3][4]} In Italy it is called Giordano's test (Manovra di Giordano).

References

- [^] Oh, Timothy T.; Schmitz, Robert L. (1993). *The Remarkable surgical practice of John Benjamin Murphy*. Urbana: University of Illinois Press. ISBN 0-252-01958-X.
- [^] Musana KA, Yale SH (August 2005). "Murphy's Sign". *Clin Med Res*. **3** (3): 132. PMC 1237152 . PMID 16160065. doi:10.3121/cm.3.3.132.
- [^] Musana K, Yale SH (May 2005). "John Benjamin Murphy (1857 - 1916)". *Clin Med Res*. **3** (2): 110–2. PMC 1183442 . PMID 16012130. doi:10.3121/cm.3.2.110.
- [^] <http://www.whonamedit.com/doctor.cfm/2803.html>



The costovertebral angle is located in the back between the 12th rib and the spine

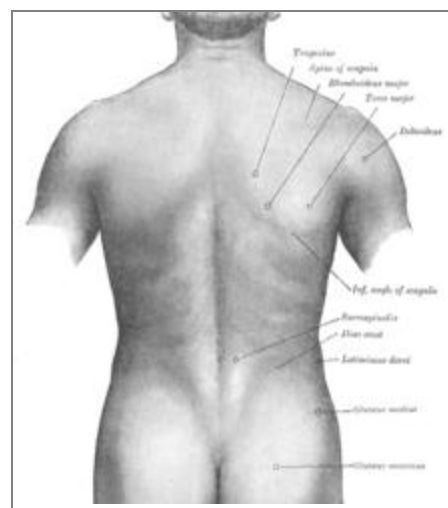
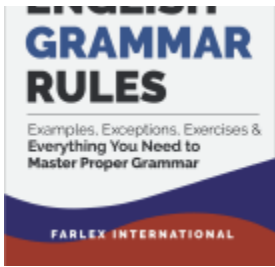

Image of a human back

This article is copied from an [article on Wikipedia®](#) - the free encyclopedia created and edited by its online user community. The text was not checked or edited by anyone on our staff. Although the vast majority of Wikipedia® encyclopedia articles provide accurate and timely information, please do not assume the accuracy of any particular article. This article is distributed under the terms of [GNU Free Documentation License](#).



Finally, Farlex brings you
all the rules of English
grammar, all in one place,



explained in simple terms.

The Farlex Grammar Book
is available now in
paperback and eBook
formats on [Amazon.com](https://www.amazon.com).

Correct all your your grammar errors instantly. Try it now.

Copyright © 2003-2020 Farlex, Inc

Disclaimer

All content on this website, including dictionary, thesaurus, literature, geography, and other reference data is for informational purposes only. This information should not be considered complete, up to date, and is not intended to be used in place of a visit, consultation, or advice of a legal, medical, or any other professional.