

Chapter 3

Distal Phalangeal and Fingertip Injuries

Leo M. Rozmaryn, MD

Distal phalangeal skeletal and soft tissue injuries are exceedingly common. Taken in their entirety, they constitute the largest percentage of hand injuries seen in the emergency room. The scenarios in which they occur constitute the full palette of human endeavor from work, sports, and the home. They are a leading cause of time lost from work and workers' compensation claims. Children are affected as often as adults. Fingertip injuries represent a broad spectrum of conditions, each with its own set of issues in diagnosis and treatment.

Mechanisms of injuries vary widely from crush, avulsion and degloving, laceration, amputation, eccentric tendon overuse, and hyperflexion or extension of the distal phalanx. They can involve any and all of the structures in the fingertip, and injuries can be open or closed. High-pressure injection injuries are a special type of fingertip injury resulting in a mini-compartment syndrome in the volar pad of the finger that, if not addressed promptly, can result in irreversible ischemia or in gangrene and eventual amputation of the tip. Closed injuries can result in fracture of the distal phalanx, dislocation and collateral ligament injuries of the distal interphalangeal (DIP) joint, closed avulsions of the flexor digitorum profundus (FDP) and mallet fingers, and articular damage that may lead to arthrosis.

Open injuries include dorsal and volar lacerations resulting in trauma to the nail complex or the terminal flexor and extensor tendons and digital nerves and nail bed crush and avulsion injuries, which can coexist with open fracture of the distal phalanx. Degloving injuries to the dorsal or volar skin frequently accompany crush injuries to the fingertip. In extreme cases, the tip of the finger may be amputated by a sharp instrument, leaving a deficit that is either transverse or oblique. Such an injury may occur in the sagittal or coronal plane or the defect can be amorphous such as in a severe crush injury. Amputations frequently have exposed bone.

Treatment of these injuries can vary widely from simple splinting to complex microvascular reconstruction. The goal of treatment is to restore an aesthetically pleasing, painless, tactile, mobile, stable fingertip that can sense pain, temperature, pressure, stereognosis, and fine touch. The fingertip must also be the terminus of the gripping mechanism of the hand. Unfortunately, all too often, these injuries are underrecognized (and, therefore, undertreated), resulting in persistent tip numbness, cold sensitivity, nail growth abnormalities, nail fold and volar pad deformities, hypesthesia, dysesthesia, and painful stiffness of the DIP joint. A knowledgeable hand surgeon ideally is the most appropriate person to manage these injuries.

The purpose of this chapter is to outline the various categories of injury to the fingertip and distal phalanx, anatomy,

physiology, mechanism of injury, treatment options, outcomes, and possible complications. Hopefully, it will serve to increase awareness of these frequently undertreated injuries and lead to better care.

Distal Phalanx Fractures

Distal phalanx fractures are the most common fracture seen in the hand. In 1988, Schneider¹ classified these fractures into 4 types:

Tuft fractures: simple and comminuted

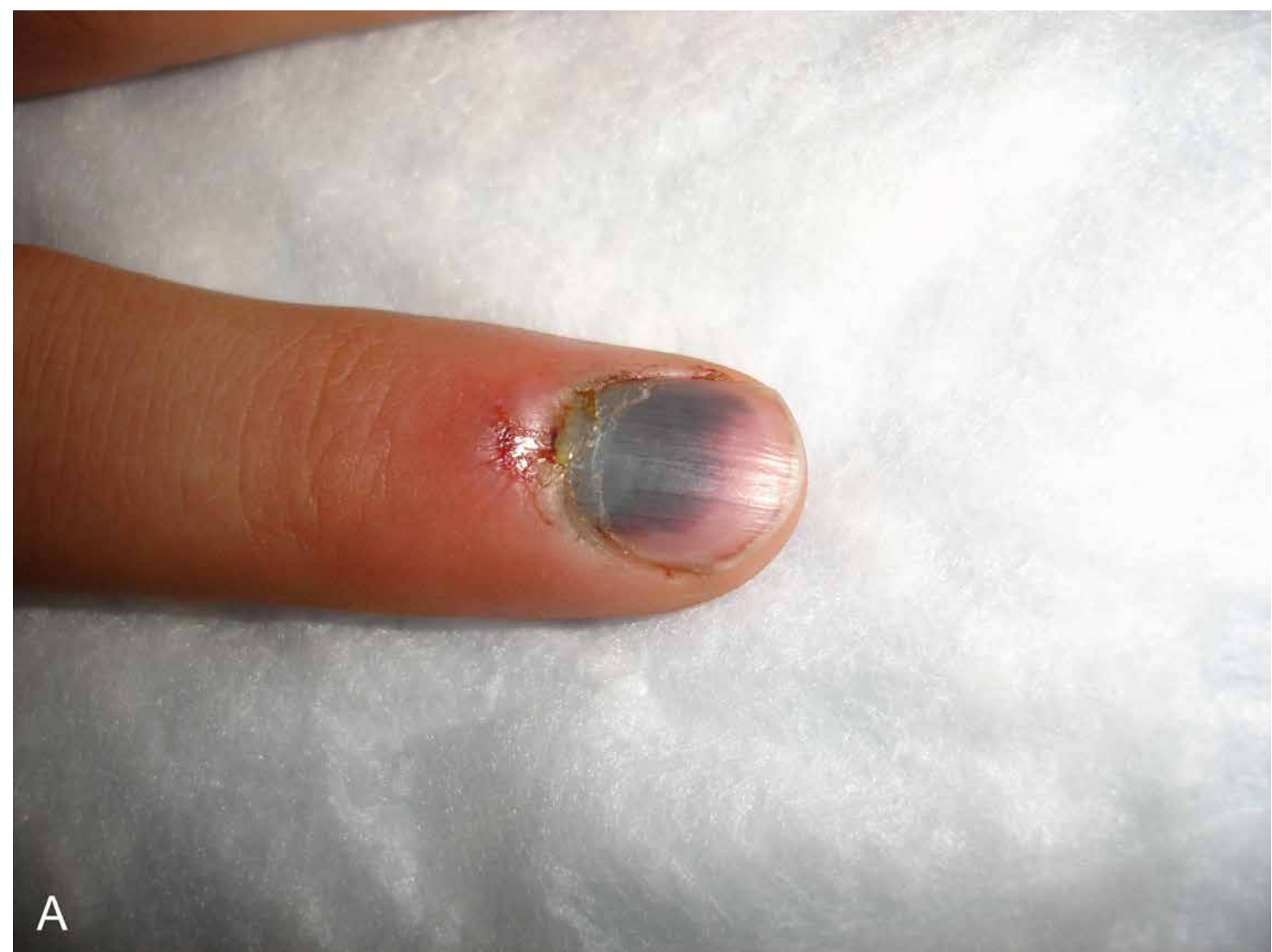
- **Shaft fractures:** transverse—stable and unstable, longitudinal
- **Articular fractures:** volar (profundus avulsion), dorsal mallet
- **Epiphyseal:** child (Salter I or II), adolescent (Salter III)

Tuft Fractures

Tuft fractures are generally associated with crush injuries and may be accompanied by open and closed injuries to the nail bed or volar pad. The force of the crush and its duration will determine the extent of the injury. Less severe injuries are frequently accompanied by mild swelling and ecchymosis (Figure 3-1). As the severity of the crush increases, the volar pad can become turgid and a subungual hematoma may develop as the sterile matrix of the nail bed lacerates under a nail plate that is otherwise adherent at the edges (Figure 3-2A). This laceration creates a communication between the tuft fracture and the underside of the nail plate. Eventually, the nail plate avulses and the nail bed lacerates. The bony tuft may or may not rupture through the sterile matrix of the nail bed. The laceration can extend around the nail folds to the volar side (Figure 3-3). If the crush is severe enough, the tip may simply amputate with or without the crushed bone.

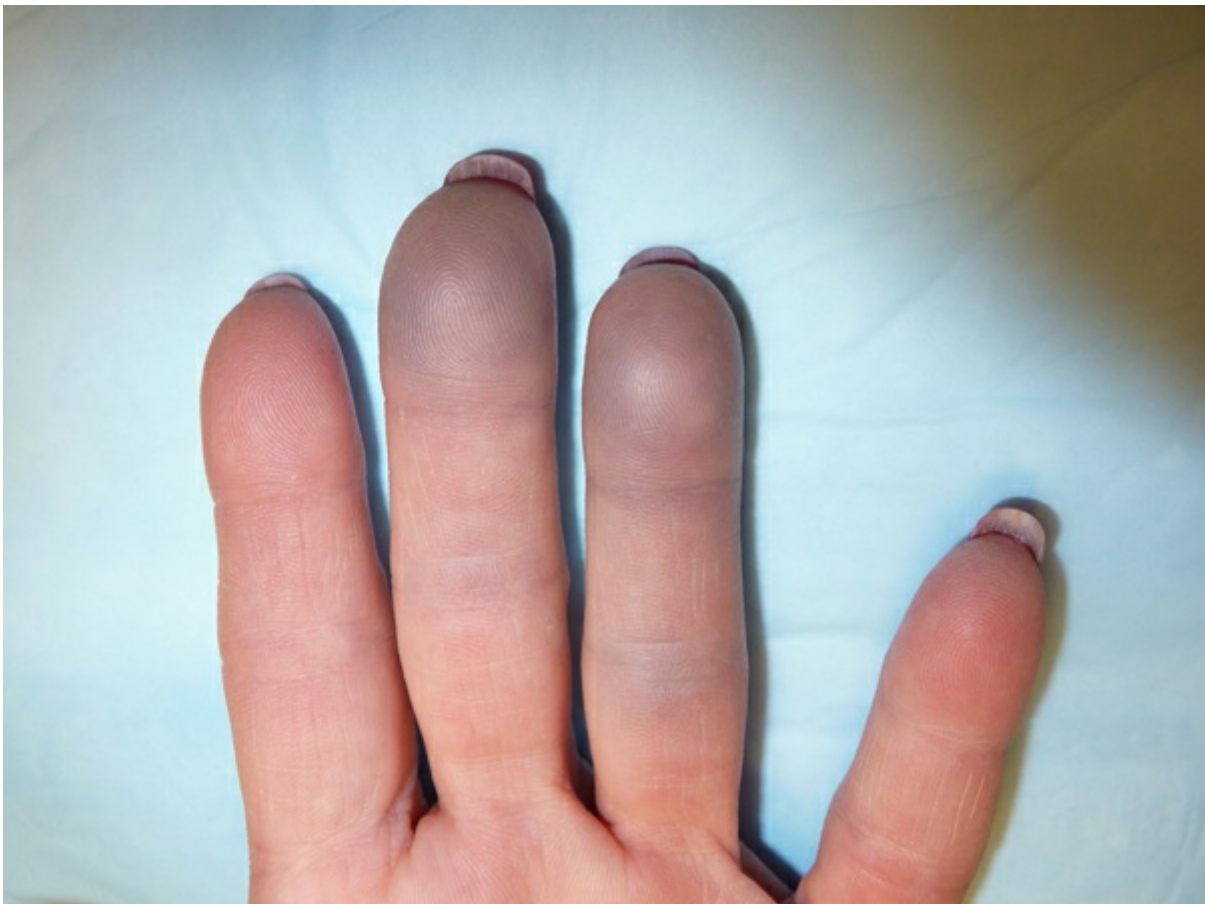

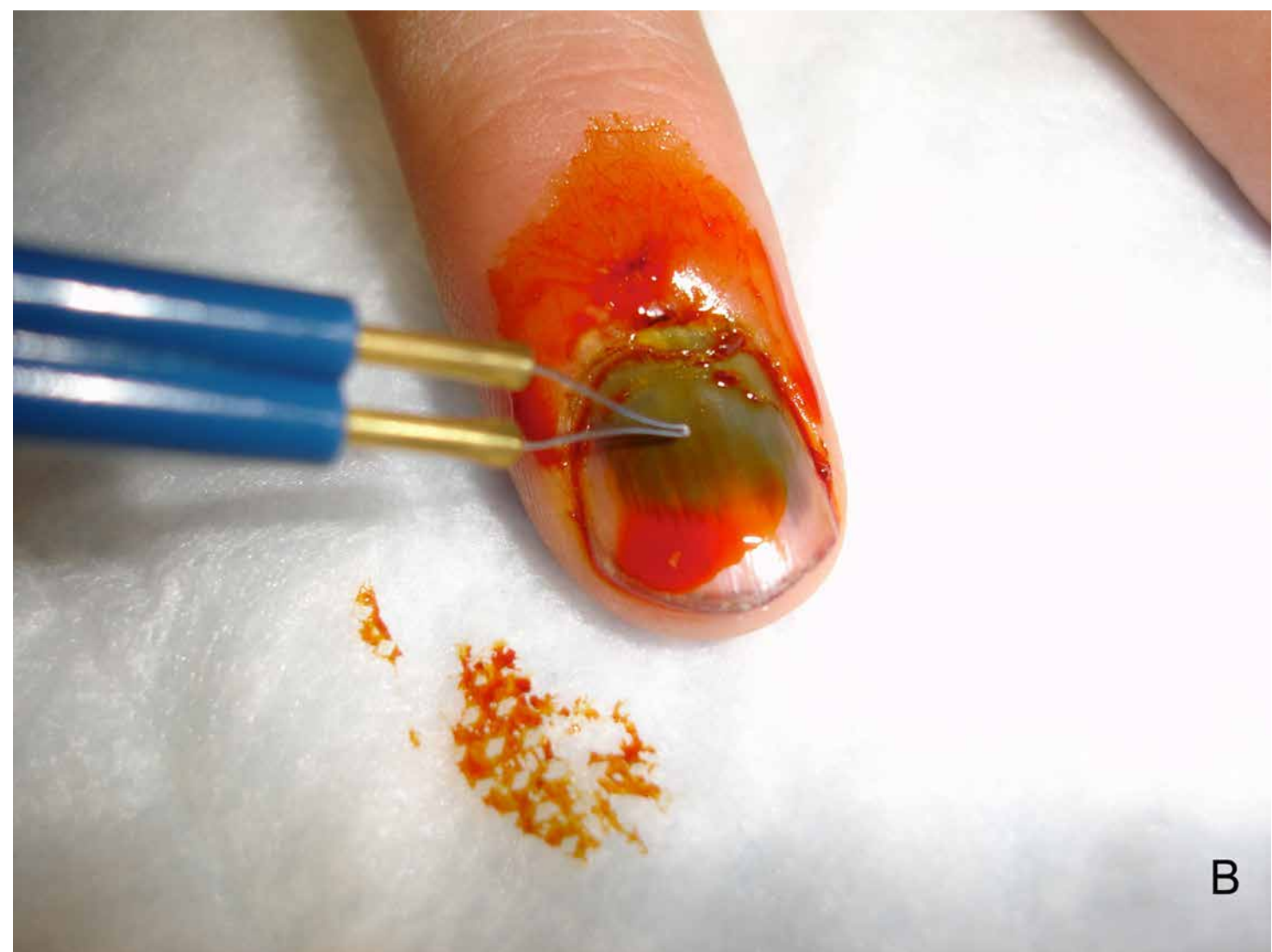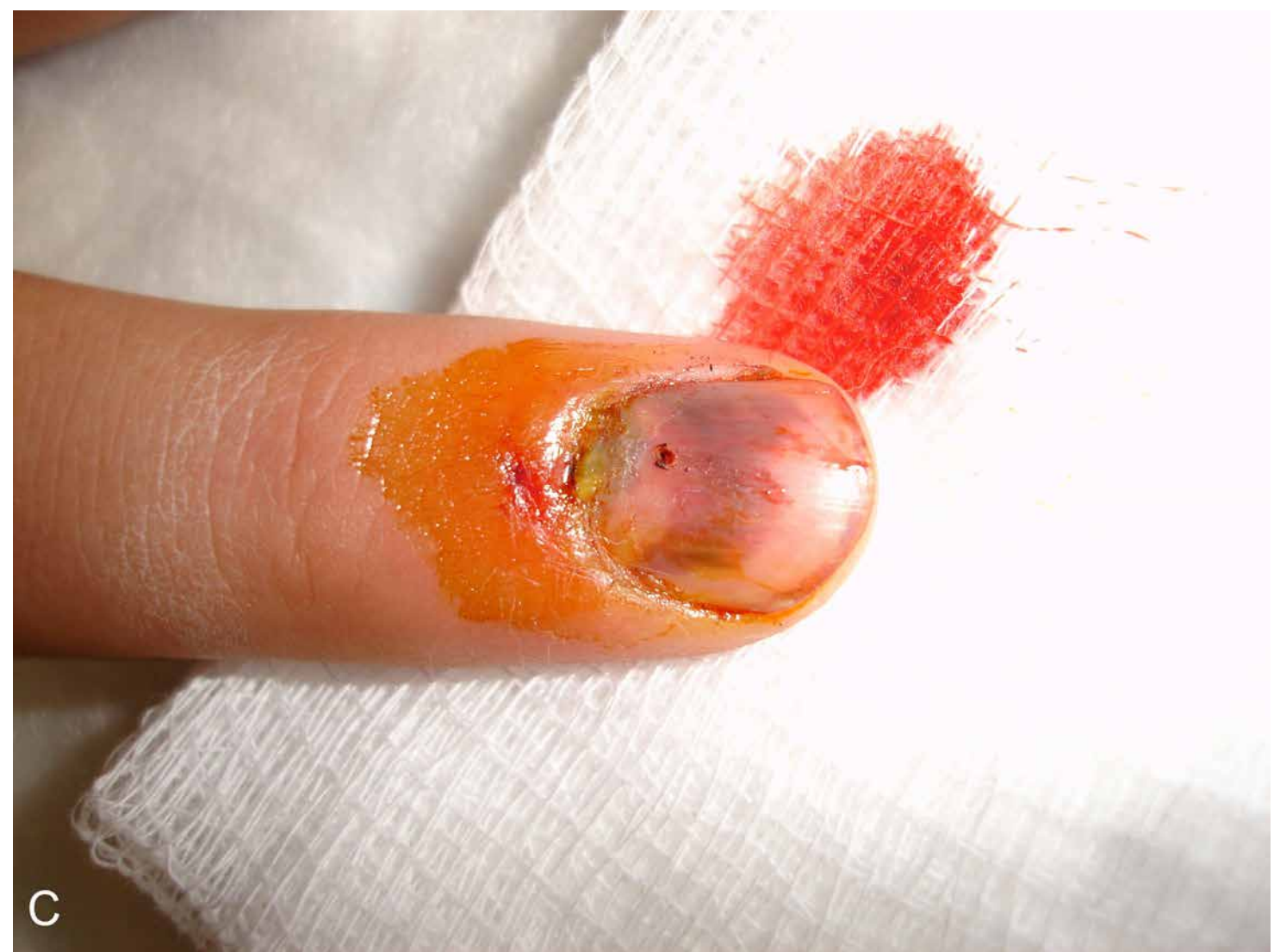Figure 3-1 Mild crush injury to the third and fourth fingertips. Note the swelling and the ecchymosis



A



B



C

Figure 3-2 A-C Subungual hematoma of more than 60% of the sterile matrix drained with an ophthalmic cautery using sterile technique. Relief is immediate.

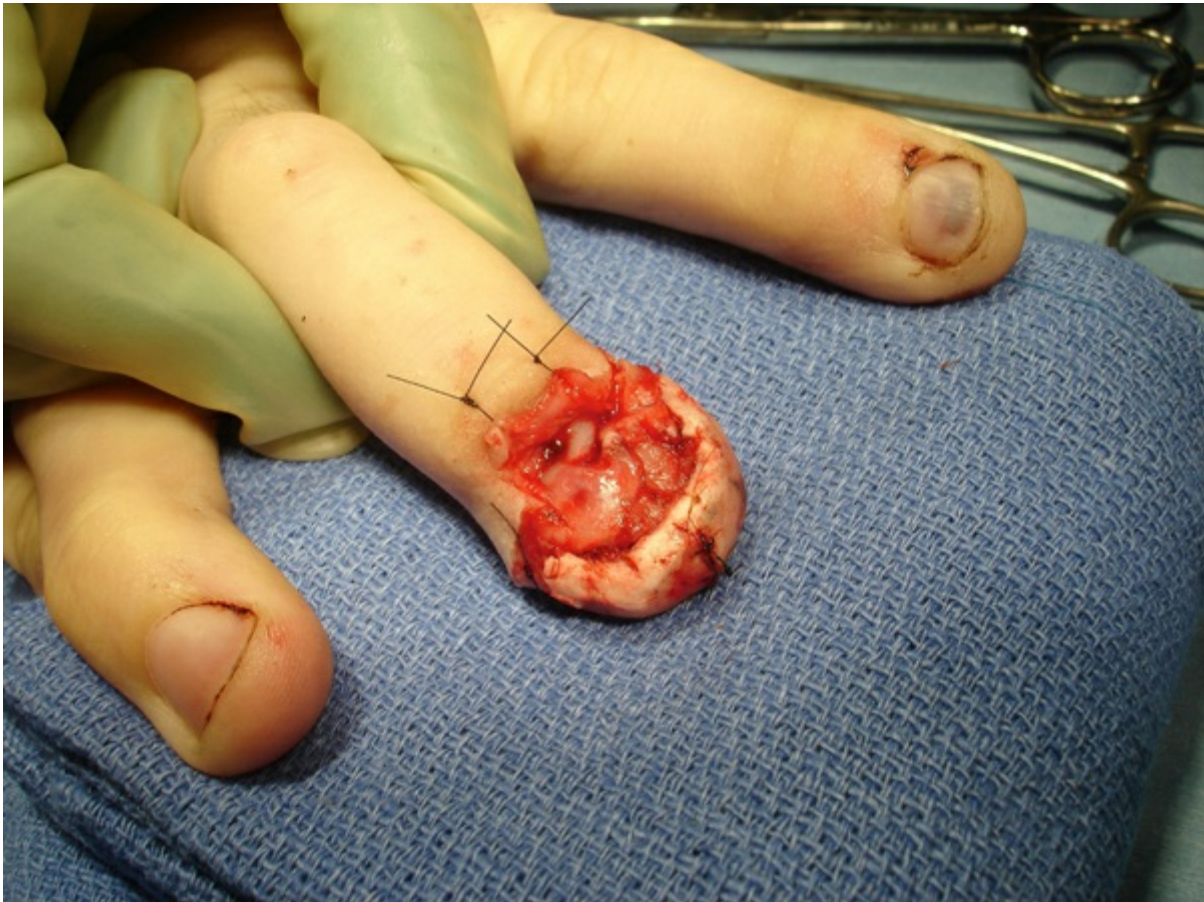

Figure 3-3 Complex nail bed laceration, burst pattern extending to the volar surface of the digit. To expose the germinal matrix, the eponychial fold is peeled back by making 2 oblique incisions

Generally, if the injury to the soft tissue is mild, the tuft requires no open treatment. In these cases, the tuft fracture is nondisplaced, and simple immobilization for 2 to 3 weeks in a total contact plaster cast or thermoplastic molded splint will suffice

(Figure 3-4). These fractures may fail to achieve radiographic bony union; rather, a functional painless fibrous union may result. Immobilization should not include the proximal interphalangeal (PIP) joint because stiffness there may result. At 3 weeks, the DIP joint should be stretched to achieve maximal range of motion.

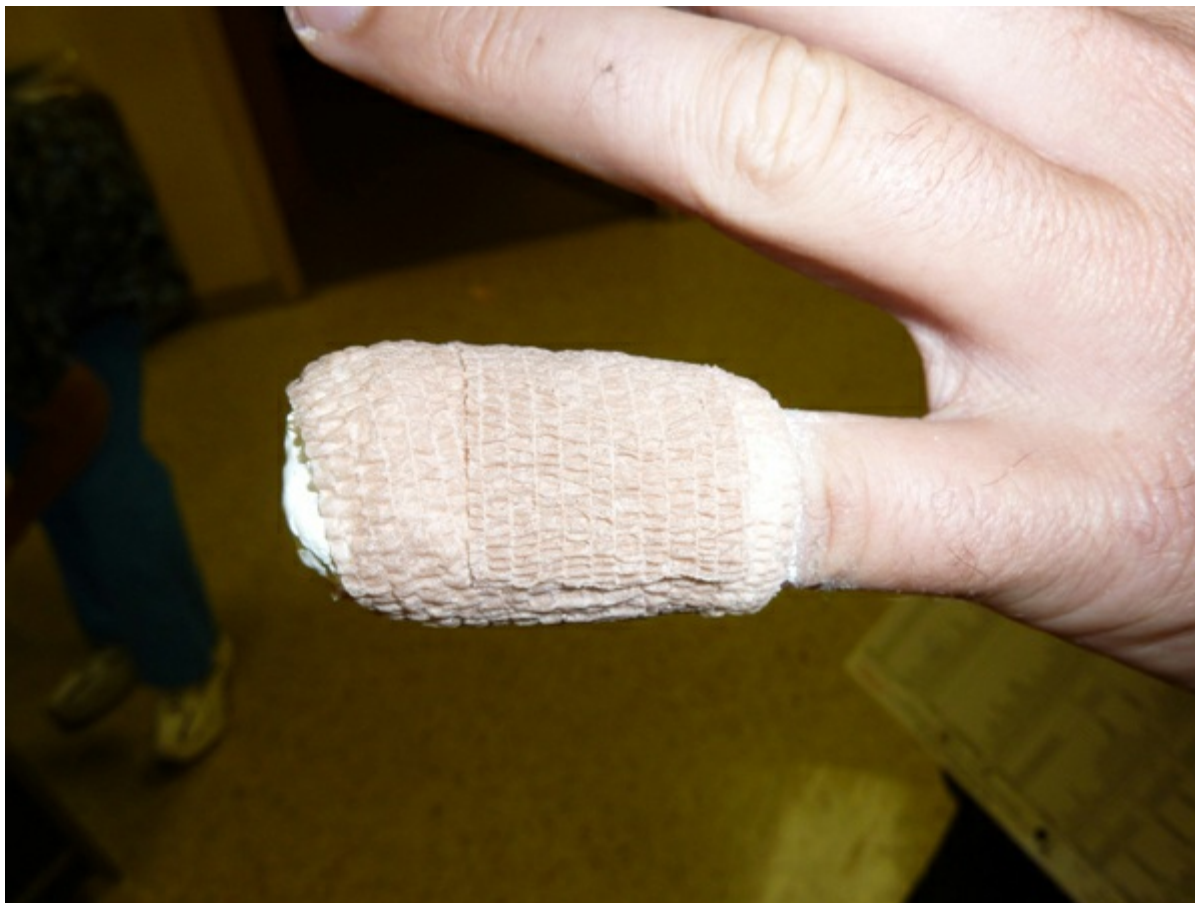

Figure 3-4 Plaster total contact splint for nondisplaced or minimally displaced fractures of the distal phalanx. With monitoring, these can even be used in the face of a closed crush injury. These frequently become loose and need replacement. Full proximal interphalangeal motion is encouraged.

Subungual hematomas are exquisitely painful, and if involving more than 50% of the sterile matrix, they will require decompression. Traditionally, a heated paperclip was used to trephine a hole in the nail plate just past the lunula. More recently, a battery-powered electric cautery provides much higher heat and will painlessly burn a drainage hole in the nail plate (see [Figure 3-2B, C](#)). The sense of relief is immediate and intense. The fingertip is immobilized for about 2 weeks and a range of motion program is begun. It must be noted that creating a hole in the nail plate converts the closed tuft fracture into an open one so that there is the risk of developing a subungual abscess that may extend into the distal phalanx. The trephination must be done under sterile technique. Recent evidence suggests that prophylactic antibiotics are not necessary unless the nail plate is removed.²

There has been controversy of late as to whether patients who present with subungual hematomas can be treated simply with trephination or whether complete removal of the nail plate with repair of the nail bed necessary. Roser and Gellman³ compared the two techniques and found no difference in final outcome regardless of the size of the hematoma or the associated fracture. It is now recommended to simply trephine the hematoma if it is greater than 50% of the nail plate.⁴ This assumes that the underlying fracture is nondisplaced. If there is displacement, then full open treatment including nail bed repair, fracture reduction, and internal fixation may be needed.

Shaft Fractures

Schneider¹ described 2 types of shaft fractures of the distal phalanx—transverse and longitudinal. *Transverse fractures* are most often caused by crush injuries accompanied by a bending moment, usually in flexion. They can be nondisplaced and stable or displaced and unstable. They can also be entirely closed or the distal fragment, while displacing into flexion, can herniate through the sterile matrix, usually avulsing the proximal nail plate out of the eponychial fold. The extent of the injury can be underappreciated. An unknowledgeable treating physician may simply “tuck” the nail plate back in and stabilize it with a suture ([Figure 3-5](#)). The underlying fracture and sterile matrix laceration are then left untreated, with serious consequences for nail growth. The open nail matrix can be a conduit for soft tissue infection and/or osteomyelitis of the distal phalanx. In higher-energy injuries, the nail folds and the volar pulp can be avulsed as well. *Longitudinal fractures* may also be open or closed and are usually a result of a crush injury. They can be extra-articular or may extend into the DIP joint ([Figure 3-6](#)).

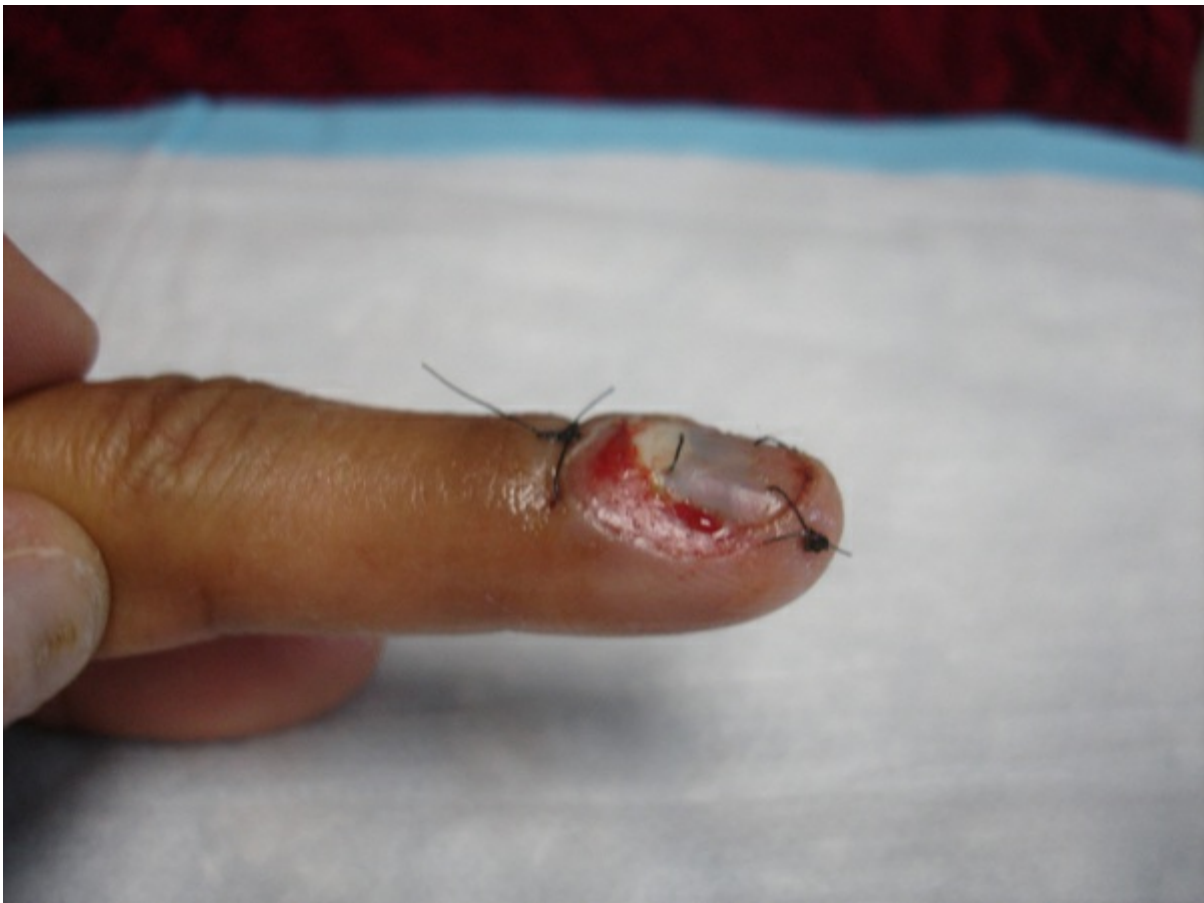
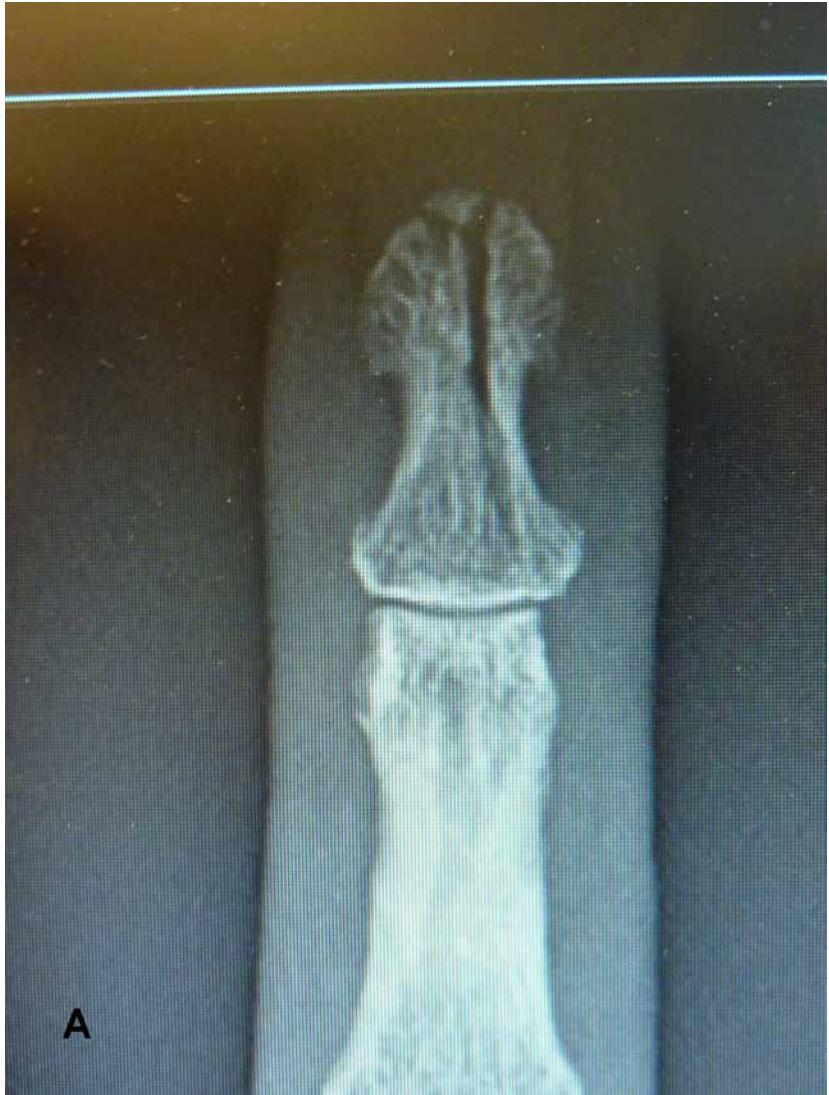
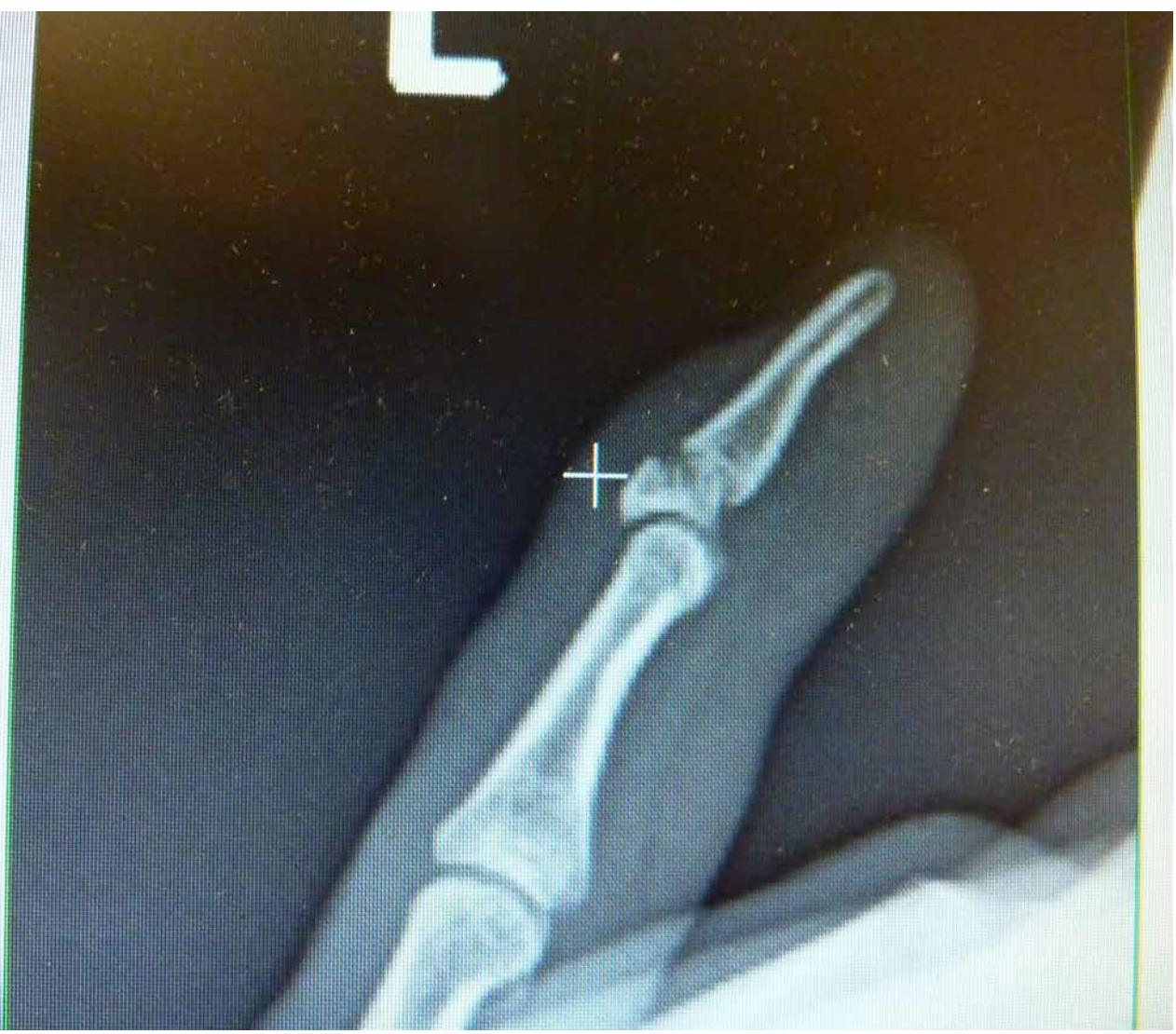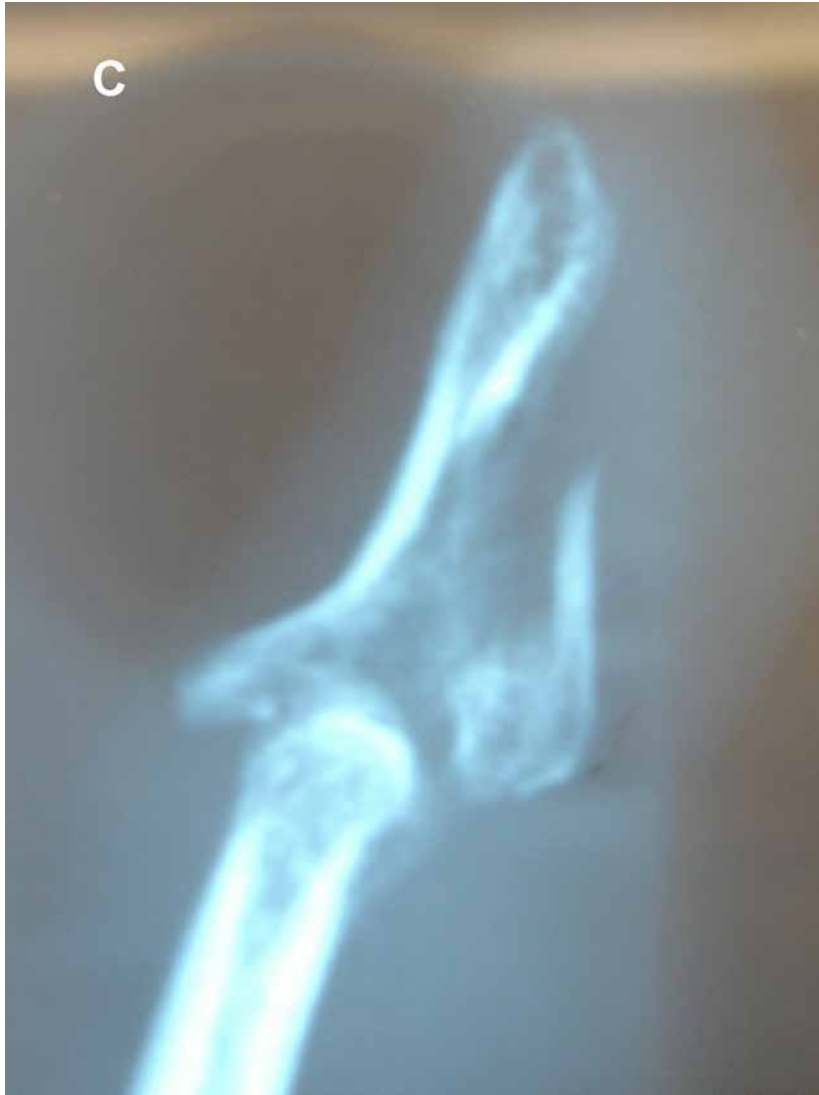Figure 3-5 Nail bed injury “repaired” by emergency room staff by tucking in the avulsed nail plate. The underlying fracture was not addressed, and upon removing the nail plate, the underlying distal phalanx was seen herniating through the sterile matrix with the proximal fold caught underneath the bone.



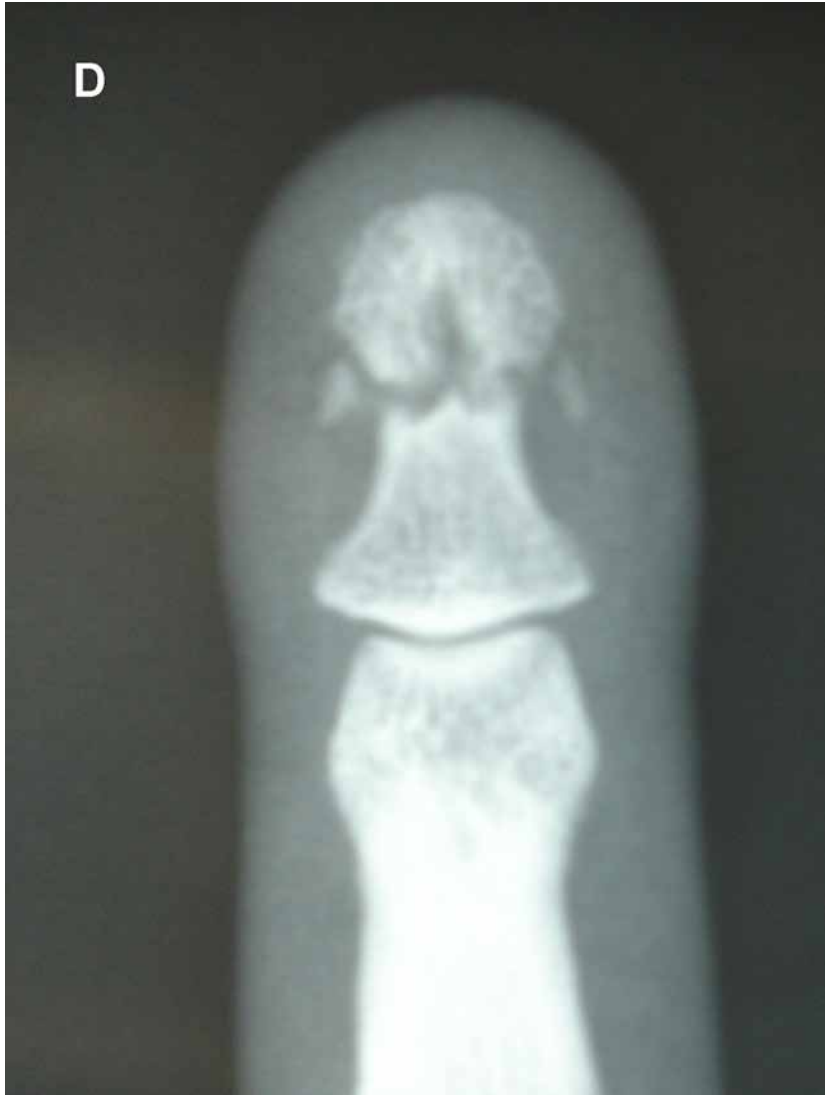B

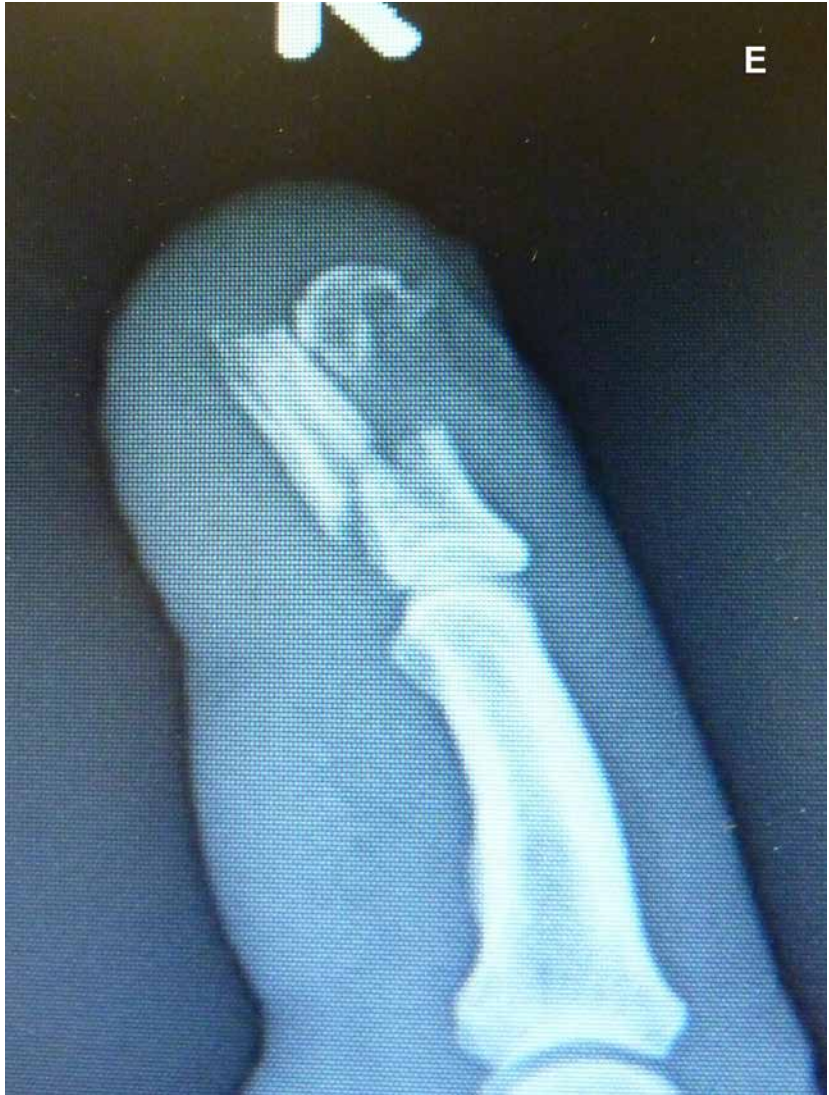

C



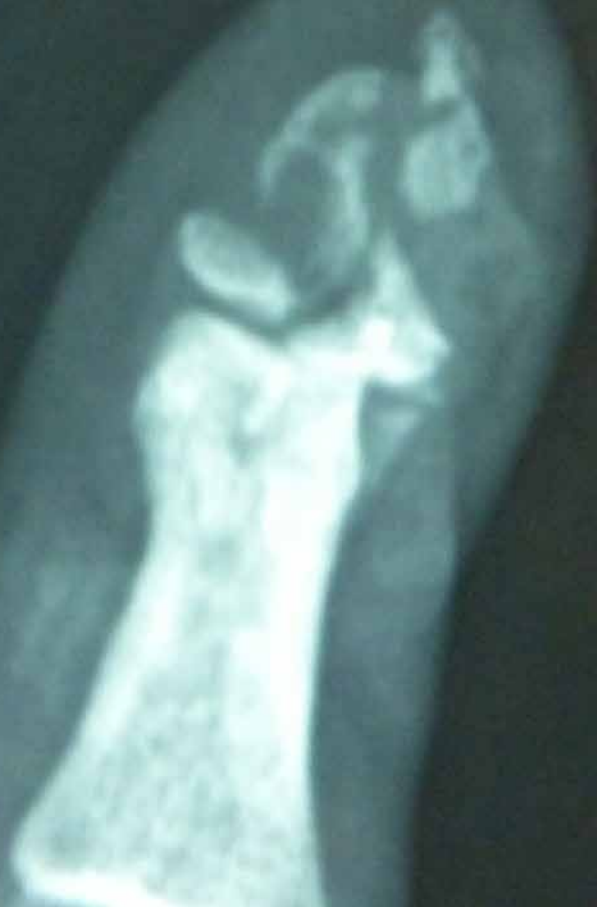D



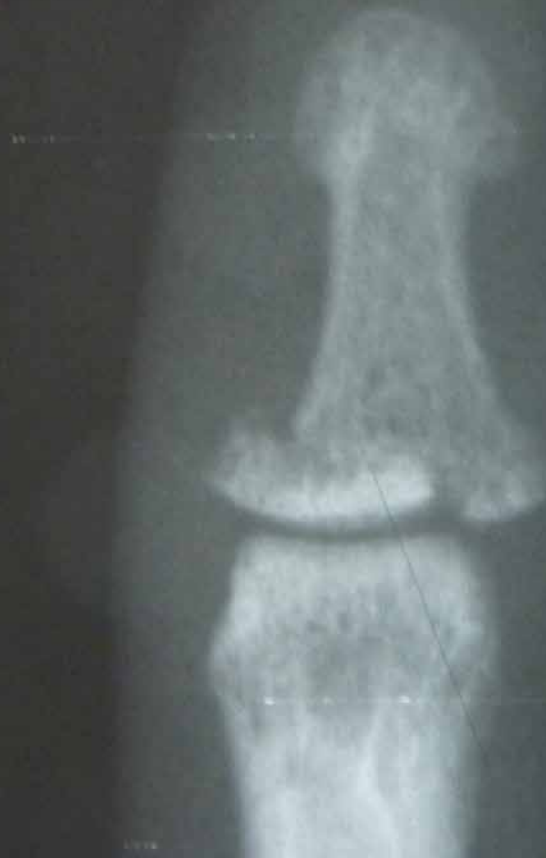

E

F



G



H



Figure 3-6 A, Nondisplaced longitudinal fracture. **B**, Angulated transverse basilar fracture. **C**, Comminuted unstable (pilon) intra-articular fracture. **D**, Displaced basilar intra-articular fracture. **E**, Comminuted segmental displaced fracture. **F**, Highly comminuted fracture of the distal phalanx. **G**, Transverse nondisplaced waist fracture. **H**, Nondisplaced distal tuft fracture.

The treatment of these injuries varies with the clinical presentation and severity of injury. Nondisplaced, closed fractures, either transverse or longitudinal, are generally treated with a splint or protective covering from the tip to the proximal end of the middle phalanx, for about 2 to 4 weeks in order to allow the pain and swelling to subside and to prevent reinjury while encouraging PIP motion. Protected range of motion exercise to the DIP joint is then begun. The tip may still need protection for an additional 2 weeks with a soft cover such as a Coban wrap (3M, Minneapolis).

Displaced, closed injuries to the distal phalanx shaft may need to be reduced anatomically and stabilized in order to prevent subsequent injury to the overlying sterile matrix and late nail deformity. If this cannot be achieved by closed reduction and splinting, it may be accomplished with a longitudinal K-wire or small screw placed distal to proximal. Usually, the wire need not extend across the DIP joint into the middle phalanx ([Figure 3-7](#)). If, however, there is insufficient bone in the proximal metaphysis of the distal phalanx, the wire can extend to the middle phalanx ([Figure 3-8](#)). Wires remain in place for 4 to 6 weeks. K-wires remain the mainstay of fixation, and use of screws must be considered with caution because of the difficulty encountered with their insertion and the ease with which they can cut out of the bone. Frequently, the distal phalanx may be curved and compound the problem.

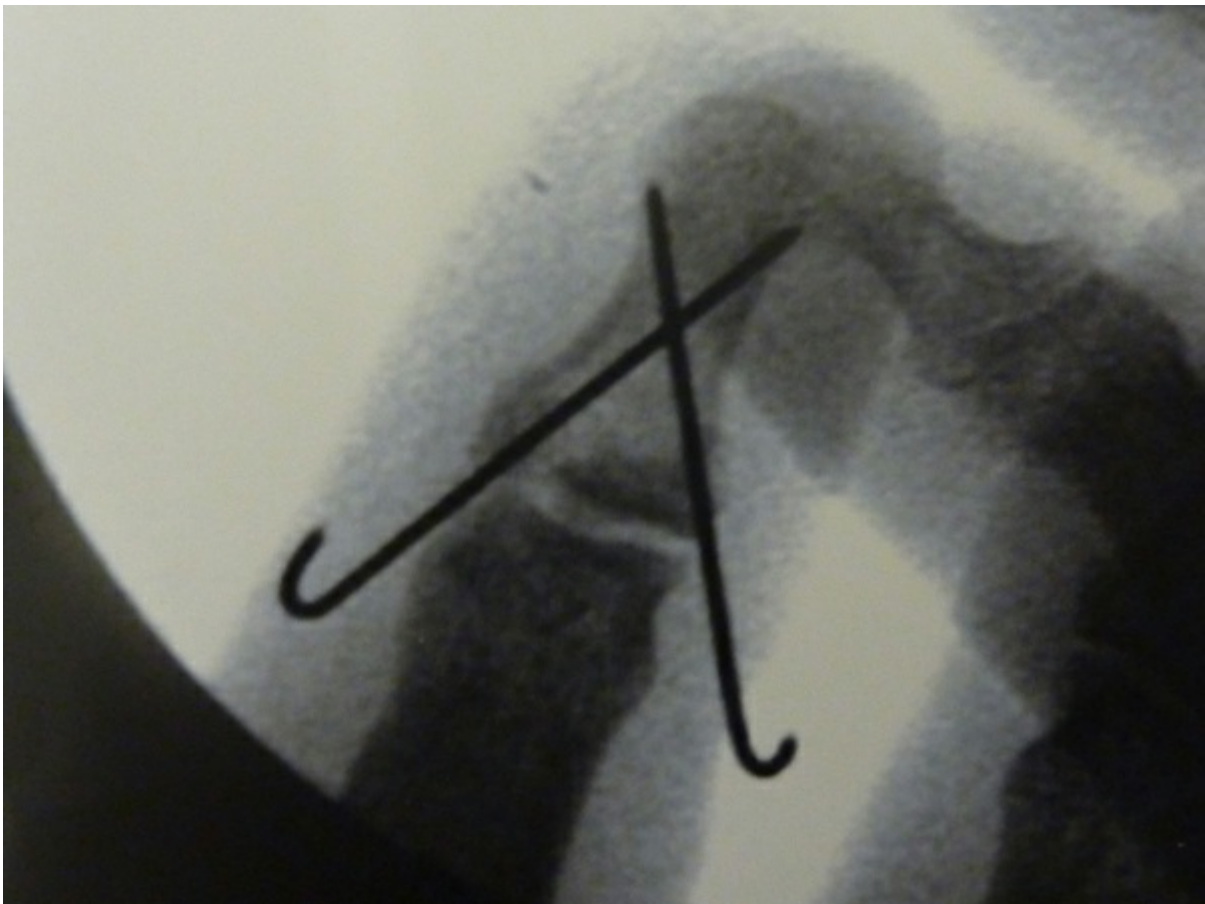

Figure 3-7 Basilar fracture pinned without crossing the distal interphalangeal (DIP) joint.

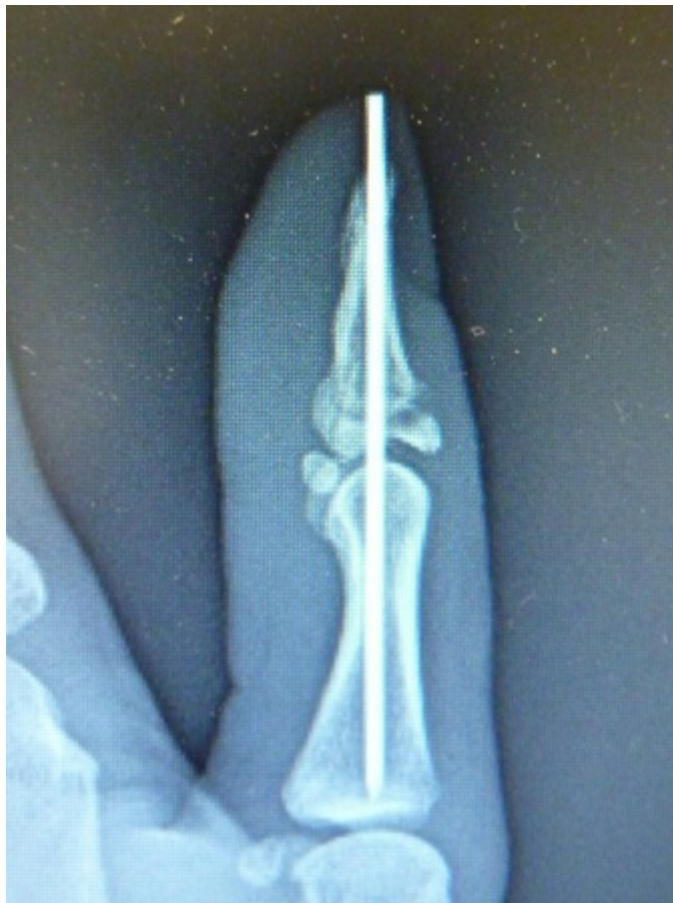
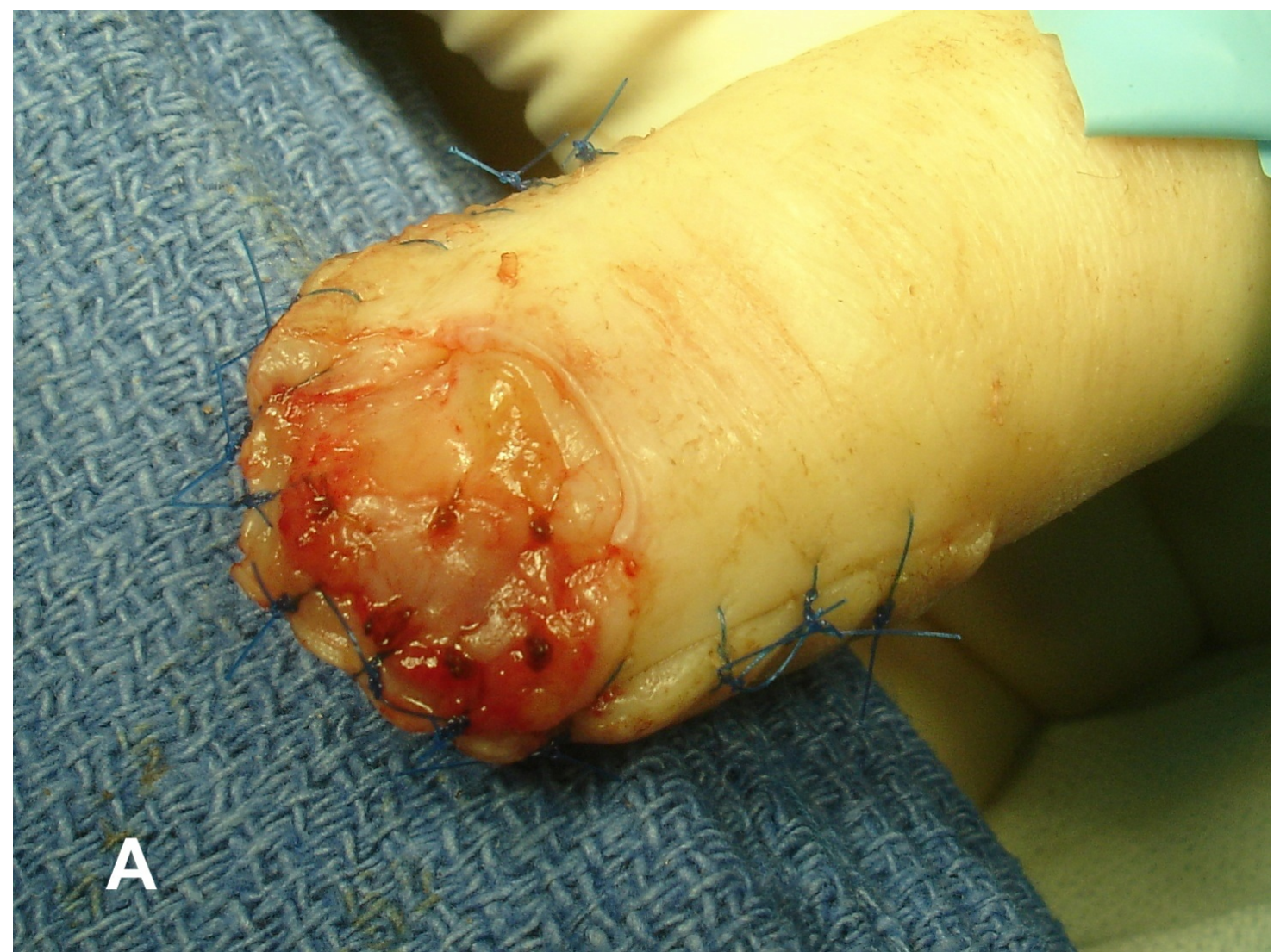
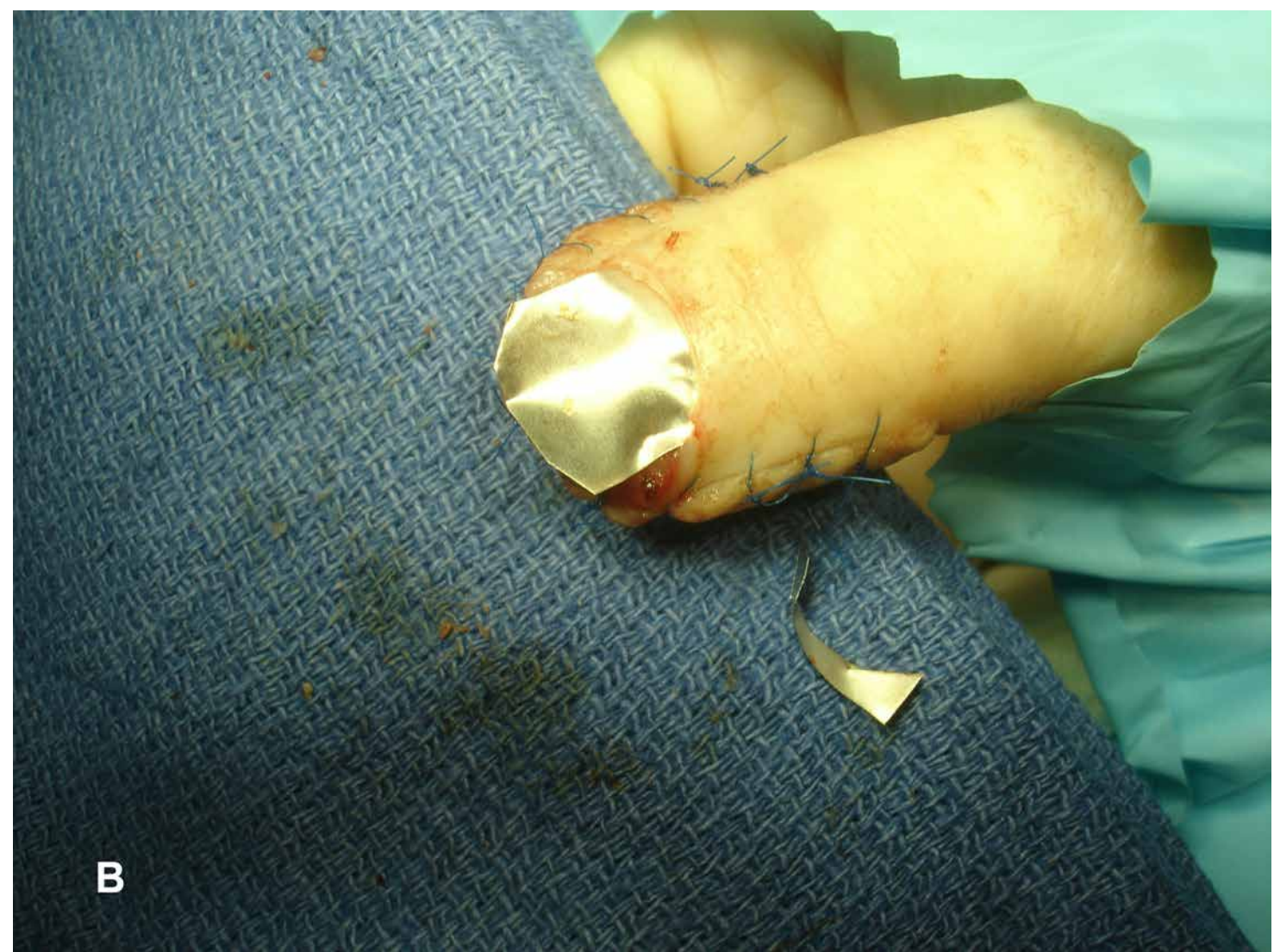
Figure 3-8 Insufficient proximal fragment necessitating transarticular pinning.

Open fractures of the distal phalanx may require removal of the nail plate and irrigation and debridement of the nail bed and the fracture site. The germinal matrix is frequently rolled up proximally or tucked under the distal fragment that is displaced dorsally and requires anatomic reduction. After stabilizing the fracture with a K-wire, the nail bed should be repaired with a 6-0 absorbable suture ([Figure 3-9](#)). If the laceration is under the eponychial fold, 2 oblique incisions on each side of the fold will raise it

up (see [Figure 3-3](#)). After repair, the nail plate, if present, or even a strip of foil from the suture package can be placed as a spacer and smooth template to retain the space under the eponychial fold. Any other associated soft tissue laceration should also be repaired. A first-line, broad-spectrum antibiotic is used for 7 to 10 days.



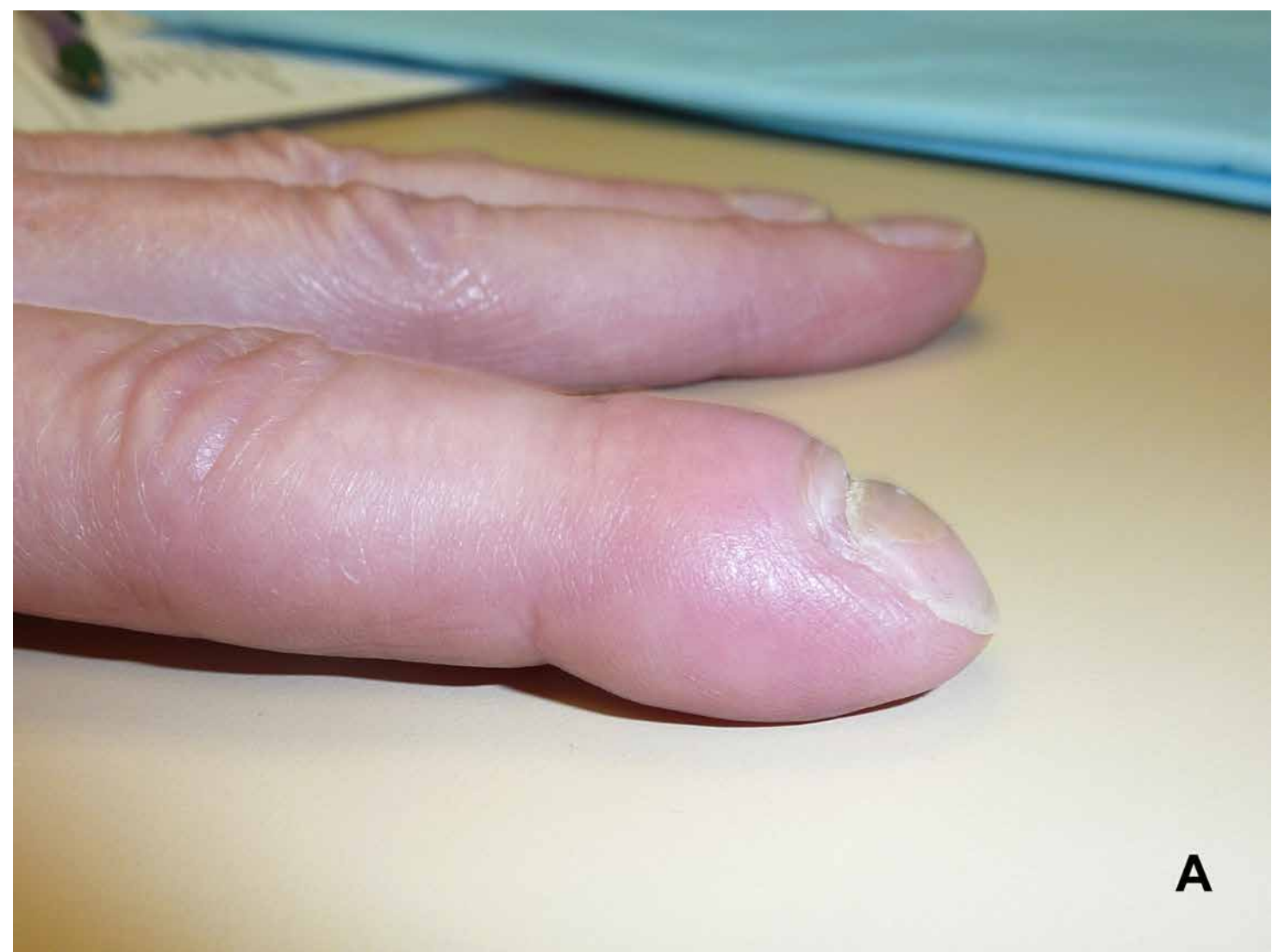
A



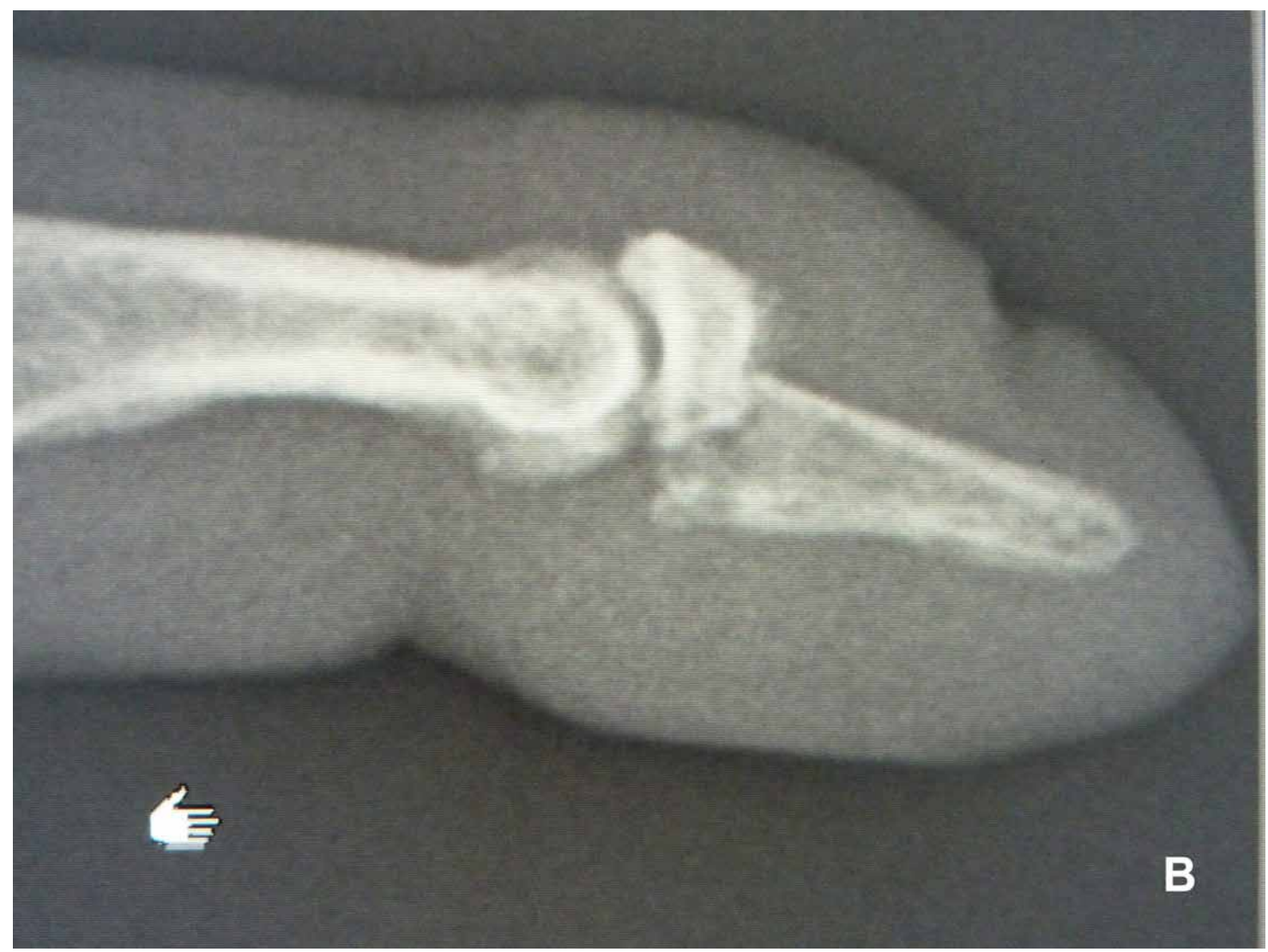B

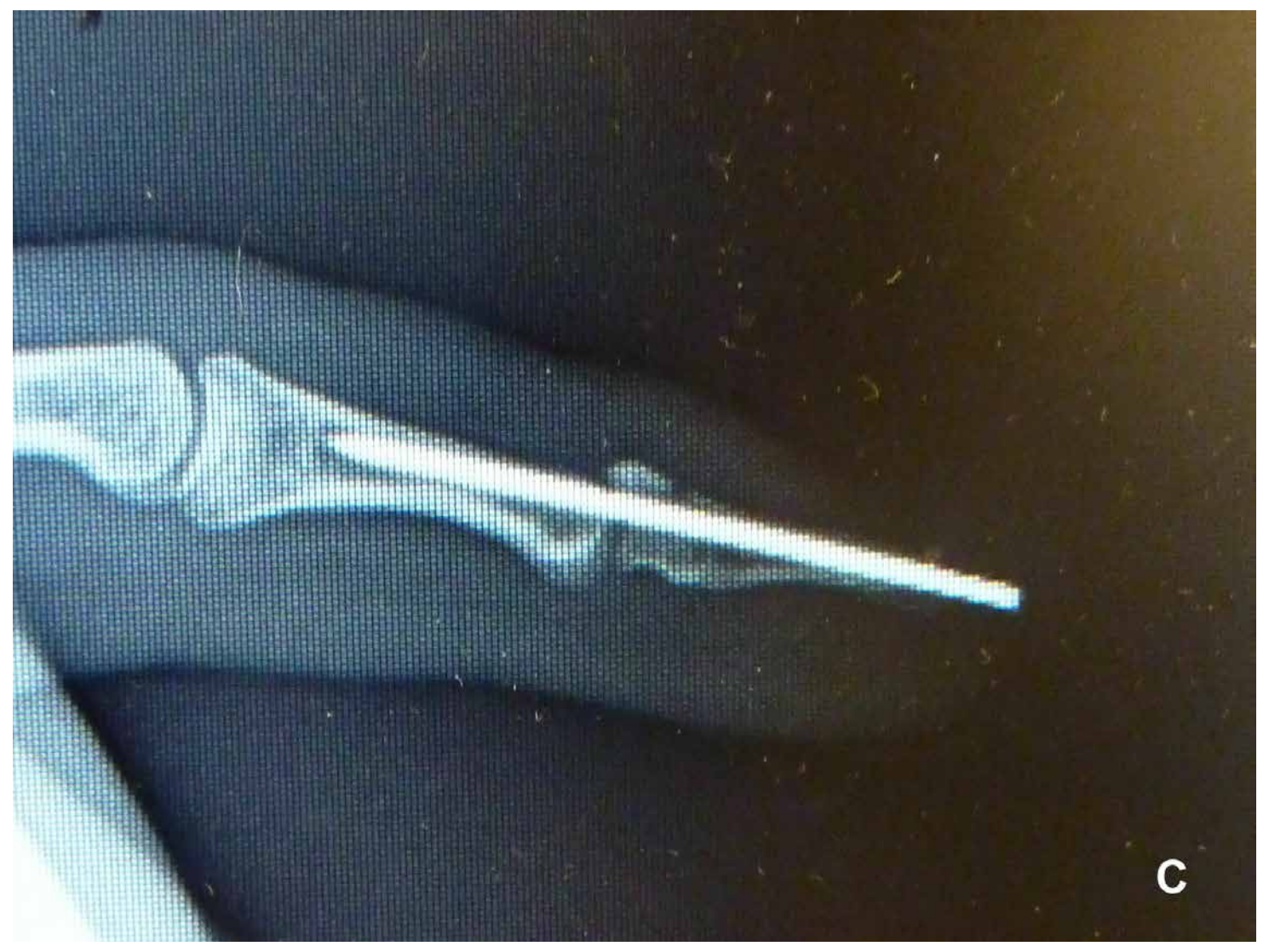Figure 3-9 A, Anatomic repair of the sterile matrix using 6-0 (absorbable) chromic suture. Surrounding structures are repaired with 6-0 Prolene. **B**, Aluminum sheet placed under the eponychial fold after nail bed repair. The spacer keeps the pouch open to prevent adherence of the ceiling of the germinal matrix to the floor.

Long-term complications such as nonunion of the distal phalanx have been successfully treated with bone grafting from the olecranon and internal fixation using headless compression screws placed distally.⁵ Complications from this technique have included stiffness of the DIP joint, sensory loss in the fingertip, DIP joint arthritis requiring fusion, and symptomatic osteonecrosis of the distal fragment and tuft requiring late removal. Malunions can be treated with osteotomy and internal fixation with successful outcome ([Figure 3-10](#)).



A



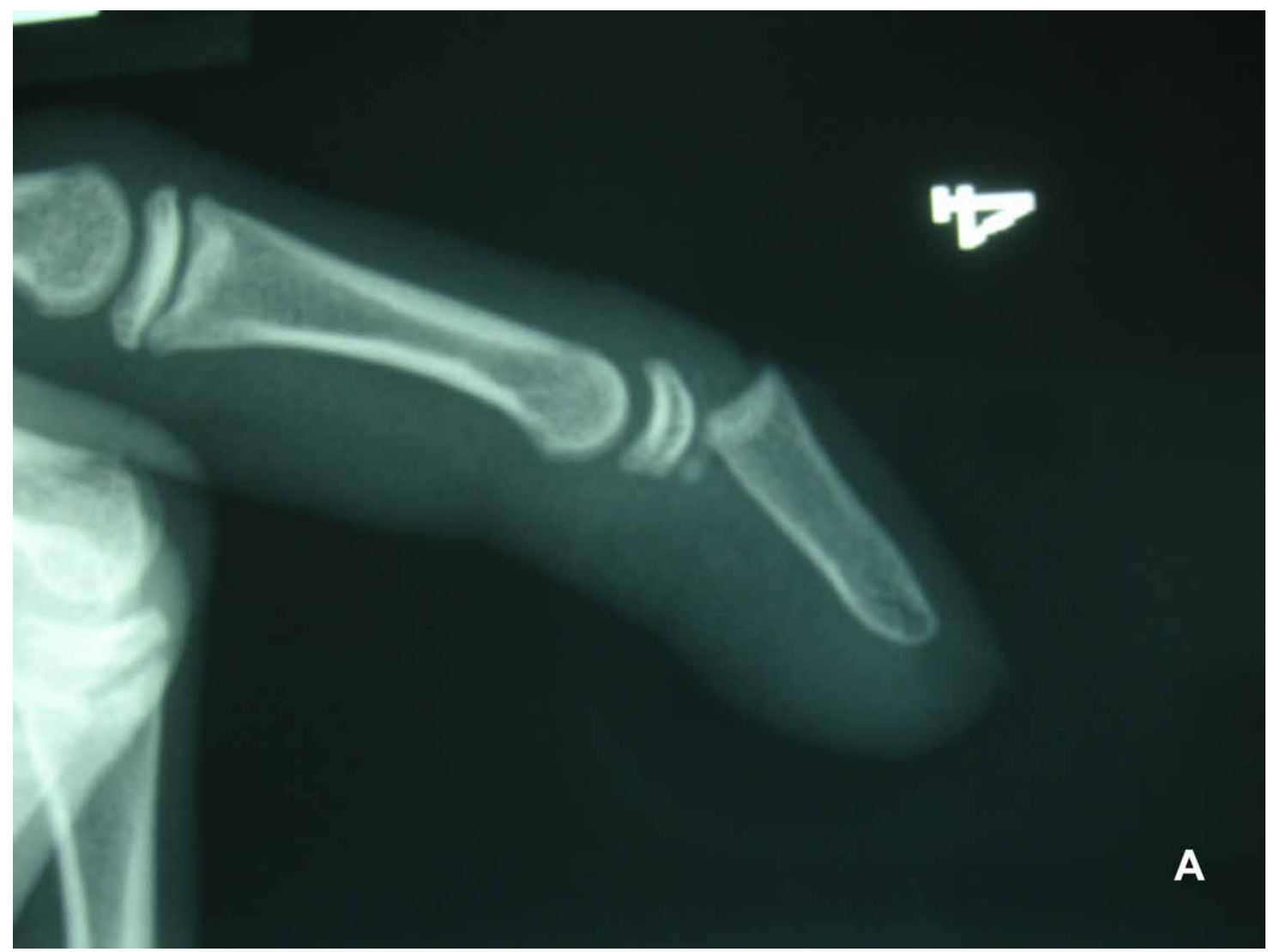

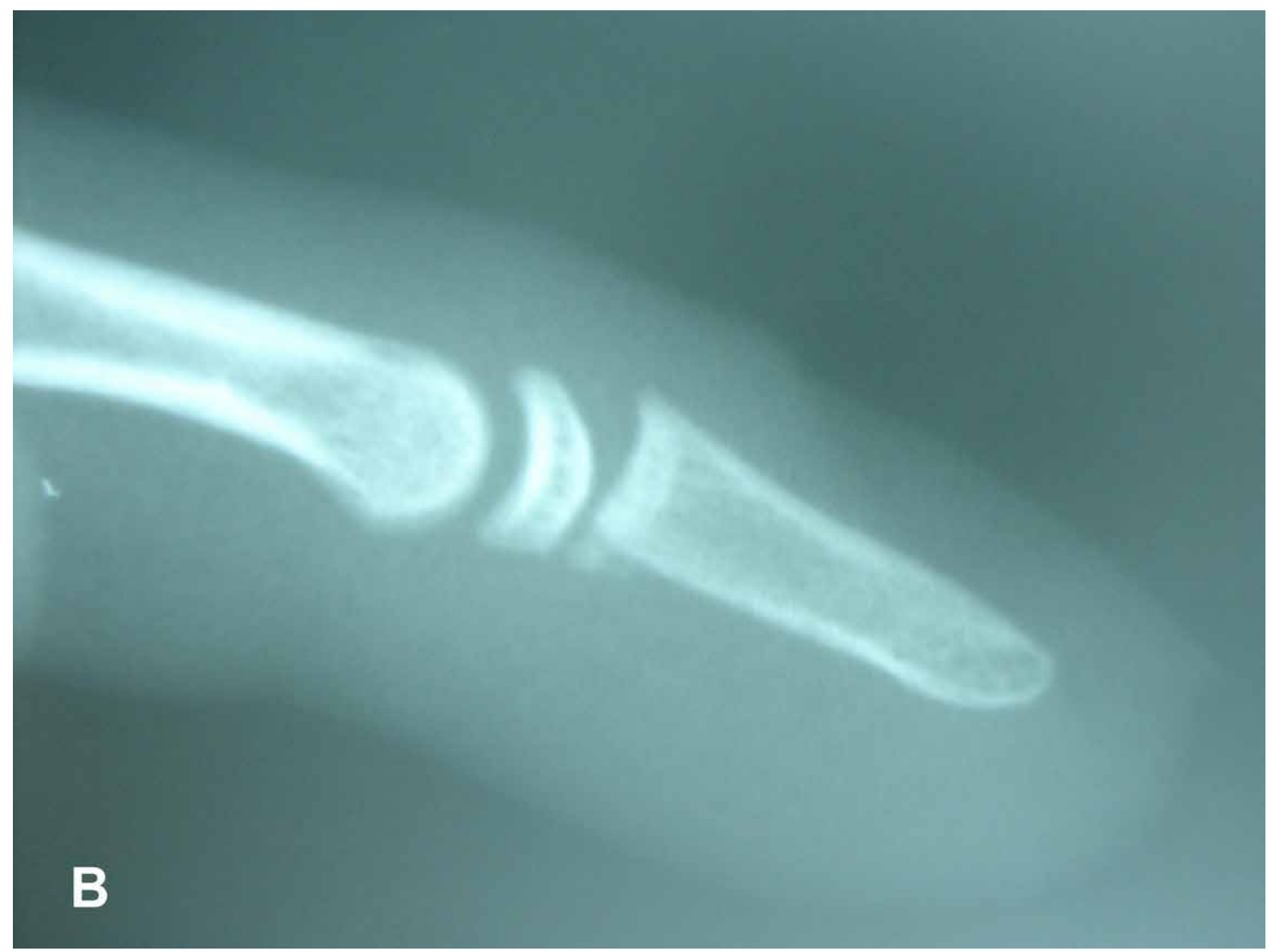C

Figure 3-10 A-C, Six-month-old malunion of the distal phalanx treated with osteotomy and internal fixation through a midlateral approach.

Pediatric Fractures of the Distal Phalanx (Seymour Fracture)

A hyperflexion injury to the fingertip in a child is frequently mistaken for a mallet finger. In reality, the extensor tendon is still attached to the proximal dorsal metaphysis of the distal phalanx.⁶ The deformity is caused by an “open book” flexion fracture of the physis at the proximal end of the distal phalanx. In preadolescents, the fracture is either a Salter-Harris Type 1 or 2; in adolescents, it is generally a Type 3 pattern ([Figure 3-11](#)). The diagnosis can be tricky in very small children, younger than 3 years, whose epiphysis may not be calcified. Because the FDP inserts on the distal phalanx distal to the fracture, it acts as a deforming force flexing the distal fragment.





B

R



C

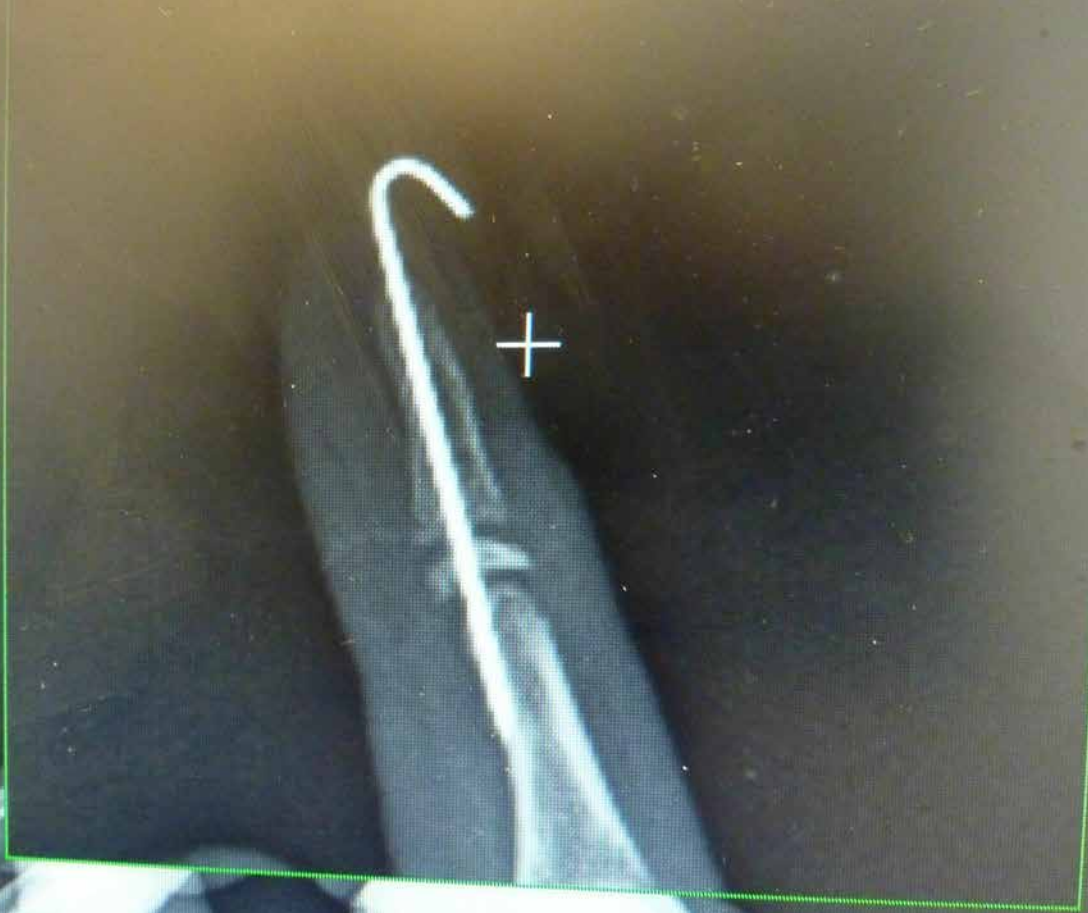

Figure 3-11 A, Seymour fracture (Salter 2) of the distal phalanx. These are frequently open. **B**, Failed closed reduction of a Seymour fracture owing to soft tissue interposition, usually a fold of germinal matrix. **C**, K-wire fixation of the Seymour fracture. The physis must be irrigated and debrided before reduction of the fracture and pinning. Nail bed repair follows.

If left untreated, growth arrest at the distal phalanx is virtually inevitable, and in young children, it will result in a shortened distal phalanx with stiffness in the DIP joint. These injuries, if closed, can be treated with simple reduction with or without K-wire fixation.

However, most of these injuries are open with the physis herniated through the nail bed. As in adults, if the fracture is simply reduced without exposing the fracture and the sterile matrix, loss of reduction owing to the interposition of the proximal nail bed and infection can occur. Rogers and Labow⁷ described a 6-year-old child who was 3 years after a crush injury to the fingertip that was treated conservatively. At 3 years, there was gross nail plate deformity overlying a nonunion at the distal phalanx. In order to minimize growth and nail bed deformity, treatment must include removal of the nail plate, careful debridement of the physis, removal of the interposed soft tissue, irrigation, fracture reduction, repair of the nail bed, and replacement of the cleaned nail plate under the eponychial fold to act as a stent to help hold the reduction. A longitudinal K-wire is placed across the fracture, if needed. Good results can be obtained with delayed presentation up to 1 month.⁶

Injuries to the Nail Apparatus (Perionychium)

Anatomy

In order to understand the underlying principles of repair of the nail apparatus, one must be knowledgeable in its anatomy and physiology. The *perionychium* is the term used to describe all the structures of the fingernail. They are the nail folds (nail wall, eponychium, and dorsal roof of the nail bed) and the nail bed, which includes the germinal and sterile matrixes and the hyponychium. The nail plate inserts into the nail fold and divides into the ventral floor and the dorsal roof. The dorsal roof is responsible for the shine of the nail plate. The germinal matrix is responsible for 90% of the nail growth, with the sterile matrix primarily responsible for nail plate adherence and thickening the nail plate (another 10%). The nail grows as the cells of the germinal matrix grow out dorsally and get compressed against the overlying nail plate, adding to it and pushing it out distally. The lateral nail folds or perionychium provides stability to the nail plate. The hyponychium at the distal end of the sterile matrix acts as a barrier against subungual infection⁸ (Figure 3-12).

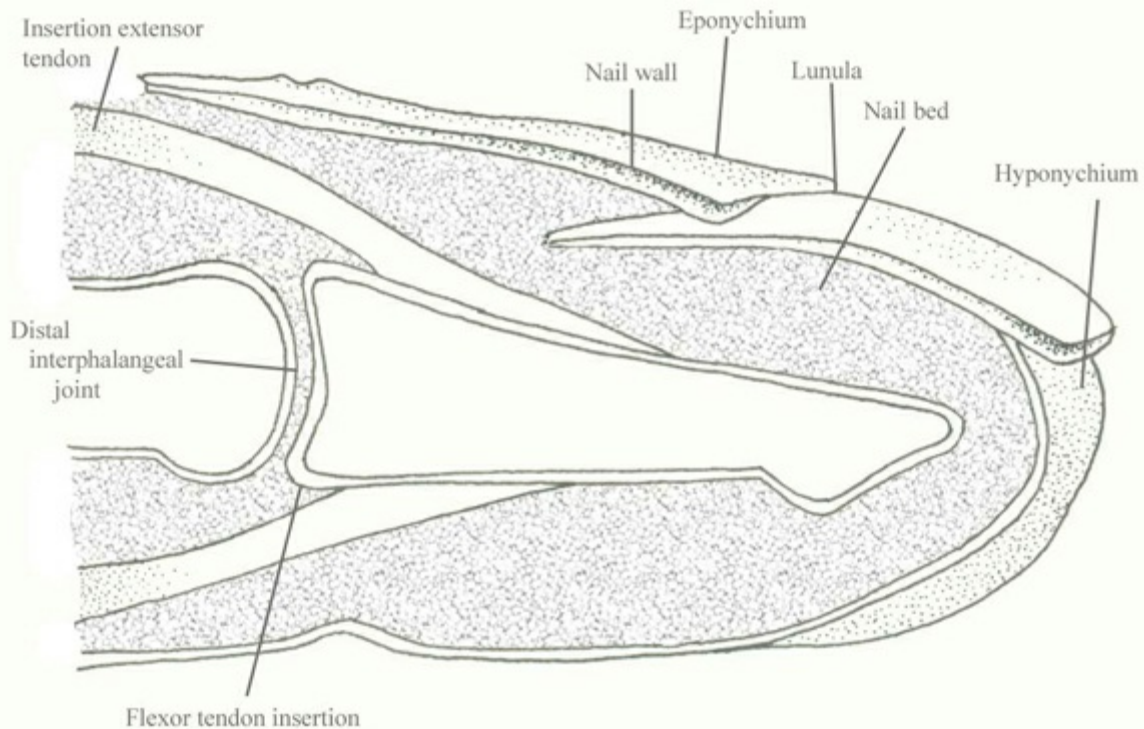
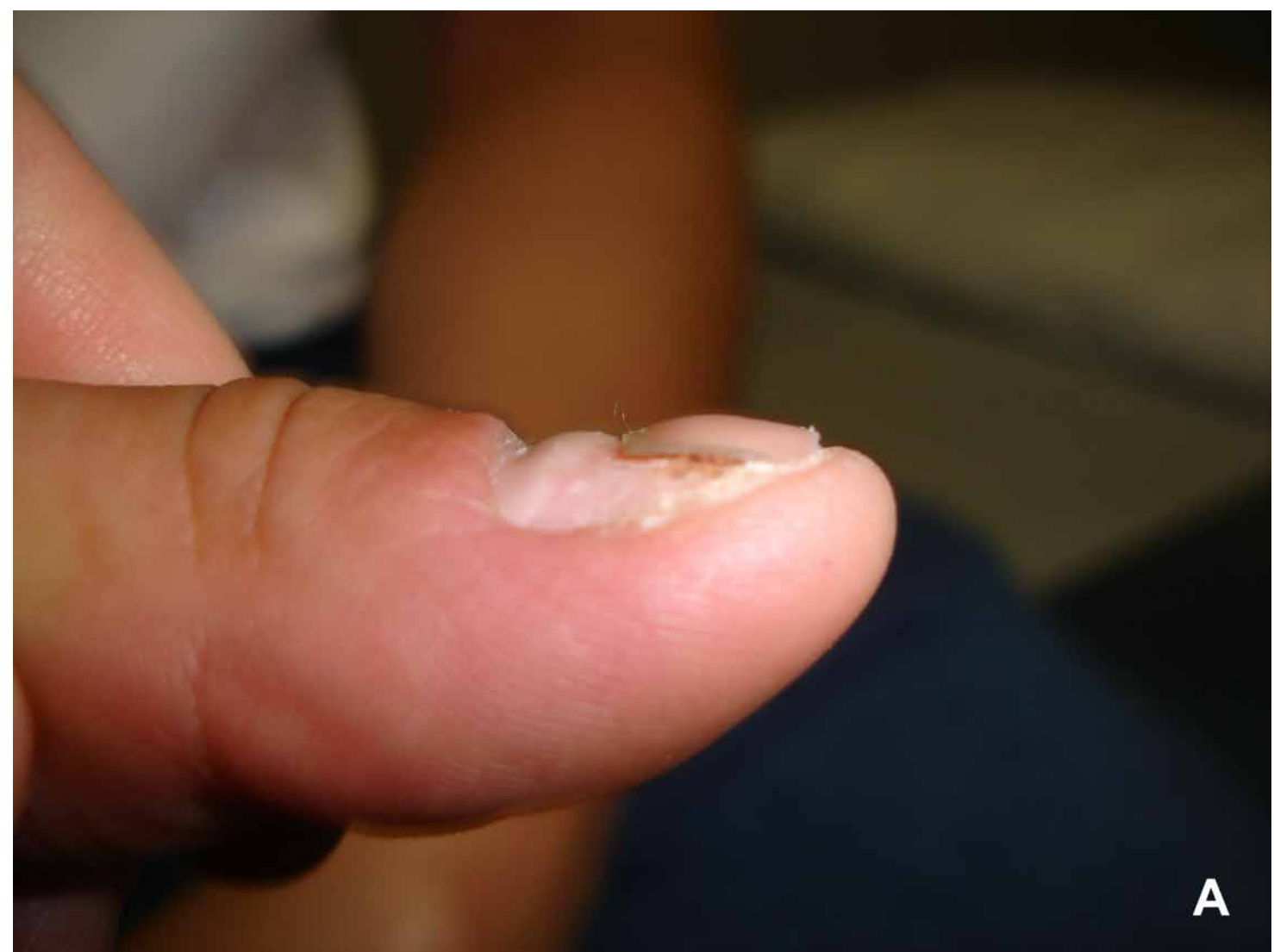

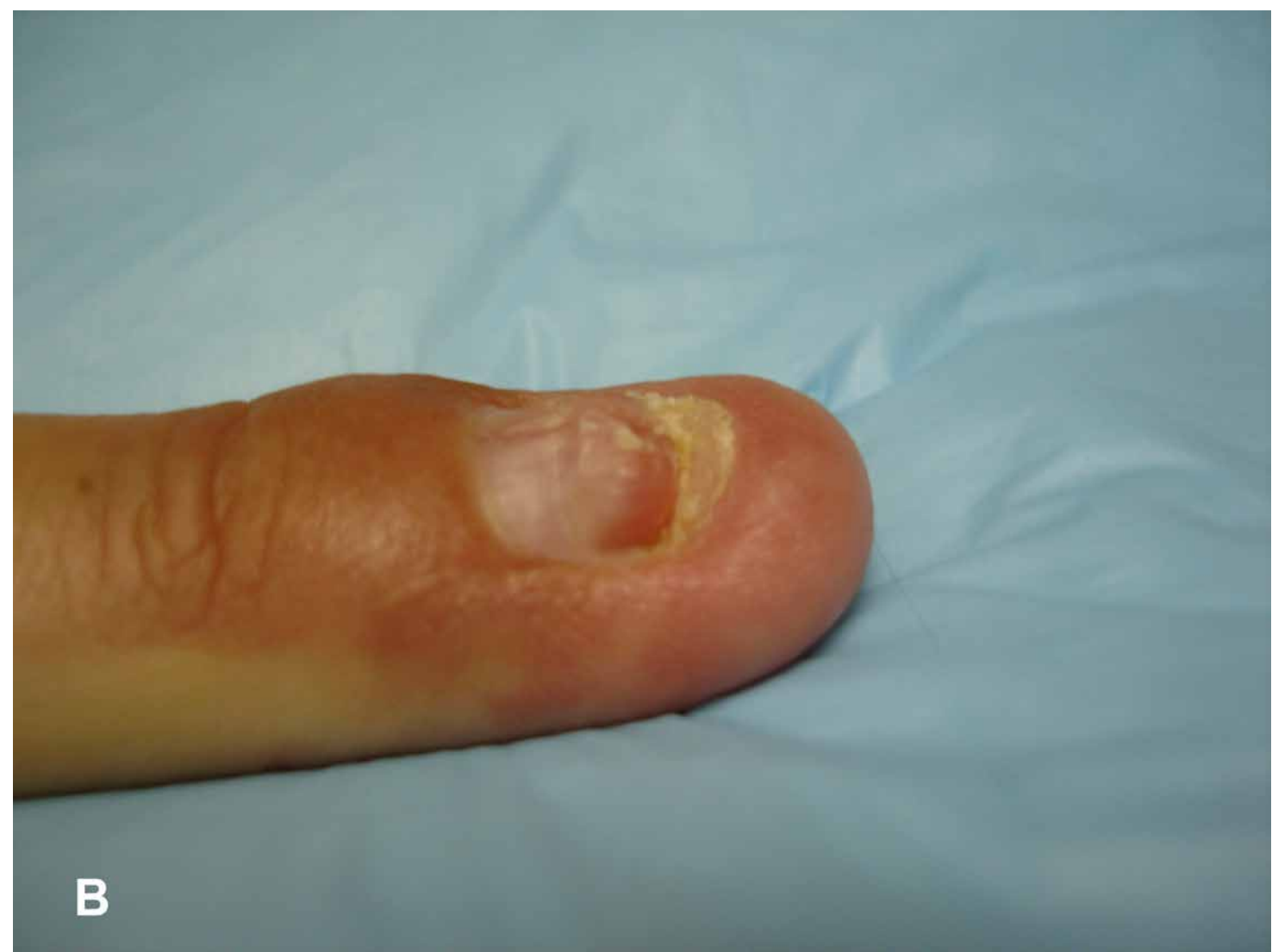Figure 3-12 Cross-sectional anatomy of the nail apparatus.

Pertinent Physiology

Baden⁹ reported that the nail plate grows at 0.1 mm/day and that, after injury, there is a 21-day delay before the nail begins to grow. Initially, the nail thickens proximal to the injury site for about 50 days and then thins out for another 30 days. This explains the noticeable “lump” that forms on the proximal nail plate as it grows in, sometimes pushing out the previous nail that has become only partially adherent to the underlying sterile matrix (Figure 3-13). The rate of nail growth accelerates from age 4 to 30 and then slows considerably. In general, it takes about 4 months for a nail plate to grow out to the end of the nail bed. Additional thickening and nail shine will develop over 1 year. Zook et al¹⁰ recommend that, after the initial repair of an injury, one should not

attempt reconstructive efforts for 1 year in order to allow the nail apparatus to stabilize.





B

Figure 3-13 A, Two months after a nail bed avulsion, the new nail ridge is “pushing” out the old nail plate from beneath and proximally. **B**, At 3 months, with the old nail gone, the initial wave of nail plate growth reaches nearly to the hyponychium. Complete remodeling of the nail plate including the development of the shine will take nearly a year.

Injuries to the Nail Bed

There are 2 predominant mechanisms of injury—crush and laceration. Injury occurs most commonly in children and young adults. The middle finger is most commonly affected. There is a fracture of the distal tuft about half the time. Higher-energy forces will avulse the nail plate out of the eponychial fold. Blunt crush injuries usually result in stellate, comminuted injuries to the nail bed. In lacerations, the width of the zone of injury depends on the type of laceration. Saw injuries will leave a much wider zone than a sharp laceration with sharp object ([Figure 3-14](#)).

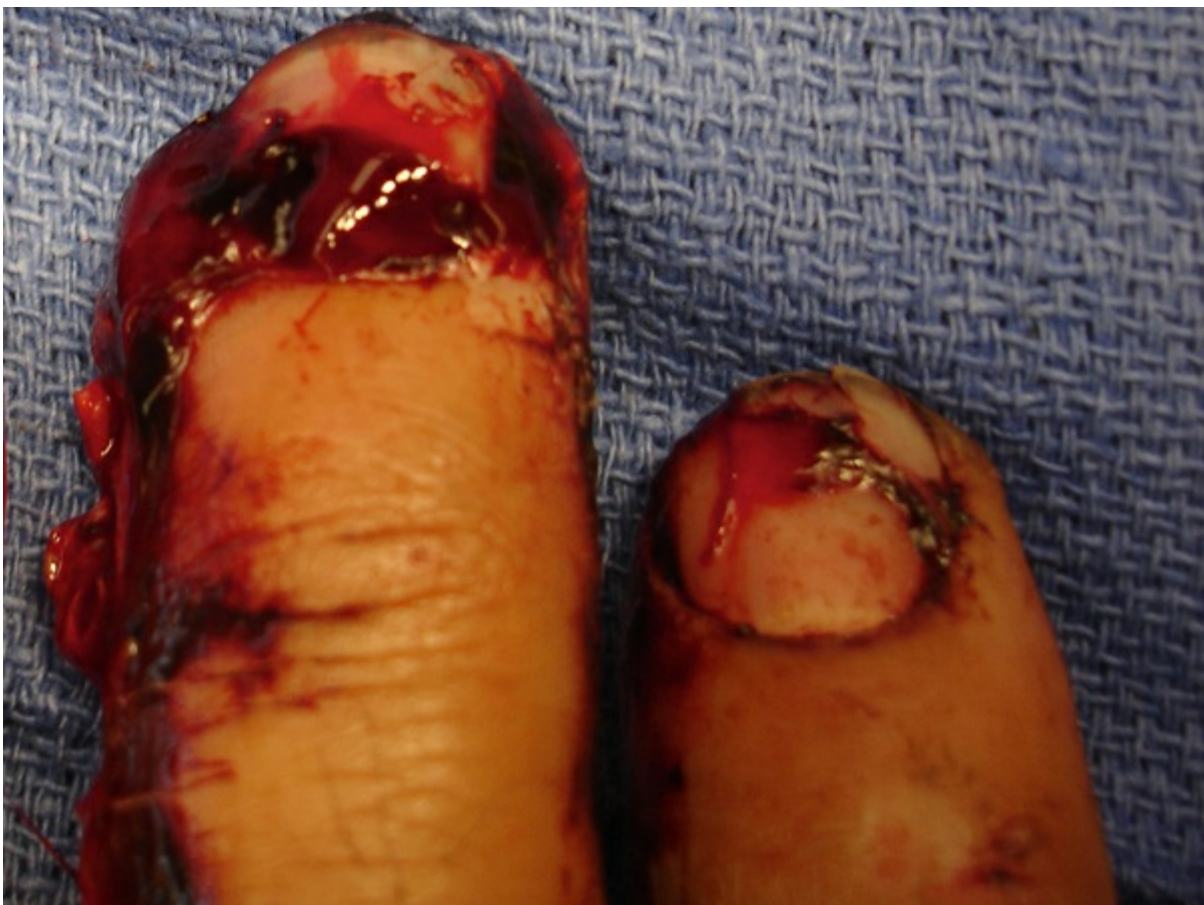

Figure 3-14 The index finger (right) shows a sharp laceration pattern with preservation of the surrounding tissue. The middle finger has a wide zone of injury with profound injury to the nail matrix and distal phalanx.

Repair of the nail bed requires a sterile and bloodless field. Loupe magnification is recommended so that accurate repair may be accomplished. Frequently, areas of nail bed are missing and possibly trapped under the nail plate. If the nail plate is still attached to a part of the sterile matrix, it should be removed very carefully to avoid further trauma. If there is any nail bed still

attached to the underside of the nail plate, it should be gently dissected off for use in the repair. The nail plate itself should be cleaned for reimplantation at the end of the repair. The edges of the nail bed can be approximated even if they are irregular, "trimming" the edges may leave an irreparable gap. Use of a 6-0 or 7-0 chromic suture on a small atraumatic needle is recommended. All free nail bed fragments, no matter how small, should be included in the repair (Figure 3-15).

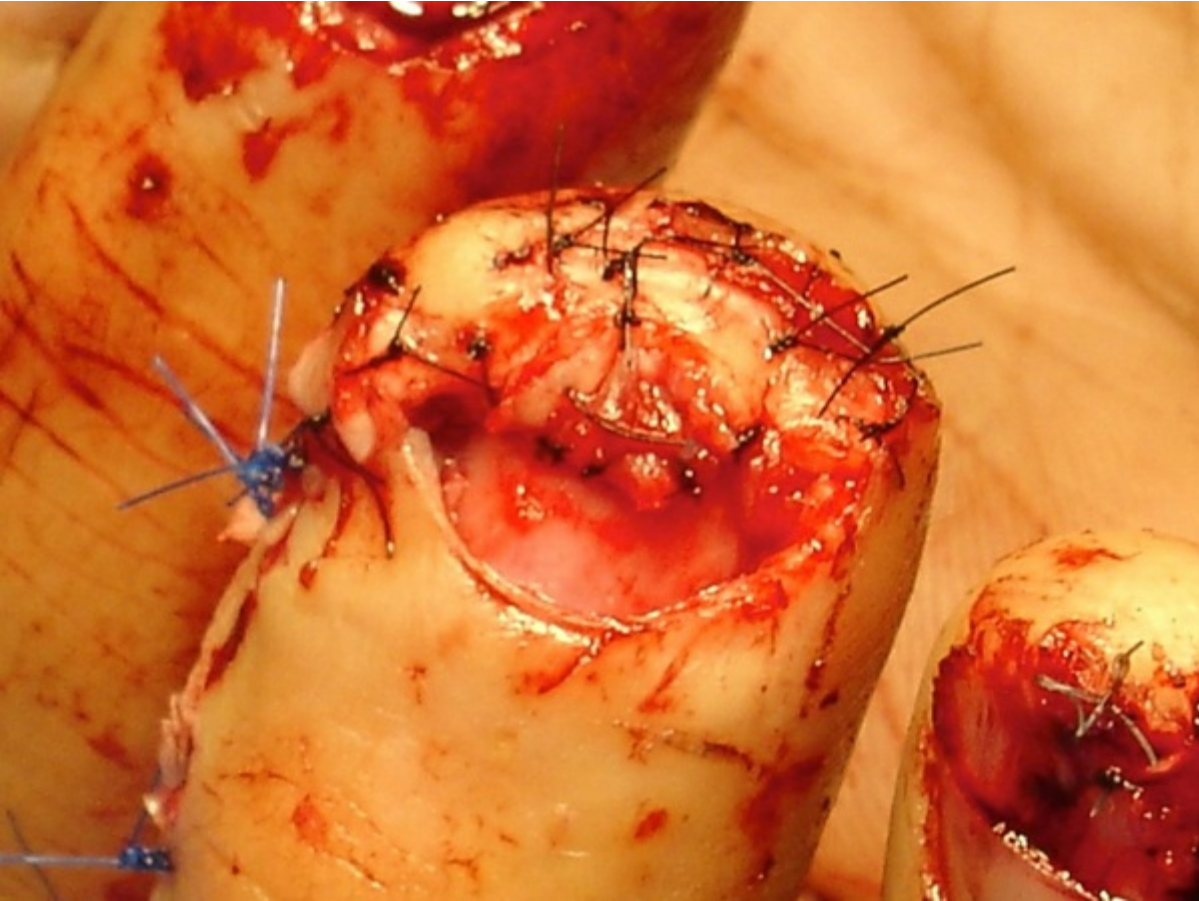


Figure 3-15 Accurate repair of the nail bed using 6-0 or 7-0 absorbable suture is critical if a cosmetically acceptable nail plate is to result.

After the repair, the nail or a substitute such as a silicone sheet, a prefabricated nail replacement, or a sliver of aluminum from a suture pack should be replaced back under the eponychial fold and sutured into place with 5-0 or 6-0 nylon (see [Figure 3-9](#)). This will have the effect of allowing the underlying repaired nail bed to mold together and help to splint any underlying bony fracture. A drainage hole can be placed into the nail to promote drainage of blood or serum from the repair site. Occasionally, the sterile matrix can be avulsed out from under the eponychial fold. These need to be repaired anatomically back underneath the field. If it is too far proximally, divergent oblique incisions at the corners of the eponychium will allow it to be flapped back and expose the underlying laceration (see [Figure 3-3](#)).

When the nail plate is avulsed proximally out of the nail fold, one needs to remove the nail completely, not just replace it back underneath. This will allow accurate repair of the sterile or germinal matrix, following which the nail plate may be reinserted and sutured down.

If there is a significant amount of nail bed missing, no other tissue graft will allow the nail plate to regrow and adhere. Several approaches have been advocated:

- Split-thickness nail bed graft from adjacent intact nail bed. This works with small defects.
- Split-thickness graft from a toenail, understanding that it may leave a permanent disfigurement in the toe.
- If there are adjacent fingers that have been amputated or mangled beyond repair and there is intact nail tissue, it can all be used as a composite graft.¹¹

After reconstruction, a nonadherent dressing is placed. At 7 to 10 days, the dressing is changed and the wound is inspected for infection or seroma ([Figure 3-16](#)). All sutures are out by 3 weeks, leaving the nail fold “implant” in place to be pushed out by the regrowing nail plate.

Injuries to the nail apparatus can be considered to be trivial injuries and relegated for treatment to physicians unfamiliar with the nuances of these injuries. Unless these injuries are cared for by experienced and trained staff, suboptimal results may ensue.

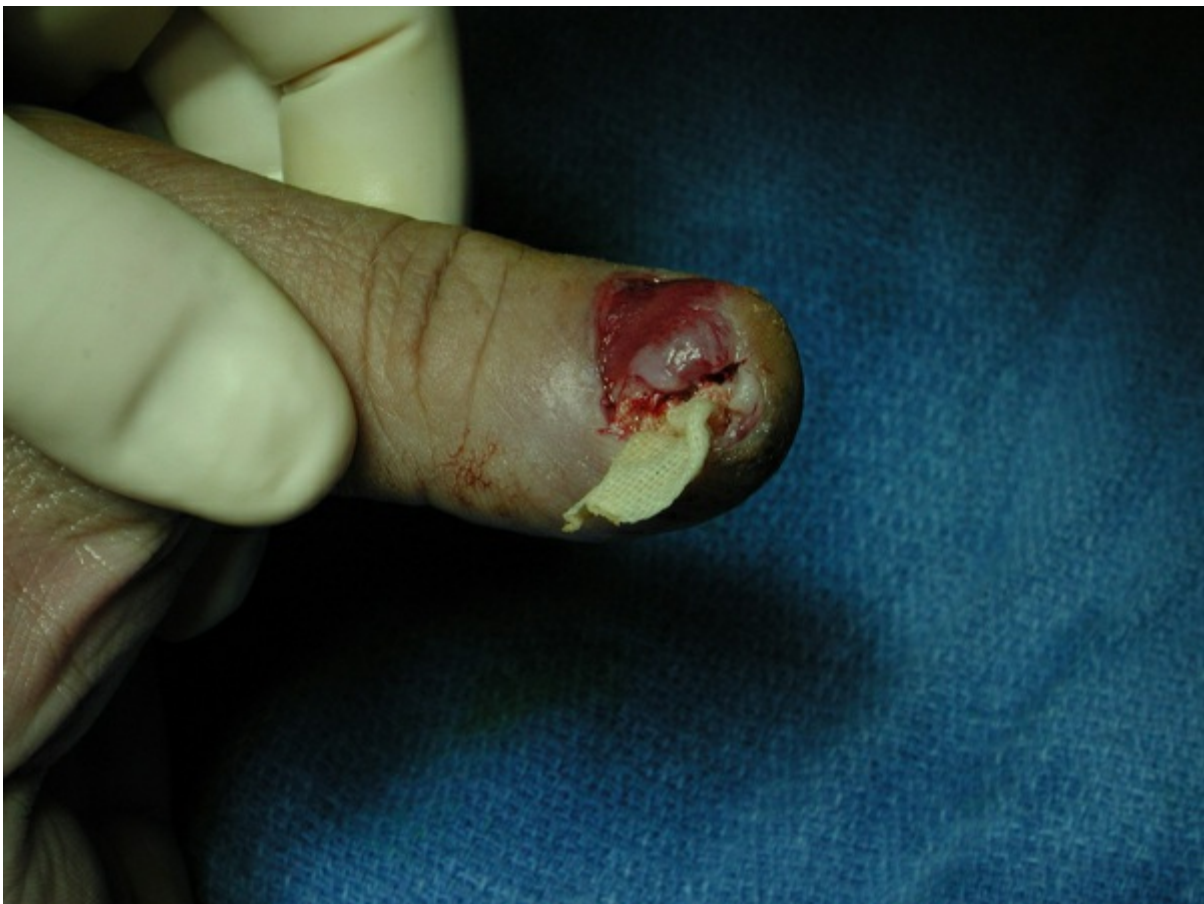

Figure 3-16 Two weeks after a nail bed repair, dehiscence necessitated incision and drainage and packing of the initial laceration.

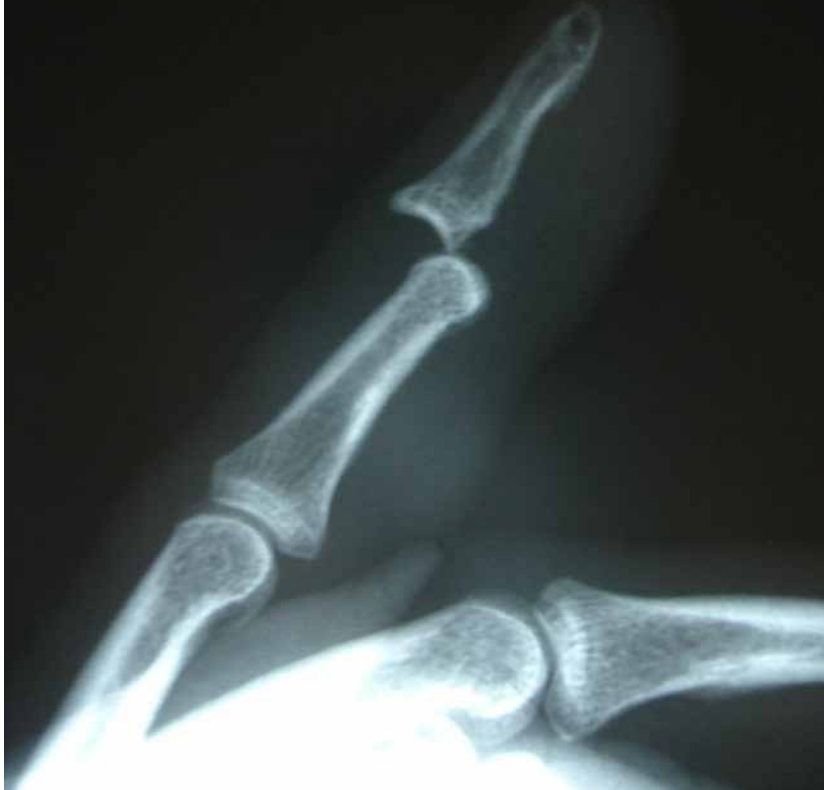Distal Interphalangeal Joint Dislocations

Stability of the DIP joint is due to its primary and secondary stabilizers. The ligamentous apparatus, the collateral ligaments, and the volar plate, which are intimate with the joint, provide a check-rein to hyperextension and lateral stress. The arrangement of

the ligaments is similar to those of the PIP joint. Secondary restraint is provided by the insertions of the terminal flexor and extensor tendons. It is interesting that the volar plate in the DIP joint, which is confluent with the terminal extent of the flexor digitorum superficialis (FDS) insertion, has no formal check-rein ligaments and is relatively weaker than the volar plate in the PIP joint.

Dislocations of the DIP joint are quite unusual owing to the short lever arm of applied stresses, but when they occur, they are usually dorsal or lateral ([Figure 3-17](#)). The mechanism of injury may be hyperextension, hyperflexion and shear, or lateral deviation. They are generally closed, but sometimes the head of the middle phalanx can herniate volarly through the skin. When these injuries are closed, they can be reduced under digital block anesthesia. Reduction of the dislocation is accomplished by longitudinal traction, volarly directed pressure on the dorsal rim of the proximal distal phalanx, and then downward pressure to flex the DIP joint. Hyperextension of the DIP joint should be avoided because it can convert the dislocation into an irreducible one, secondary to volar plate interposition. A postreduction x-ray is necessary to confirm a stable, congruent reduction. If the reduction is unstable although congruent, the joint can be stabilized with a longitudinal K-wire for 3 weeks. If the reduction is stable, treatment is closed. The DIP joint is placed into an extension block splint for about 3 weeks at about 20° of flexion using a dorsal-blocking splint. Full flexion is allowed at 1 week. After 3 weeks, full range of motion exercises are begun.

A



B

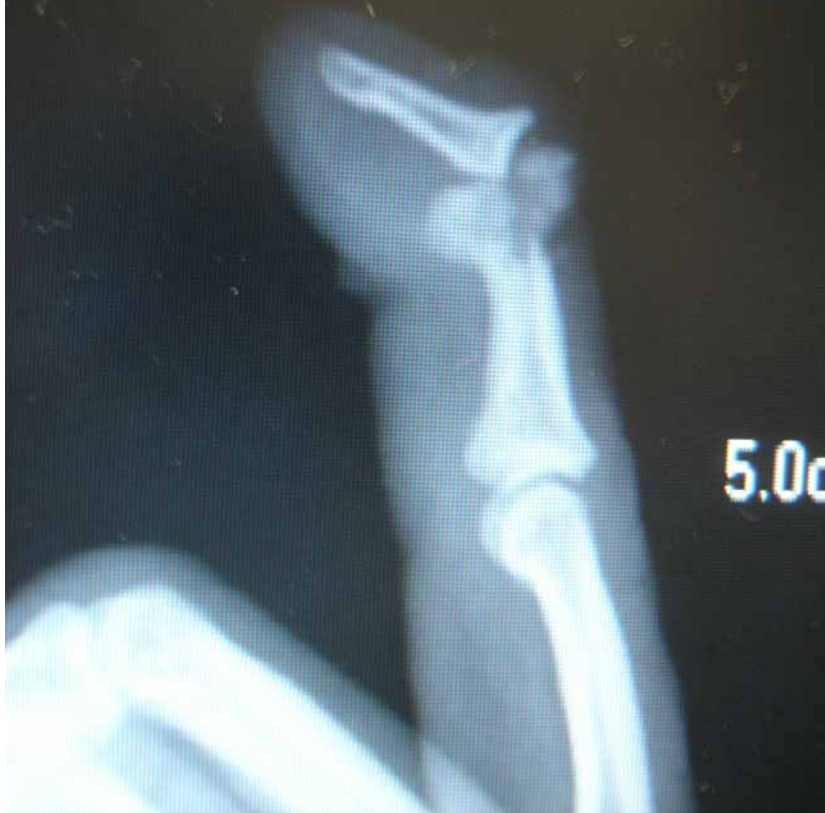

Figure 3-17 A, Dorsal dislocation of the DIP joint. These can be usually be reduced closed. **B**, Irreducible DIP dislocation with soft tissue interposition

Any residual increased joint space must be viewed with suspicion. Soft tissue interposition will render the dislocation irreducible (see [Figure 3-17](#)). There may be many causes.

The volar plate may avulse off the middle phalanx and interpose into the site. The FDP terminus may be entrapped, either pushing the head of the middle phalanx to the ulnar side or having the head herniate through the FDP itself, which may or may not rupture the tendon.¹² Abouzahr et al¹³ found 12 irreducible dorsal dislocations of the DIP joint in the literature. The majority were sports injuries, that is, attempting to catch a ball. The ring and long fingers were most affected. Nine of the 12 were open injuries. The mechanism of irreducibility was due to volar plate avulsion and interposition and FDP entrapment. In this scenario, longitudinal traction will only tighten the FDP, making it even more entrapped. There may be fracture fragments or even sesamoid bones interposed as well.¹⁴ Similar to the PIP joint, there may be a large volar lip fracture of the distal phalanx with or without FDP rupture. This fragment may be large enough to render the joint unstable even after reduction. These need to be repaired. If the fragment is still irreparable, volar plate arthroplasty has been described and has met with success.¹⁵

Irreducible and open dislocations must be treated openly. All joint structures must be addressed, and if the FDP is ruptured, it should be repaired.

Although most dislocations are dorsal, volar dislocations have been described. These usually coincide with terminal extensor disruption, leading to the view that they are nothing more than mallet fingers. Irreducible volar dislocation with extensor tendon interposition has also been reported.¹⁶

Simultaneous dislocations of the DIP and PIP joints have been described¹⁷ ([Figure 3-18](#)). These are usually high-energy sports injuries and are both dorsal dislocations. The mechanism of injury is a hyperextension force applied to the fingertip dislocating the DIP joint. If the force is still not dissipated, the energy will be transmitted to the PIP joint and dislocate this as well. These are generally treated with gentle longitudinal traction on the finger under a digital block. The PIP joint is reduced first, easing the tension on the oblique retinacular ligament, then the DIP is addressed.

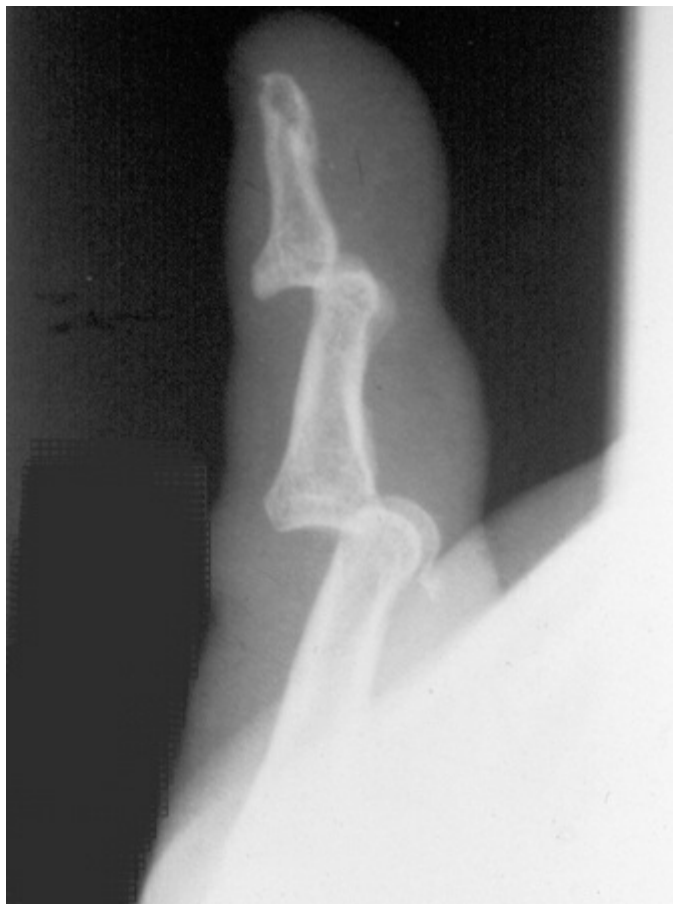

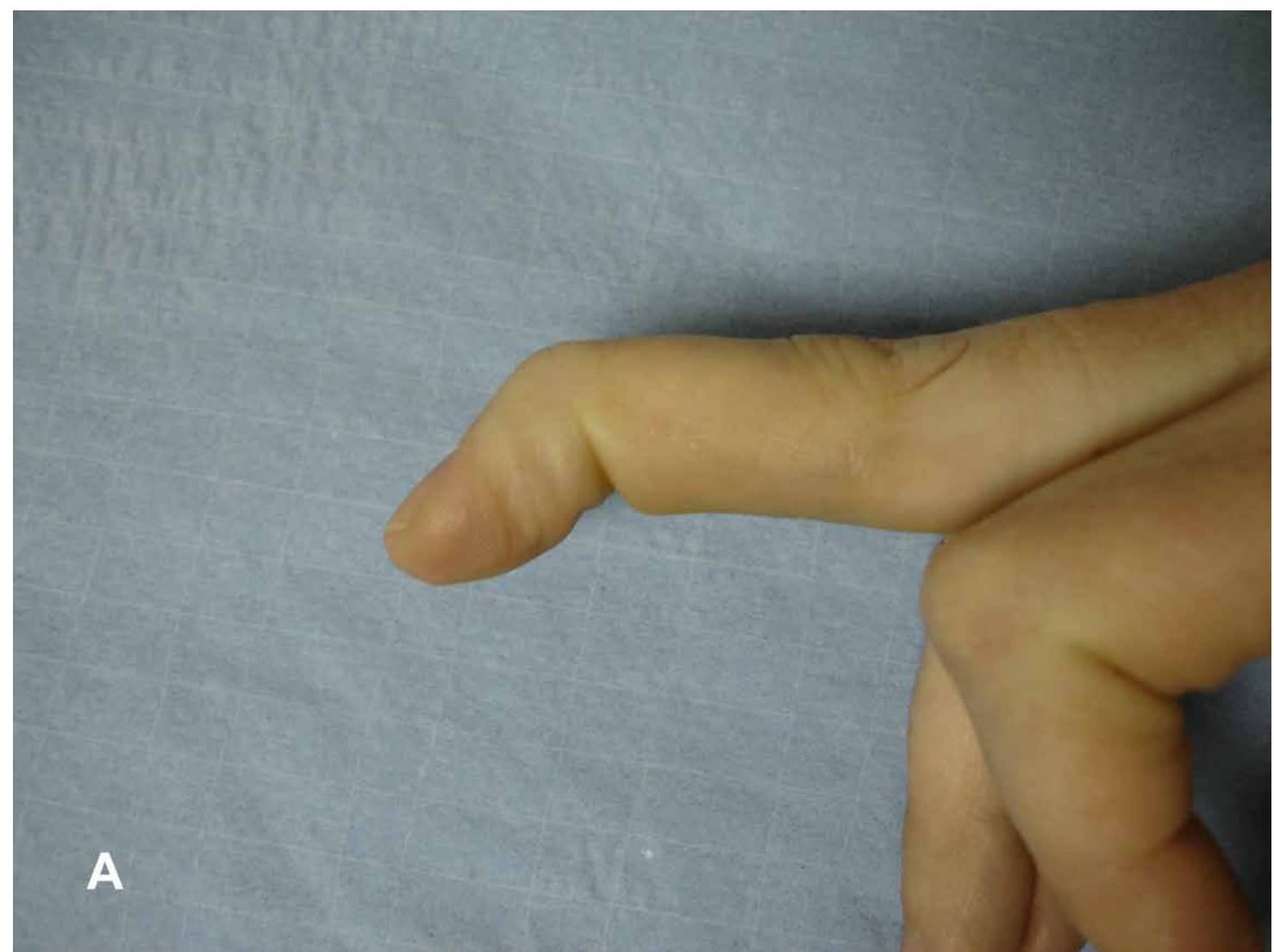
Figure 3-18 Simultaneous dislocation of the proximal interphalangeal (PIP) and DIP joint. The PIP joint is reduced first.

Single and double dislocations involving the DIP joint need to be addressed promptly. Any delay will make closed reduction difficult, if not impossible.¹⁵ Even if the joint is reduced, it is difficult to maintain because the joint capsule contracts and disruption in the joint space will significantly derange the metabolism of the hyaline cartilage and synovium in the joint. Degenerative change in the joint surfaces can occur rapidly.

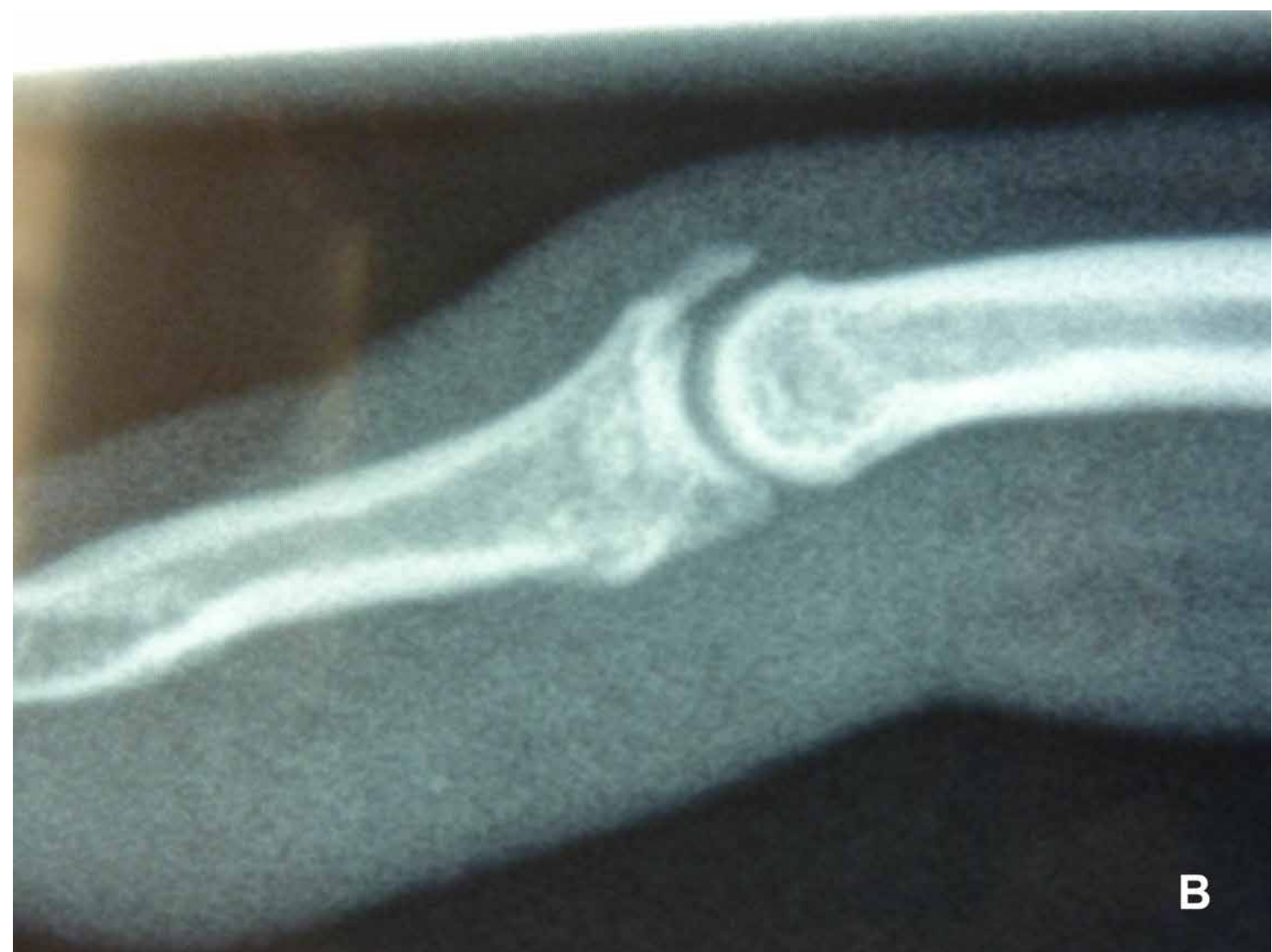Injuries to the Extensor Tendon Insertion at the Distal Interphalangeal Joint

Although the clinical presentation and mechanism of injury of mallet fractures resemble mallet fingers, the pathoanatomy and many aspects of the treatment of mallet fingers differ from mallet fractures. Both present clinically with a history of a hyperflexion/hyperextension injury to the DIP joint and an inability to extend it. Standard x-ray differentiates them.

Mallet fingers occur when the terminal extensor avulses from its insertion on the proximal dorsal lip of the distal phalanx (Figure 3-19). There may or may not be a fleck of bone attached to the tendon. The mechanism of healing of mallet fingers differs from mallet fractures, as well, in that, with fractures, there is bone-to-bone contact and the former must rely on a “scar bridge” to join the terminal end of the extensor tendon back to bone.

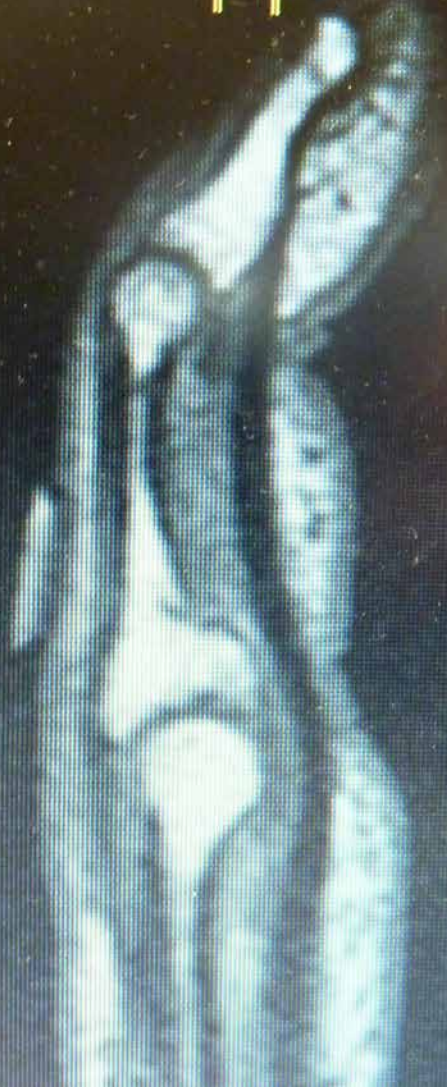

A



B

C



03:0
TR:
TE:
TI:
FA:

Figure 3-19 A, Mallet finger. Note the hyperextension of the PIP joint due to overpull of the central slip. **B**, X-ray of the finger shown in **A**. Note the avulsion fracture off the proximal dorsal lip of the middle phalanx. **C**, Magnetic resonance imaging (MRI) of a mallet finger. The extensor tendon terminates at the head of the middle phalanx, leaving a noticeable gap in continuity to the distal phalanx.

Mallet fractures have the potential to destabilize the DIP joint itself because of the disruption in the bony architecture of the distal phalanx causing volar subluxation of the DIP. Pure tendinous mallet fingers do not.

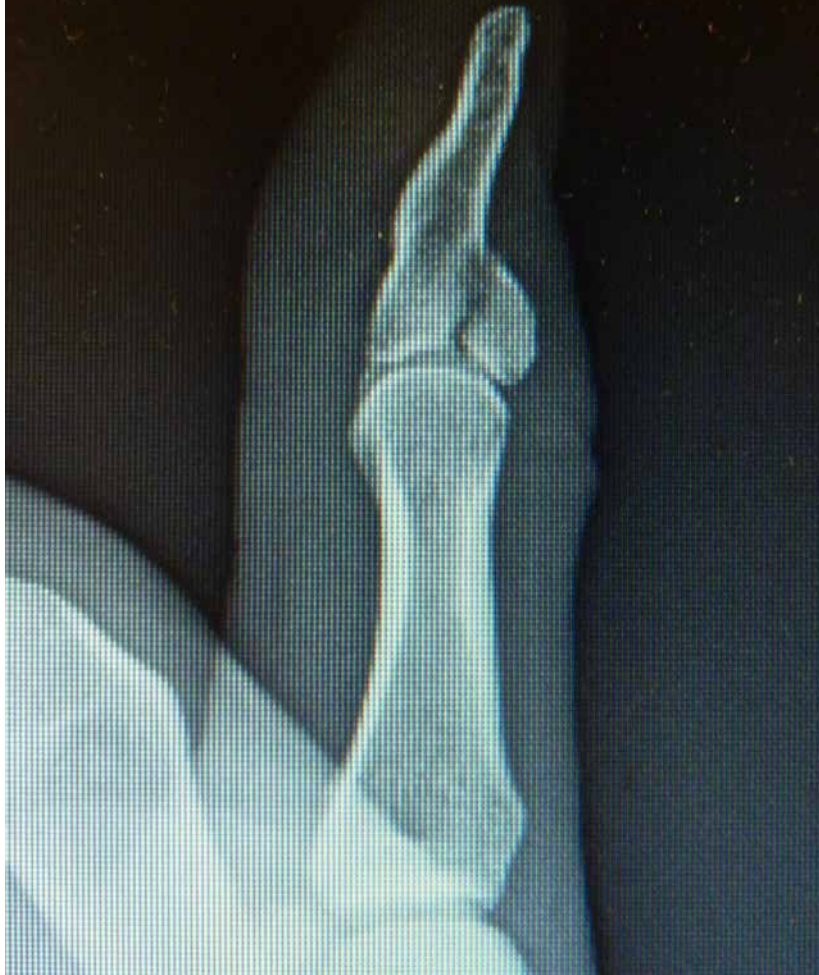Doyle¹⁸ classified mallet fingers into 4 types:

- Closed deformity with or without a “fleck” avulsion fracture of the dorsal base of the distal phalanx (see [Figure 3-19](#))
- Open laceration of the tendon at the DIP joint
- Open injury by deep avulsion or abrasion involving the skin, subcutaneous tissue, and tendon

Fractures of the distal phalanx classified into subtypes:

- Fracture of the transepiphyseal plate in children: Seymour fracture (see [Figure 3-11](#))
- Hyperflexion injury leading to intra-articular fracture of the distal phalanx involving 20% to 50% of the joint surface ([Figure 3-20](#))
- Hyperextension injury leading to fracture involving greater than 50% of the joint surface (see [Figure 3-20](#))

A



B

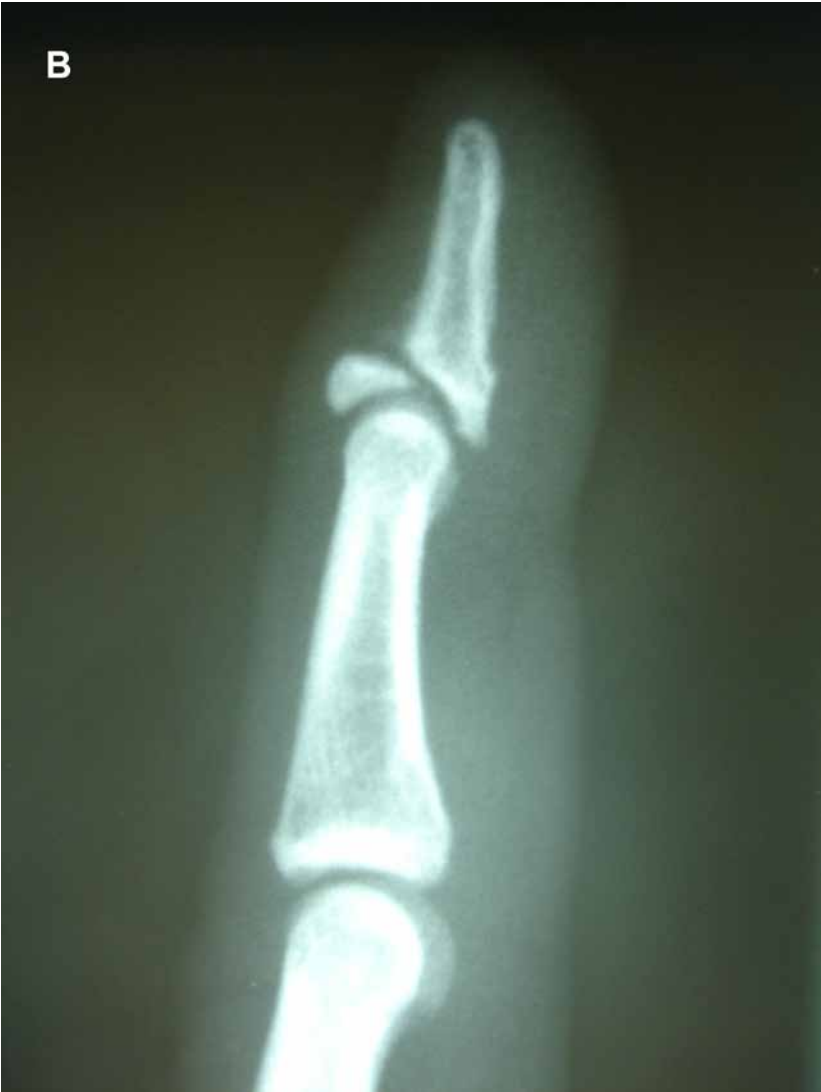

Figure 3-20 A, Nondisplaced mallet fracture involving 45% of the articular surface. **B**, Displaced mallet fracture involving 85% of the joint surface with volar subluxation of the distal phalanx.

Because of the fundamental differences in the pathomechanics and management of mallet fingers versus mallet fractures, they are dealt with separately.

Mallet Fingers

Although mallet fingers may appear to be a trivial injury, in some studies up to 25% of patients miss 6 weeks of work, sports, or even activities of daily living.¹⁹ Neglecting mallet fingers can lead to permanent fingertip disfigurement, dorsal DIP pain and inflammation, restricted DIP extension, and swan neck deformity. Laxity of 1 mm between the terminal extensor tendon and the distal phalanx will result in a 25° extensor lag.²⁰ This can all be prevented by prompt treatment.

The first report of mallet finger treatment was by Mason in 1930²¹ who advocated immediate surgical intervention for closed mallet fingers. Smilie in 1937²² devised a plaster splint to hold the DIP in hyperextension and the PIP joint in flexion. The “Stack” splint (Figure 3-21)²³ was invented in 1962 and made conservative treatment of mallet fingers more popular. Auchincloss in 1982²⁴ compared external splinting to surgical care for acute closed mallet fingers in 41 patients and found no difference in outcome. He even believed that there is no need to splint at all after 6 weeks.

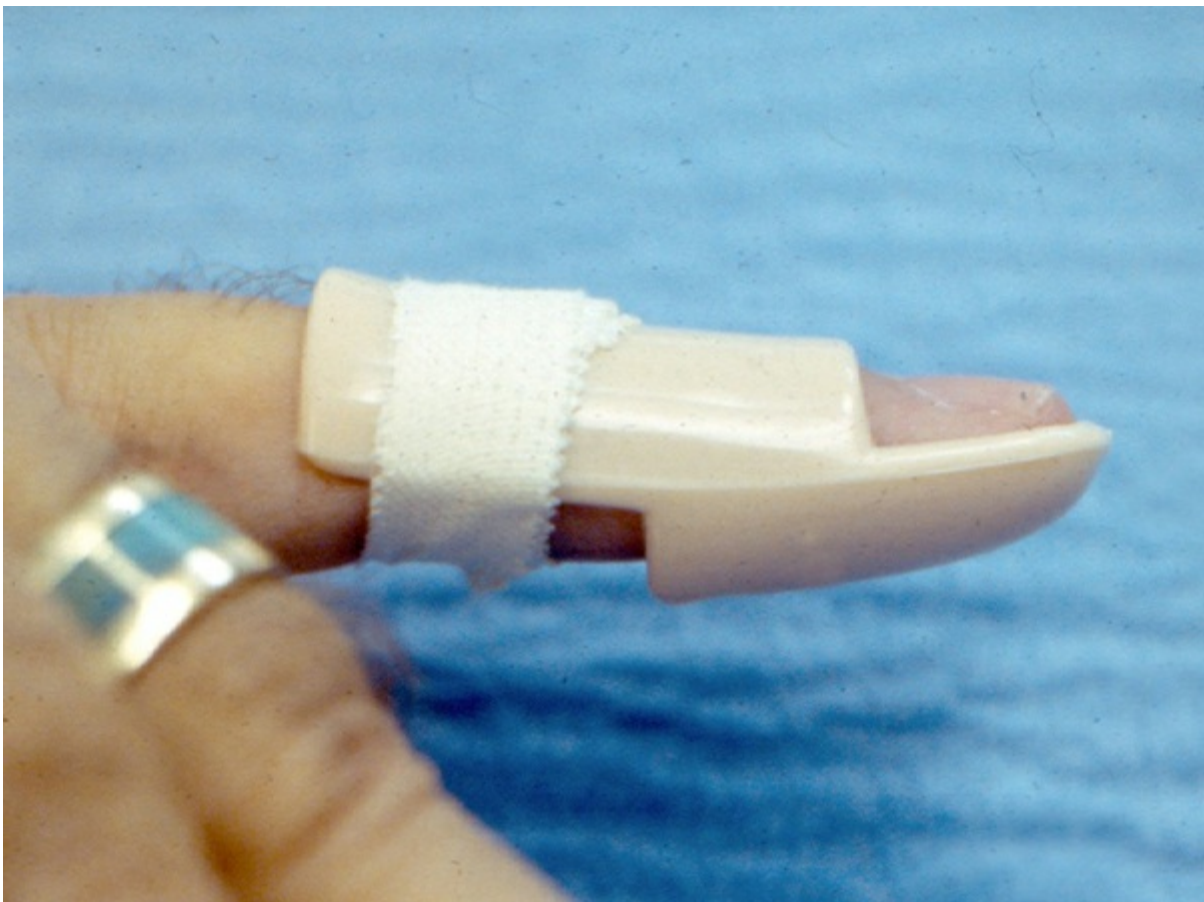


Figure 3-21 Stack splint.

There is now general agreement in the literature that initial treatment of closed mallet fingers should be nonoperative in a full-time splint that keeps the DIP joint in mild hyperextension ($<10^\circ$) for 6 to 8 weeks followed by a 4-week period of part-time (night) splinting.¹⁹ There is controversy about the best way to splint.

Most of the techniques reported used Crawford's criteria²⁵ to assess functional outcome of treatment:

- **Excellent:** Full DIP extension, full flexion, no pain
- **Good:** 0° to 10° of extension deficit, full flexion, no pain
- **Fair:** 10° to 25° of extension deficit, any flexion loss, no pain
- **Poor:** Greater than 25° of extension deficit or persistent pain

Okafor et al in 1997²⁶ reported on 31 patients treated in a thermoplastic Stack splint for an average of 7.2 weeks and followed for a mean of 5 years. There was a delay in treatment from 0 to 28 days. Of the 29 patients without fracture of less than 30%, the delay in treatment had so significant effect on outcome with regard to DIP motion or extension deficit. There was a significant positive relationship between length of splinting and final extension deficit. Patients with an intra-articular fracture had a higher incidence of degenerative changes on x-ray than those who were purely tendinous mallets. There were no complications reported in this series.

Warren and Norris et al²⁷ followed 116 patients who were randomized to wear either a Stack or an "Abouna" wire splint. Both splints were shown to be equally effective with either complete resolution of the mallet or nearly so at 10 weeks. The "Stack" was preferred by the patients as more comfortable. Maitra and Dorani¹⁹ compared the Stack splint with padded aluminum in a randomized trial in 60 patients and found that, although both splints were equally effective in correcting the extensor lag, the aluminum splint was more comfortable and had less dorsal skin maceration than the Stack. Pike et al in 2010²⁸ randomized 87 patients into 3 splint types:

- Volar-padded aluminum splint
- Dorsal-padded aluminum splint
- Custom thermoplastic splint applied to the volar side

All had the DIP in "slight" hyperextension and the PIP joint free. Splints were applied full time for 6 weeks and an additional 4 weeks if there was a lag of greater than 20°. There was 1 major complication—full-thickness skin ulceration. There were several minor complications with erythema, maceration, and some local anesthesia from splint pressure. At follow-up at 7, 12, and 24 weeks, there was an extension lag of between 5° and 10°, but it was not statistically significant at 12 weeks.

In a prospective randomized controlled trial, O'Brien and Bailey²⁹ compared the dorsal aluminum, custom circumferential thermoplastic and Stack splints followed up at 12 and 20 weeks. Splints were worn continuously for 8 weeks. Patients wearing Stack splints and aluminum splints (5/21 each) experienced skin maceration, problems with splint fit, pain, and breakage. The thermoplastic splint group (22 patients) had no complications. All experienced excellent results by Crawford's criteria²⁵ (extensor

lag of 6.4), and there was no difference between the groups.

Handoll and Vaghella in 2009³⁰ conducted a meta-analysis on splint treatment and concluded that there was “insufficient evidence to determine which splint type is best but that the splint must be stout enough to withstand everyday use.”

There has been some discussion in the literature about the vascularity to the dorsal skin over the DIP joint relevant to blanching of that skin when the DIP is hyperextended and to potential pressure from a dorsally applied splint. Flint in 1955³¹ described the vascularity of the dorsal skin of the DIP joint. The blood supply to the dorsal skin arises from dorsal branches arising from the volar digital arteries. These dorsal terminal vessels form an arcade where the branches join. Hyperextension of the DIP joint causes blanching by stretching the volar arteries and compression of the dorsal arcades by the buckling of the overlying skin. Rayan and Mullins in 1987³² showed that skin blanching occurred when the DIP joint was hyperextended to 50% of maximum in healthy volunteers. That blanching can be reproduced when a tight dorsal splint is applied.

Stern and Kastrupin 1987³³ reviewed 84 patients who were splinted and found a 45% complication rate that included skin maceration and ulceration.

Mallet Fractures

The most common articular fracture at the base of the distal phalanx is the “mallet” fracture. These occur as a result of axial load on the extended fingertip buckling it into flexion. It can cause a disruption between the terminal extensor and the distal phalanx, or it can fracture the dorsal lip of the phalanx, which migrates proximally with the terminal extensor. The bony component can be a mere avulsion or can involve more than 60% of the articular surface. The majority of these are closed injuries. If left untreated, the flexed posture of the DIP joint is likely to be permanent. Wehbe and Schneider³⁴ classified these fractures into 3 types and 3 subtypes:

- **Type 1:** No subluxation of the distal phalanx
- **Type 2:** Volar subluxation of the distal phalanx
- **Type 3:** Fracture involves the whole distal phalanx

- **Subtype A:** Fragment size less than 30% of the joint surface
- **Subtype B:** Fragment between 30% and 70% of the joint surface
- **Subtype C:** Fragment greater than 70% of the joint surface

Husain et al³⁵ in a cadaveric study showed that volar joint subluxation was not observed until the joint involvement in the fracture exceeded 43% and was consistent beyond 52% of the joint surface (Figure 3-22).

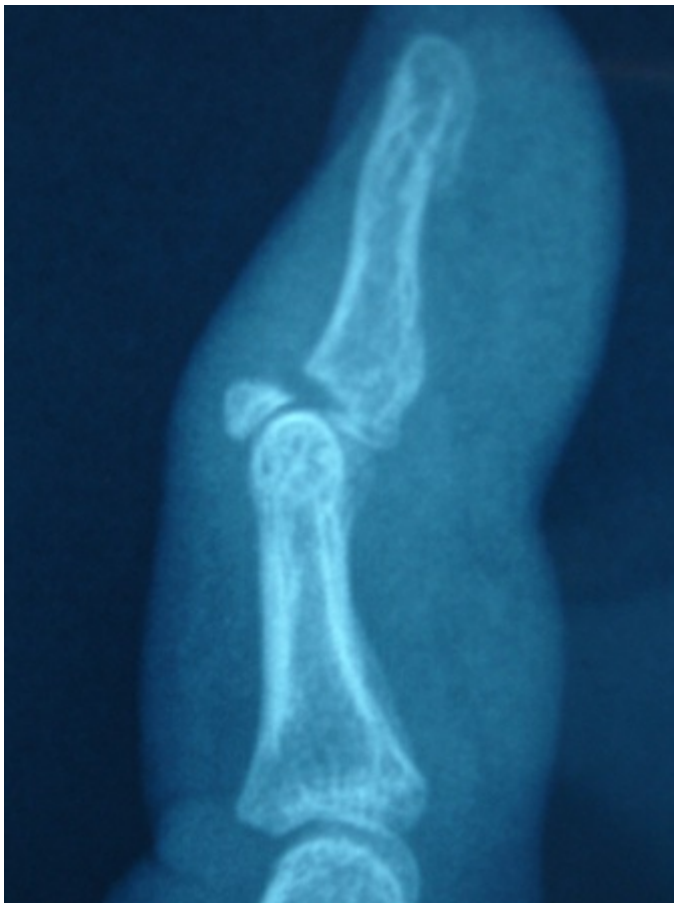

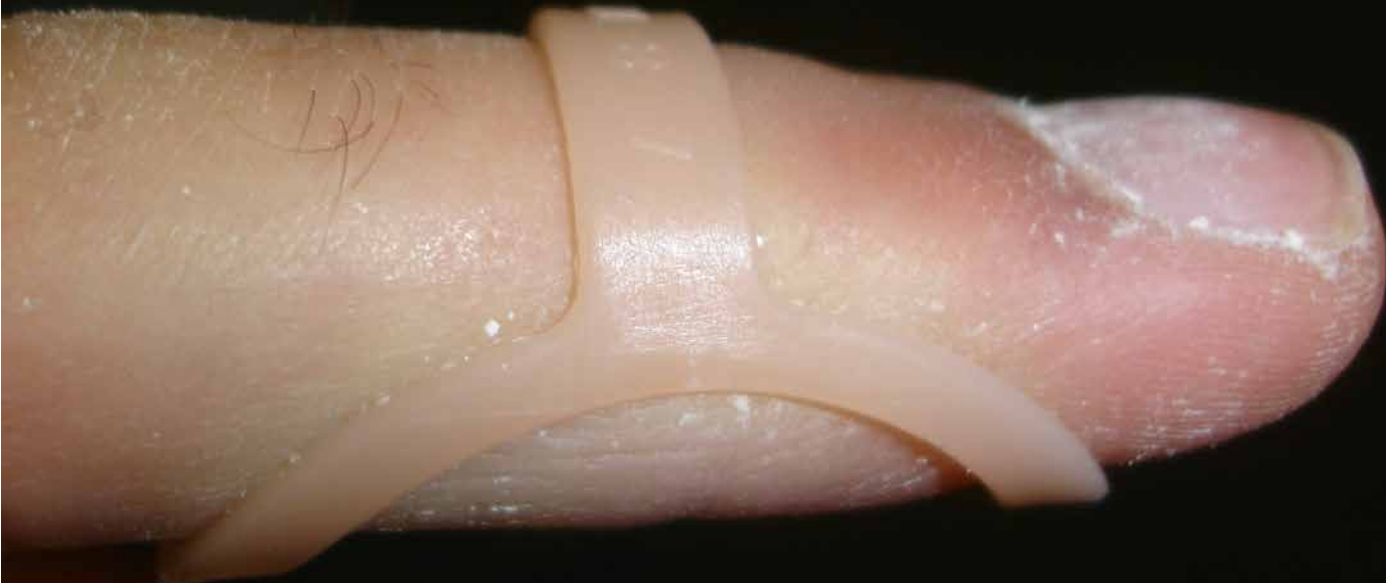Figure 3-22 Mallet fracture involving 60% of the articular surface with volar subluxation of the distal phalanx.

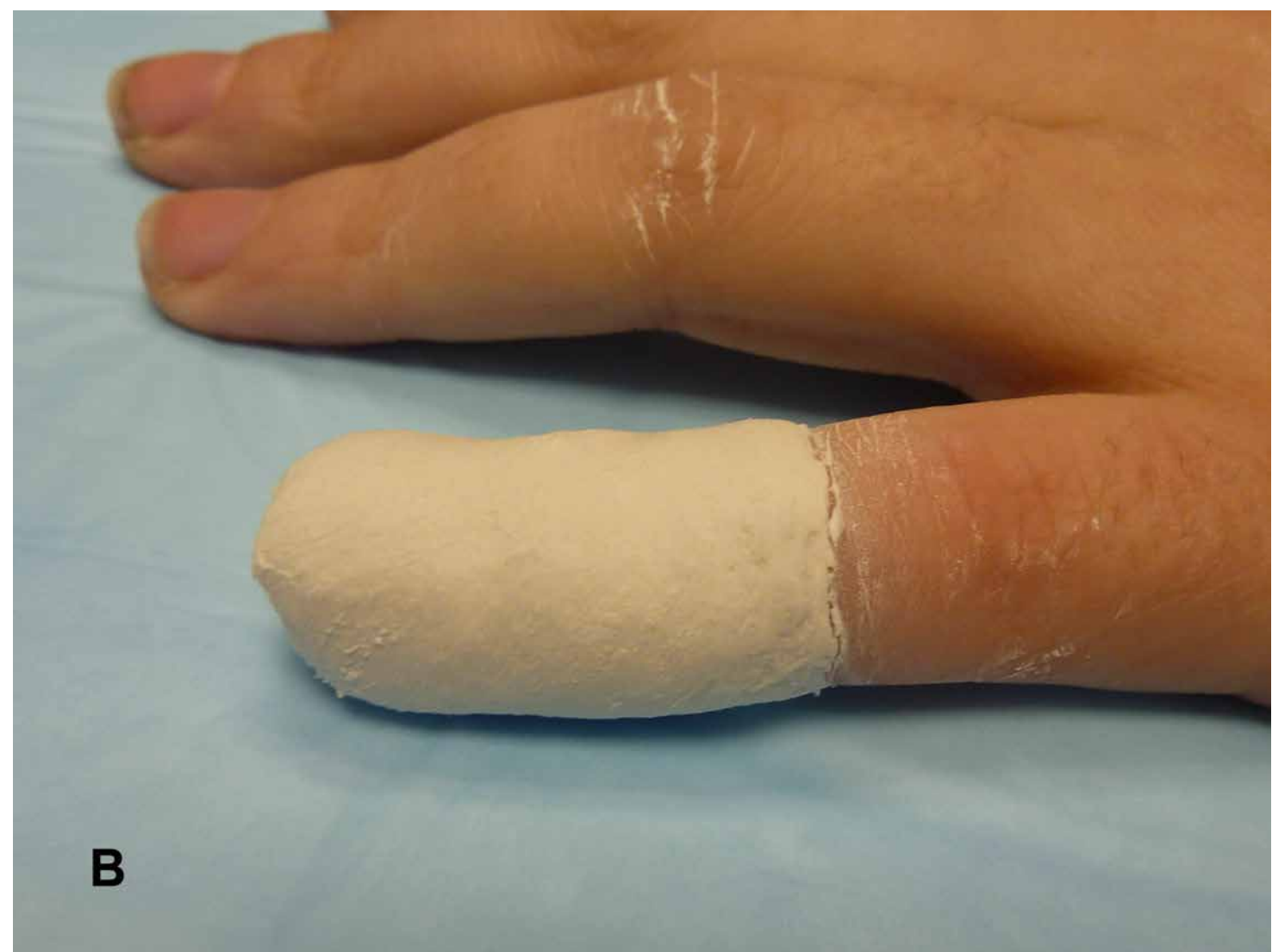The treatment of mallet fractures is highly controversial. Wehbe and Schneider³⁴ have strongly advocated the nonoperative treatment of nearly all mallet fractures except in significant volar subluxation of the distal phalanx on the head of the middle phalanx and fracture involvement of greater than 30% of the DIP articular surface, claiming the significant incidence of adverse outcomes when these injuries are treated surgically. However, when their patients were followed out to 3 years, 50% were seen

to have degenerative changes and stiffness in the DIP joint. In 1988, Stern and Kastrup³³ compared K-wire fixation with splinting and found that splinted patients had a 45% complication rate compared with 76% with the K-wires possibly due to technical errors. These included nail deformity, osteomyelitis, pulp scarring/pain, nonunion or malunion, pin breakage, pin migration, and loss of reduction. However, Luhban et al³⁶ compared nonsurgical treatment with surgery and concluded that surgery patients had cosmetically and functionally superior outcomes than nonoperative patients.

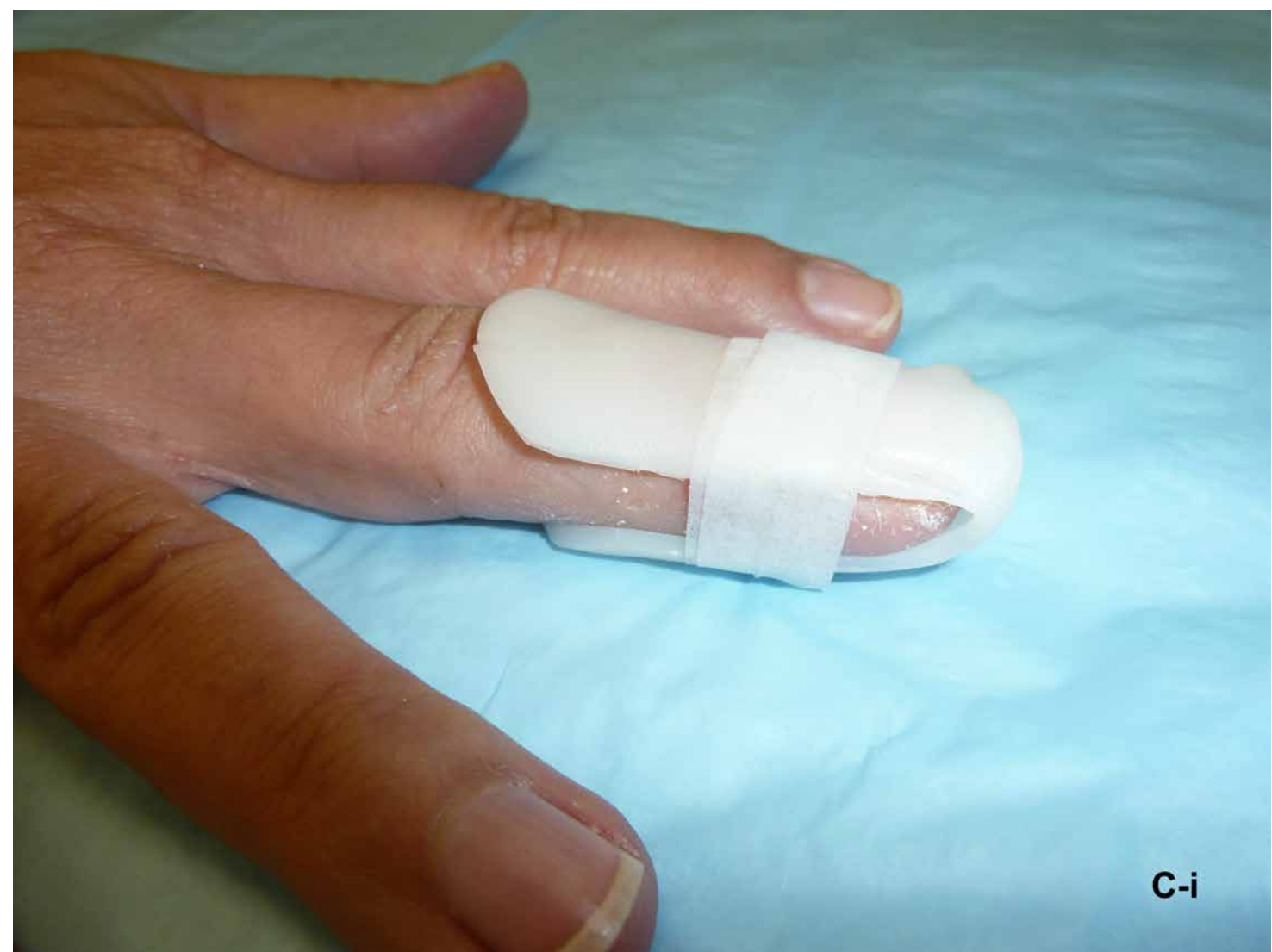Nonoperative treatment of mallet fractures include “Alumafoam” splinting, plaster finger casts, Stack and Oval-8 splints, and custom-made Thermoplastic custom-fit orthoses (Figure 3-23). These are all designed to maintain full extension of the DIP joint so that the avulsed fragment can reasonably be opposed to the main body of the distal phalanx. There is no expectation that there will necessarily be an anatomic reduction of the fracture, just enough continuity of the extensor mechanism to allow near-full DIP extension. Frequently, patients remain with a tender bony “bump” on the dorsum of the DIP joint (Figure 3-24).

A

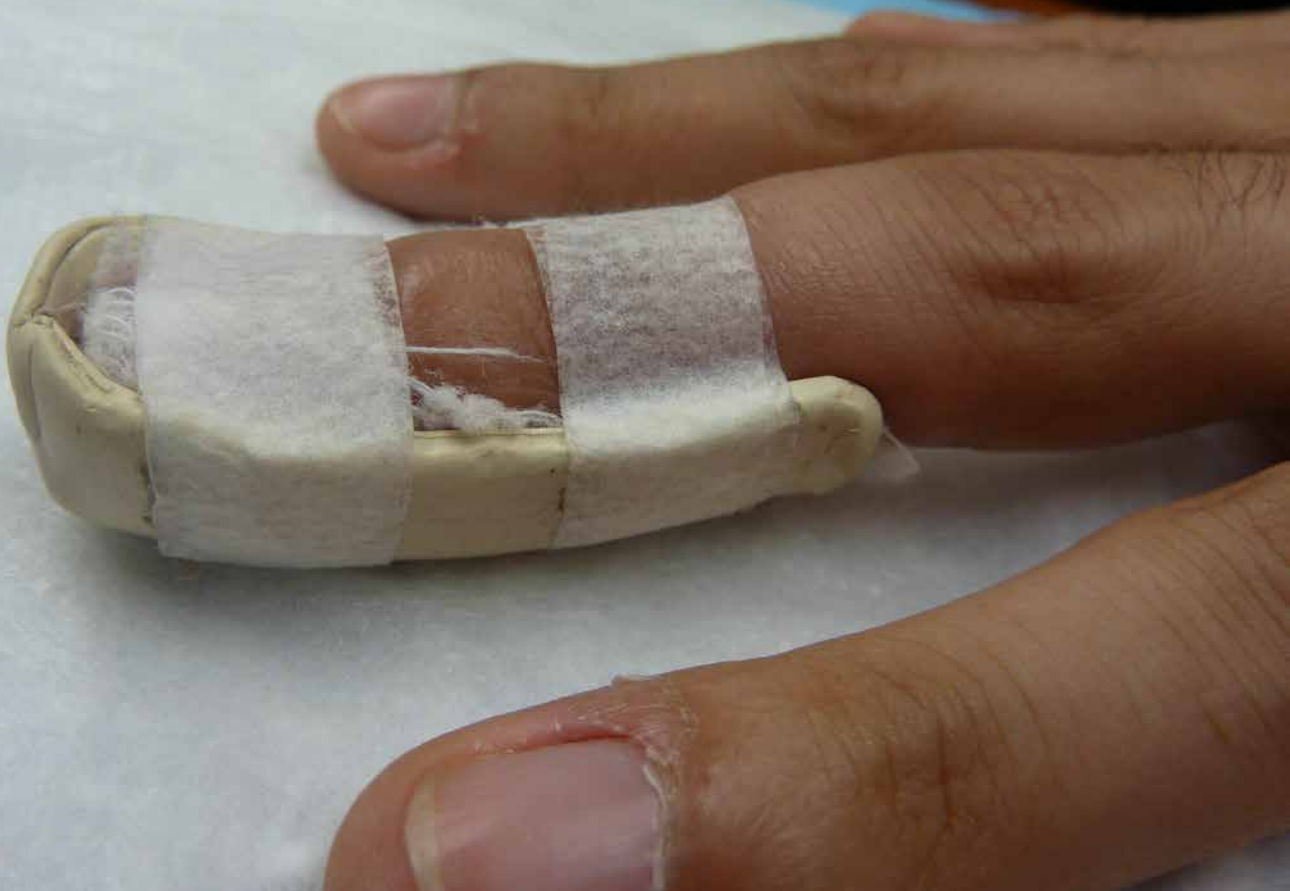



B

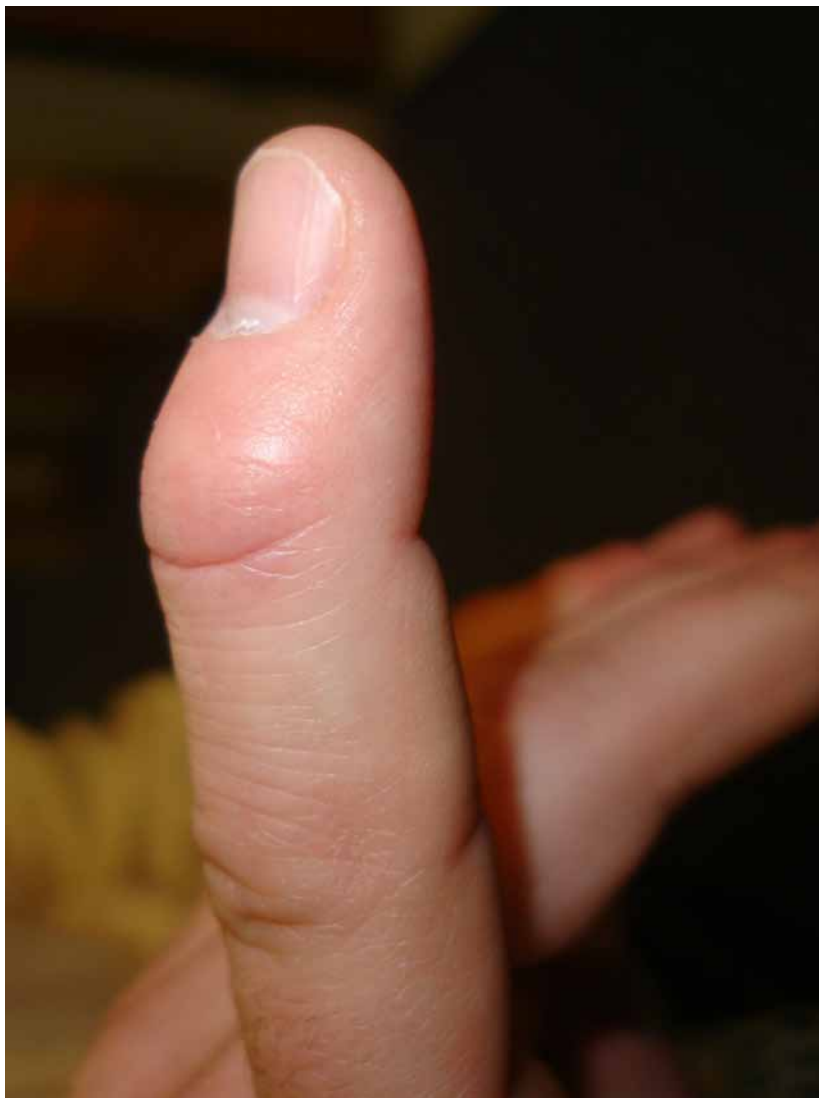

C-i



C-ii

Figure 3-23 **A**, Oval-8 splint. **B**, Plaster cast holding the DIP in 5° hyperextension. Care must be taken not to overextend the DIP to avoid vascular compromise to the dorsal skin. **C**, Custom therma-plast orthotics.



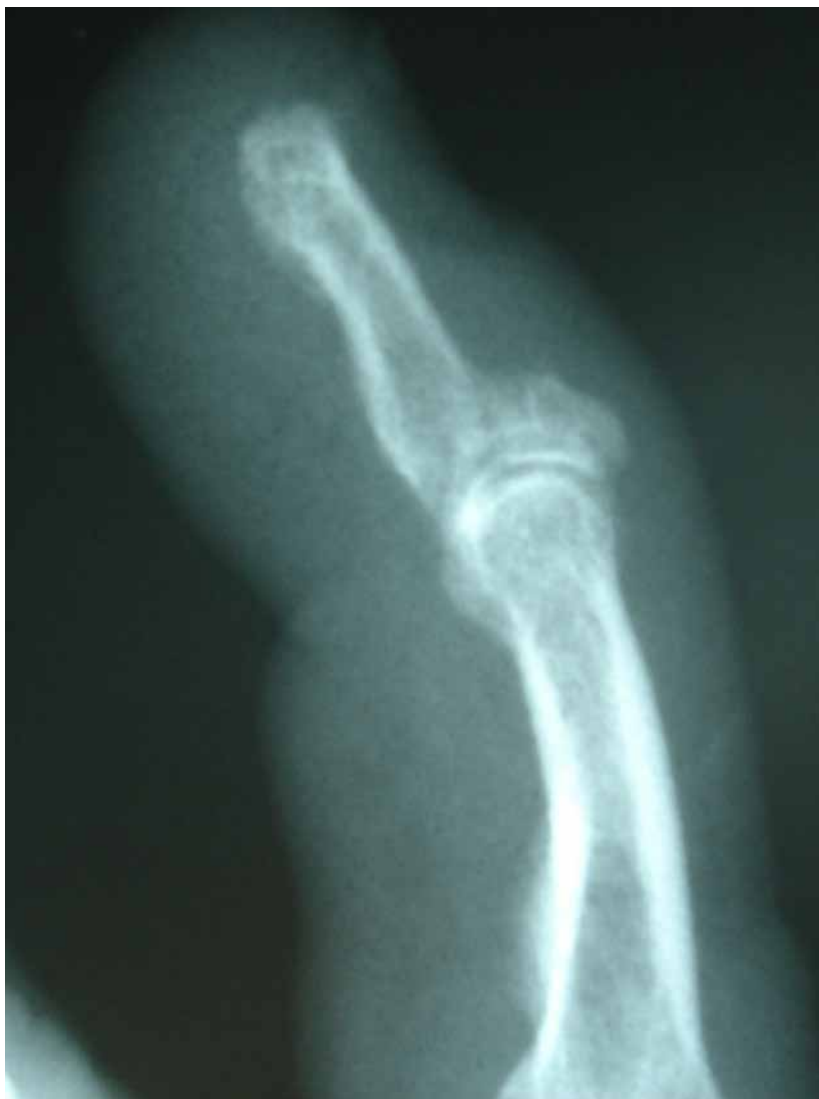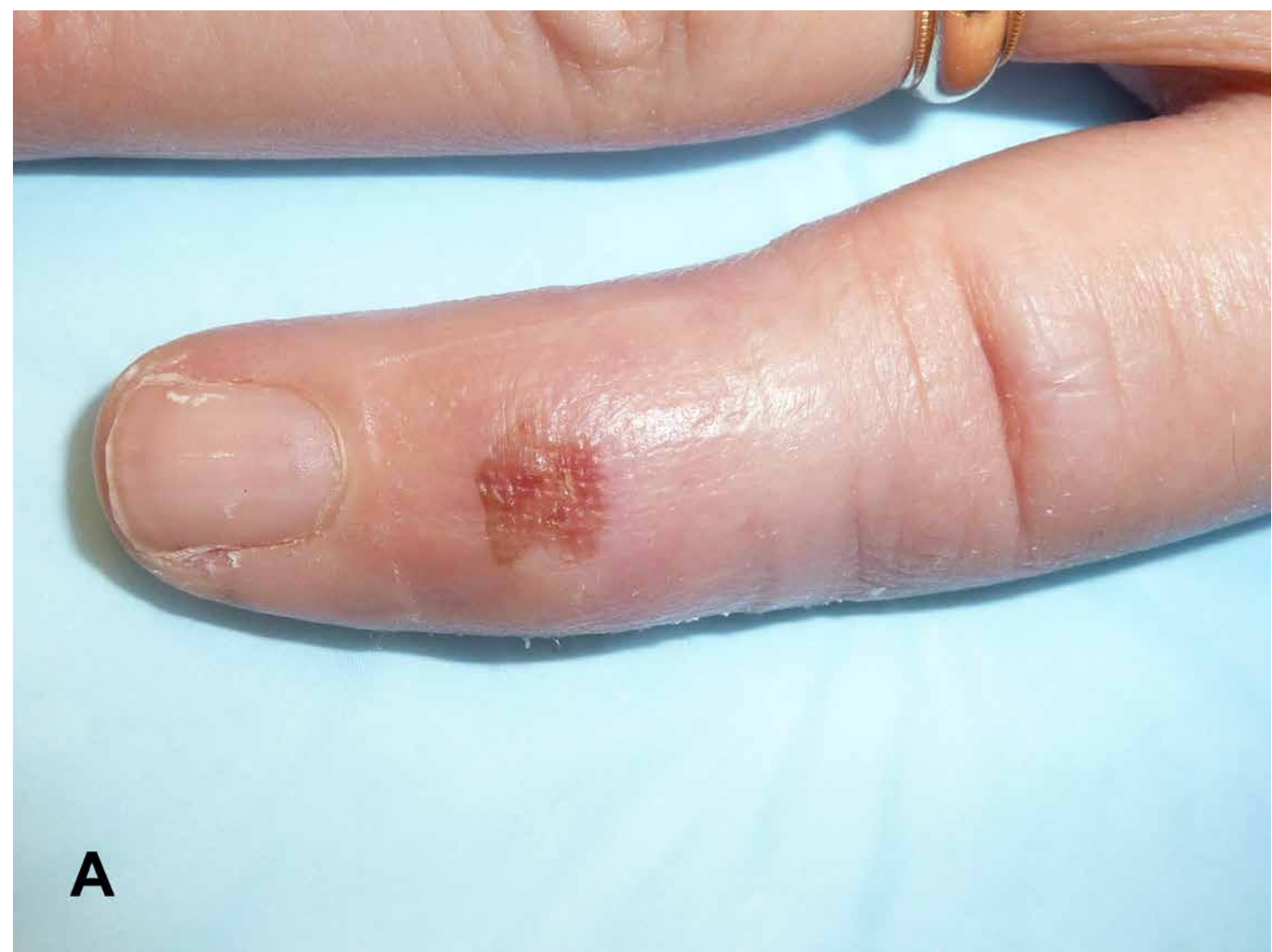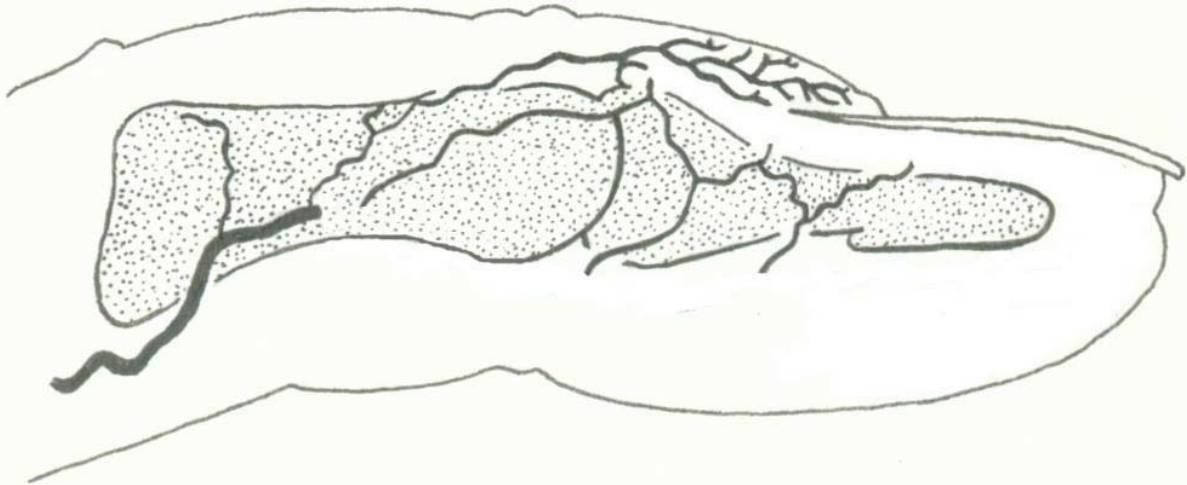


Figure 3-24 Tender bony lump on the dorsum of the DIP joint. Patient was treated in a stack splint for 8 weeks full time and 4 weeks part time. Despite the fact that the dorsal fragment has healed and the DIP joint is congruent, the painful deformity remains.

Complications of closed treatment also include pressure sores, maceration, and skin necrosis on the dorsum of the DIP, which can be full thickness (Figure 3-25). This is due to the tenuous blood supply to the dorsal skin overlying the extensor tendon insertion.²⁷ Recurrent flexion deformity and hyperextension contractures can occur, as well. Chronic malunions and resultant flexion deformities of more than



A



B

Figure 3-25 A, Pressure sore on the dorsum of the DIP joint from hyperextension splinting. **B**, Schematic drawing of the microvascular tree of the fingertip. Note the circulation to the dorsal skin proximal to the eponychial fold. With hyperextension of the DIP joint, those arterioles become compressed under the skin and can create a localized zone of ischemia.

10° at the DIP joint will result in a secondary swan-neck deformity and even degenerative changes in the DIP joint.

Many methods have been used to treat mallet fractures:

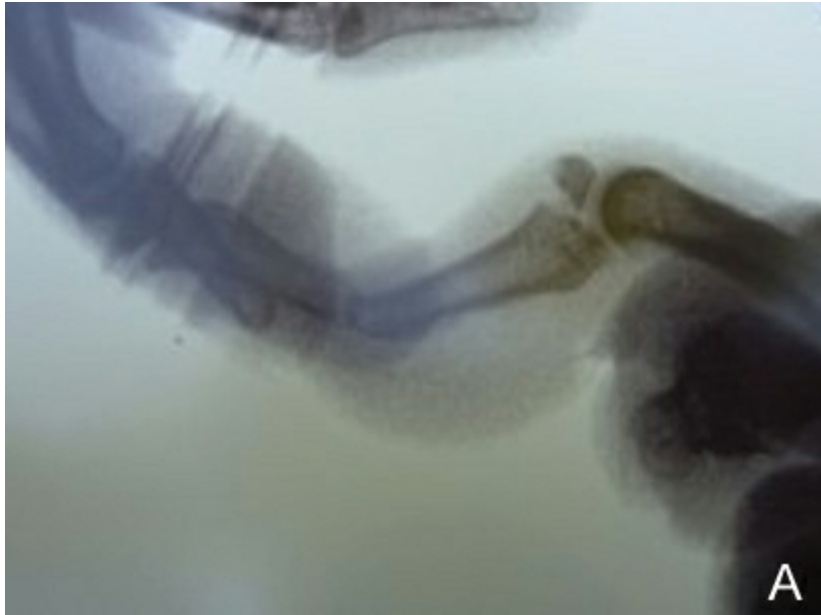- Percutaneous DIP joint pinning in extension.
- Tension band wiring of the avulsed fragment to the distal phalanx.
- Extension block pinning to “jam” the avulsed fragment against the distal phalanx into compression.
- Interfragmentary pinning/compression screw fixation of the avulsed fragment to the distal phalanx.
- Suture anchor fixation of the fragment to the distal phalanx.

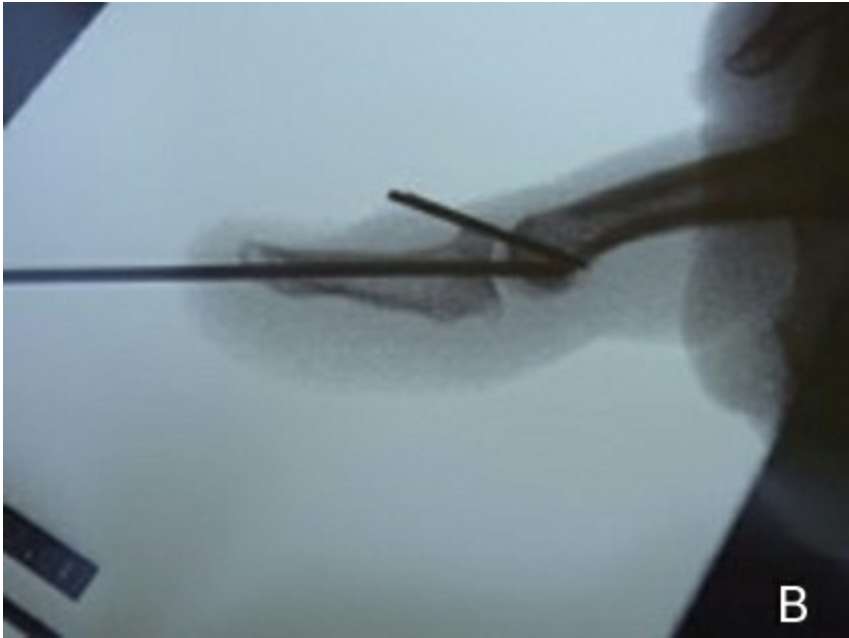- Pull-out wires or sutures over a volar button.

It should be noted that these techniques are rarely required and are presented only for management of fractures associated with a grossly unstable DIP joint.

Technique of Extension Block Pinning

With the DIP joint fully flexed, a 0.045-mm K-wire is introduced into the head of the middle phalanx proximal to the avulsed fragment through the terminal extensor tendon at an angle of 45° to the long axis of the shaft of the middle phalanx, facing proximally. Extend the DIP joint until the avulsed fragment lines up with the fracture surface of the distal phalanx. This may take some side-to-side and rotatory manipulation to achieve reduction. After reduction is achieved, a K-wire is placed across the DIP. One can drive an interfragmentary pin across the fracture site for further stability (Figure 3-26). Pins remain in place for about 6 weeks and the finger is protected with a splint for an additional 2 weeks. Multiple pins traversing the DIP articular cartilage, however, can have a detrimental effect, resulting in arthritis.





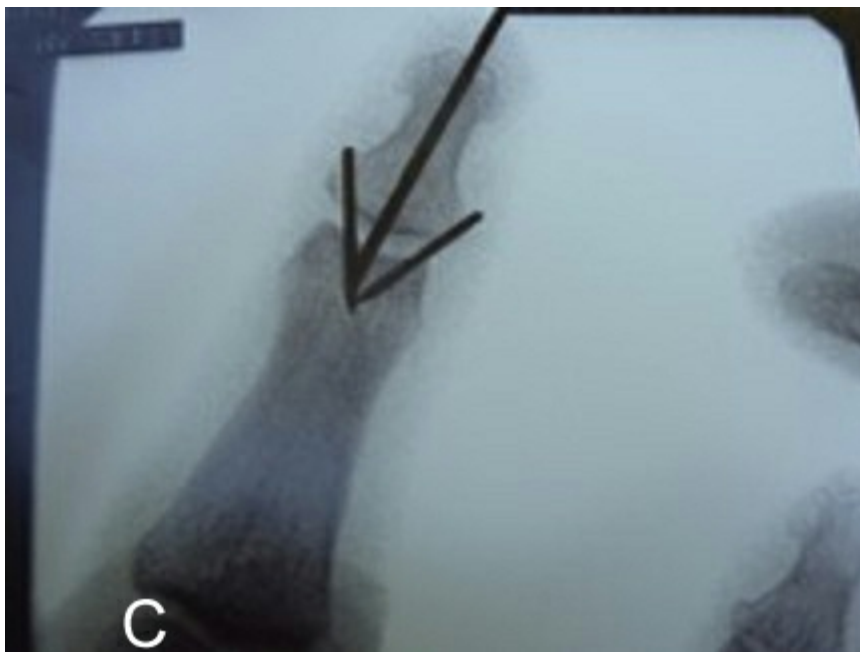


Figure 3-26 A, Displaced mallet fracture involving 50% of the articular surface. **B**, After a closed extension block pinning, care must be taken not to overreduce the fracture. **C**, Posteroanterior postoperative view. The extension block pins should not be parallel.

In 2003, Hofmister et al³⁷ reported their results with extension block pinning and found that the average time to union was 35 days, and at 1 year follow-up, the extension lag was 4° and the average flexion was 77°. They cite that, according to the Crawford classification,²⁵ 38% had excellent results with no extension loss, full DIP flexion, and no residual pain. Fifty-four percent had good results with up to 10° of extensor lag.

Technique of Tension Band Wiring

An H-shaped incision is made over the DIP joint. With the fracture exposed and debrided, 30-gauge cerclage wire is threaded transversely through the metaphysis of the distal phalanx beyond the fracture site. Two 0.035-mm K-wires are placed perpendicularly across the fracture site manually, which compress and reduce the fracture. The cerclage wire is passed around the K-wires and twisted until firm compression is achieved across the fracture. The wires are bent and cut.

Bischoff et al,³⁸ in their review of this technique, reported a 45% complication rate. These included wound breakdown, loss of reduction, and infection. Others have confirmed their findings.

Percutaneous Distal Interphalangeal Pinning

With the DIP in full extension or 5° of hyperextension, a 0.045-mm or 0.054-mm K-wire is driven under x-ray control across the DIP joint into the head of the middle phalanx. The wire may be buried or left exposed. Auchinloss²⁴ compared single-pin fixation without attention to the avulsed fragment to closed treatment alone and found a lower complication rate with a diminished extensor lag in the pin fixation group (6° vs. 10°). Pin patients reported a better subjective outcome than the closed group.

Fritz et al in 2005³⁹ described a modification of the single-wire technique in 24 patients. The fracture was opened through a dorsal approach and debrided to a clean cancellous surface. In DIP flexion, an antegrade 1-mm wire is drilled distally through the fracture site and through the tip of the finger until the tip of the wire just disappears through the fracture. The DIP joint is extended, reducing the fragment manually, and the wire is then drilled proximally through the fragment and the DIP joint. The wire was removed in 4 weeks and active range of motion exercises commenced. Follow-up time was 43 months. Fingers extended to within 2° of full extension and flexed to 72°. Nineteen patients were pain-free and 5 had mild pain with activity.

Interfragmentary Screw Fixation

After exposing the fracture distal to the DIP joint through a dorsal approach, the fracture site is cleaned and held in reduction with a towel clamp. After confirming the reduction on x-ray, 2 or 3 0.5-mm drill holes are placed perpendicularly across the fracture site and 0.8-mm screws are placed across the fracture (Figure 3-27). The finger is splinted for 6 weeks and then full range of motion is instituted. Kronlage and Faust⁴⁰ reported on 12 patients followed for 31 months. There were no postoperative complications and the average extensor lag was 6° with flexion of 70°.

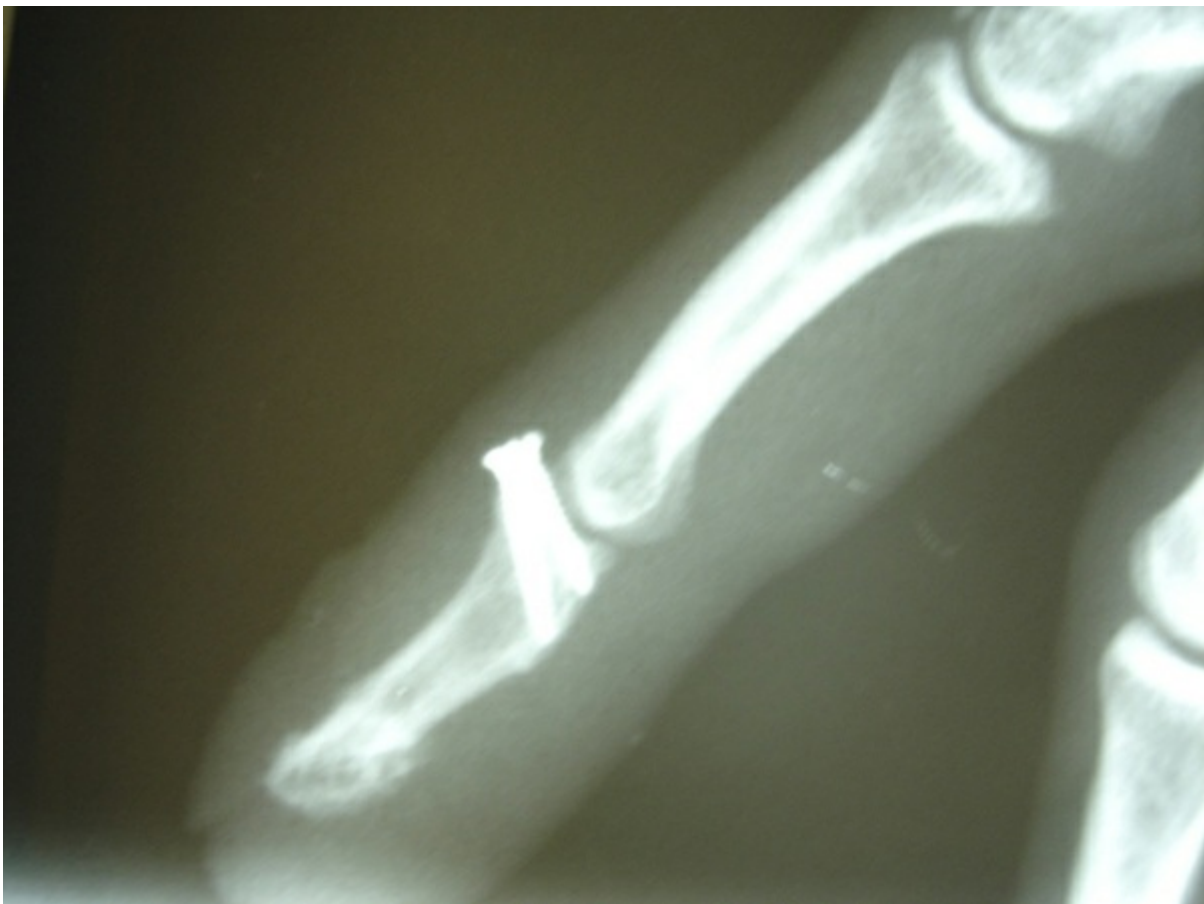

Figure 3-27 Interfragmentary screw fixation of the mallet fracture. This can be augmented by a transarticular K-wire

Pull-Out Wires Over a Volar Button

Kang et al⁴¹ reported on 59 patients who underwent interfragmentary fixation with 4-0 nylon or 24-gauge cerclage wire tied around the fracture, passed through 2 drill holes in the distal phalanx and tied over a volar button (Figure 3-28). The DIP joint was

pinned in extension with 0.9-mm K-wire. Pull-out wire was removed at 4 weeks and the K-wire was removed at 6 weeks. There was a 41% complication rate, which included skin breakdown, superficial and deep infection, recurrent mallet deformity, radial deviation of the DIP joint, and nail deformity. However, Zhang et al⁴² did a variation of the pull-out wire technique in 65 patients with an average joint involvement of 39% and DIP joint subluxation. Their technique avoided placement of a button on the volar surface of the finger. Rather, the pull-out wire was attached to an outrigger composed of a K-wire that runs transarticular through the DIP, and the segment out of the tip is bent volarly to capture the pull-out wire emerging from the pad. The K-wire is spring-loaded to maintain the pull-out wire in traction. After surgery, there was no skin necrosis, breakdown, or any infection. At 25 months' follow-up, all the fractures had healed uneventfully without fragmentation. Only 1 out of 64 patients had noticeable DIP joint pain. The mean extensor lag was 7° and the mean active DIP joint flexion was 76°.

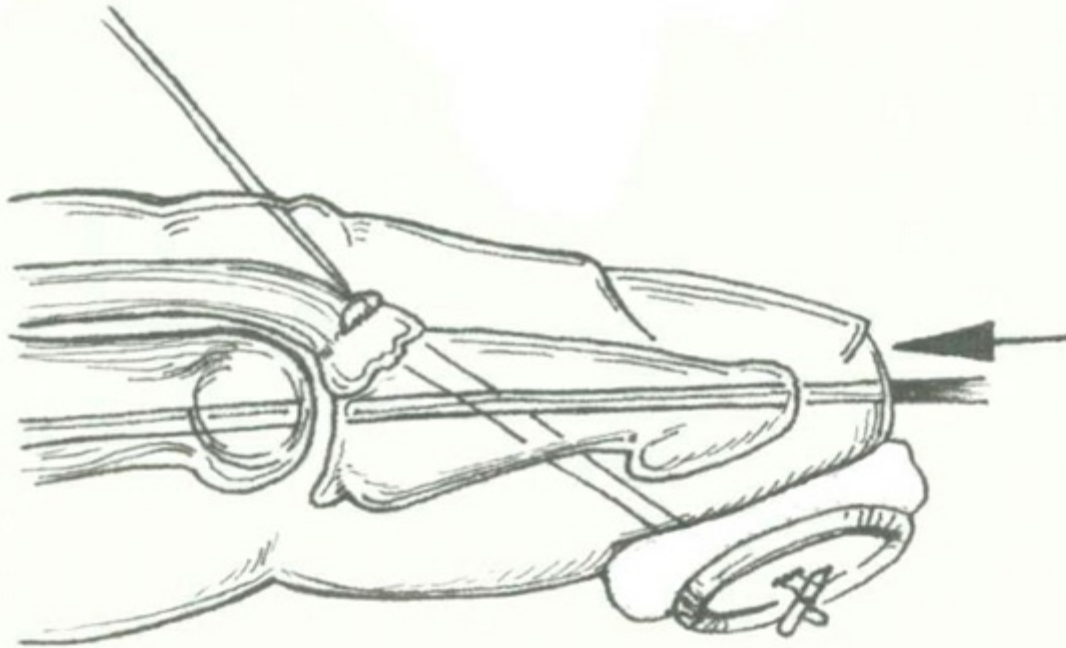


Figure 3-28 Pull-out wires over a volar button. Care must be exercised to avoid volar skin necrosis.

“Umbrella Handle” Technique

Rocchi et al in 2006⁴³ described a technique in 48 patients over 8 years utilizing a single 1-mm K-wire passed across the fracture site and out through the distal phalanx and volar skin. After bending the tip of the wire proximally, the wire is pulled from the volar side until the “hook” captures the proximal fragment and holds it in place under a small dorsal skin incision. The volar side of the wire is passed through a small volar thermoplastic cap and bent around the cap to secure the fragment. Patients are allowed immediate active range of motion of the DIP joint without restriction. The wire was removed at 6 weeks. They reported a 90%

good to excellent result according to the Crawford rating system.²⁵ One postoperative pin tract infection was reported.

Open Pinning of the Fracture and the Distal Interphalangeal Joint

Phadnis et al in 2010⁴⁴ reported their technique of open reduction and pin fixation of mallet fractures involving greater than 30° of the joint surface with associated subluxation in 20 patients. After opening the fracture site through a dorsal incision, the subluxation is reduced and held with a 1.25-mm K-wire across the DIP joint to the middle phalanx. The fracture is reduced and pinned with converging 0.6- mm K-wires (Figure 3-29). Wires are removed at 6 weeks. At 1 year follow-up, 16 patients had good to excellent results by Crawford's criteria.²⁵ Three were fair and 1 was poor. There was 1 superficial wound infection and there was loss of reduction.

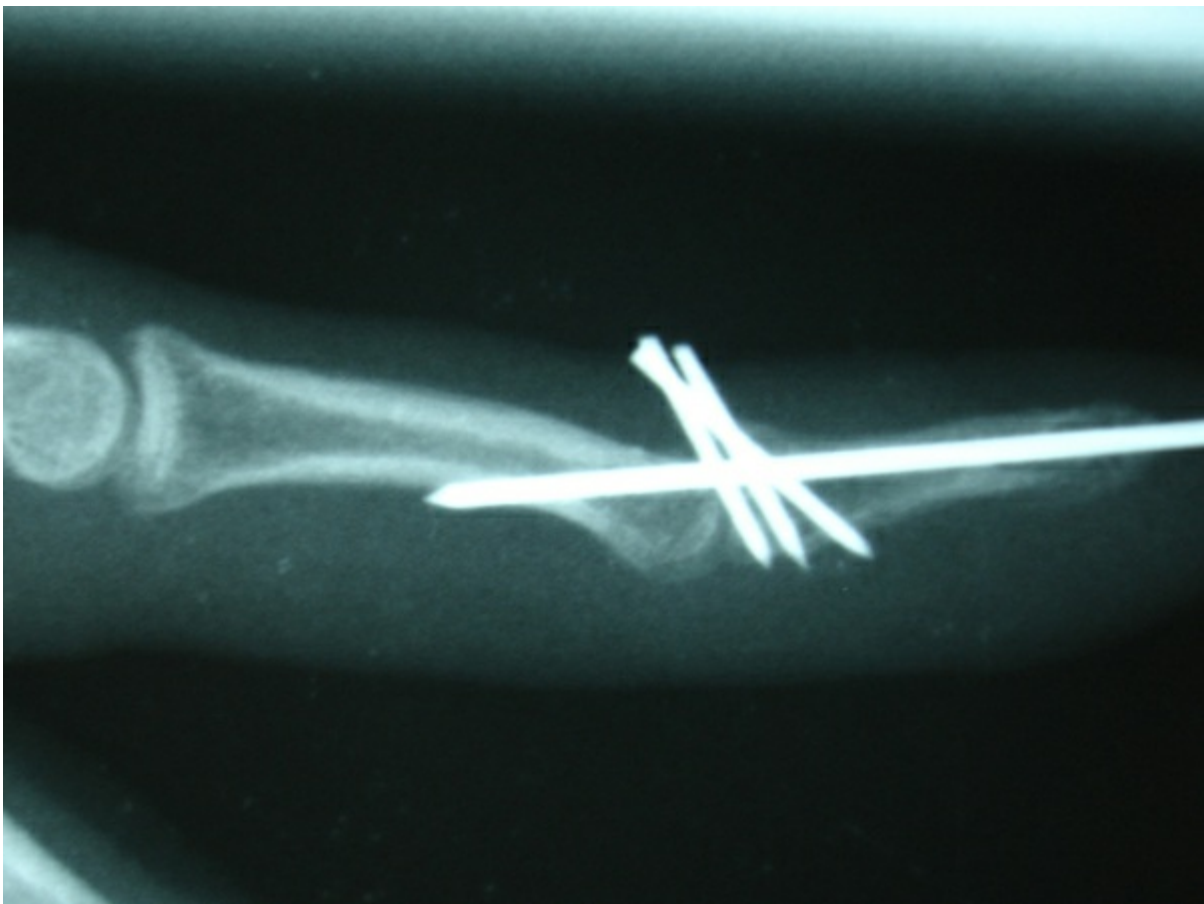

Figure 3-29 Interfragmentary pinning across the fracture site with the DIP joint stabilized with an 0.045-inch K-wire.

Open Reduction Internal Fixation Using a Hook Plate

Teoh and Lee⁴⁵ described the use of a “hook plate” fashioned from a titanium 1.3-mm plate using 1 hole and a second hole is cut through. The resulting prongs are then bent into a hook. The prongs are used to grip the bony fragment while the intact hole is

attached distally with a screw. Nine patients were followed at an average follow-up of 17 months. All the patients had a good or excellent result by Crawford's criteria.²⁵ There were no implant or skin complications or any infections. This technique did necessitate removal of the implant at a later time.

Lucchina et al in 2011⁴⁶ compared 3 techniques using interfragmentary screws, transarticular K-wire fixation, and ORIF with compression screws. They concluded that screw fixation, although technically more difficult to perform, allowed earlier return of function. Although K-wire fixation is easier to perform, it demands longer periods of immobilization and the pin tracts must be managed to avoid infection. In the ORIF group, some patients had pulp pain related to the screw lengths. Long-term functional outcome was the same in all 3 techniques.

Mallet Thumb

Tabbal et al in 2009⁴⁷ reviewed the unique characteristics of mallet thumbs, which are anatomically based but will influence treatment. Because the extensor pollicis longus (EPL) lacks lateral bands, unlike the extensor digitorum communis in the palmar digits, if the insertion into the distal phalanx is interrupted by either laceration or closed avulsion, the tendon would retract more than other digits. In their report, the tendon had retracted 1.4 cm and had enfolded on itself. This has not been reported in mallet fingers involving palmar digits.

The mechanism of closed injury is the same as other digits with acute hyperflexion force against an extended thumb, but Miura et al⁴⁸ reported that 80% of these injuries are open and only 20% are closed. Clinically, patients are unable to extend the interphalangeal joint from a flexed position but these are distinguished from other, more proximal EPL ruptures by the presence of pain and swelling over the dorsum of the interphalangeal joint.

In 1983, Din and Meggit⁴⁹ advocated for operative treatment of closed injuries, stating that there were no reports to date of successful closed treatment. Retraction of the EPL precluded splint treatment and the terminal extensor of the thumb was stout and lent itself to suture placement. Verdan in 1975⁵⁰ was the first to advocate closed treatment for these injuries, stating that these injuries were no different from other digits. This assertion was backed up in numerous subsequent studies.

Currently, there is wide agreement that primary repair and 6 weeks of splinting are appropriate in open injuries but closed injuries should be splinted for 6 to 8 weeks. There are no studies to date comparing open to closed treatment of closed injuries. Tabbai et al⁴⁷ recommend magnetic resonance imaging (MRI) evaluation of closed mallet thumbs to assess the degree of retraction. Although 1-mm of retraction has been used as benchmark for open repair, there are no data to support it. There is, of course, the option of attempting a closed treatment first and then operating if treatment fails.

Chronic Mallet Fingers

In 2011, Makhlof and Al Deek⁵¹ reviewed the treatment of chronic mallet fingers in 11 papers. It is generally assumed that

mallet fingers are considered “chronic” when significant deformity ($<20^\circ$) exists after 12 to 16 weeks of closed treatment. Seven methods of treatment have been reported in the literature:

- Excision of scar and tenorrhaphy
- Reattachment of the tendon back to bone
- Imbrication of the healed tendon (Figure 3-30)
- Tenodesis (Figure 3-31)
- Fowler central slip tenotomy (Figure 3-32)
- Spiral oblique retinacular ligament reconstruction (SORL)
- Arthrodesis graft

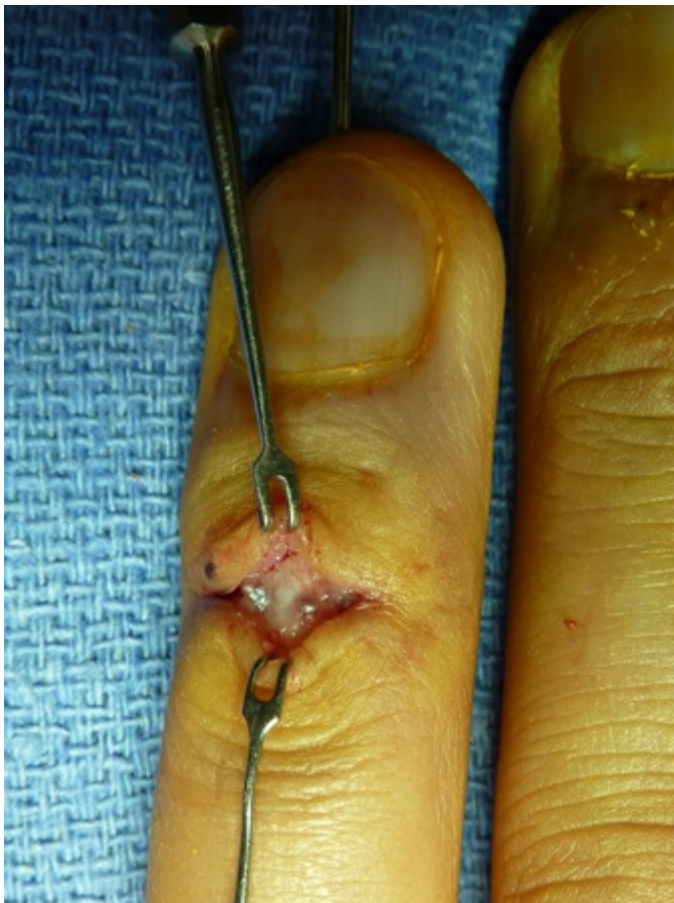

Figure 3-30 Imbrication of the terminal extensor using 4-0 Fiberwire suture. The repair is usually augmented by a transarticular K-wire.

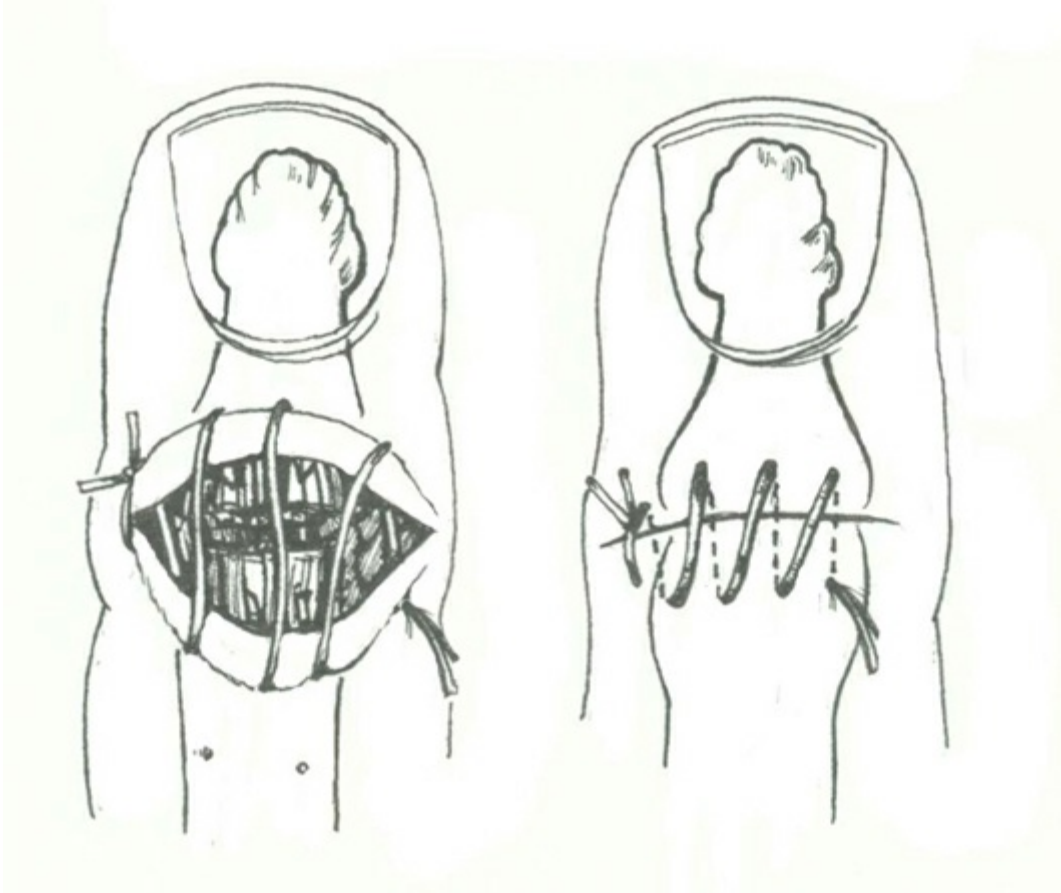
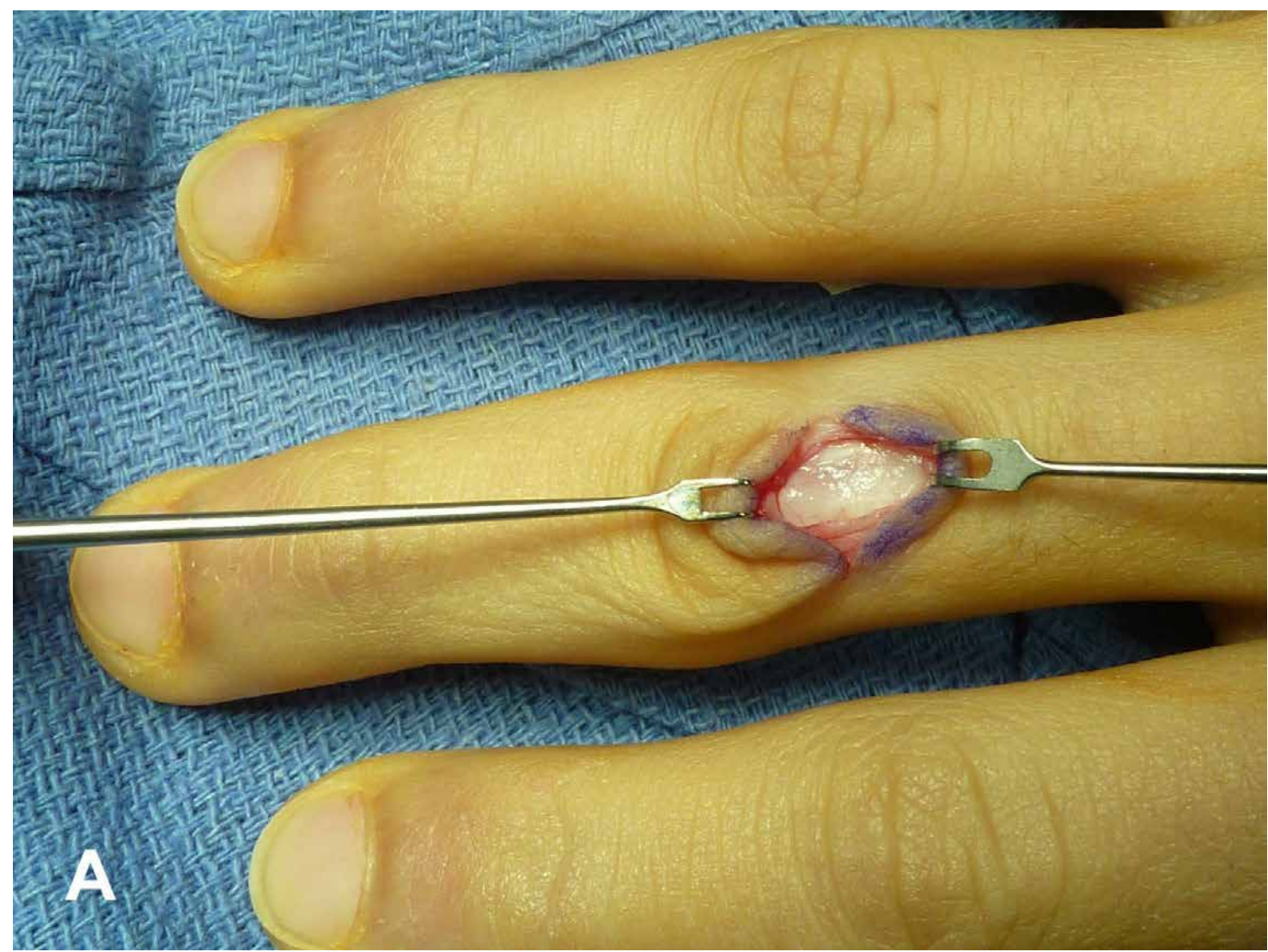
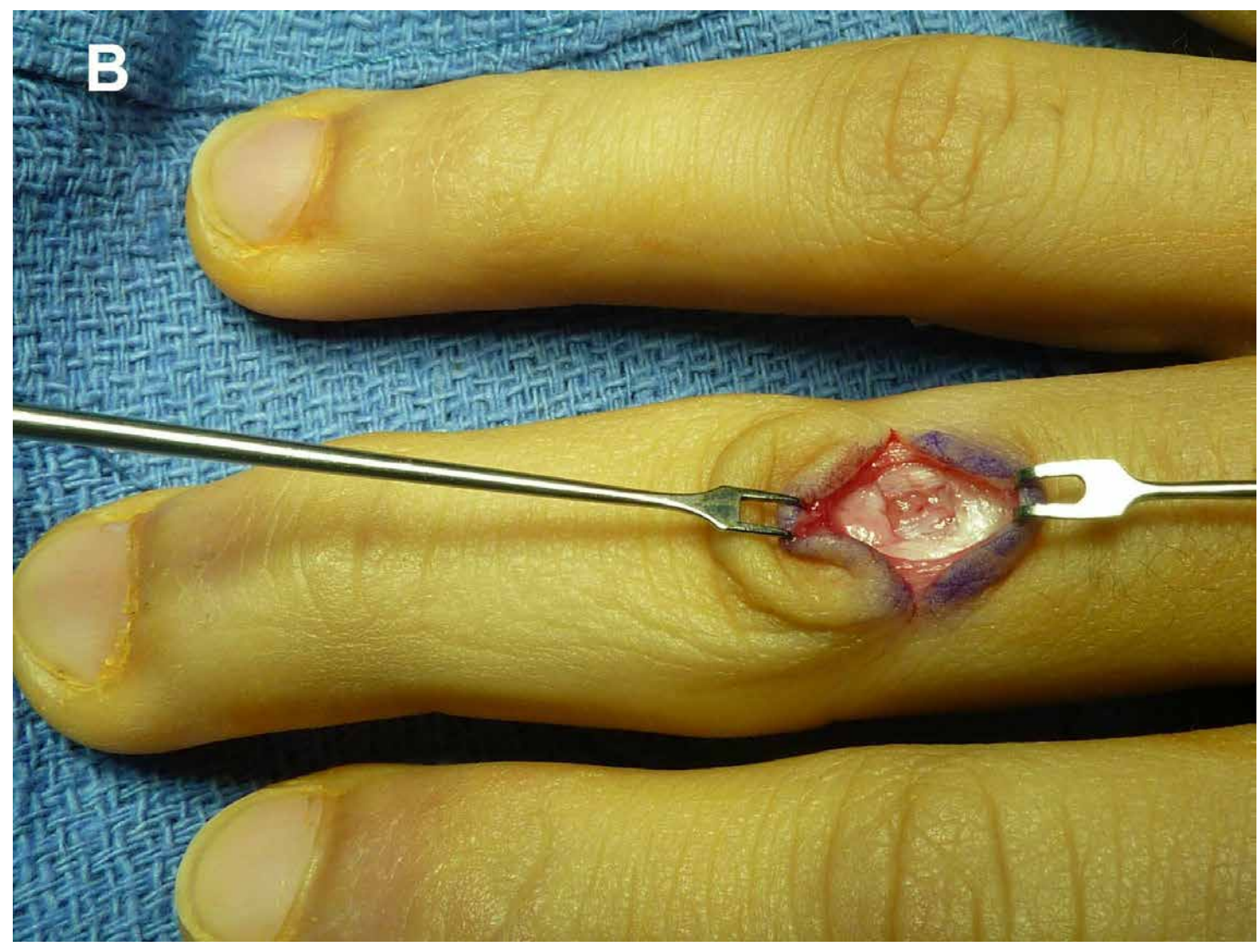


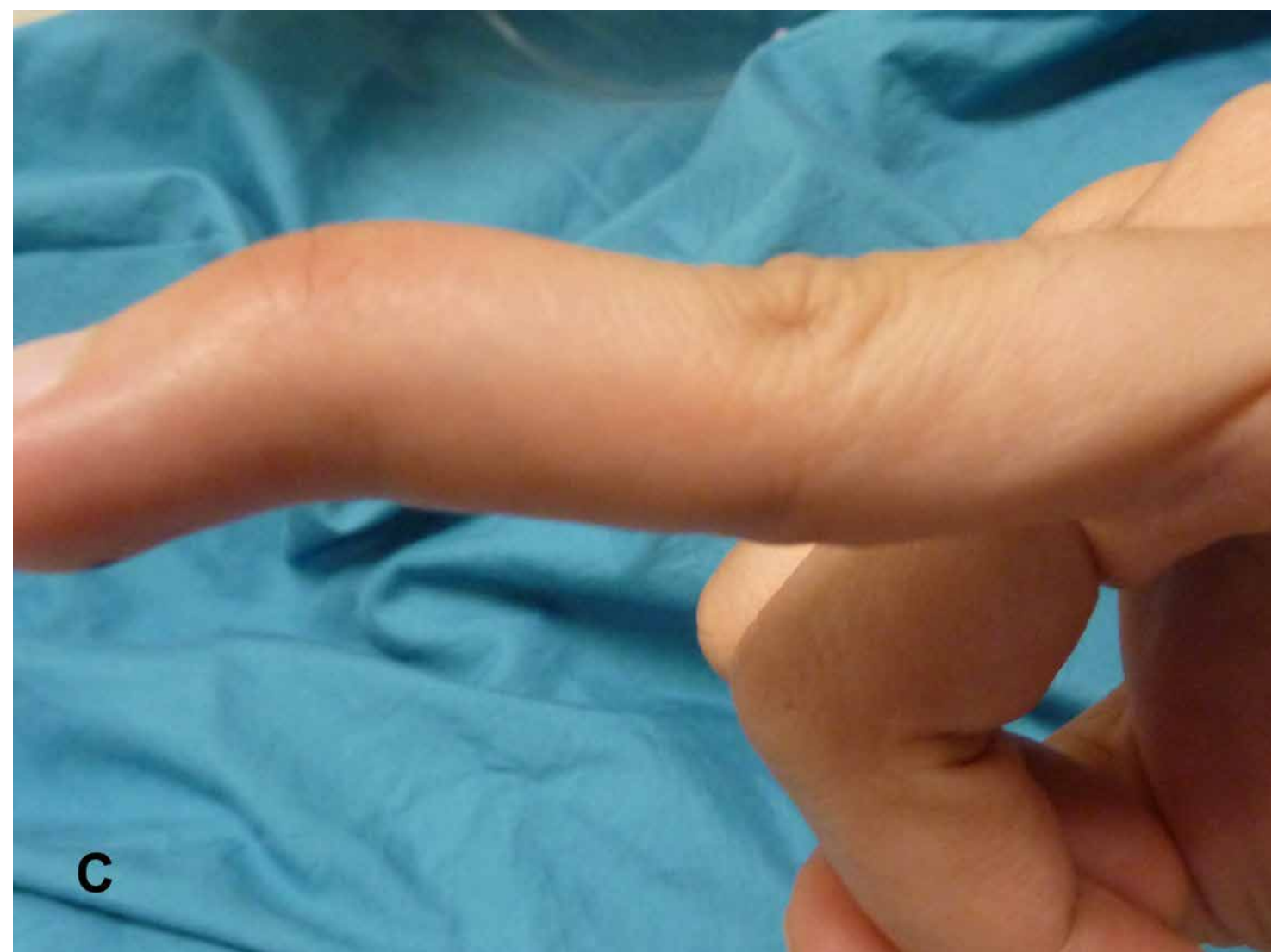
Figure 3-31 Tenodesis. The skin and tendon are sown together until the DIP joint extends. Long term, this repair has stretched out in many reports.



A

B





D

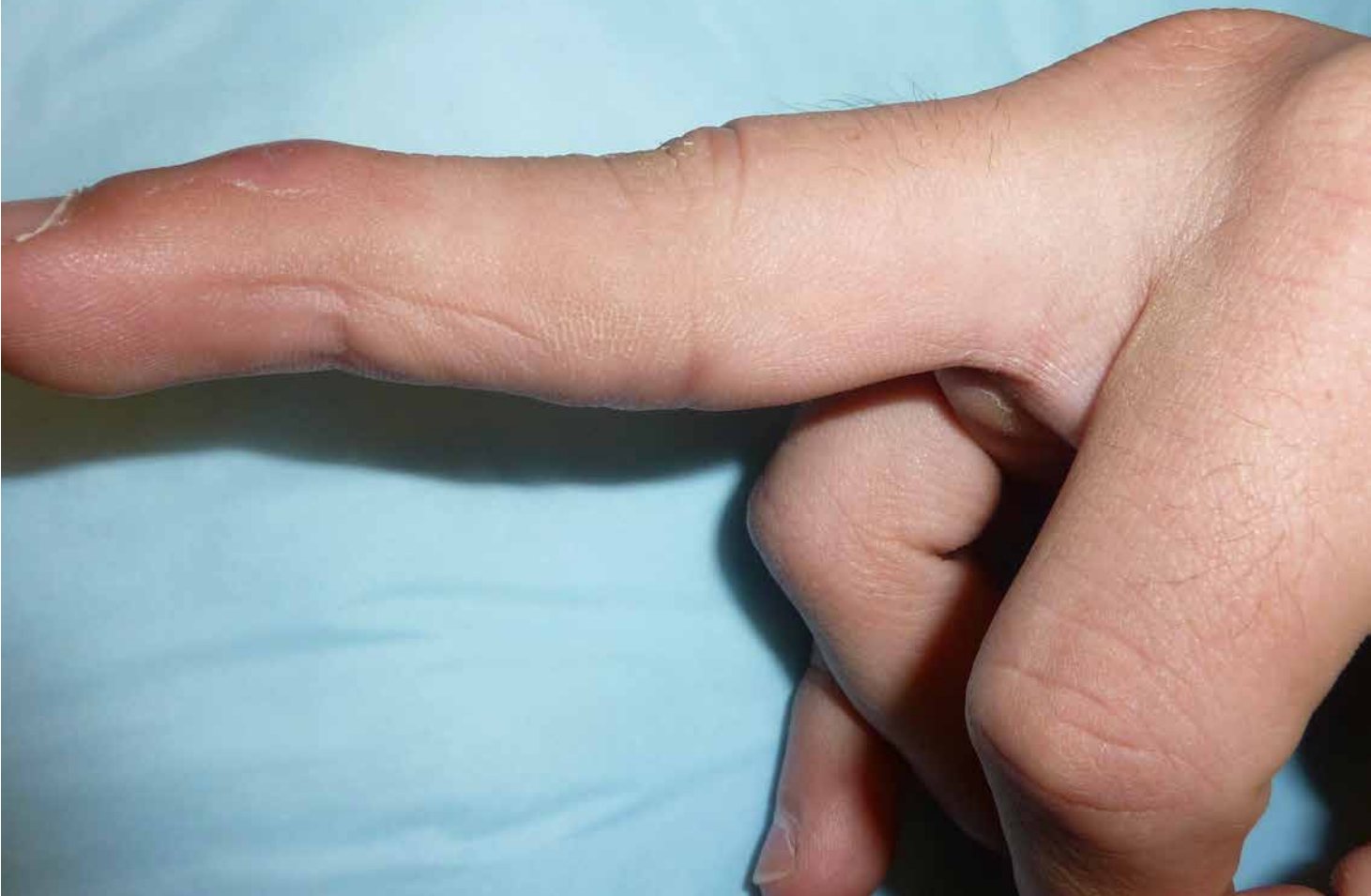
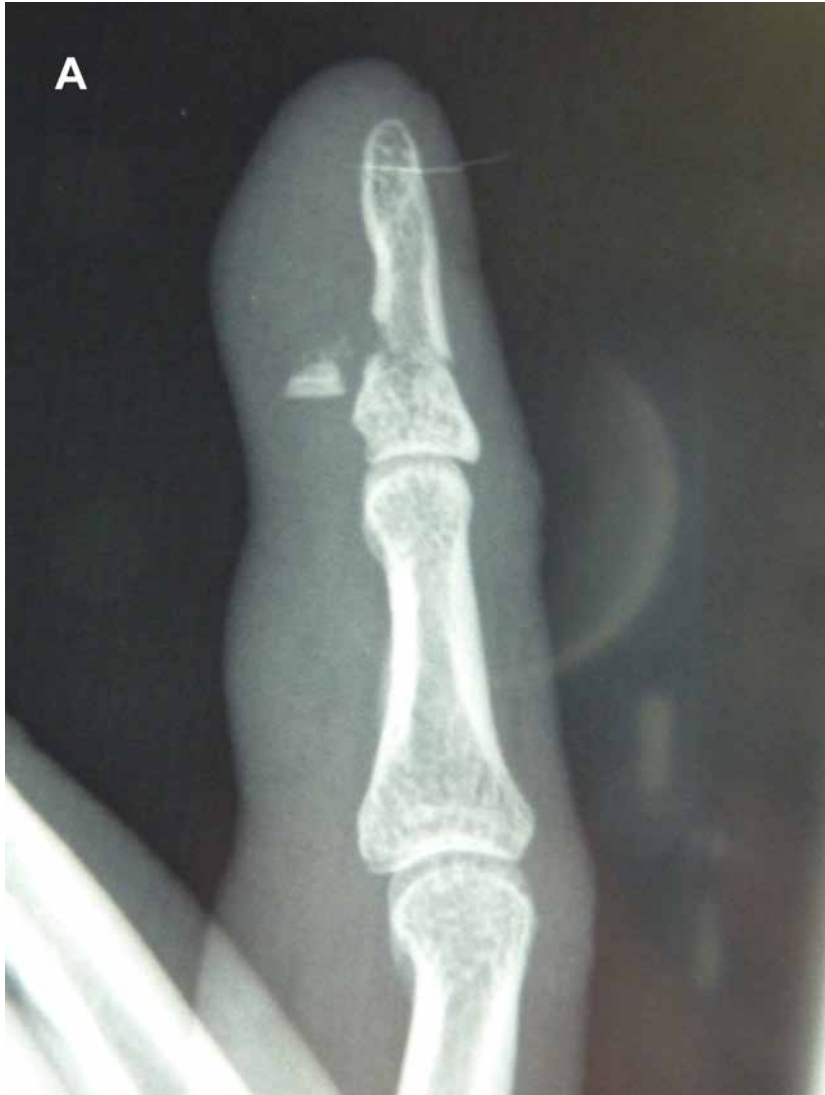
Figure 3-32 A and B, Fowler central slip tenotomy, before and after. Before sectioning, the central slip clearly delineates the lateral bands. Failure to do so can result in a PIP extension lag. Generally, these should ideally be performed in less than 35° extension lag. The author combines the central slip tenotomy with an imbrication of the terminal extensor insertion. **C**, Chronic mallet finger with a DIP extensor lag of 30° and a PIP hyperextension of 15°. **D**, At 12 weeks after central slip tenotomy and terminal extensor digitorum communis imbrication, the DIP has a 10° extensor lag and the PIP has a 5° hyperextension. In the author's experience, this improves with time.

A



B

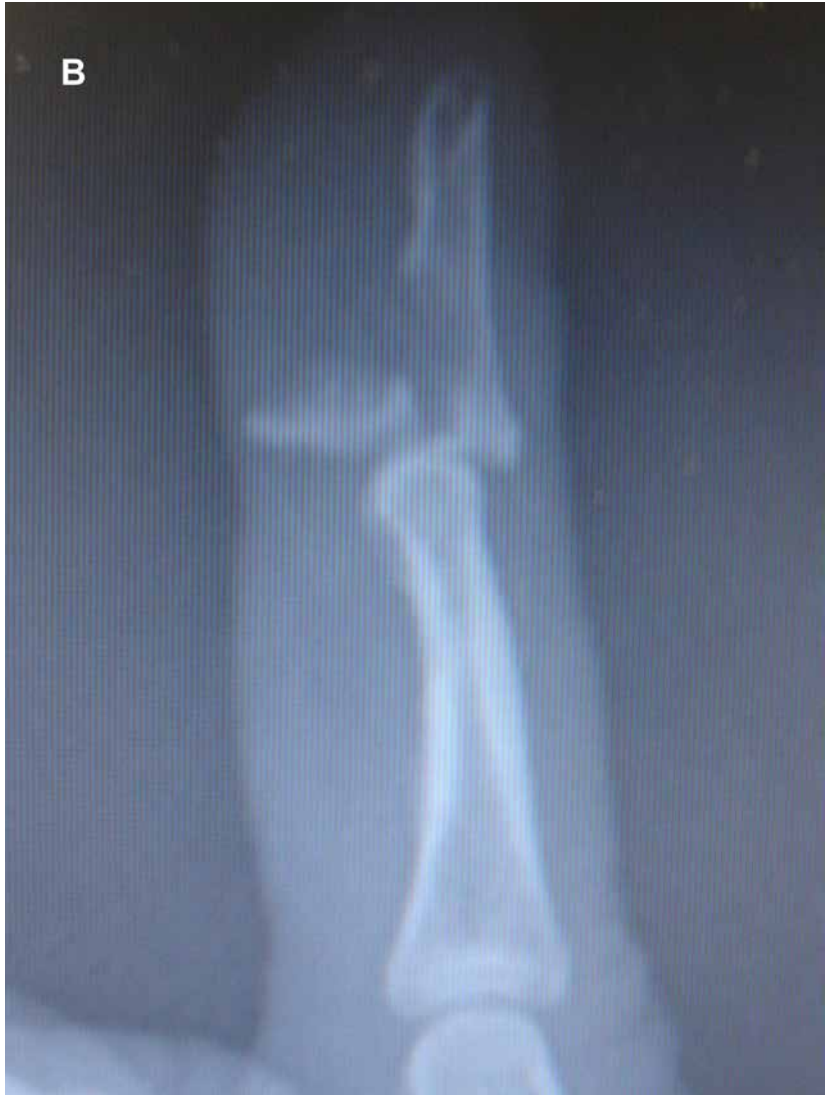

Figure 3-33 A and B, When the flexor digitorum profundus (FDP) avulses of the volar surface of the distal phalanx, bony avulsions may be flecks or involve more than 50% of the joint surface. Note the transverse metaphyseal fracture in **A**.

Makhlouf and Al Deek⁵¹ tabulated the results and showed that:

1. Fowler's release should not be attempted if the extensor lag is greater than 35°⁵²
2. Tenodesis. Excising the scar between the tendon and the bone as well as an ellipse of the dorsal skin and repairing both together with pin stabilization of the DIP joint can have a 50% to 90% excellent result.

Lind and Hansen⁵³ reported on excision of scar and tenorrhaphy. They had 40% excellent and 20% good results with less than 8° lag.

Ulkur et al in 2005⁵⁴ presented their results on 22 patients who had a direct reattachment of the tendon to bone. They had 15/22 excellent results with full range of motion, 5/22 good with less than 10° lag and 2/22 fair results.

Kleinman and Petersen in 1984⁵⁵ reported that, of 12 patients having undergone an SORL, all regained full DIP joint extension. One required tenolysis, and 1 needed graft lengthening.

Thus, it is clear that mallet finger injuries can be far more complex to care for correctly than they appear. The author's preference for the reconstruction of a chronic mallet finger is to perform a central slip tenotomy first and see how much correction is evident under anesthesia. If the correction is minimal, then imbrication of the distal phalanx extension is performed with K-wire fixation of the DIP joint in full extension for 4 weeks, followed by full active range of motion. One must be very careful not to remove too much of the central slip or an extensor lag of the middle phalanx can result (see [Figure 3-32](#)).

Pilon Fractures of the Distal Phalanx (see [Figure 3-6](#))

Dorsal fracture dislocations of the DIP joint can result in impaction of the volar base of the distal phalanx on the head of the middle phalanx, resulting in significant comminution at the base. The goal is to establish enough congruent surface to allow a functional range of motion of the DIP joint and to prevent dorsal subluxation of the distal phalanx.

Usually, closed reduction is unsuccessful and extension block pinning is helpful. ORIF is technically very difficult because the fragments are too small.

Volar plate arthroplasty has been described but is made nearly impossible because of the extended FDP insertion along the volar cortex. Primary arthrodesis of the DIP joint can be considered and afford the patient just 1 operation to salvage an otherwise irreparable injury.

Volar Lip Fractures of the Distal Phalanx and Flexor Digitorum Profundus Avulsions

FDP terminal avulsions are common injuries that are caused by forced hyperextension of the DIP joint while the finger is actively flexing. When the eccentric extension load on the FDP exceeds the mechanical strength of its terminal insertion, either the flexor tendon avulses off the bone or it will pull off the volar tip of the distal phalanx. The size of the fragment can vary between a fleck of bone to more than 50% of the joint surface. There may also be an associated metaphyseal fracture of the distal phalanx (Figure 3-33).

The common term for this injury is the *jersey finger* because of the classic mechanism of injury seen in football players. When a player forcefully grabs the jersey of an opponent to check his forward progress, the finger will be wrenched into hyperextension as the opponent advances. The player may hear or feel a sudden “pop,” usually in the ring finger. The initial pain and swelling in the finger preclude motion so it may take several weeks for the athlete to realize that he is unable to actively flex the DIP joint. There may be difficulty in flexing the PIP joint as well (Figure 3-34). Waiting too long to surgically treat an FDP avulsion may make it impossible to repair the tendon primarily and necessitate a flexor tendon reconstruction. This may depend on duration from time of injury (<6 wk) or degree of proximal displacement.

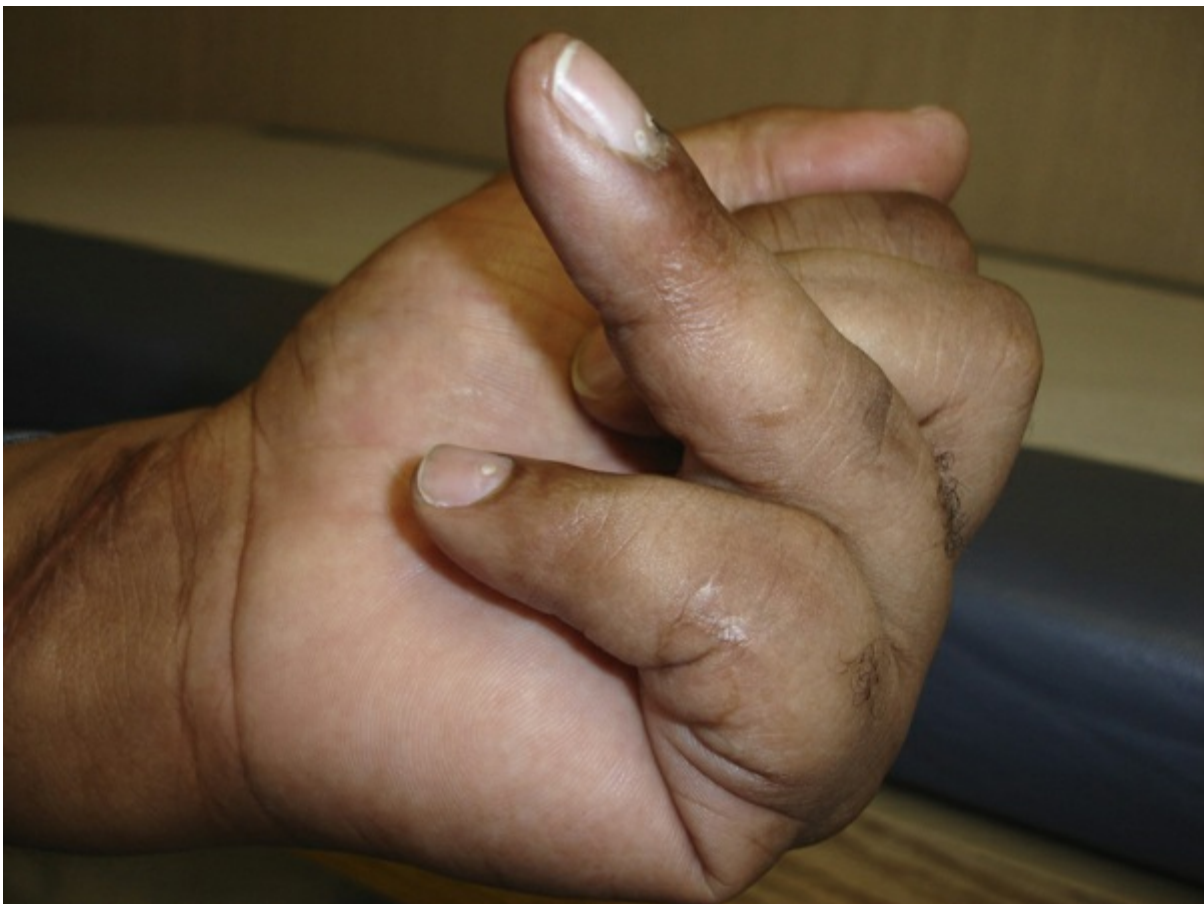

Figure 3-34 Inability to flex the DIP joint from a closed FDP rupture.

Pertinent Anatomy of Flexor Digitorum Profundus Tendon Rupture

The anatomy of the flexor tendon and the mechanism of injury will determine what type of injury will occur. It is curious that the ring finger is the most common digit that will sustain an FDP rupture. Several theories have been proposed⁵⁶:

- The ring finger FDP tendon is anatomically most tethered to the other FDP tendons so that hyperextension of that digit will be least accommodated on the flexor side.
- The insertion of the ring FDP is inherently weaker than the other FDP insertions.
- The lumbrical muscle to the ring FDP is bipennate, further tethering the tendon.

In full grip, the ring finger juts out 5 mm farther than the other digits, making it more vulnerable to injury (longer lever arm).

The extent of retraction of the tendon after rupture is the basis of the classification system of these injuries. Whereas the presence and size of an accompanying bony avulsion is an important determinant of retraction, the vincular anatomy of the FDP is critical to this repair process. The FDP possesses a vinculum breve (VB) just proximal to the DIP joint and a vinculum longum (VL) at the level of the PIP joint. When the FDP avulses off its insertion, there will be no retraction with an intact VB. The VB will rupture before the VL and, if the VL is intact, the tendon will not retract beyond the PIP joint. If both vincula are ruptured (and there is little or no attached bone fragment at the tip of the tendon), the tendon will retract into the distal palm. Further retraction will occur if finally the lumbrical ruptures. It is estimated that one half of FDP ruptures are bony avulsions.

Leversedge et al⁵⁷ described a vascular “watershed” region near the insertion point of the FDP. At the insertion, Interosseous vessels arise from the distal phalanx that feed the terminal tendon at its volar aspect. Two millimeters proximal to that, another leash of vessels emanating from the distal phalanx supplies the dorsum of the tendon. Between that complex of vessels and the blood supply coming from the VB is an area of hypovascularity measuring about 3.5 mm, which is particularly vulnerable to rupture with eccentric traction.

Classification of Injury

Leddy and Packer⁵⁸ devised a classification system of FDP avulsion based on the extent of FDP retraction and the presence and size of a bone fragment at the end of the tendon. This system has more recently been modified to reflect whether the FDP is still attached to the avulsed bone and whether there was the presence of a separate distal phalanx fracture.

- **Type 1:** Full FDP retraction into the palm. Both vincula are torn and there is no bony avulsion.
- **Type 2:** FDP retracts to the PIP joint. The VB is torn and the VL is intact. Small volar avulsion is attached to the tendon ([Figure 3-35](#)).
- **Type 3:** FDP retracts to the distal end of the A4 pulley (see [Figure 3-33](#)). The VB and VL are intact. Large bony avulsion catches on the end of the pulley, preventing further retraction.
- **Type 4:** Large volar fragment trapped at the A4 pulley but the FDP detaches from the bone and retracts into the palm. The VB and VL are both torn.

- **Type 5:** Volar fragment in the presence of either an intra-articular or an extra-articular fracture of the distal phalanx (see [Figure 3-33](#)). Tendon retraction is variable, depending on the size of the bony fragment and VB and VL continuity.

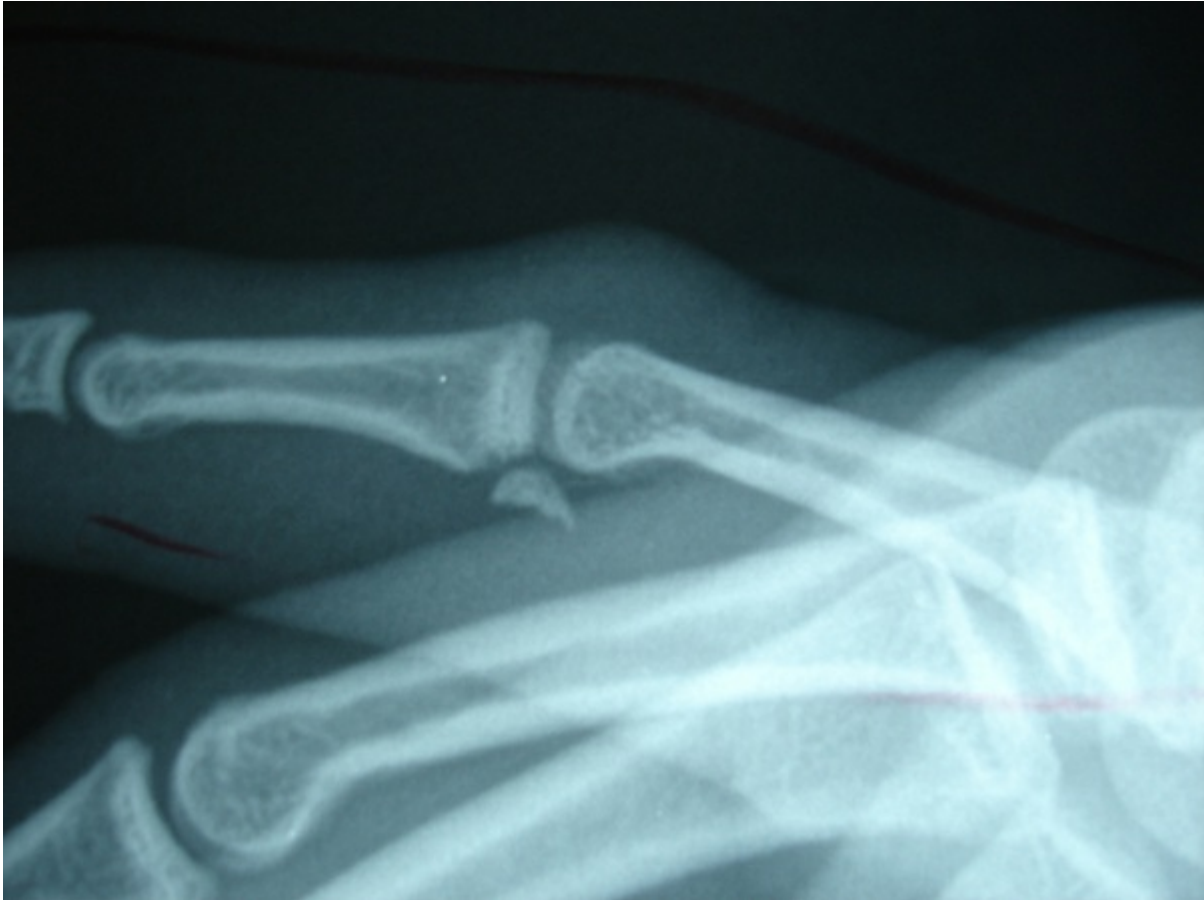

Figure 3-35 FDP retraction to the PIP joint carrying with it a bony avulsion.

Diagnosis

The primary presentation is inability to actively flex the DIP joint (see [Figure 3-34](#)). At rest, the DIP joint assumes a more extended posture than the other digits, thus disrupting the “cascade effect” of the digits whereby the ulnar digits sit in more PIP and DIP flexion than the radial ones.

The clinical examination becomes more unclear if the patient is unwilling or unable to flex the digit because of pain. However, asking the patient to actively flex the adjacent DIP joints with no resultant DIP flexion of the injured finger is diagnostic. However, when there is minimal retraction of the tendon, that is, Type 3, the DIP joint may appear to flex actively.

Local palpation along the course of the tendon is important because the point of maximal tenderness may be a clue to the location of the retracted tendon end, which may be palpable. An x-ray of the finger will identify the location of a bony avulsion but, as noted, may not determine the extent of avulsed tendon retraction. Whereas ultrasound has been recommended as a noninvasive method of determining retraction, MRI (sagittal section) ([Figure 3-36](#)) is helpful in making the diagnosis and delineating the level of retraction. Locating the source of the retraction obviates the need to make a large exploratory incision.

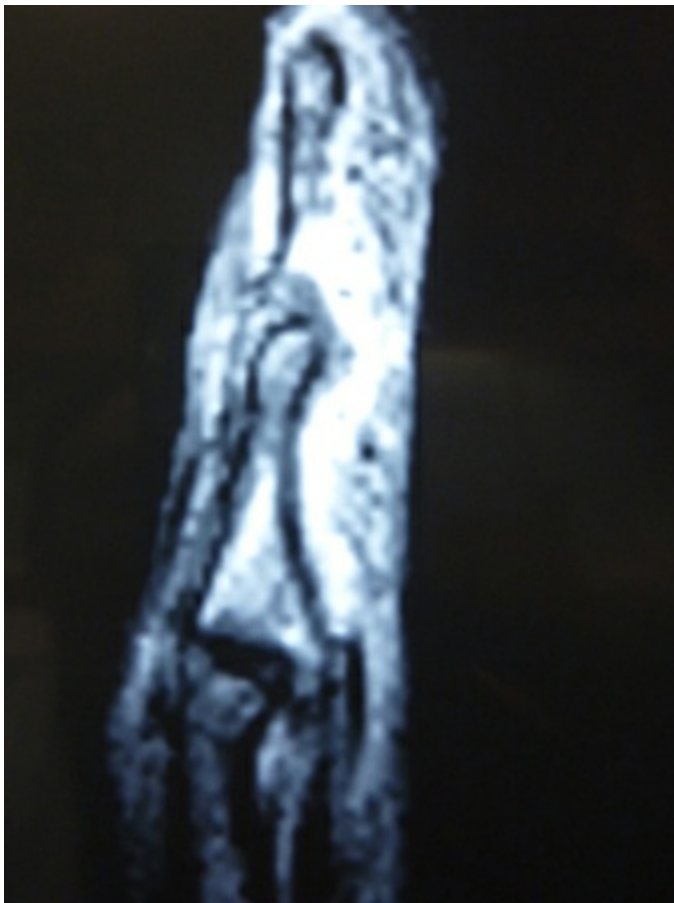


Figure 3-36 Sagittal MRI shows retraction of a closed FDP rupture to the proximal phalanx level.

Surgical Management

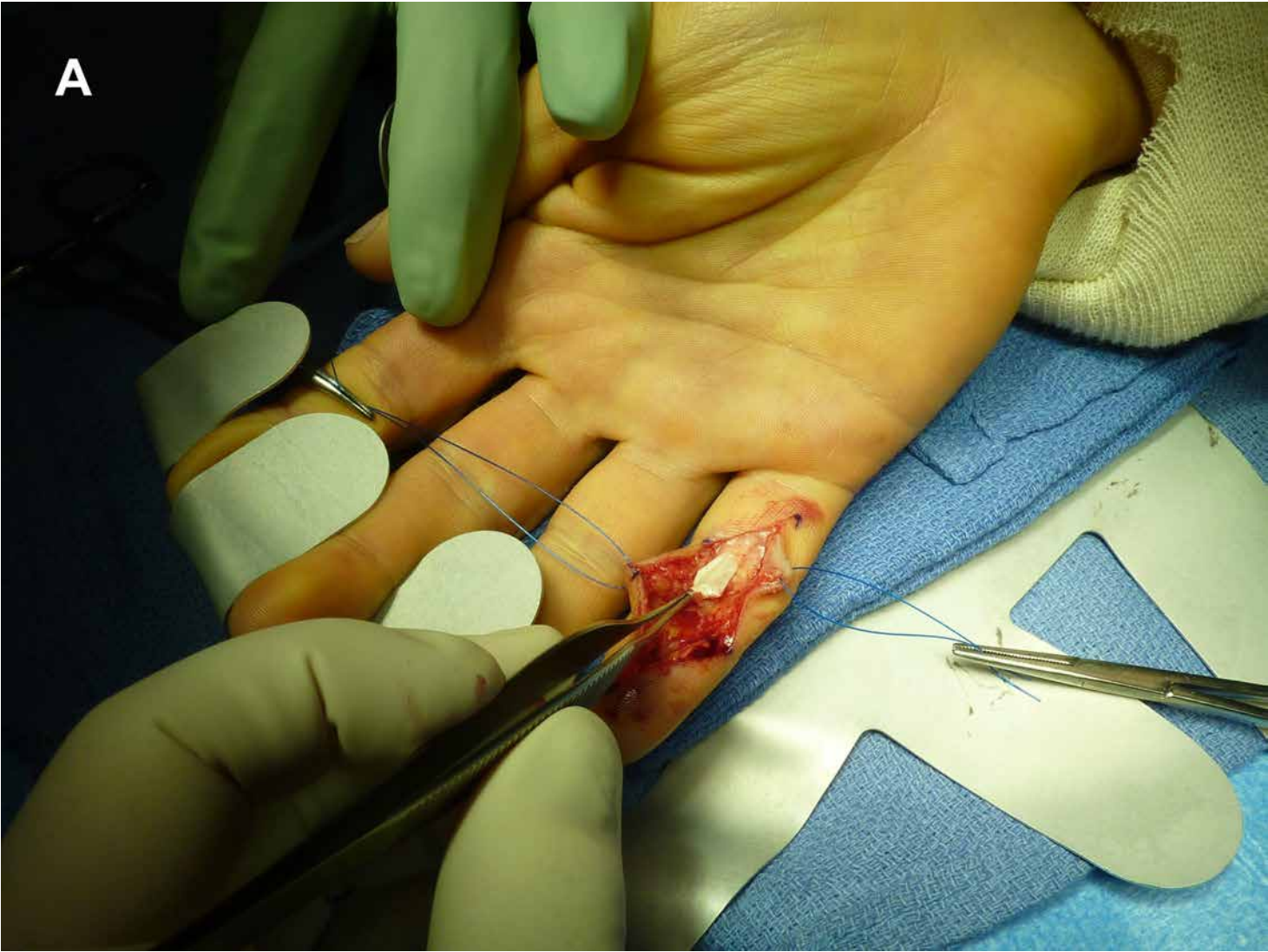Despite the relatively straightforward diagnostic signs of an FDP rupture, decrease in pain, ability to flex the PIP joint, and desire to complete an athletic season often lead to delayed treatment. Management decisions hinge on the time interval from injury to

treatment, the extent of tendon retraction, and the presence of a bone fragment.

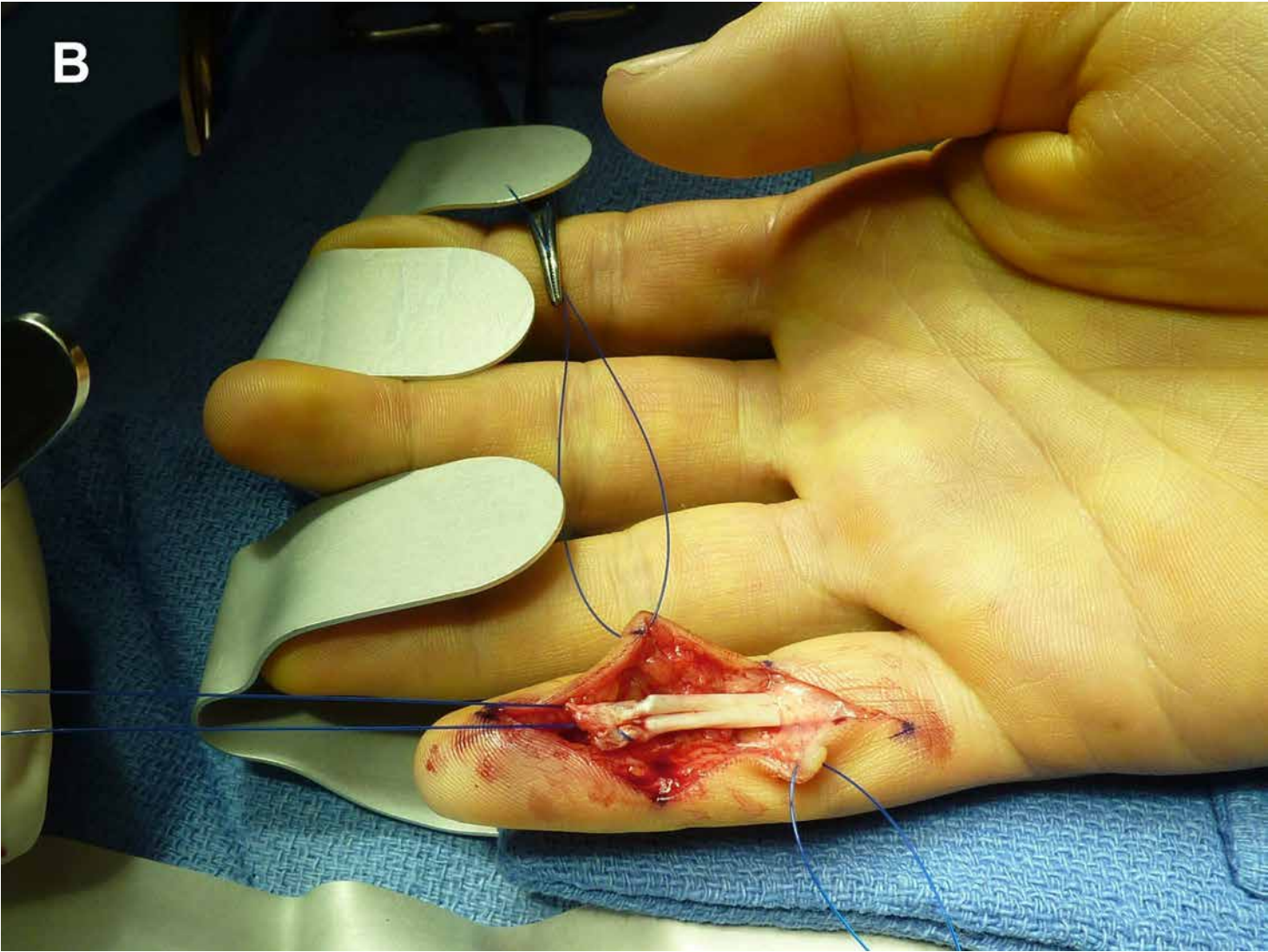
Acute injuries are best treated within 2 weeks, but primary direct repair should be considered, if possible, up to 8 weeks after injury. A variety of techniques have been described. The goal of treatment is secure fixation of the tendon to bone (or bone to bone) so that early postoperative active and passive mobilization can commence.

For pure tendon injuries, the FDP can be secured to the distal phalanx by passing locking sutures (2-0 monofilament/4-strand repair, Bunnell or Kessler) through the tendon end and passing the suture through the distal phalanx, sterile matrix, and nail plate distal to the lunula, then tying them over a dorsal button. When the tendon end is retracted into the palm, it may be difficult to pass the tendon through the intact pulley system or Camper's chiasm. Frequently, these structures need to be dilated to allow the tendon to pass through. (The use of a 7-French "pearl" pediatric feeding tube can aid in passing the tendon.) The FDP can either be passed through the Chiasm or passed around it, then passed distally under the A4 pulley and attached to the volar base of the distal phalanx, where it is attached to the distal phalanx via suture passed through the distal phalanx and tied over a button on the nail plate (Figure 3-37). Great care must also be exercised to avoid over-tensioning the repair because this can lead to the quadriga effect limiting DIP motion in the adjacent digits. The distal tendon remnant may also be sutured to the repair using a 3.0 or 4.0 FiberWire. Biomechanical studies by Silva et al⁵⁹ showed that the repair strength exceeded the loads created by early gentle active range of motion exercises. The suture and button are removed at 6 weeks. Complications include nail bed injury, skin necrosis under the button, suture rupture at the button, infection, late tendon rupture, and contracture.

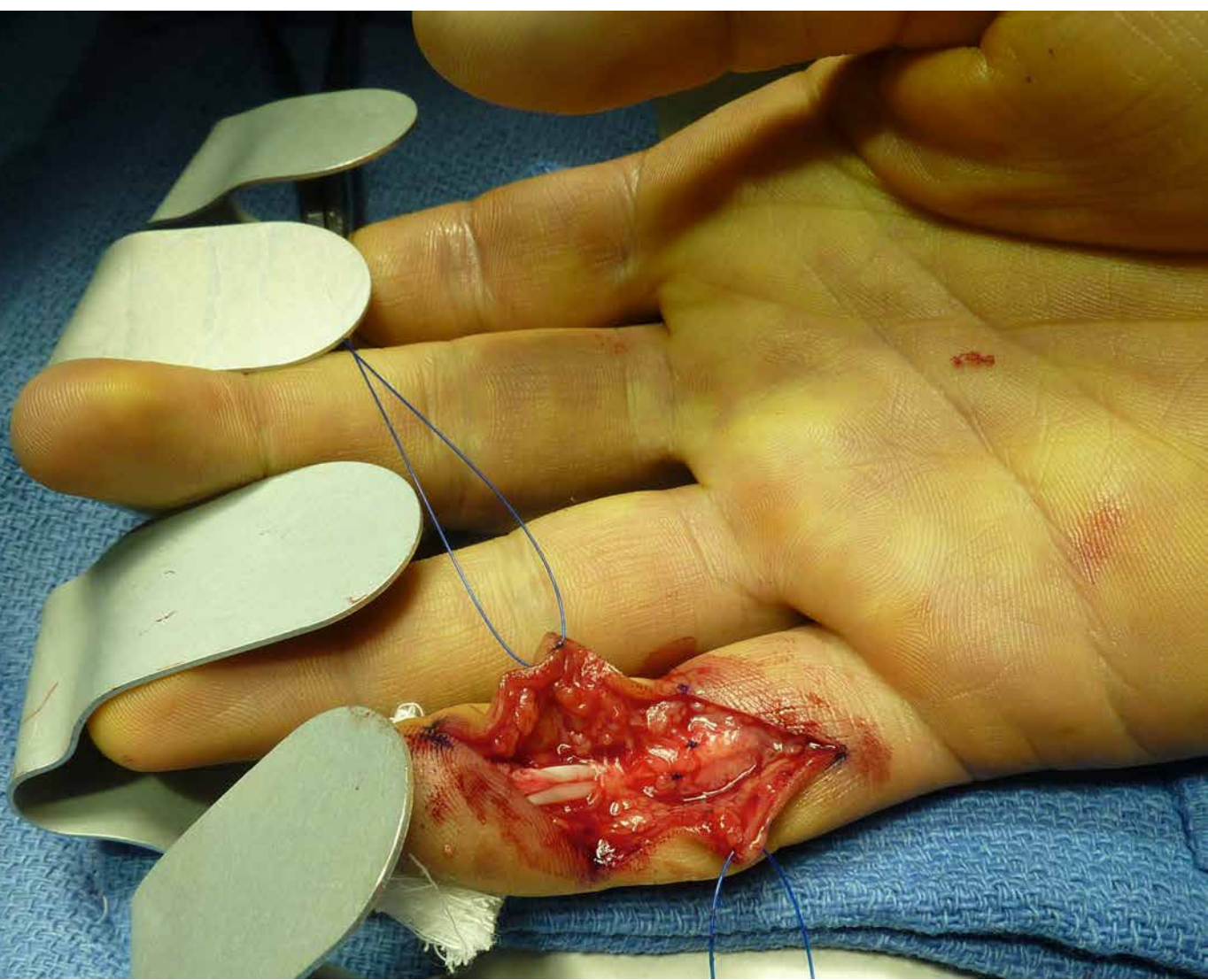A

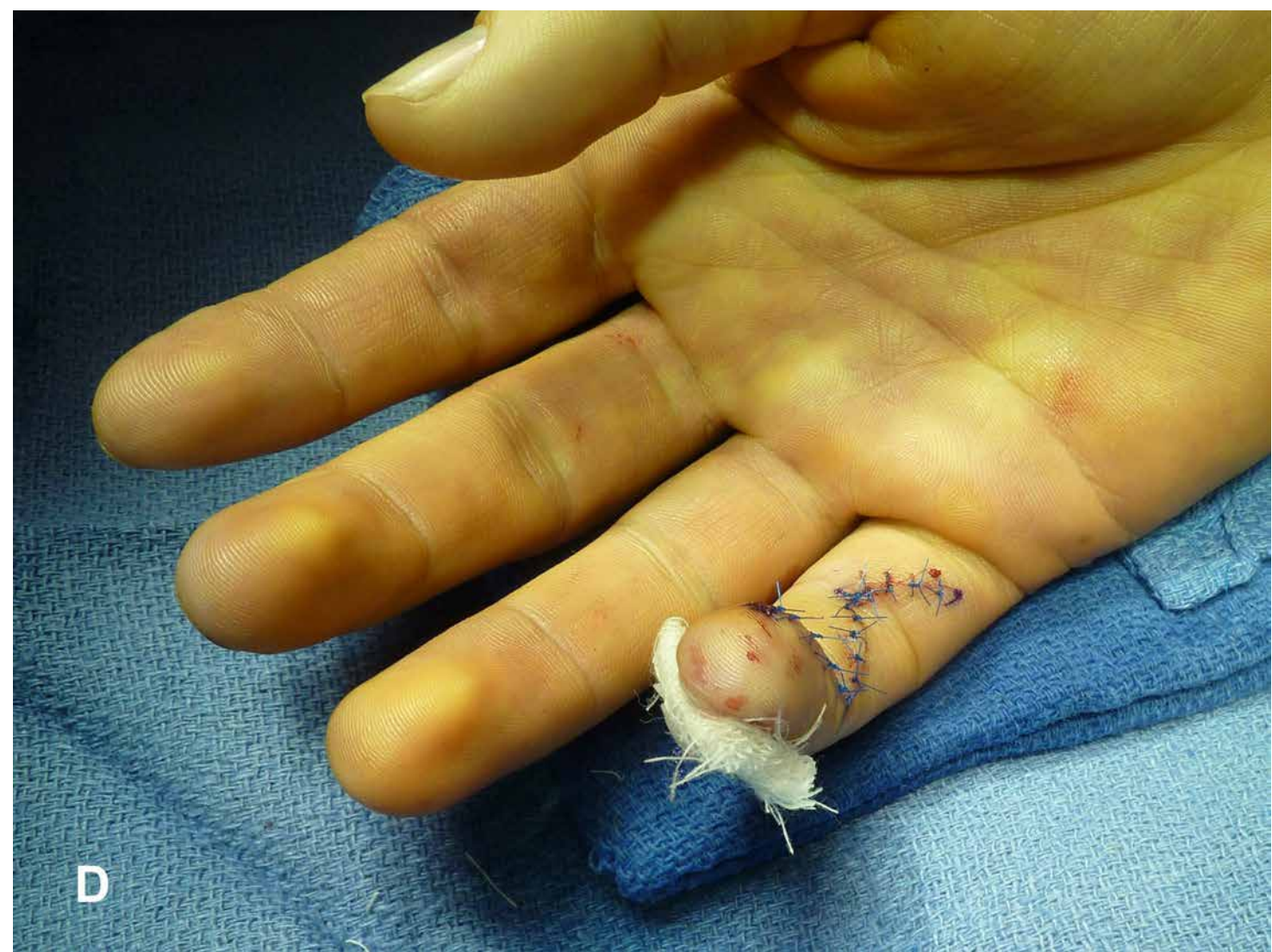


B



C





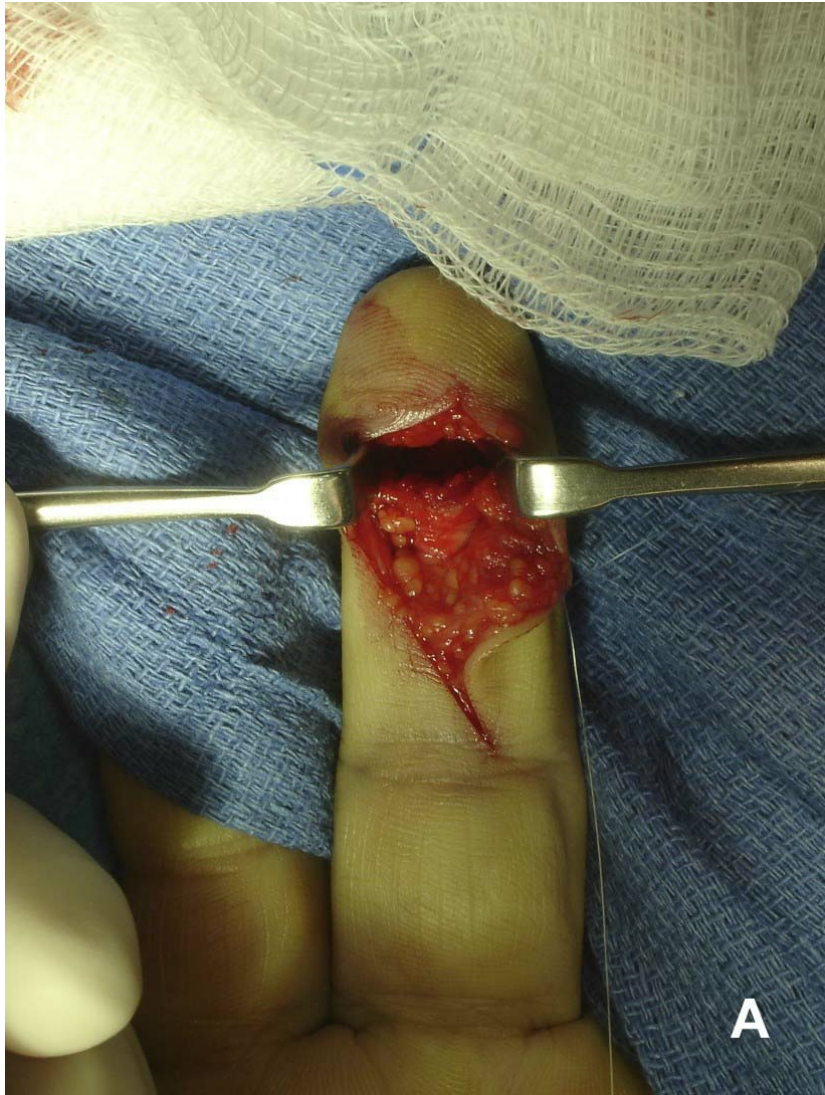D

Figure 3-37 **A**, Closed profundus rupture retracted to the proximal phalanx level. **B**, FDP advanced to its insertion checked for tension of the repair. **C**, Graft inset and tied over a dorsal button. **D**, Repair complete, normal cascade effect re-established

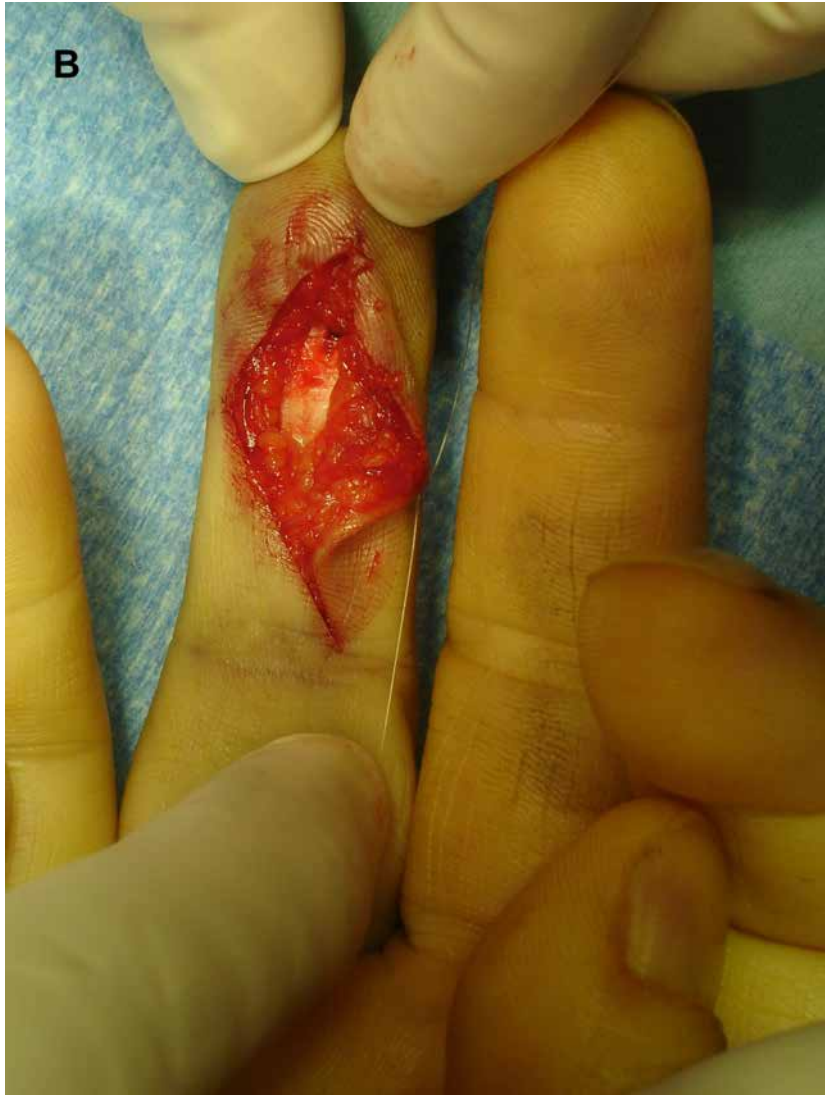Suture anchors have also been used successfully to avoid problems with the nail bed. Two pilot holes are drilled into the distal phalanx at 45° directed proximally. This increases the pull-out strength and diminishes the probability of gap formation between the tendon and the bone of the construct. Depending on the size of the distal phalanx, two minisuture or microsuture anchors are used, each with 2 strands. The biomechanical strength of the construct also exceeds the requirements for passive range of motion exercise. Failure has occurred when the anchors came out of the bone, that is, in osteoporotic bone, or the suture tore at the attachment site to the anchor. In fact, Latandresse et al⁶⁰ demonstrated that this technique is inadequate to allow early active range of motion.

However, McCallister et al,⁶¹ in comparing suture anchors and the pull-out button technique, found identical functional outcomes in both groups with regard to range of motion and grip strength. Recently, Ruchelsman et al⁵⁶ have begun to recommend combined use of pull-out wires and bone anchors, resulting in a 4-strand repair. This has been reported to provide greater pull-out strength than anchors alone, especially in osteopenic bone, with less gap formation than with pull-out sutures alone.

When there are bony avulsions, internal fixation techniques using interfragmentary minifragment screws, K-wires, and interosseous wires may be employed (Figure 3-38). Where the fragment is large enough, a minifragment plate may also be used.



B



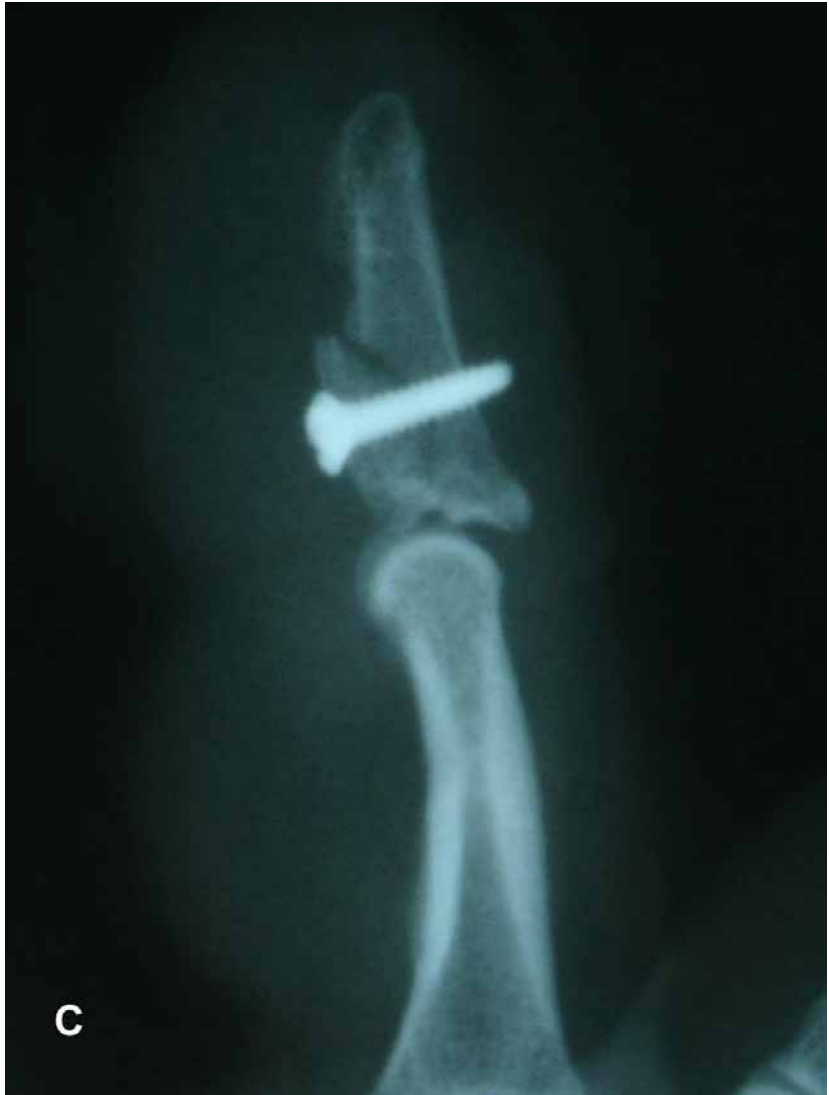

Figure 3-38 The Leddy Type 3 fracture/FDP avulsion depicted on x-ray in Figure 2-33B. **A**, The tendon/bone end is just proximal to the retractors and the dark space above is the recipient bed. **B**, The tendon is reattached (**B**) and secured (**C**) with a cortical screw.

If patients present more than many weeks after injury, management decisions are much less straightforward. In those cases in which bony avulsions are large enough that there has been little or no retraction and intact vincular blood supply to the tendon exists, excellent results can be anticipated even with delays of 6 to 8 weeks. However, when retraction has occurred, other considerations must come into play.

After many weeks, it may be impossible to advance the retracted tendon from the palm to the fingertip. Fibrosis of the FDP muscle and collapse and scarring of the pulley system combined with tendon degeneration and weakening are the main obstacles. Following acute rupture, hematoma develops in the flexor sheath, contributing to fibrosis. If primary advancement is not possible owing to contracture but the pulleys are intact, then a primary tendon graft may be used. If the pulley system has collapsed, then the options to consider are a 2-stage tendon reconstruction using Silastic rods, FDP tenodesis, or a DIP joint arthrodesis.

Rehabilitation

Initially, a dorsal blocking splint is worn with the wrist in gentle flexion, metacarpophalangeal (MCP) joints at 90° flexion and the PIPs in extension. At 7 to 10 days, passive range of motion exercises and active finger motion with wrist tenodesis can be started. At 4 weeks, place-and-hold and joint blocking exercises with the PIP and DIP joints in flexion are begun. This will help to isolate motion at a given joint by stabilizing adjacent joints. Resistive grip is started at 10 to 12 weeks.

Outcomes

Several studies have reported long-term loss of extension of 10° to 15° at the DIP joint, and others have had no loss of motion at all.⁶¹ Factors include type of repair, interval from injury to treatment, type of injury, and quality of the rehabilitation regimen. To date, there has been no Level 1 or Level 2 evidence to recommend a course of treatment.

Open Fractures of the Distal Phalanx—Digital Tip Amputations

Soft tissue and bony loss at the tip of the finger are among the most common injuries seen in a busy emergency room setting. Although initially appearing somewhat trivial, they may present serious consequences to the patient socially, economically (because of extended periods of lost work time), and psychologically. Patients may have great difficulty adapting to the loss of a fingertip and, in some cases, the tip that remains may be chronically dysesthetic and painful.

The goals of fingertip reconstruction must include:

1. Maximizing sensibility as normally as possible
2. Minimizing fingertip pain and sensitivity; avoiding painful neuromas

3. Creating a durable skin cover that can withstand normal use
4. Preventing finger stiffness (DIP and PIP joint contractures)
5. Maximizing the functional length of the finger
6. Optimizing the cosmetic result
7. Allowing early return to work
8. Obtaining a result that is in keeping with the patient's functional needs
9. Obtaining a result that corresponds to the patient's cultural and religious beliefs
10. Minimizing financial costs as best as possible
11. Minimizing nail deformity

The choice of treatment will depend on several factors:

1. The linear level of injury, that is, how much of the bony and soft tissues are left intact
2. Whether or not bone is exposed
3. Sharp versus crush amputation
4. The cleanliness of the wound
5. The obliquity of the amputation
6. The age of the patient
7. The extent of nail apparatus injury
8. Smoking and/or chronic circulatory disease history
9. The size and geometry of the wound

Martin and González del Pino⁶² have classified these injuries by the level of amputation:

- **Zone 1:** Amputation beyond the level of the distal tuft of the distal phalanx generally not affecting the nail bed.
- **Zone 2:** Amputation through the sterile matrix.
- **Zone 3:** Amputation through the germinal matrix.
- **Zone 4:** Amputation proximal to the nail apparatus and distal to the insertion of the flexor and extensor tendons.

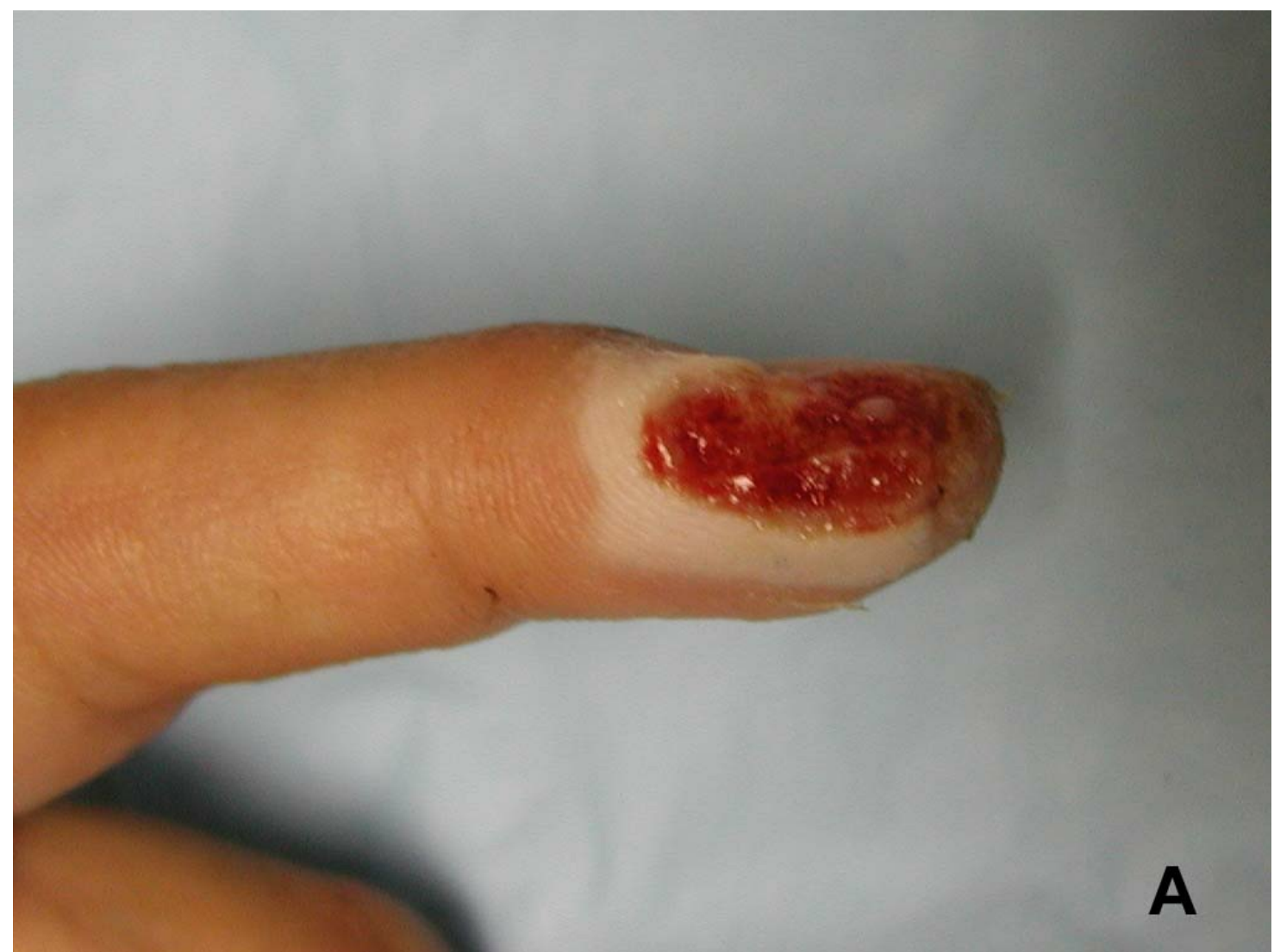This classification assumes that there is no crush or shredding/shear component to the amputation and that there is no obliquity.

The next section deals with local flaps and soft tissue management used to directly cover fingertip defects. Flaps such as fillet flaps, kite flaps, neurovascular island flaps, and rotation flaps are dealt with in the chapter on amputations.

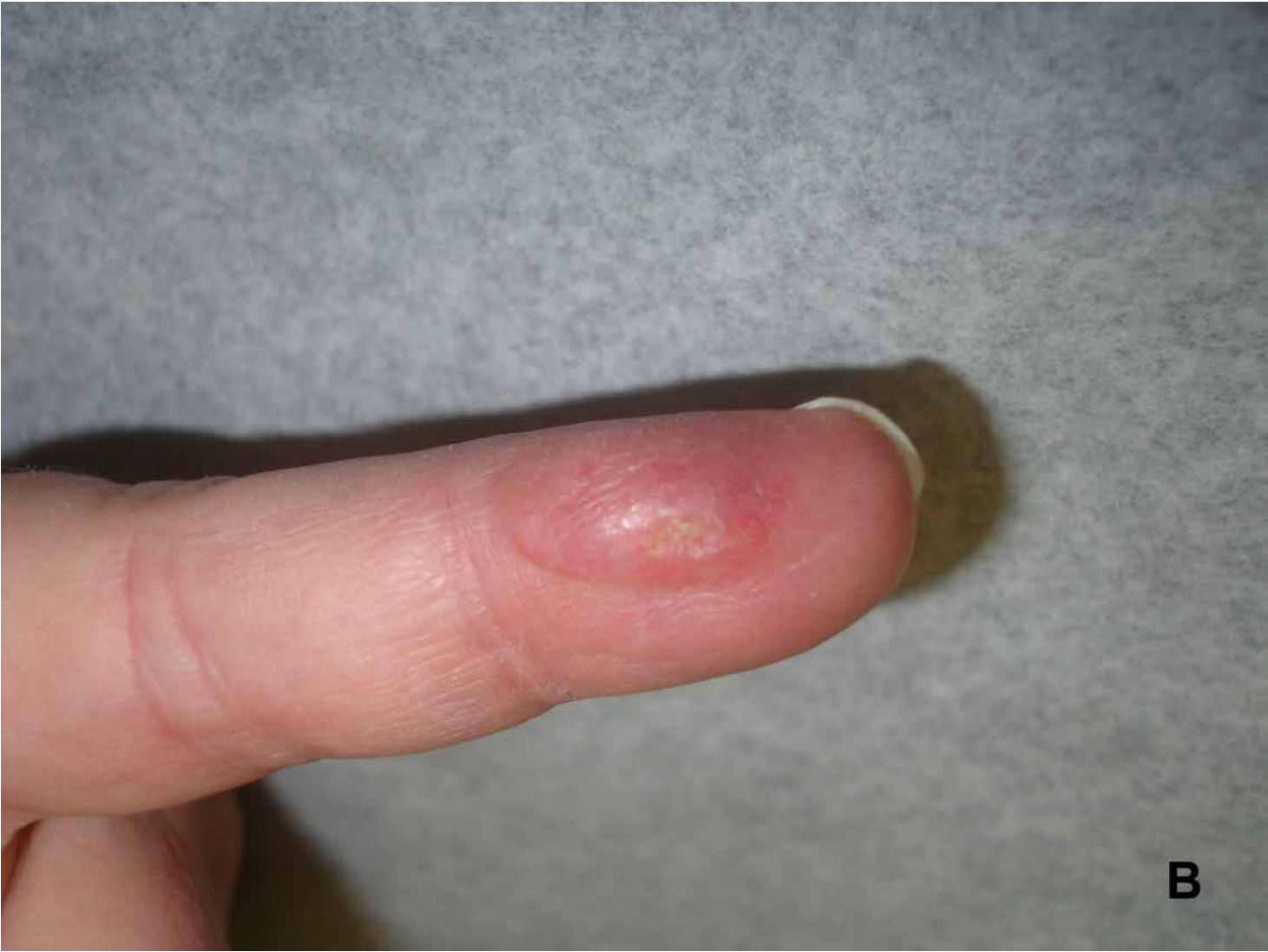Healing by Secondary Intention

In those patients whose distal fingertip amputation involves the volar or lateral pad or the tip of the finger beyond the hyponychium (Zone 1), nonoperative treatment may often yield the best result both cosmetically and functionally. It is imperative that there be no nail injury or exposed bone. The wound bed needs to be clean initially or well debrided.

As healing progresses, phagocytosis of the necrotic tissue at the end of the finger occurs, local blood vessels dilate, and an exudate forms over the wound comprised of fibrin clot and inflammatory cells.⁶³ Phagocytes clean away the necrotic tissue and fibroblasts lay down bridging scar tissue. Peripheral epithelial cells grow inward to cover the defect. The underlying scar contracts and the defect closes. New nerve endings subsequently grow into the subdermal layers and sense organs repopulate the newly covered area ([Figure 3-39](#)).



A



B

Figure 3-39 A, Oblique amputation of the fingertip involving only skin and subcutaneous tissue. An ideal candidate for healing by secondary intention. **B**, After 3 months, the tip has fully epithelialized.

Initially, wet-to-dry dressings are preferred over the first 10 to 14 days. The wound is then cleaned twice weekly and covered with a nonadherent gauze. The wound gradually becomes smaller by 10 days and is generally covered by new epithelium in 3 weeks. It is usually recommended that the defect be less than 1 cm in diameter, but larger defects generally achieve the same result with time. In situations in which there is a minimal amount of bone exposed, it may be rongeuired back below the soft tissue margin on either side, but this should be avoided distally to prevent “beaking” of the nail due to a lack of terminal support.

Mennen and Wiese in 1993⁶⁴ demonstrated 200 patients who had their fingertip injuries treated with secondary intention and had excellent return of cosmetic appearance and pain-free sensation in their fingertips with 2-point discrimination approaching 2.5 mm at 3 months. These results compare favorably with grafting and flap techniques. This technique is inexpensive, requires no surgical expertise, and has no donor site morbidity. It does, however, require meticulous wound care and encouragement from the surgeon. In those patients who work manually, return to work should be delayed until the wound is completely closed and matured.

Skin grafts

Skin grafts, full or partial thickness, have limited utility in the coverage of fingertip defects. Apart from donor deficit, skin grafts take several weeks to incorporate, require relative immobility because of the shear forces created by movement, and delay rehabilitation of the finger. Long-term studies show that fingertip defects treated in this way exhibit a higher incidence of diminished sensation, cold intolerance, and dysesthesia.⁶⁵ Full-thickness skin grafts are more durable than partial-thickness grafts. Split-thickness skin grafts commonly leave unsightly and painful donor sites.

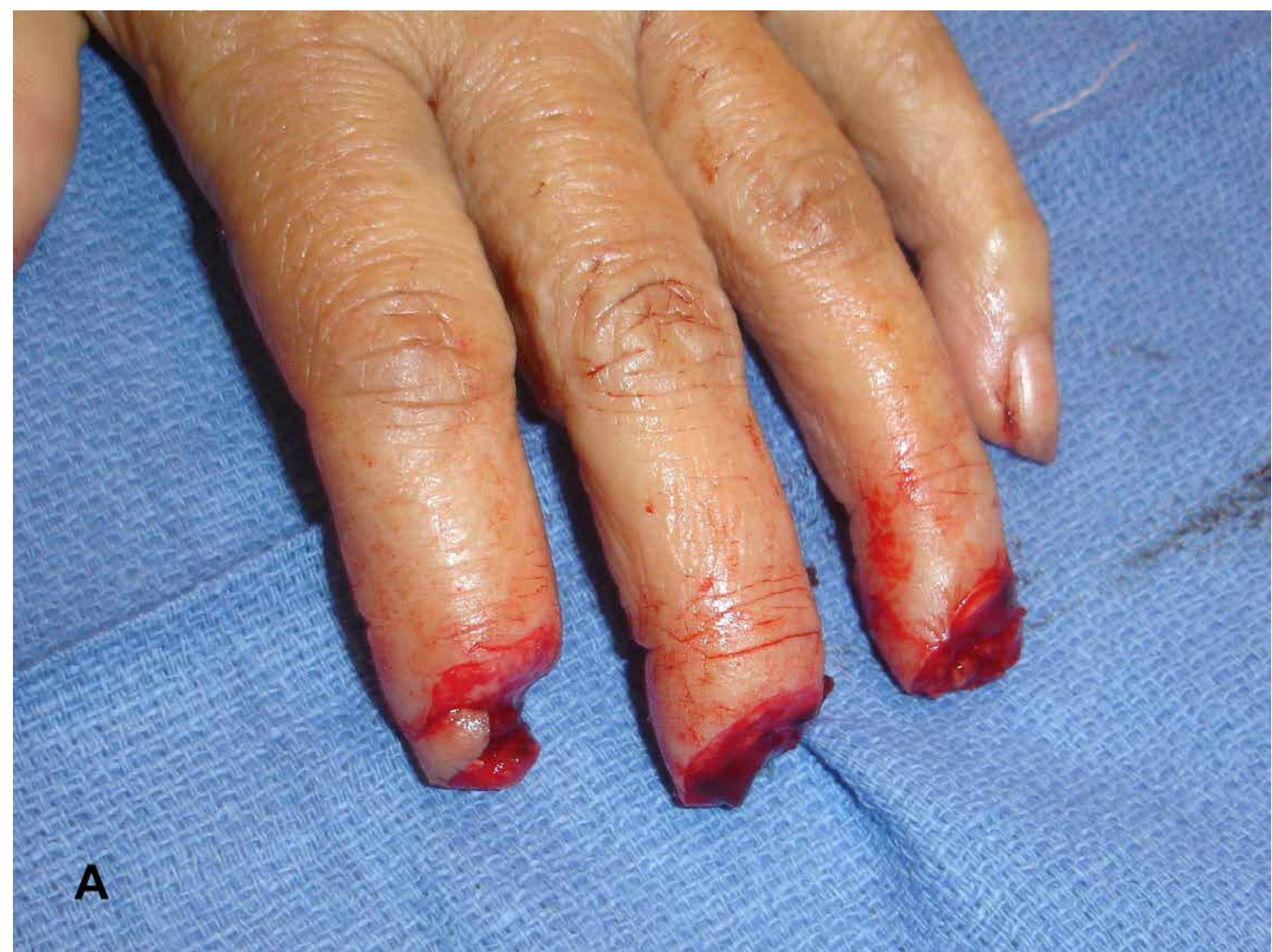In side-by-side trials, tips allowed to heal by secondary intention had a more durable cover and more normal sensation. Skin grafts, in general, have been linked to lack of durability, poor sensation, asymmetrical contraction, and donor site morbidity. Cosmetically, even if a good initial color match is made, the graft tends to darken over time, leaving an unsightly spot. Schenck and Cheema⁶⁶ reported a return of less than 6 mm of 2-point discrimination in about half the patients studied.

For patients who need rapid closure of their tip defect and have other mitigating factors such as an unstable medical condition or associated trauma, skin grafting may be an option when others are not practical. Recently, Integra bilaminar matrix has been used as skin coverage without requiring grafting. It enables re-epithelialization within 3 to 6 weeks.

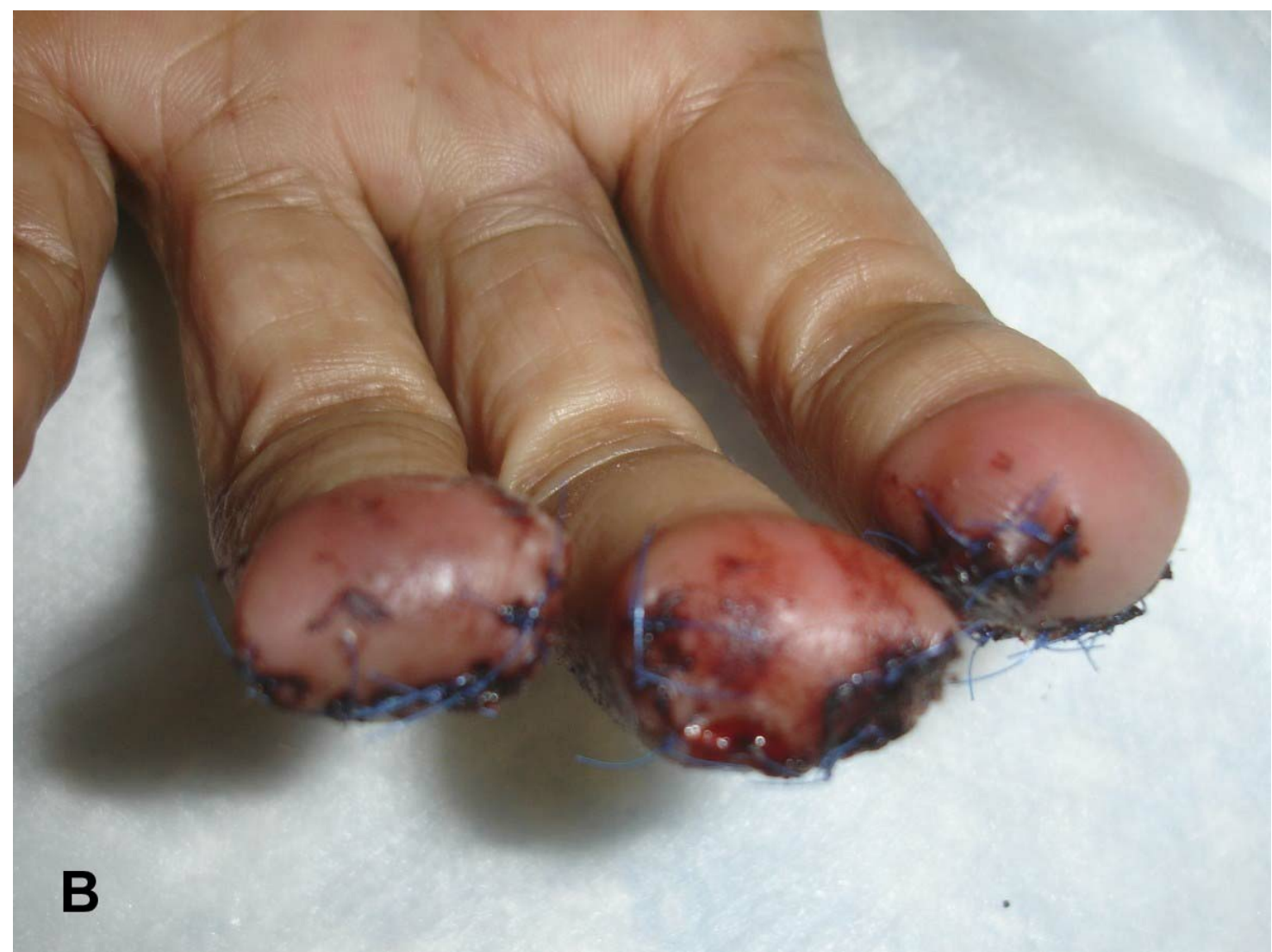Primary Closure

In cases in which the soft tissues on the dorsal and volar side of the finger are easily approximated at the end of the finger, they can be closed directly. This assumes that the bony level of amputation is proximal enough, or at least can be shortened to allow a tension-free repair. Preservation of phalangeal length is an important consideration, especially when the amputation level or the

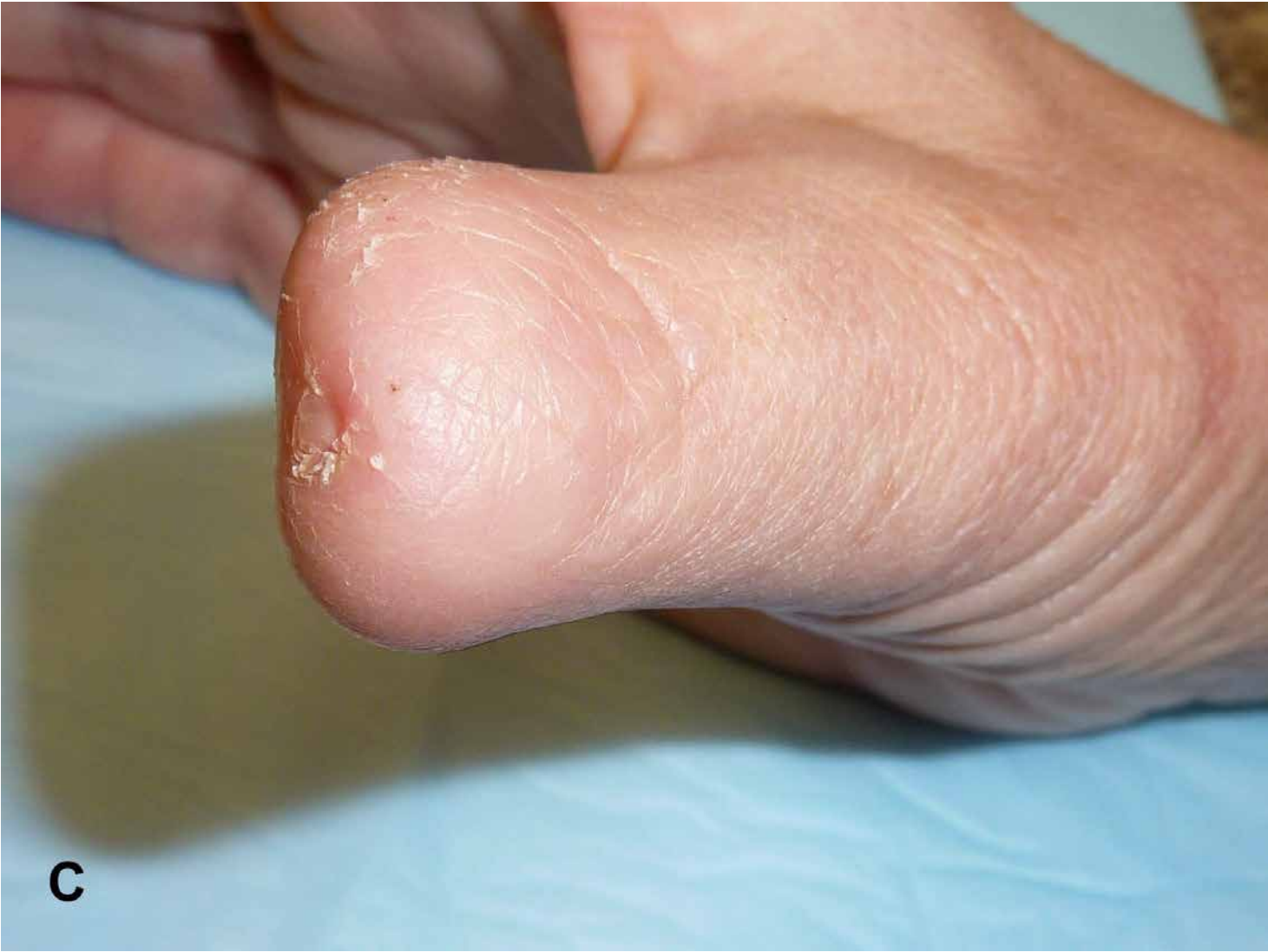perceived need to shorten the bone leaves very little phalanx beyond the DIP joint. Removing or disabling the DIP joint will diminish function. Preservation of DIP joint function requires complete nail removal and formation of dorsal and palmar skin flaps. The two flaps should be approximated with as much subcutaneous fat and connective tissue as possible to pad the end of the finger (Figure 3-40). Thin covering over the distal end of the bone will result in an unstable flap and dysesthetic fingertip. One must not try to “pad” the end of the finger by sewing the end of the flexor tendon to the terminal extensor because this may create a quadriga effect, limiting flexion of the other fingers. If the injury is a transverse amputation at the level of the nail bed, the nail bed should be trimmed back to the level of the bony amputation and not be used to cover the bone because that would inevitably lead to the development of a hook nail deformity (Figure 3-41).



A



B



C

Figure 3-40 A, Three-finger amputation at the germinal matrix area closed by primary closure. Salvage of the nail apparatus is impossible. It is important to remove all remnants of the nail apparatus. **B**, Closure must be tension free and usually involves bone shortening. The terminal ends of the digital nerve must either be recessed or turned back on itself and buried to prevent painful end neuromas. **C**, Long-term appearance of a thumb tip treated with primary closure.

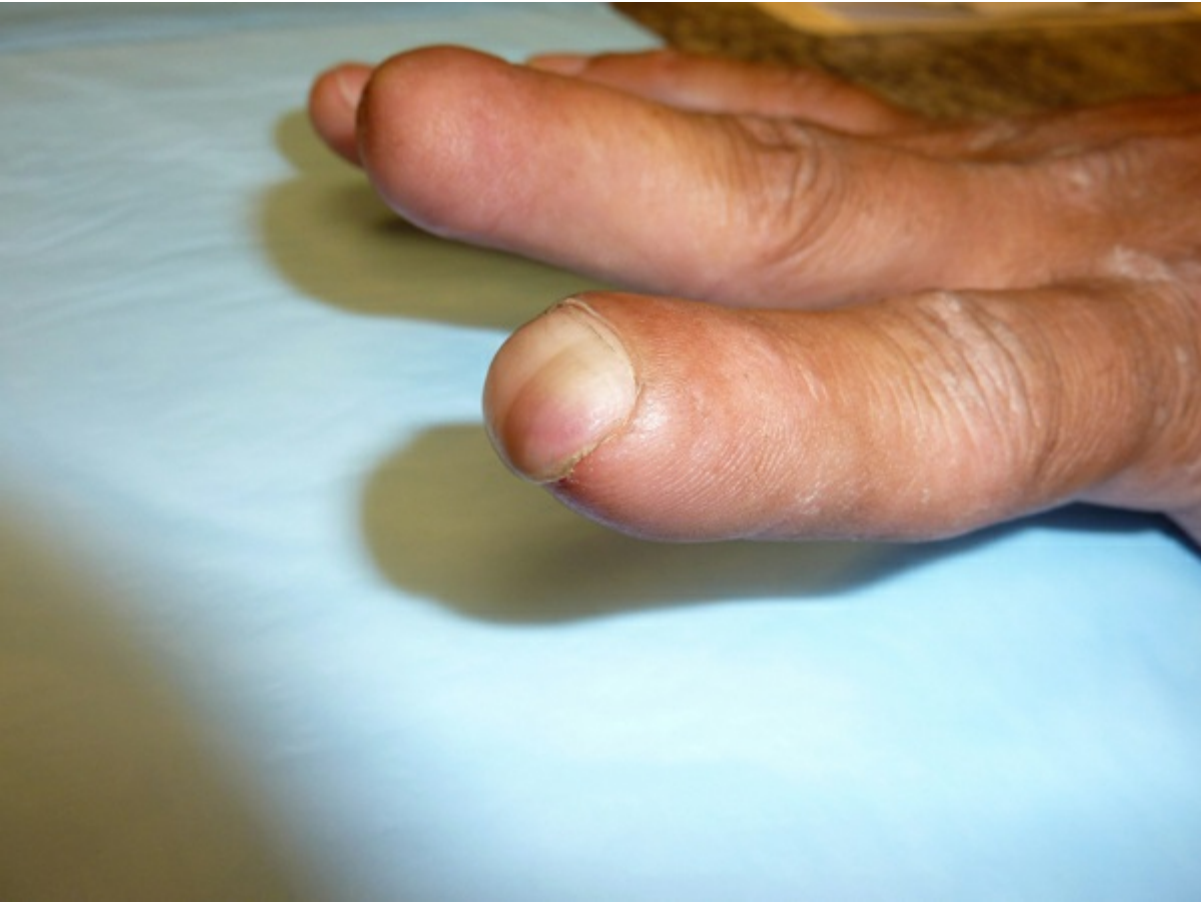

Figure 3-41 Hook nail deformity.

This approach is not practical when there is still a significant amount of nail apparatus left. If the level of amputation is at the lunula or proximal to it, it is better to completely remove the nail tissue to prevent the formation of painful and unsightly nail spikes (Figure 3-42). Prior to closure, one must dissect out the ends of the digital nerves and bury them back into the finger to prevent end neuroma. This procedure is relatively simple and will allow patients to return to work sooner (especially manual laborers) than the more complex regional or neurovascular island flaps.

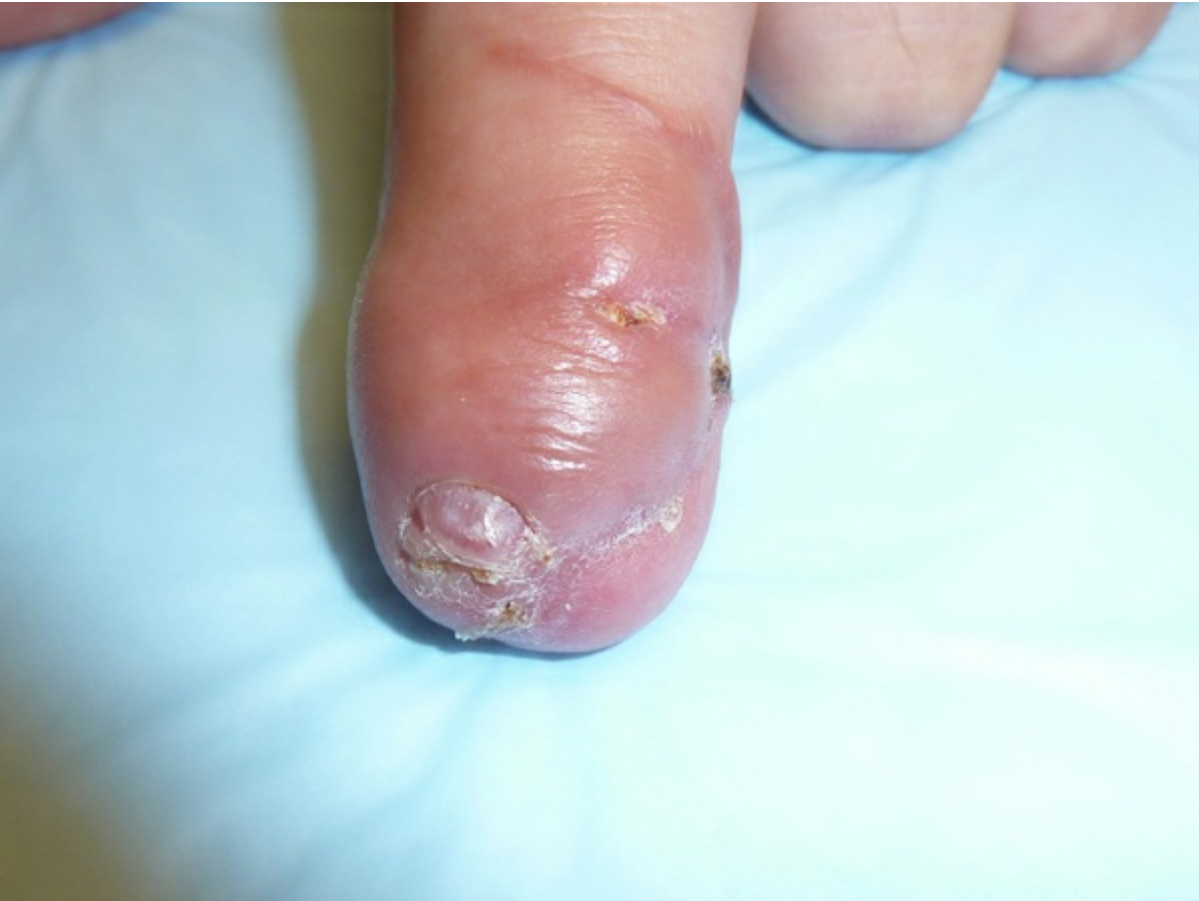

Figure 3-42 Nail spike that has formed as a result of residual nail forming tissue that was left in place when the amputation was treated with primary closure.

Composite Grafts

Very commonly after a complete sharp amputation of the fingertip at the proximal fingernail level, patients will come into the emergency room with the tip “on ice” to have it “replanted.” Although very distal fingertip microsurgical replantation has been reported, they have not commonly performed with success in the United States. It is very tempting to simply sew the tip “back on” without microvascular anastomosis and hope for the best.

Composite grafting is quite useful in children and some young teenagers but in adults older than 18 years, especially smokers and those with vascular disease, the results are less encouraging with the tip turning necrotic and secondary removal and coverage procedures ultimately required (Figure 3-43). More recently, studies have demonstrated increased survival of the tips up to 52%.⁶⁷ When nonsmokers were isolated as a group, 80% survival of the composite graft has been reported even to the age of 50 years. However, recovery of sensation is highly variable and joint stiffness has been reported. Recent studies have also reported the use of intravenous lipo-prostaglandin E₁ and ice cooling of the amputated part up to 5 hours before reimplantation, and 1 series reported up to a 95% success rate.⁶⁸ In children younger than 10 years, distal tip composite graft reattachment should be attempted. At the very least, it will function as a physiologic dressing. At worst, it will not survive and advancement flap coverage can be performed.

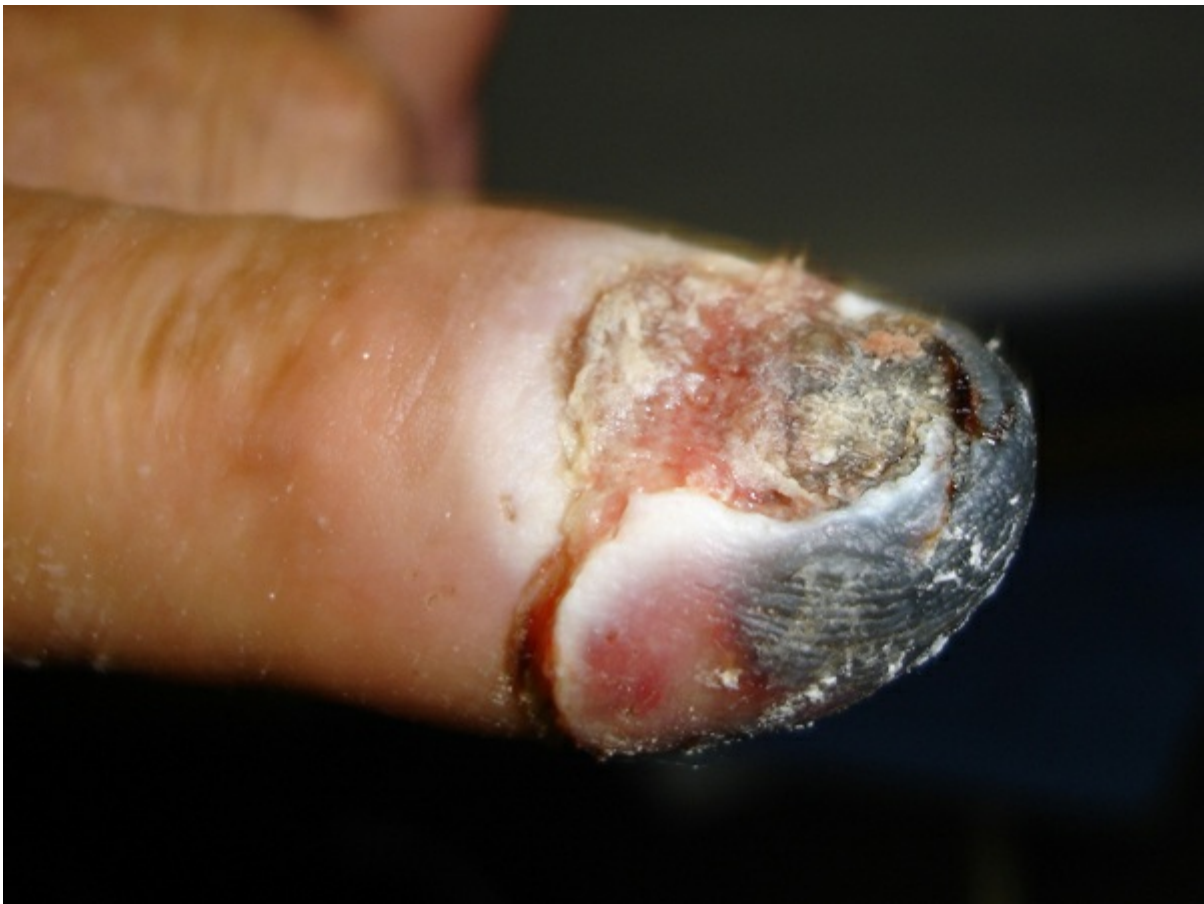

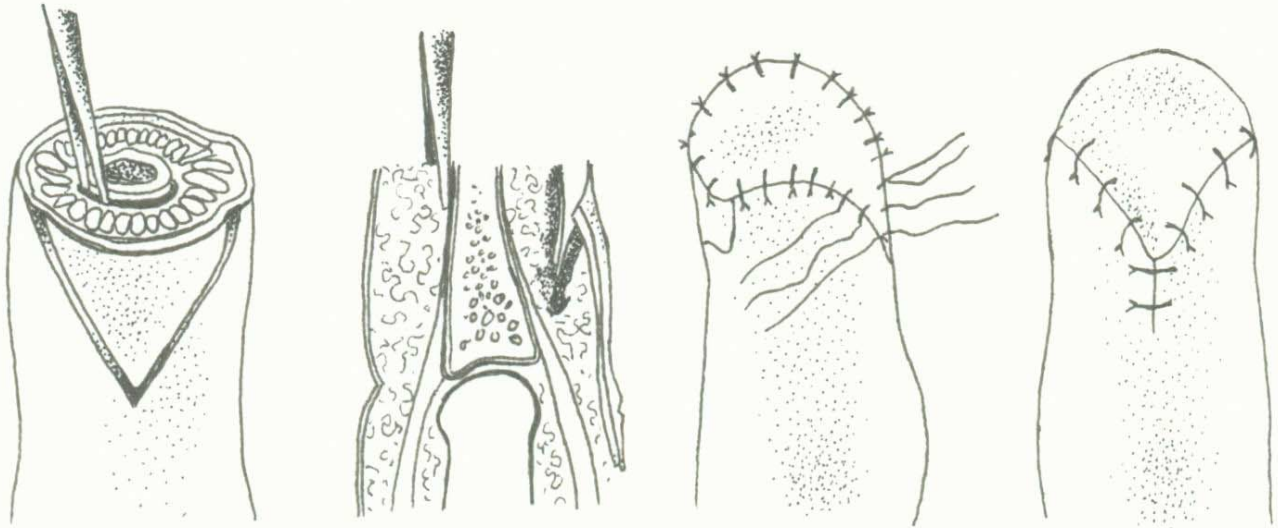
Figure 3-43 Four weeks after a composite graft in an adult. The tip has begun to necrose and the tip will need to be reamputated and reconstructed.

V-Y Advancement Flaps

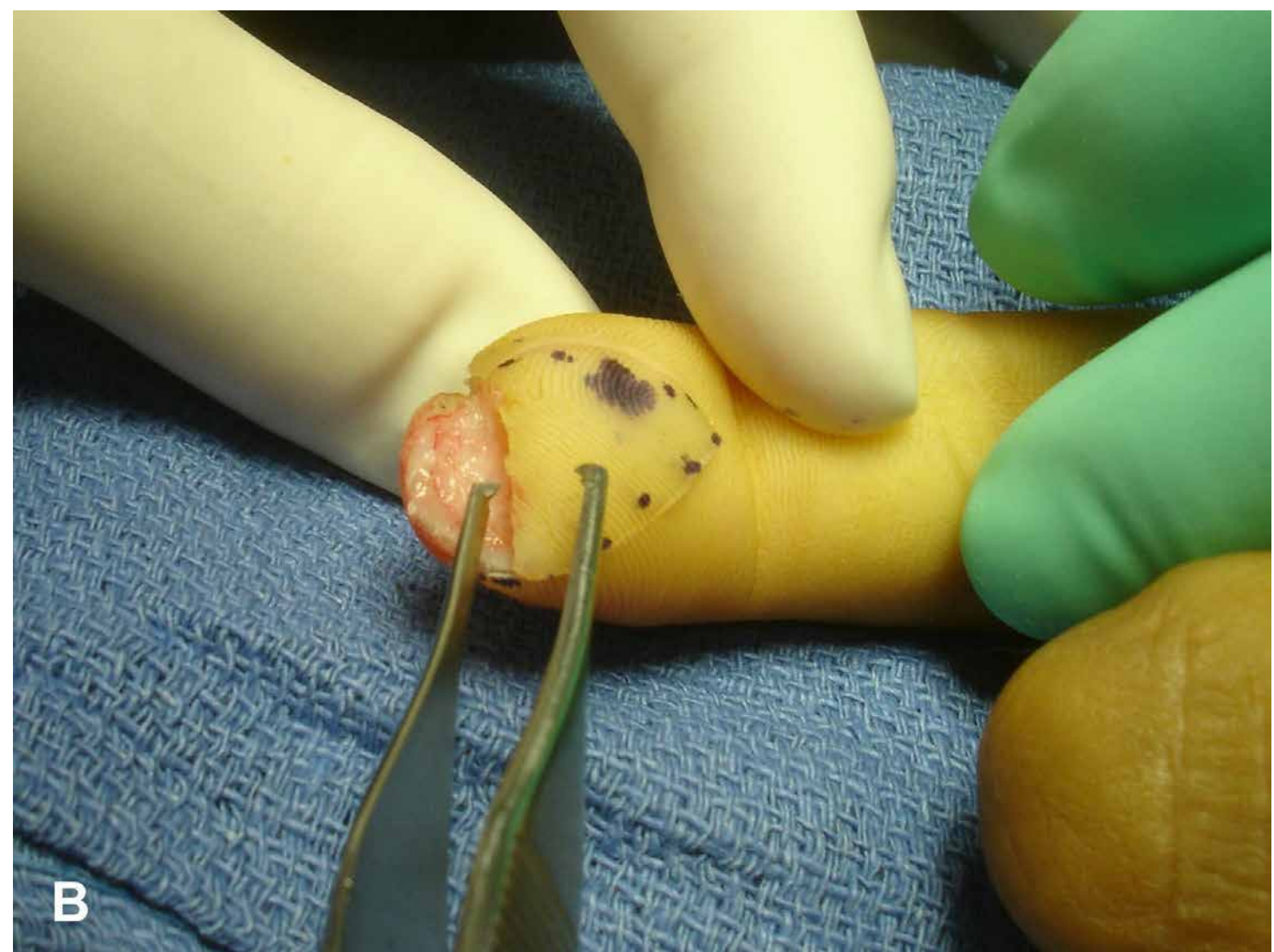
When the amputation is at the level of the distal half of the nail bed and is perpendicular to the long axis of the finger, advancing triangular vascularized pedicles from either the volar pad for a dorsal oblique amputation where there is a significant volar pad or

the sides of the finger may provide a durable, padded fingertip even in the presence of exposed bone. These are random flaps that receive their blood supply from the myriad of tiny vessels in the subcutaneous plexus.

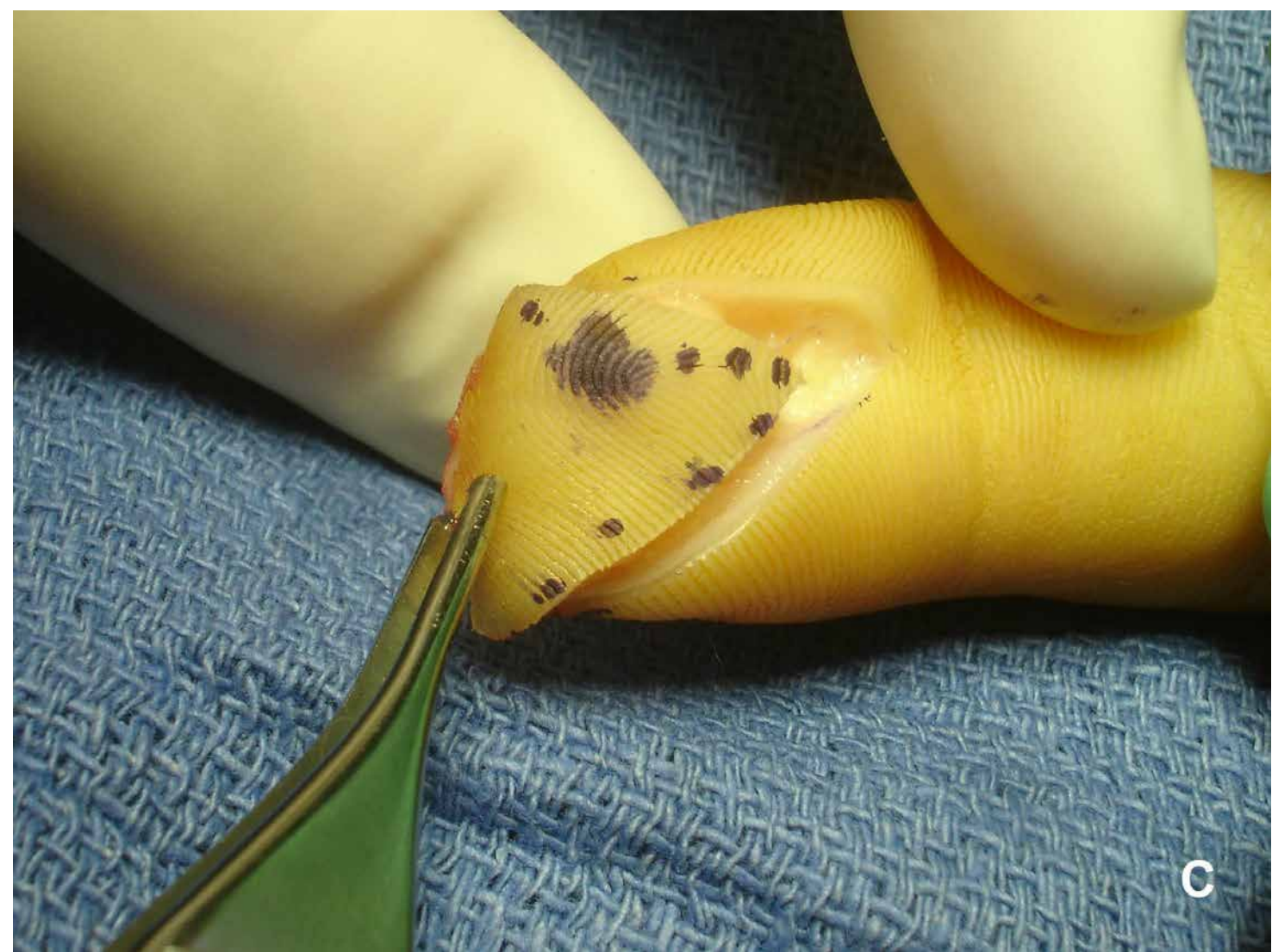
The volar flap described by Atasoy et al in 1970⁶⁹ and the bilateral lateral flaps reported by Kutler⁷⁰ have similar requirements. Both have to be elevated subperiosteally. Both are also triangular with the apex proximally and they need to be mobilized sufficiently to allow up to 8 mm of distal advancement without compromising the vascular pedicles feeding the flap (Figure 3-44). This will involve spreading and gently cutting the fibrous tissue tethering the flap proximally without cutting the vessels and nerves. Generally, the majority of the fibrous septae are dorsal, near the periosteum of the bone, whereas the nerves and blood vessels lie closer to the volar skin.



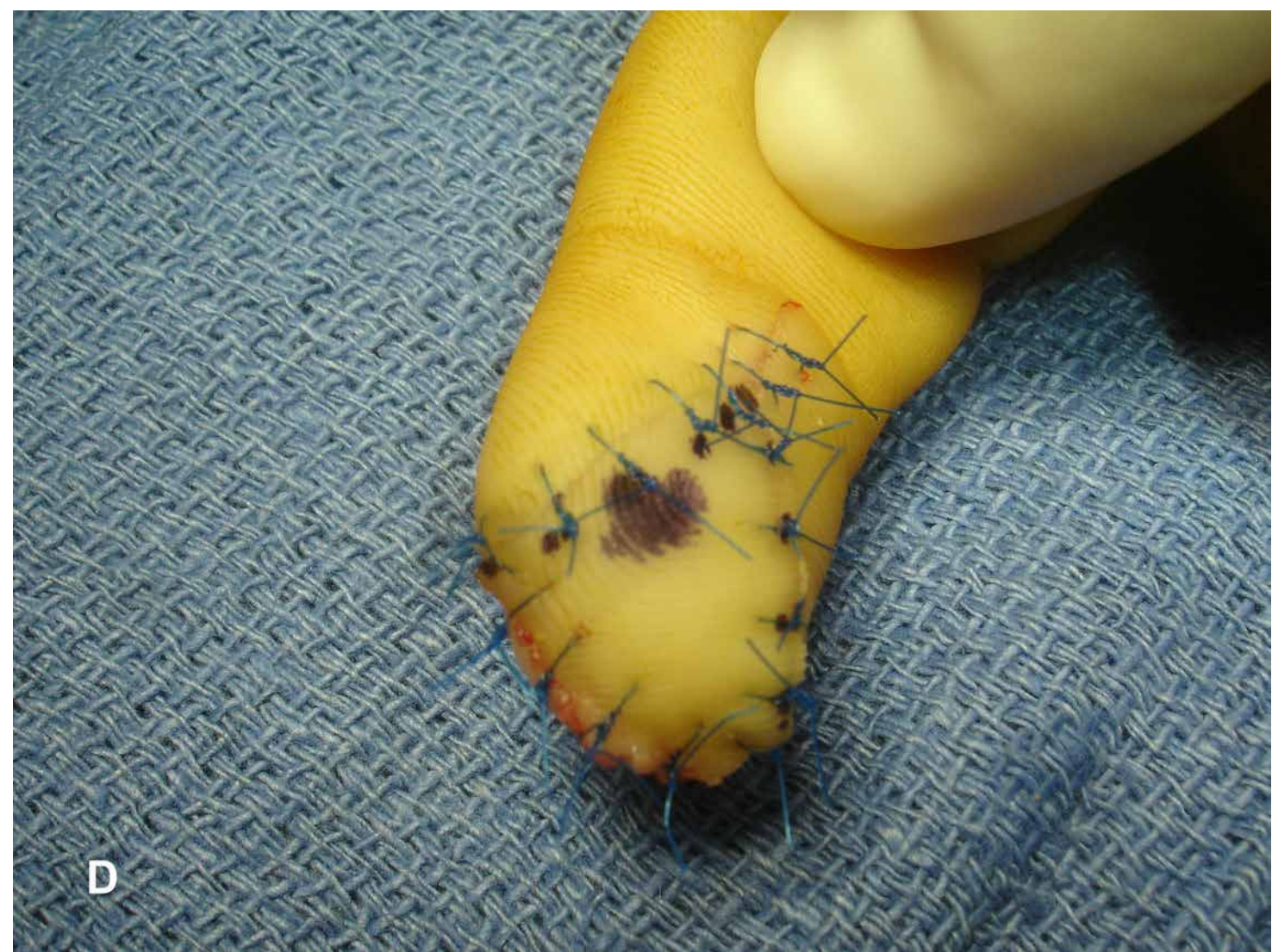A



B



C



D

Figure 3-44 A-D, Volar V-Y advancement flap. The flap needs to be mobilized subperiosteally and advanced with minimal tension so as not to cause vascular compromise.

Once the volar flaps are advanced, usually up to 8 to 10 mm, they are sutured to the hyponychium or the dorsal end of the defect. The angle of the apex should not be less than 45° and can safely be extended beyond the volar distal interphalangeal crease proximally without creating a contracture. In general, it is believed that one should not attempt the flap unless more than 50% of the volar pad remains. Some series have reported a stable, durable, sensate, and painless tip, whereas others reported dysesthesia and cold intolerance but this diminishes with time.⁷¹ This study reported earlier return to work with V-Y flaps than with skin grafts or healing by secondary intention.

Lateral Kutler flaps are raised from both sides of the digit and advanced to meet in the middle and to the dorsal and volar margins of the amputation defect (Figure 3-45). These flaps are useful in palmar oblique and transverse tip amputations. They are based on digital arteries and venae comitantes. Because the angle of the apex is much sharper than the single volar flap, the length of advancement is only about 5 mm. There is a significant incidence of dysesthesia and cold intolerance. Tupper and Miller⁷² followed

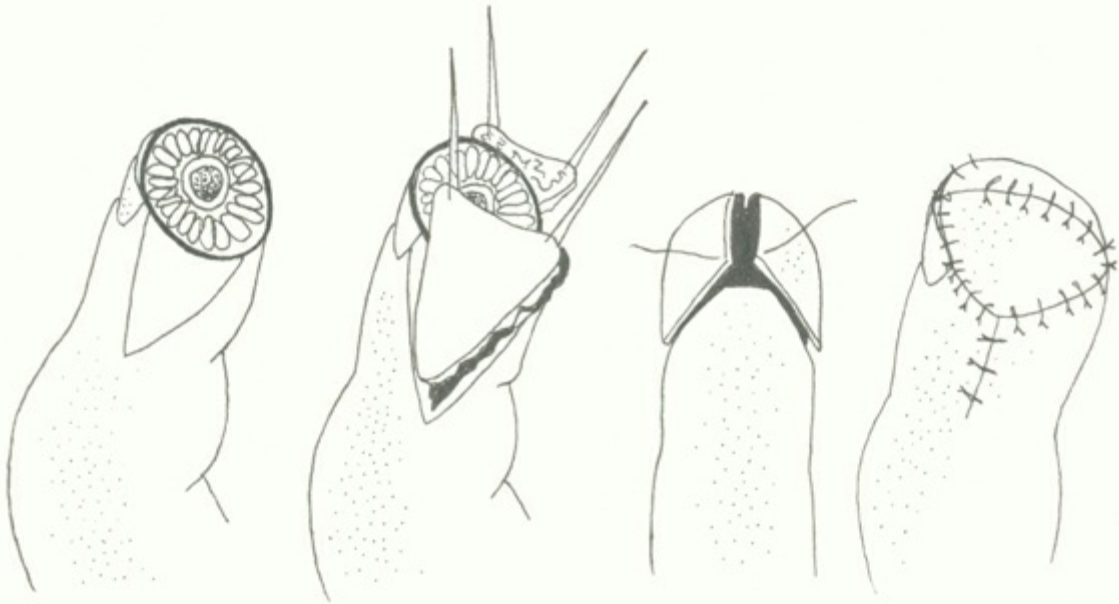


Figure 3-45 Bilateral lateral “Kutler” flaps. These flaps are extremely fragile, are difficult to advance, and have a higher necrosis rate than the volar flap.

29 patients for 6 years after volar V-Y flaps and found an average difference of about 3 mm of 2-point discrimination compared with normal controls.

An oblique triangular flap is a large flap originating from one side of the finger. The apex is proximal and the sides are 2.5 times the length of the distal base. Advancement of 12 mm is possible, but this procedure has significant problems, which include dysesthesia, cold intolerance, and suboptimal sensory recovery. Furlow⁷³ described a large volar flap that can originate at the volar PIP crease and have the distal ends sewn to each other forming a “cup” to re-create a fingertip. The flap length is up to 3 cm in length.

Great care needs to be exercised if these flaps are to be used in smokers or patients with vascular disease. There have been mixed reviews in the literature concerning outcome. One series reported normal sensibility and motion of the fingertip in 91% of

patients, and another noted hypoesthesia, dysesthesia, and cold intolerance in 70% of patients.⁷⁴

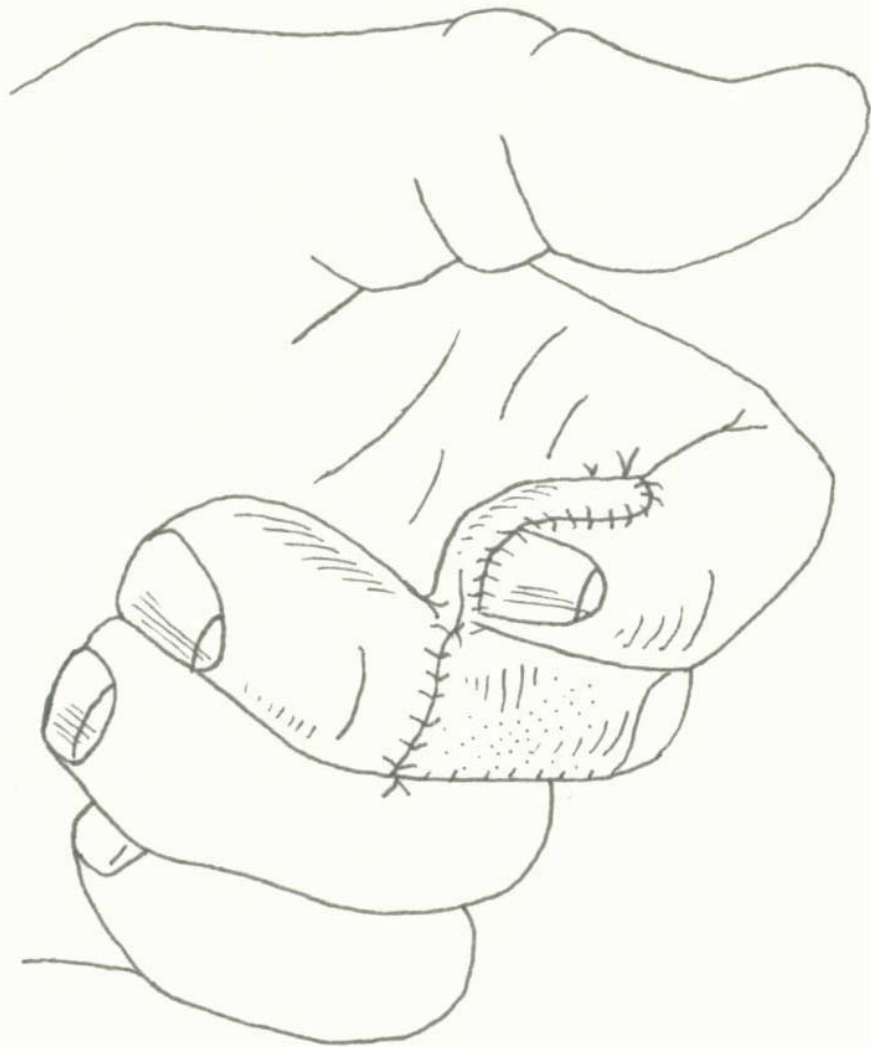
Moberg Flaps

The Moberg is a specialty flap used to cover thumb tip defects. It is an axial flap proximally based on the radial and ulnar digital arteries, veins, and nerves. Advancement of 15 mm is possible when bilateral midaxial incisions are made and the proximally based flap is raised including skin, subcutaneous tissue, digital arteries, venae comitantes, and nerves. The flexor tendon sheath is left in place. The flap can be elevated back to the volar MCP crease. To affect closure distally, the interphalangeal joint may need to be flexed. Further advancement may necessitate proximal skin release, taking care not to tether the neurovascular structures. The proximal defect will need to be skin grafted. Outcomes have been very favorable with low incidence of tip dysesthesia and cold intolerance. Normal sensitivity of the tip of the thumb has been reported, but flexion contracture is common.

This procedure cannot be performed in other digits because other digits depend on perforating branches from the volar proper digital arteries going dorsally for their dorsal vascularity. The thumb's dorsal skin has independent dorsal circulation and can tolerate separating the dorsal skin from the main trunks of the digital arteries.

Cross-Finger Flaps

Cross-finger flaps are random pattern flaps that are designed to cover soft tissue defects on the dorsal or volar aspects of fingers by transfer of adjacent tissue from one finger to another. The donor site is generally covered with a skin graft (Figure 3-46). After a period of time allowing ingrowth of vascularity into the flap from recipient tissue (usually ~3 wk), the flap is divided. There is often excellent sensory return over the defect after flap coverage.



A

B

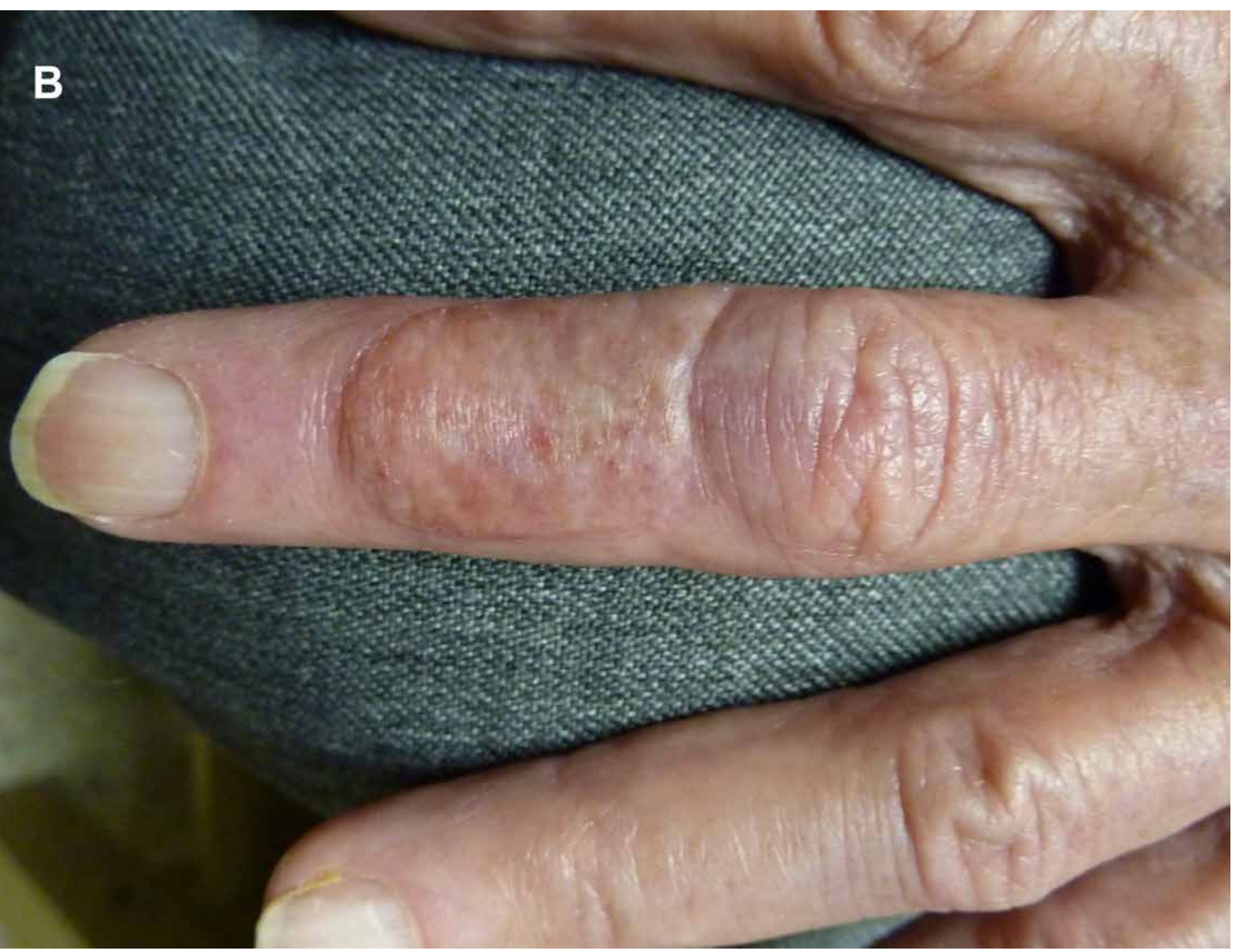

Figure 3-46 A, Cross-finger flap. The volar tip of the index finger is covered by a flap of dorsal skin from the middle finger. The donor site is covered by a full-thickness skin graft. **B**, One year after cross-finger flap, the donor site is well epithelialized and stable.

There are 2 types of cross-finger flaps—direct and reverse. A *direct flap* involves elevation of a full-thickness flap from a finger to cover the other side of an adjacent finger, that is, dorsal to volar or volar to dorsal. It is generally recommended that volar skin not be used for dorsal skin because of its glabrous nature. An *indirect or reverse flap* requires turnover of subcutaneous fascia and adipose tissue to an adjacent finger defect on the same side of the digit after lifting the skin away in the opposite direction. The skin is laid back down onto its own bed again. The recipient site is skin grafted over the flap.

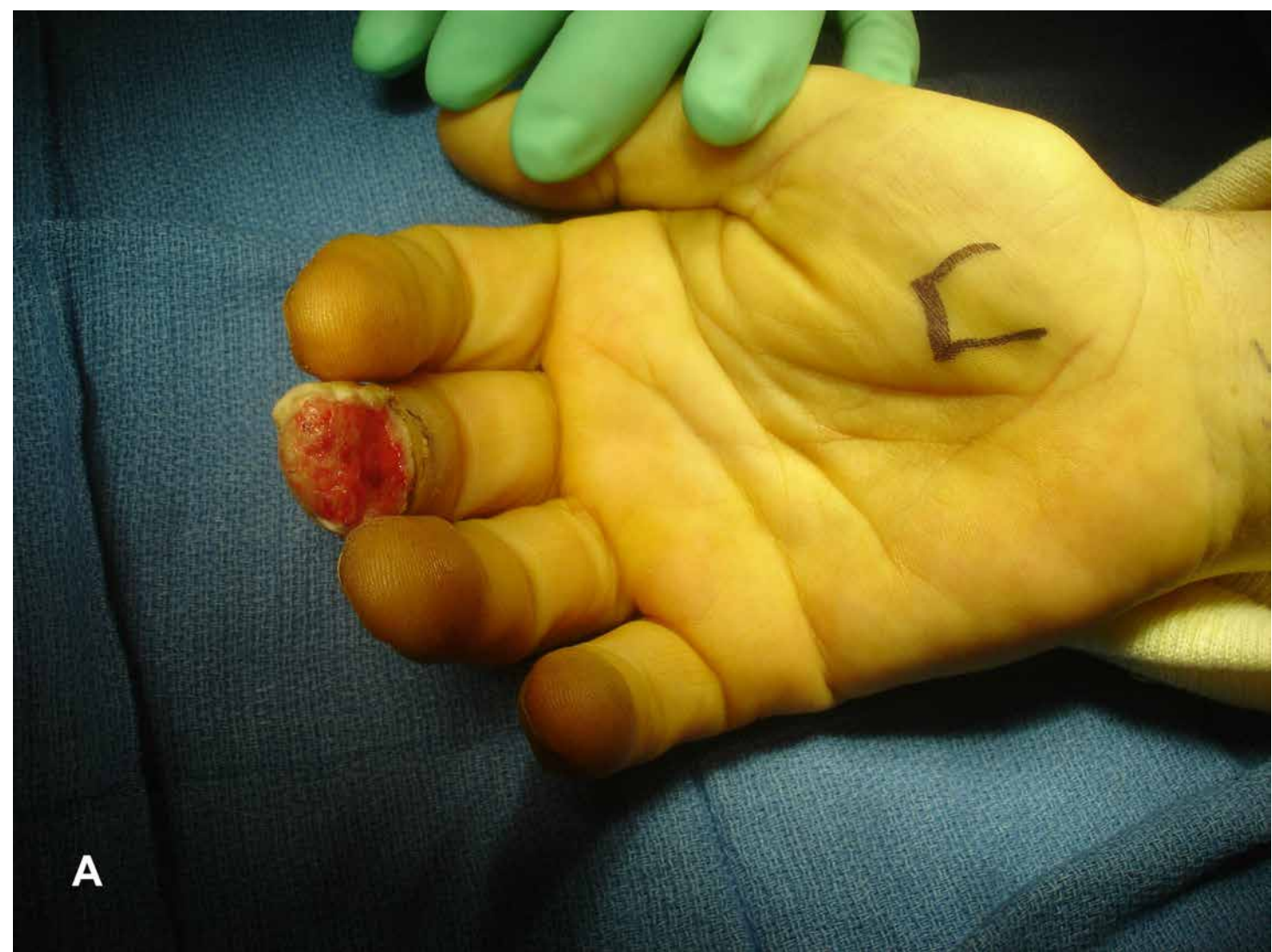Technical tips:

1. Oversize the flap by several millimeters so that it fits easily over the defect.
2. Always leave a layer of paratenon on the tendon at the donor site so that it will accept a skin graft.
3. Leave the flaps in place for at least 3 weeks so that parasitic blood flow will vascularize the flap at its new bed.
4. Avoid overflexing the donor or recipient finger to prevent contractures.
5. Cross-finger flaps are useful for fingertips when the donor site is distal to the defect, even from index finger to thumb.
6. Full-thickness skin grafts should be used to cover the donor sites and should be large enough to cover the part of the flap between the two fingers. This will prevent the base of the flap from “drying out” from below.

Nicolai and Hentenaar⁷⁵ reported that, at 4 years, 75% of their patients had return of near-normal 2-point discrimination, but this figure falls off after the age of 40, when only 40% get excellent results. Return to work generally occurs in 3 weeks for sedentary work, but manual laborers may not return for 6 months.

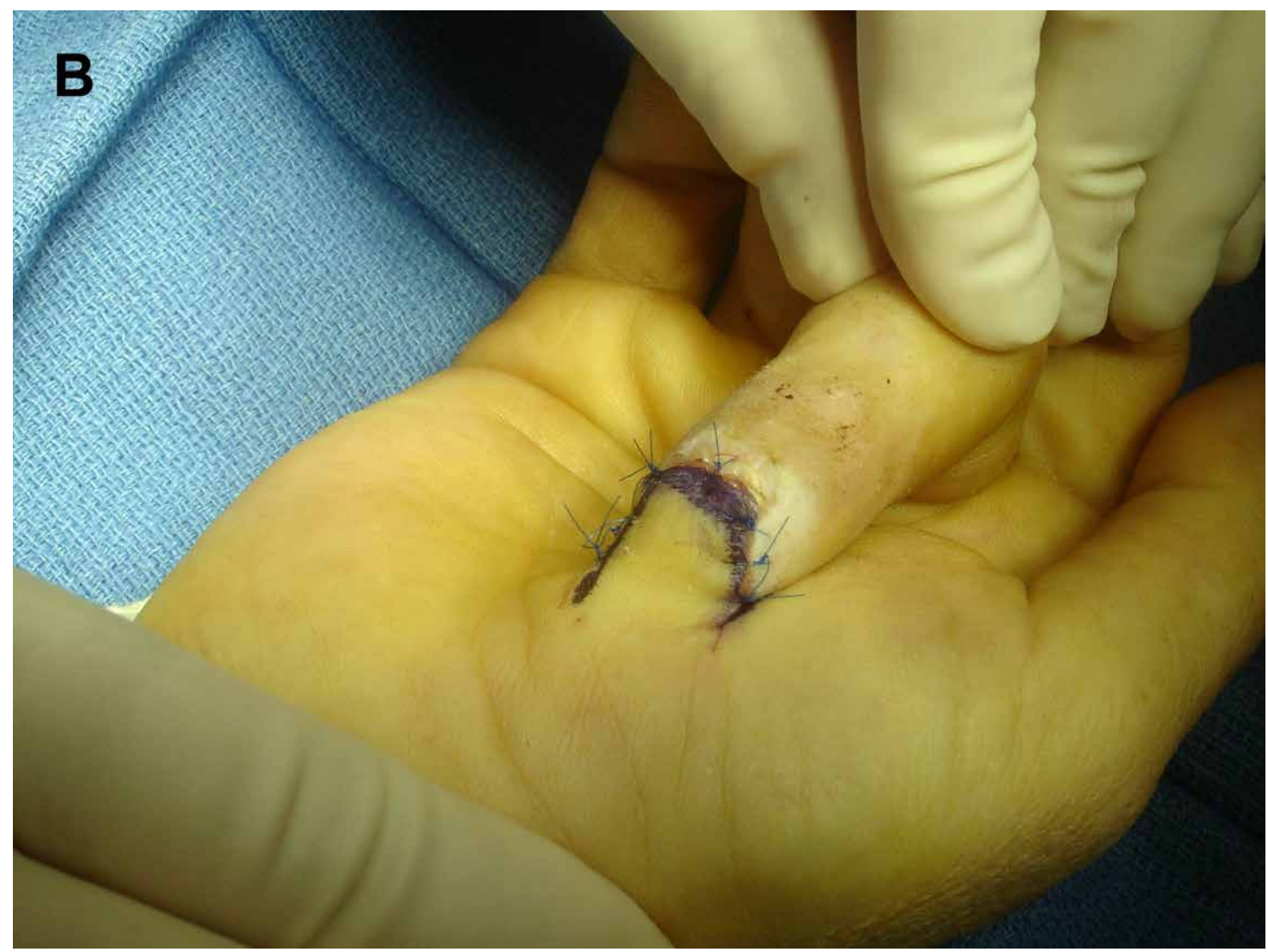Thenar Flaps

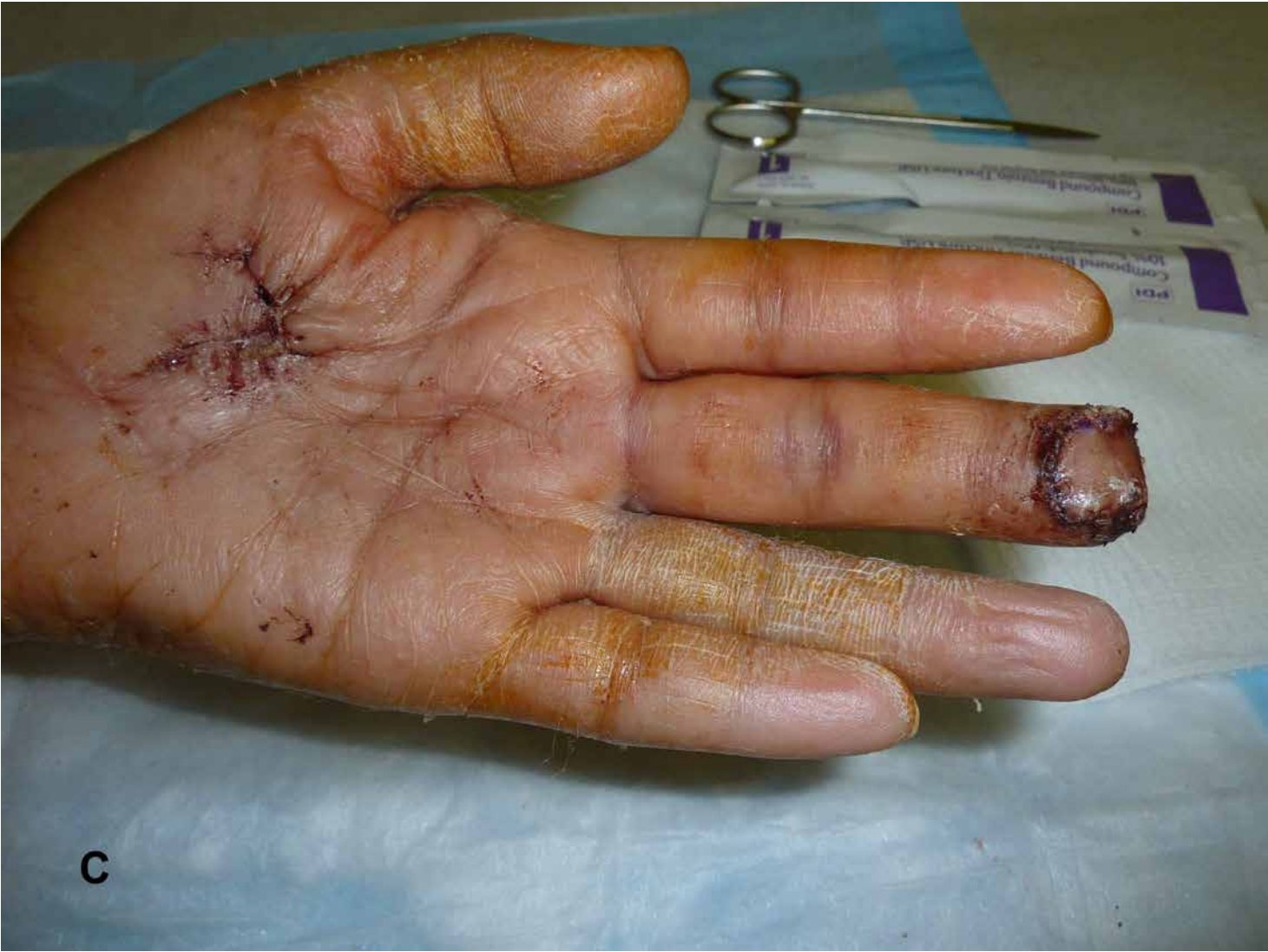A thenar flap involves elevation of a random proximally or distally based flap from the thenar eminence to cover fingertip defects in fingers that are bent down to “meet” the flap (Figure 3-47). These are most useful in coverage of fingertip defects involving the index, middle, and ring fingers. The raised flap is usually H-shaped to allow coverage of both the fingertip and the donor site later on. It is nearly twice as large as the defect to allow tension-free attachment onto the fingertip. Once the flap is inset, the finger must remain flexed at the MCP and PIP joints for about 3 weeks until new vascularity grows into the flap from the fingertip. Then the flap is divided.



A

B





C

D

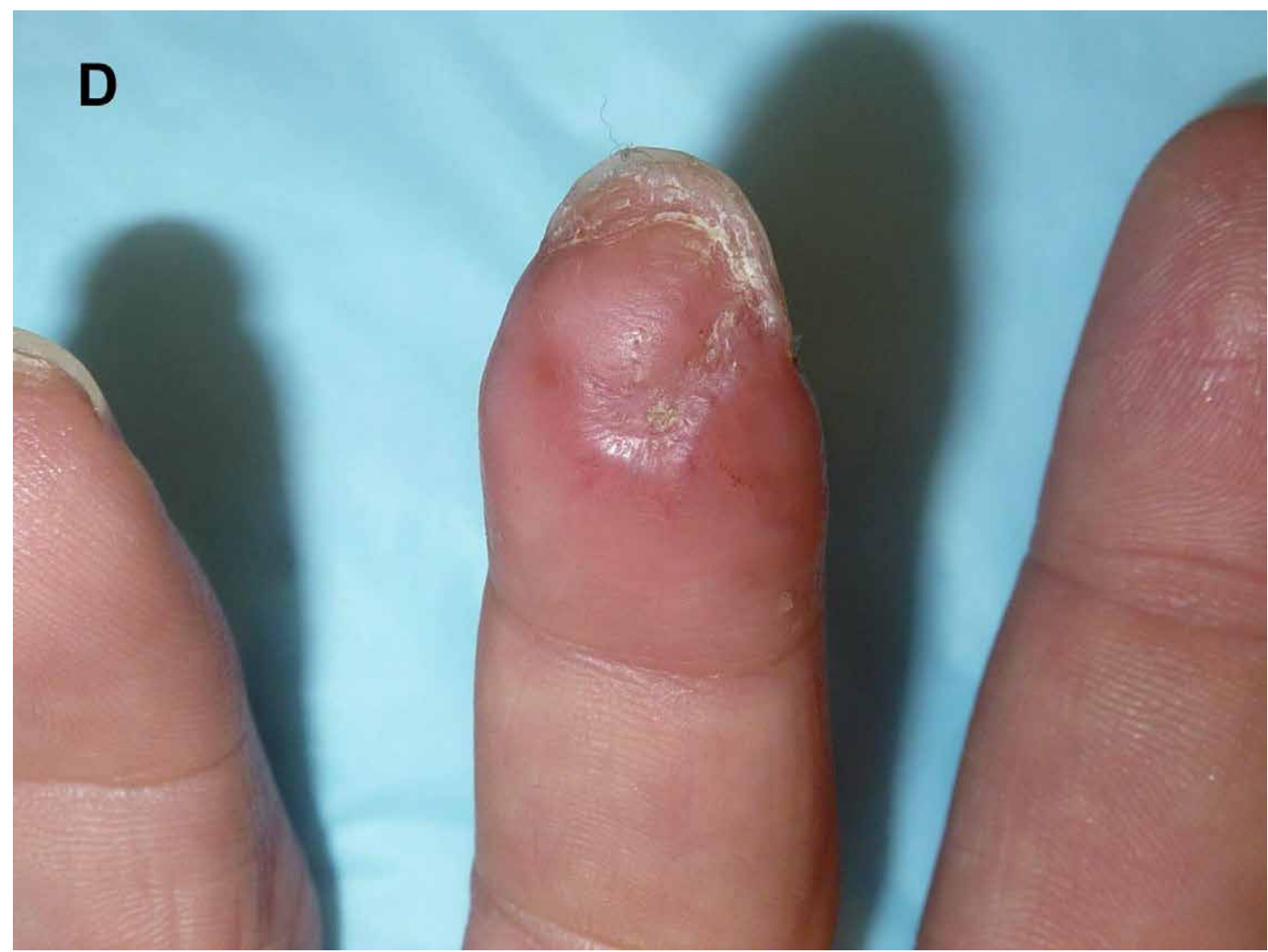

Figure 3-47 A, Large volar defect can ideally be covered with a thenar flap. However, this flap is unsuitable for older patients because of PIP stiffness that will result. **B**, Flap inset into thenar skin. Note the amount of PIP flexion required. This finger will stay in position for more than 2 weeks. **C**,

After flap separation, the donor site can be easily closed. **D**, Six months after surgery, the flap is viable and the nail has grown in.

Fingertip Injuries

This flap is contraindicated in older patients, patients with arthritic PIP or MCP joints, or patients with preexisting contractures because the 3 weeks of flexion can result in permanent stiffness. Limited sensibility is restored, but the flap is generally thick enough to pad defects even with some exposed bone.

Summary

The fingertip is the primary organ of tactile interaction with the environment and, as such, is particularly vulnerable to injury. Management decisions hinge on the mechanism and severity of injury, the tissue(s) injured, the location on the fingertip of the injury, and the overall characteristics of the patient injured. This may include age and gender, occupation, underlying medical conditions, and cultural and religious sensitivities.

Goals of treatment must be focused on restoring a mobile, sensate, painless, cosmetically pleasing fingertip that has the stability and length to facilitate power grip. The primary areas of concern are the nail apparatus, volar pad, distal phalanx, DIP joint and the insertions of the flexor and extensor tendons on the distal phalanx.

Training and experience can afford the ability to make reasonable judgments as how best to proceed, taking into account not only how best to restore the anatomy but also when not to do so, in order to return patients as rapidly as possible to productive work and home life. In conclusion, whereas there are many ways of treating fingertip injuries, ultimately common sense and prudence will yield the patient the optimal result.

REFERENCES

1. Schneider LH: Fractures of the distal phalanx. *Hand Clin* 1988;4:537-547.
2. Costello J, Howes M. Best evidence topic report. Prophylactic antibiotics for subungual hematoma. *Emerg Med J* 2004;21:503.
3. Roser SE, Gellman H. Comparison of nail bed repair versus trephination for subungual hematomas in children. *J Hand Surg* 1999;24A:1166-1170.
4. Gellman H. Fingertip-nail bed injuries in children: current concepts and controversies in treatment. *J Craniofac Surg* 2009;20:1033-1035.

5. Henry M. Variable pitch headless compression screw treatment of distal phalangeal nonunions. *Tech Hand Surg* 2010;14:230-233.
6. Seymour N. Juxta-epiphyseal fracture of the terminal phalanx of the finger. *J Bone Joint Surg* 1966;48B:347-349.
7. Rogers GF, Labow BI. Diaphyseal non-union in the distal phalanx of a child. *J Hand Surg* 2007;32E:85-87.
8. Zook EG. The perionychium: anatomy, physiology, and care of injuries. *Clin Plast Surg* 1981;8:21-31.
9. Baden HP. Regeneration of the nail. *Arch Dermatol* 1964;91:619-620.
10. Zook EG, Guy RJ, Russell RC. A study of nail bed injuries: causes, treatment and prognosis. *J Hand Surg* 1984;9A:247-252.
11. Brown RE, Zook EG, Russell RC. Reconstruction of the fingertips with a combination of local flaps and nail bed grafts. *J Hand Surg* 1999;24A:345-351.
12. Rayan GM, Elias LS. Irreducible dislocation of the distal interphalangeal caused by long flexor tendon entrapment. *Orthopedics* 1981;4:35-37.
13. Abouzahr MK, Poblete J, Vicente P. Irreducible dorsal dislocation of the distal interphalangeal joint: case report and review of the literature. *J Trauma* 1997;42:743-745.
14. Sabapathy SR, Bose VC, Rex C. Irreducible dislocation of the interphalangeal joint of the thumb due to sesamoid bone interposition: a case report. *J Hand Surg* 1995;20A:487-489.
15. Horiuchi Y, Itoh Y, Sasaki T. Dorsal dislocation of the DIP joint with fracture of the volar base of the distal phalanx. *J Hand Surg* 1989;14B:177-182.
16. Inoue G, Maeda N. Irreducible palmar dislocation of the distal interphalangeal joint of the finger. *J Hand Surg* 1987;12A:1077-1079.
17. Kim YS, Song HS, Kim HM, Chung E, Park IJ. Simultaneous double dislocation of the interphalangeal joint in a finger. *Arch Orthop Trauma Surg* 2009;129:1387-1390.
18. Doyle JR. Extensor tendons: acute injuries. In: Green DP, Hotchkiss RN, Pederson WC, eds. *Operative hand surgery*. Vol. 2. 4th ed. New York: Churchill Livingstone, 1998:1962-1970.
19. Maitra A, Dorani B. The conservative treatment of mallet finger with a simple splint: a case report. *Arch Emerg Med* 1993;10:244-248.
20. Schweitzer TP, Rayan GM. The terminal tendon of the digital extensor mechanism: part 2, kinematic Study. *J Hand Surg* 2004;29A:903-908.

21. Mason ML. Ruptures of tendons in the hand: with a study of the tendon insertions in the fingers. *Surg Gynecol Obstet* 1930;50:611-624.
22. Smillie IS. Mallet finger. *Br J Surg* 1937;24:439-445.
23. Stack G. Mallet finger. *Lancet* 1968;2:1303.
24. Auchincloss JM. Mallet-finger injuries: a prospective, controlled trial of internal and external splintage. *Hand* 1982;14:168-172.
25. Crawford GP. The molded polyethylene splint for mallet finger deformities. *J Hand Surg* 1984;9A:231-237.
26. Okafor B, Mbubaegbu C, Munshi I, Williams DJ. Mallet deformity of the finger. Five year follow-up of conservative treatment. *J Bone Joint Surg* 1997;79B:544-547.
27. Warren RA, Norris SH, Ferguson DG. Mallet finger: a trial of two splints. *J Hand Surg* 1988;13B:151-153.
28. Pike J, Mulpuri K, Metzger M, Ng G, Wells N, Goertz T. Blinded, prospective, randomized clinical trial comparing volar, dorsal, and custom thermoplastic splinting in treatment of acute mallet finger. *J Hand Surg* 2010;35A:580-588.
29. O'Brien L, Bailey M. Single blind, prospective, randomized, controlled trial comparing dorsal aluminum and custom thermoplastic splints to stack splint for acute mallet finger. *Arch Phys Med Rehabil* 2011;92:191-198.
30. Handoll HH, Vaghela MV. Interventions for treating mallet finger injuries. *Cochrane Database Syst Rev* 2004;3:CD004574.
31. Flint MH. Some observations on the vascular supply of the nail bed and terminal segments of the finger. *Br J Plast Surg* 1955;8:185-195.
32. Rayan GM, Mullins PT. Skin necrosis complicating mallet finger splinting and vascularity of the distal interphalangeal joint overlying skin. *J Hand Surg* 1987;12A:548-552.
33. Stern PJ, Kastrup JJ. Complications and prognosis of treatment of mallet finger. *J Hand Surg* 1988;13A:329-334.
34. Wehbe MA, Schneider LH. Mallet fractures. *J Bone Joint Surg* 1984;66A:658-669.
35. Husain SN, Dietz JF, Kalainov DM, Lautenschlager EP. A biomechanical study of distal interphalangeal subluxation after mallet fracture injury. *J Hand Surg* 2008;33A:26-30.
36. Lubahn JD. Mallet finger fractures: a comparison of open and closed technique. *J Hand Surg* 1989;14A:394-396.
37. Hofmeister EP, Mazurek MT, Shin AY, Bishop AT. Extension block pinning for large mallet fractures. *J Hand Surg* 2003;28A:453-459.

38. Bischoff R, Buechler U, De Roche R, Jupiter J. Clinical results of tension band fixation of avulsion fractures of the hand. *J Hand Surg* 1994;19A:1019-1026.
39. Fritz D, Lutz M, Arora R. Delayed single Kirschner wire compression technique for mallet fracture. *J Hand Surg* 2005;30B:180-184.
40. Kronlage SC, Faust D. Open reduction and screw fixation of mallet fractures. *J Hand Surg* 2004;29B:135-138.
41. Kang HJ, Shin SJ, Kang ES. Complications of operative treatment for mallet fractures of the distal phalanx. *J Hand Surg* 2001;26B:28-31.
42. Zhang X, Meng H, Shao X, Wen S, Zhu H, Mi X. Pull-out wire fixation for acute mallet finger fractures with k-wire stabilization of the distal interphalangeal joint. *J Hand Surg* 2010;35A:1864-1869.
43. Rocchi L, Genitiempo M, Fanfani F. Percutaneous fixation of mallet fractures by the “umbrella handle” technique. *J Hand Surg* 2006;31B:407-412.
44. Phadnis J, Yousaf S, Little N, Chidambaram R, Mok D. Open reduction internal fixation of the unstable mallet fracture. *Tech Hand Up Ext Surg* 2010;14:155-159.
45. Teoh LC, Lee JYL. Mallet fractures: a novel approach to internal fixation using a hook plate. *J Hand Surg* 2007;32B:24-30.
46. Lucchina S, Badia A, Nistor A, Fusetti C. Surgical treatment options for unstable mallet fractures. *Plast Reconstr Surg* 2011;2:599-600.
47. Tabbai GN, Bastidas N, Sharma S. Closed mallet thumb injury: a review of the literature and case study of the use of MRI in deciding treatment. *Plast Reconstr Surg* 2009;124:222-226.
48. Miura T, Nakamura R, Torii S. Conservative treatment for a ruptured extensor tendon on the dorsum of the proximal phalanges of the thumb (mallet thumb). *J Hand Surg* 1986;11A:229-233.
49. Din KM, Meggit BF. Mallet thumb. *J Bone Joint Surg* 1983;65B:606-607.
50. Verdan DE. Primary and secondary repairs of flexor and extensor tendon injuries. In: Flynn JE, ed. *Hand Surgery*. 2nd ed. Baltimore: Williams & Wilkins; 1975:152.
51. Makhlof V, Al Deek N. Surgical treatment of chronic mallet finger. *Ann Plast Surg* 2011;66:670-672.
52. Bowers HW, Hurst LC. Chronic mallet finger: the use of Fowler’s central slip release. *J Hand Surg* 1978;3:373-376.
53. Lind J, Hansen B. A new operation for the chronic mallet finger. *J Hand Surg Br.* 1989;14:347-349.
54. Ulker E, Cengiz A, Ozge E. Repair of chronic mallet finger using Mitek micro arc bone anchor. *Ann Plast Surg* 2005;5:393-

55. Kleinman WB, Petersen DP, Oblique retinacular ligament reconstruction for chronic mallet finger deformity. *J Hand Surg* 1984;9A:399-404.
56. Ruchelsman DE, Christoforou D, Wasserman B, Lee S, Rettig ME. Avulsion injuries of the flexor digitorum profundus tendon. *J Am Acad Orthop Surg* 2011;19:152-162.
57. Leversedge FJ, Ditsios JH, Goldfarb CA, Silva MJ, Gelberman RH, Boyer MI. Vascular anatomy of the human flexor digitorum profundus tendon insertion. *J Hand Surg* 2002;27A:806-812.
58. Leddy JP, Packer JW. Avulsion of the profundus tendon insertion in athletes. *J Hand Surg* 1977;1:66-69.
59. Silva MJ, Hollstein SB, Fayazi AH, Adler P, Gelberman RH, Boyer MI. The effects of multiple-strand suture techniques on the tensile properties of repair of the flexor digitorum profundus tendon to bone. *J Bone Joint Surg* 1998;80A:1507-1514.
60. Latandresse K, Dona E, Scougall PJ, Schreuder FB, Puchert E, Walsh WR. Cyclic testing of pullout sutures and micro-mitek anchors in flexor digitorum profundus tendon distal insertion. *J Hand Surg* 2005;30A:471-478.
61. McCallister WV, Ambrose HC, Katolik LI, Trumble TE. Comparison of pullout button versus suture anchor for zone I flexor tendon repair. *J Hand Surg* 2006;31A:246-251.
62. Martin C, González del Pino J. Controversies in the treatment of fingertip amputations: conservative versus surgical reconstruction. *Clin Orthop Relat Res* 1998;353:63-73.
63. Goitz RJ, Westkaemper JG, Tomaino MM, Sotereanos DG. Soft-tissue defects of the tissues: coverage considerations. *Hand Clin* 1997;2:189-205.
64. Mennen U, Wiese A. Fingertip injuries management with semi-occlusive dressing. *J Hand Surg* 1993;18B:416-422.
65. Shores JT, Lee WPA. Fingertip injuries. In: *Hand Surgery Update V*. Rosemont, IL: American Society for Surgery of the Hand, 2012:365-377.
66. Schenck RR, Cheema TA. Hypothenar skin grafts for fingertip reconstruction. *J Hand Surg* 1984;9A:750-753.
67. Heistein JB, Cook PA. Factors affecting composite graft survival in digital tip amputations. *Ann Plast Surg* 2003;50:299-303.
68. Eo S, Hur G, Cho S, Azari KK. Successful composite graft for fingertip amputations using ice cooling and lipo-prostaglandin E1. *J Plast Reconstr Surg* 2003;50:299-303.
69. Atasoy E, Ioakimidis E, Kasdan ML, Kutz JE, Kleinert HE. Reconstruction of the amputated finger with a triangular volar flap. A new surgical procedure. *J Bone Joint Surg* 1970;52A:921-926.

70. Kutler W. A new method for finger tip amputation. *JAMA* 1947;133:29.
71. Frandsen PA: A V-Y plasty as a treatment of fingertip amputation. *Acta Orthop Scand* 1979;49:255-259.
72. Tupper J, Miller G. Sensitivity following volar V-Y plasty for fingertip amputations. *J Hand Surg* 1985;10B:183-184.
73. Furlow LT. V-Y "cup" flap for volar oblique amputations of the fingers. *J Hand Surg* 1984;9B:253-256.
74. Foucher G, Boulas JH, Silva BD. The use of flaps in the treatment of fingertip injuries. *World J Surg* 1991;15:58-462.
75. Nicolai JPA, Hentenaar G. Sensation in cross finger flaps. *Hand* 1981;13:12-16.