

# **Equine Dental Developmental Abnormalities**

Jack Easley, DVM, MS, Diplomate ABVP (Equine)

Author's address: Equine Veterinary Practice, PO Box 1075, Shelbyville, KY 40066; E-mail: easleydvm@aol.com.

## **Take Home Message**

Abnormalities of dental development occur quite commonly in the horse. They can present with a wide range of clinical signs. Detailed oral and radiographic examinations are often needed to diagnose a developmental dental abnormality. Therapy can vary from removal of offending dental overgrowths to aggressive periodontal therapy and/or surgical tooth extraction.

## **Introduction**

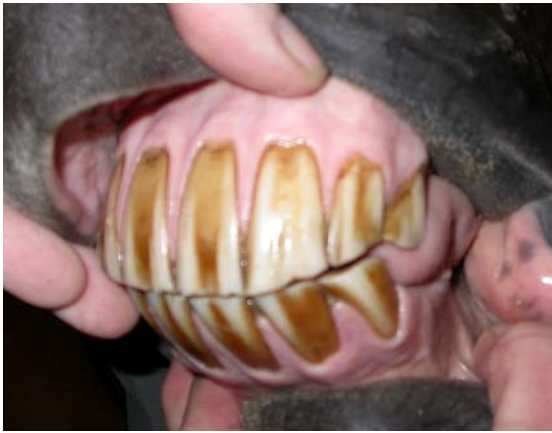Abnormalities of dental development and eruption occur quite commonly in the horse and result in a wide range of clinical conditions. A congenital/developmental problem present at the time of tooth eruption often leads to acquired dental problems as the teeth continue to erupt and wear. Consequently, several different dental abnormalities whose pathogenesis may be inter-related, are often present at the time of clinical presentation.

## **Supernumerary Teeth**

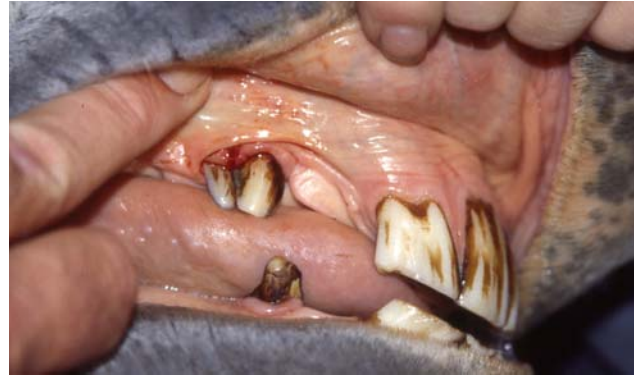Supernumerary teeth are teeth in excess of the normal expected number in any of the dental arcades. This disorder has been referred to as polydontia or hyperdentition. Supernumerary teeth (polydontia) are uncommonly diagnosed in the horse and the exact prevalence of the condition is unknown.

Supernumerary teeth can be loosely categorized morphologically in two categories: 1) Supplemental teeth that resemble teeth of the normal series in crown and root morphology although not always in size (Fig 1). If a horse has more than the usual number of teeth in an arcade, it may be impossible to be sure which tooth is supernumerary. 2) Rudimentary or dysmorphic teeth that are abnormally shaped and smaller in size than normal teeth.

The term "connate" describes a tooth anomaly that can arise from the fusion of a number of tooth germs or arising from partial splitting of a tooth primordium. Connate teeth are not necessarily supernumerary teeth, but some equine cheek teeth are connated (Fig. 2). Supernumerary teeth may develop in a normal direction of eruption or in an inverted, transverse, ectopic or other abnormal direction (Fig. 3). They may occur singly, multiply, unilaterally or bilaterally and in one or both jaws.



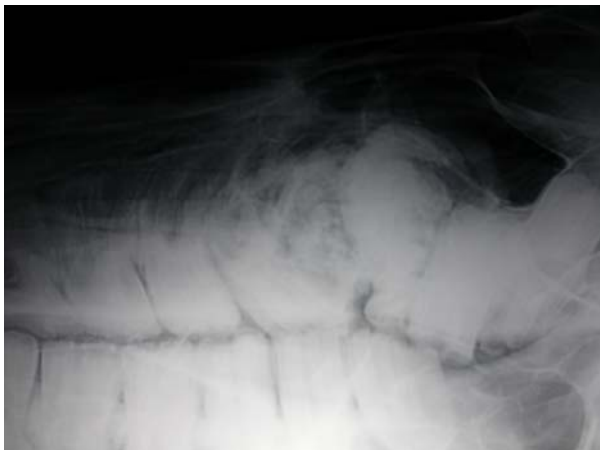**Figure 1.** 15-year-old Warmblood gelding with no history of a dental problem. Oral examination revealed a supplemental supernumerary left upper corner incisor tooth. This tooth was of normal size and shape. The crown had become prominent due to lack of occlusal wear.



**Figure 2.** A connate supernumerary right upper canine tooth in a 10-year-old, Thoroughbred gelding. The rostral (mesial) tooth appears to be of normal size and shape. The distal tooth which shares a common dental socket, is small and more conical than normal.

In general, the prevalence of equine supernumerary cheek teeth is greatest at the peripheries of the tooth class fields. The evidence is strongest with respect to the caudal aspects of the molar teeth but supernumerary teeth can also occur lingually, buccally or rostrally to the normal arcades. Clinical signs most commonly associated with supernumerary cheek teeth are dental overgrowths and diastemata, which cause secondary periodontal disease. Examination of a radiograph that encompasses the entire affected dental arcade is often necessary to diagnose this condition.

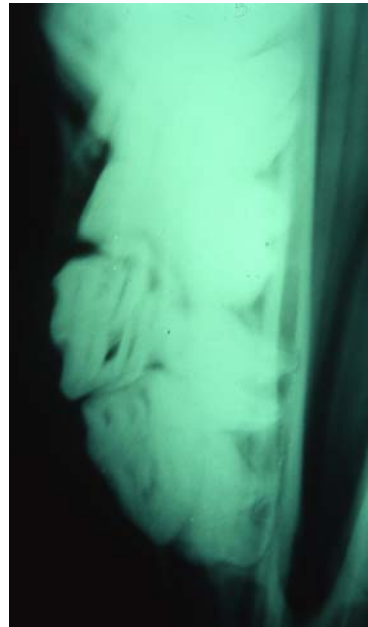
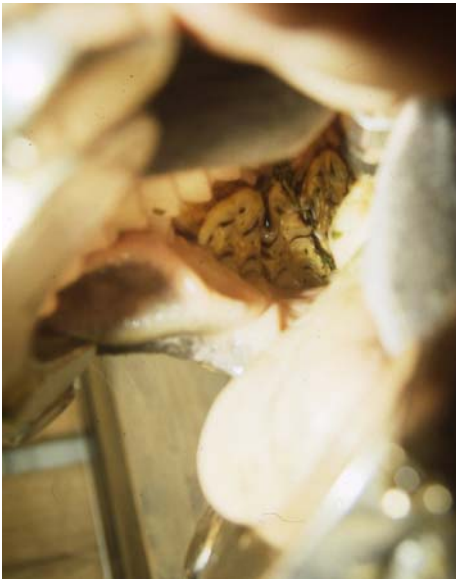Supernumerary canine and wolf teeth seldom occur but can be supplemental or connate. Supernumerary incisors of horses always belong to the permanent dentition and are reported more commonly in horses than are supernumerary cheek teeth. The main differential diagnosis for supernumerary incisors or cheek teeth is retained deciduous teeth. In some cases it may be clinically difficult to determine whether an extra tooth is a retained deciduous tooth or a supernumerary tooth. Radiographic examination of the



**Figure 3.** A thin, 19-year-old, pregnant, Thoroughbred mare with a history of chronic intermittent right-sided nasal discharge and dysmastication. Oral examination revealed an abnormal dental wear pattern with a deep periodontal pocket in the area of 110. A lateral radiograph revealed a dysplastic tooth present in the 110 position with chronic reactive cementum surrounding the reserve crown and apex. 109 and 111 were vertically tilted and had drifted into the 110 position. An unerupted supernumerary 7<sup>th</sup> upper cheek tooth (112) was present distal to and partially superimposed on the penultimate tooth.

affected jaw may be indicated to determine the identity of an extra tooth. A retained deciduous tooth has a more mature root and shorter reserve crown than the adjacent permanent teeth, and these distinguishing characteristics are seen during radiographic examination (Fig. 4).

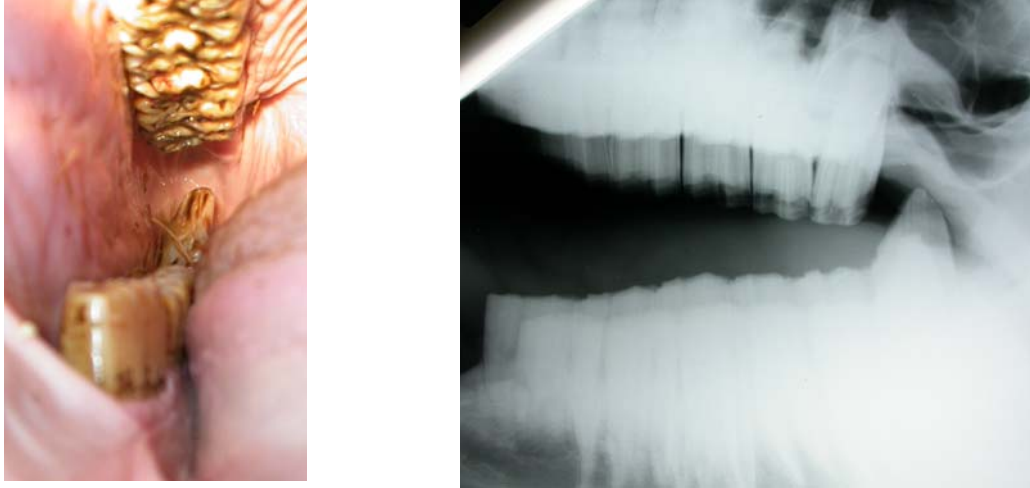
Management of horses with supernumerary teeth is generally limited to regular assessment of the dentition coupled with aggressive dental floating to minimize the opportunity for soft tissue damage by unopposed tooth elongations or sharp enamel points. If complications such as severe periodontal disease or maxillary sinusitis occur, the supernumerary tooth or displaced adjacent tooth should be extracted and appropriate therapy undertaken to manage associated pathology.



**Figure 4. A 5-year-old miniature horse mare with a history of packing food in the buccal spaces. Oral examination revealed bilateral double rows of upper premolar teeth. Radiographic examination revealed that the reserve crowns of the buccal rows of premolars had short, mature apical ends. These were compatible with partially retained, worn, buccally displaced deciduous premolars. A dental elevator was used to displace the retained deciduous teeth buccally. The loose teeth were then easily extracted. The horse began to eat better within several days. Retained deciduous teeth can be easily confused with supernumerary dentition during a clinical examination.**

### **Oligodontia**

Oligodontia is the congenital absence of a tooth germ or retention and inclusion of a tooth within the jaw. It is difficult to differentiate developmental oligodontia from acquired tooth loss caused by damage to or displacement of a dental bud from injury. It is possible for permanent tooth germs of a young horse to be damaged, displaced or removed when deciduous teeth or jaw bones are injured. Absence of a tooth in the dental arcade leads to mesial drift or tipping of neighboring teeth. Lack of wear of the antagonist to the missing



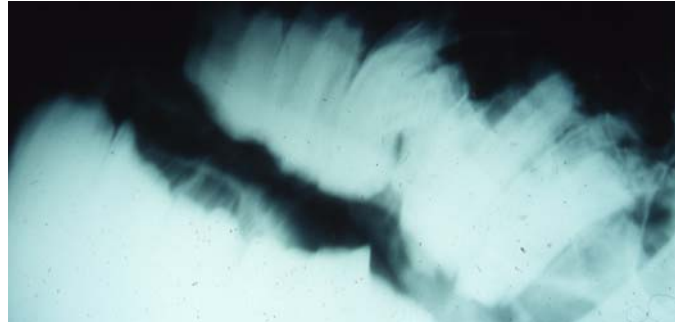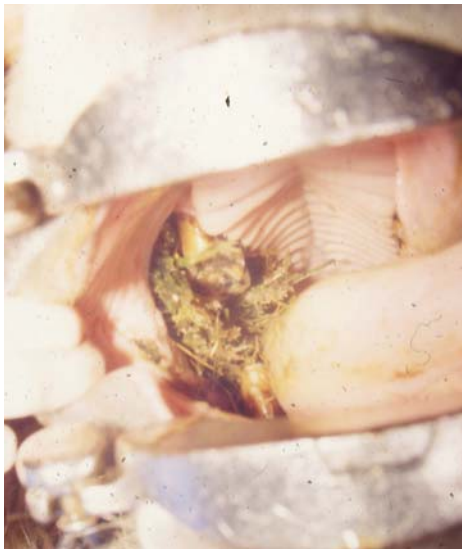**Figure 5.** A 17-year-old, Thoroughbred mare with a history of head tossing while eating. Oral examination revealed large, bilateral dental overgrowths (ramps) on the caudal aspect of 311 and 411 and smaller ramps on the rostral aspect of 306 and 406. Examination of an open-mouth, lateral radiograph revealed the abnormal dental wear pattern. Each upper arcades contained only 5 cheek teeth. Bilateral oligodontia produced characteristic overgrowths on the rostral and caudal aspects of the opposing arcades.

tooth can lead to dental elongations and abnormal mastication (Fig. 5). Radiographic examination is often necessary to confirm a diagnosis of true oligodontia. Oligodontia may be associated with other epidermal defects such as poor development of hair and hooves.

### **Dental Dysplasia**

Dental dysplasia (i.e., abnormal growth and/or development of a tooth) may result in an irregularly shaped tooth that does not fit well into a dental row. The poor fit may lead to food “pocketing” and periodontal disease (Figs. 6 and 7). Enamel hypoplasia has been associated with certain drugs or chemicals administered to the dam during gestation or it may be idiopathic in origin. Abnormal enamel morphology has been observed with branched pulp horns or abnormally shaped teeth. Enamel acts as the scaffolding and template for deposition of dentin and cementum. These tissues follow the abnormal enamel pattern and consequently all three calcified tissues are dysplastic. Dental dysplasia can involve the abnormal formation of the entire tooth structure or only a single tissue type.

Dental dysplasia and oligodontia were reported in a Thoroughbred colt that was monitored from birth to 28 months of age. Serial radiographic examinations revealed the absence of several deciduous and permanent teeth as well as abnormally shaped and positioned teeth in the molar arcades. Cemental hypoplasia usually involves the infundibular portion of the tooth but can be seen as a defect of the peripheral, coronal or reserve crown or root cement.




**Figure 6.** A 14-year-old, Appaloosa mare with a history of dysmastication. Oral examination revealed an abnormal dental wear pattern on the right dental arcade (i.e., wave mouth). A shallow periodontal pocket with feed packing was present between 108 and 110. A small, smooth occlusal surface was observed on 109. Examination of an open-mouth, lateral radiograph demonstrated the dental occlusal wear abnormalities. A dysplastic vertically impacted 109 was present. The other teeth in the right upper arcade had drifted interproximally to close the 109 space.

### Abnormal Dental Eruption

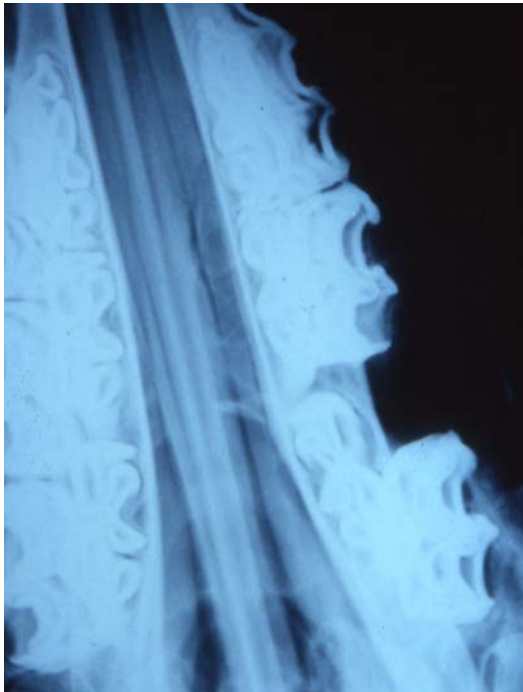
Abnormal dental eruption, or maleruption, is often seen following trauma to developing teeth or surrounding bones but has also been reported to be congenital or idiopathic in origin. Cheek teeth can become vertically impacted when dental buds are developing in abnormal or crowded areas in the dental arcades. Teeth may become rotated or otherwise displaced due to developmental malpositioning of tooth buds or overcrowding before, during or after eruption.

Dixon, et al reported that 70% of cheek tooth displacements were developmental in origin due to overcrowding of the cheek tooth row at the time of eruption. This research team frequently found that if a cheek tooth was displaced in one arcade, the same tooth in the contralateral arcade was also displaced. The remaining 30% of displacements were felt to be due to abnormal tooth positioning which may result in non-eruption of the displaced teeth if they are sufficiently horizontal to the adjacent teeth.



**Figure 7.** A 22-month-old, Thoroughbred colt with a slowly developing firm lump on the left mandible. Oral examination revealed normal dentition for a colt of this age. A lateral radiograph demonstrated a rostro-laterally displaced dysplastic dental bud of the 2<sup>nd</sup> lower cheek tooth (307). The deciduous tooth (707) was in its normal position. This tooth bud was surgically removed leaving the deciduous tooth in place. A one year follow-up revealed that the horse was in race training and that the teeth were normal in appearance. The deciduous 3<sup>rd</sup> premolar (707) was still in place even though the other 07 caps had shed normally.





**Figure 8.** A 6-month-old, Quarterhorse colt with a presenting complaint of packing hay in the right cheek. Oral examination revealed a 1 cm wide diastema between 507 and 508. DV radiographs of the head revealed a distally displaced and buccally rotated deciduous right upper 4<sup>th</sup> premolar (508). This horse was lost to follow-up.

Developmental diastemata are often due to insufficient angulation of teeth to achieve good compression between adjacent teeth. Another cause for diastemata is embryonic teeth developing too far apart (Fig 8).

### **Conclusion**

Equine dental developmental abnormalities can involve tooth number, morphology or position in the dental arcades. The horse has vertically successional teeth and developmental defects can involve either deciduous or permanent dentition. The horse has hypsodont teeth which erupt continuously throughout the horse's life. Some developmental abnormalities of the teeth of a very young horse may not cause the horse to exhibit clinical signs until the horse reaches middle age. For example, a horse with a developmental dental abnormality often develops periodontal pockets, abnormal wear patterns and other signs associated with these abnormalities as the horse ages.

A detailed oral examination should include checking teeth for proper number and position. Only the exposed crown of the equine tooth can be visualized in the oral cavity. Therefore, because many developmental defects may not be recognized simply by oral examination, the dentition should be examined radiographically to further delineate abnormalities.

Congenital dentofacial deformities that lead to dental malocclusions such as mandibular brachygnathia (parrot mouth), prognathia (sow mouth), and campylorrhinus lateralis (wry nose) are also developmental abnormalities but are reserved for another discussion.

## References

Dixon PM, et al. Equine Dental Disease Part 2: A long-term study of 400 cases: Disorders of development and eruption and variations in position of the cheek teeth. *Equine Vet J*, 1999; 31:519-528.

Dixon PM, Easley KJ, Ekmann A. Supernumerary teeth in the horse. *Clinical techniques in equine practice*, 2005; 4:155-161.

Quinn GC, Tremaine WH, Lane JG. Supernumerary cheek teeth (N=24): clinical features, diagnosis and outcome in 15 horses. *Equine Vet J*, 2005, 37(6): 505-509.

Baker GJ. Abnormalities of development and eruption. In: Baker GJ and Easley J, ed. *Equine dentistry*, 2<sup>nd</sup> ed., London: Elsevier Saunders, 2005; 69-77.

Dacre IT. Equine dental pathology. In: Baker GJ and Easley J, ed., *Equine dentistry*, 2<sup>nd</sup> ed, London: Elsevier Saunders, 2005; 91-109.

Wintzer HJ. *Equine Diseases, a textbook for students and practitioners*. New York: Springer Verlag, 1986;90-91.

Dixon PM, et al. Equine dental disease, part I: a long term study of 400 cases: disorders of incisor, canine and first premolar teeth. *Equine Vet J*, 1999; 31:369-377.

Ramzan PHL, Dixon PM, Kempson SA, et al. Dental dysplasia and oligodontia in a thoroughbred colt. *Equine Vet J*, 2001; 33:99-104.

De Bowes RM, Gaughan EM. Congenital Dental Diseases of Horses. In: Gaughan EM and De Bowes RM, ed. *Vet Clin North Am Equine Pract*, Vol 14, No 2, Philadelphia: W.B. Saunders, 1998; 273-289.