

Skin/Wound Referral Resource

This resource was designed by the University of Michigan Health System Multidisciplinary Pressure Ulcer Prevention Committee for nursing and physician use. This document's main purpose is to serve as a reference to assist caregivers in identifying which service(s) to consult based on wound/skin disorder type.

- Consults to the Wound/Ostomy Team can be generated by nursing and/or physician staff using CareLink.
- Consults to these services must be generated by a physician:
 - Physical Therapy Wound Care
 - Dermatology
 - Rheumatology
 - Plastic Surgery
 - General Surgery
 - Vascular Surgery
 - Trauma/Burn Surgery

If you have questions or need clarification after reviewing this document, please contact one of us:

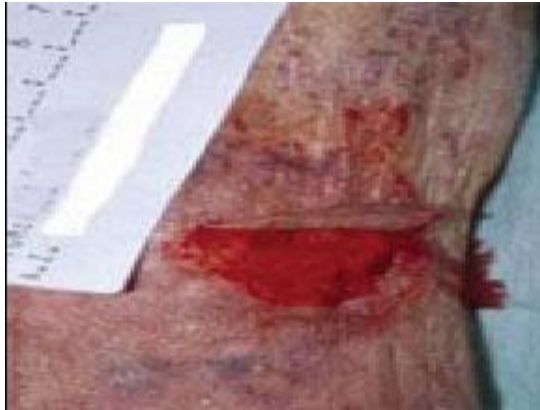Tracey A. Bruce, RN, BSN
Nursing Supervisor
Wound and Ostomy Team
(734) 936-2994
tbruce@umich.edu

Steven C. Haase, MD
Medical Director, Wound Care
(734) 615-3435
shaase@umich.edu

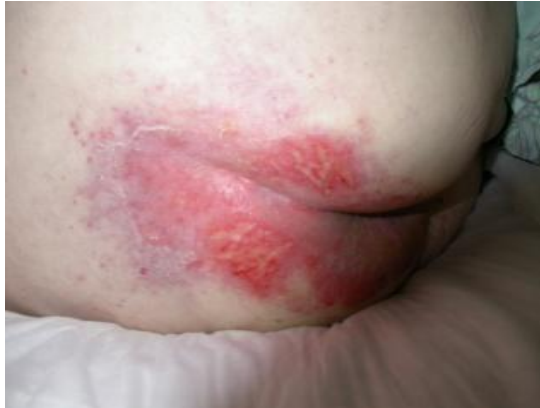References:

- Mosby's Medical Dictionary. Sixth Edition, Mosby, 2001.
- Habif, TA. Clinical Dermatology. Fifth Edition, Mosby, 2009.
- "Pressure Ulcer Stages Revised by NPUAP," (online resource: <http://www.npuap.org/pr2.htm>), NPUAP 2007. Accessed Nov 22, 2010.
- Bergquist-Beringer, S; Davidson, J. "NDNQI Pressure Ulcer Training Modules." (online resource: <https://www.nursingquality.org/NDNQIPRESSUREULCERTRAINING/>), National Database of Nursing Quality Indicators by the American Nurses Association, 2006-2010. Accessed Nov 22, 2010.
- "Types of Psoriasis" (online resource: <http://www.psoriasis.org/NetCommunity/Page.aspx?pid=386>), National Psoriasis Foundation, 2010. Accessed Nov 22, 2010.
- Mustafa, NM; Lavizzo, M. Sweet's syndrome in a patient with Crohn's disease: a case report. *Journal of Medical Case Reports*. 2008, **2**:221.

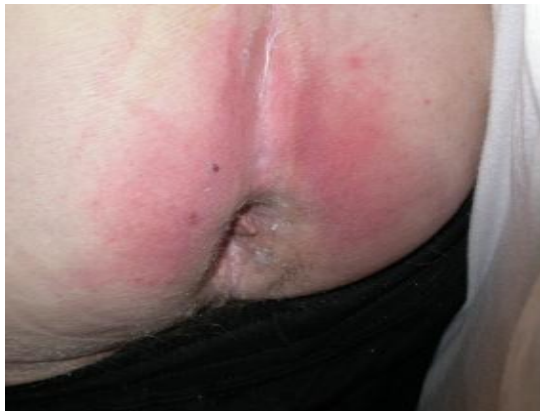Skin Tear: traumatic skin loss at the dermal/epidermal junction due to friction and/or shear; may occur when lifting or turning a patient, bumping into objects, or with the removal of tape or adhesive dressings.



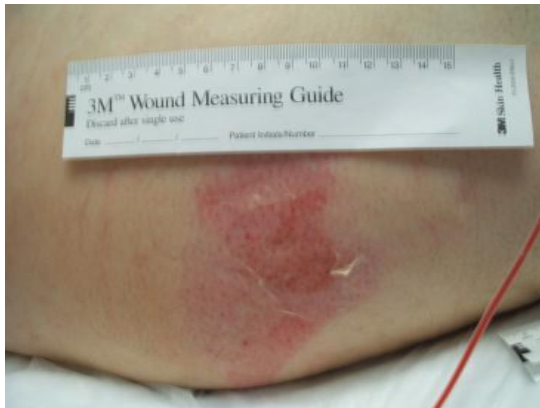
Incontinence-Associated Dermatitis: an inflammation of the skin that occurs when urine and/or stool comes into contact with perineal or peri-genital skin. The area may be red and/or denuded. It may be pruritic (itchy) and/or painful.



Stage I Pressure Ulcer: intact skin with non-blanchable redness of a localized area, usually over a bony prominence. Darkly pigmented skin may not have visible blanching; its color may differ from the surrounding skin.



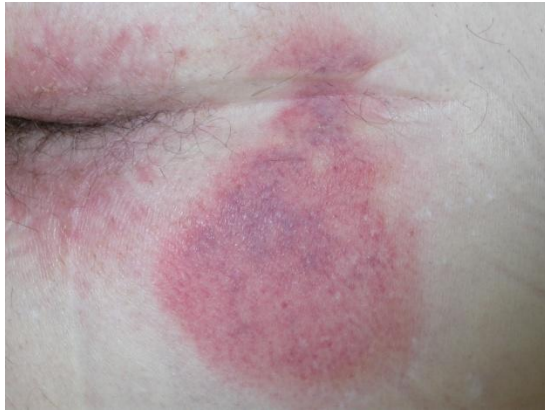
Stage II Pressure Ulcer: partial-thickness loss of skin presenting as a shallow open ulcer with a red/pink wound bed, without slough. May also present as an intact or open (ruptured) serum-filled blister.



Manage per Dressing Selection Guidelines
Consult Wound/Ostomy Team if concern arises

Suspected Deep Tissue Injury:

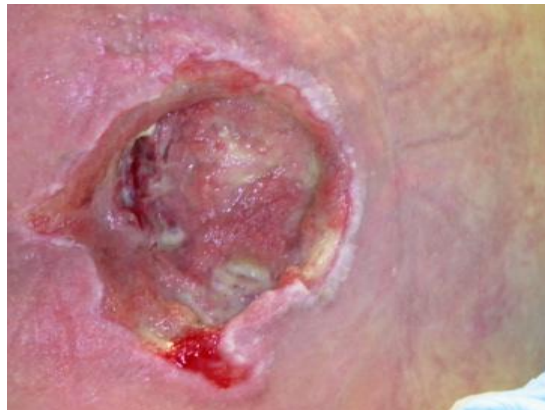
Injury: purple or maroon area of discolored intact skin or blood-filled blister due to damage of underlying soft tissue from pressure and/or shear. The area may be preceded by tissue that is painful, firm, mushy, boggy, warmer or cooler as compared to adjacent tissue.



Consult Wound/Ostomy Team

Stage III Pressure Ulcer:

full-thickness skin loss. Subcutaneous fat may be visible, but bone, tendon, or muscle are not exposed. Slough may be present, but does not obscure the depth of wound. These wounds may have undermining or tunneling.



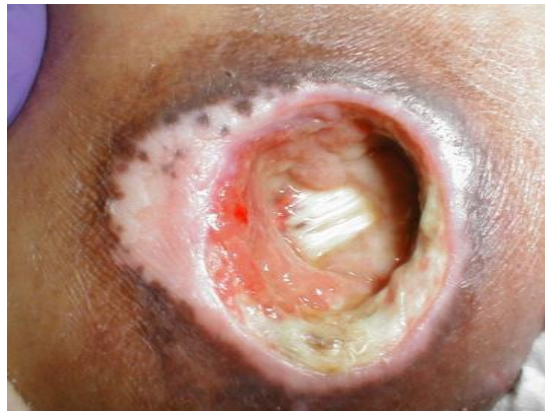Consult Wound/Ostomy Team*

*Wound/Ostomy Team will evaluate and may recommend one of the following consults be placed by the primary service:

- PT/Wound Care consult for minor debridement and pulse lavage, or...
- Plastic Surgery consult for surgical debridement

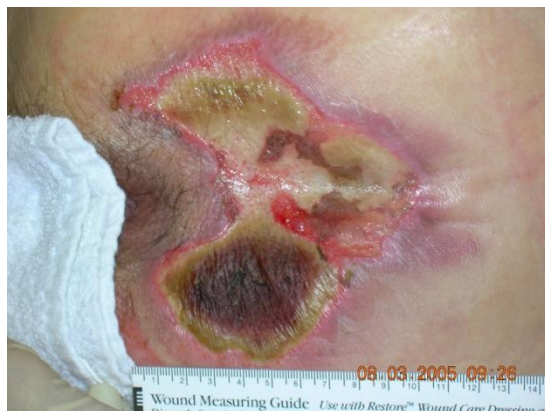Stage IV Pressure Ulcer:

full thickness tissue loss with exposed bone, tendon, and/or muscle. Slough or eschar may be present on some parts of the wound bed. These wounds often include undermining and tunneling.




Unstageable Pressure Ulcer:

full thickness tissue loss in which the base of the ulcer is covered by slough (yellow, tan, gray, green, or brown) and/or eschar (tan, brown, or black). The ulcer stage cannot be determined until this tissue is removed.



Dermatologic Lesions:

This category includes superficial skin lesions, rashes, and a few unusual wounds that are best treated by Dermatology. Their service will often perform a biopsy to confirm the diagnosis.



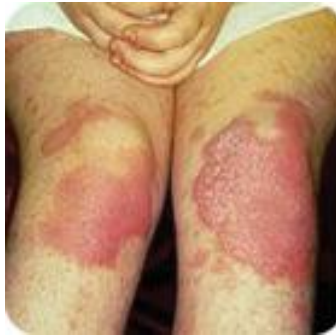Consult Dermatology

(This consult must be placed by a physician.)

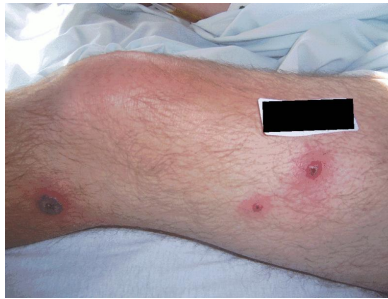Skin Rashes

Skin Lesions (Nevi, Moles, Keratoses, Warts)

Psoriasis: A common chronic skin condition characterized by circumscribed red patches covered by thick, dry silvery adherent scales that are the result of excessive development of epithelial cells. (photo: www.psoriasis.org)

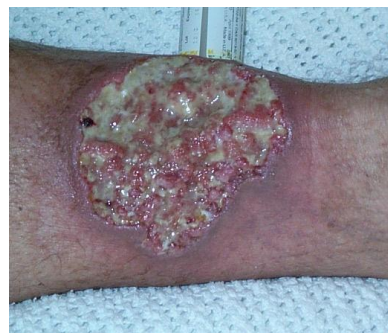

Sweet's Syndrome: A condition usually seen on the upper body of middle-aged women, characterized by one or more large, rapidly extending, erythematous, tender or painful plaques, accompanied by fever and dense infiltration of neutrophils in the upper and middle dermis. (photo: Mustafa, *Journal of Medical Case Reports*, 2008)



Pemphigus: An uncommon, severe disease of the skin and mucous membranes, characterized by thin-walled bullae arising from apparently normal skin or mucous membrane.

Pyoderma Gangrenosum: A rapidly evolving, idiopathic, chronic debilitating skin disease that usually accompanies a systemic disease, especially chronic ulcerative colitis, and is characterized by irregular, boggy, blue-red ulcers with undermined borders surrounding purulent necrotic bases. This lesion can worsen with surgical debridement and is often treated instead with systemic and/or topical immunosuppressants. (photo: public domain)



Deep Abscesses: A cavity containing pus and surrounded by inflamed tissue; often detected on CT or MRI; may require drainage by surgery or interventional radiology

Necrotizing Fasciitis: An infection of the subcutaneous tissue that results in the destruction of fascia and fat; often spreads rapidly along the deep fascia; typically treated as a surgical emergency

Fournier's Gangrene: An infective gangrene of the scrotum or vulva caused by an anaerobic hemolytic strain of streptococcus.

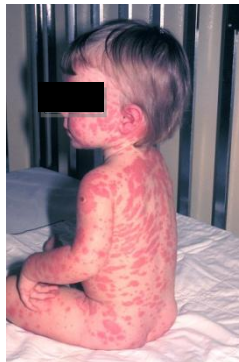Consult General Surgery

(This consult must be placed by a physician.)

Burns: An injury to the tissues of the body caused by hot objects or flames, electricity, chemicals, radiation or gases; depth of burn determines need for surgical intervention; often require intensive wound care

Large Desquamating Wounds:

- **Stevens Johnson Syndrome:** A serious, sometimes fatal, inflammatory disease affecting children and young adults. It is characterized by the acute onset of fever, bullae on the skin, and ulcers on the mucous membranes of the lips, eyes, mouth, nasal passage, and genitalia. (photo: public domain)



- **Toxic Epidermal Necrolysis:** A rare skin disease characterized by epidermal erythema, superficial necrosis, and skin erosions.

Consult Trauma/Burn

(This consult must be placed by a physician.)

Wounds Due to Autoimmune Disorders:

- **Vasculitis:** Inflammation of the blood vessels; may be caused by a systemic disease or an allergic reaction. Some vasculitic disease involves only the skin, while others may involve vessels in different organs.
- **Systemic Lupus Erythematosus:** A chronic inflammatory disease affecting many systems of the body. May present with skin rash or lesions; often a "butterfly rash" over nose and malar eminences is noted.
- **Scleroderma:** Chronic hardening and thickening of the skin caused by new collagen formation, with atrophy of pilosebaceous follicles.

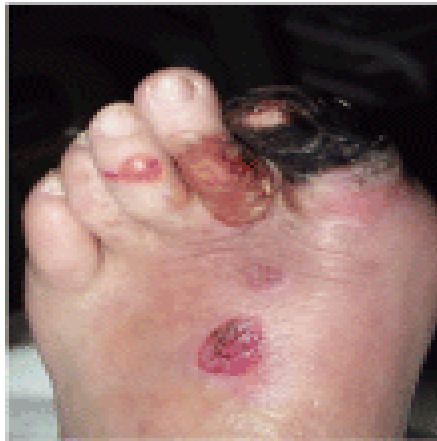Consult Rheumatology

(This consult must be placed by a physician.)

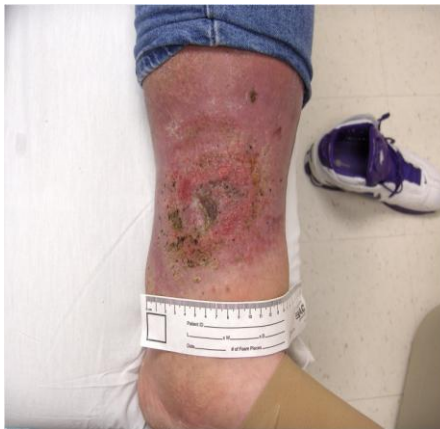Wounds Due to Arterial or Venous Disease

Examples include:

- **Pulseless extremities**
- **Arterial Ulcers:** Wounds caused by impaired arterial blood flow, usually to the lower leg and foot, which leads to tissue ischemia, necrosis and loss.
Ulcer characteristics include:
 - Well-defined margins or “punched out” appearance
 - Minimal exudateLegs with ischemic disease may have:
 - Cool skin
 - Shiny skin
 - Decreased or absent pulses
 - Abnormal vascular studies
 - Pain



- **Venous Ulcers:** Wounds caused by a decrease in blood flow return from the lower extremities to the heart; the underlying cause is usually damaged or incompetent veins. Venous wounds are usually located on the calf or ankle.
Ulcer characteristics include:
 - Irregular margins
 - Shallow depth
 - Minimal pain
 - Moderate to heavy drainageLegs with venous disease may have:
 - Brownish discoloration of lower legs
 - Edema
 - Dry skin



Consult Vascular Surgery

(This consult must be placed by a physician.)