

# Abdominal x rays made easy: calcification

Ian Bickle and Barry Kelly return after a month off with the fourth part in their series on reading plain abdominal x ray films

As outlined earlier in the series a small number of densities may be seen on plain radiographs. The most radio-opaque (brightest) of any natural substance is calcium, which appears white. The reason calcium shows the greatest radio-opacity is that it "obstructs" x rays more than any other natural substance. Consequently, fewer of those x rays reach the x ray plate, and the film appears white.

Iatrogenic or artefactual metallic objects appear even brighter white (this will be discussed in the final part of this series). The vast majority of calcium is contained in the bones—a normal, expected location (bony abnormalities will be covered in the next part of this series).

The incidence of physiological calcification of normal anatomical structures increases with age and reflects that calcium is deposited over time.

Calcium can be seen in normal and abnormal structures. Abnormal calcification in some cases merely indicates underlying pathology whereas in others the calcification is the pathology.

## Box 1: Normal structures that calcify

- Costal cartilage
- Mesenteric lymph nodes
- Pelvic vein clots (phlebolith)
- Prostate gland

## Calcification of normal structures (box 1)

Evaluation of the abdominal radiograph might start at the top, working down the film. The film should include the lower anterior ribs. As you will recall, towards the midline anteriorly, a rib changes from bone to cartilage and is termed costal cartilage. The cartilage of ribs one to seven articulates with the sternum whereas ribs eight to 10 indirectly connect to the sternum by three costal cartilages, each of which is connected to the one immediately adjacent to it (ribs 11 and 12 are floating). This cartilage can calcify, which is termed costocalcinosis. Although appearing strikingly abnormal, it is harmless and usually age related (fig 1).

Further down, mesenteric lymph nodes may calcify and appear as oval, smooth, outlined structures (fig 2). These can be confused with small kidney stones, especially in a patient without previous films who presents with abdominal pain. Are such incidental harmless calcified nodes

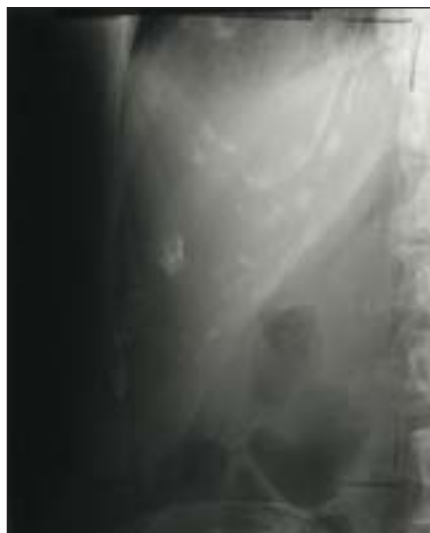

Fig 1

responsible for the pain or are renal calculi. This diagnostic dilemma may be solved by the exact location. If due calcification is identified along the urinary pathway (typically along the line of the transverse processes of the vertebral bodies) an intravenous urogram to compare against a plain control film may be necessary for a decisive diagnosis. Alternatively, unenhanced computed tomography can be used. Also contained in the pelvis is the pelvic phlebolith, seen as a small, smooth, round, white opacity. Phleboliths are small areas of calcification in a vein. They may be difficult to differentiate from small kidney stones.

The final calcification in this section is found only in men. This is calcium that collects in the ageing prostate gland and is therefore observed low down in the pelvic brim. Prostate calcification may also occur in cancerous tissue.

## Calcification indicating pathology (box 2)

### Pancreas

The pancreas lies at the level of T9-T12 vertebrae. Calcification of the pancreas is usually found in chronic pancreatitis, although there are some rarer causes. If calcification is extensive, the full outline of the pancreas may be observed, mostly on the left side, but may cross over the midline. This "speckled" calcification occurs on the network of ducts within the pancreatic tissue where most of the calcium is deposited (fig 3).

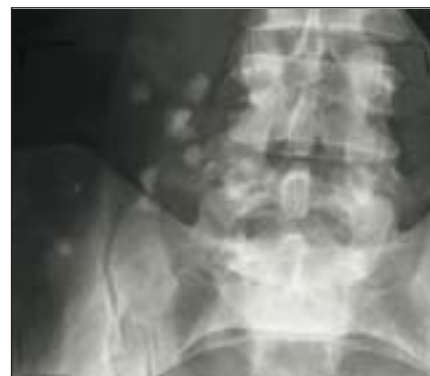

Fig 2

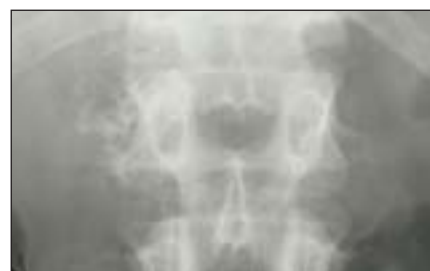

Fig 3

## Box 2: Abnormal structures that contain calcium

### Calcium indicates pathology

- Pancreas
- Renal parenchymal tissue
- Blood vessels and vascular aneurysms
- Gallbladder fibroids (leiomyoma)

### Calcium is pathology

- Biliary calculi
- Renal calculi
- Appendicolith
- Bladder calculi
- Teratoma

### Renal calcification

Between the T12-L2 vertebral region, nephrocalcinosis may be identified. This is calcification of the renal parenchymal tissue (fig 4). This is indicative of renal pathology, which includes hyperparathyroidism, renal tubular acidosis, and medullary sponge kidney.

### Vascular calcification

Perhaps the most striking calcification is in the blood vessels, most notably the arteries. The whole vessel(s) may be exquisitely

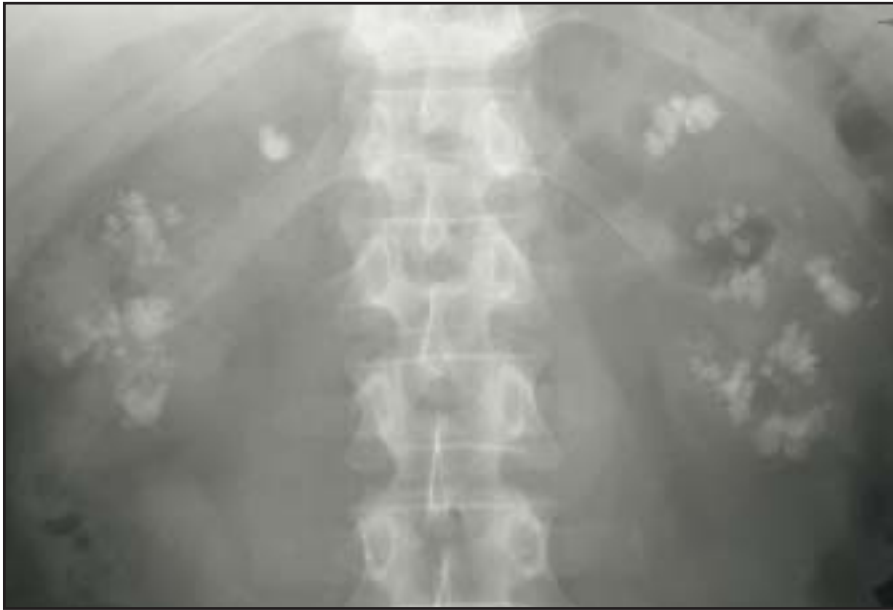

Fig 4

outlined by calcium (fig 5). A great deal of calcification may be indicative of a widespread atheromatous process within the arteries, especially in diabetes.

In the infrarenal arterial region, below the second lumbar vertebrae, abdominal aortic aneurysms are typically located. Over time, as the atheromatous material is laid down in the lumen, calcium may be deposited. This may appear on an abdominal radiograph, and can be identified, often incidentally, by giving a rough indication of the internal diameter. An abdominal ultrasound scan should immediately follow for accurate assessment, and to determine the timing of surgery or observational follow up.

#### **Gynaecological calcification**

The final structure in this section is found only in women—fibroids. These can become calcified and appear as rounded structures of varying size and location in the pelvis (fig 6).

#### **Pathological calcification**

The final section on calcification on abdominal x ray film refers to pathological calcification. This almost exclusively manifests as calculi in various locations. Calculi may be asymptomatic.

#### **Biliary calculi**

Biliary calculi are commonly referred to as gallstones. Plain abdominal x ray film in itself is poor at identifying these calculi and detects only 10-20%. Ultrasound is the gold standard for first line imaging. A plain abdominal radiograph is often the initial investigation in patients with abdominal pain and may identify these

laminated, faceted, often multiple, radiopacities in the right upper quadrant of the radiograph (fig 7). Very rarely a large calculus may erode into the gallbladder wall, creating a fistula to the adjacent small bowel. This calculus may then pass along the intestinal tract until it cannot travel any further, usually in the distal ileum a little proximal to the ileocaecal valve, and cause an obstruction of the

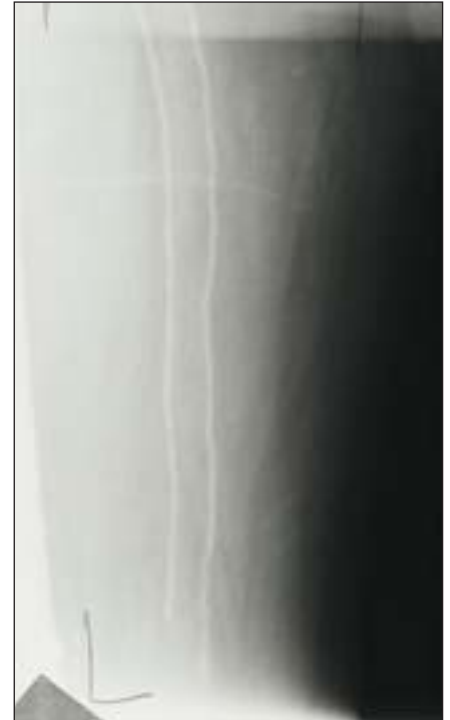

Fig 5

small bowel (see part 2 of this series). Gas may also be seen in the biliary tree on the abdominal radiograph (see part 3 of this series). This phenomenon is termed a gallstone ileus. In the right upper quadrant the wall of the gallbladder itself may

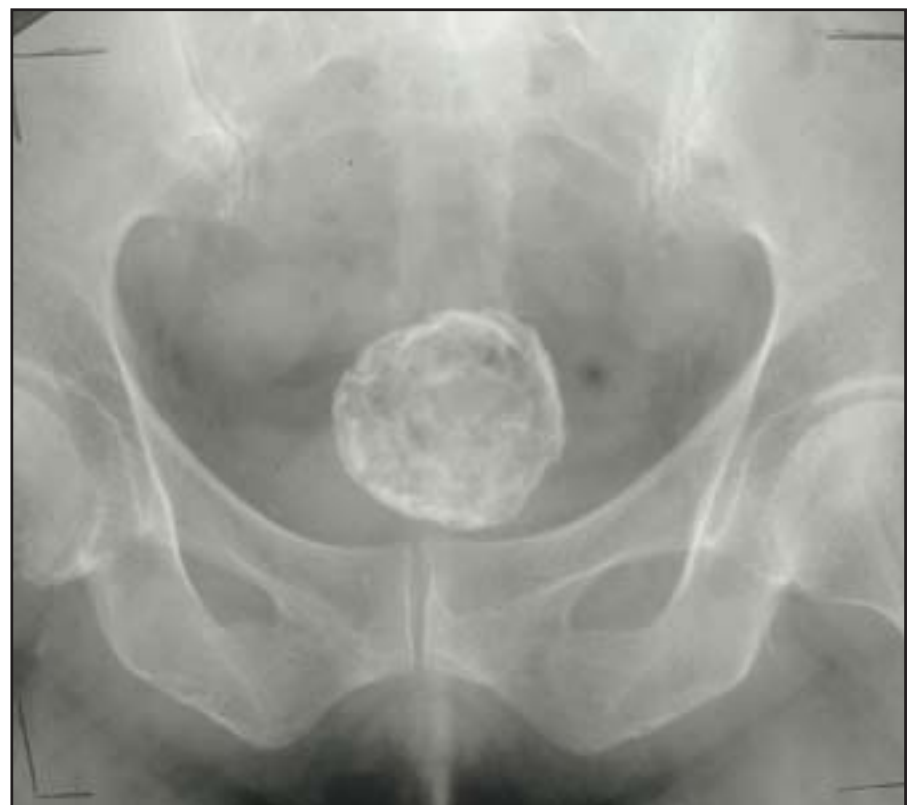

Fig 6

become calcified after repeat incidences of cholecystitis—this is termed a porcelain gallbladder (fig 8). A significant relation (20%) exists between this and the development of gallbladder malignancy.

### Renal calculi

These are much more commonly identified on the abdominal radiograph; up to 80% are visible. The variable detection is a

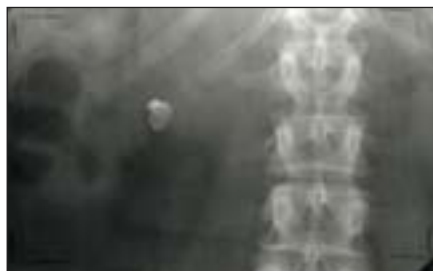

Fig 7

result of the different degree of radio-opacity, which, in turn, is dependent on the composition of the calculus. Renal calculi may also vary greatly in size, the largest being a “staghorn” calculus. They are, however, usually smaller but found on the well defined pathway of the urinary tract and seen by looking down the transverse processes of the vertebrae, across the sacroiliac joint to the level of the

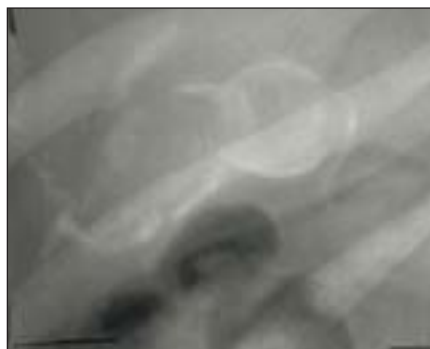


Fig 8

ischial spine. It is also worth noting that calculi tend to obstruct at some favoured locations, which include the pelviureteric, brim of the pelvis, and vesicoureteric junctions.

### Appendix and bladder

In the region of the right iliac fossa, a small calcified, round radio-opacity may well be an appendicolith. These are seen in 15% of appendicitis. In the pelvic region of the abdominal x ray film bladder calculi may be seen, but less commonly than biliary or renal calculi. Bladder stones are usually quite large and often multiple. Calcification of a bladder tumour may also occur.

A final mention goes to the teratoma, a

type of tumour derived from the primitive germ cell lines, which occurs in the ovaries and testes. In some instances teeth may develop from the ectoderm layer; as they are highly calcified they will appear on the radiograph and are easily identified as they look tooth shaped (fig 9).

The next part of this series looks at bones and soft tissue findings on abdominal x ray films.

**Ian C Bickle** final year medical student, Queen's University, Belfast  
 medicine@totalise.co.uk

**Barry Kelly** consultant radiologist, Royal Victoria Hospital, Belfast

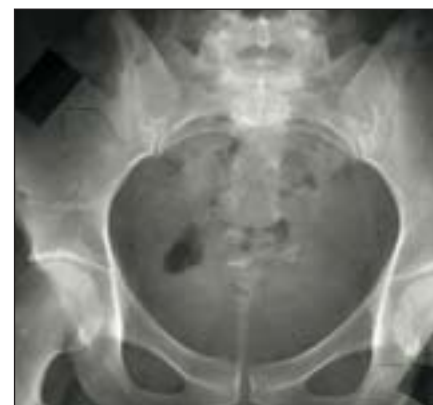

Fig 9

## Neurodegenerative terms

***β-Amyloid:*** β-Amyloid protein causes problems only when it is converted from its normal soluble form to insoluble β-pleated sheets, which accumulate into neurotoxic amyloid plaques. In its healthy role it is probably involved in stabilising cell walls.

***Prions:*** These are proteins produced by the prion gene and probably have a role in maintaining the electrical activity of cells. In Creutzfeldt-Jakob disease, the normal soluble form changes its configuration by folding up differently, allowing it to form insoluble β-pleated sheet structures. The protein forms prion plaques that are neurotoxic. The pathological changes are transmissible.

***α-Synuclein:*** This protein is found in Parkinson's disease and dementia with Lewy bodies. Its role in the normal state is unclear. In pathological states this protein forms intraneuronal inclusions (Lewy bodies).

***Tau:*** This protein is found in the microtubules of nerve cells, and its role is to help stabilise them. The role of microtubules is to transport cellular components. In Alzheimer's disease, tau protein becomes hyperphosphorylated and then accumulates into neurofibrillary tangles that disrupt the microtubules. In frontal lobe dementias the balance of different forms of tau protein change, interfering with transportation in the cells.

***Parkin:*** A second protein found in Lewy bodies and implicated in Parkinson's disease.

***Ubiquitin:*** Ubiquitin is associated with proteins that are about to break down. Their usual function is probably to protect proteins. In many dementias an accumulation of ubiquitinated proteins is found—for example, in Lewy bodies.

***Glutamine repeats:*** These are additional repeats of the amino acid glutamine, which when joined to proteins, increase the risk of soluble proteins folding into insoluble β-pleated sheets. They are commonly found on huntingtin, the abnormal protein found in Huntington's disease.

***Neuroserpinopathies:*** Neuroserpin is a protein that is precipitated out to form insoluble inclusions in nerve cells, eventually causing cell death. Familial encephalopathies with neuroserpin inclusion bodies are rare but have been identified in a small number of families.

***Superoxide dismutase 1:*** This is a natural human antioxidant enzyme that clears free radicals from the brain, maintaining the health of cell membranes.

*Abi Berger BMJ*