

## REVIEW

# Saline Contrast Echocardiography in the Era of Multimodality Imaging—Importance of “*Bubbling It Right*”

Saurabh K. Gupta, M.D., D.M., Sudhir S. Shetkar, M.D., D.M., Sivasubramanian Ramakrishnan, M.D., D.M., and Shyam S. Kothari, M.D., D.M.

Department of Cardiology, All India Institute of Medical Sciences, New Delhi, India

Saline contrast echocardiography is an established imaging modality. Logical interpretation of a carefully performed study is vital to realize its diagnostic potential. In this review, we discuss utility of saline contrast echocardiography in evaluation of various pathologies within and outside the heart other than a patent foramen ovale. (Echocardiography 2015;32:1707–1719)

**Key words:** saline contrast echocardiography, right-to-left shunt

## Introduction:

Saline contrast echocardiography (SCE) using agitated saline is an established, simple, inexpensive and yet surprisingly effective diagnostic tool that might help in solving a vexing diagnostic problem. Though the use of SCE is known since 1968,<sup>1</sup> this test is underutilized in clinical practice. Mapping the path of blood flow with the help of microbubbles provide diagnostic certainty that is useful even in the era of color flow mapping. Color flow mapping can sometimes be hampered by poor echogenicity and other technical factors whereas the SCE provides clearer information. This simple test might obviate the need of more expensive tests like magnetic resonance imaging (MRI) or computed tomography (CT) in some cases, or aid in their interpretation in the clinical context. SCE is well established for detection of patent foramen ovale (PFO). There has been a growing list of clinical entities that can be diagnosed with SCE provided it is performed and interpreted appropriately. In this article, we briefly review the utility of SCE in evaluation of various structural defects other than PFO, with clinical examples.

## Saline contrast echocardiography:

### Physiological basis:

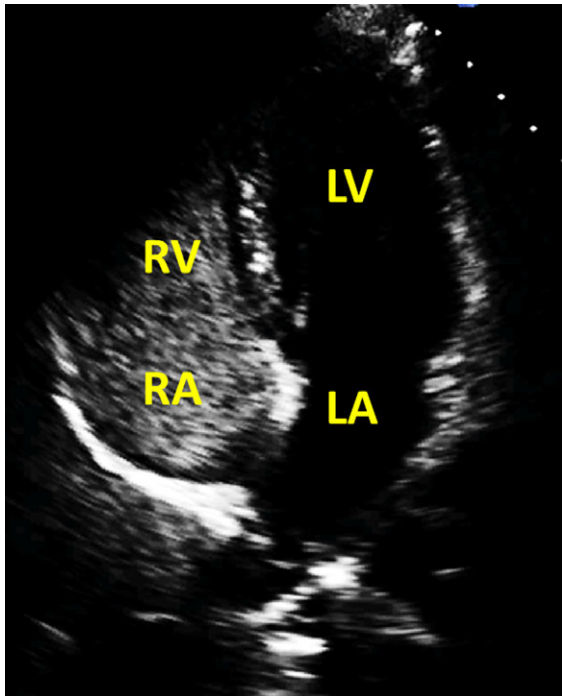
During echocardiography, blood appears black because sound scattered by red blood cells is

weak compared to the adjacent tissues at the usual frequencies employed. The reflection of ultrasound waves by gas filled microbubbles is much more compared to adjacent tissues. This difference in echogenicity between microbubbles and tissues enhances backscatter to produce a unique sonographic image with increased contrast.<sup>2,3</sup> The microbubbles produced by an injection of agitated saline are too large to cross pulmonary capillaries and therefore in the absence of a right-to-left shunt these remain confined to the right side of the heart. Such a study is labelled as “negative contrast echocardiogram” (Fig. 1 and movie clip S1). The appearance of these microbubbles in the left atrium (LA), left ventricle (LV) or aorta, commonly referred to as “positive contrast echocardiogram,” is diagnostic of a right-to-left shunt. Few bubbles in a healthy individual may appear due to physiologic intrapulmonary shunt especially in the phase of hypoxia. This intrapulmonary shunting resolves with the resolution of underlying illness or oxygen supplementation and does not warrant further evaluation particularly if not relevant clinically.<sup>4,5</sup>

### Preparation and injection of agitated saline:

A large bore intravenous cannula is placed in either of the arms. The selection of arm varies from laboratory to laboratory. Our own preference is to use left arm considering high incidence of persistent left superior vena cava (SVC) especially in structurally abnormal hearts. 5–10 mL of 0.9% saline is then mixed with 0.2–1 mL air and agitated using two 10 mL syringes connected through a three-way stopcock. This saline air mixture must be inspected carefully and any visible

Address for correspondence and reprint requests: Saurabh Kumar Gupta, M.D., D.M., Department of Cardiology, Room No. 23, 7<sup>th</sup> floor, Cardiothoracic Sciences Centre, All Institute of Medical Sciences, New Delhi, India – 110029. Fax: +91-11-26588663; E-mail: drsaurabhmd@gmail.com



**Figure 1.** Saline contrast echocardiogram with microbubbles confined to right side cardiac chambers, normal or negative contrast study. LA = left atrium; LV = left ventricle; RA = right atrium; RV = right ventricle.

bubble must be discarded before injection. The scattered echos emanating from this solution can be further improved by mixing small amount of patient's own blood albeit at an increased risk of contamination.<sup>6,7</sup> This agitated saline air mixture is then injected rapidly. The echocardiogram machine is set to record at least 20 cardiac cycles after starting the acquisition which must coincide with the injection of agitated saline. The recorded echo loops are then analyzed offline for the sequence of microbubbles appearance in various cardiac chambers. If the clinical suspicion is high the injections must be repeated using the same intravenous access as well as from the other hand and lower limb. Also, the injections may need to be repeated with imaging in different echocardiographic views.

#### Interpretation:

The return of bubble contrast into the left side is proportionate to the size of the right-to-left shunt. Based on the opacification, SCE can be graded as grade 0 – No bubbles; grade 1, occasional filling with <20 bubbles; grade 2, >20 bubbles but incomplete opacification; and grade 3, complete, intense opacification.<sup>8</sup> Higher is the grade of opacification higher is the specificity of

SCE especially while evaluating intrapulmonary shunts.<sup>8</sup>

#### Safety of saline contrast echocardiography in patients with right-to-left shunt:

Air embolism because of injection of agitated saline for SCE is very rare with reported incidence of 0.062% in a multicenter survey.<sup>9</sup> In a recent series, none of the 281 patients had any adverse event.<sup>10</sup> In another study of 132 patients of hereditary hemorrhagic telangiectasia with grade 3 shunt only 2% (three) patients had paresthesia and migraine while none of the patients with shunt less than grade 3 had any adverse event.<sup>7</sup> Further, these episodes are transient with no residual neurologic deficits making SCE a safe diagnostic tool.<sup>11–13</sup> In our own experience, we have not observed a serious neurological event during the study even in patients with significant right-to-left shunt in more than few 100 patients studied over the years.

#### Saline contrast echocardiography for structural abnormalities:

SCE for detection of PFO is well established. We present clinical scenarios showing the utility of SCE in evaluation of patients with suspected structural defects other than PFO.

#### Excluding right-to-left shunt as the cause of systemic desaturation:

Persistent cyanosis is almost always indicative of congenital heart disease (CHD). Rarely it occurs due to abnormal hemoglobin. A negative SCE study in such a situation excludes the right-to-left shunt as a cause of cyanosis.

A 14-year-old boy presented with mild cyanosis since early childhood. He did not have any other symptoms. The respiratory and cardiovascular examination was normal. Chest radiograph, electrocardiogram and echocardiogram also did not suggest any abnormality. SCE was then performed during which microbubbles remained confined to the right atrium (RA), right ventricle (RV) and pulmonary artery (PA) i.e., negative SCE (Fig. 1 and movie clip S1). Further evaluation confirmed the presence of Methemoglobinemia.

#### Detection of intracardiac shunt:

**Left-to-right shunt:** In the era of color Doppler imaging, left-to-right shunts are diagnosed with relative ease. Suboptimal echocardiography window may however make the detection difficult. In the absence of good subcostal window the identification of even large atrial septal defect (ASD) may not be easy. Apical four-chamber view may show false echo drop out and lead to

erroneous diagnosis of ASD. In addition, occasionally flow from coronary sinus (CS) or inferior vena cava (IVC) may be mistaken as an ASD. SCE in these situations can easily confirm the presence of ASD by demonstrating an area of bubble-free space (negative shadow) within the RA, close to the septum due to blood flowing left to right. This feature of SCE is rarely utilized but can be helpful. Similarly, left-to-right shunt in aortopulmonary window (APW) may be detected by negative shadow and might be helpful especially in patients with pulmonary arterial hypertension (PAH).

### Right-to-left shunt:

#### Anomalous drainage of systemic veins to the left atrium:

Anomalies of systemic venous connection are uncommon yet important cause of right-to-left shunt. In the most common type, left SVC is persistent and drains into LA either directly or through unroofed CS and is easily detectable with SCE with the injection made in the left arm.

**Persistent left SVC to LA direct or via deficient coronary sinus**—Persistent left SVC is seen in approximately 0.5% of population. In majority left SVC drains into RA through dilated CS. Left SVC sometimes drains anomalously to LA either directly or via completely deficient CS, better known as unroofed CS. Uncommonly there is incomplete deficiency in CS (partial unroofing of CS). Routine echocardiography can detect anomalous connection of left SVC to LA and unroofed CS. The diagnosis of partial unroofing of the CS however remains challenging. Persistent left SVC with unroofing of CS is more frequent in congenitally malformed hearts particularly with atrial isomerism and heterotaxy.

A 3-month-old infant was brought to the outpatient department with complain of mild cyanosis. The clinical examination was unremarkable except mildly reduced systemic saturation (SpO<sub>2</sub> 94%). The echocardiogram showed small ASD shunting left to right. Interestingly the CS was extremely floppy that protruded into the mitral valve during ventricular diastole although with no impairment of valve function (Fig. 2A). Left SVC was persistent which drained normally into the RA through CS. Although floppy wall of the CS aroused suspicion of unroofing it could not be demonstrated. SCE was then performed with the injection in the left arm vein during which the bubbles appeared first in the CS and then filled the RA (Fig. 2B and movie clip S2). More importantly, bubbles were seen entering in to the LV directly

from the CS confirming the diagnosis of partial unroofing (Fig. 2C and movie clip S2).

Even in the current era of multimodality imaging SCE was the best suited investigation for the present case. Thin and floppy wall of the CS would have made anatomical diagnosis with both CT as well as MRI difficult. Further, this right-to-left shunt might escape detection if SCE is performed only from the right arm.<sup>14</sup>

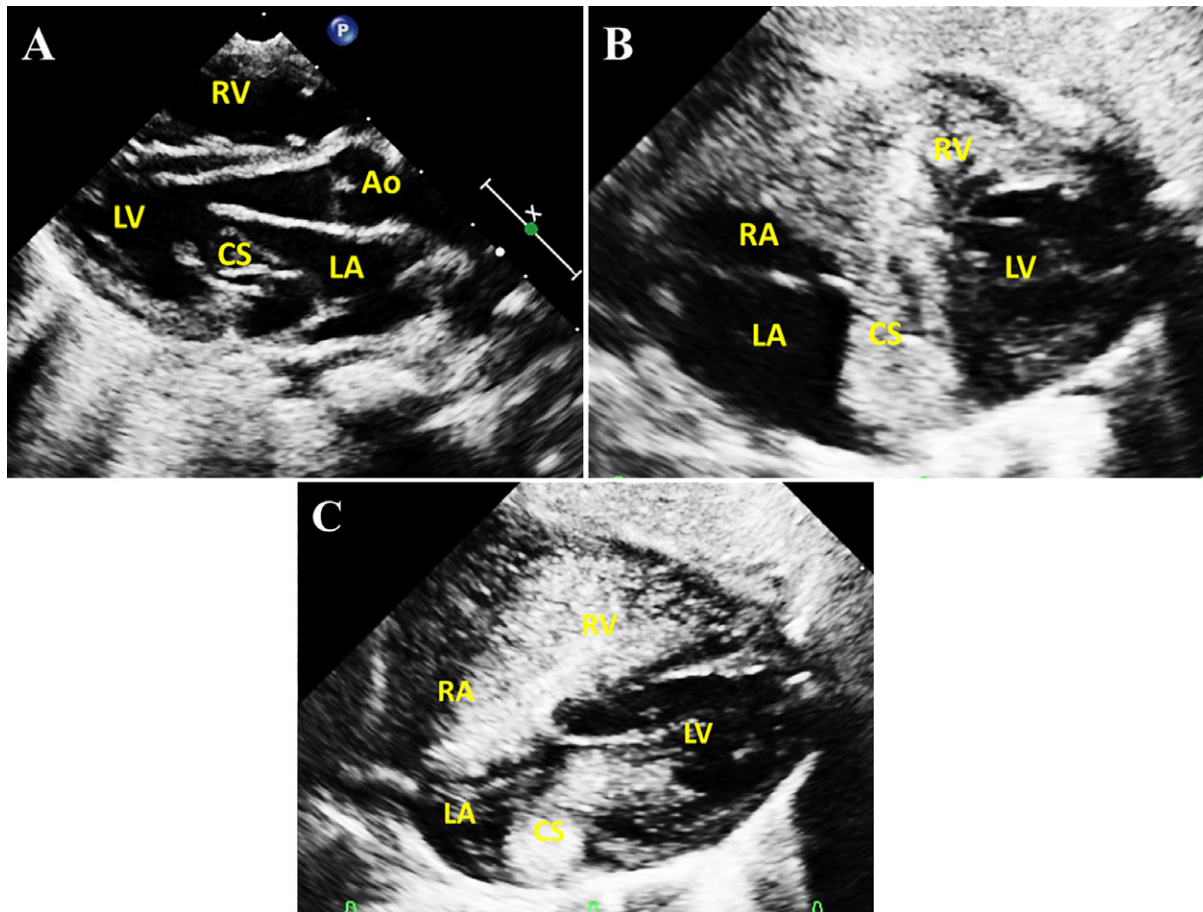
**Persistent left SVC to LA via left upper pulmonary vein**—Rarely left SVC is reported to drain into LA through left upper pulmonary vein (LUPV)<sup>15,16</sup> Unlike direct connection or connection via CS microbubbles in this situation enters LA through the pulmonary vein mimicking intrapulmonary shunt (see later). Had it been only right arm injection for SCE, the diagnosis of left SVC to LUPV shunt would have remained obscured.<sup>16</sup>

**Right SVC to LA**—In hearts with normal connections right sided SVC is dominant and connects to the RA. Rarely this right SVC connects anomalously to the LA. The cyanosis may be too subtle to be noticed and the echocardiogram in such a patient appears almost normal except for some dilatation of the LA and LV. Direct identification of the anomalous drainage is difficult especially if not looked for.

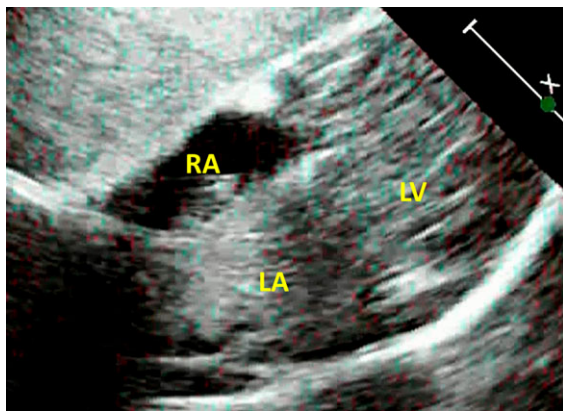
A 6-year-old girl presented with exertional dyspnea. Cardiovascular examination was normal but there was mild systemic desaturation (SpO<sub>2</sub> 90%). The echocardiogram did not show any intracardiac right-to-left shunt. There was no left SVC and a good sized connecting cava was present. There was suspicion of anomalous connection of right SVC to LA. The LV was dilated with normal contractility. SCE was then performed first from the left arm and then was repeated from the right forearm vein (Fig. 3 and movie clip S3). In both instances there was immediate and intense filling of the LA with some microbubbles appearing in RA via small ASD. The microbubbles were confined to the right side during SCE from lower limb vein confirming normal connection of IVC to RA.

Microbubbles appearing first in LA after left arm injection of agitated saline are mostly seen with left SVC to LA. In vast majority of hearts with situs solitus, right SVC is dominant and therefore with injection in the right arm, if the microbubbles appear first in LA it can only happen if the right SVC is anomalously connected to LA.<sup>17</sup> Rarely right SVC may show anomalous connection to LA while left SVC connects normally to RA through CS. In such a situation, SCE from the left arm alone is likely to miss the diagnosis of anomalous right SVC. SCE from right arm nonetheless demonstrates this beyond doubt (Fig. 4).<sup>18</sup>





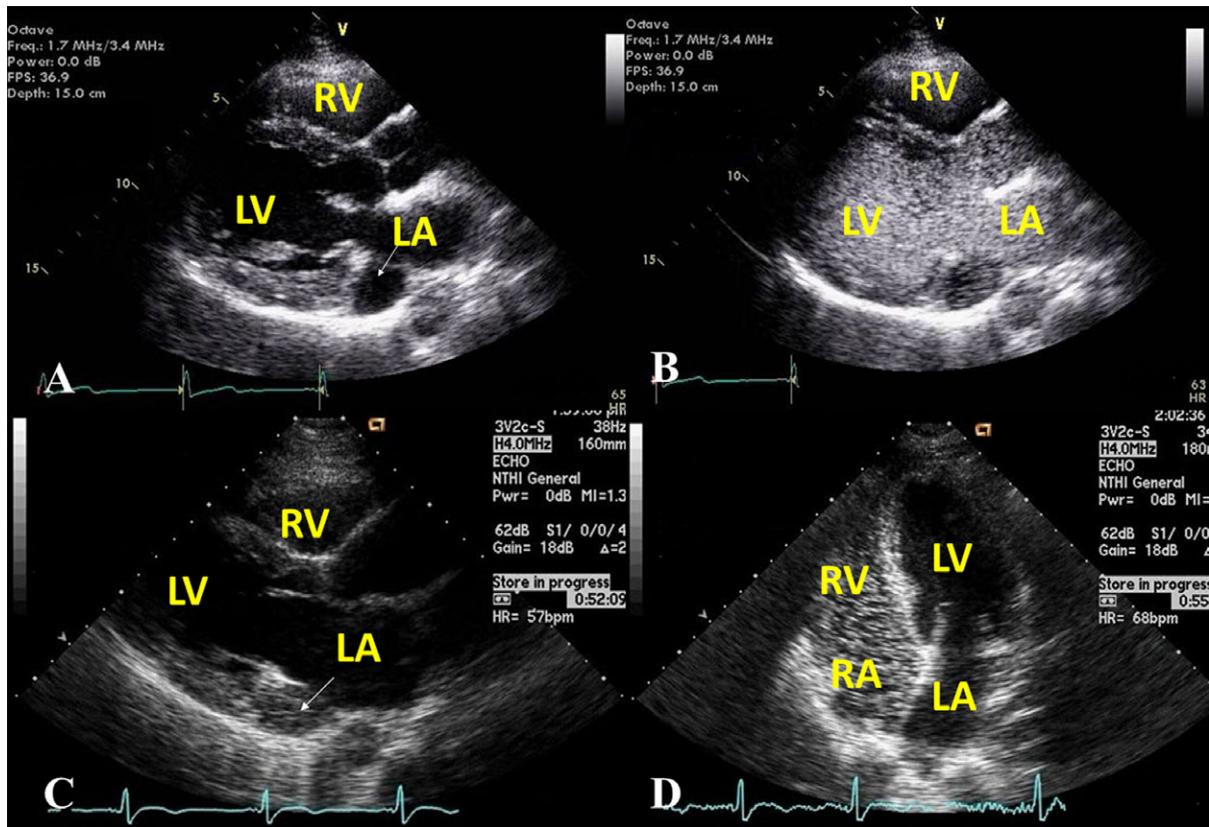
**Figure 2.** **A.** Transthoracic echocardiogram in parasternal long-axis view shows floppy coronary sinus (CS) protruding into the mitral valve during ventricular diastole. SCE performed with injection in the left arm and imaging from the subcostal approach shows **B.** intense filling of right atrium (RA) and right ventricle (RV) through persistent left SVC and dilated CS with **C.** simultaneous but brief filling of left ventricle (LV) from the partially unroofed CS (**C**). Ao = aorta; LV = left ventricle.



**Figure 3.** SCE with imaging from subcostal approach with the injections in the right as well as left arm resulting in intense filling of LA and LV. Microbubbles during injection from the lower limb remained confined to RA and RV confirming normal connection of IVC to RA (not shown here). Published with permission from Shetkar et al.<sup>17</sup>

**Anomalous connection or drainage of IVC to LA**—Congenital anomalous connection of IVC to LA is rare but well described entity. Rarely IVC is inadvertently routed to LA during surgical closure of ASD. Similar situation of IVC draining into LA might arise in an occasional patient of ASD with prominent eustachian valve allowing preferential streaming.

A 35-year-old male presented with cyanosis, dyspnea on exertion and history of right sided hemiparesis and aphasia that recovered partially. He had undergone surgical closure of ASD at the age of 4 years following which he was apparently well. Gradually worsening cyanosis was never investigated until recent cerebrovascular event. The investigations showed a high hemoglobin level of 20 gm/dL for which several hematological investigations were done. Transthoracic echocardiogram was adjudged as normal. In view of the high clinical suspicion transesophageal echocardiogram (TEE) was performed and SCE was done from the femoral vein which unequivocally



**Figure 4.** SCE performed from left arm **A, B**, shows intense filling of coronary sinus (CS), right atrium (RA) and right ventricle (RV). Saline injection from right arm **C, D**, resulted in immediate and intense opacification of left atrium (LA) and left ventricle (LV) with no bubbles appearing in CS. Adapted with permission from Sadek et al.<sup>18</sup>

cally showed IVC directed to the LA (Fig. 5 and movie clip S4), a known complication of ASD surgical closure when the eustachian valve is mistaken for the septum. There was late filling of RA through a small residual ASD. Injection from the right arm was normal.<sup>19</sup>

**Congenital total anomalous systemic venous drainage**—Total anomalous systemic venous connection (TASVC) is yet another rare situation with all systemic veins i.e., SVC, IVC and CS connected to LA. Complete venous return fails to get oxygenated and systemic oxygen saturation as well as the survival depends upon the right-to-left shunt across ASD.

An 11-year-old girl presented with severe cyanosis (SpO<sub>2</sub> 55%) and extreme limitation of activities. There was no obvious right-to-left shunt. Atrial septum was thin at fossa ovalis region but no definite ASD was visualized. The drainage of pulmonary veins was normal. Anomalous connection of both SVC and IVC, i.e. TASVC was suspected in view of hypoplasia of tricuspid valve, RA and RV. Subsequently performed SCE confirmed the diagnosis when microbubble opacified the LA densely after injections from the arm

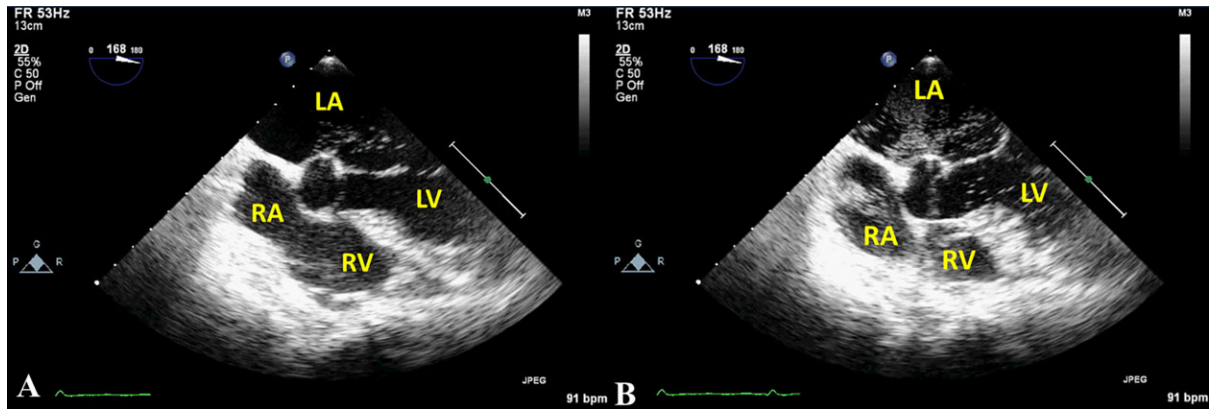
as well as the lower limb (Fig. 6A and movie clip S5). This was followed by microbubbles filling the RA via ASD (B).

The diagnosis in all these cases was possible only because of clinical suspicion and selection of appropriate venous approach for SCE. The diagnosis could remain obscured if the injection is not made in the left arm in case with partial unroofing of CS<sup>14</sup> and left SVC to LUPV connection,<sup>16</sup> in the right arm in case of normally draining left SVC but anomalously draining right SVC<sup>18</sup> and in lower limb vein in case with IVC to LA connection.<sup>19</sup> Thus it is important to select vascular access for SCE based on clinical requirement and not by the ease of cannulation.

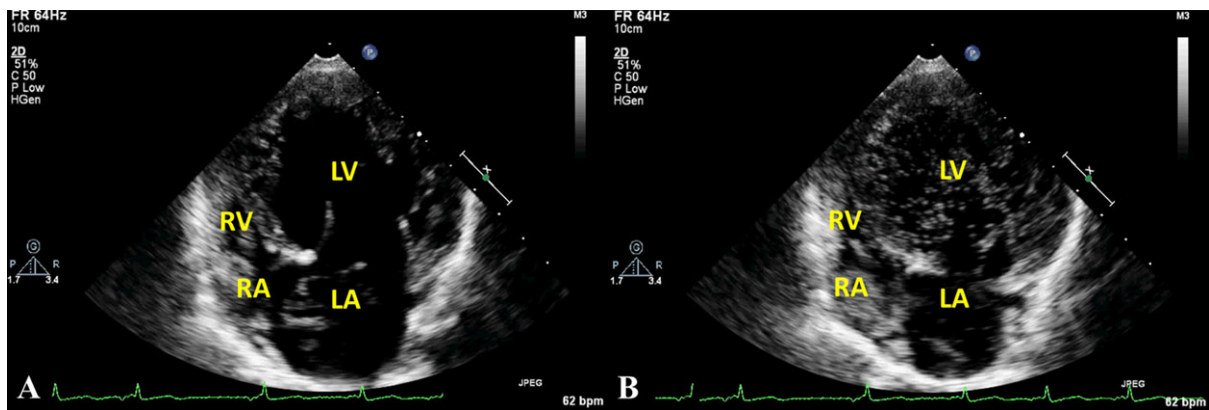
#### Reversal of left-to-right shunt:

##### Eisenmenger syndrome: shunt reversal due to elevated pulmonary vascular resistance:

The detection of a shunt lesion is easy with good left-to-right shunt, but is challenging in borderline shunt with raised pulmonary vascular resistance (PVR) especially when dealing with APW and or patent ductus arteriosus (PDA). Suboptimal acoustic window adds to the difficulty as



**Figure 5.** Transesophageal echocardiography with saline injected in lower limb vein. **A.** The microbubbles first appeared in left atrium (LA) and left ventricle (LV) followed by **B.** faint filling of right atrium (RA) and right ventricle (RV) through small residual atrial septal defect. Adapted with permission from Desai et al.<sup>19</sup>



**Figure 6.** Transthoracic echocardiography in apical four-chamber view with saline injection in the lower limb showing **A.** microbubbles appearing first in left atrium (LA) and left ventricle (LV) followed by **B.** right atrium (RA) and right ventricle (RV) through an atrial septal defect. Similar sequence of bubbles was observed with injection in arm veins (not shown here) confirming the diagnosis of anomalous drainage of both SVC and IVC.

majority of these patients are adults. This can have significant clinical impact as these patients may be wrongly labelled as having primary pulmonary hypertension.

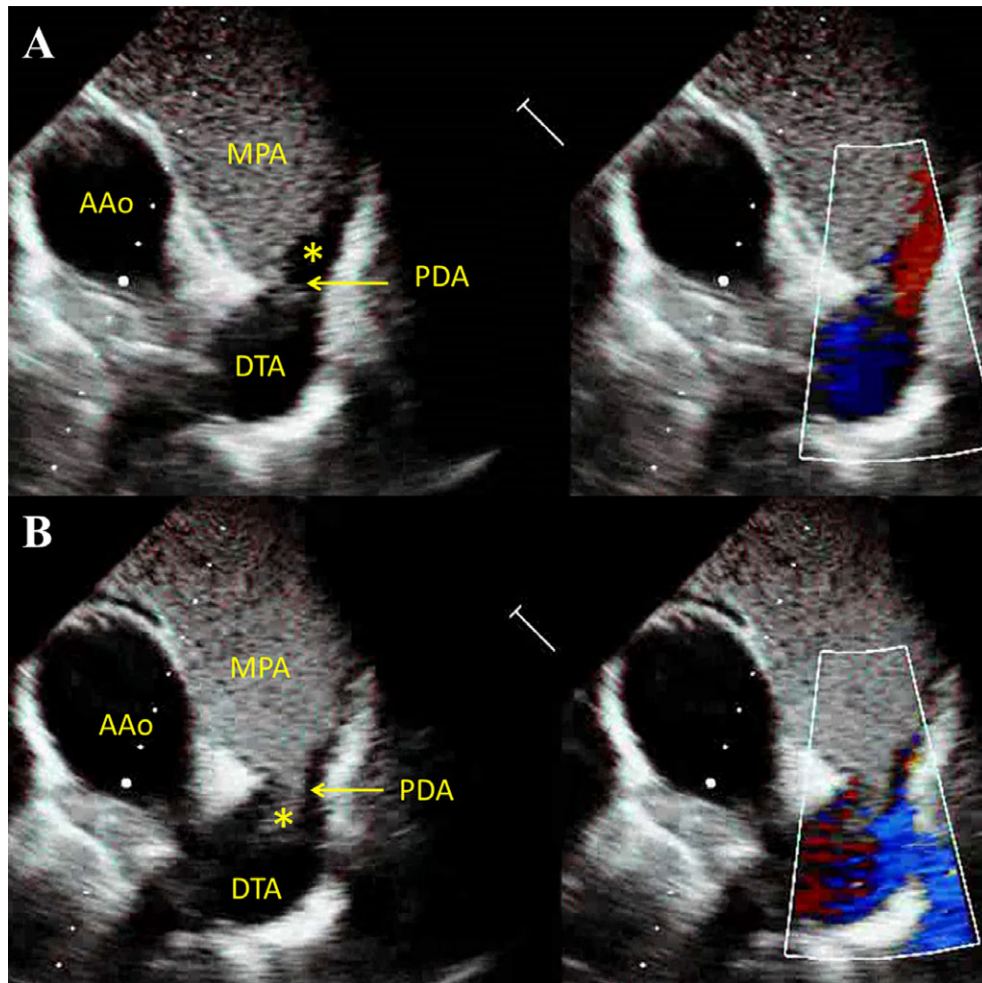
An 18-year-old girl complained of exertional breathlessness for preceding 1 year. The pulse oximetry measured the systemic saturation at 92% with no differential cyanosis. There was no cardiomegaly or murmur. The pulmonary component of the second heart sound was loud with narrow split and suggested the diagnosis of PAH. The transthoracic echocardiogram failed to show any ASD or ventricular septal defect (VSD). SCE was then performed with imaging first in apical four-chamber view during which no microbubble appeared in the LA or LV. The agitated saline was then injected with imaging in modified high parasternal short-axis view. This time the microbubbles were seen traversing from the PA to descending thoracic aorta thus confirming

both the diagnosis of PDA and the presence of bidirectional shunt (Fig. 7 and movie clip S6).

This case demonstrates the importance of appropriate imaging plane while performing SCE. Had it been only the apical four-chamber view the diagnosis of PDA related Eisenmenger syndrome would have been missed. Similarly, in appropriate clinical context SCE must be repeated with imaging in parasternal short-axis view to rule out APW (Fig. 8 and movie clip S7). Further, the width of microbubble jet provides an estimate of the size of underlying shunt.

**Right-to-left shunt in ASD with normal PA pressure and PVR**—Unlike post-tricuspid shunts such as VSD and PDA, cyanosis in a patient with ASD does not always indicate raised PVR or inoperability. Cyanosis in a patient with ASD can occur with coexisting anomalies of systemic venous connection. Straddling SVC or IVC in cases with sinus





**Figure 7.** SCE in high parasternal short-axis view from a patient with large patent ductus arteriosus (PDA) and elevated PVR. **A.** Negative contrast in main pulmonary artery (MPA) (\*) demonstrates left-to-right shunt. **B.** Microbubbles (\*) escaping from MPA to descending thoracic aorta (DTA) through PDA confirms the presence of right-to-left shunt. Note the absence of microbubbles in ascending aorta (AAo).

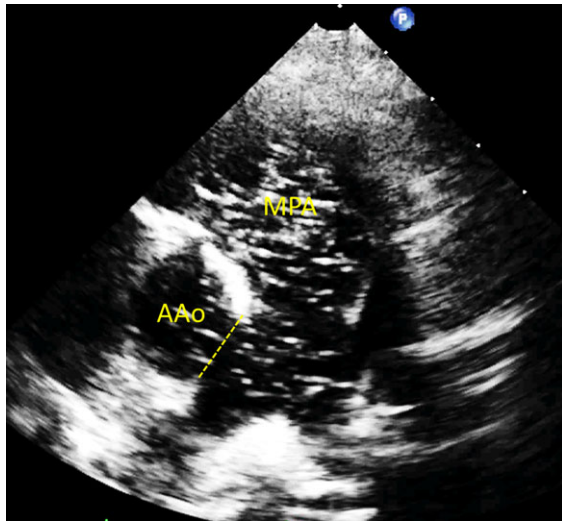
venous type of ASD or prominent Eustachian valve in some cases of secundum ASD allows abnormal drainage of systemic veins despite normal connections. In addition, reduced RV compliance seen with RV cardiomyopathy and RV myocardial infarction may also cause the blood to shunt from RA to LA resulting in cyanosis. Occasionally tricuspid regurgitation jet directed towards LA in patients with ostium primum ASD lead to systemic desaturation. SCE in such situation by demonstrating the right-to-left shunt provides an explanation for cyanosis despite normal PA pressure.

**Platypnea orthodeoxia syndrome**—Dyspnea and hypoxia in upright posture, commonly known as platypnea-orthodeoxia, result from variety of reasons.<sup>20</sup> Patients with platypnea are often labelled as “functional” as they are nearly asymptomatic while lying down. Detailed clinical evaluation supplemented by pulse oximetry in supine and

sitting posture can diagnose but exact mechanism remains unclear. SCE in some of these cases can confirm the diagnosis and demonstrate the underlying mechanism much to the relief of the doctor and the patient. Shirashi and colleagues reported an interesting case of dilated aortic root wherein SCE using tilt table TEE showed massive right-to-left shunt across PFO upon sitting thus validating the mechanism of platypnea (Fig. 9).<sup>21</sup>

#### **Extracardiac (intrapulmonary) shunt:**

SCE does not rely on direct visualization of the shunt but depends upon mapping the path of microbubbles and therefore is an obvious choice to detect extracardiac right-to-left shunts. A delayed appearance of microbubbles in LA is generally considered pathognomonic of pulmonary arteriovenous malformations (PAVM) in clinical practice.



**Figure 8.** SCE in parasternal short-axis view from a patient with large aorto-pulmonary window (APW) and severe PAH. Microbubbles after arriving in the main pulmonary artery (MPA) enters ascending aorta (AAo) through APW (broken arrow). The width of microbubble stream allows estimation of the size of APW.

A 17-year-old boy had cyanosis at rest and exertional dyspnea. Clinical examination was unremarkable except for cyanosis (SpO<sub>2</sub>) 84%. ECG, chest radiograph and echocardiogram was normal. SCE performed subsequently showed filling of LA with the microbubbles after few cardiac cycles. More importantly the microbubbles were seen entering into LA via left pulmonary vein localizing the PAVM to left lung (Fig. 10 and movie clip S8). Digital subtraction angiography confirmed PAVM in the left lower lobe which was then closed percutaneously.

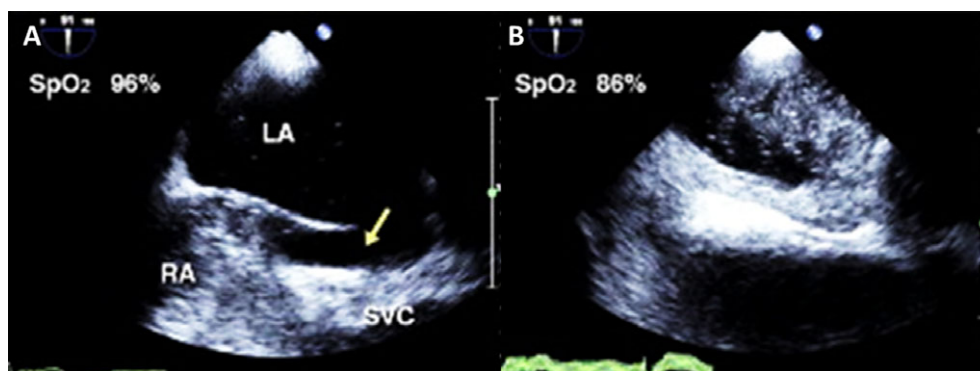
Unlike cardiac shunts, in a patient with intrapulmonary shunt occurs at the level of PA and microbubbles are expected to appear in LA with some delay. A delay of 3–5 beats is commonly used as an indicator of intrapulmonary shunt.

However, the “3 beat rule,” as was initially described or its later adaptation to “3–5 beat rule” could have exceptions.<sup>22</sup> The delay is not unique to intrapulmonary shunt and is also seen in cases with PFO if the atrial septum is aneurysmal, restricting free transit of the microbubbles.<sup>23,24</sup> On the contrary brisk and extensive opacification of LA can occur with extensive intrapulmonary shunt particularly if bilateral.<sup>25</sup> Visualization of microbubbles entering via pulmonary veins on the other hand is a better sign to demonstrate shunt occurring within the lungs especially if performed in with TEE. Excluding some cases with unusual forms of systemic vein to pulmonary vein connections (see later), the entry of microbubbles in LA via pulmonary veins is diagnostic of intrapulmonary shunt. Further, pulmonary vein that shows the microbubbles provides useful information regarding the site of PAVM.<sup>26</sup>

The opacification in SCE depends upon the amount of right-to-left shunt and forms the basis of semiquantitative grading with grade 0 having no bubbles while grade 3 showing intense filling.<sup>8</sup> SCE has high sensitivity and high negative predictive value of >97% justifies the use as screening tool for PAVM.<sup>10,27</sup> Poor specificity of 49% and low positive predictive value (PPV) especially with lower grades of opacification limits its accuracy as a diagnostic test. Grade 1 SCE might appear due to the presence of physiologic right-to-left shunt with possible increase in supine position and does not warrant subsequent CT for confirmation until the clinical suspicion is high.<sup>4,5,8,27</sup>

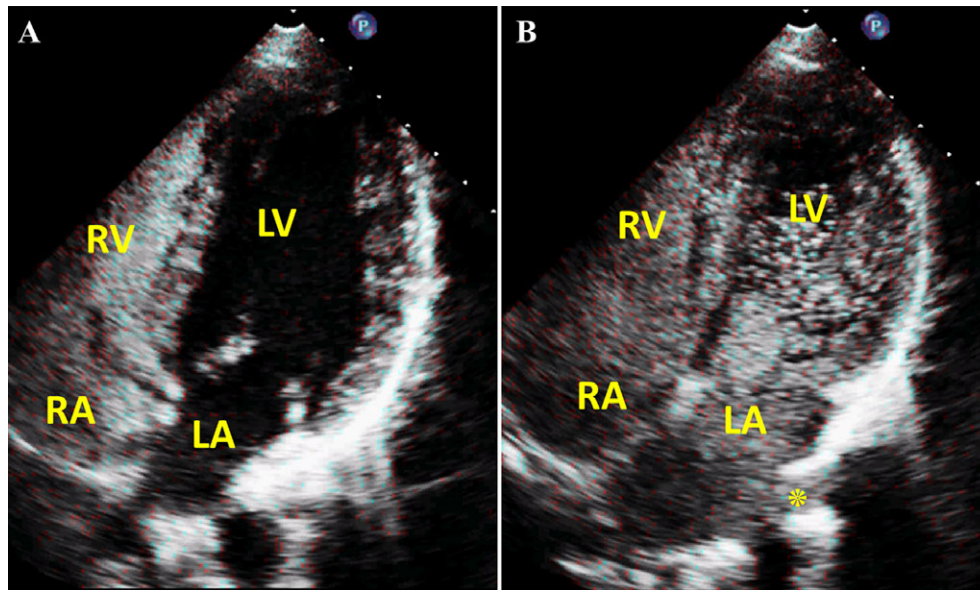
#### Right-to-left shunts at unusual locations:

**Pulmonary artery to left atrium shunt:** An extremely unusual form of right-to-left shunt can occur in the presence of a communication, usually large, between branch PA and LA. Although can be diagnosed with color Doppler imaging it can be easily demonstrated by intense filling of



**Figure 9.** SCE using TEE approach in supine position **A.** shows minimal right-to-left shunt through PFO (arrow) in supine position which gets exaggerated while sitting **B.** Adapted with permission from Shirashi et al.<sup>21</sup>





**Figure 10.** Transthoracic echocardiogram in apical four-chamber view with injection on the left arm **A.** showing intense filling of right atrium (RA) and right ventricle (RV) but no microbubbles in left atrium (LA) or left ventricle (LV). **B.** There is intense filling of LA and LV after few cardiac cycles. The entry of microbubbles from the left sided pulmonary vein (\*) localizes PAVM to the left lung.

LA soon after PAs are opacified following injection of agitated saline contrast. The entry of microbubbles from the roof of LA coinciding with the site of defect provides certainty to the diagnosis of this rare anomaly.

**Leaks and obstruction in intra- or extra-cardiac baffles:** During cardiac surgery for CHDs, redirection procedures such as atrial switch operation (Mustard and Senning operation) involve extensive rerouting of systemic and pulmonary veins. Complex anatomy in the postoperative state makes the diagnosis of leaks and obstructions in these baffles challenging. SCE is useful in this setting as it delineates the path of blood flow and can clarify a diagnostic dilemma.<sup>28,29</sup>

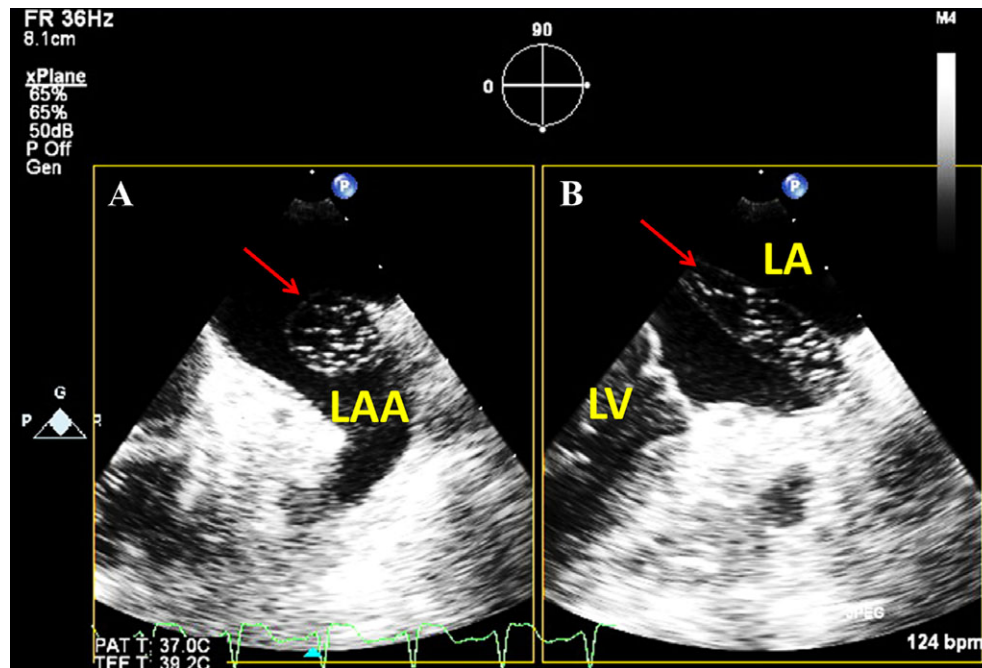
Certain cyanotic CHDs cannot be repaired and these patients can only be palliated by bidirectional Glenn (BDG) and total cavopulmonary connection (TCPC) surgery wherein SVC alone or both SVC and IVC are connected to PAs. Normal functioning of TCPC circuit relies heavily on appropriately low PVR. A small communication (fenestration) between TCPC circuit and atrium is left intentionally during surgery in doubtful situations with elevated PA pressure and or borderline size of the PAs. This fenestration acts as safety valve in the immediate postoperative period. If the patient show signs of high pressure in this newly formed venous circuit then it allows right-to-left shunt and help maintaining cardiac output. Suboptimal windows inherent to the

postoperative state however limit the visualization. SCE in such a scenario provides an easy way to confirm the patency of fenestration.

**Systemic to pulmonary venous connections:** Venous collaterals develop in patients with SVC obstruction. Occasionally abnormal connections develop between systemic veins and pulmonary veins resulting in right-to-left shunt.<sup>30</sup> In a case of SVC obstruction, Beigel et al. demonstrated their presence by performing SCE. After injection of agitated saline in forearm microbubbles appeared first in LA while RA filled late from the IVC. Subsequently performed CT angiogram confirmed the presence of venovenous collaterals between systemic veins and LUPV allowing drainage of SVC blood via IVC.<sup>31</sup> Similar connections develop in some patients after cavopulmonary connection surgeries (BDG and TCPC) if the pressure in PA or the systemic venous circuit is elevated.<sup>32</sup> Although not emphasized by the authors, microbubbles in these instances are expected to enter LA via pulmonary vein receiving the collateral from systemic vein.

#### **Diagnosis of abnormal flows and structures in right side chambers:**

The role of SCE in augmenting Doppler signal and endocardial definition on the right sided pathologies is well known.<sup>33</sup> Newer contrast agents that cross pulmonary vasculature have brought LV within the reach of contrast echocar-



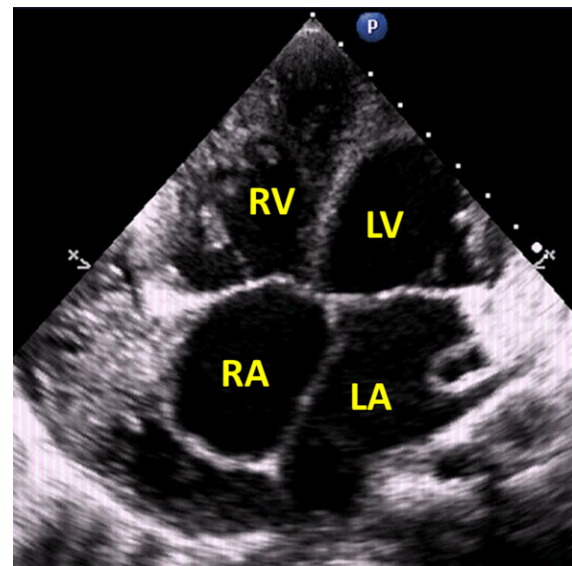
**Figure 11.** TEE X plane imaging with saline injected in the left arm shows **A.** microbubbles within a cystic structure (arrow), lying posterior to LA appendage (LAA) and **B.** traversing within LA before opening into RA confirming intra-atrial course but normal drainage of left SVC. Adapted with permission from Irwin et al.<sup>36</sup>

diography allowing analysis of LV endocardium, regional wall motion abnormalities and various myocardial perfusion studies.<sup>34</sup>

Despite improved diagnostic ability of echocardiography some shadows pose considerable difficulty in the diagnosis. SCE in some of these cases is useful adjunct. Rare cases such as the ones reported by Wilhelm et al.<sup>35</sup> and Irwin et al.<sup>36</sup> showed a cystic mass within the LA. The diagnosis remained uncertain even after cardiac MRI.<sup>36</sup> Microbubbles within this cystic structure with left arm SCE proved it to be persistent left SVC having an unusual course within LA (intra-atrial course) (Fig. 11).<sup>35,36</sup>

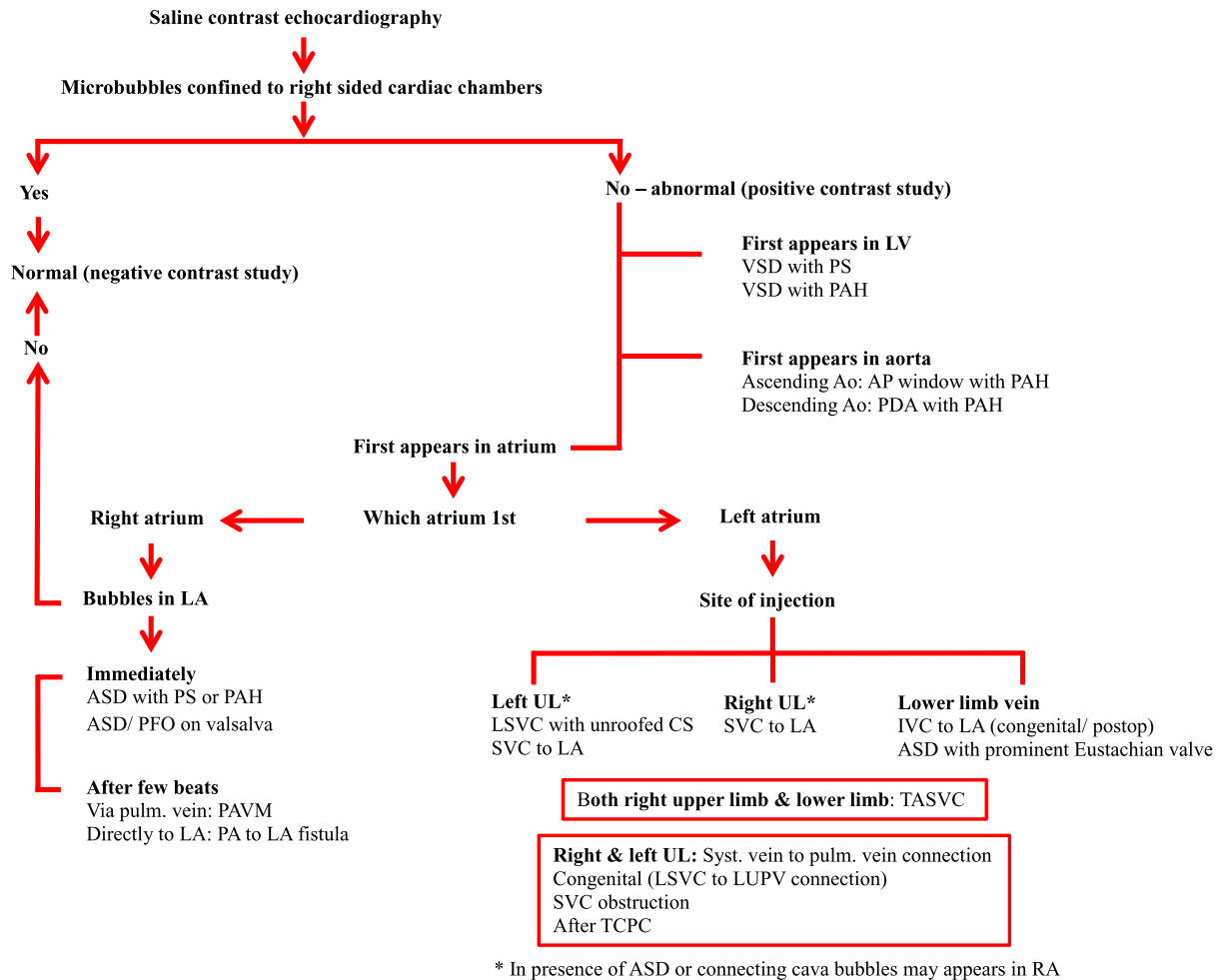
#### Other uses of saline contrast echocardiography:

The indications of SCE have expanded rapidly in recent times. Saline injection through the puncture needle confirms its position during pericardiocentesis.<sup>37,38</sup> Pericardiocentesis is relatively easy in the presence of large pericardial collection. However, it is challenging in cases of localized collection of modest pericardial fluid. The confirmation of access into the pericardial space is of paramount importance. SCE is extremely useful in such cases. After presumed entry into the pericardial space with the needle, small amount of agitated saline is injected. Echocardiographic visualization of bubbles that remains confined to the pericardial space confirms the position of the



**Figure 12.** Saline contrast echocardiogram performed during pericardiocentesis. The pericardial fluid is confined lateral to the right atrium. The appearance of bubbles within the pericardial space confirms the position of the needle and facilitates pericardiocentesis. In the event of inadvertent entry in a cardiac chamber the bubbles shall appear inside the heart enabling the operator to reposition the needle.

needle (Fig. 12 and movie clip S9). Similarly, SCE can confirm the position of the catheter during central venous catheterization by visualization of



**Figure 13.** Suggested algorithm for interpretation of saline contrast echocardiography to diagnose various right-to-left shunts. Ao = aorta; ASD = atrial septal defect; CS = coronary sinus; IVC = inferior vena cava; LA = left atrium; LL = lower limb; LSVC = left superior vena cava; LUPV = left upper pulmonary vein; LV = left ventricle; PA = pulmonary artery; PAH = pulmonary arterial hypertension; PAVM = pulmonary arteriovenous malformation; PFO = patent foramen ovale; PDA = patent ductus arteriosus; PS = pulmonary stenosis; PV = pulmonary vein; RA = right atrium; SVC = superior vena cava; TASVC = total anomalous systemic venous connection; TCPC = total cavopulmonary connection; UL = upper limb; VSD = ventricular septal defect.

the bubbles injected under echocardiographic guidance.<sup>39,40</sup> The appearance of bubbles outside the margins of the vessel is almost diagnostic of misplaced central venous catheters.<sup>41</sup>

### Interpreting saline contrast echocardiogram in a patient with suspected right-to-left shunt:

SCE if performed appropriately and interpreted logically, based on site of injection and the sequence of microbubble appearance in the heart, allows differentiation of various usual and unusual right-to-left shunts (Fig. 13). In addition, delineation of the site of entry of microbubbles within LA also provides insights into the diagnosis.

### Conclusion:

SCE is an inexpensive, easily available and reproducible modality that adds certainty to the

clinical diagnosis in many circumstances, and may identify unusual cause of cyanosis in appropriate clinical context provided it is performed and interpreted carefully.

### References

- Gramiak R, Shah PM: Echocardiography of the aortic root. *Invest Radiol* 1968;3:356–358.
- Soliman Oll, Geleijnse ML, Meijboom FJ, et al: The use of contrast echocardiography for the detection of cardiac shunts. *Eur J Echocardiogr* 2007;8:S2–S12.
- Soliman Oll, De Jong N, Van Der Zwaan HB, et al: Contrast echocardiography: Mechanism of action, safety and clinical application. *Minerva Cardioangiol* 2010;58:343–355.
- McMullan DM, Reimer RK: Embryology and anatomy of intrapulmonary shunts. *Echocardiography* 2015;32:S190–S194.
- Velthuis S, Buscarini E, Gossage JR, et al: Clinical implications of pulmonary shunting on saline contrast echocardiography. *J Am Soc Echocardiogr* 2015;28:255–263.



6. Lange MC, Zetola VF, Plovesan EJ, et al: Saline versus saline with blood as a contrast agent for right to left shunt diagnosis by transcranial Doppler: Is there a significant difference? *J Neuroimaging* 2012;22:17–20.
7. Jeon DS, Luo H, Iwami T, et al: The Usefulness of a 10% air-10% blood-80% saline mixture for contrast echocardiography: Doppler measurement of pulmonary artery systolic pressure. *J Am Coll Cardiol* 2002;39:124–129.
8. Gazzanniga P, Buscarini E, Leandro G, et al: Contrast echocardiography for pulmonary arteriovenous malformations screening: Does any bubble matter? *Eur J Echocardiogr* 2009;10:513–518.
9. Bommer WJ, Shah PM, Allen H, et al: The safety of contrast echocardiography: Report of the Committee on Contrast Echocardiography for the American Society of Echocardiography. *J Am Coll Cardiol* 1984;3:6–13.
10. van Gent MW, Post MC, Luermans JG, et al: Screening for pulmonary arteriovenous malformations using transthoracic contrast echocardiography: A prospective study. *Eur Respir J* 2009;33:85–91.
11. Holcomb BW, Loyd JE, Byrd BF, et al: Iatrogenic paradoxical air embolism in pulmonary hypertension. *Chest* 2001;119:1602–1605.
12. Romero JR, Frey JL, Schwamm LH, et al: Cerebral ischemic events associated with “bubble study” for identification of right to left shunts. *Stroke* 2009;40:2343–2348.
13. Tsvigoulis G, Heliopoulos I, Stamboulis E: Safety of TCD “bubble study”. *Stroke* 2010;41:e195.
14. Thaiyananthan NN, Jacono FJ, Patel SR, et al: Right to left anatomic shunt associated with a persistent left superior vena cava. The importance of injection site in demonstrating the shunt. *Chest* 2009;136:617–620.
15. Hutyra M, Skala T, Sanak D, et al: Persistent left superior vena cava connected through the left upper pulmonary vein to the left atrium: An unusual pathway for paradoxical embolization and a rare cause of recurrent transient ischemic attack. *Eur J Echocardiogr* 2010;11:E35.
16. Recto MR, Sadlo H, Sobczyk WL: Rare cause of persistent left superior vena cava to left upper pulmonary vein: Pathway for paradoxical embolization and development of transient ischemic attack and subsequent occlusion with an Amplatzer vascular plug. *J Invasive Cardiol* 2007;19:E313–E316.
17. Shetkar SS, Gupta SK, Gulati GS, et al: Right superior vena cava to left atrium: Importance of “bubbling it right”. *Echocardiography* 2014;31:E161–E162.
18. Sadek H, Gilkeson RC, Hoit BD, et al: Case of anomalous right superior vena cava. *Circulation* 2006;114:e532–e533.
19. Desai M, Talwar S, Kothari SS, et al: Inferior vena cava to left atrium shunt presenting with polycythemia and stroke three decades following closure of atrial septal defect. *Congenit Heart Dis* 2013;8:E102–E105.
20. Cheng TO: Platypnea-orthodeoxia syndrome: Etiology, differential diagnosis and management. *Cathet Cardiovasc Interv* 1999;47:64–66.
21. Shirashi Y, Hakuno D, Isoda K, et al: Platypnea-orthodeoxia syndrome due to PFO and aortic dilation. *JACC Cardiovasc Imaging* 2012;5:570–571.
22. Freeman JA, Woods TD: Use of saline contrast echo timing to distinguish intracardiac and extracardiac shunts: Failure of the 3-to-5-beat rule. *Echocardiography* 2008;25:1127–1130.
23. Attaran R, Imran A, Kudithipudi V, et al: Protocol for optimal detection and exclusion of a patent foramen ovale using transthoracic echocardiography with agitated saline microbubbles. *Echocardiography* 2006;23:616–622.
24. Woods T, Patel A: A critical review of patent foramen ovale detection using saline contrast echocardiography: When bubbles lie. *J Am Soc Echocardiogr* 2006;19:215–222.
25. Naqvi TZ, Nagai T, Atar S, et al: Early appearance of echo contrast simulating an intracardiac shunt in a patient with liver cirrhosis and intrapulmonary shunt. *J Am Soc Echocardiogr* 2002;15:379–381.
26. Ahmad S, Nanda NC, Nekkanti R, et al: Contrast transesophageal echocardiographic detection of a pulmonary arteriovenous malformation draining into left lower pulmonary vein. *Echocardiography* 2003;20:391–394.
27. Zukotynski K, Chan RP, Chow CM, et al: Contrast echocardiography grading predicts pulmonary arteriovenous malformations on CT. *Chest* 2007;132:18–23.
28. Silverman NH, Snider AR, Colo J, et al: Superior vena caval obstruction after Mustard’s operation: Detection by two-dimensional contrast echocardiography. *Circulation* 1981;64:392–396.
29. Bouma BJ, van der Sloot JA: Utility of contrast echocardiography to detect baffle leak in Mustard patients. *Echocardiography* 2011;28:E154–E155.
30. Gilkeson RC, Nyberg EM, Sachs PB, et al: Systemic to pulmonary venous shunt: Imaging findings and clinical presentations. *J Thorac Imaging* 2008;23:170–177.
31. Beigel R, Thomson LEJ, Seigel RJ: An unusual case of saline contrast injection in the anterior cubital vein appearing in the left heart prior to the right heart. *J Am Coll Cardiol* 2013;62:e13.
32. Magee AG, McCrindle BW, Mawson J, et al: Systemic venous collateral development after the bidirectional cavopulmonary anastomosis: Prevalence and predictors. *J Am Coll Cardiol* 1998;32:502–508.
33. Arora H, Virani SS, Simpson L, et al: Contrast echocardiography for right sided conditions – case report and literature review. *Tex Heart Inst J* 2008;35:38–41.
34. Senior R, Becher H, Monashan M, et al: Contrast echocardiography: Evidence-based recommendations by European association of echocardiography. *Eur J Echocardiogr* 2009;10:194–212.
35. Wilhelm J, Issa H, Behrmann C, et al: Atypical course of a persistent left superior vena cava through the left atrium. *Eur J Echocardiogr* 2011;12:635.
36. Irwin RB, Greaves M, Schmitt M: Left superior vena cava: Revisited. *Eur Heart J Cardiovasc Imaging* 2012;13:284–291.
37. Tsang TSM, Enriquez-Sarano M, Freeman WK, et al: Consecutive 1127 therapeutic echocardiographically guided pericardiocentesis: Clinical profile, practice patterns, and outcomes spanning 21 years. *Mayo Clin Proc* 2002;77:429–436.
38. Ainsworth CD, Salehian O: Echo-guided pericardiocentesis – let the bubbles show the way. *Circulation* 2011;123:e210–e211.
39. Vezzani A, Brusasco C, Palermo S, et al: Ultrasound localization of central vein catheter and detection of postprocedural pneumothorax: An alternative to chest radiography. *Crit Care Med* 2010;38:533–538.
40. Weekes AJ, Johnson DA, Keller SM, et al: Central venous catheter placement evaluation with saline flush and bedside echocardiography. *Acad Emerg Med* 2014;21:65–72.
41. Schiavetti A, Ventriglia F: Contrast echocardiography test for intrapleural extravasation by central venous catheter. *Imag Med* 2014;6:21–24.

### Supporting Information

Additional Supporting Information may be found in the online version of this article:

[Correction added on August 20, 2016, after first online publication: The supporting information movie clips legends were corrected.]

**Movie clip S1.** PDA with elevated PVR: Eisenmenger syndrome.

**Movie clip S2.** Negative contrast study.

**Movie clip S3.** Persistent left SVC with partial unroofing of CS.

**Movie clip S4.** Right SVC to LA.

**Movie clip S5.** IVC to LA with residual ASD after surgical closure of ASD.

**Movie clip S6.** Total anomalous systemic venous connection to LA.

**Movie clip S7.** APW with elevated PVR: Eisenmenger syndrome.

**Movie clip S8.** Pulmonary arteriovenous malformation.

**Movie clip S9.** Saline contrast echocardiography during pericardiocentesis.