

Pyogenic granuloma of the transverse colon. Report of a pediatric case

Eugenia Altamirano,* Ricardo Drut*

RESUMEN

Presentamos un ejemplo único de granulomas piógenos múltiples y asintomáticos encontrados en la mucosa del colon transverso a 4 cm en sentido caudal de una ostomía en el colon transverso, en un niño de dos años con aganglioneosis rectal. La peculiar lesión formaba un grupo de masas exofíticas topográficamente relacionadas, de hasta 5 mm de altura, que contenían la proliferación de los capilares. Los marcadores endoteliales CD31, CD34 y FVIII fueron positivos y el Glut-1 negativo. Este caso parece ser el segundo informe de granuloma piógeno con afección a la mucosa colónica en niños.

Palabras clave: colon, granuloma piógeno.

ABSTRACT

We report a unique pattern of multiple asymptomatic pyogenic granuloma found in the mucosa of the transverse colon, 4 cm distally to a colostomy site in a 2 year old boy with rectal aganglioneosis. The peculiar lesion formed a group of exophytic, topographically-related masses up to 5 mm in height containing the proliferated capillaries. Endothelial markers (CD31, CD34, FVIII) were positive but Glut-1. The example appears to be the second report of pyogenic granuloma involving the colonic mucosa of children.

Key words: colon, pyogenic granuloma.

P pyogenic granuloma is a polypoid type of lobular capillary hemangioma. The lesion mimics exuberant granulation tissue. Pyogenic granuloma most commonly arises in the skin and oral or nasal mucosa being extremely unusual its development at the gastrointestinal tract. Although cases have been reported as presenting in both sexes at any age, pyogenic granuloma in the bowel at the pediatric age are exceptional. We are reporting a child having multiple agminated pyogenic granuloma in the transverse colon, near a colostomy site performed for rectal aganglioneosis.

CASE REPORT

This 2, 7/12-year-old boy had history of aganglioneosis and transverse colostomy done at 5 days of age. He was now admitted for final surgery through Duhamel surgery. In the meantime he presented two episodes of acute gastroenteritis and mucosal prolapse at the ostomy at age 1 year.

PATHOLOGY FINDINGS

The surgical specimen included a 35 cm length large bowel including the ostomy site, the distal colon and rectum. The calibre of the colon was remarkably reduced, and thus

its functioning. At 4 cm distally to the ostomy site there were 7 small, reddish, 3 to 6 mm in diameter, 4 to 5 mm height polypoid masses. These were apart each other but arranged in a jigsaw puzzle-like pattern due to the small diameter of the colon (figure 1).

MICROSCOPIC FINDINGS

The simples showed normal intramural ganglia at the proximal and distal ostomy sites and nodular lymphoid hyperplasia in the mucosa. The distal end of the surgical specimen (rectum) showed absence of ganglionic cells in the intramural plexi.

* Departamento de patología, Hospital Superiora Sor María Ludovica, La Plata, Argentina.

Correspondencia: Dr. Ricardo Drut. Departamento de patología, Hospital Superiora Sor María Ludovica, La Plata, Argentina.

E-mail: patologi@netverk.com.ar

Recibido: abril, 2008. Aceptado: junio, 2008.

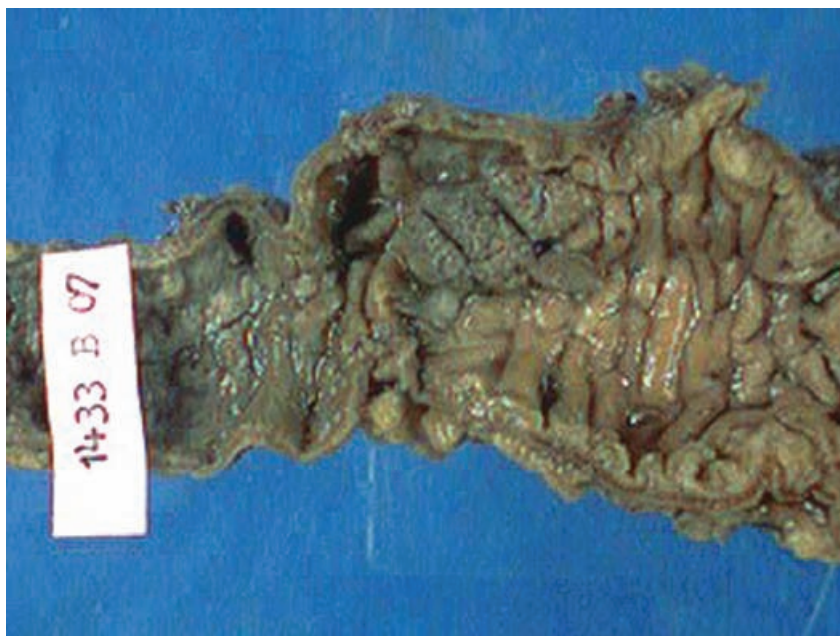


Figure 1. Gross of the lesion recognized as a group of strawberry-like masses in the upper half of the colonic mucosa at the center of the figure.

The polypoid masses belonged to exophytic proliferations of capillary vessels partially surrounded by edematous stroma with inflammatory cells, in between local crypts (figures 2 A to C). The surface epithelium was eroded and regenerative epithelial cells lined the included crypts. Each of the lesions was wide apart from the other. The endothelial cells proved to be immunohistochemically positive for CD31, CD34 (figure 3) and FVIII, as well as negative for GLUT-1. The

combined findings were interpreted as belonging to a peculiar localization of pyogenic granuloma.

DISCUSSION

Pyogenic granuloma is a benign lesion its etiology remaining unresolved. Its development has been related mainly to previous local trauma (resulting in an exuberant reactive granulation tissue), hormonal stimuli (since it is to be observed in the skin and oral mu-

cosa of pregnant women), bacterial or viral infections, or arteriovenous anastomosis.¹ However, these conditions are not always present.

Pyogenic granuloma is most commonly referred as a polypoid capillary haemangioma, more frequently appearing at the skin and oral or nasal mucosa as a small granulation tissue-like exophytic mass rich in capillaries.

Vascular tumours and malformations at the gastrointestinal tract are infrequent being even rarer at the colon and stomach.² Most of the reported cases of pyogenic granuloma at the gastro-intestinal tract developed in adults (mainly at 5th and 7th decade), and without sex prevalence. The site of the lesion has been variable presenting at the esophagus, jejunum, ileum, colon and rectum. We could find only one reference reporting two pediatric patients.³ In these children one lesion developed at the splenic angle of the colon and the other in the rectal mucosa. The main clinical finding in all the cases was bleeding being it hematemesis, melena or proctorrhagia, with the resulting anemia.

In the present patient the lesions were in the colonic mucosa of the transverse colon, distally to a

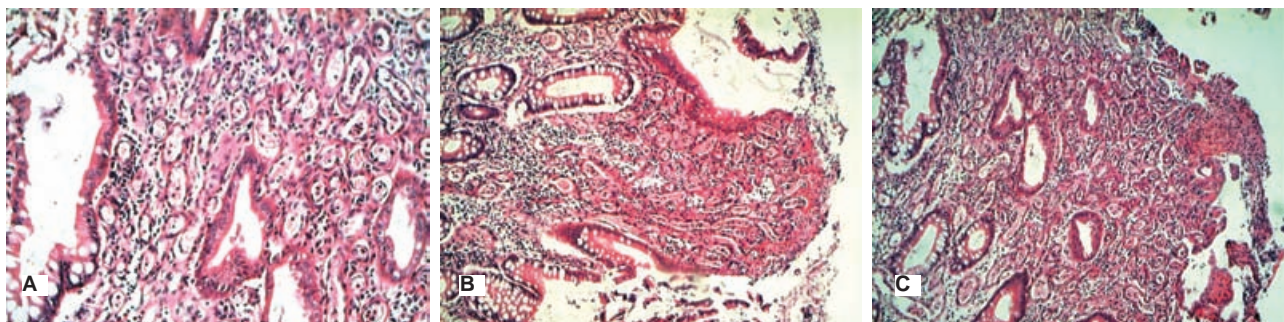


Figure 2. Images depicting the increased number of small capillaries with distinctive walls forming the stroma in between the local crypts. Notice focal erosion of the surface epithelium (H&E).

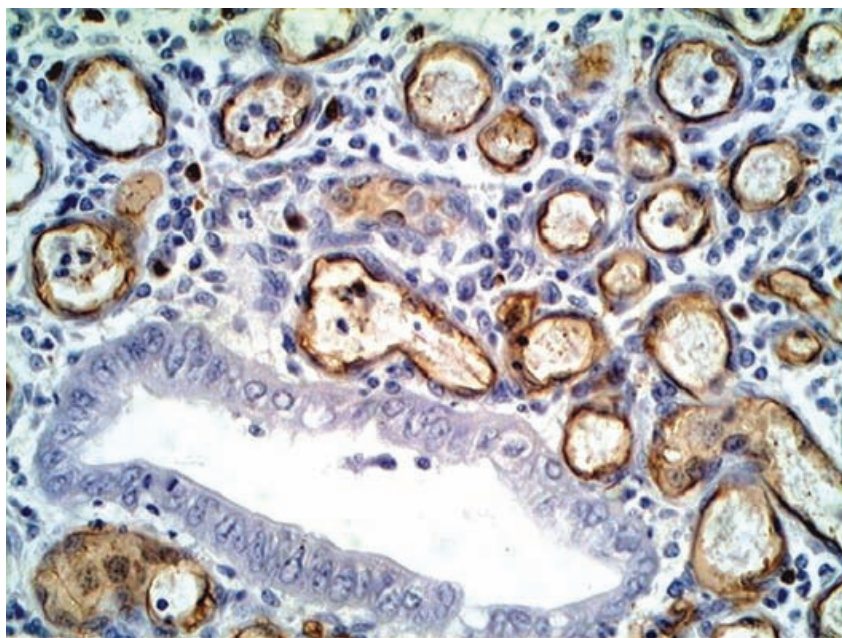


Figure 3. CD34 immunostaining highlighting the endothelial cells of the capillaries.

colostomy and were completely asymptomatic. At the same time, the clinical data of the patient (aganglionosis and colostomy at the transverse colon) made this a peculiar case. Although as referred, the lesions were near the colostomy site they were far enough as to be apart from the granulation /scarring tissue resulting from the surgical procedure. At the same time it was quite striking the peculiar agminated pattern of the polypoid masses, each one separated

from the other although resulting in an anatomically-related bunch. This peculiar pattern has not been referred previously. The immunohistochemical endothelial markers CD31, CD34 and FVIII stained appropriately the endothelial cells of the lesions. The negative reaction for GLUT1 militates against the possibility of the lesion being an example of infantile hemangioma.

Pyogenic granuloma must be included in the differential diagnosis

of polypoid lesions of the bowel such as inflammatory polyp, bacillary angiomatosis and Kaposi sarcoma.⁴ In the present case the immunohistochemistry was done just to stand out the endothelial cells since the definitive diagnosis may be achieved simply through the H&E routine stain.

In brief, we are reporting the finding of a conglomerate of several pyogenic granulomas at the colonic mucosa distally (4 cm) to a colostomy site in a 2 year-old child with rectal aganglionosis.

REFERENCES

1. van Eeden S, Offerhaus GJA, Morsink FH, van Rees BP, et al. Pyogenic granuloma: an unrecognized cause of gastrointestinal bleeding. *Virchows Arch* 2004;444(6):590-3.
2. Yao T, Nagai E, Utsunomiya T, Tsuneyoshi M. An intestinal counterpart of pyogenic granuloma of the skin. A newly proposed entity. *Am J Surg Pathol* 1995;19:1054-60.
3. Blanchard SS, Chelimsky G, Czinn SJ, Redline R, Splawski J. Pyogenic granuloma of the colon in children. *J Pediatr Gastroenterol Nutr* 2006;43:119-21.
4. González-Vela MC, Val-Bernal JF, Garijo MF, García-Suárez C. Pyogenic granuloma of the sigmoid colon. *Ann Diag Pathol* 2005;9:106-9.