

## Medically important ants: a systematic review of the global distribution and clinical consequences of their bites and stings

Hormigas de importancia médica: revisión sistemática de su distribución global y consecuencias clínicas de sus mordeduras y picaduras

Mario Javier Olivera<sup>1\*</sup> <https://orcid.org/0000-0002-6885-6353>

Julián Felipe Porras Villamil<sup>2</sup> <https://orcid.org/0000-0003-1861-4601>

<sup>1</sup>Instituto Nacional de Salud. Bogotá DC, Colombia.

<sup>2</sup>Universidad Nacional de Colombia, Facultad de Medicina. Bogotá DC, Colombia.

\*Corresponding author: [moliverajr@gmail.com](mailto:moliverajr@gmail.com)

### ABSTRACT

**Introduction:** From the medical point of view, only some ants are of special interest. Due to the diversity of ants and the growing contact with humans, it is necessary to have a better understanding of the factors and problems, which lead to adverse clinical outcomes.

**Objective:** The aim of this study was to conduct a systematic review of published studies on ants and their impact on the medical field to synthesize fragmented knowledge and to inform the current state of this problem.

**Methods:** A systematic literature review was conducted in Medline, EMBASE, SciELO and Google Scholar, with no time threshold. The search strategy was limited to articles published in Portuguese, English and Spanish. Eligible studies were case reports and case series that reported outcomes in humans caused by ant stings. Patient-level and study-level information was extracted.

**Results:** The literature search yielded 1909 studies; of which 30 case reports and 16 case series reporting a total of 95 cases were included. Of these 48 patients were women (50.5%), and the median age was  $36.1 \pm 25.5$  years old. The most frequently reported complications were severe pain, anaphylaxis and acute respiratory distress syndrome. The death of eighteen patients was documented (18.9%). Ants from the genera *Solenopsis* spp.,

*Myrmecia* sp., *Paraponera clavata*, *Pachycondyla sennaarensis*, *Myrmecia rubra* caused most of the accidents

**Conclusions:** Severe allergic reactions caused by ants are a rare event, however, mortality can be high. An increase of ant related accidents is expected, a quick diagnosis and treatment is necessary to avoid fatalities.

**Keywords:** ants; Formicidae; humans; allergy; bites and stings.

## RESUMEN

**Introducción:** Desde el punto de vista médico, solo algunas hormigas son de especial interés. Debido a la diversidad de hormigas y al creciente contacto con humanos, es necesario comprender mejor los factores y problemas que conducen a resultados clínicos adversos.

**Objetivo:** Realizar una revisión sistemática de estudios publicados sobre las hormigas y su impacto en el campo médico para sintetizar conocimientos fragmentados e informar sobre el estado actual del problema.

**Métodos:** Se realizó una revisión bibliográfica sistemática en Medline, EMBASE, SciELO y Google Scholar, sin límite de tiempo. La estrategia de búsqueda se limitó a artículos publicados en portugués, inglés y español. Se seleccionaron informes y series de casos sobre consecuencias de las picaduras de hormigas en humanos. Se extrajo información a nivel de paciente y a nivel de estudio.

**Resultados:** La búsqueda bibliográfica obtuvo 1 909 estudios, de los cuales se seleccionaron 30 informes y 16 series sobre un total de 95 casos. De estos, 48 pacientes eran mujeres (50,5 %) y la media de edad era  $36,1 \pm 25,5$  años. Las complicaciones más frecuentes fueron dolor intenso, anafilaxia y síndrome de dificultad respiratoria aguda. Se documentó la muerte de 18 pacientes (18,9 %). Hormigas de los géneros *Solenopsis* spp., *Myrmecia* sp., *Paraponera clavata*, *Pachycondyla sennaarensis* y *Myrmecia rubra* causaron la mayoría de los accidentes.

**Conclusiones:** Las reacciones alérgicas graves provocadas por hormigas son un evento raro; sin embargo, la mortalidad puede ser alta. Se espera un incremento de los accidentes relacionados con las hormigas. Se requiere un diagnóstico y tratamiento rápidos para evitar muertes.

**Palabras clave:** hormigas; Formicidae; humanos; alergias; mordeduras y picaduras.

Received: 18/02/2019

Accepted: 19/12/2020

## Introduction

Ants are insects that belong to the Order Hymenoptera (with over 150 000 species)<sup>(1)</sup> which include wasps, hornets and bees; ants are one of the most common insect families,<sup>(2)</sup> they belong to the superfamily Formicoidea with currently more than 12 500 species in 290 genera being described.<sup>(3)</sup> These insects are characterized by having a wide distribution, and an incredible species richness and abundance,<sup>(4)</sup> and are one of the best adapted organisms to urban life and hostile environmental conditions<sup>(5,6)</sup> and can cause a wide array of clinical conditions.<sup>(7)</sup> Subfamilies Ponerinae, Dorylinae and Myrmeciinae are important to medical and veterinary dermatology.<sup>(8)</sup> Due to their inherent diversity the members of this superfamily generate a diverse assemble of injuries from mechanical damage to envenomation to systemic manifestations.<sup>(9)</sup>

The ants that can cause systemic reactions have been found around the world, for example Fire Ants, have been found in Asia, Australia and throughout the American continent;<sup>(10)</sup> showing the importance of this types of ants in the medical field.<sup>(11)</sup> Being this the case, physicians must be aware of the management of the different medical conditions that can be produce after a bite or sting, which in severe allergic reactions, includes the use of intramuscular epinephrine in the lateral aspect of the thigh (*Vastus lateralis*),<sup>(12)</sup> as well as the use of antihistamines and corticosteroids.<sup>(13)</sup> One important aspect is that approximately 1% of children and 3% of adults are allergic to Hymenoptera stings, many without history of a sting reaction.<sup>(14)</sup>

On the other hand, ants can serve as mechanical vectors carrying potentially serious pathogens, possibly having an impact on hospital infections,<sup>(15)</sup> circumstance that is increasingly important<sup>(16)</sup> as more ants are being identified as carriers.<sup>(17)</sup> On the other hand, ants appear to have beneficial properties. For example there is evidence that ant venom has anti-cancer properties,<sup>(18)</sup> are important in the control of pests in certain settings<sup>(19)</sup> and are able to distinguish between Diabetes Mellitus and Diabetes insipidus (ants are attracted to the urine of the former).<sup>(20)</sup> Also, the use of mandibles of giant ants, such as *Eciton burchellii*, *Eciton hamatum* in America and *Dorylus* sp. in Africa, as a suture method has been documented.<sup>(21,22)</sup>

Finally, as greenhouse gases accumulate, new areas could be colonized, allowing invasive species to cross the environmental barriers that are being erased by climate change, making contact with such insects more probable and more clinically important.<sup>(23)</sup> Especially in remote locations and rural areas,<sup>(24)</sup> which can be a call to use mobile health teams and field epidemiologists to manage and attend these medical problems,<sup>(25)</sup> which can be a good strategy. Due to the increasing importance of ants in the medical and veterinary field, due to the climatic changes that humanity will face head on in the following decades and the wide array of clinical conditions and species responsible of such, this study aimed to assess the impact on human health of ant bites/stings, through a systematic review

## **Methods**

### **Search strategies**

Systematic literature searches following the PRISMA strategy were conducted in the following databases: Medline, EMBASE, SciELO and Google scholar. The search strategy combined five search terms related to the impact of ant bites on human health: 1) Ants, 2) Formicidae, 3) Disease, 4) humans and 5) mortality. The search included all publications until July 31, 2018, with no specific start date.

### **Study selection and data extraction**

The studies were eligible for inclusion if they reported cases or series of cases of ant bites and included at least one patient. We defined studies as a case report if they described a single case and as a series of cases if they described more than one patient. Studies that were not published in English, Spanish or Portuguese were excluded. Two reviewers independently screened the search results for inclusion and then extracted all data using a standardized data extraction form. The discrepancies were resolved through discussion until consensus was reached. Information was extracted about the first author, country, year of publication, genus and species of ant, number of patients, age, sex, clinical manifestations and the outcome of death or complete remission.

### **Statistical analysis**

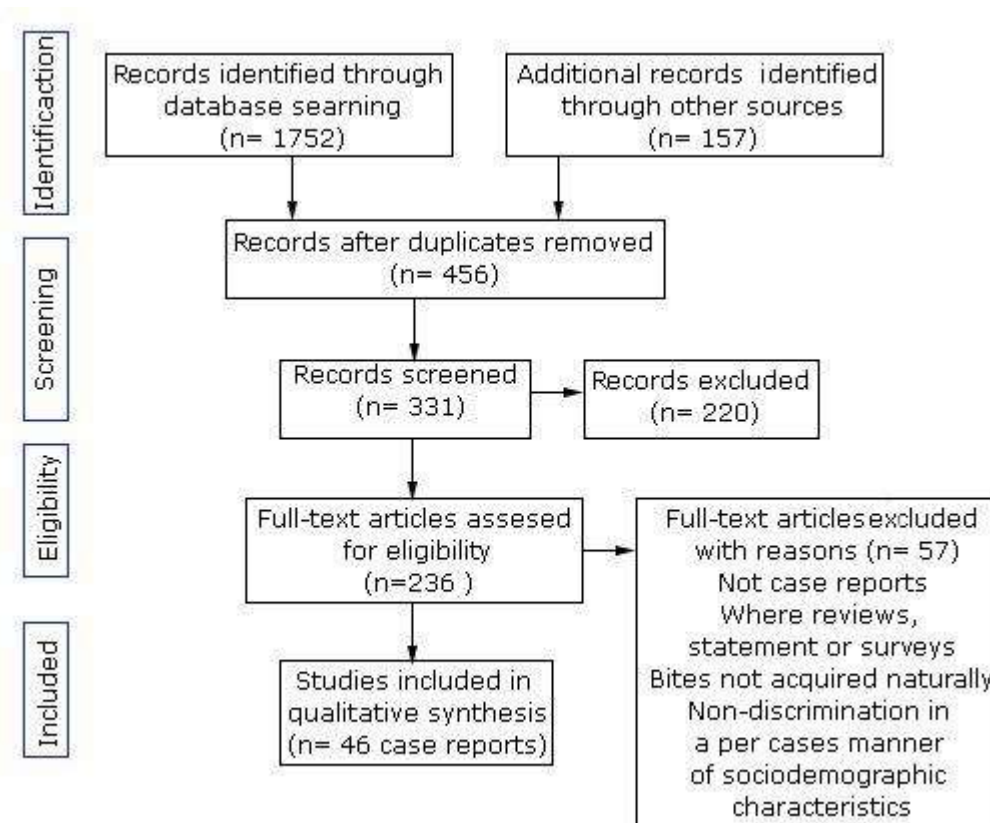
The data extracted were summarized as means with standard deviation for quantitative variables and as number and percentage for qualitative variables, as appropriate. Comparisons between groups were performed using the chi-square test or Fisher's exact test,

depending on the case. All analyses were performed using the statistical package Stata, version 13.0 (Stata Corp LP, College Station, TX, USA).

## Results

### Description of included studies and data obtained

The systematic literature searches yielded 1909 studies (Fig. 1). Among these, 1453 duplicates were excluded. On screening titles and abstracts for relevance, 220 studies were excluded, giving a total of 236 full texts that were assessed. Of these, 46 studies met the inclusion criteria.



From: Moher D, Liberati A, Tetzlaff J, Altman DG. Preferred reporting items for systematic reviews and meta-analyses: the PRISMA statement. PLoS Med 6(7): e1000097. doi.10.1371/journal.pmed.1000097

**Fig. 1** - PRISMA strategy and results.

Of the 46 included studies, 30 case reports and 16 case series reported a total of 95 cases. The 95 cases included in this review had an average age of 36.1±25.5 years old and 48 were women (50.5%). Tables 1 shows some sociodemographic characteristics of the cases

included in this study, as well as the outcome of the case and the involved ant species in a regional basis. Table 2 shows the signs and symptoms registered in the different reports.

**Table 1** - Case Reports, Sociodemographic characteristics, Country and Ant Species involved from the different regions of the World

Case Reports, Sociodemographic characteristics and Ant Species from Africa								
#	Continent	Country	Ref.	Year	Sex	Age (years)	Species involved	Outcome
1	Africa	Uganda	(26)	2010	M	40	<i>Dorylus</i> sp.	Alive
Case Reports, Sociodemographic characteristics, Country and Ant Species involved from Asia								
#	Continent	Country	Ref.	Year	Sex	Age (years)	Species involved	Outcome
2	Asia	Saudi Arabia	(27)	2009	1 Male	34	<i>Pachycondyla senaarensis</i>	Alive
					3 Females	34.3±12.7		
3	Asia	Korea	(28)	1999	F	44	<i>Pachycondyla (Incertae sedis) solitaria</i>	Alive
4	Asia	Taiwan	(29)	2015	M	7	<i>Polyrachis dives</i>	Alive
5	Asia	India	(30)	2012	M	1 and a half years old	<i>Solenopsis geminata</i>	Alive
6	Asia	Thailand	(31)	2012	M	10	<i>Oecophylla smaragdina</i>	Alive
7	Asia	Sri Lanka	(32)	2011	3 Females	29±1.7	Unknown	Alive
							<i>Tetraponera nigra</i>	Alive
							<i>Odontomachus simillimus</i>	Alive
8	Asia	Japón	(33)	2002	M	20	<i>Brachyponera chinensis</i>	Alive
9	Asia	Iran	(34)	2004	F	32	<i>Pheidole</i> sp.	Alive
10	Asia	Iran	(35)	2008	M	35	<i>Pheidole</i> sp.	Alive
11	Asia	Iran	(36)	2004	M	29	<i>Pheidole pallidula</i>	Alive
					F	25		
12	Asia	Iran	(37)	2003	M	18	<i>Pheidole</i> sp.	Alive
					F	31		
13	Asia	Korea	(38)	2005	2 Females	52±8.5	<i>Monomorium pharaonis</i>	Alive
14	Asia	Saudi Arabia	(39)	2006	F	32	<i>Pachycondyla senaarensis</i>	Alive
15	Asia	Taiwan	(40)	2014	M	21	<i>Solenopsis invicta</i>	Alive
Case Reports, Sociodemographic characteristics, Country and Ant Species involved from Europe								
#	Continent	Country	Ref.	Year	Sex	Age (years)	Species involved	Outcome

16	Europe	Spain	(41)	2007	F	27	<i>Solenopsis invicta</i>	Alive
17	Europe	Italy	(42)	2011	M	4	<i>Crematogaster scutellaris</i>	Alive
18	Europe	Italy	(43)	2008	M	14	<i>Pheidole pallidula</i>	Alive
<b>Case Reports, Sociodemographic characteristics, Country and Ant Species involved from North America</b>								
#	Continent	Country	Ref.	Year	Sex	Age (years)	Species involved	Outcome
19	North America	United States	(44)	1998	M	26-month-old	<i>Solenopsis invicta</i>	Alive
20	North America	United States	(45)	1995	3 Females	46±40.9	<i>Solenopsis invicta</i>	1 Death
21	North America	United States	(46)	2000	2 Males	29.5±17.7	<i>Solenopsis invicta</i>	Alive
					1 Female	81		
22	North America	United States	(47)	1971	M	49	<i>Solenopsis invicta</i>	Alive
23	North America	United States	(48)	1974	3 Males	24.5±14.8	<i>Solenopsis invicta</i>	Alive
							<i>Solenopsis xyloni</i>	
				1 Female	9	<i>Pogonomyrmex rugosus</i>		
24	North America	United States	(49)	1989	2 Males	48.5±24.5	<i>Solenopsis invicta</i>	Death
					2 Females	16.5±21.9		
25	North America	United States	(50)	1975	1 Female	27	<i>Solenopsis</i> spp.	Alive
					4 Males	14±15.1	<i>Solenopsis richteri</i>	
26	North America	United States	(51)	1974	F	25	<i>Solenopsis invicta</i>	Alive
27	North America	United States	(52)	2009	M	40	<i>Solenopsis xyloni</i>	Alive
28	North America	Canada	(53)	2013	F	43	<i>Solenopsis</i> sp.	Alive
29	North America	United States	(54)	2013	M	2	<i>Solenopsis invicta</i>	Alive
30	North America	United States	(55)	2015	F	43	<i>Formica rufa</i>	Alive
31	North America	United States	(56)	2008	F	3 months old	<i>Solenopsis xyloni</i>	Death
32	North America	United States	(57)	1992	M	19 months old	<i>Solenopsis invicta</i>	Alive
33	North America	United States	(58)	2004	2 Males	66±8.5	<i>Solenopsis</i> sp.	5 Death
					5 Females	80±9.3		2 Females Alive
34	North America	United States	(59)	2006	5 Males	40.6±36.4	<i>Solenopsis</i> sp.	3 Males Death

					4 Females	79±10.4		3 Females Death
35	North America	United States	(60)	1999	M	60	<i>Solenopsis</i> sp.	Alive
					F	67		Death
36	North America	United States	(61)	2005	M	41	<i>Pogonomyrmex rugosus</i>	Alive
37	North America	United States	(62)	1997	F	33.5±0.7	<i>Solenopsis xyloni</i>	Alive
							<i>Solenopsis aurea</i>	Alive
							<i>Solenopsis geminata</i>	Alive
<b>Case Reports, Sociodemographic characteristics, Country and Ant Species involved from South America</b>								
38	South America	Brazil	(63)	2015	F	42	<i>Solenopsis invicta</i>	Alive
39	South America	Bolivia	(64)	2007	2 Males	55	<i>Pseudomyrmex</i> sp.	Alive
						Unknown		
40	South America	Venezuela	(65)	2010	M	32	<i>Odontomachus bauri</i>	Alive
41	South America	Venezuela	(66)	2002	F	8	<i>Odontomachus bauri</i>	Alive
42	South America	Brazil	(67)	2010	M	52	<i>Pachycondyla goeldii</i>	Alive
43	South America	Brazil	(68)	2005	M	64	<i>Dinoponera gigantea</i>	Alive
<b>Case Reports, Sociodemographic characteristics, Country and Ant Species involved from Oceania</b>								
#	Continent	Country	Ref.	Year	Sex	Age (years)	Species involved	Outcome
44	Oceania	Australia	(69)	2006	4 Males	15.5±21.7	<i>Myrmecia gratiosa</i>	Alive
					6 Females	36.3±25.9	<i>Myrmecia nigriceps</i>	
							<i>Myrmecia ludlowi</i>	
45	Oceania	Australia	(70)	2012	F	4	<i>Rhytidoponera metallica</i>	Alive
46	Oceania	Australia	(71)	2002	M	47	<i>Solenopsis invicta</i>	Alive

Regarding clinical manifestations, it was found that the most frequently reported complications were Severe pain, Anaphylaxis and Acute Respiratory Distress Syndrome. The death of eighteen patients was documented (18.9%), all of these reported fatalities originated from the United States of America, although deaths secondary to ant attacks must have occurred elsewhere. Ants from the genera *Solenopsis* spp, *Myrmecia pilosula*, *Paraponera clavata*, *Pachycondyla sennaarensis*, *Brachyponera chinensis*, *Myrmecia rubra*, *Pseudomyrmex* spp. caused most of the accidents.



Results found in this review by region were the following:

- **Asia:** In this region of the included cases 64.2% were Male. 14 cases were included. The countries of origin were Iran, Korea, Taiwan, Sri Lanka, India and Thailand. The average age of the cases was  $25.6\pm 13.4$ . *Pachycondyla* sp., *Polyrachis* sp., *Solenopsis* sp., *Oecophylla* sp., *Barchyponera* sp., *Pheidole* sp. and *Monomorium* sp.
- **Africa:** Just one report, a 40 years old Male from Uganda, with a case produce by *Dorylus* sp.
- **Europe:** 3 reports, one from Spain the others from Italy, with a mean age of  $15\pm 11.5$ , 66% female. Involved genus: *Solenopsis* sp., *Crematogaster* sp. and *Pheidole* sp.
- **North America:** A total of 19 reports (18 from the United States of America, 1 from Canada), 47.3% were women, Mean age of  $36.4\pm 28.5$  years-old. *Solenopsis* sp, *Formica* sp. and *Pogonomyrmex* sp.
- **South America:** 6 cases, 4 Males 2 females, mean age of  $42.1\pm 20$  years. Genus involved: *Solenopsis* sp., *Pseudomyrmex* sp., *Pachycondyla* sp., *Odontomachus* sp. and *Dinoponera* sp.
- **Oceania:** 3 reports from Australia, 2 males 1 Female, mean age  $18\pm 25$ . Genus involved: *Myrmecia* sp. *Rhytidoponera* sp. and *Solenopsis* sp.

**Table 2 - Signs and symptoms registered in the case reports included in this review**

Skin	Nervous System	Cardiopulmonary system	Digestive System	Other
Alopecia	Blurred vision	Apnea	Abdominal pain	Anaphylaxis or Anaphylactic shock
Burning sensation	Cerebral ischemia	Asthma	Bloody stools	Anuria
Diaphoresis (Sweating)	Collapse	Cardiac congestive failure	Dysphagia	Conjunctival injection
Erythematous lesions (macules)	Confusion	Cardiopulmonary arrest	Emesis	Corneal damage
Facial angioedema	Convulsion	Cardiopulmonary failure	Persisten lump in throat	Glassy eyes
Generalize erythema	Dizziness	Chest pain	Vomiting	Incontinence
Localize Edema	Drowsiness	Chest tightness		Lymphadenopathy
Localize Pain	Fainting	Cough		Malaise
Maculopapular rash	Hypo-reactivity	Cyanosis		Rhabdomyolisis
Necrosis	Hypotonia	Desaturation		Swollen eyelids and lips
Pain	Nightmares	Dyspnea		Renal tubular necrosis
Pruritus	Presyncope	Feeble pulses		Uremic haemolytic syndrome
Pustules	Stroke	Hypotension		
Scarring	Unconsciousness	Irregular respiratory rate		
Secondary infection	Vertigo	Laryngeal edema		
Urticaria	Letargy	Nasal congestion		
Urticiform plaques		Respiratory distress		
Vesicles		Respiratory failure		
Wheal and Flare reactions		Rhinorrea		
Facial flushing		Shortness of Breath		
		Swelling of Upper Airways (Laryngeal edema)		
		Tachycardia		
		Tight or Swollen throat		
		Wheezing		
		Dysphonia		

Additionally, in this systematic review it was found that 40% of the reports originated from the United States of America, followed by Iran (8.6%), Australia (6.5%) and Brazil (6.5%), the majority of reports (76%) were published posterior to the year 2000, 21 from 2000 to 2009 and 14 from 2010 to 2018. At last, in an study published by from Klotz *et al.*,<sup>(72)</sup> cases were registered from Europe (*Formica rufa*), Australia (*Myrmecia pilosula*, *Myrmecia forficata*, *Myrmecia pyriformis*), Tasmania, Korea (*Brachyponera chinensis*, *Pachycondyla (Ectonomymex) sp.*), Japan (*Brachyponera chinensis*), Venezuela

(*Odontomachus bauri*) and the United States (*Hypoponera punctatissima*, *Solenopsis aurea*, *Solenopsis xyloni*, *Solenopsis geminata*, *Tetramorium* sp, *Pogonomyrmex maricopa*, *Pogonomyrmex barbatus*, *Pseudomyrmex ejectus*) some of those from different species than those found in this review.

## Global distribution of medically important ants according to the Systematic Literature Review

Table 3 shows a summary of the medically important ants divided by the regions in which reports have been written based on the findings of the systematic research of literature.

**Table 3** - Distribution of ant species and medical Importance based on the Information found in this Review

Africa	Asia	Europe	South America	North America	Oceania
<i>Cataglyphis bicolor</i>	<i>Brachyponera chinensis</i>	<i>Crematogaster scutellaris</i>	<i>Atta</i> sp.	<i>Formica rufa</i>	<i>Myrmecia forficata</i>
<i>Dorylus</i> spp.	<i>Monomorium pharaonis</i>	<i>Formica rufa</i>	<i>Dinoponera gigantea</i>	<i>Formica rufa</i>	<i>Myrmecia gratioiosa</i>
<i>Pachycondyla sennaarensis</i>	<i>Odontomachus similimus</i>	<i>Monomorium pharaonis</i>	<i>Eciton</i> sp.	<i>Hypoponera punctatissima</i>	<i>Myrmecia ludlowi</i>
	<i>Oecophylla smaradigna</i>	<i>Solenopsis invicta</i>	<i>Hypoponera punctatissima</i>	<i>Pogonomyrmex barbatus</i>	<i>Myrmecia nigriceps</i>
	<i>Pachycondyla goeldii</i>	<i>Solenopsis fugax</i>	<i>Odontomachus bauri</i>	<i>Pogonomyrmex maricopa</i>	<i>Myrmecia pilosula</i>
	<i>Pachycondyla (Ectonomymex) sp.</i>	<i>Tetramorium caespitum</i>	<i>Pachycondyla goeldii</i>	<i>Pogonomyrmex rugosus</i>	<i>Myrmecia pyriformis</i>
	<i>Pachycondyla</i> (Incertae sedis) solitaria		<i>Paraponera clavata</i>	<i>Pseudomyrmex ejectus</i>	<i>Rhytiponera metallica</i>
	<i>Pachycondyla sennaarensis</i>		<i>Pseudomyrmex</i> sp.	<i>Pseudomyrmex</i> sp.	<i>Solenopsis invicta</i>
	<i>Pheidole pallidula</i>		<i>Solenopsis invicta</i>	<i>Solenopsis aurea</i>	
	<i>Pheidole</i> sp.		<i>Wasmannia auropunctata</i>	<i>Solenopsis fugax</i>	
	<i>Polyrachis dives</i>			<i>Solenopsis geminata</i>	
	<i>Solenopsis geminata</i>			<i>Solenopsis geminata</i>	
	<i>Solenopsis</i> sp.			<i>Solenopsis richteri</i>	
	<i>Tetraponera nigra</i>			<i>Solenopsis</i> sp.	
	<i>Trichomyrmex (Monomorium) destructor</i>			<i>Solenopsis xyloni</i>	
				<i>Tetramorium</i> sp.	
				<i>Wasmannia auropunctata</i>	
				<i>Pogonomyrmex rugosus</i>	
				<i>Solenopsis fugax</i>	

## Africa

In this continent, Safari ants (*Dorylus* spp.), also known as Siafu, Army or Driver ants, are characterized by having colonies with millions of individuals capable of causing ulcers secondary to biting<sup>(26)</sup> and anaphylaxis by injecting venom in multiple stings.<sup>(41)</sup> Allergic reactions can also be caused by *Cataglyphis* sp.<sup>(73)</sup> and *Pachycondyla senaarensis*,<sup>(39)</sup> the latter with severe anaphylactic reactions.<sup>(74)</sup>

## South America

In this region of the world systemic reactions are caused in general by ants of the genera *Solenopsis* sp. (Fire Ants, “Hormiga Colorada”), *Pseudomyrmex* sp. (Novice ants) and *Paraponera* sp. (Tocandira or Bullet Ants).<sup>(9)</sup> A clinical condition, first diagnosed in 1968,<sup>(75)</sup> called West Indian Punctate Keratopathy<sup>(76)</sup> is in reality caused by *Wasmannia auropunctata*<sup>(77)</sup> which can cause leukomas.<sup>(78)</sup> Fire Ants, as well, can cause damage to the cornea.<sup>(79)</sup> Other important ants are: *Pseudomyrmex* spp.,<sup>(64)</sup> *Odontomachus bauri*<sup>(65)</sup> and *Pachycondyla goeldii*.<sup>(67)</sup> On the other hand, *Dinoponera gigantea*<sup>(80)</sup> can cause mechanical damage.

## North America

In the United States the most commonly involved ants are the Red Fire Ants (*Solenopsis invicta*) and the Black Fire Ants (*Solenopsis richteri*). These ants arrived in the first half of the XX century through the port of Mobile, Alabama.<sup>(81)</sup> The sting of this ant causes pustules with a clear clinic pathologic evolution.<sup>(81)</sup> This ant has invaded at least 14 states.<sup>(82)</sup> Such attacks can be fatal.<sup>(83)</sup> In infested areas the frequency of stings per month<sup>(84)</sup> and annual attack rate are high.<sup>(85)</sup> In addition, cutaneous sporotrichosis caused secondary to stings of this kind of ants has been reported.<sup>(86)</sup> Several other species of ants of medical importance in this region have been reported.<sup>(52,87)</sup> In Canada, the first reported case of Fire ant attack was documented in 2013.<sup>(88)</sup> The attacks of these ants have been documented in all age groups and in all places and settings.<sup>(54,89)</sup>

## Asia

In Asia, medically important species belong to the genus: *Pachycondyla* sp.,<sup>(27,90)</sup> *Polyrachis dives*<sup>(91)</sup> and *Solenopsis geminate* (30). Weaver Ants eggs have also been involved in allergic reactions.<sup>(92)</sup> Other less common ants belong to the following genus: *Tetraponera* sp., *Odontomachus* sp.<sup>(32)</sup> and *Brachyponera* sp.<sup>(93)</sup> In the Middle East the Black Samsun Ant<sup>(94)</sup> is one of the most important causes of allergies. Ants of the species *Pheidole* sp., which are believed to be lipophilic, can cause alopecia.<sup>(34-36)</sup> Allergic reactions to *Monomorium pharaonis* have also been reported.<sup>(95)</sup>

## Oceania

In Australia, *Myrmecia pilosula*,<sup>(96)</sup> *Rhytidoponera metallica*<sup>(97)</sup> and *Myrmecia pyriformis* are considered dangerous.<sup>(90)</sup> *Solenopsis invicta* has caused anaphylaxis cases<sup>(71)</sup> and deaths.<sup>(98)</sup> Other ants to which patients have shown hypersensitivity belong to the genus *Myrmecia* sp.<sup>(99)</sup> *Solenopsis geminata* have caused allergic vasculitis in Indonesia.<sup>(100)</sup>

## Europe

In Italy, the most frequent insects causing cutaneous allergies were ants of the species *Solenopsis fugax* and *Monomorium destructor*.<sup>(101)</sup> Allergic reactions have been reported caused by *Solenopsis invicta*,<sup>(102)</sup> *Crematogaster scutellaris*<sup>(42)</sup> and *Formica rufa*.<sup>(103)</sup> In

Italy a case of alopecia caused by ants of the species *Pheidole pallidula* (Barber ant) on an Italian adolescent when he acquired the infestation in Iran.<sup>(43)</sup>

### Ants as Mechanical Vectors

These insects can be mechanical vectors of many pathogens<sup>(104)</sup> and can be pests in hospitals.<sup>(105)</sup> A study conducted in Brazil, found that at least 19 species of ants belonging to 5 subfamilies infested hospitals and nosocomial settings, including species of *Acromyrmex* sp., *Labidus* sp., and *Solenopsis* sp.,<sup>(106)</sup> associated bacteria include *Bacillus* spp., *Listeria* spp., *Arcanobacterium* spp., *Streptococcus* spp., *Pseudomonas aeruginosa* among others.<sup>(107)</sup> Also they can transport this nosocomial bacteria to the community.<sup>(108)</sup>

### Ants in the Forensic Field

Formicidae are also important in the forensic field being active in several if not all the stages of the decomposition process. For example, if we consider that this process can be divided in 5 stages (Fresh carcass, Bloated, Active, Advanced and the final stage Remains),<sup>(109)</sup> several genera of ants (*Camponotus* sp., *Cephalotes* sp., *Solenopsis* sp., amongst others) are the most prominent insect species in the first two stages. In this invasion ants influenced the time of decomposition of the carcasses and preyed on eggs and larvae of *Diptera* delaying colonization and decomposition.<sup>(110)</sup> Additionally, ants are capable of producing post-mortem injuries specially in the early period<sup>(111)</sup> that can cause post-mortem bleeding<sup>(112)</sup> and injuries that can be confused of being done in an antemortem setting,<sup>(113)</sup> obscuring the estimation of the postmortem interval.<sup>(114)</sup> The invasion of dead bodies have been documented in other locations involving similar genera.<sup>(115)</sup> On the other hand, ants can aid in the forensic investigation, the analysis of such insects, in this case the species *Lasius fuliginous*, led to the identification of the crime scene.<sup>(116)</sup>

### Ants as Biomarkers of Environmental Degradation

Ants also can be used to determine the state of environmental health; in Brazil, for example a study in Mato Grosso found that species of *Camponotus (Mymaphaenus)* sp. and *Forelius brasiliensis* can be considered bioindicators of environmental degradation whereas *Camponotus atriceps*, *Pachycondyla crassinoda* and *Paraponera clavata* are associated to preserved environmental condition.<sup>(117)</sup>

### Ants as Pests in Insectariums

It has been shown that ants can be detrimental and damaging to the species of arthropods contained in insectariums. One of such examples are the species *Tapinoma melanocephalum* which is capable of eating the eggs of different species of Mosquitos (for example *Aedes aegypti*) and Triatomine bugs (for example *Triatoma flavida*).<sup>(118)</sup>

An infographic summarizing the findings of these review can be found in figure 2.

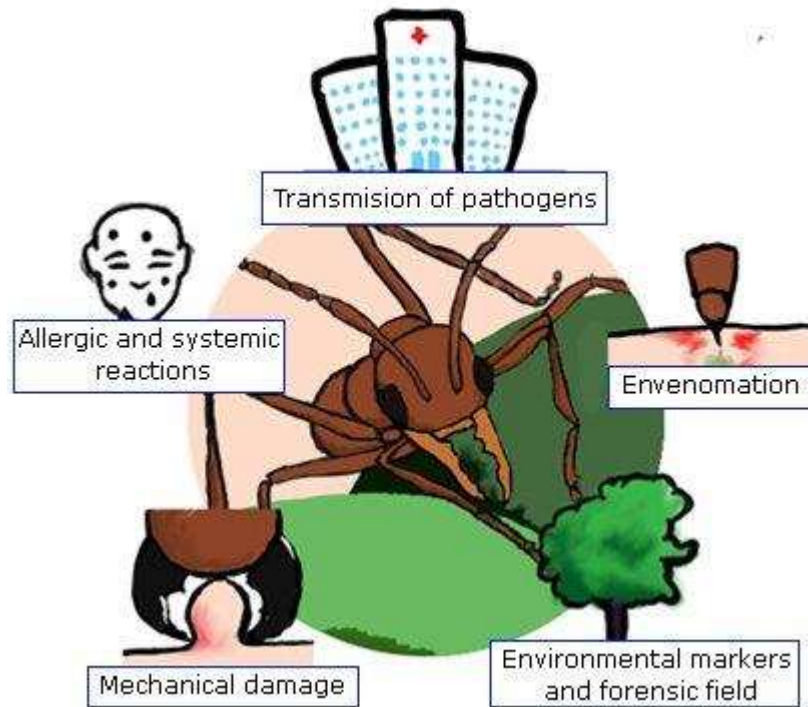


Fig. 2 - Infographic of the Medical Importance of Ants.

## Discussion

This comprehensive systematic review provides an overview of the ants of medical importance, their distribution and effects of the sting on human health, which can lead to death. Although not all ant stings lead to allergic reactions, some species have the capacity to generate an allergic response with a range of clinical presentations, which may include local reactions to serious systemic reactions such as anaphylactic shock. Although these events are rare, once they occur, mortality is high.

Our results show that there are different species of ants that can generate important consequences in human health. These ants are distributed worldwide and can affect people in any age range and sex. In this review no difference in the reports between sexes was found.

The contact of humans with this type of insects and other arthropods,<sup>(119)</sup> is increasing, and in turn increases the number of accidents. This increase is the result of urban expansion, the accumulation of garbage that attracts insects, and the incredible capacity of the Formicidae superfamily to adapt to diverse environments, from humid forests to deserts.<sup>(23)</sup>

Despite their importance they are a little studied group, they have not received the due attention from the researchers; it is necessary to know much more about ants and the Order Hymenoptera. There is still controversial evidence about possible cross-reactions between different poisons of different species,<sup>(120)</sup> the evolutionary relationship of such poisons across genera and the distribution of attacks around the world.<sup>(121,122)</sup>

The clinical effects caused by ant stings can range from localized reactions with clinical manifestations such as pain, papules, vesicles, pustules and ulcers to systemic reactions with blurred vision, dizziness, vomiting, diarrhea and anaphylaxis,<sup>(9)</sup> also coma<sup>(123)</sup> or alterations

during pregnancy,<sup>(124)</sup> reactions with varying degrees of severity,<sup>(125)</sup> which can have fatal consequences.<sup>(126)</sup> These systemic reactions, that can be immediate<sup>(127)</sup> or not existent,<sup>(128)</sup> are important in children,<sup>(129)</sup> and are usually caused by allergens present in the venom of some genera of ants (for example *Solenopsis* sp., *Pachycondyla* sp., and *Myrmecia* sp.). These allergens are different between genera and are composed of biogenic amines, cytotoxic and neurotoxic peptides (melittin, apamin, mastoparan) as well as proteins (for example phospholipase A).<sup>(130,131)</sup>

The venom of Fire Ants (*Solenopsis* sp.), which are one of the most studied ants groups,<sup>(81)</sup> because this species has invaded several countries around the world in the continents of America, Europe, Asia and Oceania. It is an aggressive genus that have displace the indigenous species and are responsible for vicious indoors and outdoors attacks and have proven to be a difficult to control ant, with over 70 years of foothold in the United States. Although its global importance has already been documented,<sup>(10)</sup> have a venom with at least have at least four different groups of allergens, each with different functions, primarily enzymes and proteins.<sup>(97)</sup> This venom have cross reactivity across species of the same genera<sup>(132)</sup> and other members of the order,<sup>(133)</sup> although cross reactivity with other genera of ants have controversial evidence.<sup>(134)</sup> For the management of the allergic reactions there is an existent therapy to desensitize the patients,<sup>(135)</sup> although there are designed patterns of administration,<sup>(136,137)</sup> there is contradicting evidence of the effectivity of this therapy.<sup>(138)</sup> At last, the epidemiology of attacks and its distribution in central and south America is all but unknown, although attempts to identify and clarify such aspects of their ecoepidemiology.<sup>(139)</sup>

Lastly, ants carry a several number of potentially serious pathogens,<sup>(140)</sup> one of the first reports of this aspect of its biology was published in the seventies involving Pharaoh's ants (*Monomorium pharaonis*) in the United Kingdom<sup>(141)</sup> and Germany.<sup>(142)</sup> Circumstance that is increasingly important<sup>(16)</sup> given that other ants have been identified as carriers of this poison and have been found in places considered clean, such as nurseries and food depots.<sup>(17)</sup> The main limitations of this study include a possible publication bias because less significant findings are less likely to be published, and that may have inflated estimates of mortality. On the other hand, information on the clinical manifestations and comorbidities of the patients was limited, which have a strong impact on mortality. In addition, there were case reports, which are known to have low methodological quality and are not representative of the population.

In conclusion, the systematic review conducted in this study indicates that severe allergic reactions caused by the bite/sting of ants are a rare event, however, once they occur, mortality is high. It is expected to increase the number of accidents of ants of medical interest with humans, for which it is necessary to quickly diagnose and treat cases adequately and thus avoid a death. All the clinical manifestations that can be caused by the bite/sting of ants are unknown. It is important to mention that only a small percentage of the ant species are of medical interest and some species are of great importance in other fields of knowledge.

## Bibliographic references

1. Abdelrahman RZ, Mohamad HM, Morsy AT, Morsy TA. Allergic Reactions Caused By Venom Of Hymenopterous Stinging Insects And The Role Of Health Care Workers. *Journal of the Egyptian Society of Parasitology*. 2015;45(2):403-12.
2. Hölldobler B, Wilson EO. *The ants*. Cambridge, MA: Harvard University Press; 1990.
3. Potiwat R, Sitcharungsi R. Ant allergens and hypersensitivity reactions in response to ant stings. *Asian Pacific Journal of Allergy and Immunology*. 2015;33(4):267-75.
4. Alonso LE, Agosti D. *Biodiversity studies, monitoring, and ants: an overview*. Washington: Smithsonian Institution Press; 2000.
5. Bragança MAL, Lima JD. Composição, abundância e índice de infestação de espécies de formigas em um hospital materno-infantil de Palmas, TO. *Neotropical Entomology*. 2010;39(1):124-30.
6. Lutinski JA, Lutinski CJ, Cortés Lopes B, Barros de Moraes AB. Estrutura da comunidade de formigas (Hymenoptera: Formicidae) em quatro ambientes com diferentes níveis de perturbação antrópica. *Ecol Austral*. 2014;24(2):229-37.
7. Tracy JM. *Insect allergy*. The Mount Sinai journal of medicine, New York. 2011;78(5):773-83.
- Haddad Junior V, Cardoso JLC, França FODS, Wen FH. Acidentes por formigas: um problema dermatológico. *An Bras Dermatol*. 1996;71(6):527-30.
9. Costa AG, Chaves BA, Murta FLG, Sachett JAG, Sampaio VS, Silva VC, et al. Hymenoptera stings in Brazil: A neglected health threat in Amazonas state. *Rev Soc Bras Med Trop*. 2018;51(1):80-4.
110. Ascunce MS, Yang CC, Oakey J, Calcaterra L, Wu WJ, Shih CJ, et al. Global invasion history of the fire ant *Solenopsis invicta*. *Science (New York, NY)*. 2011;331(6020):1066-8.
11. Al Gazlan S. RE: Black ant stings caused by *Pachycondyla sennaarensis*: A significant health hazard. *Annals of Saudi Medicine*. 2010;30(3):245-6.
12. Sampson HA, Munoz-Furlong A, Campbell RL, Adkinson NF, Jr., Bock SA, Branum A, et al. Second symposium on the definition and management of anaphylaxis: summary report--Second National Institute of Allergy and Infectious Disease/Food Allergy and Anaphylaxis Network symposium. *The Journal of Allergy and Clinical Immunology*. 2006;117(2):391-7.
13. Alsowaidi S, Hana AA, Zarouni KM, Zaabi AHA, Abdulle A. Anaphylactic patient characteristics, clinical features, and current practice in the emergency unit. *Biomed Res*. 2010;21(4):406-10.
14. Golden D. Stinging insect allergy. *Am Fam Phys*. 2003;67(12):2541-6.
15. Santos PFd, Fonseca AR, Sanches NM. Formigas (Hymenoptera: Formicidae) como vetores de bactérias em dois hospitais do município de Divinópolis, Estado de Minas Gerais. *Rev Soc Bras Med Trop*. 2009;42(5):565-9.
16. Pereira RdS, Ueno M. Formigas como veiculadoras de microrganismos em ambiente hospitalar. *Rev Soc Bras Med Trop*. 2008;41(5):492-5.



17. Moreira DDO, Morais Vd, Vieira-da-Motta O, Campos-Farinha AEdC, Tonhasca Jr A. Ants as carriers of antibiotic-resistant bacteria in hospitals. *Neotropical Entomology*. 2005;34(6):999-1006.
18. Heinen TE, da Veiga AB. Arthropod venoms and cancer. *Toxicon*. 2011;57(4):497-511.
19. Way MJ, Javier G, Heong KL. The role of ants, especially the fire ant, *Solenopsis geminata* (Hymenoptera: Formicidae), in the biological control of tropical upland rice pests. *Bulletin of entomological research*. 2002;92(5):431-7.
20. Trowell HC. Ants distinguish diabetes mellitus from diabetes insipidus. *British Medical Journal (Clinical Research ed)*. 1982;285(6336):217.
21. Haddad FS. Suturing methods and materials with special emphasis on the jaws of giant ants (an old-new surgical instrument). *The Lebanese Medical Journal*. 2010;58(1):53-6.
22. Kallmeyer V, Hershman MJ, Champion KM. [Wound closure with giant ants. Remedies and therapeutic methods in American Indian medicine]. *Fortschritte der Medizin*. 1985;103(35):86-7.
23. Turillazzi S, Turillazzi F. Climate changes and Hymenoptera venom allergy: are there some connections? *Current opinion in allergy and clinical immunology*. 2017;17(5):344-9.
24. Luber G, Prudent N. Climate Change and Human Health. *Trans Am Clin Climatol Assoc*. 2009;120:113-7.
25. Allen O. Anthill and other injuries: a case for mobile allied health teams to remote Australia. *The Australian Journal of Rural Health*. 1996;4(1):33-42.
26. Chianura L, Pozzi F. Case report: A 40-year-old man with ulcerated skin lesions caused by bites of safari ants. *The American Journal of Tropical Medicine and Hygiene*. 2010;83(1):9.
27. AlAnazi M, AlAshahrani M, Alsalamah M. Black ant stings caused by *Pachycondyla sennaarensis*: A significant health hazard. *Annals of Saudi Medicine*. 2009;29(3):207-11.
28. Yun YY, Ko SH, Park JW, Hong CS. Anaphylaxis to venom of the *Pachycondyla species* ant. *The Journal of Allergy and Clinical Immunology*. 1999;104(4 Pt 1):879-82.
29. Chang HM, Chang GH. An Unexpected Foreign Body: A Hypopharyngeal Ant. *Otolaryngology-Head and Neck Surgery : official Journal of American Academy of Otolaryngology-Head and Neck Surgery*. 2015;153(4):683-4.
30. Havaladar PV, Patil SS, Phadnis C. Anaphylaxis due to Red fire ant bite. *Ind Pediatr*. 2012;49(3):237-8.
31. Chansakulporn S, Charoenying Y. Anaphylaxis to weaver ant eggs: a case report. *Journal of the Medical Association of Thailand = Chotmaihet Thangphaet*. 2012;95 Suppl 12:S146-9.
32. Ratnatilaka GA, Herath RR, Dias RK. Severe anaphylaxis following ant bites. *The Ceylon Medical Journal*. 2011;56(1):34-5.
33. Fukuzawa M, Arakura F, Yamazaki Y, Uhara H, Saida T. Urticaria and anaphylaxis due to sting by an ant (*Brachyponera chinensis*). *Acta Derm Venereol*. 2002;82(1):59.
34. Aghaei S, Sodaifi M. Circumscribed scalp hair loss following multiple hair-cutter ant invasion. *Dermatology Online Journal*. 2004;10(2):14.
35. Namazi MR, Jorizzo JL. Ant-induced alopecia: a case report and literature review. *Arch Dermatol*. 2008;144(11):1526-7.

36. Mortazavi M, Mansouri P. Ant-induced alopecia: report of 2 cases and review of the literature. *Dermatology Online Journal*. 2004;10(1):19.
37. Shamsadini S. Localized scalp hair shedding caused by Pheidole ants and overview of similar case reports. *Dermatology Online Journal*. 2003;9(3):12.
38. Kim CW, Choi SY, Park JW, Hong CS. Respiratory allergy to the indoor ant (*Monomorium pharaonis*) not related to sting allergy. *Annals of Allergy, Asthma & Immunology* : official Publication of the American College of Allergy, Asthma, & Immunology. 2005;94(2):301-6.
39. Al-Shahwan M, Al-Khenaizan S, Al-Khalifa M. Black (samsun) ant induced anaphylaxis in Saudi Arabia. *Saudi Medical Journal*. 2006;27(11):1761-3.
40. Lee YC, Wang JS, Shiang JC, Tsai MK, Deng KT, Chang MY, et al. Haemolytic uremic syndrome following fire ant bites. *BMC nephrology*. 2014;15:5.
41. Fernandez-Melendez S, Miranda A, Garcia-Gonzalez JJ, Barber D, Lombardero M. Anaphylaxis caused by imported red fire ant stings in Malaga, Spain. *J Investig Allergol Clin Immunol*. 2007;17(1):48-9.
42. Monti G, Cosentino V, Castagno E, Nebiolo F. Anaphylaxis caused by *Crematogaster cutellaris* sting in an Italian child. *J Investig Allergol Clin Immunol*. 2011;21(7):576-7.
43. Veraldi S, Lunardon L, Francia C, Persico MC, Barbareschi M. Alopecia caused by the "barber ant" *Pheidole pallidula*. *Int J Dermatol*. 2008;47(12):1329-30.
44. Amador M, Busse FK, Jr. Corneal injury caused by imported fire ants in a child with neurological compromise. *J Pediatr Ophthalmol Strabismus*. 1998;35(1):55-7.
45. deShazo RD, Williams DF. Multiple fire ant stings indoors. *South Med J*. 1995;88(7):712-5.
46. Reschly MJ, Ramos-Caro FA, Mathes BM. Multiple fire ant stings: report of 3 cases and review of the literature. *Cutis*. 2000;66(3):179-82.
47. Smith JD, Smith EB. Multiple fire ant stings. A complication of alcoholism. *Arch Dermatol*. 1971;103(4):438-41.
48. Lockey RF. Systemic reactions to stinging ants. *The Journal of Allergy and Clinical Immunology*. 1974;54(3):132-46.
49. Rhoades RB, Stafford CT, James FK, Jr. Survey of fatal anaphylactic reactions to imported fire ant stings. Report of the Fire Ant Subcommittee of the American Academy of Allergy and Immunology. *The Journal of Allergy and Clinical Immunology*. 1989;84(2):159-62.
50. Rhoades RB, Schafer WL, Schmid WH, Wubbena PF, Dozier RM, Townes AW, et al. Hypersensitivity to the imported fire ant: A report of 49 cases. *The Journal of Allergy and Clinical Immunology*. 1975;56(2):84-93.
51. Majeski JA, Durst GG, McKee KT. Acute systemic anaphylaxis associated with an ant sting. *South Med J*. 1974;67(3):365-6.
52. Klotz JH, Pinnas JL, Greenberg L, Quimayousie D, Schmidt JO, Klotz SA. What's eating you? Native and imported fire ants. *Cutis*. 2009;83(1):17-20.
53. Lee JK, Betschel SD. A case of the first documented fire ant anaphylaxis in Canada. *Allergy, Asthma, and Clinical Immunology* : official Journal of the Canadian Society of Allergy and Clinical Immunology. 2013;9(1):25.

54. Cochran J, McSwain SD, Evans M, Webb S, Tecklenburg F. Anaphylaxis and delayed hymenoptera in a child with fire ant envenomation. *Am J Emerg Med.* 2013;31(3):632.e1-3.
55. Asawa A, Simpson KH, Bonds RS. Ketotifen use in a patient with fire ant hypersensitivity and mast cell activation syndrome. *Annals of Allergy, Asthma & Immunology : official publication of the American College of Allergy, Asthma, & Immunology.* 2015;114(6):443-6.
56. More DR, Kohlmeier RE, Hoffman DR. Fatal anaphylaxis to indoor native fire ant stings in an infant. *The American Journal of Forensic Medicine and Pathology.* 2008;29(1):62-3.
57. Cohen PR. Imported fire ant stings: clinical manifestations and treatment. *Pediatr Dermatol.* 1992;9(1):44-8.
58. deShazo RD, Kemp SF, deShazo MD, Goddard J. Fire ant attacks on patients in nursing homes: an increasing problem. *The American Journal of Medicine.* 2004;116(12):843-6.
59. Rupp MR, deShazo RD. Indoor fire ant sting attacks: a risk for frail elders. *Am Journal Med Sci.* 2006;331(3):134-8.
60. deShazo RD, Williams DF, Moak ES. Fire ant attacks on residents in health care facilities: a report of two cases. *An Int Med.* 1999;131(6):424-9.
61. Klotz JH, Schmidt JO, Pinnas JL. Consequences of Harvester Ant Incursion into Urbanized Areas: A Case History of Sting Anaphylaxis. *Sociobiology.* 2005;45(3).
62. Hoffman DR. Reactions to less common species of fire ants. *The Journal of Allergy and Clinical Immunology.* 1997;100(5):679-83.
63. Haddad Junior V, Larsson CE. Anaphylaxis caused by stings from the *Solenopsis invicta*, lava-pes ant or red imported fire ant. *An Bras Dermatol.* 2015;90(3 Suppl 1):22-5.
64. Tórriz Salazar J, Tórriz Salazar JT, Taboada JE, Gutiérrez Méndez J, Avilés Armijo D, Tórriz Salazar J, et al. Insuficiencia Renal Aguda por picadura de hormigas del palo santo (*Pseudomyrmex* spp). *Gac Méd Bol.* 2007;30(1):50-3.
65. Rodríguez-Acosta A, Sánchez EE, Navarrete LF. Intensa reacción alérgica en paciente mordido por la hormiga negra (*Odontomachus bauri*). *Revista Cubana de Medicina Tropical.* 2010;62(1):117-24.
66. Rodríguez-Acosta A, Reyes-Lugo M. Severe human urticaria produced by ant (*Odontomachus bauri*, Emery 1892) (Hymenoptera: Formicidae) venom. *Int J Dermatol.* 2002;41(11):801-3.
67. Costa Manso E, Croce M, Pinto JR, Souza Santos K, Delazari Santos L, Baptista Dias N, et al. Anaphylaxis due to *Pachycondyla goeldii* ant: a case report. *J Investig Allergol Clin Immunol.* 2010;20(4):352-3.
68. Haddad Junior V, Cardoso JLC, Moraes RHP. Description of an injury in a human caused by a false tocandira (*Dinoponera gigantea*, Perty, 1833) with a revision on folkloric, pharmacological and clinical aspects of the giant ants of the genera *Paraponera* and *Dinoponera* (sub-family Ponerinae). *Rev Inst Med Trop Sao Paulo.* 2005;47:235-8.
69. Gilhotra Y, Brown SG. Anaphylaxis to bull dog ant and jumper ant stings around Perth, Western Australia. *Emergency Medicine Australasia : EMA.* 2006;18(1):15-22.
70. Mehr S, Brown S. A case of ant anaphylaxis. *J Paediatr Child Health.* 2012;48(3):E101-E4.

71. Solley GO, Vanderwoude C, Knight GK. Anaphylaxis due to Red Imported Fire Ant sting. *Med J Aust.* 2002;176(11):521-3.
72. Klotz JH, deShazo RD, Pinnas JL, Frishman AM, Schmidt JO, Suiter DR, et al. Adverse reactions to ants other than imported fire ants. *Annals of Allergy, Asthma & Immunology* : official publication of the American College of Allergy, Asthma, & Immunology. 2005;95(5):418-25.
73. Sanad EM, Helmy AZ, Morsy TA. Ant allergy in Benha District Qualyobia Governorate, Egypt. *J Egypt Soc Parasitol.* 2002;32(3):901-6.
74. Khalid M, El-Tawil M, Al-Musleh A, Alkilani H, Al-Khalout B. Black Ant Sting Allergy: A Clinical Problem in Qatar. *Mid East J Emerg Med.* 2000;1(2):14-5.
75. Rice NS, Jones BR, Ashton N. Punctate keratopathy of West Indians. *Br J Ophthalmol.* 1968;52(12):865-75.
76. Tucker G, Karpinski L, Fuseler J. Morphology and distribution of light-scattering granules in the corneas of South Florida cats. *J Cell Biol.* 1979;83:479A.
77. Galvis V, Tello A, Jaramillo LC, Paredes D, Camacho PA. Prevalence of Punctate Keratopathy of West Indians in a Colombian Referral Center and a New Name Proposed: Rice s Keratopathy. *The Open Ophthalmology Journal.* 2015;9:12-6.
78. Rosselli D, Wetterer JK. Stings of the Ant *Wasmannia auropunctata* (Hymenoptera: Formicidae) as Cause of Punctate Corneal Lesions in Humans and Other Animals. *Journal of Medical Entomology.* 2017;54(6):1783-5.
79. Amador M, Busse FK, Jr. Corneal injury caused by imported fire ants in a child with neurological compromise. *J Pediatr Ophthalmol Strabismus.* 1998;35(1):55-7.
80. Haddad Junior V, Cardoso JLC, Moraes RHP. Description of an injury in a human caused by a false tocandira (*Dinoponera gigantea*, perty, 1833) with a revision on folkloric, pharmacological and clinical aspects of the giant ants of the genera *Paraponera* and *Dinoponera* (sub-family *Ponerinae*). *Rev Inst Med Trop Sao Paulo.* 2005;47(4):235-8.
81. Villada G, Hafeez F, Ollague J, Nousari CH, Elgart GW. Imported fire ant envenomation: A clinicopathologic study of a recognizable form of arthropod assault reaction. *Journal of Cutaneous Pathology.* 2017;44(12):1012-7.
82. Steigelman DA, Freeman TM. Imported fire ant allergy: case presentation and review of incidence, prevalence, diagnosis, and current treatment. *Annals of Allergy, Asthma & Immunology* : official publication of the American College of Allergy, Asthma, & Immunology. 2013;111(4):242-5.
83. Prahlow JA, Barnard JJ. Fatal anaphylaxis due to fire ant stings. *The American Journal of Forensic Medicine and Pathology.* 1998;19(2):137-42.
84. Lofgren CS, Banks WA, Glancey BM. Biology and control of imported fire ants. *An Rev Entomol.* 1975;20:1-30.
85. Yeager W. Frequency of fire ant stinging in Lowndes County, Georgia. *Journal of the Medical Association of Georgia.* 1978;67(2):101-2.
86. Miller SD, Keeling JH. Ant sting sporotrichosis. *Cutis.* 2002;69(6):439-42.
87. Erickson TB, Cheema N. Arthropod Envenomation in North America. *Emerg Med Clin North Am.* 2017;35(2):355-75.
88. Lee JK, Betschel SD. A case of the first documented fire ant anaphylaxis in Canada. *Allergy, Asthma & Clinical Immunology.* 2013;9(1):25.

89. Bahna SL, Strimas JH, Reed MA, Butcher BT. Imported fire ant allergy in young children: skin reactivity and serum IgE antibodies to venom and whole body extract. *The Journal of Allergy and Clinical Immunology*. 1988;82(3 Pt 1):419-24.
90. Shek LP, Ngiam NS, Lee BW. Ant allergy in Asia and Australia. *Current Opinion in Allergy and Clinical Immunology*. 2004;4(4):325-8.
91. Chang HM, Chang GH. An Unexpected Foreign Body: A Hypopharyngeal Ant. *Otolaryngology Head Neck Surgery*. 2015;153(4):683-4.
92. Chansakulporn S, Charoenying Y. Anaphylaxis to weaver ant eggs: a case report. *Journal of the Medical Association of Thailand*. 2012;95 Suppl 12:S146-S9.
93. Fukuzawa M, Arakura F, Yamazaki Y, Uhara H, Saida T. Urticaria and anaphylaxis due to sting by an ant (*Brachyponera chinensis*). *Acta Dermato Venereologica*. 2002;82(1):59.
94. Alshami A, Adeli M, Alyafei K, Nisar S. Anaphylaxis presenting to the pediatric emergency centers in Qatar. *The Journal of Allergy and Clinical Immunology*. 2018;141(2):AB156.
95. Kim CW, Choi SY, Park JW, Hong CS. Respiratory allergy to the indoor ant (*Monomorium pharaonis*) not related to sting allergy. *Annals of Allergy, Asthma & Immunology*. 2005;94(2):301-6.
96. Valentine MD. Anaphylaxis and stinging insect hypersensitivity. *Jama*. 1992;268(20):2830-3.
97. Tankersley MS, Ledford DK. Stinging insect allergy: state of the art 2015. *J Allergy Clin Immunol Pract*. 2015;3(3):315-22; quiz 23.
98. McGain F, Winkel KD. Ant sting mortality in Australia. *Toxicon*. 2002;40(8):1095-100.
99. Brown SG, van Eeden P, Wiese MD, Mullins RJ, Solley GO, Puy R, et al. Causes of ant sting anaphylaxis in Australia: the Australian Ant Venom Allergy Study. *Med J Aust*. 2011;195(2):69-73.
100. Knight D, Bangs MJ. Cutaneous allergic vasculitis due to *Solenopsis geminata* (Hymenoptera: Formicidae) envenomation in Indonesia. *The Southeast Asian Journal of Tropical Medicine and Public Health*. 2007;38(5):808-13.
101. Stingeni L, Bianchi L, Hansel K, Neve D, Foti C, Corazza M, et al. Dermatitis caused by arthropods in domestic environment: an Italian multicentre study. *Journal of the European Academy of Dermatology and Venereology : JEADV*. 2017;31(9):1526-33.
102. Fernandez-Melendez S, Miranda A, Garcia-Gonzalez J, Barber D, Lombardero M. Anaphylaxis caused by imported red fire ant stings in Málaga, Spain. *J Investig Allergol Clin Immunol*. 2007.
103. Seebach JD, Bucher C, Anliker M, Schmid-Grendelmeier P, Wuthrich B. [Ant venoms: a rare cause of allergic reactions in Switzerland]. *Schweizerische medizinische Wochenschrift*. 2000;130(47):1805-13.
104. Silva LT, Pichara NL, Pereira MA, Fiorini JE. Formigas como veículo de patógenos no Hospital Universitário Alzira Velano, em Alfenas — MG. *Rev Med Minas Gerais*. 2005;15(1):13-6.
105. Gray KJ, Porter C, Hawkey PM, Compton SG, Edwards JP. Roger's ants: a new pest in hospitals. *BMJ (Clinical Research ed)*. 1995;311(6997):129.

106. Lutinski JA, Ahlert CC, De Freitas BR, Trautmann MM, Tancredo SP, Mello Garcia FR. Ants (Hymenoptera: Formicidae) in hospitals of southern Brazil. *Rev Colomb Entomol.* 2015;41(2):235-40.
107. Maximo HJ, Felizatti HL, Ceccato M, Cintra-Socolowski P, Beretta AL. Ants as vectors of pathogenic microorganisms in a hospital in Sao Paulo county, Brazil. *BMC Research Notes.* 2014;7:554.
108. Rodovalho CM, Santos AL, Marcolino MT, Bonetti AM, Brandeburgo MA. Urban ants and transportation of nosocomial bacteria. *Neotropical Entomology.* 2007;36(3):454-8.
109. Early M, Goff ML. Arthropod succession patterns in exposed carrion on the island of O'ahu, Hawaiian Islands, USA. *Journal of Medical Entomology.* 1986;23(5):520-31.
110. Ramos-Pastrana Y, Virgüez-DÍAz Y, Wolff M. Insects of forensic importance associated to cadaveric decomposition in a rural area of the Andean Amazon, Caquetá, Colombia. *Acta Amaz.* 2018;48(2):126-36.
111. Bonacci T, Vercillo V. Outdoor post-mortem bite injuries by *Tapinoma nigerrimum* (Hymenoptera, Formicidae) on a human corpse: Case report. *Journal of Forensic and Legal Medicine.* 2015;33:5-8.
112. Heath KJ, Byard RW. Ant activity as a source of postmortem bleeding. *Forensic Science, Medicine, and Pathology.* 2014;10(3):472-4.
113. Campobasso CP, Marchetti D, Introna F, Colonna MF. Postmortem artifacts made by ants and the effect of ant activity on decompositional rates. *The American Journal of Forensic Medicine and Pathology.* 2009;30(1):84-7.
114. Lindgren NK, Bucheli SR, Archambeault AD, Bytheway JA. Exclusion of forensically important flies due to burying behavior by the red imported fire ant (*Solenopsis invicta*) in southeast Texas. *Forensic Science International.* 2011;204(1-3):e1-3.
115. Ekanem MS, Dike MC. Arthropod succession on pig carcasses in southeastern Nigeria. *Papéis Avulsos de Zoologia (São Paulo).* 2010;50(35):561-70.
116. Benecke M, Seifert B. Forensic entomology exemplified by a homicide. A combined stain and postmortem time analysis. *Archiv fur Kriminologie.* 1999;204(1-2):52-60.
117. Rocha WdO, Dorval A, Peres Filho O, Vaez CdA, Ribeiro ES. Formigas (Hymenoptera: Formicidae) Bioindicadoras de Degradação Ambiental em Poxoréu, Mato Grosso, Brasil. *Floresta Ambient.* 2015;22(1):88-98.
118. Pérez O, Rodríguez J, Bisset J, Leyva M, Díaz M, Fuentes O, et al. Manual de indicaciones técnicas para insectarios. La Habana: Editorial Ciencias Médicas; 2004.
119. Ortiz EB, Prada, JR, Villamil Jimenéz LC. Las garrapatas del ganado bovino y los agentes de enfermedad que transmiten en escenarios epidemiológicos de cambio climático. IICA; 2016 [acceso: 07/06/2018]. Disponible en: <http://repiica.iica.int/docs/B4212e/B4212e.pdf>
120. Jakob T, Müller U, Helbling A, Spillner E. Component resolved diagnostics for hymenoptera venom allergy. *Current Opinion in Alergy and Clinical Immunology.* 2017;17(5):363-72.
121. Stahlhut JK, Fernández-Triana J, Adamowicz SJ, Buck M, Goulet H, Hebert PDN, et al. DNA barcoding reveals diversity of Hymenoptera and the dominance of parasitoids in a sub-arctic environment. *BMC Ecol.* 2013;13:2.

122. GABI. antmaps.org 2018 [acceso: 07/06/2018]. Disponible en: <http://www.antmaps.org>
123. Elhence GP, Singh MM, Hazra DK, Gopal K. Antemortem ants bite and coma. A case report. *Indian Journal of Medical Sciences*. 1970;24(11):745-7.
124. Rizk DE, Mensah-Brown E, Lukic M. Placental abruption and intrauterine death following an ant sting. *International Journal of Gynaecology and Obstetrics: the official organ of the International Federation of Gynaecology and Obstetrics*. 1998;63(1):71-2.
125. Owens VJ, Malloy C, Schuman S, Caldwell S, Bellamy D. Underrecognition of morbidity from stings of the red imported fire ant in the southeastern United States. *Public Health Nursing (Boston, Mass)*. 1990;7(2):88-95.
126. Bloom FL, DelMastro PR. Imported fire ant death. A documented case report. *The Journal of the Florida Medical Association*. 1984;71(2):87-90.
127. Bircher AJ. Systemic immediate allergic reactions to arthropod stings and bites. *Dermatology*. 2005;210(2):119-27.
128. Diaz JD, Lockey RF, Stablein JJ, Mines HK. Multiple stings by imported fire ants (*Solenopsis invicta*), without systemic effects. *South Med J*. 1989;82(6):775-7.
129. Levine M. Pediatric envenomations: don't get bitten by an unclear plan of care. *Pediatric Emergency Medicine Practice*. 2014;11(8):1-12.
130. Muller UR. Hymenoptera venom proteins and peptides for diagnosis and treatment of venom allergic patients. *Inflammation & Allergy Drug Targets*. 2011;10(5):420-8.
131. Alsharani M, Alanazi M, Alsalamah M. Black ant stings caused by *Pachycondyla sennaarensis*: a significant health hazard. *Annals of Saudi Medicine*. 2009;29(3):207-11.
132. Hoffman DR. Ant venoms. *Current Opinion in Allergy and Clinical Immunology*. 2010;10(4):342-6.
133. Hoffman DR, Dove DE, Moffitt JE, Stafford CT. Allergens in Hymenoptera venom. XXI. Cross-reactivity and multiple reactivity between fire ant venom and bee and wasp venoms. *The Journal of Allergy and Clinical Immunology*. 1988;82(5 Pt 1):828-34.
134. Hoffman DR. Hymenoptera venom allergens. *Clinical Reviews in Allergy & Immunology*. 2006;30(2):109-28.
135. Tille KS, Parker AL. Imported fire ant rush desensitization using omalizumab and a premedication regimen. *Annals of Allergy, Asthma & Immunology : official publication of the American College of Allergy, Asthma, & Immunology*. 2014;113(5):574-6.
136. Haymore BR, McCoy RL, Nelson MR. Imported fire ant immunotherapy prescribing patterns in a large health care system during a 17-year period. *Annals of Allergy, Asthma & Immunology : official publication of the American College of Allergy, Asthma, & Immunology*. 2009;102(5):422-5.
137. Dietrich JJ, Moore LM, Nguyen S, Hagan LL, Tankersley MS. Imported fire ant hypersensitivity: a 1-day rush immunotherapy schedule without premedication. *Annals of Allergy, Asthma & Immunology : official publication of the American College of Allergy, Asthma, & Immunology*. 2009;103(6):535-6.
138. Forester JP, Johnson TL, Arora R, Quinn JM. Systemic reaction rates to field stings among imported fire ant-sensitive patients receiving >3 years of immunotherapy versus <3 years of immunotherapy. *Allergy and Asthma Proceedings*. 2007;28(4):485-8.

139. Bueno-Marí R, Almeida A, Navarro JC. Emerging Zoonoses: Eco-Epidemiology, Involved Mechanisms, and Public Health Implications. *Front Public Health*. 2015;3:157.
140. Fonseca AR, Batista DR, Amaral DPD, Campos RBF, Silva CG. Formigas (Hymenoptera: Formicidae) urbanas em um hospital no município de Luz, Estado de Minas Gerais. *Acta Scien*. 2010;32(1):29-34.
141. Beatson SH. Pharaoh's ants as pathogen vectors in hospitals. *Lancet (London, England)*. 1972;1(7747):425-7.
142. Steinbrink H. Pharaoh ants in a ward for premature infants. *Angewandte Parasitologie*. 1978;19(1):28-31.

#### **Conflict of interests**

No conflict of interest exists.

#### **Author's contribution**

*Mario Javier Olivera*: Conceptualization, formal analysis, methodology and writing original draft.

*Julián Felipe Porrás-Villamil*: Conceptualization, formal analysis, methodology and writing original draft.