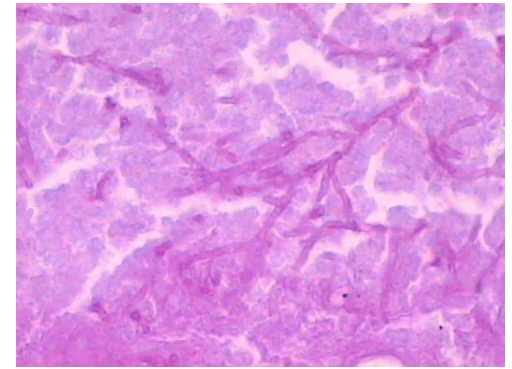
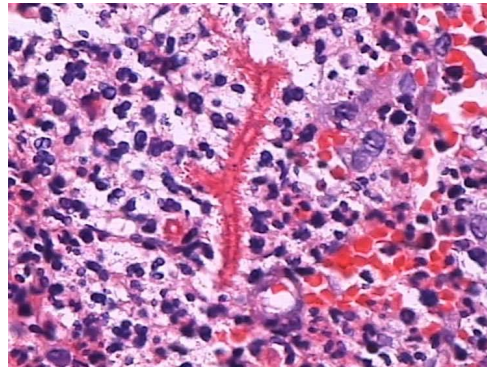
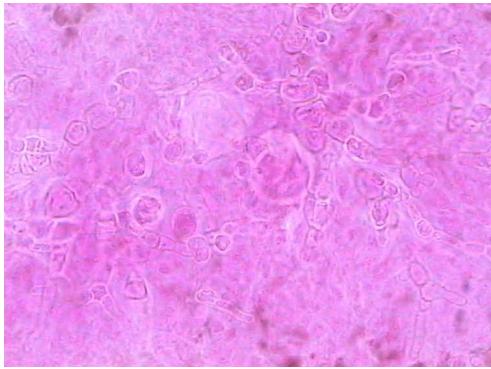
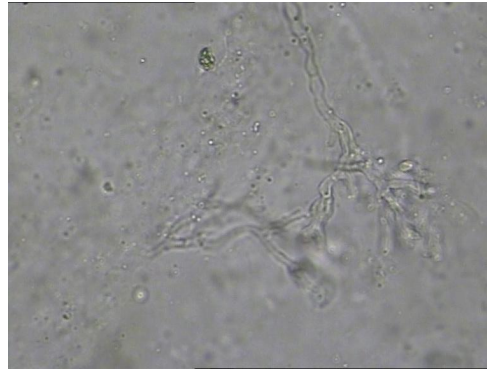
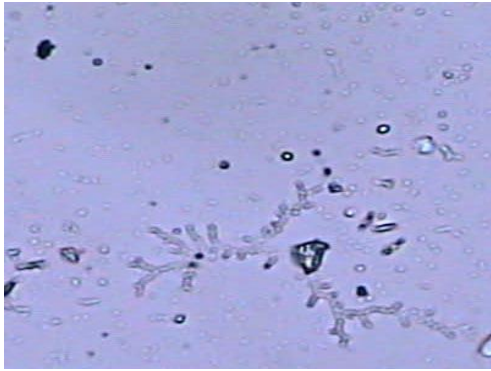

肺曲霉菌感染

北京儿童医院 赵顺英

曲霉菌概论

□ 真菌分类



肺曲霉病

ABPA

定植

曲霉球

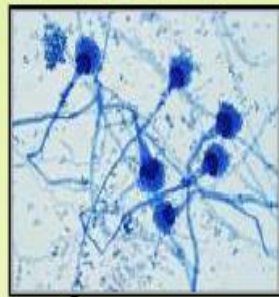
慢性肺曲霉病

侵袭性肺曲霉病

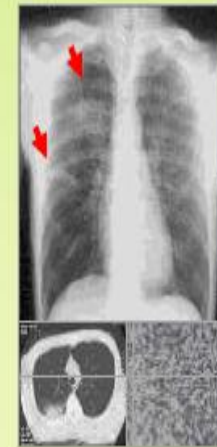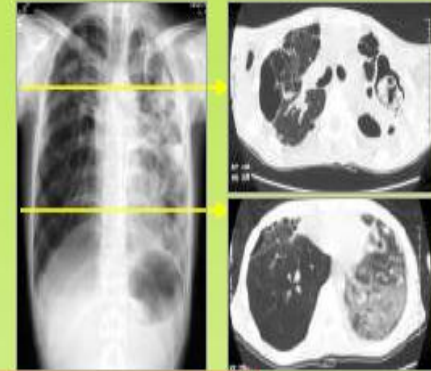
毁损肺 (既往结核分枝杆菌感染, COPD, 支气管扩张)

中性粒细胞缺乏症

侵袭



土壤, 植物, 空气



肺曲霉病三种形式

- 侵袭性：急性、亚急性、慢性
- 寄生性
 曲霉球
- 过敏性
 变态反应性肺-支气管肺曲霉病（ABPA）
 过敏性肺泡炎

一、侵袭性肺曲霉病

- 急性侵袭性肺曲霉病（IPA）
- 亚急性侵袭性肺曲霉病（SAIA）

既往称为慢性坏死性肺曲霉病，感染（<3个月），通常在轻—中等免疫抑制患者中发生
- 慢性侵袭性肺曲霉病

1. 急性侵袭性肺曲霉病

急性吸入所致

急性免疫重度抑制者：

高危因素：粒缺、病毒感染后

免疫制剂、机械通气等

吸入环境大量存在的曲霉

粮食、干草、木材、地下环境、空调管道等

提示急性侵袭性肺曲霉病的影像学征象

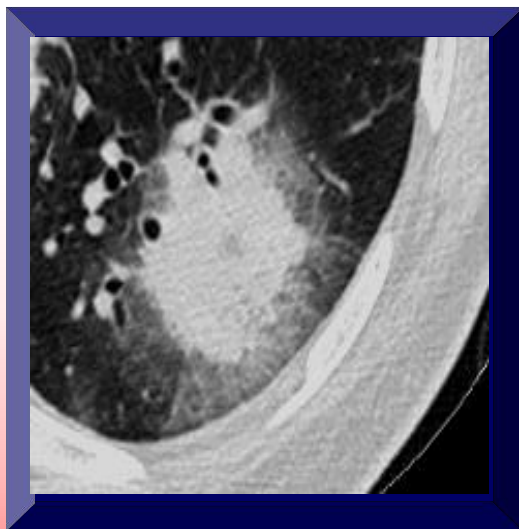
早期出现胸膜下密度增高的结节实变影和（或）楔形实变影、团块状阴影，病灶周围可有晕轮征(halo sign)；

数天后肺实变区液化、坏死，出现空腔阴影或新月形空气征(air-crescent sign)。

急性侵袭性肺曲霉病 (IPA) 的CT特征

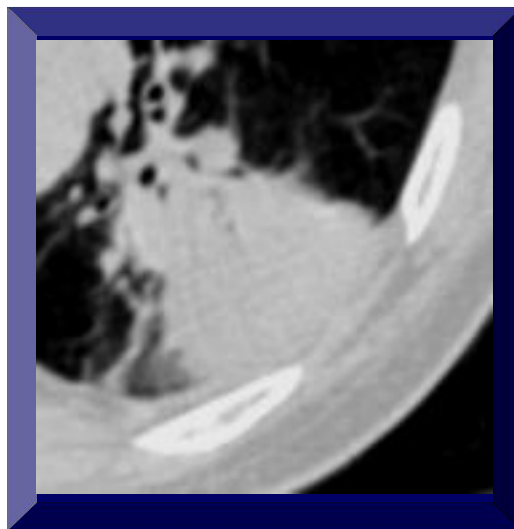
胸部CT表现的演变

晕轮征



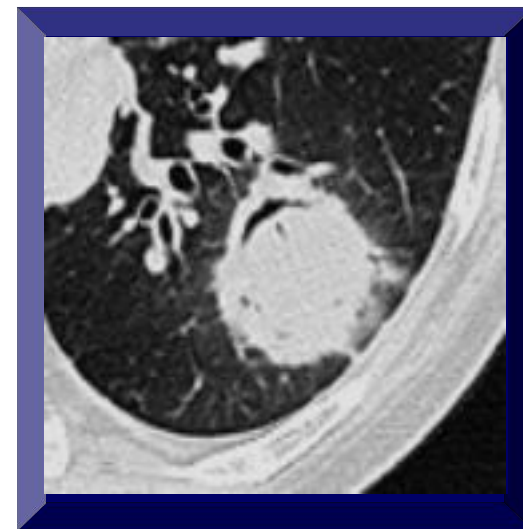
D 0 - 5

实变



D 5 - 10

新月征



D 10 - 20

血管侵袭性肺曲霉病

- 一般认为本病专门见于严重粒缺患者，现在也注意到它同样可见于其他具有危险因素的患者。
- 组织学改变为霉菌侵犯肺的小到中等大小肺动脉导致闭塞，形成出血坏死性小结节，或以胸膜为基底的楔形出血性梗死。CT特征包括：
 - ◆ 结节及其周围晕影
 - ◆ 楔形实变
 - ◆ 空洞和空气半月征：空洞内容物为梗死肺组织，通常出现在中性粒细胞恢复阶段，提示预后较好。

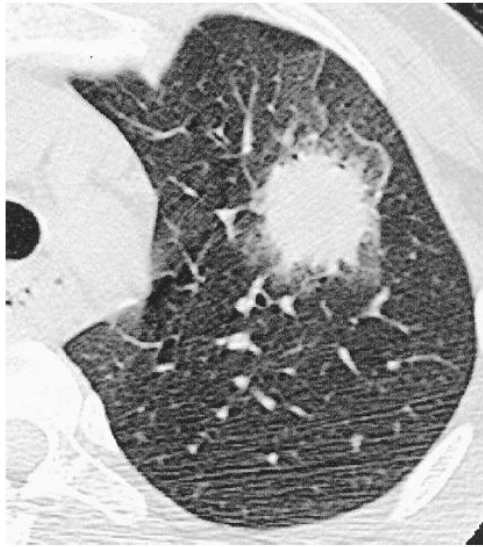


Fig 1. CT halo sign. This first thoracic CT scan (day 0) was performed in a patient with febrile neutropenic leukemia. The ground glass attenuation surrounding the nodule was considered a typical halo sign. The diagnosis of IPA was considered highly likely, and antifungal treatment was started.

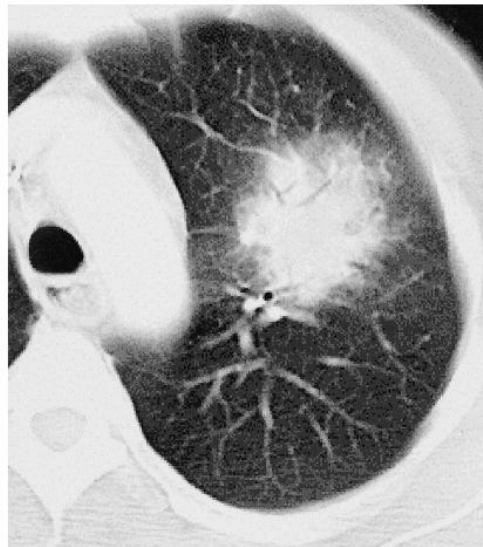

Fig 2. Low specific CT image. A new CT scan was performed 4 days later (day 4). It showed an increase of the left-sided aspergillary mass with partial loss of peripheral ground glass attenuation.

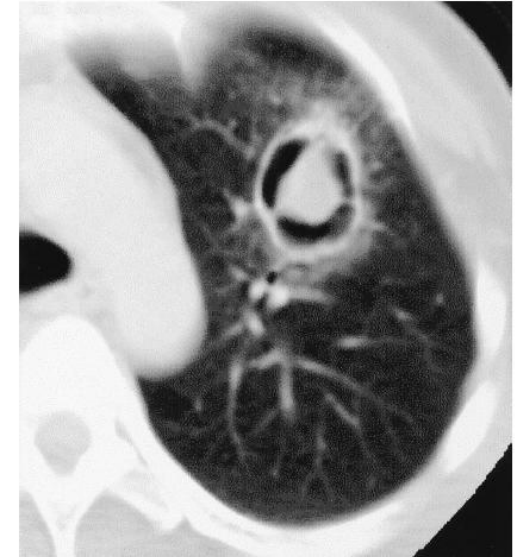


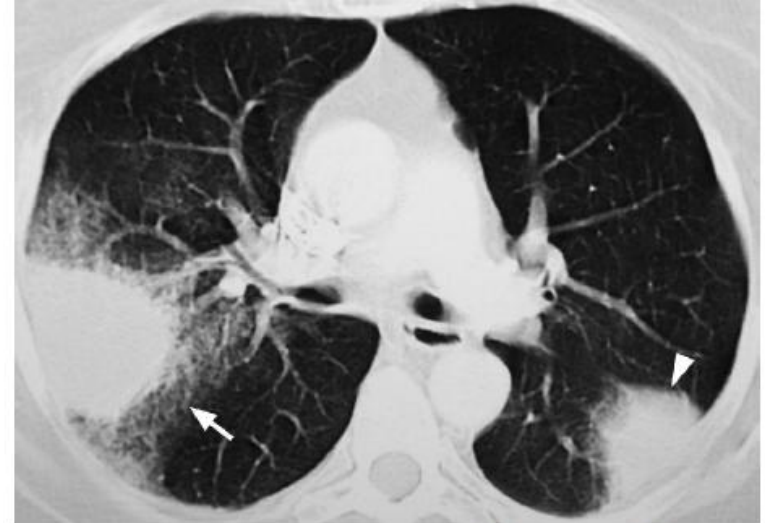
Fig 3. CT air-crescent sign. Marrow recovery occurred on day 7. On day 10, an air-crescent sign appeared on CT scan. A surgical resection confirmed the diagnosis of IPA. Subsequently, the patient received itraconazole for 12 months, and 30 months later, she was well and alive.

血管侵袭性肺曲霉病

- 血管侵袭性曲霉菌病在CT下表现为结节和周围边界有细小毛玻璃样改变的晕轮征，这是由于曲霉侵犯小到中等大小气道导致堵塞，出现出血坏死性小结节或以胸膜为基底的楔形出血性梗死
- CT findings include multiple nodules associated with a halo of ground-glass attenuation, representing adjacent hemorrhage, and patchy areas of pleural based wedge-shaped consolidation, corresponding to hemorrhagic infarction.

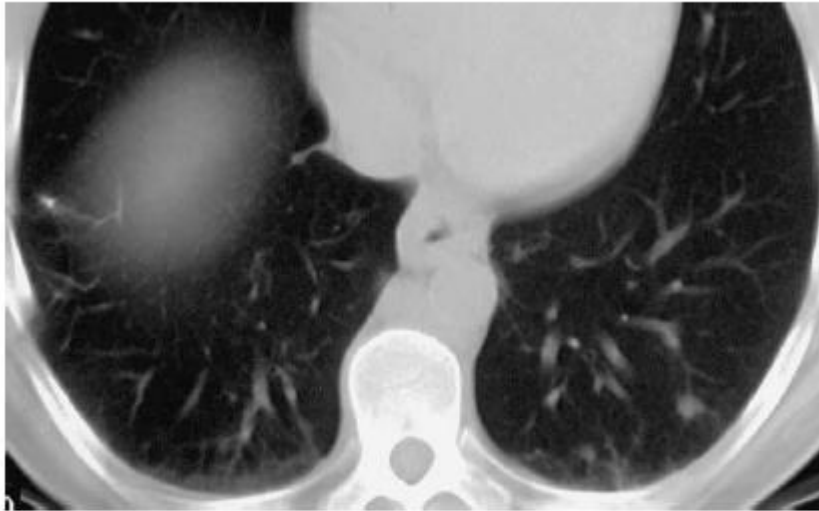

FIG 9. A nonenhanced CT through the lower thorax showing subtle left lower lobe nodule due to invasive aspergillosis in a renal transplant recipient. The patient had multiple other nodules, one of which had been biopsied to confirm the diagnosis. Note the thick-walled esophagus secondary to concurrent cytomegalovirus infection.

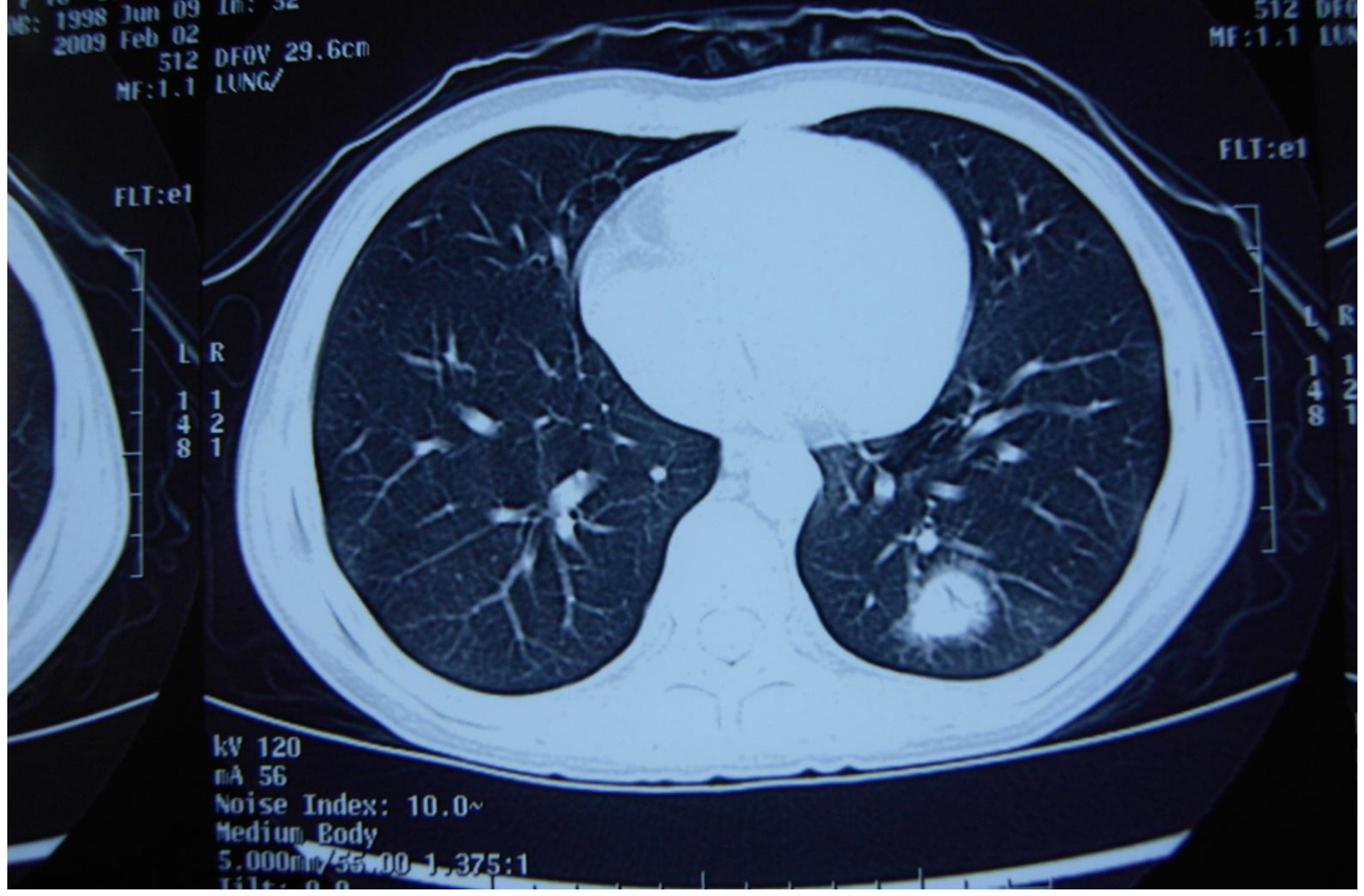


Transverse CT scan obtained in a 50-year-old woman with invasive pulmonary aspergillosis treated with a high dosage of steroids to reduce cerebral edema from anaplastic oligodendroglioma. A large mass is seen in the right upper lobe, surrounded by a wide zone of ground-glass attenuation (arrow) demonstrating the halo sign. A smaller mass (arrowhead) is seen in the left lower lobe; it has indistinct margins but no well-defined halo sign.

CHILDREN HOSPITAL
ACC Num: 01131036
JINLU
F 10 00669495
DOB: 1998 Jun 09
2009 Feb 02
512
MF: 1.1

LightSpeed VCT SYSHVC04
Ex: 44142
Se: 3
SN I159.75
Im: 32
DFOV 29.6cm
LUNG

ACC Num: 01131036
JINLU Se:
F 10 00669495 SN:
DOB: 1998 Jun 09 Im:
2009 Feb 02
512 DFO
MF: 1.1 LUN



FLT:e1

FLT:e1

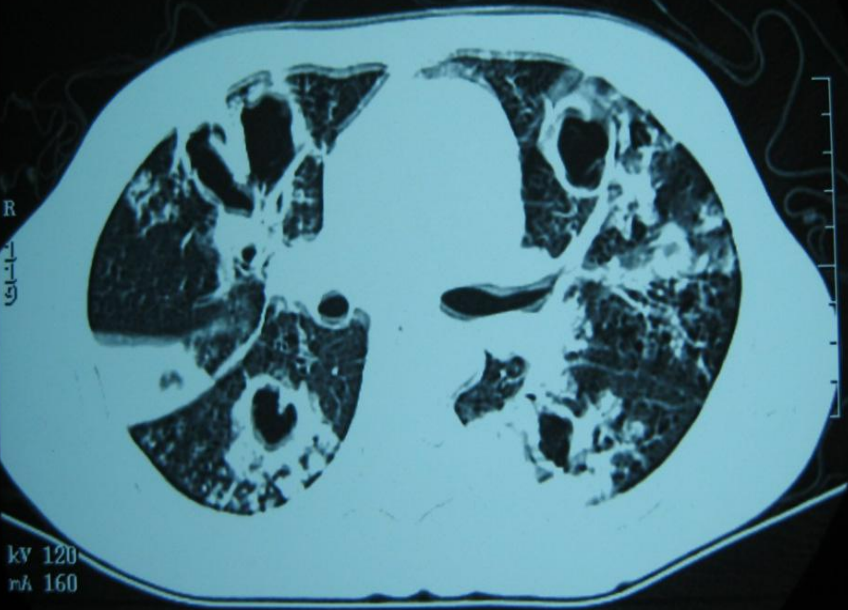
L R
1 1
4 2
8 1

L R
1 1
4 2
8 1

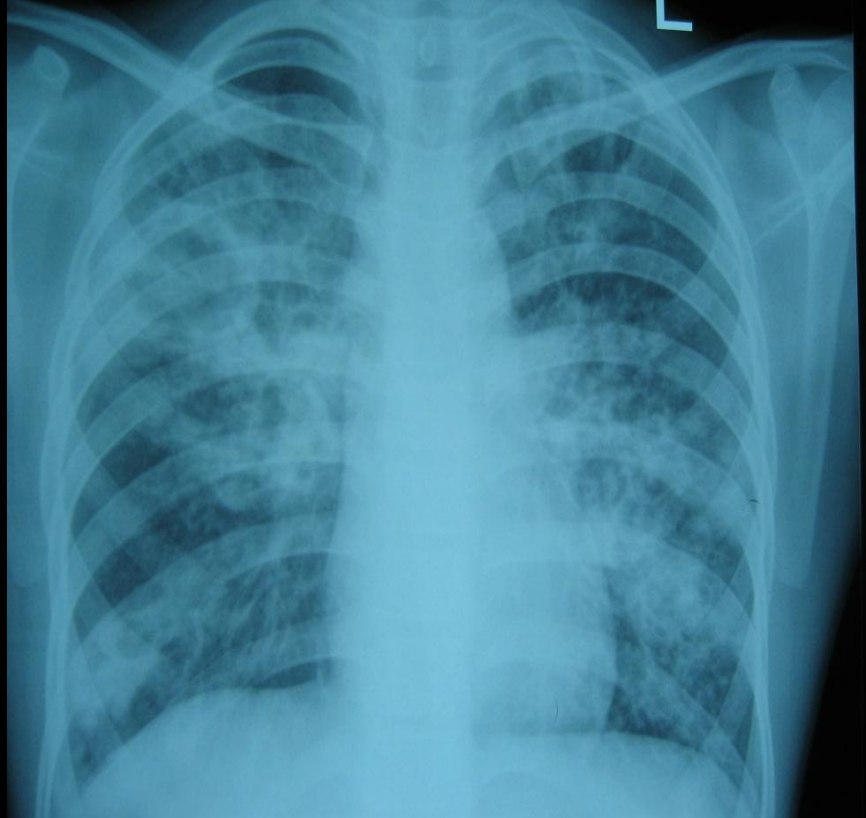
kV 120
mA 56
Noise Index: 10.0~
Medium Body
5.000mm/55.00 1.375:1
Tilt: 0.0

SN 188.73
In: 77

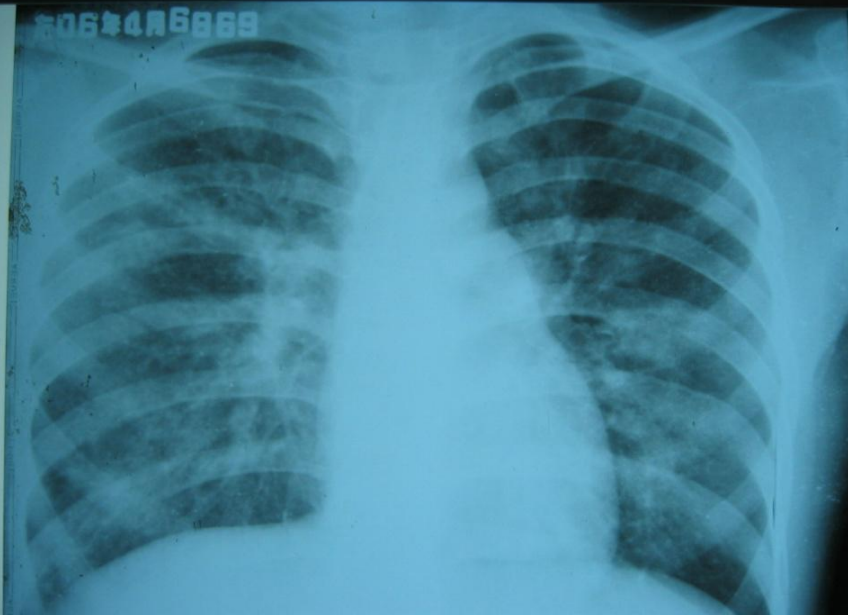
DFOV 30.2cm
LUNG



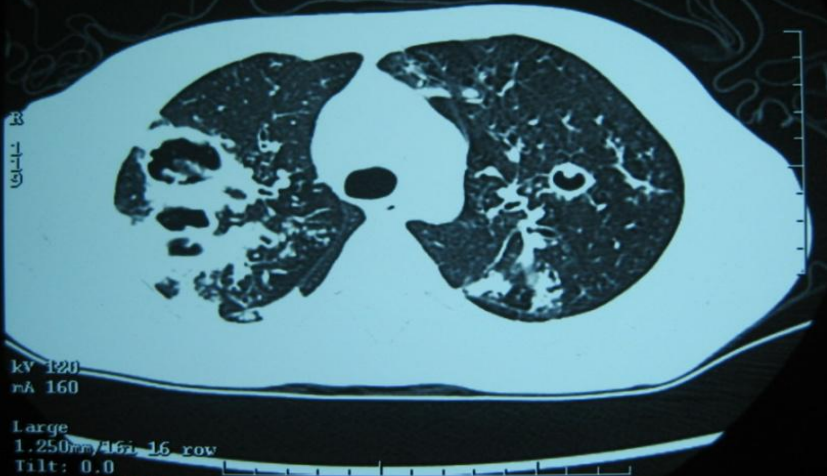
DOB: 1994 Oct 28
2006 Apr 25
512
MF:1.1


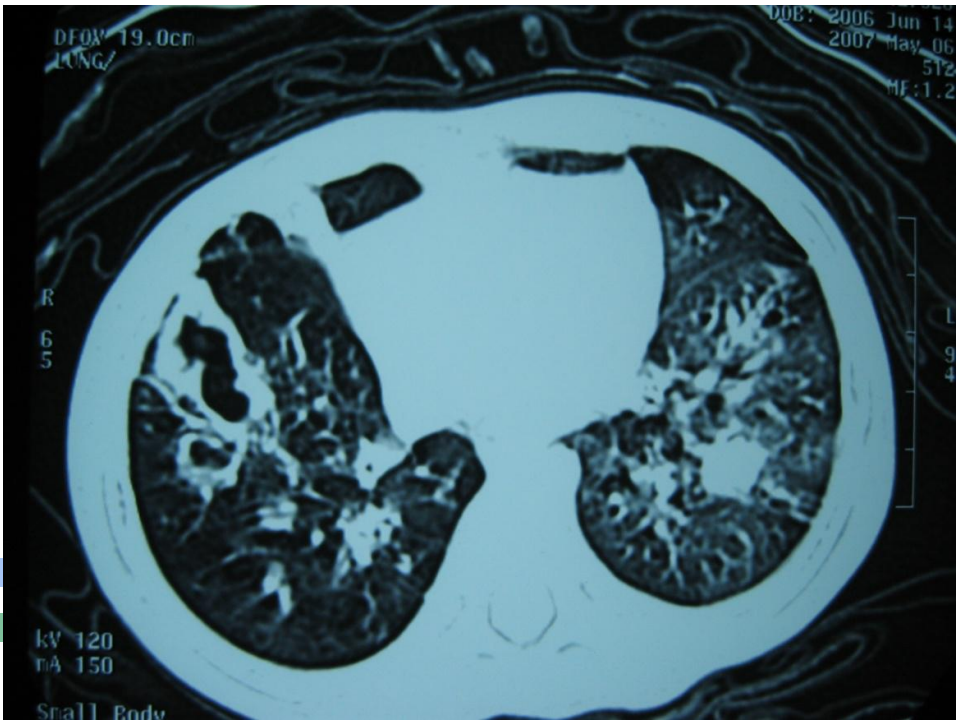
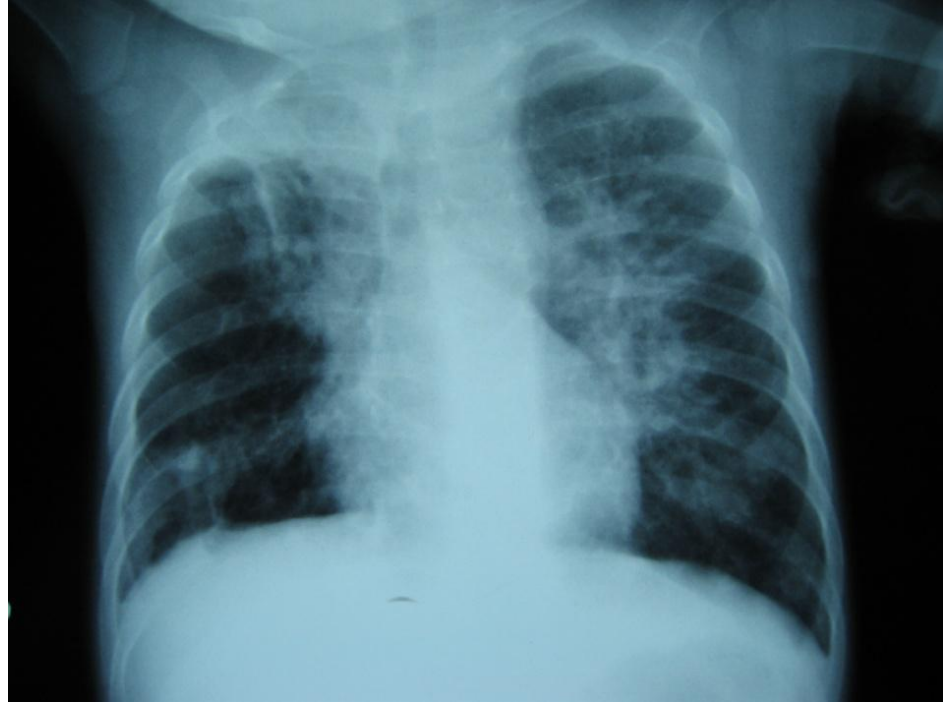
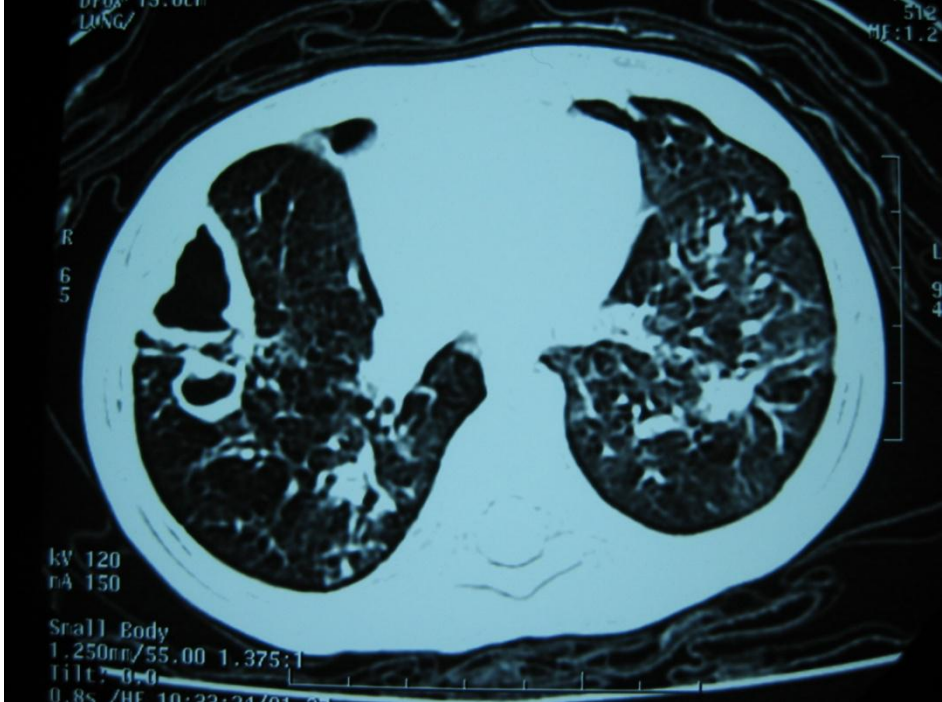

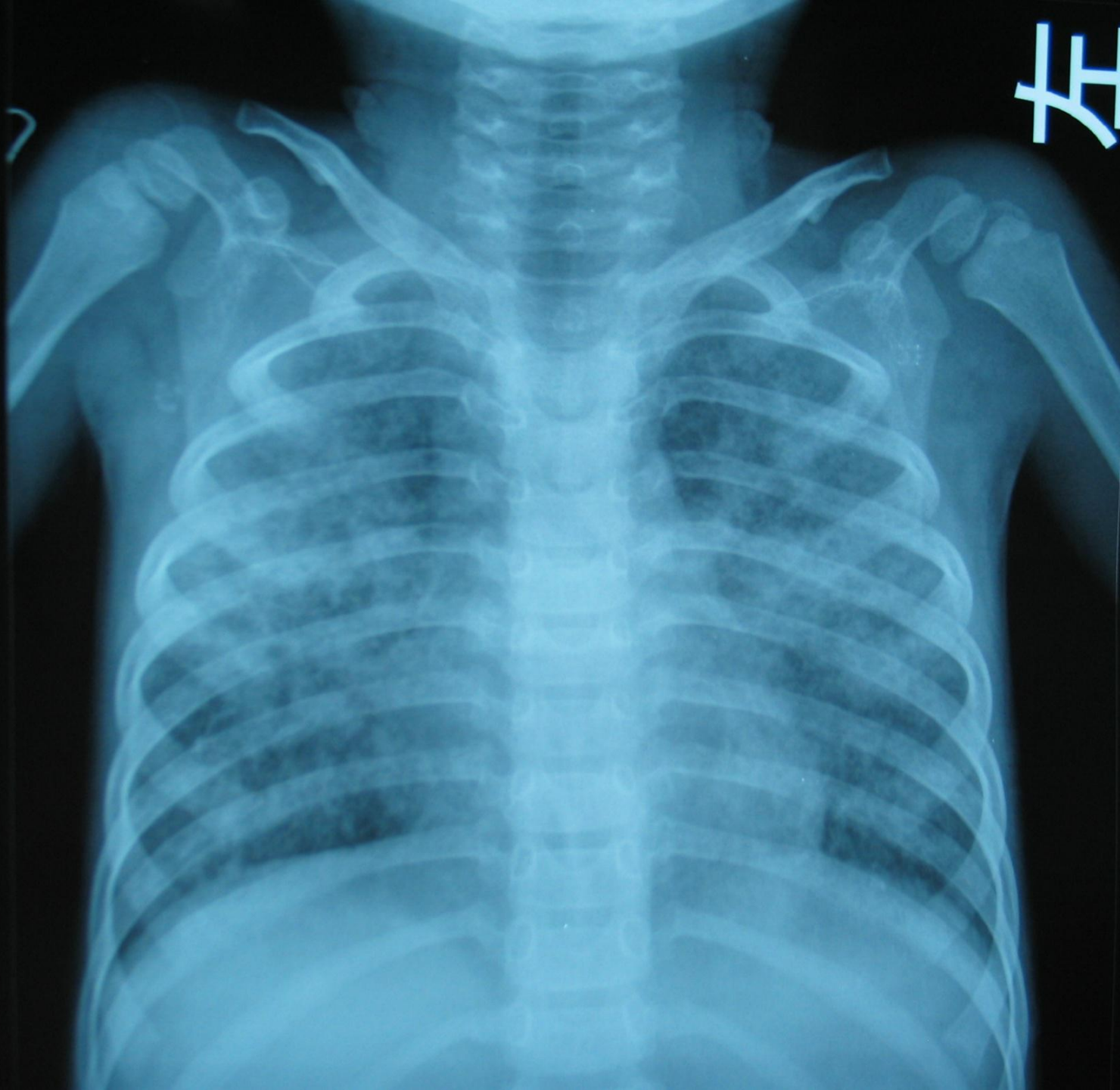
2006年4月25日



DFOV 30.2cm
LUNG







左

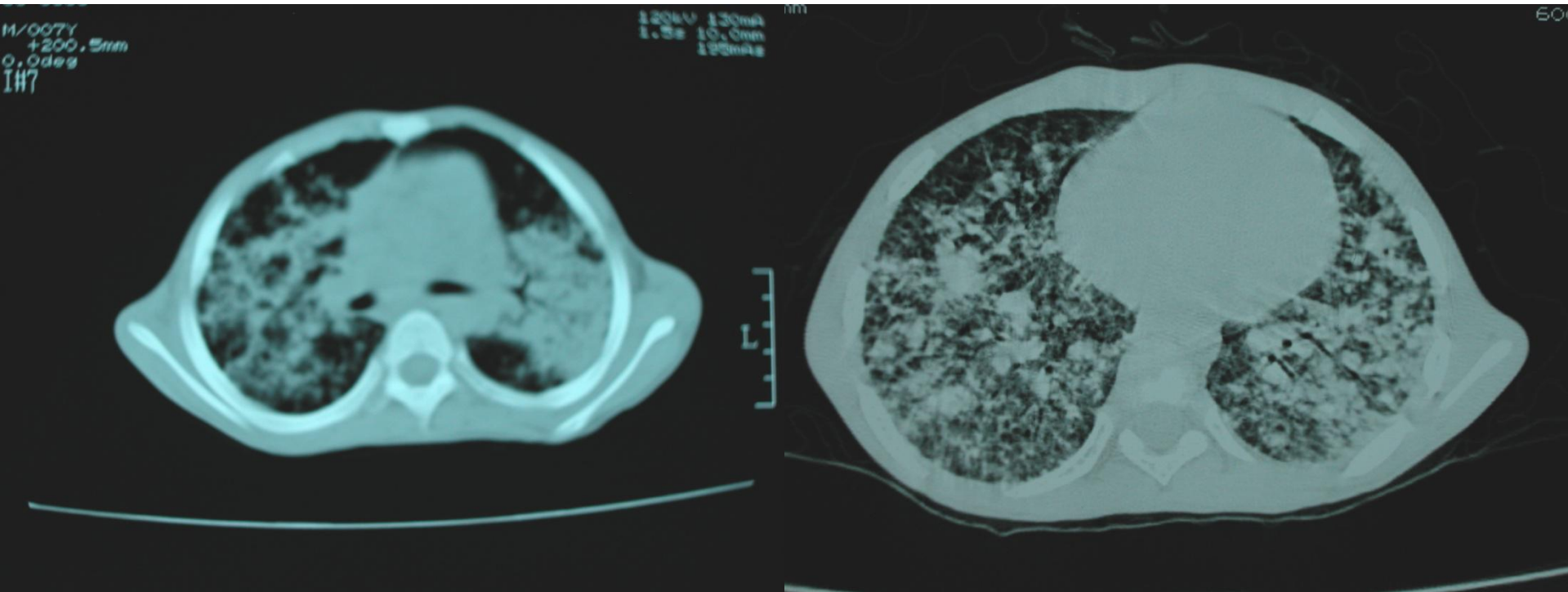
2007 8 8 14:22:56

21497

Patient Name: M 1500-1-1



北京儿童医院
BEIJING CHILDREN'S HOSPITAL





2. 亚急性侵袭性肺曲霉病（SAIA）

之前被归类为慢性坏死性或半侵袭性肺曲霉病

可以发现菌丝侵入肺实质，较难

SAIA发生在轻度免疫抑制或极度虚弱患者中

病程数月 to 数年



亚急性侵袭性肺曲霉病（SAIA）

SAIA典型的患者群为：

糖尿病，人工营养，酒精中毒，高龄

慢性阻塞性肺疾病，结缔组织病

宿主因素—原发性免疫功能缺陷病

慢性肉芽肿病的诊断线索：

卡介苗接种处化脓

皮肤感染：脓疱疮、肛周脓肿

淋巴结化脓感染

接种卡介苗处腋窝钙化淋巴结

肺部感染

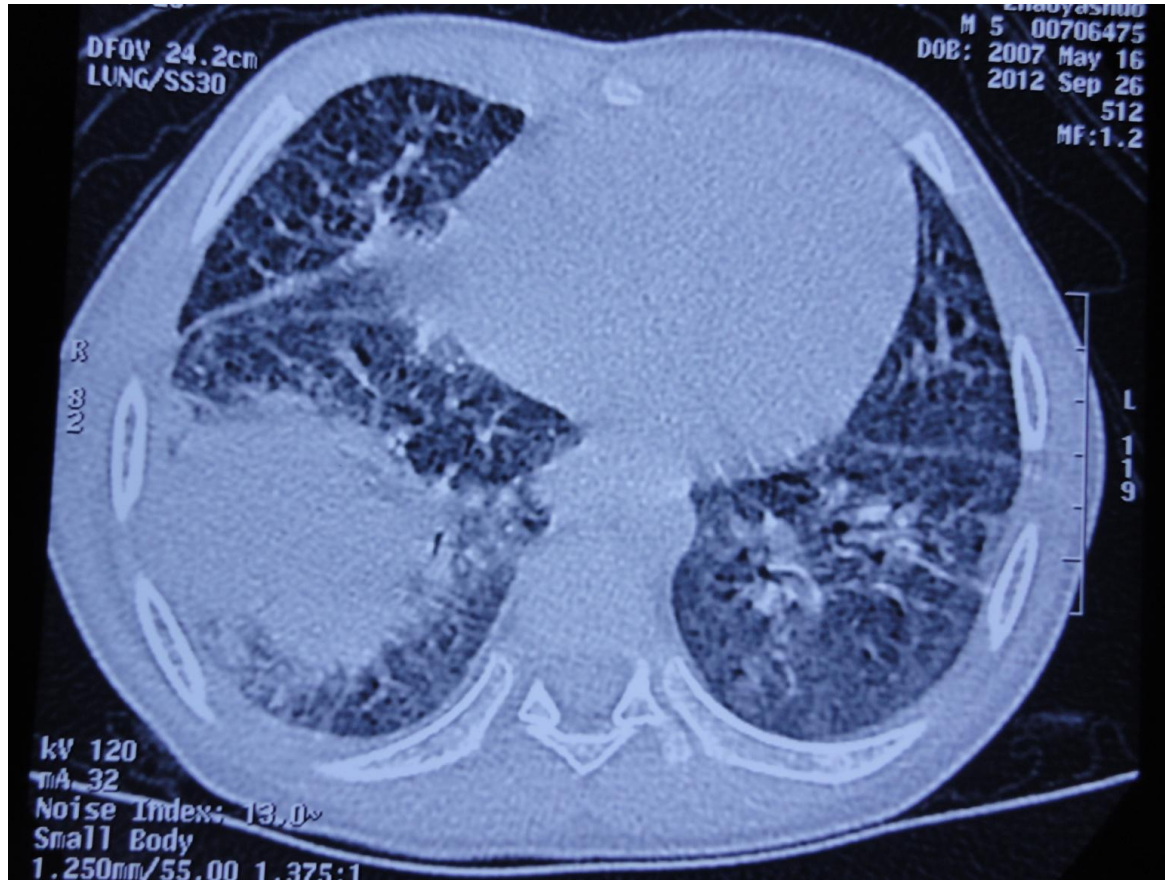
亚急性影像学改变

- 实变
- 空洞

实变为结节、团块样

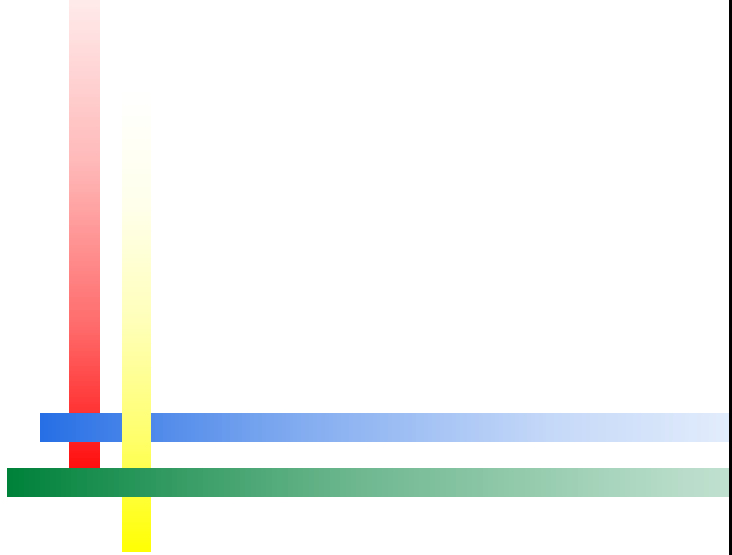
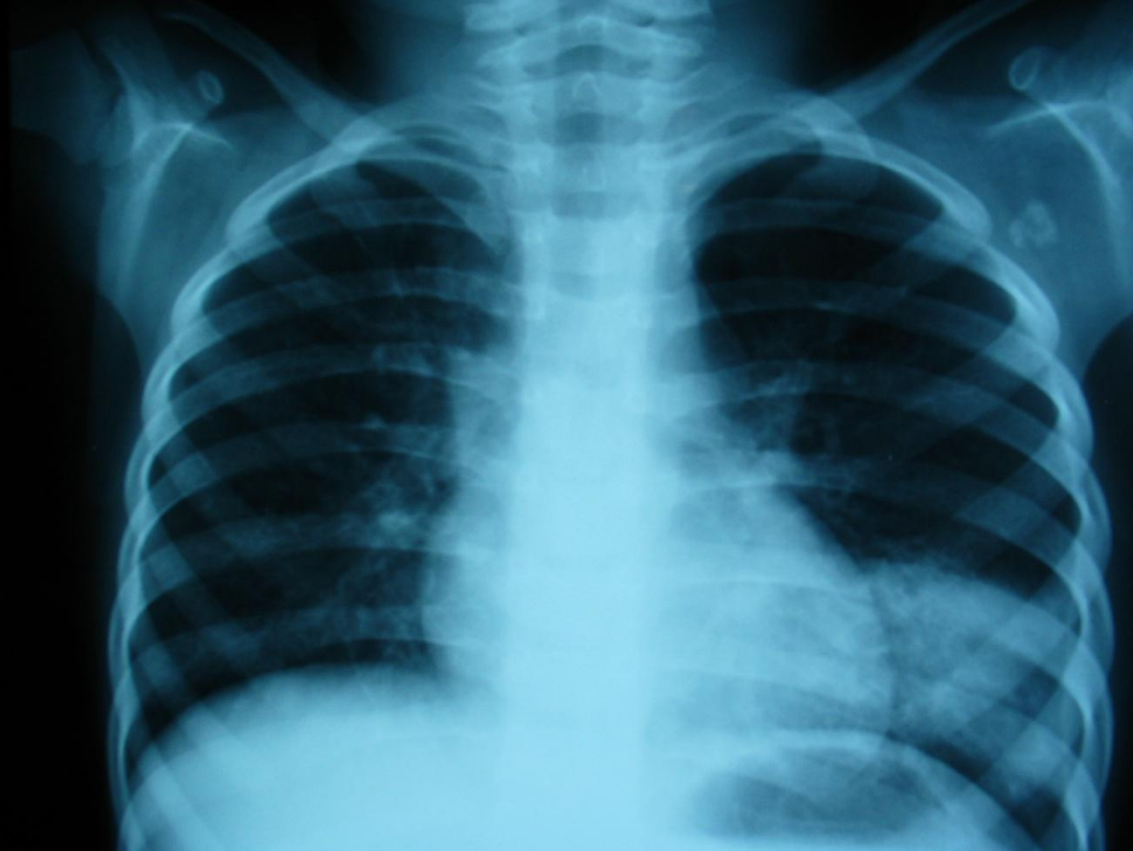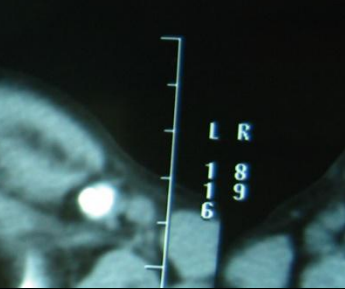
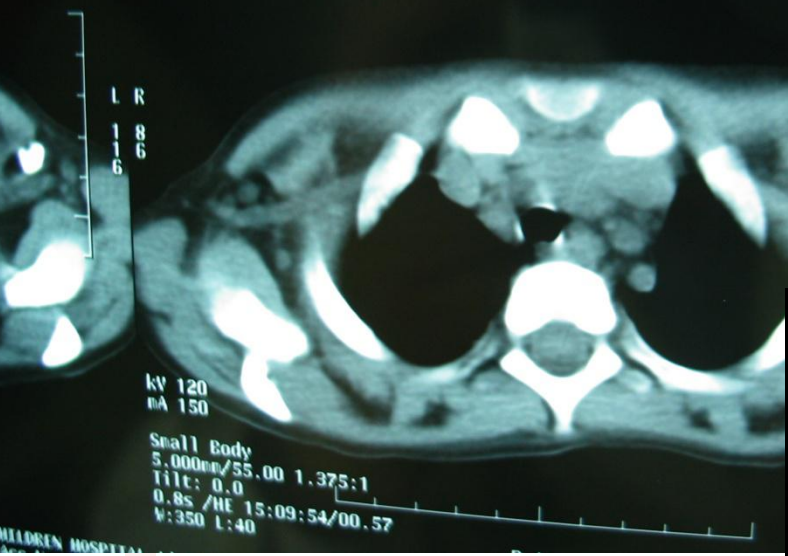
免疫缺陷病合并真菌感染

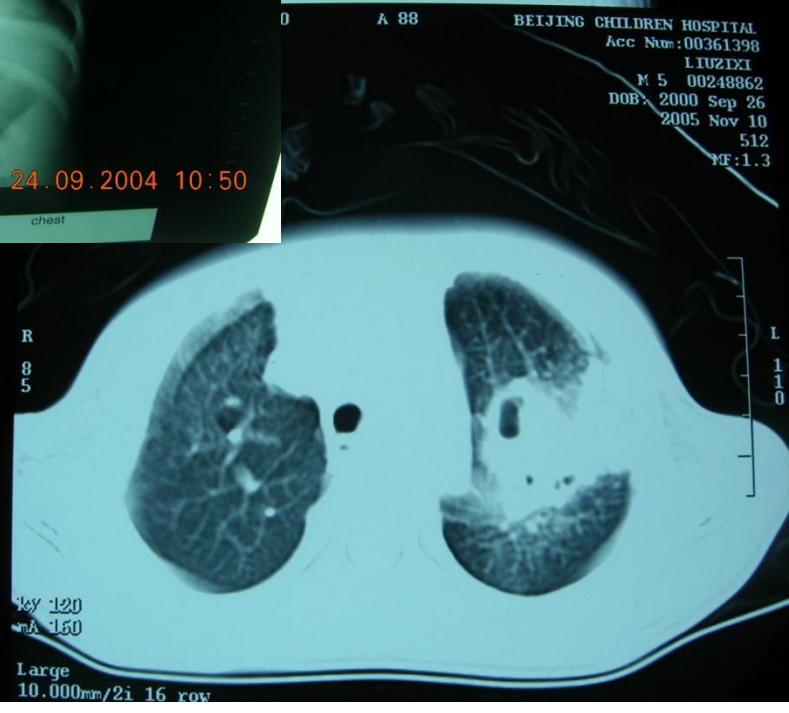
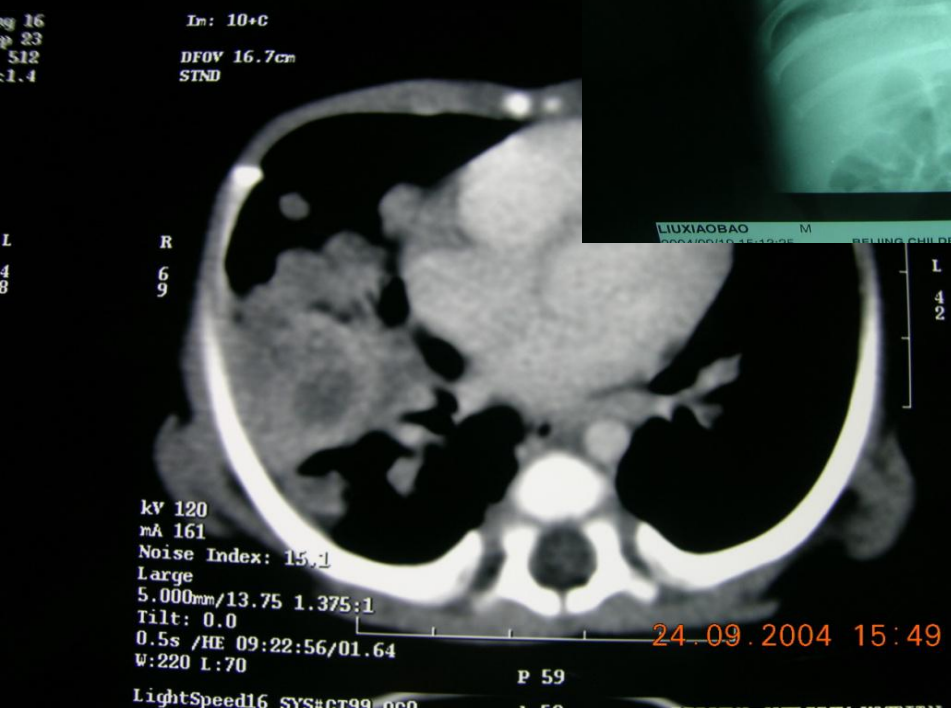
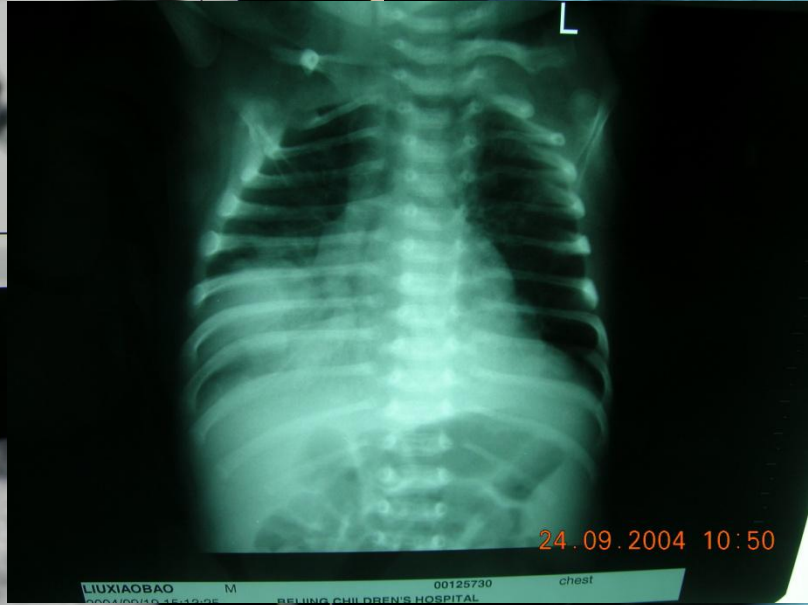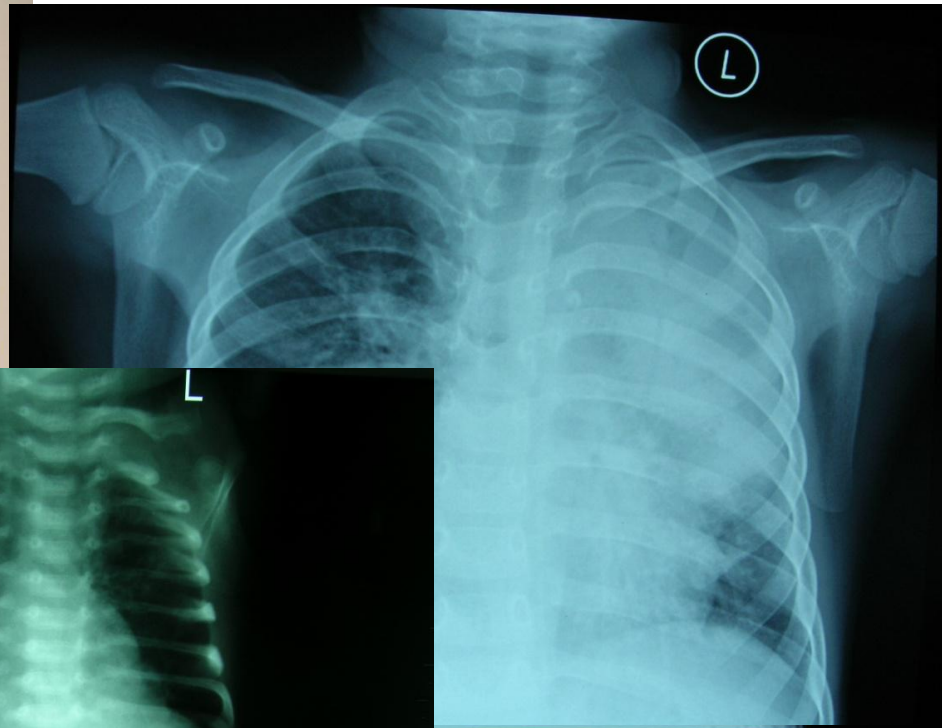
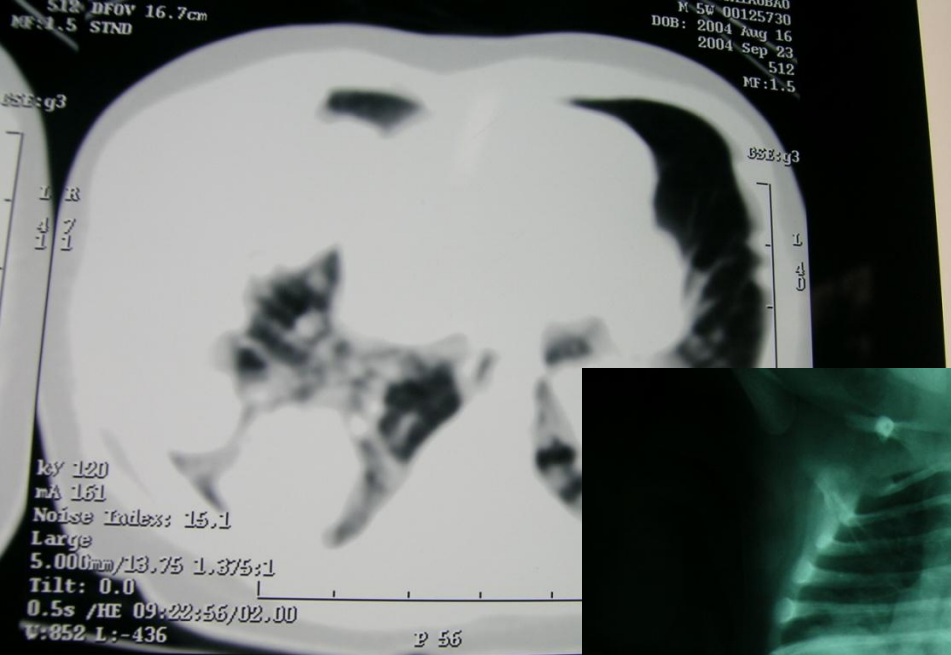
慢性肉芽肿病合并曲霉菌感染



REN HOSPITAL LightSpeed VCT SYS#CT64_0C0 A 85
Num: 00657753 Ex: 12473
JINSHIBO Se: 2
4 00414100 SN I10.50
2002 Jul 29 Im: 8
2007 Apr 05
512 DFOV 24.3cm
MF:1.2 STND/

BEIJING CHILDREN HOSPITAL LightSp
Acc Num:00657753 Ex: 124
JINSHIBO Se: 2
M 4 00414100 SN I15.
DOB: 2002 Jul 29 Im: 9
2007 Apr 05
512 DFOV 24
MF:1.2 STND/





W: 910
L: -661

BEIJING CHILDREN

2002.10.29 10:29:24.7
16480. 2. 1. 5

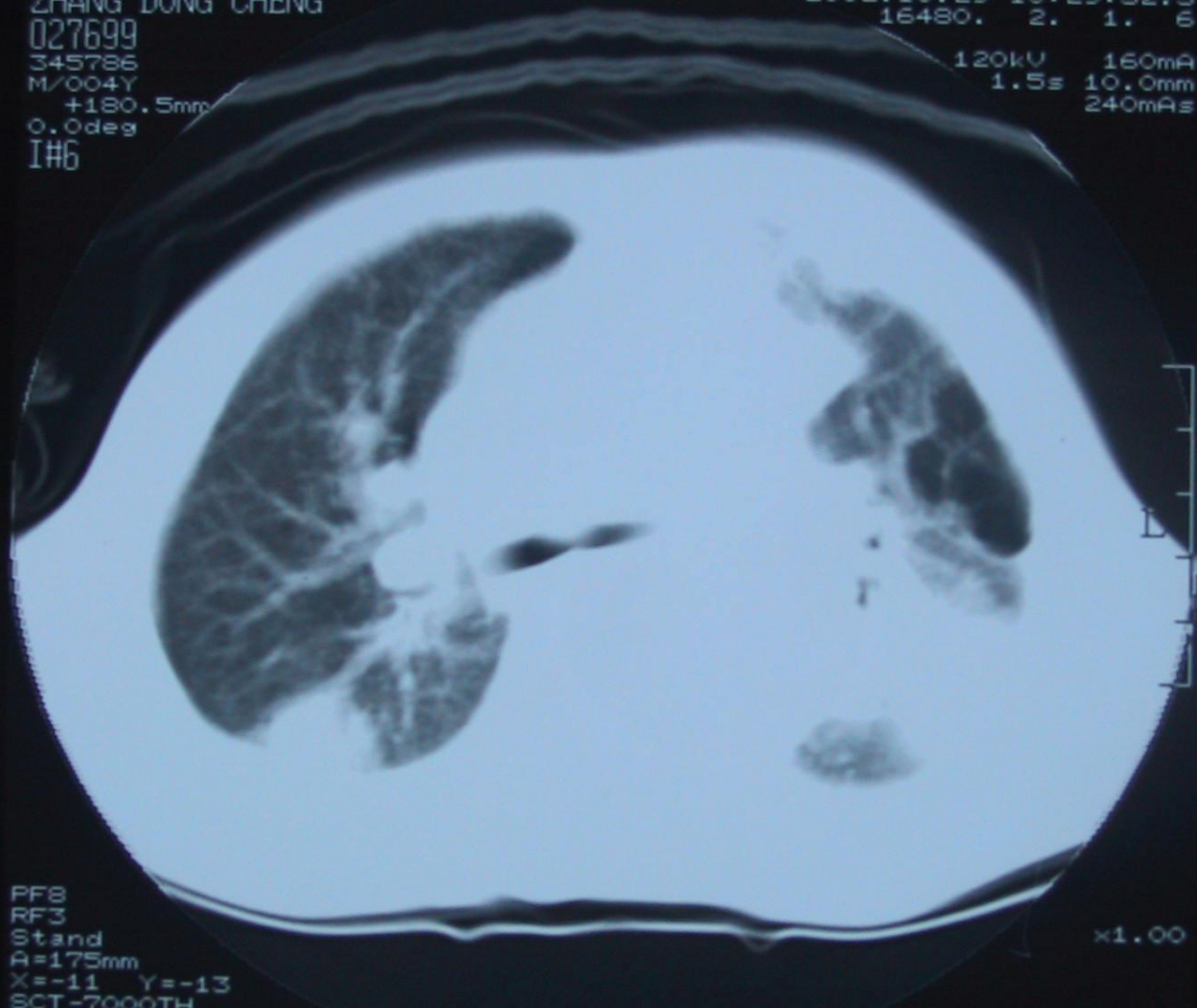
ZHANG DONG CHENG
027699
345786
M/004Y
+180.5mm
0.0deg
I#6

2002.10.29 10:29:32.3
16480. 2. 1. 6

120kV 160mA
1.5s 10.0mm
240mAs

ZHANG DONG CHENG
027699
345786
M/004Y
+170.5mm
0.0deg
I#7

120kV 160mA
1.5s 10.0mm
240mAs



x1.00

PF8
RF3
Stand
A=175mm
X=-11 Y=-13
SCT-7000TH
BEIJING CHILDREN HOSPITAL

W: 958
L: -630

P

x1.00

PF8
RF3
Stand
A=175mm
X=-11 Y=-13
SCT-7000TH
BEIJING CHILDREN

W: 996
L: -632

2002.10.29 10:29:54.0
16480. 2. 1. 9

ZHANG DONG CHENG
027699
345786

2002.10.29 10:30:35.4
16480. 2. 1. 10

120kV 160mA

ZHANG DONG CHENG
027699

3. 慢性侵袭性肺曲霉病

慢性空洞型肺曲霉病（CCPA）：最常见

慢性纤维化肺曲霉病（CFPA）

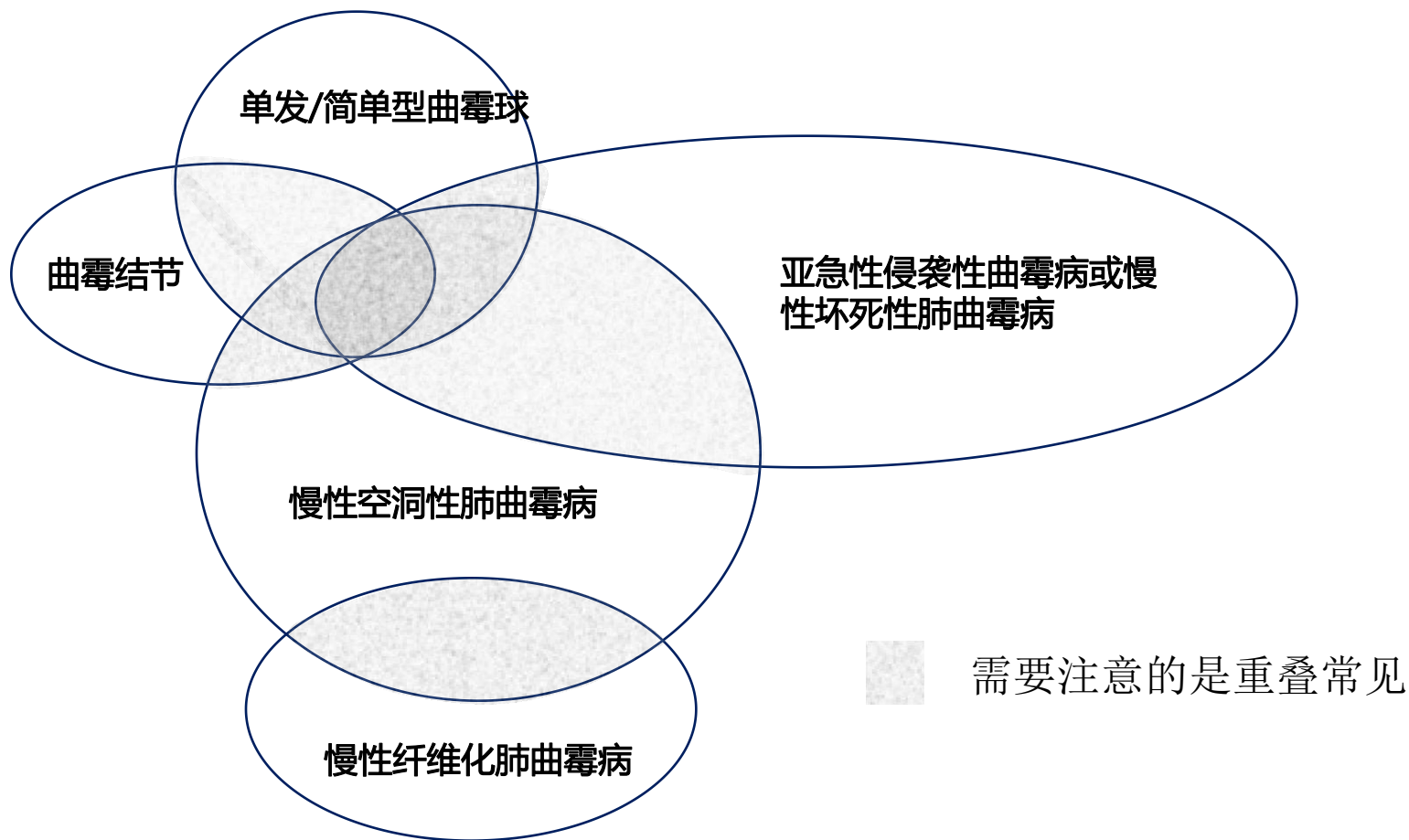
曲霉结节：不常见

曲霉球：不常见

3.1 不同类型慢性肺曲霉病（CPA） 的诊断标准

类型	定义
曲霉球	发生在非免疫抑制患者中的包含真菌球的单发肺部空腔，血清和微生物证据指向曲霉菌。患者伴有轻微或无任何症状。在就诊前至少3个月没有任何影像学进展。
慢性空洞型肺曲霉（CCPA）	单发或多发肺部空腔（伴随薄壁或厚壁空腔）可能包含一个或多个曲霉球或不规则的内容物。血清和微生物证据指向曲霉菌。患者伴有明显的肺部症状和全身症状，以及在此之上就诊前至少3个月的影像学进展（新发的空腔，空腔壁周围的渗出增加或纤维化的增加）
慢性纤维化肺曲霉（CFPA）	至少2个肺叶严重的纤维化肺结构破坏并伴有由于慢性空洞型肺曲霉病导致的肺功能丢失；单个肺叶严重的纤维化肺结构破坏伴有空腔，该空腔单纯由慢性空洞型肺曲霉病对该肺叶的影响造成。通常这种纤维化表现为实变，但是大空腔周围伴有纤维化同样可见。
曲霉结节	单个或多个结节（可以空腔化或不空腔化）是慢性肺曲霉病不常见的类型。它们容易和肺部的结核球，肿瘤，球孢子病和其他诊断相混淆。曲霉结节只能通过组织学进行诊断。不表现为组织侵袭，尽管常发生坏死。

3.2 不同类型慢性肺曲霉病（CPA）的重叠

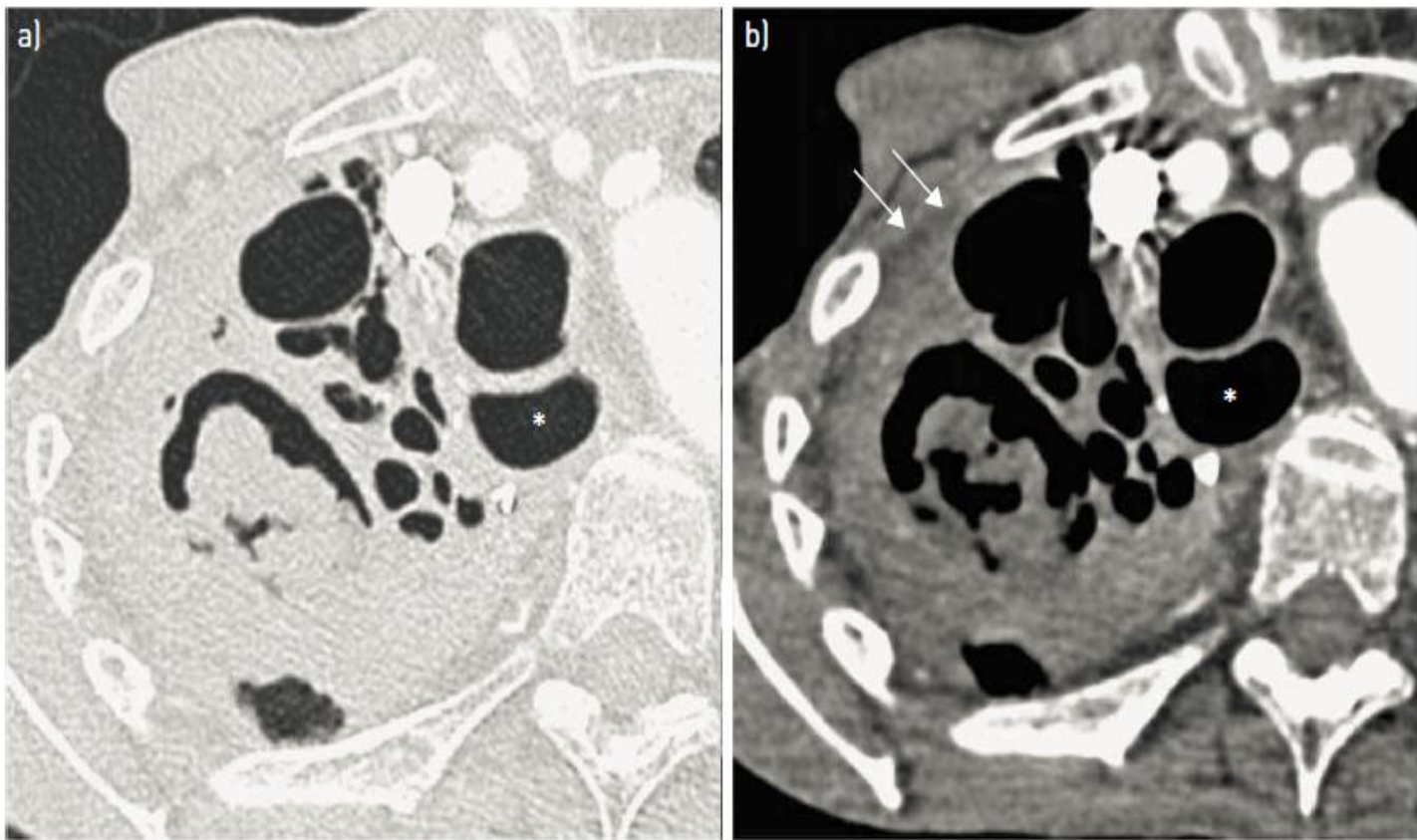


3.3 慢性空洞型肺曲霉病（CCPA）

- 慢性空洞型肺曲霉病之前也被称为复杂型曲霉球
- 通常表现为多发的空腔（包含或不包含曲霉球）
- 患者伴有肺部或全身症状，就诊前病灶存在至少3个月，并伴有炎性介质的增加
- 在未接受治疗的情况下，数年后这些空洞可以进展扩大并融合，逐步发展成为空腔周围浸润或胸膜穿孔。空腔内的曲霉球可以出现或消失
- 需要借助曲霉特异性血清学或微生物学证据作为CCPA的诊断。



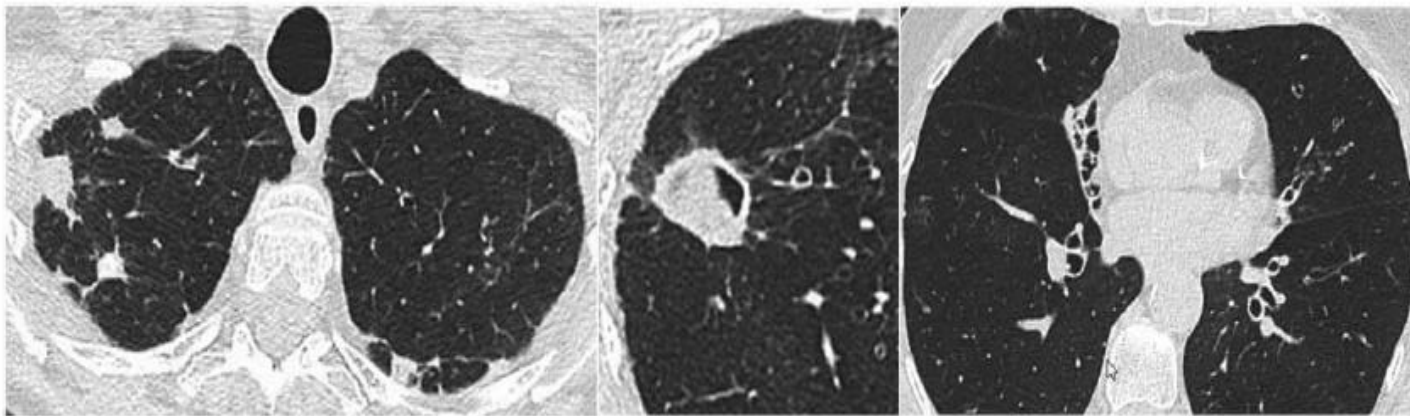
北京儿童医院
BEIJING CHILDREN'S HOSPITAL



如图4，所示慢性空洞性肺曲霉病患者的轴向位肺窗（a）和右上叶的纵隔窗（b）影像学表现。多发空腔，最大的空腔内伴有真菌球附在壁上。空腔壁无法分辨是胸膜增厚还是毗邻肺泡的实变。高衰减区域显示胸膜外肥大（白色箭头所指）。*区域：为陈旧性食道，请勿误认为是空洞。

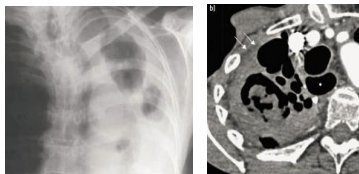
曲霉结节 (Aspergillus nodule)

单个或多个结节 (<3cm) (不出现空腔化) 是慢性肺曲霉病少见的表现 (如图)。它容易和肺癌, 转移癌, 隐球菌结节, 球孢子菌病或其他少见病原体相混淆。只能通过组织病理进行确认诊断。有类风湿性关节炎的患者这种结节可能是单纯的风湿性结节或包含曲霉菌。尽管坏死常见但无法证明组织侵袭的存在。有时出现的直径大于3厘米的病灶可伴有一个坏死中心。文献中缺乏对该疾病的理想描述, 最好的描述是“由曲霉菌所致的肿块样病变”



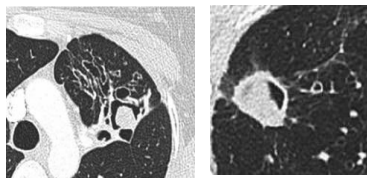
如上图, 连续的肺窗内的轴向位影像显示曲霉结节, 具有不均一的大小和不规则边界。患者陈旧性的支气管扩张和中叶的小叶中心性扩张内出现边界厚度不均的空腔, 空腔内有真菌球填充。

曲霉球和单发（简单）肺曲霉球



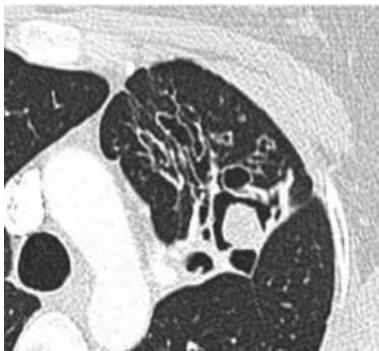CFPA

CCPA



简单肺曲霉球

SAIA



曲霉球形态学表现为真菌球，绝大多数由真菌菌丝和细胞外基质组成，是慢性肺曲霉病最特征性的影像特点。通常在胸部CT下于肺组织或胸膜空腔或扩张支气管中可见。曲霉球可见于除曲霉结节之外所有类型的慢性肺曲霉病，是疾病后期的表现，是由空腔内表面生长真菌塌陷入空腔内所形成的。真菌球由其他任一真菌形成也非常常见。在侵袭性肺曲霉病中“空气征”同样被关注，空腔内的可见的内容物是包含曲霉菌（或其他真菌）的肺梗阻。后者最好的表述是“真菌性肺坏死物”，常见于免疫抑制患者中。曲霉球是CPA的重要特征，但需要其他附加信息进行疾病归类和治疗决策。

单发（简单）肺曲霉球

单发肺曲霉球是在单一空腔内的单个曲霉球。就诊前数月内无任何进展，该类型非常少见。患者伴有肺部或全身症状以及血清或微生物证据证明是曲霉菌所致。

侵袭性肺曲霉菌诊断

宿主因素或环境因素

临床和影像学证据

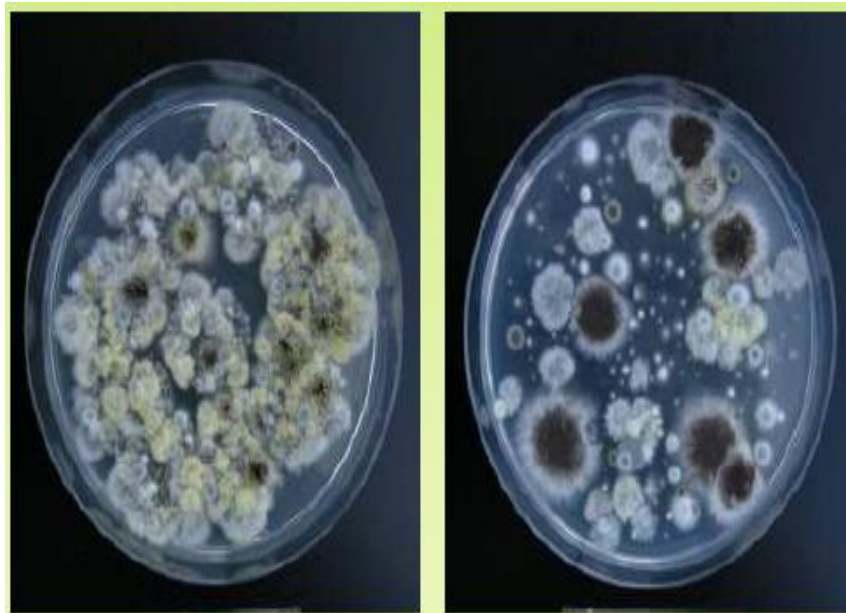
微生物学证据



北京儿童医院
BEIJING CHILDREN'S HOSPITAL

慢性肺曲霉病家族案例

患者居住在超过50年房龄的
木质机构建筑中
-----潮湿且陈旧



IPFI的分级诊断标准

诊断级别	宿主因素 ^a	临床证据	微生物学	组织病理
确诊	+	+	+	-
临床诊断	+	+	+	-
拟诊	+	+	-	-

a:原发感染者可无宿主因素

诊断依据—微生物学证据

- 有临床诊断意义的微生物学检查
- 有确诊意义的微生物学检查

有临床诊断意义的微生物学证据

- (1) 合格痰标本直接镜检发现菌丝，且培养连续2次以上分离到同种真菌；
- (2) 支气管肺泡灌洗液经直接镜检发现菌丝，真菌培养阳性；
- (4) 血液标本曲霉半乳甘露聚糖抗原（GM）检测连续2次吸光指数（I）值 >0.8 （ $0.5?$ ）或单次I值 >1.5 ；

有确诊意义的微生物学证据

- (1) 肺组织真菌培养阳性;
- (2) 胸腔积液真菌培养阳性;
- (3) 血液真菌培养阳性(曲霉除外污染);

诊断依据-组织病理学

存在真菌感染的病理改变，注意鉴别
发现菌丝或孢子等真菌成分

血清学检查

- 葡聚糖
- (1-3)- β -D-glucan

- 半乳甘露聚糖
- Galactomannan (GM)



血清学检查的影响因素

半乳糖甘露聚糖在血中存在时间短，建议：

- 高危人群每周至少检测**2**次
- 结合影像学、培养结果综合分析诊断

结果判定标准

- 界值的确定

肺曲霉病三种形式

- 侵袭性：急性、亚急性、慢性
- 寄生性
 曲霉球
- 过敏性
 变态反应性肺-支气管肺曲霉病（ABPA）
 或 过敏性肺泡炎



过敏性支气管肺曲霉病（ABPA）

发生于哮喘病人，为持续或重症哮喘的原因之一

咳嗽、喘息，典型咳棕褐色痰栓

中心性支气管扩张

游走性肺部浸润

血清总IgE升高超过1000

烟曲霉特异性IgG升高

烟曲霉特异性IgE升高

过敏性支气管肺曲霉病 (ABPA)

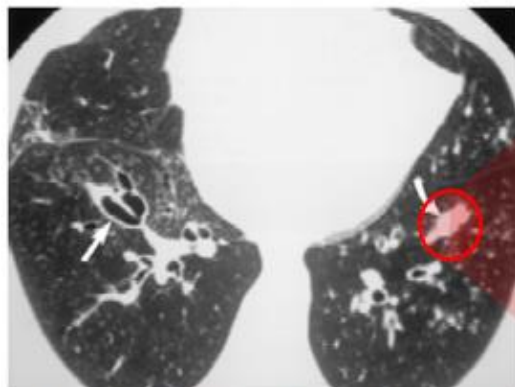


FIG. 23. Axial high resolution CT image (window width 1,000, level -700) reveals central bronchiectasis (straight arrow) and mucoid impaction (curved arrow), characteristic of allergic bronchopulmonary aspergillosis.

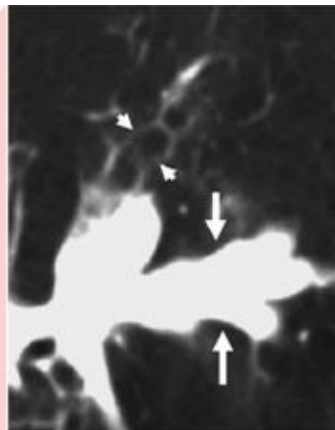
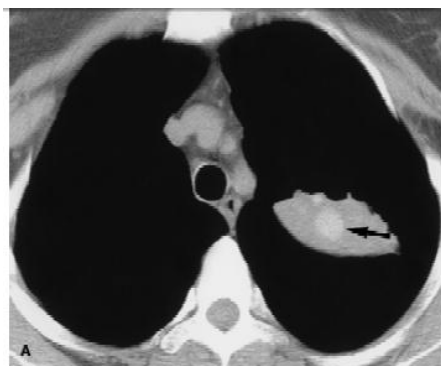
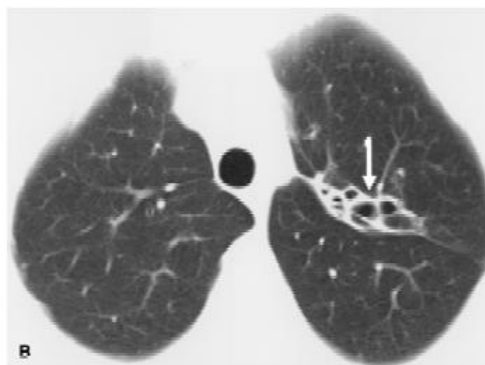
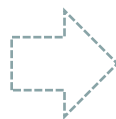

Fig. 1 ABPA. Varicose bronchiectasis (arrow heads) and mucoid impaction (arrows) in a segmental bronchus (arrow). Note the "finger-in-glove" appearance of the opaque mucoid impaction.

CT显示ABPA伴有中央支扩和粘液嵌塞



•纵隔窗CT影像显示在左上肺有一个细小的圆形阴影并伴有细微的黏液嵌塞

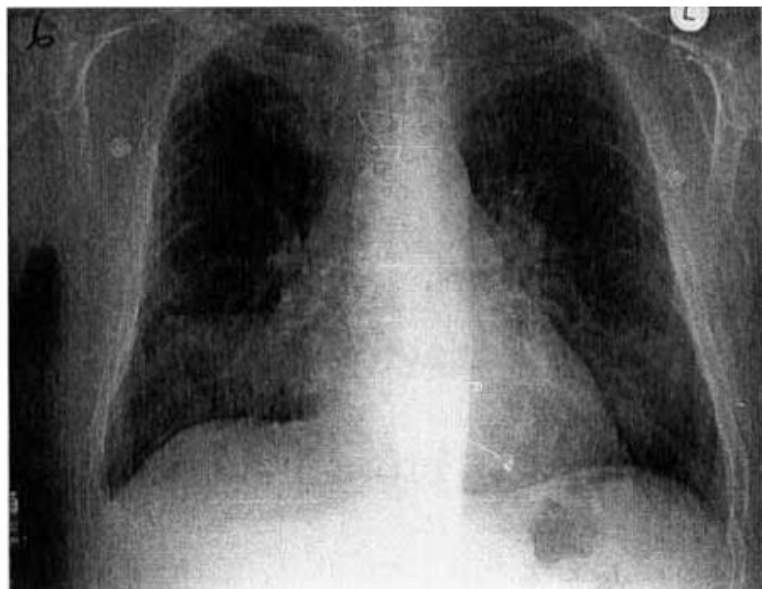


•3个月后肺部影像复查显示在之前粘液嵌塞的部位表现出清晰的支气管扩张

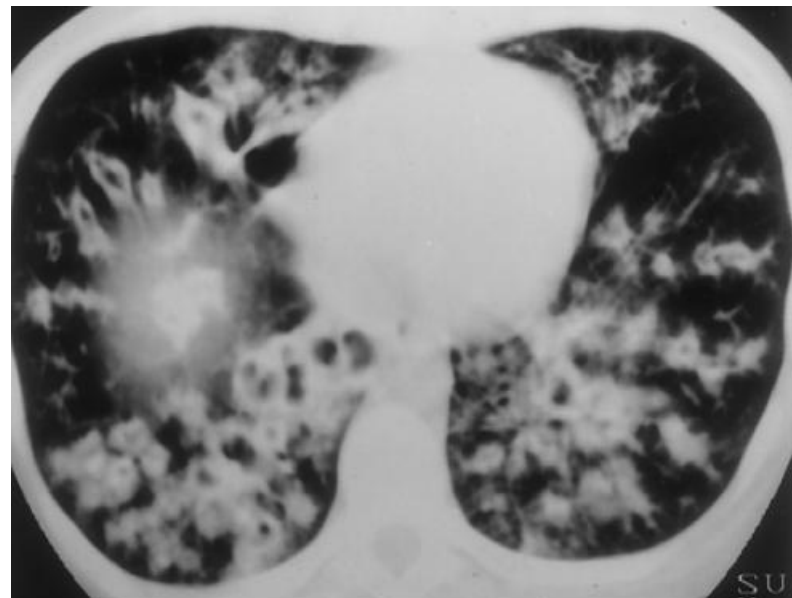
阻塞性支气管曲霉菌病（OBA）

支气管内寄生的非侵袭性曲霉菌。常导致假膜和溃疡的产生，最显著的特点就是腔内大量曲霉的生长常见的表现为粘液嵌塞。免疫受限患者常见，表现为咳嗽发热和新发的哮喘¹⁻²

1例心脏移植术后伴发OBA



1例艾滋病患者伴发OBA

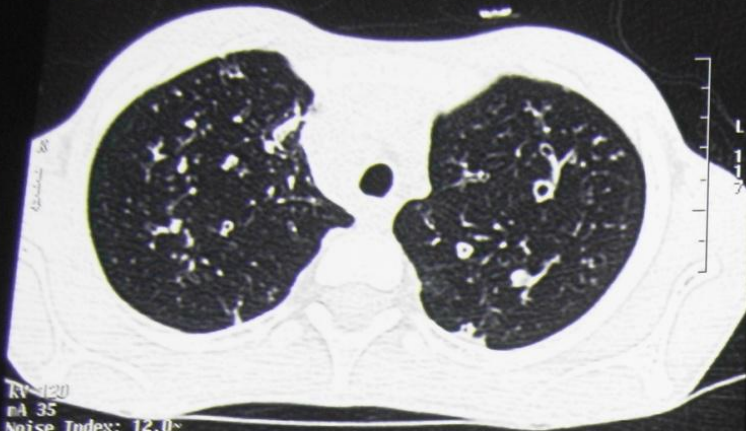

1. Hummel M, Mycoses 1993;36:425-8

2. 《侵袭性肺真菌病影像学图集》，何礼贤，李华茵，邵长周等

DFOV 30.0cm
LUNG/

512
MF:1.3



KV 120
mA 35
Noise Index: 12.0
Large Body
1.250mm/55.00 1.375:1
T1470: 0.0
0.8s /HE 10:38:20/00_72
V:1254 L:-569

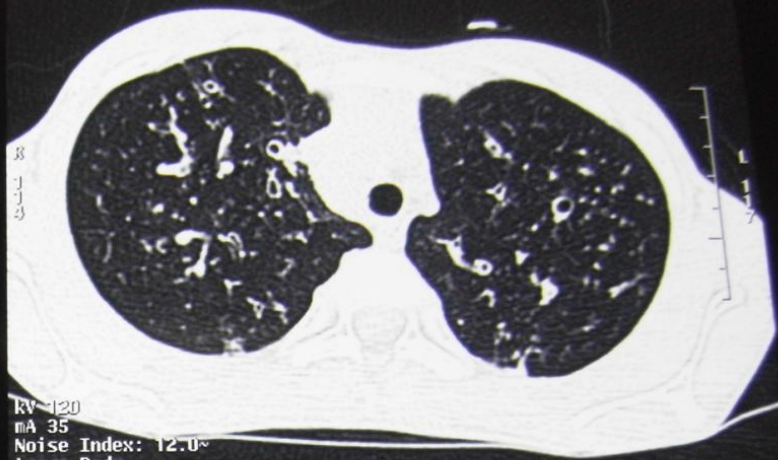LightSpeed VCT SYS#vct64 A 128
Ex: 28976
Se: 3
SN I57.00
In: 14

BEIJING CHILDREN HOSPITAL
Acc Num: 01904452
ZHANGSHIQI
M 12 00141906
DOB: 1998 Oct 25
2011 Jul 25
512
MF:1.3

DFOV 30.0cm
LUNG/

DFOV 30.0cm
LUNG/

512
MF:1.3

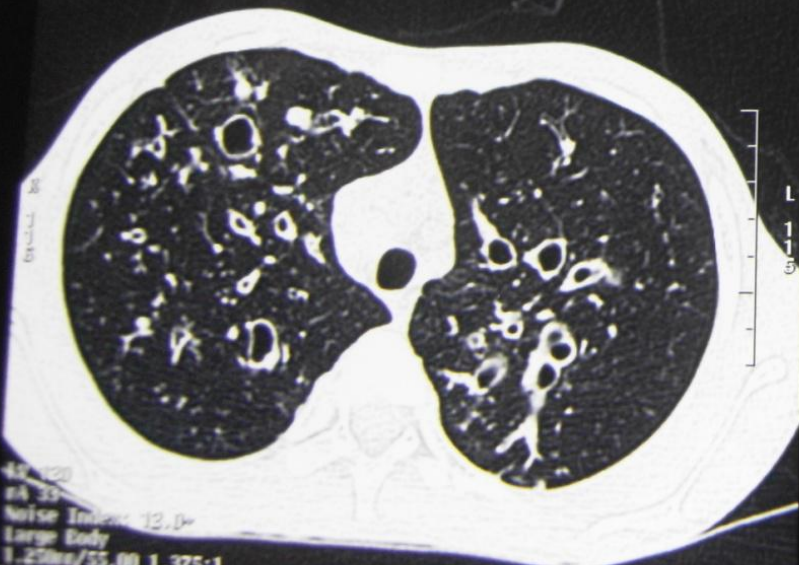

KV 120
mA 35
Noise Index: 12.0
Large Body
1.250mm/55.00 1.375:1
T1470: 0.0
0.8s /HE 10:38:20/00_79
V:1254 L:-569

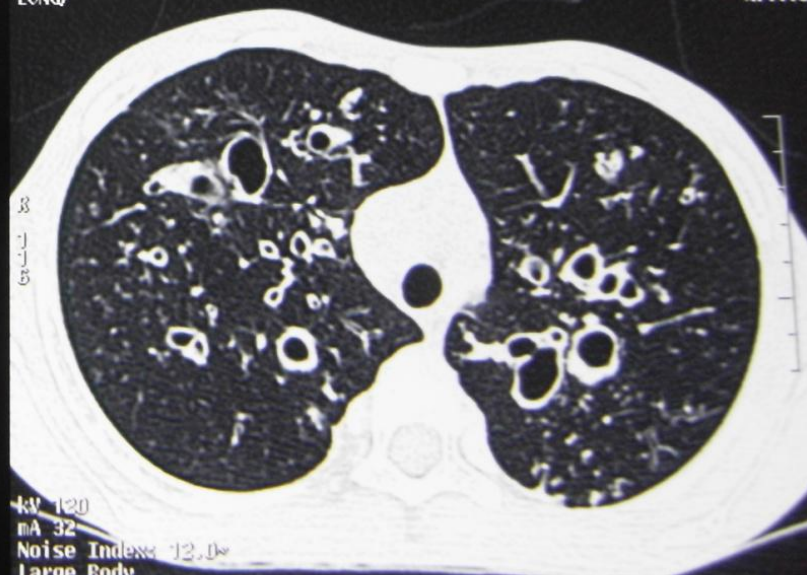LightSpeed VCT SYS#vct64 A 128
Ex: 28976
Se: 3
SN I62.00
In: 15

BEIJING CHILDREN HOSPITAL
Acc Num: 01904452
ZHANGSHIQI
M 12 00141906
DOB: 1998 Oct 25
2011 Jul 25
512
MF:1.3

DFOV 30.0cm
LUNG/



KV 120
mA 35
Noise Index: 12.0
Large Body
1.250mm/55.00 1.375:1
T1470: 0.0
0.8s /HE 10:38:20/01_01
V:1254 L:-569



KV 120
mA 32
Noise Index: 12.0
Large Body
1.250mm/55.00 1.375:1
T1470: 0.0

过敏性肺泡炎

急性过敏性肺泡炎

急性吸入抗原

发热、呼吸困难、喘息

环境接触时和临床和影像学表现可作出诊断

轻型病例胸片表现不明显，易误诊

过敏性肺泡炎的影像学表现

- 急性表现为边界模糊的小叶中心性结节
磨玻璃阴影
- 亚急性表现为弥漫性小叶中央毛玻璃样结节，
伴有粘液嵌塞

外源过敏性肺泡炎

过敏性肺泡炎是由于吸入曲霉菌孢子导致的系统性过敏反应。曲霉菌接触史通常发生在潮湿的起居空间和污水的误吸。

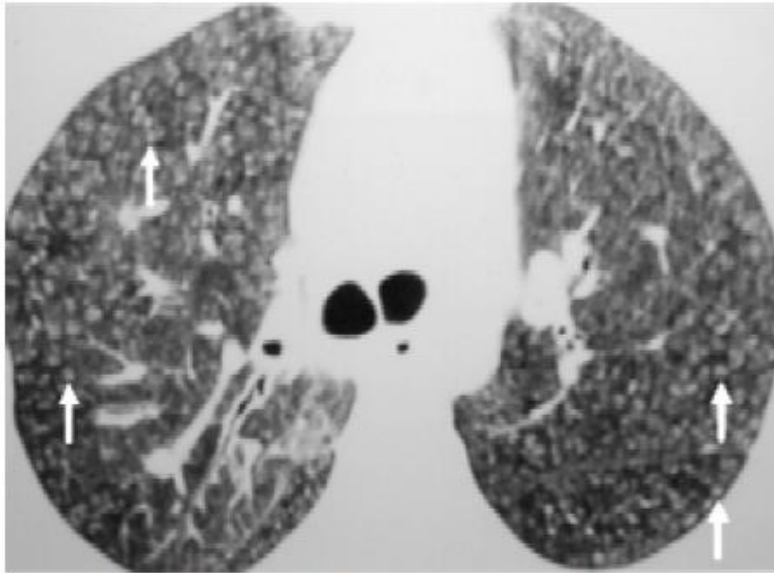


FIG. 29. Axial high resolution CT image (window width 1,000, level -700) in a patient with *Aspergillus*-induced subacute hypersensitivity pneumonitis. High resolution CT reveals the characteristic appearance of diffuse, bilateral poorly defined, ground-glass centrilobular nodules (arrows).

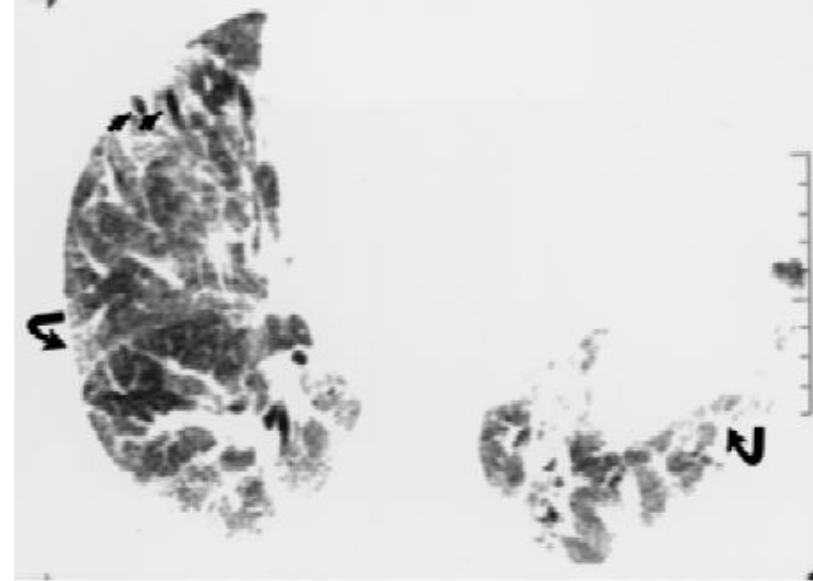
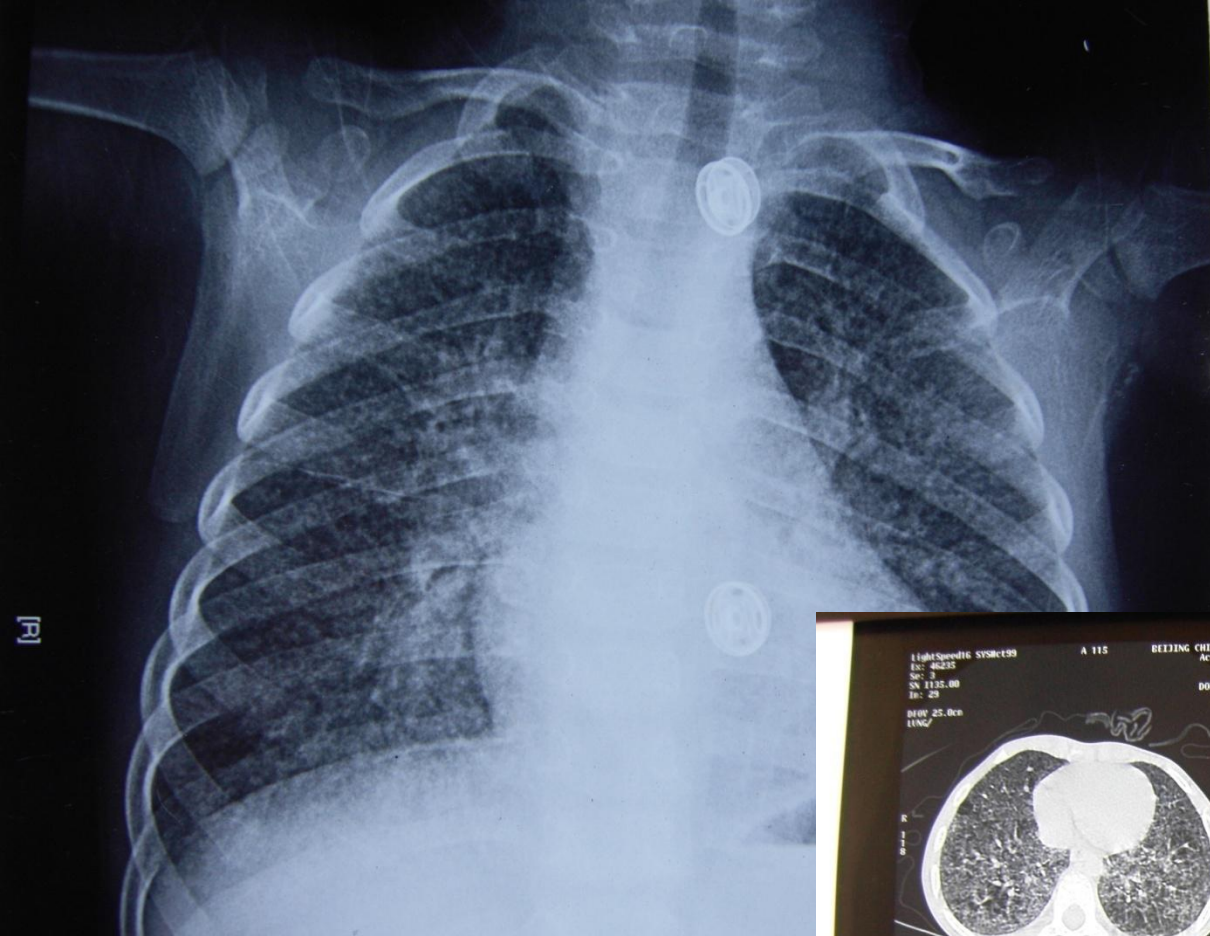
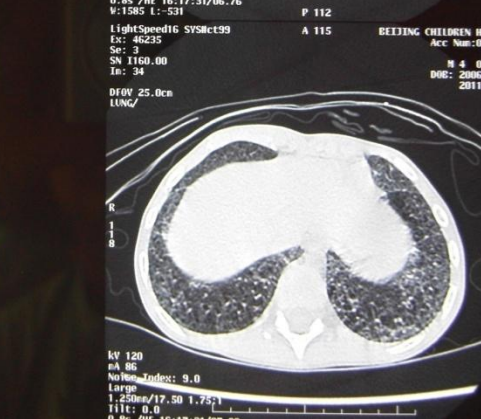
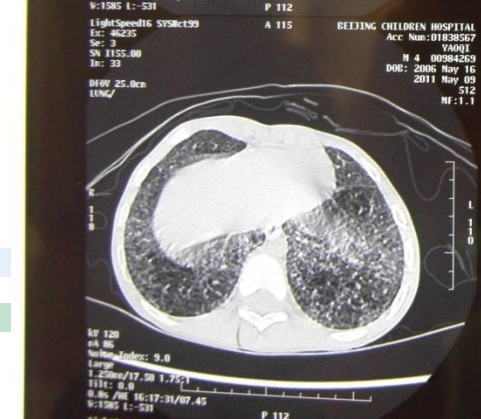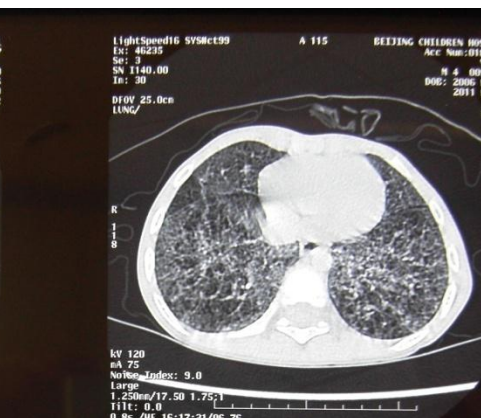
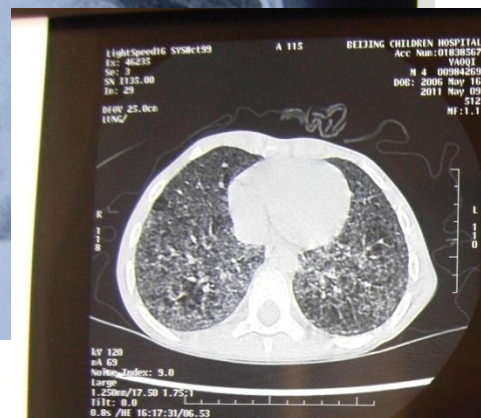


FIG. 30. High resolution CT image (window width 1,000, level -700) in a patient with chronic hypersensitivity pneumonitis related to *Aspergillus* exposure from a hot tub reveals bilateral traction bronchiectasis (straight arrows) associated with ground-glass opacity and reticulation and coarse linear opacities (curved arrows), consistent with fibrosis related to chronic hypersensitivity pneumonitis.



[R]



提示

- 曲霉引起的过敏性肺泡炎
- 可以是慢性肉芽肿的表现

肺曲霉菌病治疗

- 抗真菌治疗
- 糖皮质激素治疗
- 外科治疗
- 免疫增强剂等

抗真菌治疗

可选择伏立康唑、伊曲康唑、卡泊芬净、两性霉素B，病情重者可联合两种抗真菌药物治疗。氟康唑对肺曲霉感染无效。

两性霉素B是治疗侵袭性肺曲霉病的传统药物。目前认为病情较重者，可首选伏立康唑。卡泊芬净适用于患者不能耐受其他药物或其他药物无效时的治疗。

CPA treatment - principles

- ❑ Important defects in innate immunity so long term (i.e. life-long) antifungal treatment, if possible
- ❑ Some patients appear not to progress, but should to be kept under observation, as progression may be subclinical
- ❑ Minimise other causes of lung infection with immunisation and antibiotics
- ❑ Itraconazole, voriconazole and posaconazole all effective, but adverse events – check levels
- ❑ Amphotericin B and micafungin IV useful for failure of oral azole therapy
- ❑ Gamma IFN helpful in some cases
- ❑ Monitor for azole resistance



北京儿童医院
BEIJING CHILDREN'S HOSPITAL

谢谢

气道侵袭性曲霉病

- 气管
- 支气管
- 细支气管炎

气道侵袭性曲霉病

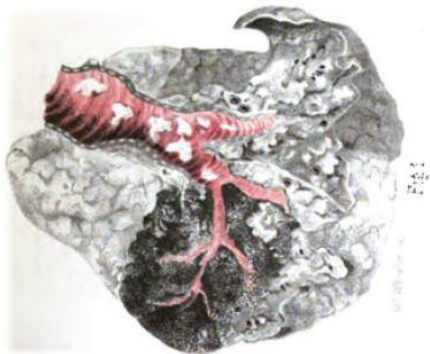

Figure 1. Drawing of the appearance of the airways from the autopsy of a 3-year-old girl with *Aspergillus* tracheobronchitis who was presumably not immunocompromised.

- 组织学证明曲霉侵犯气道基底膜和细支气管，没有或很少血管浸润和凝固性坏死。
- 约占IPA的14-34%，常发生于严重免疫抑制患者，部分见于免疫正常者。

大气道IA：段支气管以近（包括气管）

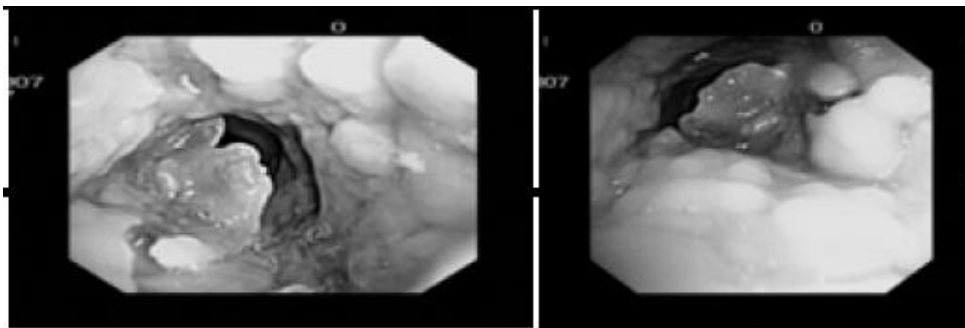
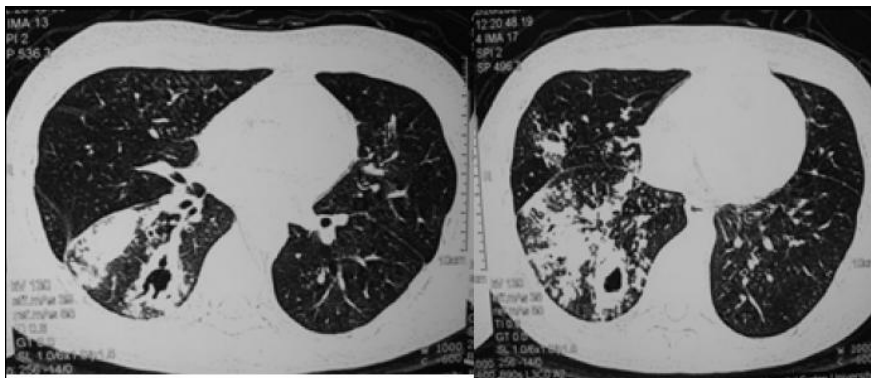


图1. 气管腔内声门下约1cm始见广泛分布的、大小不等的灰白色突出物病向下延伸至隆突上5cm。活检病理示镜下为坏死组织及曲霉团，未见支气管壁及肺泡组织。组织培养为烟曲霉。

纤支镜窥见管腔内块物，不光滑，表面可有坏死或分泌物；管腔见不同程度阻塞。CT无异常，或见阻塞性肺炎/不张，亦可以有肺内浸润。

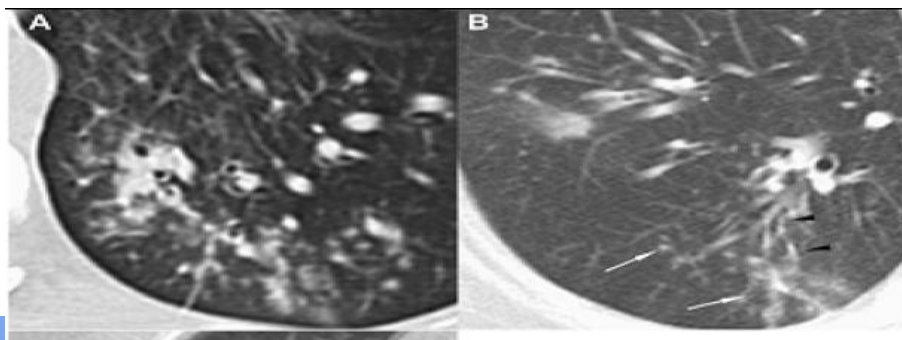
气道侵袭性曲霉病

中气道IA：亚段支气管至5mm直径的细支气管



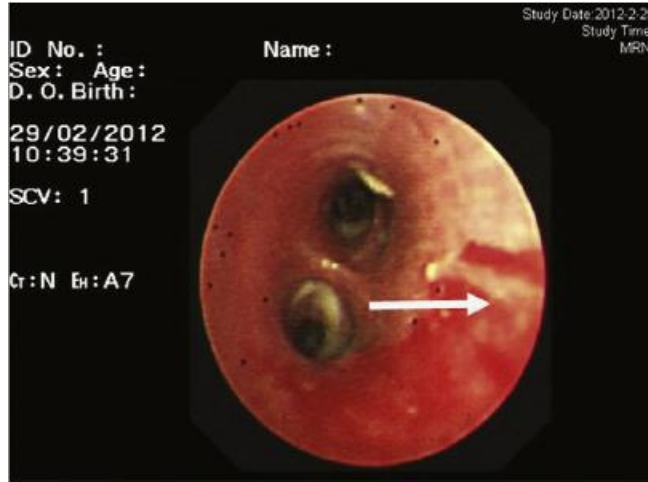
CT示肺实变、境界不清的结节，周围有浸润，偶有晕影，病灶内常见坏死和空洞，甚至巨大空洞(慢性坏死性曲霉病)；病灶呈单发或多发。阻塞性支气管肺曲霉病在CT上显示双肺圆形和管状阴影，支气管镜发现管腔内充满炎症物质。

小气道IA：< 5mm细支气管至呼吸性细支气管



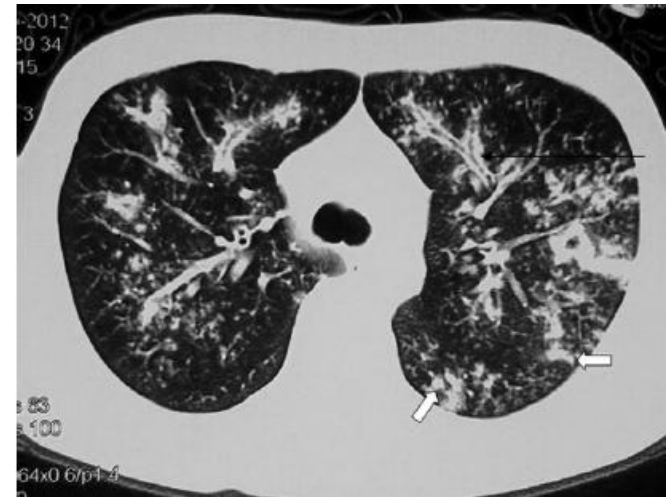CT示广泛的小叶中央性小结节，可见树芽征 (tree-in-bud)；或见小叶中央性实变、支气管周围实变，常见小空洞。此外亦可表现为弥漫性磨玻璃样渗出

气道曲霉菌病CT下树丫征表现



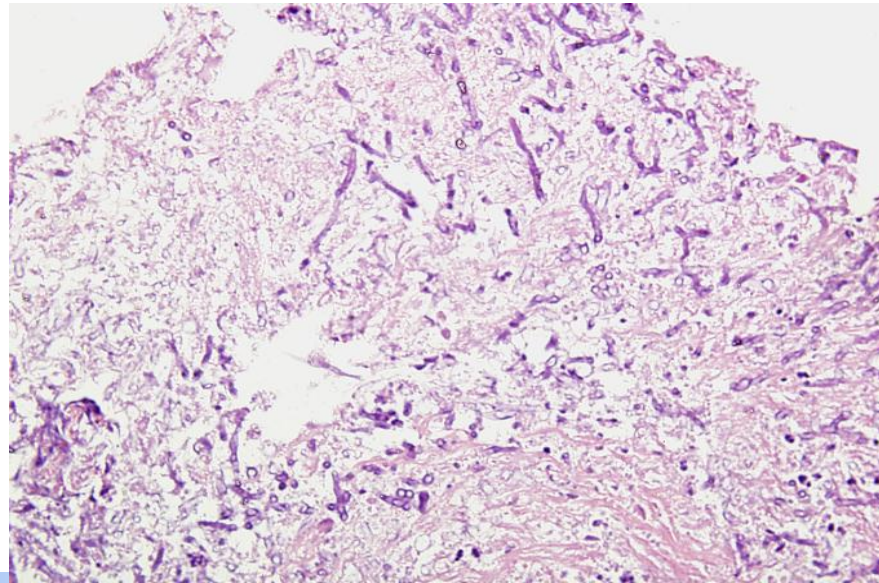
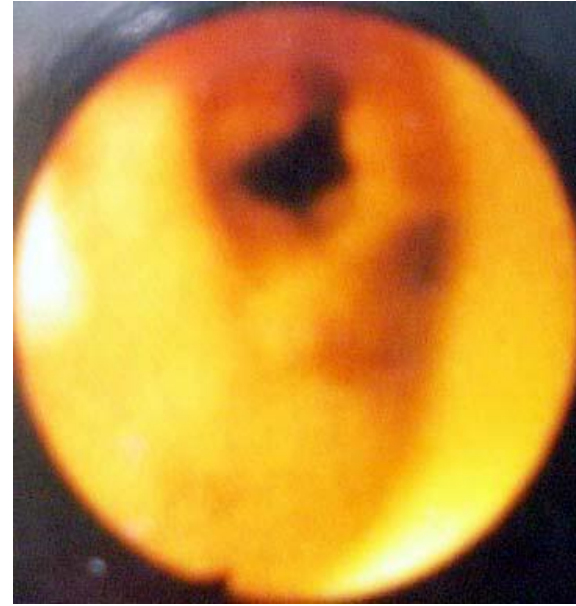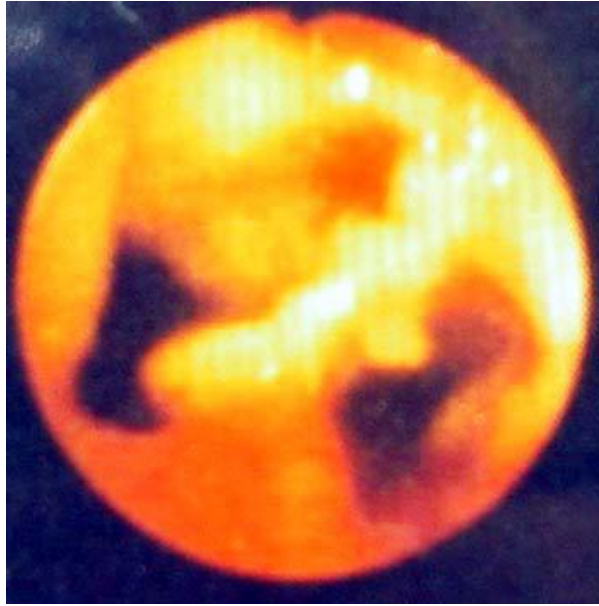支气管镜检查，右侧肺叶病变（如箭头所示）。脓性分泌物覆盖了支气管壁

胸部CT扫描，双肺存在多发的病变，包括：空腔，细支气管炎伴支气管壁增厚，以及树丫征（如白色箭头）





北京儿童医院
BEIJING CHILDREN'S HOSPITAL



不同肺曲霉菌病类型对应HRCT表现

肺曲霉菌病类型	高分辨CT (HRCT) 表现
急性支气管肺炎	细支气管周围实变和结节，小叶中心结节
血管侵袭性肺曲霉病	结节伴有晕轮，数日后进展为空腔
急性细支气管炎/气道侵袭性	通常不显著，气道伪膜性病变或粘膜增厚
半侵袭性肺曲霉病	肺叶上段实变及胸膜增厚，数周（月）后进展为空腔，空腔内存在阴影
曲霉球	CT下可发现可移动的腔内团块状影
ABPA	肺叶中段和上段出现支气管扩张和粘液嵌塞，肺小叶亚段支气管的嵌塞
过敏性肺泡炎	急性表现为多发毛玻璃样阴影及实变；亚急性表现为弥漫性小叶中央毛玻璃样结节，伴有粘液嵌塞；慢性表现为牵引性支气管扩张蜂窝状病变，毛玻璃样阴影等
阻塞性支气管曲霉菌病	肺叶下段粘液嵌塞，结节

临床常见的肺部曲霉菌病 HRCT下的影像学表现

图1A 气腔小结节和树芽征

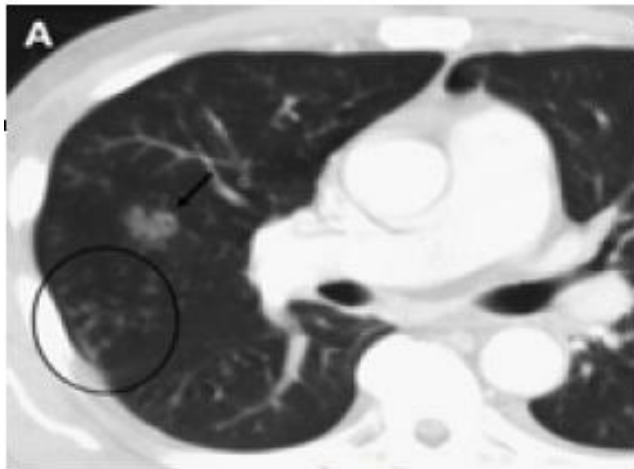


图1B 磨玻璃样病变

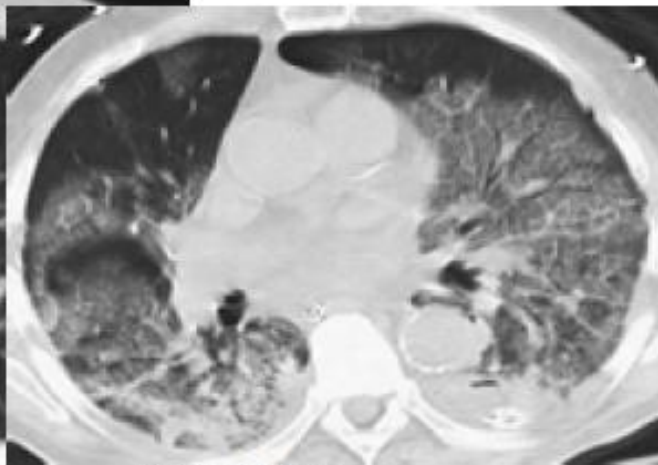


图1C 气腔实变

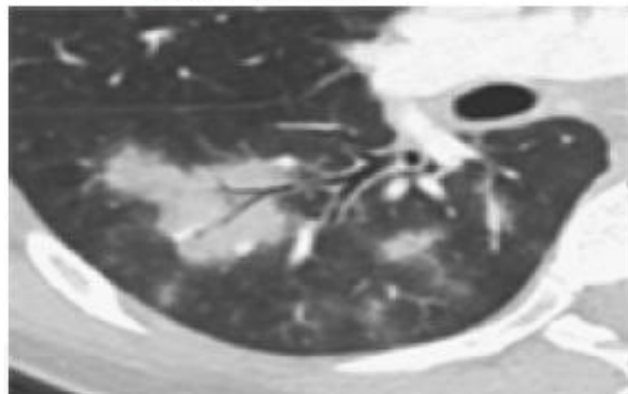
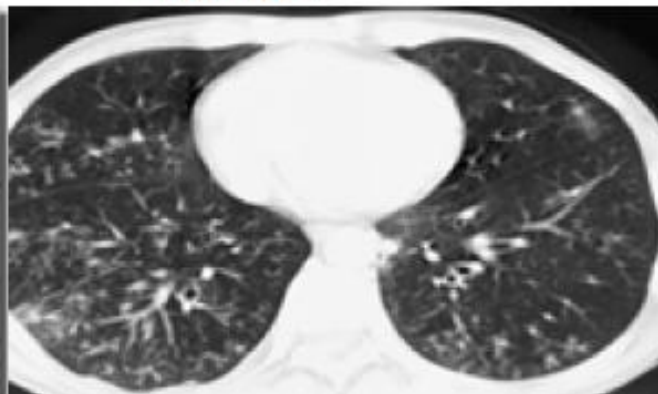
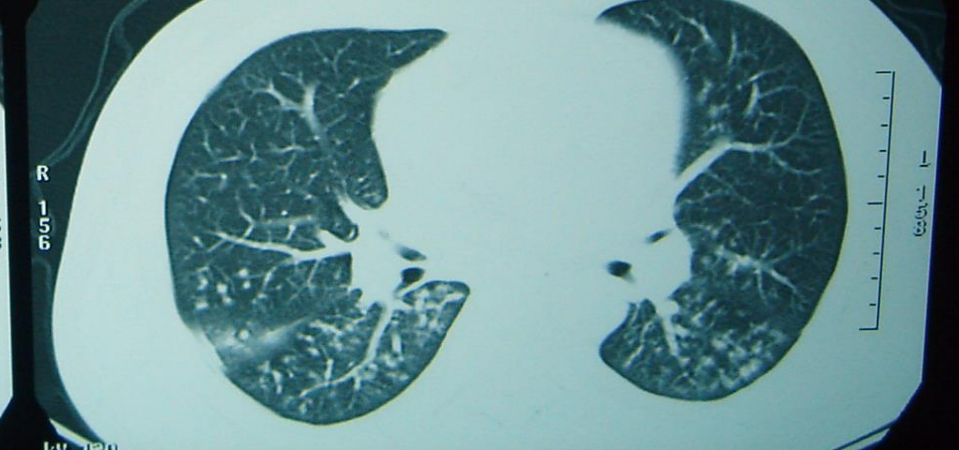
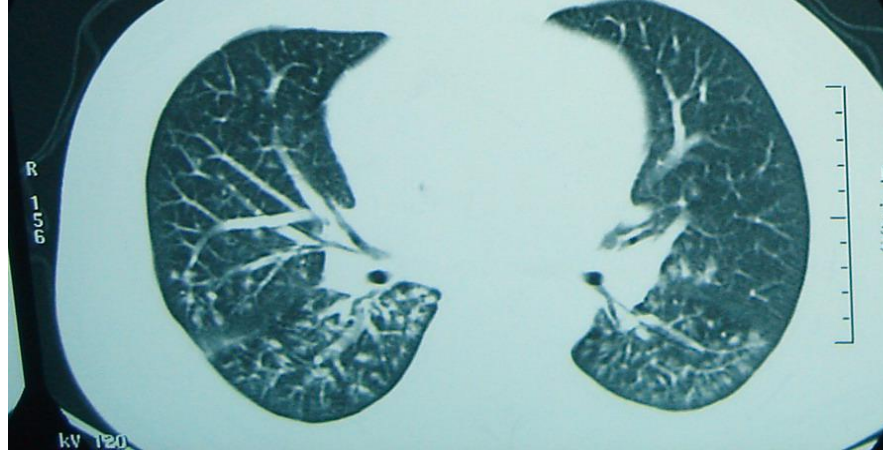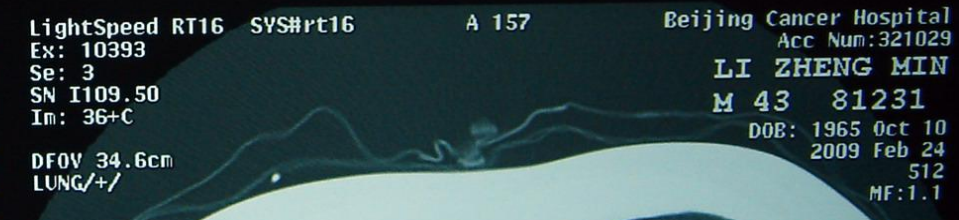

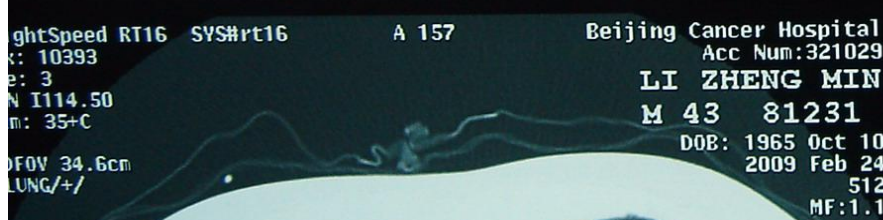
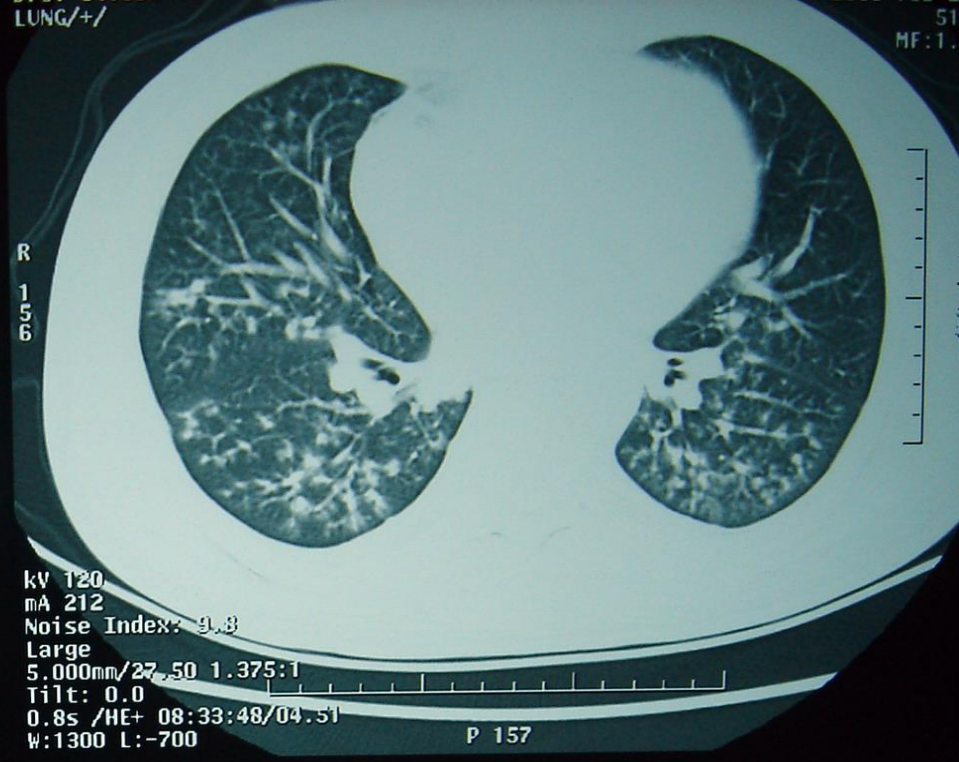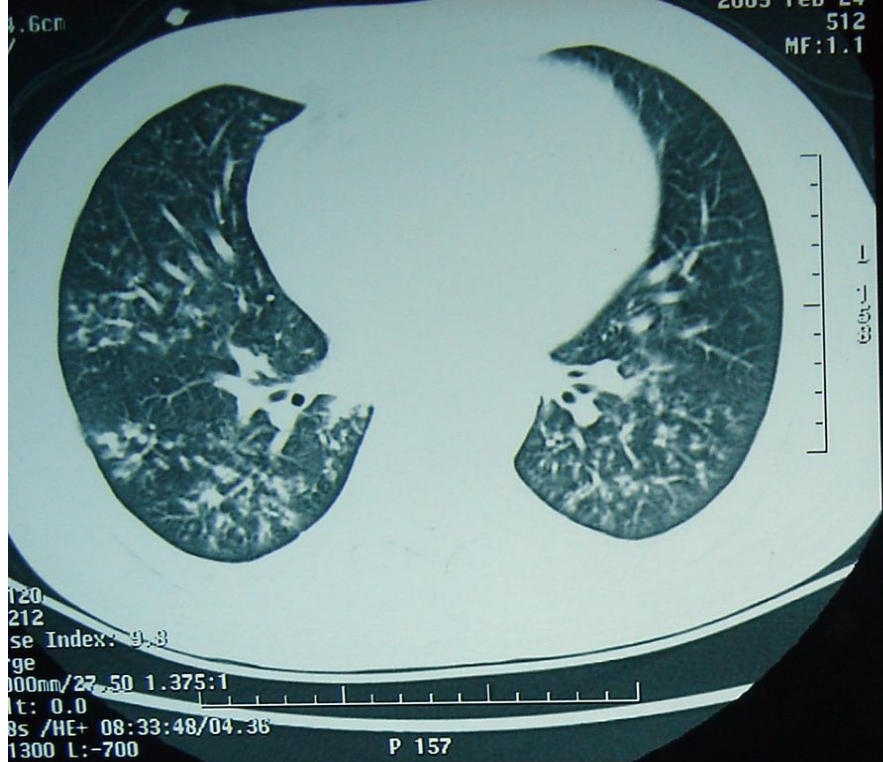图1D 树芽征

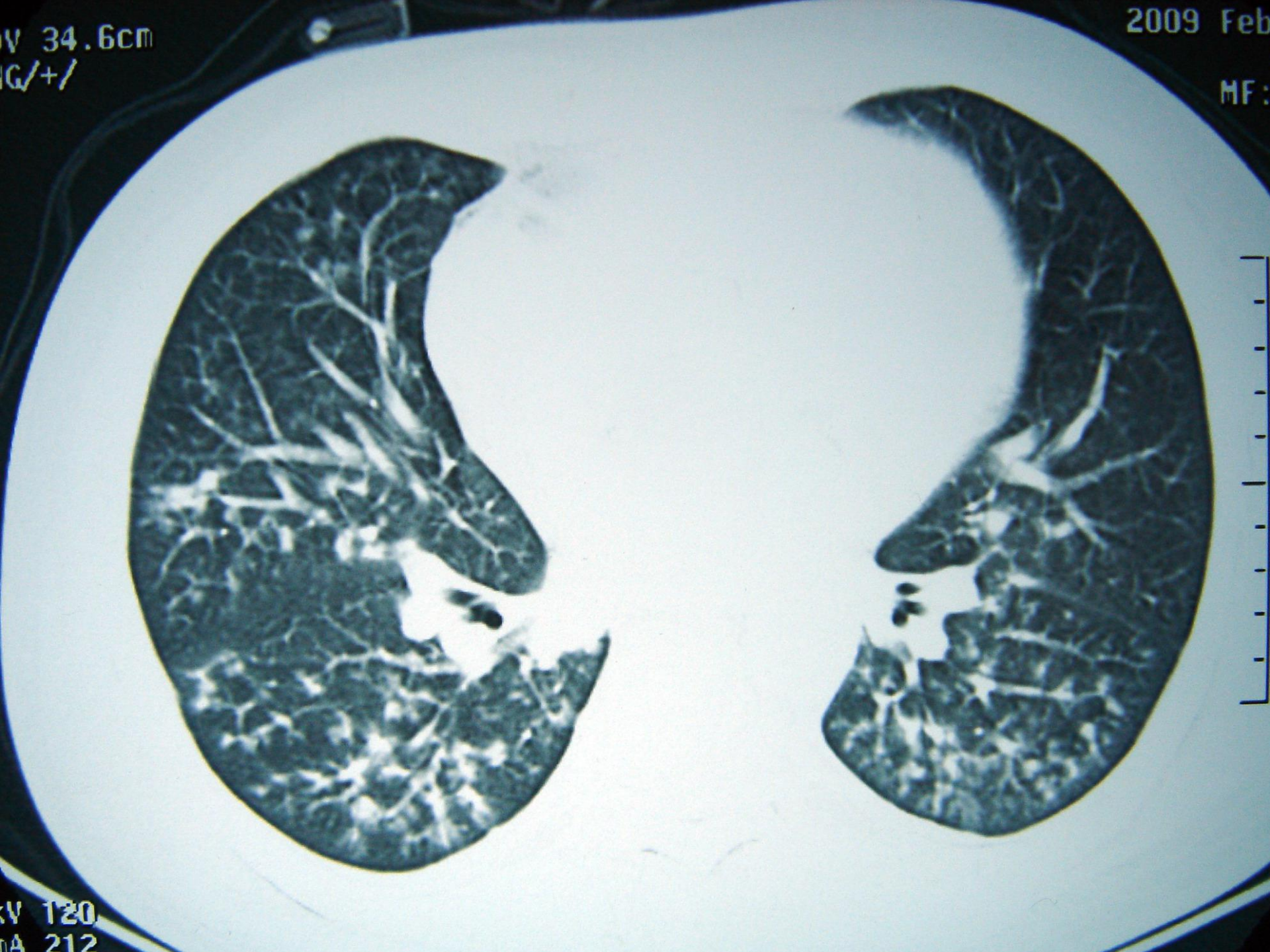





V 34.6cm
G/+/

2009 Feb

MF:



V 120
A 212



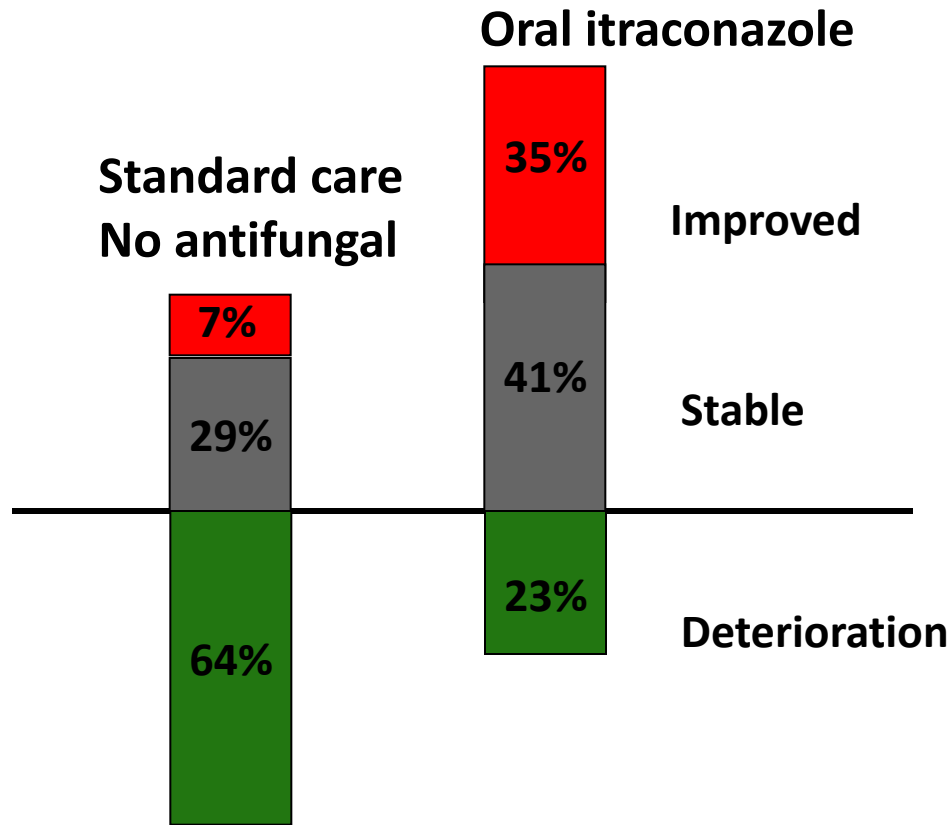


Oral triazole therapy for CPA

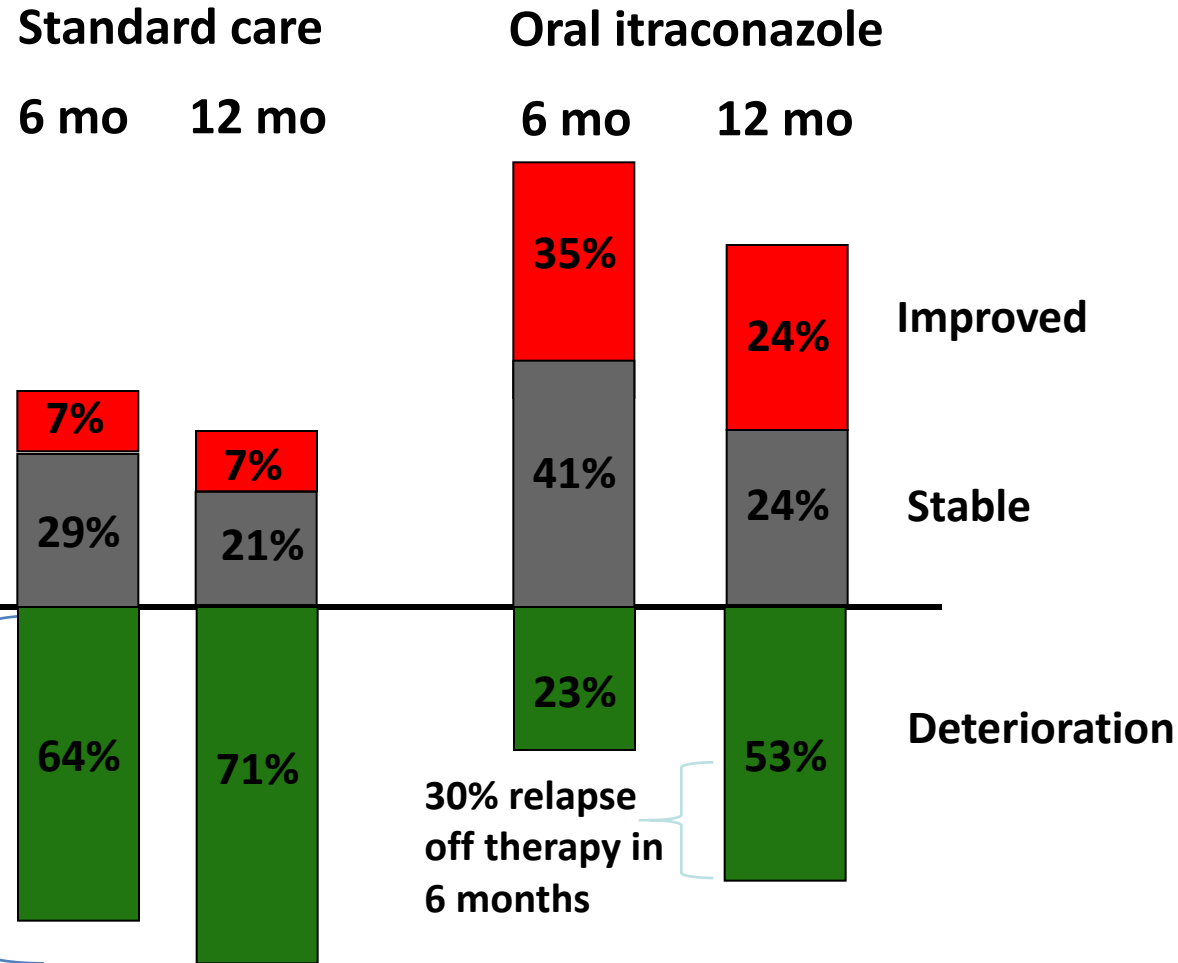
Population	Intention	Intervention	SoR	QoE	Reference	Comment
CPA patients with progressive disease	Control of infection	Itraconazole Start 200mg BID, adjust with TDM	A	II	Agarwal, 2013; De Buele, 1998, Dupont, 1990; Campbell, 1991; Tsubura, 1997; Denning, 2003; Nam, 2009; Al-shair, 2013	No data to indicate which agent is preferable.
		Voriconazole Start 150-250mg BID, adjust with TDM	A	II	Saito, 2009; Cadranel, 2012, Jain, 2006; Sambatakou, 2006; Camuset, 2007; Philippe, 2009; Al-shair, 2013	Voriconazole preferred for SIA/CNPA and patients with fungal balls to minimise risk of resistance
		Posaconazole Start 400mg BID	B	II	Felton, 2010;	

TDM required for itraconazole and voriconazole or desirable for posaconazole
 Target concentrations transferred from IA, PK/PD and prophylaxis data

Impact of oral itraconazole therapy for chronic pulmonary aspergillosis after TB over 6 months



Chronic pulmonary aspergillosis - response to itraconazole after 6 months therapy, compared to





Alternative intravenous therapy for CPA

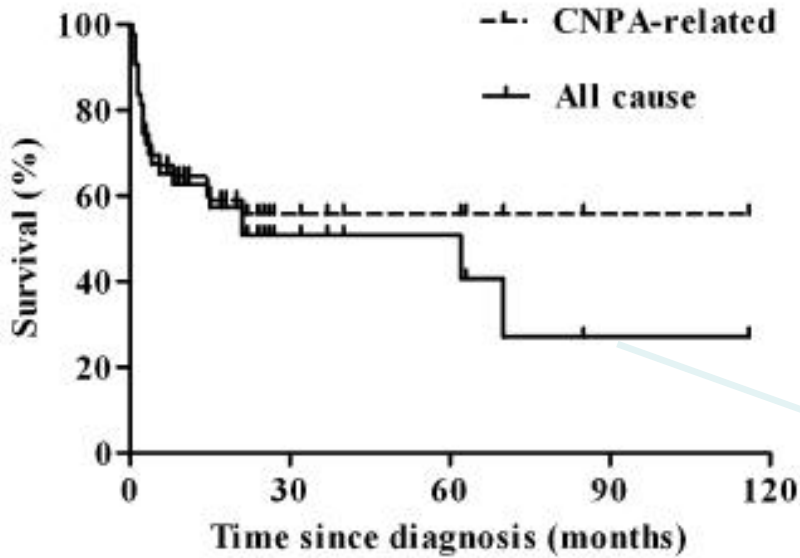
Population	Intention	Intervention	SoR	QoE	Reference	Comment
CPA patients with progressive disease, who fail, are intolerant of triazoles or have triazole resistance	Control of infection	Micafungin 150mg/d	B	II	Kohno, 2011; Kohno, EJCMID 2013; Saito, 2009; Kohno, 2011; Kohno, 2004; Izumikawa, 2007; Yasuda, 2009; Nam, 2009	
		Amphotericin B deoxycholate 0.7-1.0mg/kg/d	C	III	Denning, 2003	
		Liposomal AmB 3mg/kg/d	B	Ila	Newton, 2014	
		Caspofungin 50-70mg/d	C	Ila	Kier, 2014; Kohno ECCMID 2013	



北
BEIJING

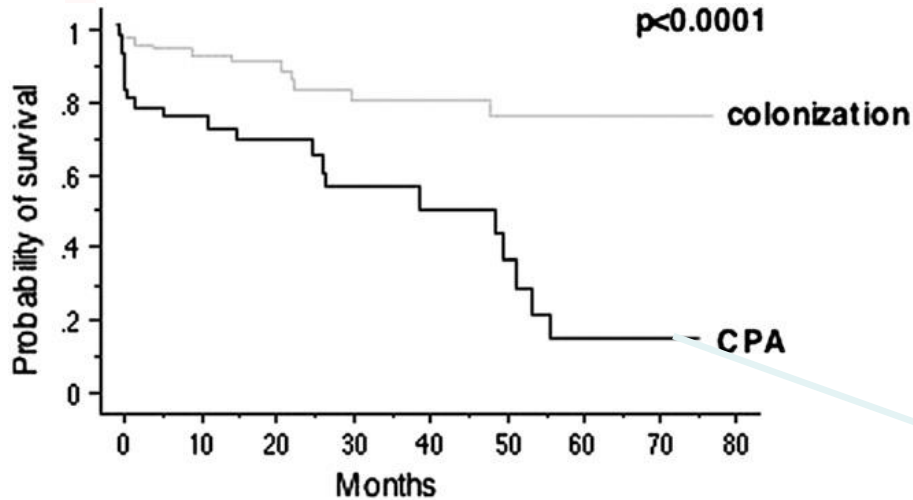
Prognosis

CPA + subacute IA
Korea (1995-2007)



75% mortality

Japan (2001-9)



80% mortality



Local cavity therapy for CPA

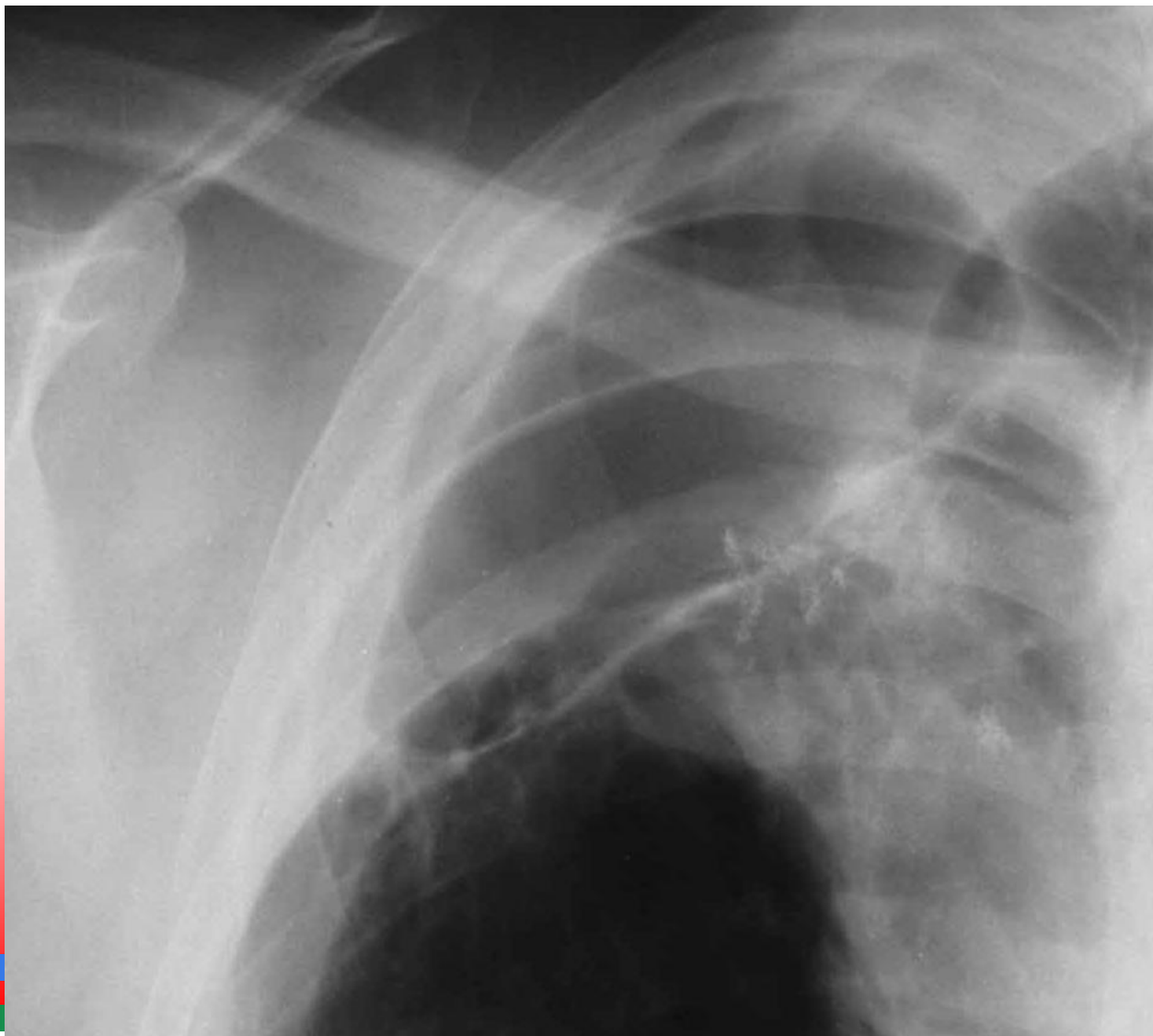Population	Intention	Intervention	So R	Qo E	Reference	Commen t
CPA with aspergilloma, unwilling or unable to take oral therapy, multi-azole resistance and inoperable	Control of infection	Instillation of amphotericin B deoxycholate into cavity	C	II	Giron, 1998; Kravitz, 2013	Experime ntal



Duration of antifungal therapy for CPA

Population	Intention	Intervention	SoR	QoE	Reference	Comment
CPA patients on antifungal therapy	Control of infection, arrest of pulmonary fibrosis, prevention of haemoptysis, improved quality of life.	6 mo antifungal therapy	B	II	Agarwal, 2013; Yoshida, 2012; Nam, 2010; Felton, 2010; Camuset, 2007; Jain, 2006; Cadranel, 2012	Optimal duration of therapy in CPA is unknown, indefinite suppressive therapy may be appropriate in selected patients
		Long term antifungal therapy, depending on status and drug tolerance	C	III	Felton, 2010; Camuset, 2007; Jain, 2006; Cadranel, 2012	
					Camuset, 2007 Cadranel, 2012	
Subacute IA/CNPA	Cure	6 mo	B	II		

Chronic cavitary pulmonary aspergillosis



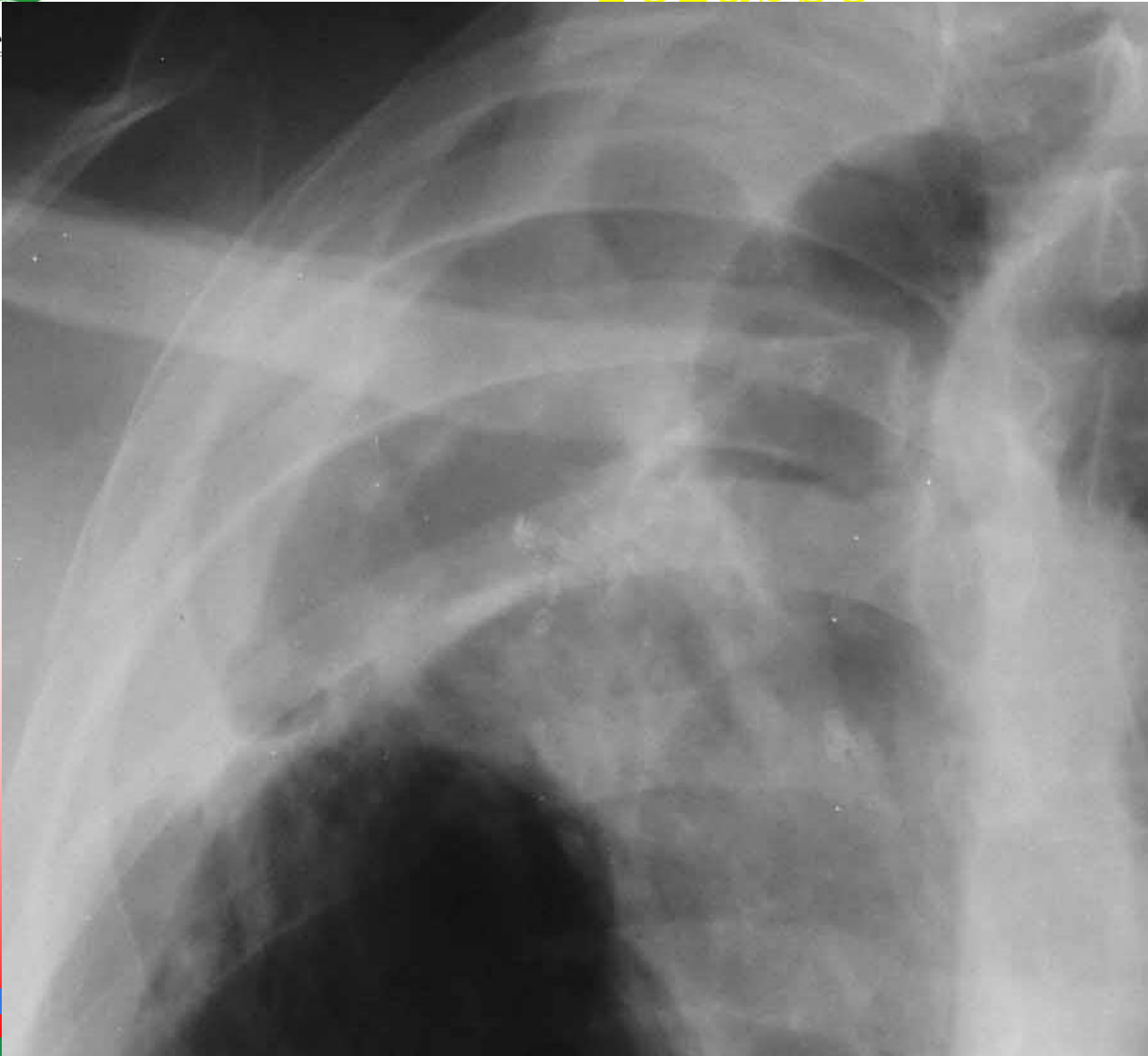Patient RW
June 2002

Stable,
asymptomatic
, normal
inflammatory
markers,
just
detectable
Aspergillus
precipitins

Itraconazole
stopped
after 5
years

Chronic cavitary pulmonary aspergillosis relapse

北京儿
BEIJING CHILDREN'S HOSPITAL



Patient RW
January
2003

Marked
change,
with new
cough,
weight
loss,
↑ CRP/ESR
and
↑ Aspergill
us
precipitins

Itraconazol
e restarted



Corticosteroid therapy for CPA

Population	Intention	Intervention	SoR	QoE	Reference	Comment
CPA patients with progressive disease not on adequate antifungal therapy	Symptom control	Prednisolone	D	III	Denning, 2003	Without adequate antifungal therapy, corticosteroid accelerates progression Note azole/steroid drug interaction
CPA patients with progressive disease on adequate antifungal therapy	Essential control of underlying disease	Prednisolone 5-30mg/d or other immunosuppressive therapy	B	II		Common indications include sarcoidosis, rheumatoid arthritis, COPD and ABPA/asthma exacerbations



Therapies for haemoptysis in CPA

GREAT ORMOND STREET HOSPITAL

Population	Intention	Intervention	So R	Qo E	Reference	Comment
CPA patients with haemoptysis	Arrest of bleeding	Tranexamic acid 1.5-4g/d	B	II	Tscheikuna, 2002; Kokturk, 1997	In selected cases in which BAE and antifungal disease control is not achieved
		Factor 7	C	III		
		Bronchial artery embolisation	A	II	Jardin, 1988; Swanson, 2002; Corr, 2006; Serasli, 2008; Shigemura, 2009	
		Surgical resection	B	II	Shigemura, 2009; Erdogan, 2005	

Have omitted management of massive haemoptysis from Table – will be referred to in written text. Would be helpful to have an authoritative text/reference on this.

Indications for surgery in CPA



Population	Intention	Intervention	SoR	QoE	Reference	Comment
Simple/single aspergilloma	Cure and prevention of life-threatening haemoptysis	Lobectomy or any other segmental resection	A	II	Daly, 1986; Regnard, 2000; Kim, 2005; Pratap, 2007; Brik, 2008; Muniappan, 2014; Farid, 2013; Chen, 2012; Nacera, 2012; Lejay, 2011; IDSA 2008	Ratio risks/benefits = define surgical risk assessment scale Patients should be seen in centres with experience of aspergillois surgery May require conversion to thoracotomy
		Video-assisted thoracic surgery (VATS)	B	II	Chen, 2014; Muniappan, 2014.	
CCPA refractory to medical management (including multi-azole resistance) with antifungal treatment and/or life-threatening haemoptysis.	Improved control of disease, possibly cure	Careful risk assessment, followed by lobectomy or pneumonectomy	A	II	Kim, 2005; Farid, 2013 (others)	Prior embolization as a temporizing procedure Highly experienced surgical team required
		Thoracoplasty with simultaneous cavernostomy and muscle transposition flap	C/D	III	Grima, 2008 Igai , 2012	

Text will elaborate on bronchoscopic fungal ball removal, pre-operative assessment, bronchial artery embolisation, nutrition, antifungal therapy and peri-operative strategies to reduce risk of pleural aspergillois

Reducing the risk of *Aspergillus* empyema

- If likelihood of spillage intracavitary contents low, no antifungal therapy
- If likelihood of spillage intracavitary contents moderate or high, give pre- and postop antifungal therapy, usually voriconazole, sometimes micafungin
- Beware drug interactions with voriconazole
- If spillage occurs, wash pleural space with amphotericin B or taurolidine 2%.
- Follow up after surgery required, if

Assessing risk pre-operatively

1

Lower risk	Higher risk
Risk of <i>Aspergillus</i> empyema	
Intrapulmonary cavity	Pleural involvement including thickening
Solid lesion	Cavitary lesion with fungal ball or fluid level
Smooth-walled cavity	Irregular or bumpy cavity surface (indicating fungal growth on surface of cavity)
Single lesion or small, localised collection of several interrelated lesions	Extensive multicavity lesion
	Prior radiotherapy to proposed surgical site
	Prior lobectomy or other thoracic surgery

Assessing risk pre-operatively

2

Lower risk	Higher risk
Risk of space infection	
Localised lesion and lobectomy or segmental resection	Second lobectomy or pneumonectomy
Chest wall normal	Scoliosis or ankylosing spondylitis
	Other pleural/pulmonary disease preventing full lung mobilisation
	Immunosuppression
	Intrapleural spillage during surgery

Assessing risk pre-operatively

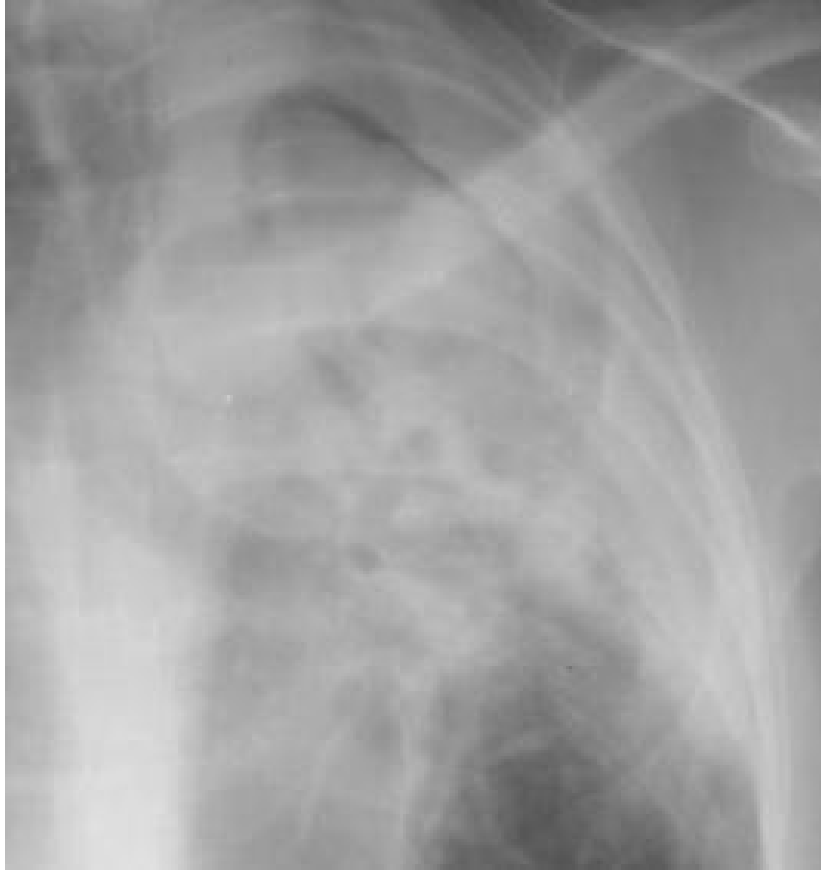3

Lower risk	Higher risk
Risk of overall poor outcome	
Good pulmonary function	FEV1 <1.0 L/sec
Young	Older (> 70 years)
Well nourished	Thin, low BMI or reduced albumin
No other significant comorbidities	Diabetes, other concurrent pulmonary infection (ie non-tuberculous mycobacterial or <i>Pseudomonas</i> infection)
	Other associated significant comorbidities (i.e. lymphoma, autoimmune hepatitis, organ transplantation)

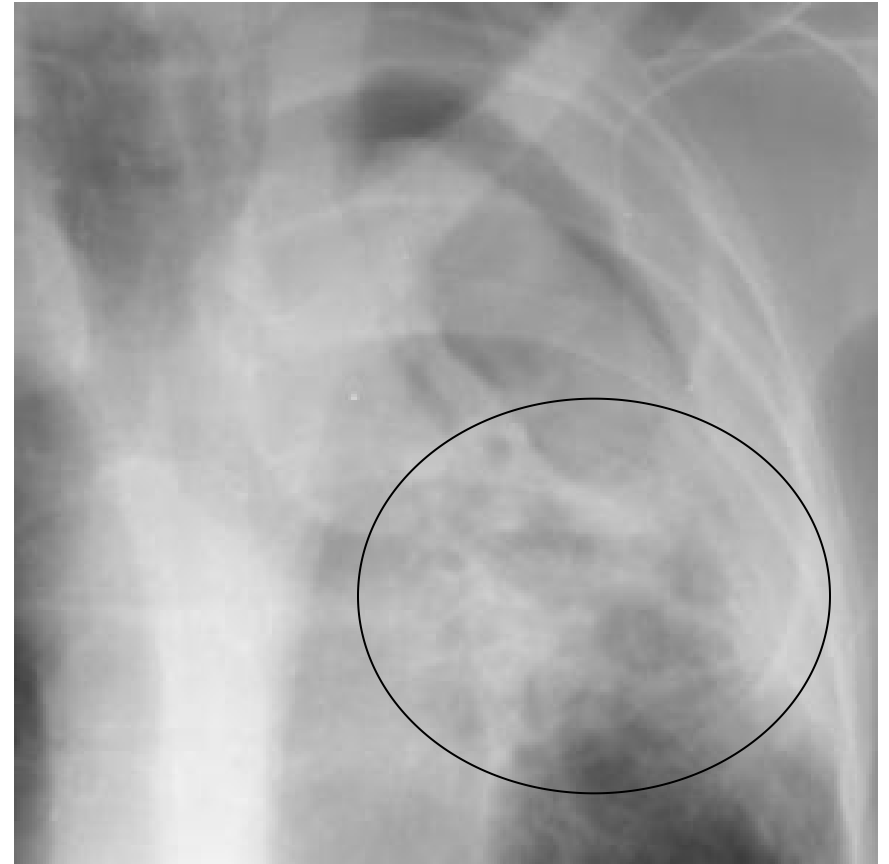


北京儿童医院
BEIJING CHILDREN'S HOSPITAL

Chronic cavitary pulmonary aspergillosis - an example of radiographic failure



Patient SS
April 2004



Patient SS
July 2004, despite
receiving itraconazole
for 3 months



北京儿童医院
BEIJING CHILDREN'S HOSPITAL

Aspergillus nodule

Natural history - unclear

Treatment, if not fully resected - unclear

We do a careful (3 monthly) follow up for 1 year with at least 1 repeat CT scan.

If multiple nodules - risk of tumour in one of the nodules.
cough, five complained of dyspnoea, two complained of weight loss, and one complained of haemoptysis.



Follow up of Aspergillus nodule and after resection surgery

Population	Intention	Intervention	SoR	QoE	Reference	Comment
Aspergillus nodule not treated with antifungal therapy	To identify progression early and/or carcinoma of lung if multiple lesions	3-6 mos clinical follow up with (low dose) imaging, inflammatory markers and Aspergillus IgG/precipitins	A	III	Farid, 2013; Muldoon, 2014	Not necessary if entire single nodule resected
Post-lobectomy/pneumonectomy	To detect recurrence early	3-6 mos then 6 monthly for 3 years with inflammatory markers and Aspergillus IgG/precipitins	A	III	Farid, 2013.	No predictors of recurrence yet described. Full re-evaluation if consistent increase in Aspergillus IgG titres.



Respiratory specimen diagnosis of CPA

北京儿童医院

Population	Intention	Intervention	SoR	QoE	Reference	Comment
Cavitary or nodular pulmonary infiltrate in non-immunocompromised patients	Diagnosis or exclusion of CPA	Direct microscopy for hyphae	A	II	Uffredi, 2003	In CPA histology distinguishes between SAIA/CNPA and CCPA. Microscopy positive is a strong indicator of infection
		Histology	A	II	Denning, 2003;	
		Fungal culture (respiratory secretion)	A	III		
	To document or exclude other pathogens	Fungal culture (transparietal aspiration)	B	II	Horvath, 1994	Bacterial culture plates less sensitive than fungal culture plates
		Aspergillus PCR (respiratory secretion)	C	II	Denning, 2013; Duddy, 2012	PCR more sensitive than culture
Bacterial culture	C	II	Horvath, 1994.			

Molecular detection of *Aspergillus* spp. in sputum

Laboratory result	CPA
Culture positive for <i>A. fumigatus</i>	7/42 (16.7%)
qPCR positive for <i>Aspergillus</i> spp	30/42 (71.4%)




Antigen diagnosis of CPA

Population	Intention	Intervention	SoR	QoE	Reference	Comment
Cavitary or nodular pulmonary infiltrate in non-immunocompromised patients	Diagnosis or exclusion of CPA	Antigen (BAL)	B	II	Izumikawa, 2012	Antigen studied in BAL and serum, but not sputum.
		Antigen (serum)	C	II	Izumikawa, 2012; Kono, 2013; Shin, 2014	
		Antigen (sputum)	No data			

Aspergillus IgG in blood

Key diagnostic test



Falling levels is good, but takes months or years



Aspergillus antibody diagnosis of CPA

Population	Intention	Intervention	SoR	QoE	Reference	Comment
Cavitary or nodular pulmonary infiltrate in non-immunocompromised patients	Diagnosis or exclusion of CPA	Aspergillus IgG antibody	A	II	Guitard, 2012; Baxter, 2012; Van Toorenbergen, 2012	IgG and precipitins test standardisation incomplete
		Aspergillus precipitins	A	II	BTS, 1970; Uffredi, 2003; Kitasato, 2009; Ohba, 2012; Baxter, 2012	Most in house tests poorly validated, with uncertain sensitivity the major problem.
		Aspergillus IgM antibody	D	III	Brouwer, 1988;	Sensitivity for Aspergillus nodule uncertain
		Aspergillus IgA antibody	D	III	Schonheyder 1987; Nimomiya, 1990;	
In context of asthma/ABPA/CF		Aspergillus IgE antibody	B	II	Denning, 2003; Agarwal, 2012	

Radiological diagnosis and follow up of CPA

QUEST CHILDREN'S HOSPITAL

Population	Intention	Intervention	SoR	QoE	Reference	Comment
Features of cavitation, fungal ball, pleural thickening and/or upper lobe fibrosis	Raise suspicion of CPA for physicians	Radiological report must mention possible CPA	A	II	Roberts, 1987; Kim, 2000; Franquet, 2001; Denning, 2003; Greene, 2005; Kobashi, 2006; Godet, 2014	CPA is often missed for years and patients mismanaged. Microbiological testing required for confirmation
Suspicion of chronic pulmonary aspergillosis on CXR	Diagnosis or exclusion of CPA	CT scan (contrast)	A	II	Greene, 2005	High quality CT with vessel visualisation
		PET scan	D	III		
Follow up on or off therapy		CT (low dose) or CXR	B	III	Baxter, 2011; Kim, 2013	Expert radiology advice.
		Initial FU at 3 to 6 mos and with change of status	B	III	Greene, 2005; Cadranel, 2012	General need to minimise radiation exposure, especially multiple CT
			A	II	Felton, 2009; Cadranel.	

