

# Morphological variations in the placental shapes, site of attachment of umbilical cord in assisted reproduction

Ananthi V<sup>1\*</sup>, Rajkumar D<sup>2</sup>, Muniappan V<sup>3</sup>

<sup>1</sup>Tutor, <sup>2</sup>Dean, <sup>3</sup>Professor and HOD, Department of Anatomy, Rajah Muthiah Medical College, Annamalai University, Chidambaram.

Email: [ananthisricharan@gmail.com](mailto:ananthisricharan@gmail.com)

## Abstract

**Background:** Placenta is a fetomaternal organ, acts as a mirror and reflects the fetal growth in utero. Umbilical cord is a connecting link between fetus and placenta. Our present study aimed to find the mode of insertion of umbilical cord and various placental shapes in natural conception and in assisted reproduction. **Materials and Methods:** 30 Placentas of natural conception and 30 placentas with 42 umbilical cords (12 cases of Twins, 18 cases of singleton) of assisted reproduction were collected from obstetrics and Gynaecology department, Rajah Muthiah Medical College and Hospital and from Private Fertility centre in and around Chidambaram. Human ethical committee clearance was obtained before sample collection. Shape of placenta and mode of insertion of umbilical cord were examined and noted. Umbilical cord diameter was measured using measuring tape and compass. **Results and Discussion:** Diameter of umbilical cord was 1.2 cm in natural conception, 0.89 cm in assisted reproduction. Irregular shape of placenta was increased in assisted reproduction and velamentous cord insertion was also increased in assisted reproduction. These results would be useful in Neonatologists who handle newborns of assisted reproductive mothers.

**Key Words:** Velamentous insertion, Diameter, Shape of placenta, Eccentric insertion

## \*Address for Correspondence:

Dr. Ananthi V, Tutor, Department of Anatomy, Rajah Muthiah Medical College, Chidambaram. Pin code 608002.

Email: [ananthisricharan@gmail.com](mailto:ananthisricharan@gmail.com)

Received Date: 05/06/2019 Revised Date: 18/07/2019 Accepted Date: 24/08/2019

DOI:

## Access this article online

Quick Response Code:



Website:

[www.medpulse.in](http://www.medpulse.in)

Accessed Date:  
04 December 2019

## INTRODUCTION

The placenta is a vital organ, which reflects the internal status of fetus in utero. It has two components fetal portion which is formed by villous chorion, maternal portion formed by decidua basalis, the part of uterine endometrium.<sup>1</sup> Umbilical cord is the connecting cable and link between the fetus and placenta. The embryo remains attached to the trophoblast by extra embryonic mesoderm in into which the coelom does not extend. This extra

embryonic mesoderm forms the connecting stalk. As a result of embryonic end of connecting stalk comes to lie on the ventral surface of embryo. It is attached in the region of umbilical opening.<sup>2</sup> The umbilical cord consists of an outer covering of flattened amniotic epithelium, containing Wharton's jelly (an interior mass of mesoderm) with two umbilical arteries and one umbilical vein. Initially there are two arteries and two veins. Later right vein disappears. The umbilical cord normally insert to the central portion of placenta, well away from placental edge<sup>3,4</sup>, it's considered as central insertion of cord. If the umbilical cord is inserted within 2 cm from the placental edge, it is considered as marginal insertion.<sup>5,6</sup> Grossly visible branching of the umbilical vessels before their insertion onto the placental surface is known as furcated placenta. Human placenta is defined as discoidal organ (in contrast to the other shapes eg. zonary, bidiscodal, diffuse etc). After delivery of the fetus, the placenta becomes separated from the uterine wall and together with so called 'membranes' is expelled as "after birth"<sup>7</sup>. Placenta shape, size and insertion of cord vary

widely between pregnancies. The placental shape is usually round or oval. However it may be irregular, bilobate or multilobate. Irregular placental shape has been associated with low birth weight, altered feto placental ratio, as it may show the altered placental function in utero<sup>8</sup>. Placenta utilizes the 1/3 of oxygen and glucose that are supplied to maternal blood, protein synthesis rate was higher in placenta when compared to liver<sup>9</sup>. The probability of identifying congenital anomalies will be higher with meticulous umbilical cord examination in the earlier period of gestation<sup>10</sup>.

**Assisted Reproduction:**

Assisted Reproduction is a technique where gametes are manipulated artificially, fertilized embryo can be reinserted into mother’s uterus. Assisted Reproductive Technique (ART) is an invaluable gift to infertile couple those who are exhausted by taking various treatments and failed it. There are some fall outs in ART because of artificial manipulation of gametes. Intracytoplasmic sperm injection [ICSI] is a technique where the deposition of single spermatozoon directly into cytoplasm of oocyte, thus bypassing the zona pellucida and oolemma. Our present study aimed to analyze the variations in the placental shape, mode of insertion of umbilical cord, diameter of umbilical cord in assisted reproduction and its clinical significance in Indian population.

**MATERIALS AND METHODS**

30 placentas of natural conception and 30 placentas with 42 umbilical cords (out of 30, 12 cases are dichioinic diamniotic twins and 18 cases are singleton ) of assisted reproduction were collected from OG Department, Rajah Muthiah Medical College and Hospital and from private fertility centre in and around Chidambaram. Human ethical committee clearance was obtained before sample collection. Placentas were washed in running tap water to remove the blood clots. Completeness of membranes was examined, shape of placenta was observed and diameter of umbilical cord was measured using measuring tape and compass. Mode of insertion of umbilical cord was observed on fetal surface of placenta.

**RESULTS**

Changes in the development and site of insertion of umbilical cord can cause problems which have the potential to affect the maternal and fetal growth and development [11-13]. Diameter of cord, various placental shapes and mode of insertion of umbilical cord of natural conception and assisted reproduction were noted and tabulated. Furcated placenta was noted in 2 cases of assisted reproduction (fig 1).



Figure 1: Furcated placenta      Figure 2: Velamentous insertion of umbilical cor

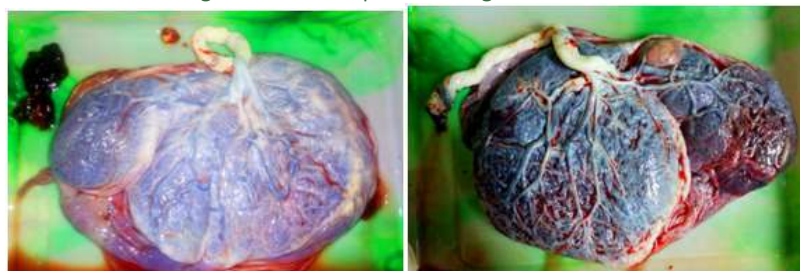


Figure 3: placenta with accessory lobe      Figure 4: Succenturiate placenta with cyst

Statistical analysis was performed for analyzing the diameter of umbilical cord using SPSS. The data obtained from the study were compiled and expressed as mean ± standard deviation. Mann-Whitney test was performed. Two tailed ‘t’ test were done. Z value and P values are also tabulated. P value of < 0.05 was taken as significant.

**Table 1:** Various shapes of placenta in natural conception and in assisted reproduction

S.No	Different Shapes	Normal		ICSI	
		Total no. of Cases 30		Total no. of Cases 42	
		No. of cases	%	No. of cases	%
1.	Round	21	70	26	61.9
2	Oval	7	23.3	10	23.81
3	Irregular	3	6.66	6	14.28

**Table 2:** Mode of insertion of umbilical cord in natural conception and assisted reproduction

S.No	Mode of insertion	Normal		ICSI	
		Total no. of Cases 30		Total no. of Cases 42	
		No. of cases	%	No. of cases	%
1.	Central	17	56.66	24	57.14
2	Eccentric	12	40	7	16.66
3	Marginal	1	3.33	7	16.66
4	Velamentous	0	-	4	9.52

## DISCUSSION

The deoxygenated fetal blood leaves the fetus through two umbilical arteries that pass through the umbilical cord. When they reach the fetal surface of the placenta, the vessel divides into branches and enters the chorionic villi. The oxygenated blood returns to the fetus through venules and veins in the chorionic villi that form the umbilical vein. "Trophoblast invasion" is a process in which the chorionic frondosum or early placenta moves with advancing gestation to get a better supply from the vascularised area.<sup>14</sup> The conceptus once reaches the blastocyst stage, it is able to implant. Once it forms as a blastocyst, it becomes asymmetrical and internal cells form a compact inner cell mass that remains in contact only with the part of the outer polar region. ART procedures may interfere in some ways with polar trophoblast differentiation. In Donald N. Disalvo *et al*<sup>15</sup>, sonographic studies of 46 pregnancies, he found the central insertion of cord in 70.37% cases, marginal mode of insertion in 22.22% cases, velamentous mode of insertion in 7.41% cases. In Sepulveda *et al*<sup>16</sup> study, they found central mode of insertion of cord in 93.8% cases, marginal mode of insertion in 5.21% cases and velamentous insertion in 0.96% cases using colour doppler ultrasound study. According to Manikanda Reddy *et al*<sup>17</sup>, 75.45% of cases were central mode of insertion, 16.36% of cases were marginal insertion of cord, 7.27% of cases were furcated placentas and 0.9% of cases were velamentous type of insertion. In Gavrill *et al*<sup>18</sup> study, abnormal shape of placenta significantly increased in assisted reproduction when compared to the control group. There was a significant difference in the insertion of cord in ART when compared to natural conception. In our present study, central mode of insertion of cord was found in 56.66% cases, eccentric mode of insertion of cord was found in 40% cases and marginal mode of insertion of cord was found in 3.33% cases in natural conception (table 2). In ART pregnancies,

central mode of insertion was found in 57.14% cases, eccentric mode of insertion of cord was found in 16.66% cases, marginal mode of insertion of cord was found in 16.66% cases and velamentous mode of insertion of cord was found in 9.52% cases (fig 2, table 2). Velamentous insertion of cord was significantly increased in assisted reproduction. Our present study results were in concordance with the Gavrill *et al* study. This velamentous insertion is associated with low birth weight, growth retardation, low APGAR score, abnormal fetal heart patterns and congenital anomalies like oesophageal atresia, obstructive uropathies, congenital hip dislocation, asymmetrical head shape, spina bifida, VSD, single umbilical artery, bilobed placenta.<sup>19,20</sup> In Ragnath *et al*<sup>21</sup> study, placenta in most of cases was round in 93.7% cases, oval in 7% cases. But accessory lobe was not found. In present study, shape of the placenta was round in 70% cases, oval in 23.37% cases and irregular in 14.28% cases of natural conception. There was a significant increase in irregular shape of placenta in assisted reproduction (table 1). Accessory lobe was found in 13.33% (4/30) cases of assisted reproduction (fig 3). There was a cyst on the fetal surface of placenta in 6.66% (2/30) cases (fig 4). Abnormal shape has been associated with increased intrauterine fetal death, extreme preterm delivery and fetal growth restriction.<sup>22</sup> In Annapurna *et al*<sup>23</sup> study, mid thickness of umbilical cord was 2.1 to 3.5 cm in majority of cases. According to Kouvalainen *et al*<sup>24</sup>, average diameter of umbilical cord was 1.5 cm. In present study, mid thickness of cord was 1.2 cm in natural conception, 0.89 cm in assisted reproduction. Our present study results were in concordance with previous study. There was a significant reduction in diameter of umbilical cord in assisted reproduction. So, compression of vessels within the cord may occur, which may cause fetal growth retardation, small for gestation age. Overall, there was a significant reduction in diameter of cord in ART.

Irregular shape of placenta was increased in ART and also velamentous cord insertion was increased in ART. These changes may affect the fetal growth and development indirectly. These data would be useful for neonatologists who handle newborn of ART mothers.

## CONCLUSION

We conclude that there was significant changes in the placental shapes, mode of insertion of umbilical cord in assisted reproduction when compared to natural conception. These results would affect the fetal growth and development indirectly. These results will be useful for obstetricians and gynecologists who handle the infertile cases.

## REFERENCES

1. Yetter JF. Examination of the placenta. *Am Fam Physician*. 1998; 57(5):1045-54.
2. Moore KL., Persuad TVN. Placenta and Fetal Membranes. In: Moore and Persaud, editor. *The Developing Human Clinically oriented embryology*, 7<sup>th</sup> Edition. 2003; Saunders, Philadelphia. 119-131.
3. Robinson LK., Jones KL., Benirschke K. The nature of structural defects associated with velamentous and marginal insertion of the umbilical cord. *Am J Obstet Gynecol* 1983; 146:191-193.
4. Lennan Mc. Implications of the eccentricity of the human umbilical cord. *American Journal of Obstetrics and Gynecology*. 1968;101(8):1124-30
5. Pretorius DH., Chau C., Poeltler DM., Mendoza A., Catanzarite VA., Hollenbach KA. Placental cord insertion visualization with prenatal ultrasonography. *JUM*. 1996; 15(8):585-596.
6. Liu CC., Pretorius DH., Scioscia AL., Hull AD. Sonographic Prenatal Diagnosis of Marginal Placental Cord Insertion. *JUM*. 2002; 21(6):627-632.
7. Moore KL., Persuad TVN. Female reproductive system. In: Susan standing, editor. *Gray's anatomy*, 39<sup>th</sup> Edition. Churchill Livingstone, New York. 2004; 1339-48.
8. Salafia CM., Yampolsky M., Misra DP., Shlakhter O., Haas D., Eucker B., Thorp J. Placental surface shape, function, and effects of maternal and fetal vascular pathology. *Placenta*. 2010; 31(11):958-962.
9. Kaplan CG. *Postpartum Examination of the Placenta. Clinical obstetrics and gynaecology*. 1996; 39(3):535-48.
10. Arun Kinare. Fetal environment. *Indian J Radiol Imaging*. 2008; 18(4): 326-344.
11. Collins JH. Umbilical cord accidents: human studies. *Semin Perinatol*. 2002; 26(1): 79-82.
12. Cunningham FG., Leveno KJ., Bloom SL. *Williams obstetrics*. 22nd ed. New York. McGraw Hill: 2005: 68-9, 626-9.
13. Vance ME. The Placenta. In: Fraser DM, Cooper MA eds. *Myles Textbook for Midwives*. 15ed. 2009; Edinburgh: Churchill Livingstone: 152.
14. Monie IW. Velamentous insertion of the cord in early pregnancy. *Am J Obstet Gynecol* 1965; 93:276-281.
15. Donald N., Di Salvo, Carol B. Benson, Faye C. Laing. Sonographic evaluation of the placental cord insertion site. *American journal of Radiology*. 1998; 170:1295-1298.
16. Sepulveda W., Rojas I., Robert JA. Placental detection of velamentous insertion of the umbilical cord: a prospective colour Doppler ultrasound study. *Ultrasound Obstet Gynecol*. 2003; 21:564-569.
17. Manikanta Reddy V., Geetha P., Nim VK. Variations in Placental Attachment of Umbilical Cord. *Journal of Anatomical Society of India*. 2012; 61(1):1-4.
18. Gavril P., Jauniaux E., Leroy F. Pathologic Examination of Placentas from Singleton and Twin Pregnancies Obtained After in Vitro Fertilization and Embryo Transfer. *Pediatric Pathology*. 1993; 13(4):453-462.
19. Benirschke K., Kauffman P. Anatomy and pathology of the umbilical cord and major fetal vessels. In: Benirschke K, Kauffman P, eds. *Pathology of the human placenta*. 5th ed. New York: Springer-Verlag. 2006; 249 -276.
20. Raithatha N., Patel M., Patel R., Chauhan N. Velamentous insertion of umbilical cord in twin pregnancy. *NJIRM*. 2011; 2:121-123.
21. Ragunath G., Vijayalakshmi SV. A study on morphology and the morphometry of the human placenta and its clinical relevance in a population in Tamilnadu. *J Clin Diagn Res*. 2011; 5(2):282-286.
22. Costa SL., Proctor L., Dodd JM., Toal M., Okun N., Johnson JA., Windrum R., Kingdom JCP. Screening for placental insufficiency in high risk pregnancies: is earlier better? *Placenta* 2008; 29(12):1034-40.
23. Bose A., Pandit VK. Morphometric Analysis Of Human Placenta And Umbilical Cord In Hundred Patients From Malwa Region Of Central India. *Indian Journal of Research*. 2018; 7(3):37-38.
24. Kouvalainen K., Pynnonen AL., Makarainen M., Peltonen T. Weights of placental membranes and umbilical cord. *Duodecim*. 1971; 87:1210-1214.

Source of Support: None Declared  
Conflict of Interest: None Declared