

## A Mixed Bag of Oral Lesions in Tots & Teens: Diagnostic Tips & Treatment Options, #1



April 2018

Catherine M. Flaitz, DDS, MS  
 Professor, Division of Pediatric Dentistry  
 The Ohio State University  
 College of Dentistry  
 Associate Chief of Dentistry  
 Nationwide Children's Hospital

## Course Objectives

Improve the practitioners' ability to:

- Diagnose a variety of common oral lesions
- Determine the best questions to ask when taking a history
- Discover useful new entities and new findings about well-known disorders
- Select the best management approaches for the child-patient.

## Oral Lesions in Children

- Congenital disease; syndromes
- Tooth eruption
- Vague history
- Family and pets matter
- Traumatic component
- Orthodontic appliances
- Growth spurts
- Infections are common
- Reactive lesions
- Delayed diagnosis of serious disease



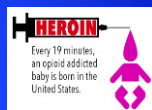## U.S. Mortality Drops for Infants

- Mortality rates declined by 15% (2005 – 2014)
- 6.86 deaths/100,000 live births in 2005
- 5.82 deaths/100,000 live births in 2014
- Greatest declines in babies born to Pacific Islanders and black women
- Deaths declined for congenital defects, SIDS (29%), prematurity, maternal complications
- Rates for fatal accidental injuries rose 11%
- Reference: CDC NCHS, 3-2017



## Increase in Congenital Diseases

- Opioid addiction
- Old diseases:
  - Congenital syphilis
  - Increased by 46% (2012-2015)
  - 11.6 cases/100,000 live births in 2014
- New diseases:
  - Congenital Zika



## Zika Virus Infection



- Zika virus (ZIKV): RNA virus of *Flaviviridae* family
- Transmit: *Aedes* species mosquito; in utero, sexual, including oral sex, blood transfusion, transplant
- 1 in 5 infected will become symptomatic
- Incubation: 3-12 days; duration: 2-7 days
- S/S: fever, rash, arthralgia, myalgia conjunctivitis, headache, oral ulcers, pharyngitis, palatal petechiae
- DX: Travel history; serum, urine ZIKV rRT-PCR and serum IgM ab
- TX: Supportive, analgesics (acetaminophen)

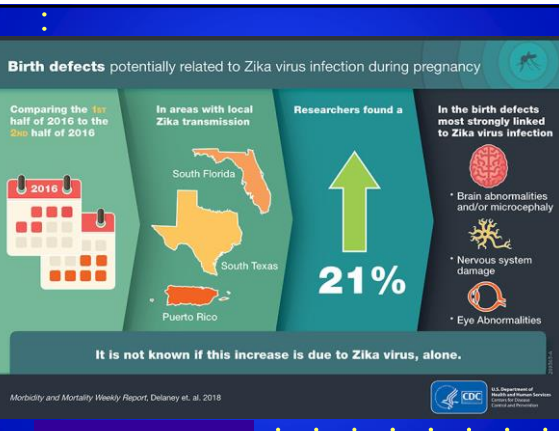
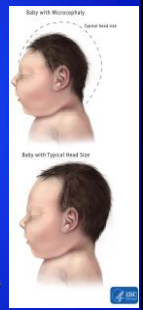## Zika Stats 3/2018

- US cases: 5,673
  - US Territories (PR): 37,177
  - Completed pregnancies, US: 2,233
    - Live birth defects: 112
    - Fetal losses with defects: 9
  - Completed pregnancies, Territories: 4,055
    - Live birth defects: 157
    - Fetal losses with defects: 8
- www.cdc.gov/zika

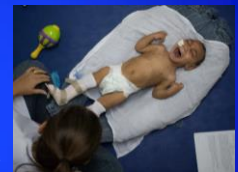

## Complications

- Guillain-Barre syndrome: autoimmune disorder with limb weakness, paresthesia, facial weakness, dysphagia
- Congenital infection: microcephaly, vision, hearing loss, seizures, neurologic abnormalities, feeding difficulties, dysphasia, contractures, muscle hypertonicity, hypothyroid, pituitary disorders
- Fetal Risk: 6%; First trimester: 15% (Similar to French territories)



## Congenital Zika Syndrome



AP: Associated Press, Oct 2016

- ✓ Prevention: Avoid travel to high risk areas
- ✓ Infected male partner: Use condoms or avoid sex during pregnancy or for 6 months, if not pregnant

## Oral Lesions in Schoolchildren

- |                                  |                                    |
|----------------------------------|------------------------------------|
| • Aphthous ulcers                | • Fordyce granules                 |
| • Erythema migrans               | • Melanotic macule                 |
| • Herpes labialis                | • Mucocele                         |
| • Fissured tongue                | • Tumors, NOS                      |
| • Cheek-biting/linea alba        | • Hemangioma/vascular malformation |
| • Traumatic ulcer                | • Papilloma, verruca vulgaris      |
| • Purpura                        | • Overall Prevalence: 27.5%        |
| • Candidiasis, angular cheilitis |                                    |
| • Commissural lip pits           |                                    |
| • Gingival hyperplasia           |                                    |
- 
- Fehmida, Flaitz, et al. AAPD abstract, 2014

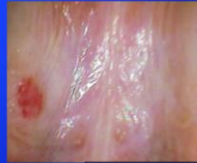
## Symptomatic Oral Lesions

- Red mucosal lesions
  - Red or Blue Blanching Lesions
  - Red or Blue Non-blanching Lesions
- Ulcerative lesions
  - Ulcers of Sudden Onset & Short Duration
  - Ulcers of Variable Onset & Long Duration
- White or yellowish mucosal lesions
  - White Surface Thickening
  - White Surface Material



## Red Lesions in Children

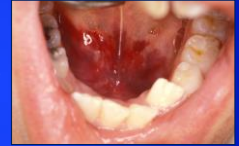- Red or Blue Blanching Lesions
  - Hemangioma or vascular malformation
- Red or Blue Non-blanching Lesions



Infantile capillary hemangioma  
Photo: Dr. Ian Kott

## Red-Blue Non-Blanching Lesions

- Flat or elevated lesion
- Pooling of blood or increased vascularity
- Smooth or granular surface
- Bleeding with manipulation
- No tissue blanching
- May be mildly symptomatic
- History of trauma or irritation
- Systemic disease when widespread

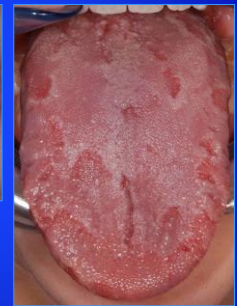
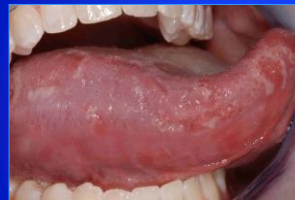
Dx: Ecchymosis  
Beware: Condylar fracture

## Benign Migratory Glossitis

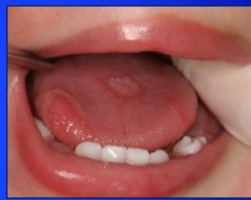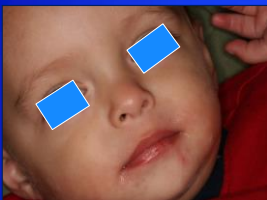- Geographic tongue, erythema migrans
- Cause: Unknown; genetic, allergy
- Prevalence: Up to 3%; all ages; ↑ in children
- Site: Tongue, esp. dorsum; extraglossal
- Duration: Persistent; waxes and wanes
- S/S: Multiple, red annular patches with white scalloped border; loss of filiform papillae; +/- burning sensation; +/- fissured tongue
- Concerns: Food restrictions; cosmetic concern

## Benign Migratory Glossitis



- Concurrent lesions:
- ✓ Fissured tongue
  - ✓ Crenations on lateral borders
  - ✓ Lingual papillitis

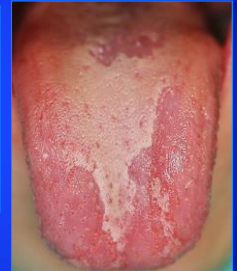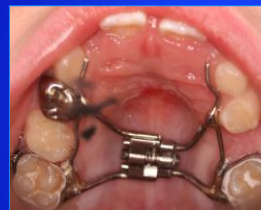## Benign Migratory Glossitis



- ✓ Early onset may be marker for psoriasis & disease severity
- ✓ BMG tends to be nontender when associated with psoriasis

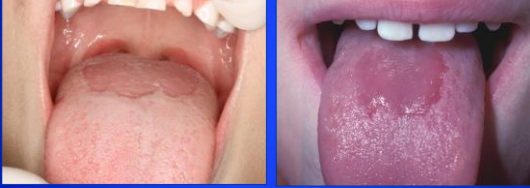Piccinal B et al: International Journal of Dermatology 2017

## Geographic Tongue



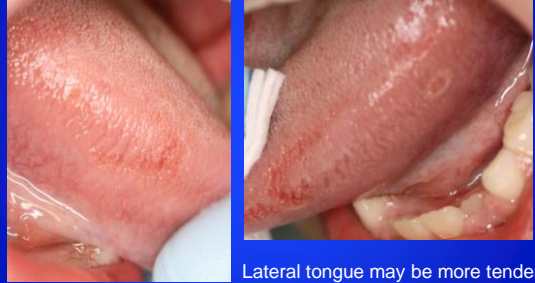Appliances do not cause the lesion but may exacerbate the symptoms

## Mimics Median Rhomboid Glossitis



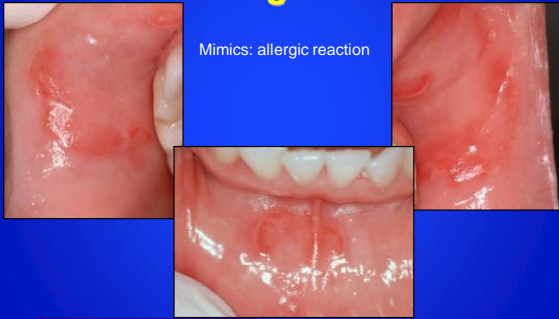
Key feature: Annular patches move around

## Subtle Signs of BMG



Lateral tongue may be more tender

## Extraglossal Erythema Migrans



Mimics: allergic reaction

## Questions to Ask?

- Does it come and go and change patterns?
- Is it usually on the tongue?
- Does the child have allergies, eczema, asthma, or other skin problems?
- Does it interfere with eating? Weight loss? Growth rate?
- Meds, OTC and oral hygiene products?
- Other family members affected?
- Is it associated with a fever?

## Benign Migratory Glossitis

ID factor; use gentle oral hygiene products

Topical coating agents, anesthetics:

- Benadryl & Maalox suspension
- OTC gels, rinses

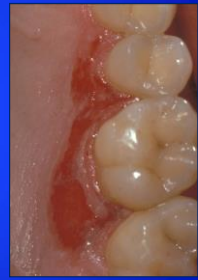Topical steroids +/- antifungals:

- Fluocinonide gel .05%
- Other topical steroids
- Nystatin/triamcinolone ointment
- Triamcinolone 0.1% in Nystatin oral rinse



## What Else Is In The Bag?

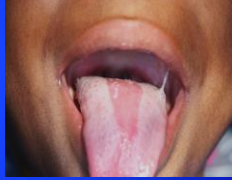- Benign migratory glossitis
- Contact allergy
- Candidiasis
- Traumatic erosion
- Transient lingual papillitis
- Lichen planus
- Erythroplakia



Pizza burn erosion

## Median Rhomboid Glossitis

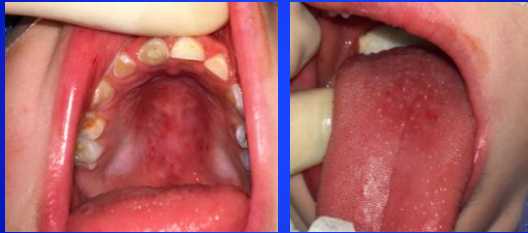- Form of candidiasis
- AKA: Central papillary atrophy
- Site: Midline, posterior dorsal tongue
- S/S: Red rhomboid patch, nontender
- Kissing lesion on palate
- Tx: Antifungal agents



## Oral Candidiasis

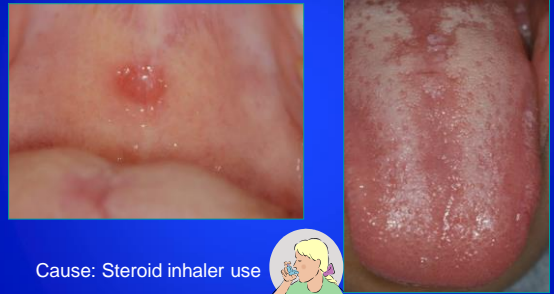- Cause: *Candida species*, *Candida albicans*
- Prevalence: 40 – 60% normal oral inhabitant
- Predisposing factors: ↓ immune status, medications, poor oral hygiene, appliances, pacifiers, poor diet, diabetes, dry mouth
- Site: Usually multifocal oral involvement
- Variants: Pseudomembranous, erythematous, hyperplastic types
- S/S: Red or white patches, erosions, burning sensation, taste perversion, sore throat

## Erythematous Candidiasis



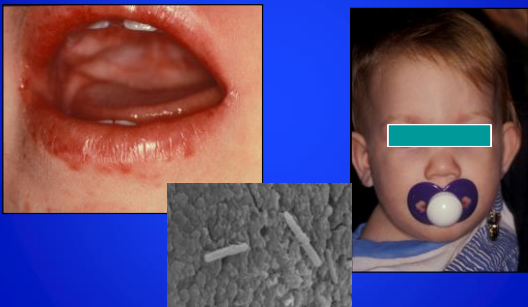- ✓ Dental caries are a reservoir for fungus
- ✓ Gingivitis, glossitis, palatal erythema, chapped lips
- ✓ Mimics: allergic reaction, viral infection

## Erythematous Candidiasis

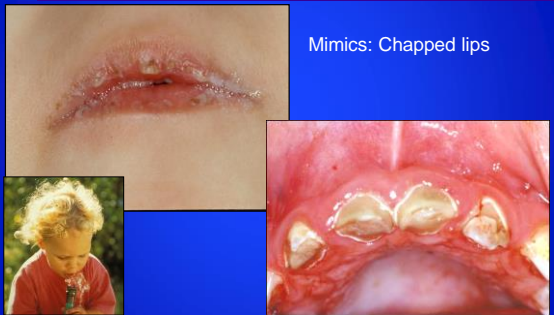

Cause: Steroid inhaler use

## Erythematous Candidiasis

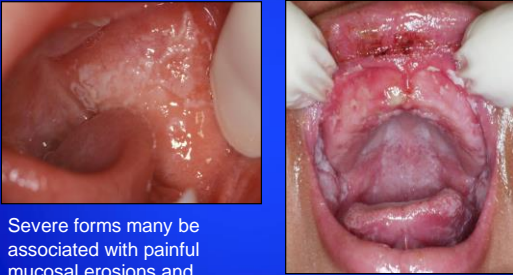

## Cheilocandidiasis



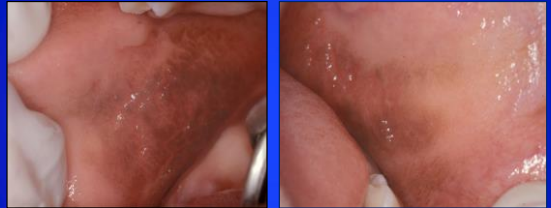
Mimics: Chapped lips

## Pseudomembranous Candidiasis



Severe forms may be associated with painful mucosal erosions and dysphagia

## Pigmented Candidiasis



✓ May trigger an inflammatory melanosis in children with increase in skin pigmentation

## Oropharyngeal Candidiasis

### Topical Agents:

- Nystatin suspension 100,000 U/mL
- Clotrimazole troches 10 mg
- Oravig (miconazole) buccal tabs 50 mg
- Chlorhexidine gluconate oral rinse 0.12%



### Systemic Agents:

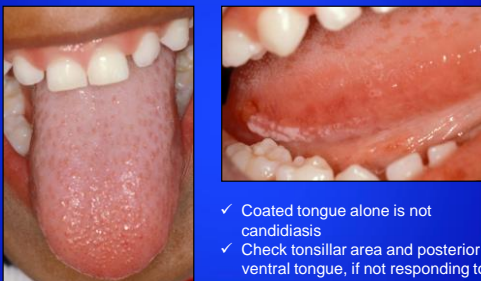
- Diflucan, g (fluconazole) 100 mg tabs, 10 mg/mL, 40 mg/mL susp
- Sporanox (itraconazole) 100mg/10mL

## Miconazole (Oravig): Topical

- Form: Adherent, slowly dissolving 50 mg tablet
- Usual dosage:
- Adolescents >16 yrs: 1 tablet for 14 days. Apply to the upper gum region, just above the upper lateral incisor. Alternate sides of the mouth.



## Pseudomembranous Candidiasis



- ✓ Coated tongue alone is not candidiasis
- ✓ Check tonsillar area and posterior ventral tongue, if not responding to topical treatment

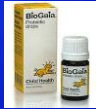## Probiotics and Oral Health

- Probiotics: Living microorganisms (primarily bacteria) that are safe for consumption and when ingested in sufficient quantities have beneficial effects on human health beyond basic nutrition



## Probiotics: Mechanism of Action

- Secrete antimicrobial substances (organic acids, hydrogen peroxide, bacteriocins)
- Compete with pathogenic organisms for adhesion sites on mucosa
- Modify environment by modulating pH & O<sub>2</sub>-reduction potential
- Stimulates nonspecific humoral immunity
- Modulates humoral & cellular immune response
- Combination of strains beneficial effects



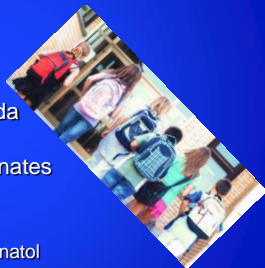## Probiotics



- Purpose: To help prevent diarrhea from antibiotics
- Examples: Culturelle (lactobacillus GG), Dan Active (lactobacillus, strep thermophilus), others
- Duration: Take probiotics during antibiotic treatment and up to a week afterwards
- Sig: Take 2 hours after each antibiotic dose to improve probiotic survival

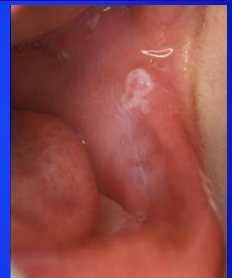## New Evidence in the Bag

- Probiotic species:
  - Lactobacillus* spp.
  - Bifidobacterium* spp.
  - Saccharomyces* spp.
- Preventive effect: Candida colonization
- Population: Preterm neonates and elderly
- Systematic reviews:
  - Hu H-J, et al: *Pediatr Neonatol* 2017
  - Ai R, et al: *Arch Oral Biol* 2017



## Breastfeeding Keratosis

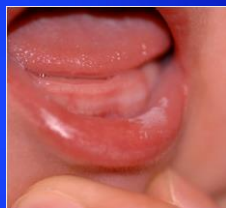- Frictional keratosis
- Cause: Forceful sucking
- Site: Labial mucosa, anterior buccal mucosa
- S/S: White adherent plaques, nontender; +/- leukoedema, sucking calluses
- Tx: Modify sucking habits
- Mimics: Candidiasis



Kiat-amnuay S, et al, 2013

## What Does It Mimic?

- Pseudomembranous candidiasis
- Mucosal sloughing
- Mucosal burn
- Plaque/materia alba
- Koplik spots
- Sucking keratosis in infants

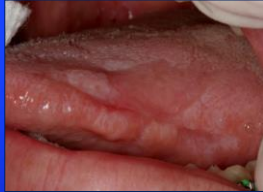
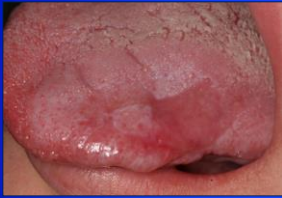
HX: Infant had 3 rounds of Nystatin with no resolution

## Oral Erythroplakia

- Definition: Red patch that cannot be defined clinically or pathologically as another condition
- Prevalence: Rare in children
- Risk factor: Same as oral cancer
- Site: Oral floor, tongue, soft palate complex
- S&S: Soft, velvety red patch +/- white foci
- TX: Excision and long-term follow-up
- 90% represent severe dysplasia or worse

## Erythroplakia



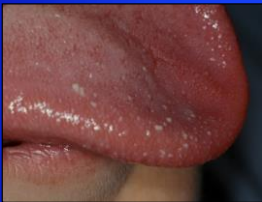### Mimics:

- ✓ Geographic tongue
- ✓ Traumatic erosion
- ✓ Contact allergy

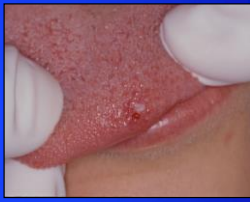## Transient Lingual Papillitis

- Lesion: Inflamed fungiform papillae
- Cause: Unknown, trauma, allergy/sensitivity, GERD, hormonal, URI, viral infection,
- Gender/Age: F>M; Wide age range
- Site: Dorsal tongue; Anterior, lateral
- Duration: 1 to 7 days
- 3 types: Single, diffuse or clustered
- S/S: Painful, red or white papules +/- fever, lymphadenopathy, may recur
- TX: Topical steroids, anesthetics, coating agents

## Transient Lingual Papillitis



Diffuse pattern



Small clustered pattern

## Allergic Contact Mucositis

- Cause: Hypersensitivity reaction to variety of products
- Prevalence: Unknown, less common than skin
- Risk factor: Atopic individuals, ↓ salivary flow
- Site: Buccal, labial mucosa, gingiva, tongue
- Types: Acute and chronic forms
- DX: Temporal relationship; allergy testing
- Variants: Plasma cell gingivitis, foreign body gingivitis, angioedema, perioral dermatitis, exfoliative cheilitis

## Allergic Contact Mucositis

### Signs/Symptoms of Acute Disease:

- Burning sensation, diffuse swelling, erythema, vesicles, bullae, ulcers, lingual papillitis

### Signs/Symptoms of Chronic Disease:

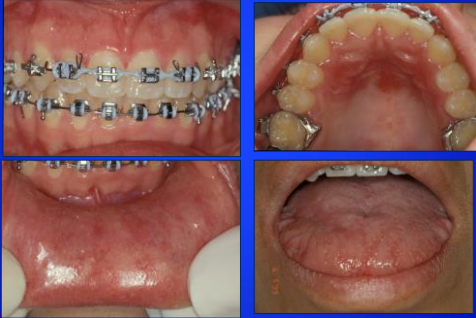- Burning sensation, erythema, white plaques, gingival swelling, angular cheilitis, chapped lips, perioral dermatitis, unpleasant or metallic taste

## Nickel Hypersensitivity in US

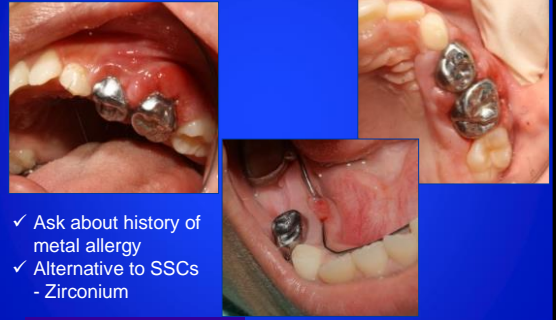- 2008 Allergen of the Year by ACDS
- Prevalence:
  - 18% of the US population
  - 11 million children
  - #1 cause of + patch tests (33% kids tested)
- Nondental sources: Body piercing, jewelry, buckles, keys, pens, paper clips, toys, zippers, snaps, cell phones, electronics, eye frames
- Dental sources: SSC, orthodontic band and attachments, lingual arch wires



## Nickel Allergy



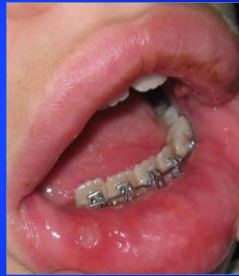## Nickel Allergy



- ✓ Ask about history of metal allergy
- ✓ Alternative to SSCs - Zirconium

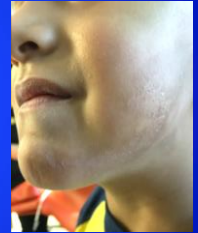## Foods & High Nickel Content

- Soy products
- Licorice
- Buckwheat
- Cocoa powder
- Clams
- Cashews
- Figs
- Canned foods
- [www.aad.org/public/diseases/rashes/nickel-allergy](http://www.aad.org/public/diseases/rashes/nickel-allergy)



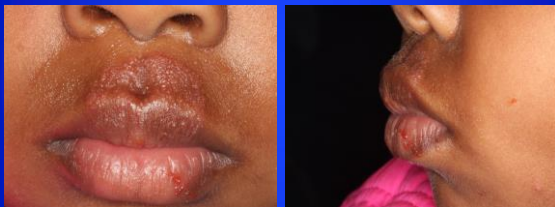## Irritant Contact Dermatitis

- Etchant gel: 37-38% phosphoric acid
- S/S: Sudden burning, itching, swelling, vesicles, color changes
- Tx: Emollients, +/- topical steroids, topical antibiotics
- Complications: Scarring, pigmentation changes
- +/- contact allergy



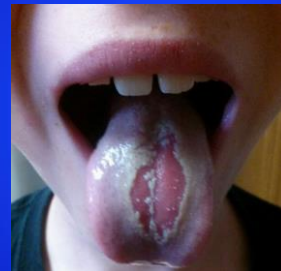Ale I, et al. Expert Rev Clin Immunol 2010

**HX: 13 YO female who had multiple sealants placed under rubber dam**



Suspected cause: Super Etch gel, 37% phosphoric acid

**CC: This is a healthy child with a sore tongue of several days' duration. Dad and son were having a bonding moment.**



Irritant Contact Glossitis



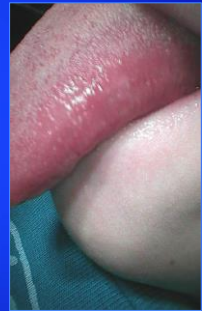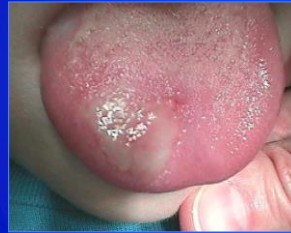## Oral Fixed Drug Eruption



- FDE is a recurrent site-specific lesions of the skin and/or mucosa when a drug is taken
- Age: Wide age range, including <10y
- Oral lesions occur alone (14%) or with genital, ocular, nasal or skin lesions
- Site: Tongue, palate, labial mucosa
- S/S: Ulcers, erythema, bullae +/- pigmentation
- Drugs: Naproxen, co-trimoxazole, fluconazole, tetracyclines, ibuprofen, clarithromycin
- Tx: ID and DC drug; palliative care



## Oral Fixed Drug Eruptions



3 YOM taking Bactrim for otitis media

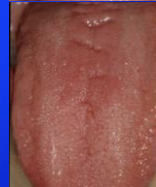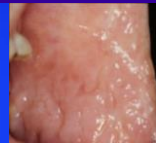## Allergic Contact Mucositis

- Identify and eliminate the cause
- Plaque control: Gentle oral hygiene products, consider chlorhexidine rinse
- Topical coating agents, if tender:
  - Benadryl & Maalox suspension
- Topical steroids, in severe cases:
  - Dexamethasone elixir 0.5mg/5mL
  - Others (see aphthous ulcers)



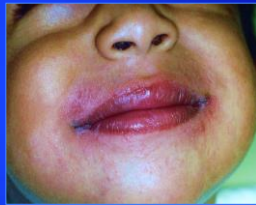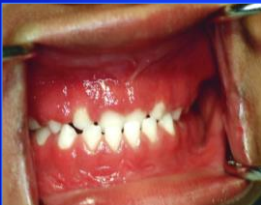## Orofacial Granulomatosis

- Granulomatous disease due to abnormal immune reaction
- Food allergens – trigger in children; may have GI problem
- Site: Lip, tongue and gingiva
- S/S: Swelling, erythema, ulcers, tissue tags, cobblestone pattern, fissured tongue
- Dx: Biopsy
- Tx: ID allergen, steroids, others



## Orofacial Granulomatosis

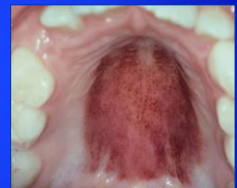Healthy 3YO with Milk Allergy



Need to rule out Crohn's disease

## Submucosal Hemorrhage

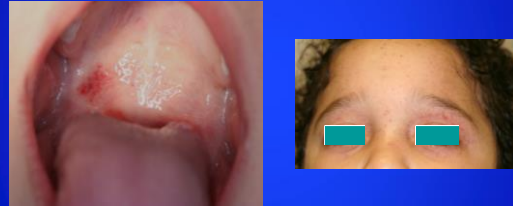
- Entrapment of blood in the tissues
- Terms: Petechiae, purpura, ecchymosis, hematoma
- Causes: Traumatic and nontraumatic
- Nontraumatic causes: Blood dyscrasias, viral infections (IM, measles), anticoagulants



## Childhood Leukemia

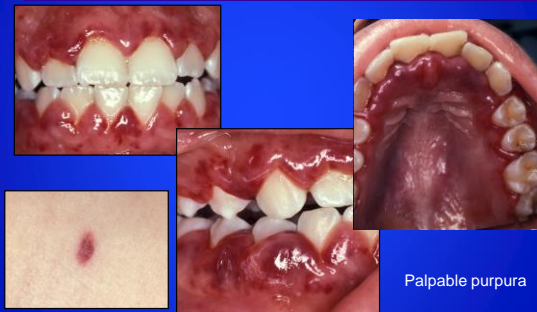- Acute lymphocytic/lymphoblastic leukemia
  - Most common form: 80% of cases
  - Petechiae, palpable purpura of skin, mucosa: 50%
  - Other S/S: NUG, cellulitis, persistent ulcers, gingival bleeding and mobile teeth
- Acute myeloid leukemia
  - Second most common form: 20% of cases
  - Diffuse gingival enlargements
  - Chloroma (granulocytic sarcoma)

## Acute Lymphocytic Leukemia



Purpura of the soft palate  
Petechial lesions of face with swelling

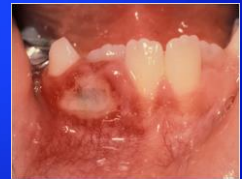## Acute Myeloid Leukemia



Palpable purpura

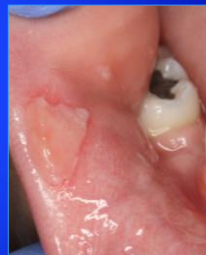## Ulcerative Lesions in Children

- Focal ulcers of sudden onset and short duration
- Multifocal ulcers of sudden onset and short duration
- Focal ulcers of variable onset and persistent duration
- Multifocal ulcers of variable onset and persistent duration



## Focal Ulcers of Sudden Onset

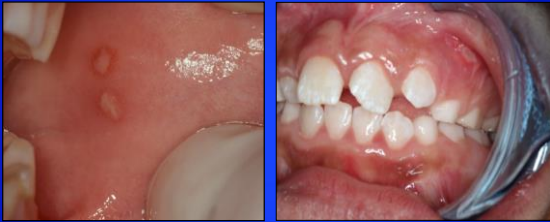- Single or localized lesions of acute onset
- Usually shallow ulcers
- Tender to painful
- Duration is usually <2 wks
- Usually recurrent pattern
- Most are site-specific
- Frequent familial history
- Very common diseases



## Aphthous Stomatitis

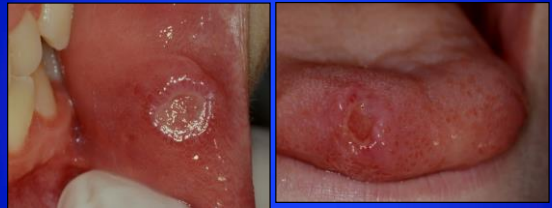- T cell-mediated immunologic reaction
- Prevalence: 20-30% of US children
- Causes: Immune defect, genetics, ↓ mucosal barrier, ↑ antigenic exposure, nutritional (↓ B1,2,6,12, folate, iron, zinc)
- Site: Nonkeratinized oral mucosa
- Duration: 2 days to 6 weeks
- Types: Minor, major, herpetiform
- S/S: Single or multiple painful ulcers; sudden onset

### Aphthous Minor: 80%



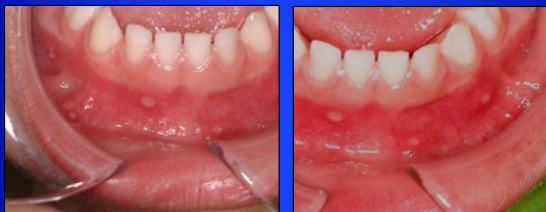Findings: 1-3 ulcers, <1 cm in size that heal in 7-10 days without scarring; variable recurrence rate

### Aphthous Major: 10%



Findings: Single to several ulcers that are deep and >1 cm, Prolonged healing > 2 weeks with scarring

### Herpetiform Aphthae: 10%



Findings: 10-100 ulcers that are 1-3 mm in size, may develop in waves  
Variable healing pattern and may scar

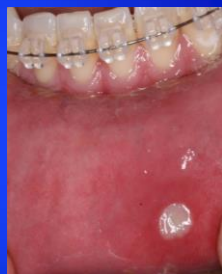### Aphthous Stomatitis

- Hematologic abnormalities in children: 20%
- Laboratory Studies:
  - White blood cell count and differential
  - Hematocrit and hemoglobin
  - Red blood cell count
  - Erythrocyte sedimentation rate
  - Serum ferritin, B12, folate
  - Antigliadin, tissue transglutaminase Ab, endomysial Ab

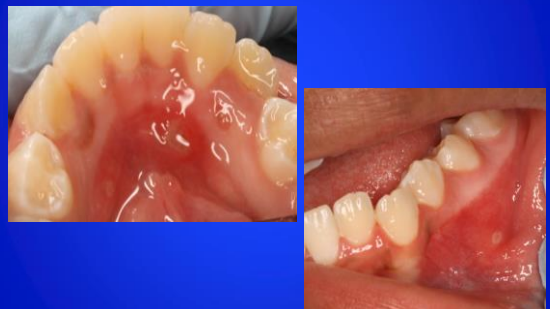

### Potential Allergens for Aphthae

- Food: Chocolate, coffee, peanuts, almonds, strawberries, cheese, tomatoes, citrus, wheat
- Other: Benzoic acid, cinnamaldehyde, sodium lauryl sulfate, menthol, peppermint, eugenol, Balsam of Peru
- Medications: NSAIDs
- Metals: Nickel, chromium



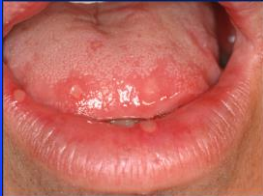### Chips & Hot Sauce as Cause



## Complex Aphthosis

### Diagnosis

- Constant presence of > 3 oral aphthae OR
- Recurrent oral and genital ulcers AND
- Exclusion of Bechet's disease

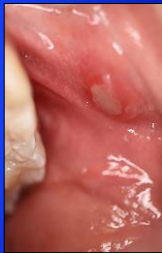

## Questions to Ask?

- Recurrence rate, duration, location, other sores on the body?
- Any known allergies? Food likes and dislikes?
- Weight loss? Growth rate?
- Meds, OTC products, oral hygiene products
- Any other family member get them?
- Any oral habits? What else put in the mouth?
- Any stomach, joint, bowel, bruising problems?
- Headaches, dizziness, fever, swollen glands?
- Bad taste? Hot burps?

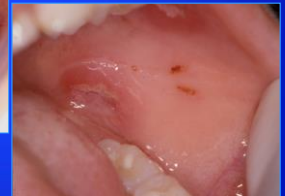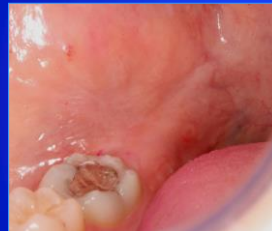## Aphthae & Systemic Disorders

- Periodic fever, aphthous, pharyngitis, adenitis
- Gastroesophageal reflux disease
- Crohn disease, ulcerative colitis
- Celiac disease
- Neutropenia, anemia
- Immunodeficiency syndromes
- Reactive arthritis
- Nutritional deficiency
- Bechet disease
- Zika virus infection



Crohn disease

## GERD: Oral Ulcers & Erosions



## Aphthous Ulcers: Topical Agents

- Peridex, generics (chlorhexidine 0.12%) mouthrinse
- Triamcinolone in dental paste 0.1%
- Betamethasone valerate ointment 0.1%
- Fluocinonide gel, ointment .05%
- Temovate (clobetasol) gel, ointment .05%
- Vibramycin (doxycycline) syrup 50 mg/5mL
- Low-level laser ?



## Aphthous Stomatitis

### Topical or systemic agents:

- Dexamethasone elixir, solution 0.5mg/5mL
- Celestone (betamethasone) syrup 0.6mg/5mL

### Systemic agents:

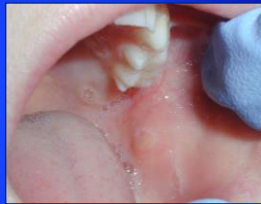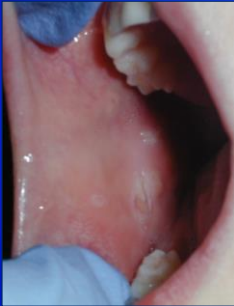
- Prednisone 20 mg tabs (20-60mg/day) X 5 days
- Cimetidine 300 mg tabs, solution

### Nutritional supplement:

- Vitamin B12 1000 mg (SL, PO)
- Peridin-C (citrus bioflavonoids + ascorbic acid)

**Natural agent:** Honey (>1 YO)

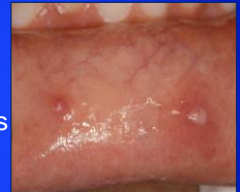## Pseudomembranous Candidiasis



Complication of overuse of topical steroids

## What Else Is In The Bag?

- Aphthous minor ulcer
- Traumatic/factitial ulcer
- Recurrent HSV infection
- Transient lingual papillitis
- Superficial mucocele
- Contact allergy
- Systemic diseases



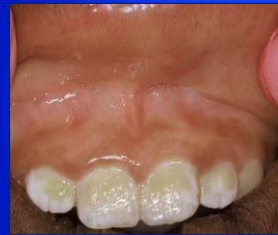Superficial mucoceles

## Celiac Disease

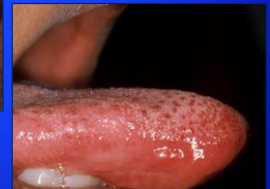

- Genetic immune-mediated enteropathy
- Trigger: Gluten grains (wheat, barley, rye)
- Prevalence: .5% to 1% (1 in 100)
- S/S: GI distress, anemia, joint pain, fatigue, asthma, short stature, arthritis, vitamin K deficiency
- Oral S/S: Enamel hypoplasia, oral ulcers, gingivitis, dry mouth
- Tests: IgA antihuman tissue transglutaminase (TTG), IgA endomysial antibody IF (EMA), antigliadin AB

## Celiac Disease



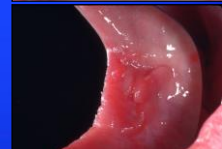
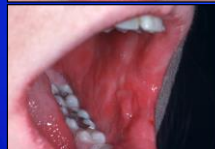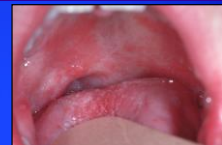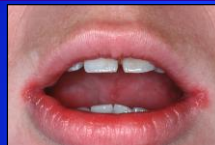- ✓ Mild enamel hypoplasia
- ✓ Resolving tongue ulcer
- ✓ Mucosal pallor



## Crohn's Disease

- Type: Inflammatory disease of GI tract
- Age: Starts in childhood
- Oral lesions precede GI lesions: 30%
- S/S: Cramping pain, diarrhea, nausea, weight loss, anemia, decreased growth
- Oral S/S: Aphthous-like ulcers, tissue tags, cobblestone pattern, diffuse or nodular swelling, stomatitis; orofacial granulomatosis; Staph infection
- TX: Sulfasalazine, steroids, immunomodulators and biologics, others

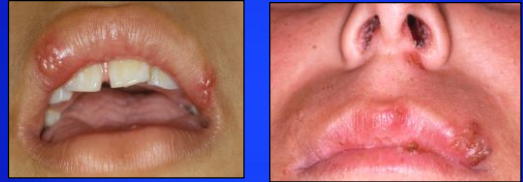## Crohn's Disease



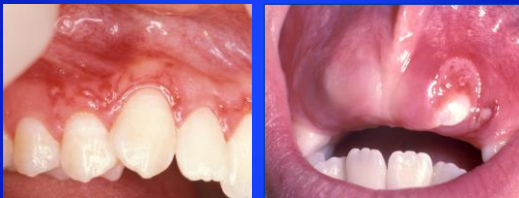## Secondary HSV Infection

- Cause: Reactivation of HSV-1
- Types: Herpes labialis, facialis, intraoral HSV
- Prevalence: 20-35%; ↑ with lower SES
- Risk factors: UV light, trauma, fever, teething, menses
- Site: Perioral skin, vermillion, gingiva, hard palate
- Duration: 7 - 14 days
- S/S: Recurrent, acute onset, prodromal redness, tender, clustered vesicles & ulcers, referred pain
- Complication: Scars, erythema multiforme, Bell's palsy, herpetic whitlow, blindness

## Herpes Labialis & Facialis



## Recurrent Intraoral HSV



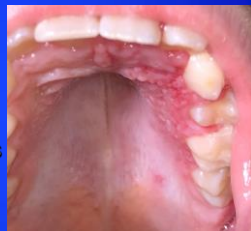## HSV - Hot Off the Press!

- NHANES study, 2015-2016 – ages 14-49
- Prevalence: HSV 1 – 48%; HSV 2 – 12%
- Both types higher in ♀ – 51% vs 45% in ♂
- Pediatric prevalence: 14-19 YO – 27%
- HSV 1: highest among Mexican-Am (72%) vs non-Hispanic whites (37%)
- HSV 2: highest among non-Hispanic blacks (35%) vs non-Hispanic whites (8%)
- Both down significantly from 1999-2000 study

• NCHS Data Brief, #304, Feb 2018

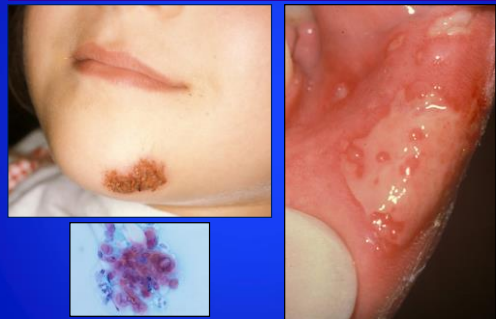## New Pattern: Zosteriform HSV

- Recurrent HSV
- Distribution: Follows an affected nerve to midline
- S/S: Burning, tingling, itchy sensation; painful cluster of vesicles, ulcers
- Mimics: Herpes zoster
- ID the trigger; may be dental treatment
- Tx: Antivirals, palliative



11 YOWF – Painful, raw lesions of sudden onset

## Recurrent HSV & Dental Trauma



## Recurrent Herpetic Infection

### Systemic Agents:

- Sitavig (acyclovir) 50 mg buccal tab X 1
- Zovirax, g (acyclovir) 400 mg capsules
  - Take 1 capsule 3 times a day X 5 days
- Valtrex, g (valacyclovir) 1 g tablets
  - Take 2 tablets twice daily, 12 hours apart, when symptoms first develop
- Famvir, g (famciclovir) 500 mg tablets
  - Take 3 tablets as a single dose at first sign of infection (not recommended for children)

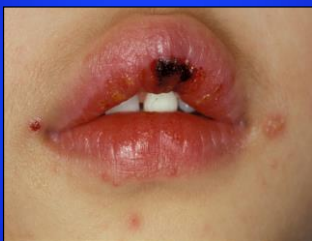

## Recurrent Herpetic Infection

- Topical Antiviral Agents for Lips
- All approved for use in children > 12 yrs
  - Docosanol (Abreva) cream 10% (OTC)
    - Sig: Apply 5 times/day for up to 10 days
  - Penciclovir cream 1%
    - Sig: Apply q2h while awake for 4 days
  - Acyclovir cream 5%
    - Apply 5 times /day for 5 days
  - Xerese (acyclovir 5%/hydrocortisone 1%) cream
    - Apply 5 times/day for 5 days (new, expensive)



## Herpes-Associated Erythema Multiforme



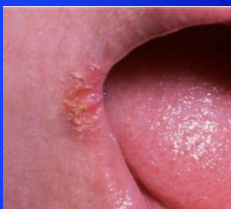In children with recurrent oral ulcers, 20% have history of both aphthous ulcers and herpetic lesions.

## Questions to Ask?

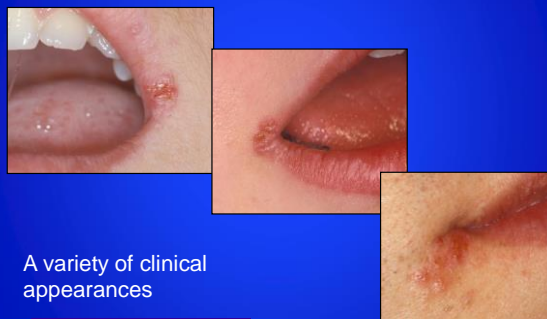- Recurrence rate, duration, location of sores?
- Start as a sore, pimple or a blister?
- Do rashes on the face develop also?
- Do the sores occur inside & outside the mouth?
- Weight loss? Growth rate?
- Any other family member get them?
- Any stomach, joint, bowel, bruising problems?
- Headaches, dizziness, fever, swollen glands?

## Angular Cheilitis in Children

- Inflammatory lip lesion
- Cause: *Candida albicans*, *S. aureus*
- Factors: Drooling & licking lips, oral candidiasis, lip incompetence, chapped lips,
- Site: Corners of mouth
- S/S: Erosions, ulcerated fissures, papules; may bleed; tender; recurs
- Complication: Scar, pigment changes



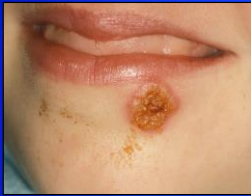## Angular Cheilitis



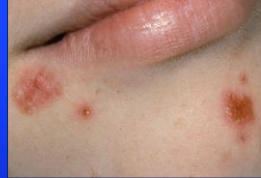A variety of clinical appearances



## Perioral Impetigo



- ✓ May mimic fungal or viral infection
- ✓ May have a secondary infection



### Topical Antibiotics:

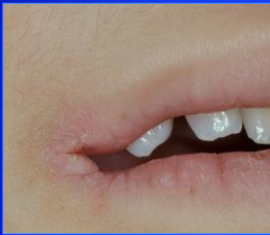- ✓ Bactroban (mupirocin) 2% ointment
- ✓ Altabax (retapamulin) 1% ointment BID X 5 days

## Angular Cheilitis

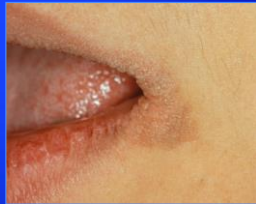

- Identify and eliminate the cause
- Nystatin ointment 100,000 U/g
- Clotrimazole cream 1% (RX and OTC)
- Miconazole cream, ointment 2% (RX, OTC)
- Ketoconazole cream 2%
- Triamcinolone/Nystatin ointment, cream
- Hydrocortisone/iodoquinol cream 1%
- Impetigo - Bactroban (mupirocin) oint 2%

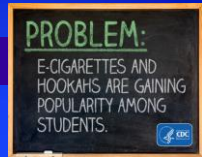
## Angular Cheilitis or Not?



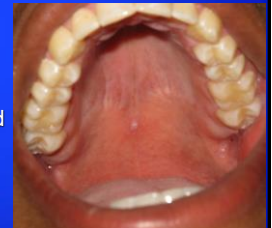- ✓ Orofacial Warts
- ✓ Post-inflammatory melanosis



## Hookah

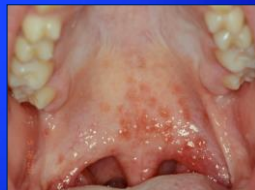

- Water pipe with flavoring, chemical, +/- tobacco
- Current use of hookahs increased in middle and high school students (2011-2016).
- 2.0% of middle school used hookah in past 30 d
- 5% of HS students used hookah in the past 30 d
- S/S: Palatal, lip irritations



## Multifocal Ulcers of Sudden Onset

- Widespread distribution of acute onset
- Painful, dysphagia
- Duration is usually < 2 weeks
- Vesicles → ulcers
- Oral +/- skin lesions
- Systemic features
- Cause is often viral
- Most are common diseases

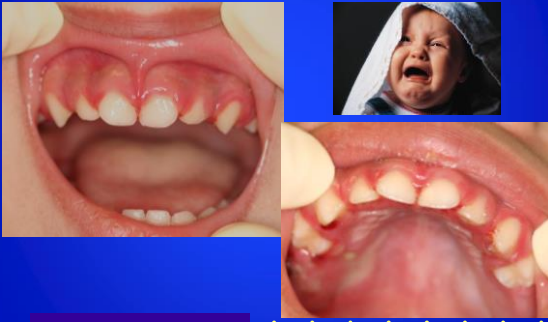

Herpangina

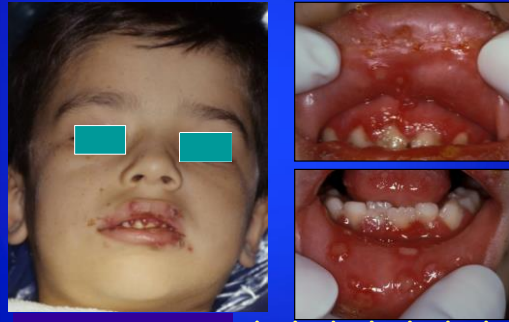## Primary Herpes Simplex Infection

- Cause: HSV-1, HSV-2
- Types: Gingivostomatitis, pharyngitis
- 2 age peaks: 6 mos - 5yrs; early 20s
- Transmission: Direct contact, saliva, sexual
- Symptomatic disease: 12-30% infected
- Site: Oropharyngeal, anogenital & cutaneous
- Duration: 7 - 14 days
- S/S: Acute onset, fever, lymphadenopathy, malaise, pain, erythema, vesicles, ulcers, drooling, dysphagia; widespread oral lesions

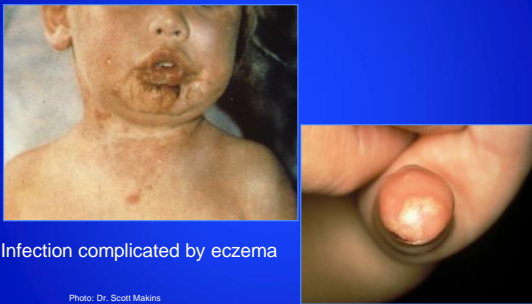## Primary HSV Infection



## Primary HSV Infection



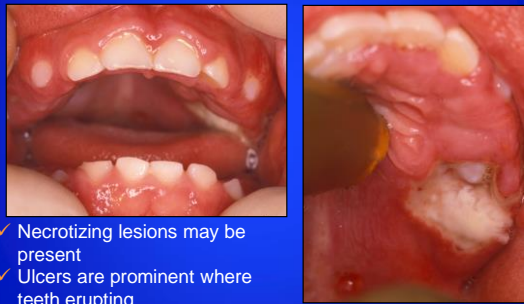## Primary HSV Infection



Infection complicated by eczema

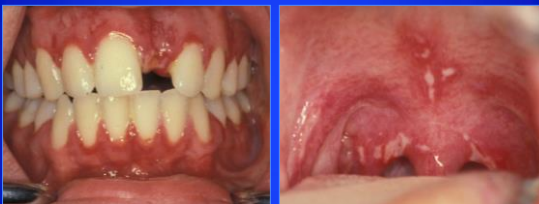Photo: Dr. Scott Makins

## Primary HSV Infection



- ✓ Necrotizing lesions may be present
- ✓ Ulcers are prominent where teeth erupting

## HSV Pharyngitis



Mimics:  
Infectious mononucleosis  
Herpangina  
Gonococcal pharyngitis



## Primary HSV: When to Treat?

- Cochrane Review: Weak positive evidence
- Early infections - the first 3 days
- Severe cases with extensive skin lesions
- Cases with periorbital or ocular lesions
- Immunosuppressive drugs, steroids
- Children who are immunocompromised
- Multiple siblings who are close in age?
- Caution with renal disease, dehydration

## Primary HSV Infection

- Topical Coating Agents:
  - Benadryl/Maalox susp +/- lidocaine viscous 2%
  - Sucrets (dyclonine) throat lozenges
- Systemic Agents:
  - Zovirax, g (acyclovir) 200mg/5mL, caps 400mg
  - Valtrex, g (valacyclovir) tabs 1g
- Nutritional Liquid Supplements and Fluids
- Topical Antimicrobial Agent for 2<sup>o</sup> Infection:
  - Chlorhexidine rinse .12% (after ulcers resolved)



## What Else Is In The Bag?

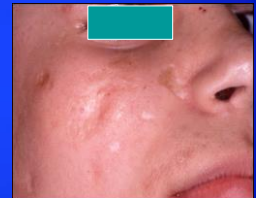- Primary herpetic gingivostomatitis
- Herpangina & Roseola infantum
- Hand, foot, and mouth disease
- Varicella and herpes zoster
- Herpetiform aphthae
- Erythema multiforme
- Necrotizing ulcerative gingivitis
- Streptococcal or Staphylococcal stomatitis
- Infectious mononucleosis (EBV)
- Gonorrhoeal stomatitis

## Herpes Zoster (Shingles)

- Reactivation of varicella-zoster virus following varicella infection (chickenpox)
- 5% of cases occur in children <15 YO
- Prodromal pain from ganglionitis and necrosis due to replicating viruses
- S/S: fever, malaise, headache, lymphadenopathy, sensitive teeth, otitis media; unilateral prodromal pain, burning, itching
- Rarely tooth devitalization & osteonecrosis of bone

## HZ Risk Factors in Children

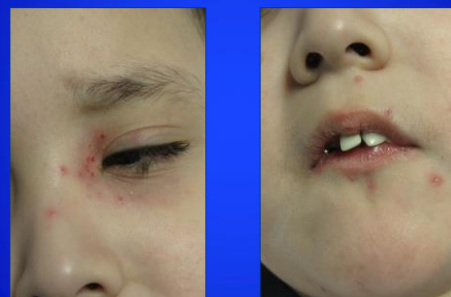- Leukemia, other malignancies
- Immunocompromised
- In utero VZV exposure
- Primary VZV in 1<sup>st</sup> year
- Antitumor necrosis factor agents
- Immune reconstitution inflammatory syndrome



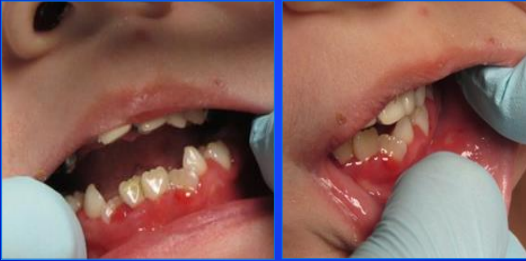## Herpes Zoster (Shingles)

- 1-4 mm vesicles along dermatome
- Shallow ulcers that stop at midline
- Duration: 2-4 weeks
- Postherpetic neuralgia: uncommon in children
- Ocular involvement - blindness
- Ramsay Hunt syndrome: facial paralysis, vertigo with involvement of external auditory canal; may have acute onset dysphagia, dysphonia and cranial, cervical, or pharyngeal pain

## Herpes Zoster



## Herpes Zoster



## Enterovirus Infection

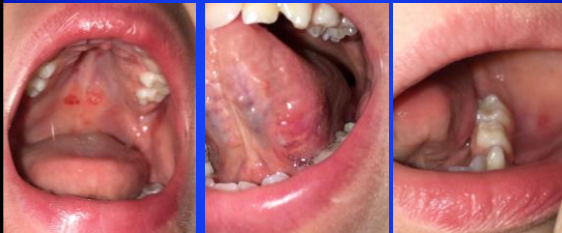### Herpangina

- Common, acute infection
- Virus: CA, CB, EV71
- Age: Most <6 yr
- S/S: +/- Fever, sore throat, dysphagia
- Oral: Vesicles, ulcers on soft palate, tonsillar pillar
- Adverse: Encephalitis, carditis, pneumonitis, paralysis
- May recur – different virus

### Hand-Foot-Mouth

- Common, acute infection
- Virus: CA, EV71
- Age: Most <6 yr
- S/S: +/- Fever, sore throat, dysphagia, hands, feet, buttock, other skin
- Oral: Vesicles, ulcers on tongue, buccal, labial mucosa
- Adverse: Same
- May recur – 4% in 36 mo

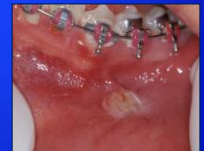## Hand-Foot-Mouth Disease



4 YOWM with mouth sores of sudden onset, no fever, no obvious skin lesions  
Oral lesions tend to more anterior and multifocal distribution

## Persistent Focal Ulcers

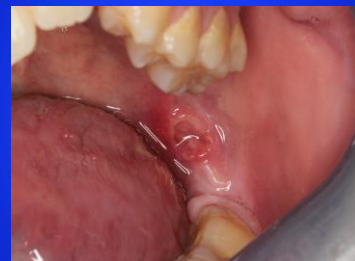- Solitary ulcer; usually gradual onset
- Tender to painful
- Duration is usually > 3 weeks
- Deep ulcer with irregular borders
- Red, granular or thick necrotic surface
- +/- Systemic features
- Cause is often variable
- Heal with scarring
- Uncommon to rare



## Traumatic Granuloma (TUGSE)

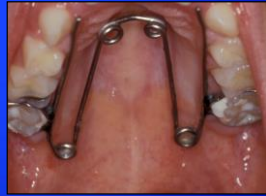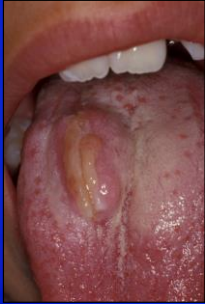- Cause: Chronic trauma
- Contributing factors: Biting habit, dental problems, ortho appliances, xerostomia, pain insensitivity
- Age: Infants to adults
- Site: Tongue – most common
- Duration: 1 - 8 months
- S/S: Painful, deep, persistent ulcer, may have elevated granulation tissue
- TX: ID the cause, topical anesthetics/coating agents, steroids, biopsy

## Persistent Ulcer & BMG



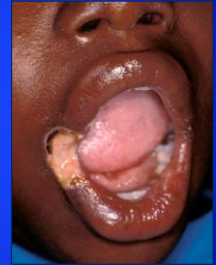Med Hx: CL/CP, ADD, seizure disorder, ostitis media

## Traumatic Granuloma



## What Else Is In The Bag?

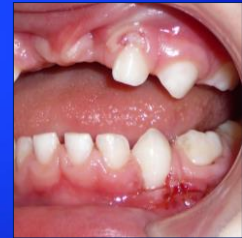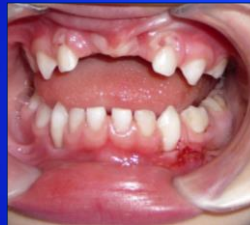- Traumatic granuloma
- Factical ulcer
- Aphthous major
- Electrical burn
- Noma
- Langerhans cell histiocytosis
- Ulcerated tumor
- Squamous cell carcinoma



## Factitial Oral Injuries

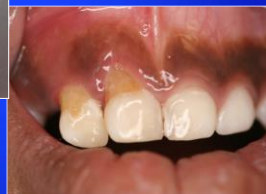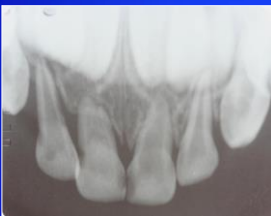
- Type: Self-inflicted oral lesions
- Age/Gender: 80% ≤ 12 years old; F > M
- Method: Fingernails, teeth, toothpick, pacifier, toothbrush, hair, pen, toy
- Site: Easy to reach location; facial gingiva, lips, buccal mucosa
- S/S: Chronic ulcers, gingival recession, bizarre shape, sharp outlines; single or multiple
- TX: ID the cause; palliative treatment; psychological assessment

## Factitial Mucosal Injuries

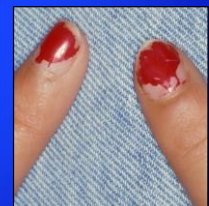
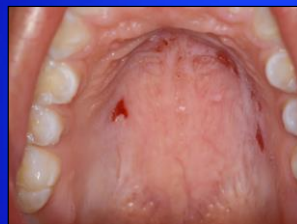
Photos: Dr. Marilyn Sandor

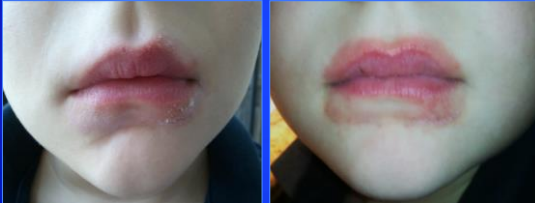## Factitial Mucosal Injuries



## Factitial Mucosal Injuries

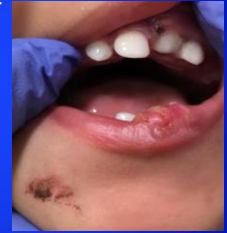

## Lip-sucking Habit

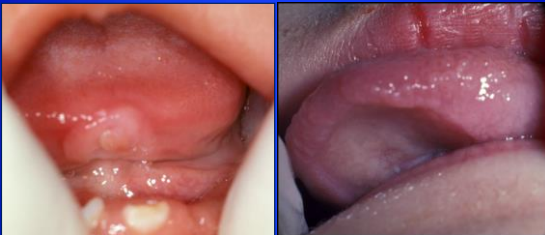

## Traumatic Ulcers in Children

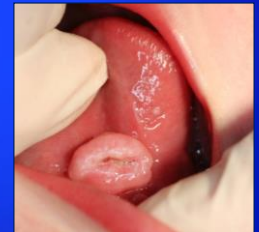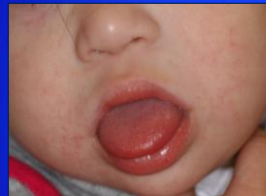- Usually due to accidents
- Riga-Fede disease: Anterior ventral tongue
- Bednar's aphthae: Soft palate
- Ulcerated median rhomboid glossitis: Midline dorsal tongue
- Factitial pacifier habit
- Primary cause: Aberrant sucking habits in infants



## Riga Fede Disease

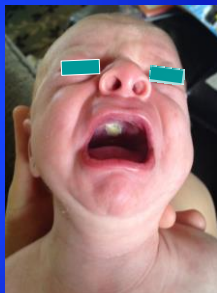


## Riga-Fede Disease



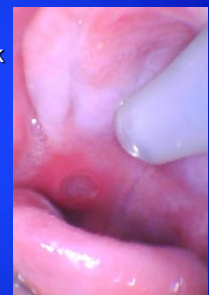## Mystery Lesion

- 7 wk old male presented with palatal lesion. Mom states it has been ongoing for 4 to 5 weeks. Problems with eating and weight loss
- Placed on nystatin susp
- Referred to oral surgeon for biopsy
- Felt to be fungal but uncertain. Nystatin slightly decreased lesion size.



## Breastfeeding Shields

- Pros: Comfort for mother
- Pros: Benefits of breast milk
- Cons: Decreased milk flow
- Cons: Traumatic palatal ulcers (Bednar's aphthae)



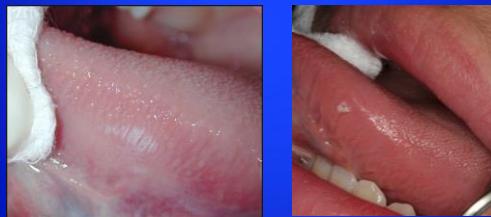## Oral Ulcers in Infants

- Identify and eliminate the cause
- Modify the feeding position
- Modify the feeding device
- Smooth incisal edges of lower teeth
- Topical steroid +/-
- Chlorhexidine oral rinse
- Biopsy lesion, if persistent
- Medical consultation
- Avoid topical benzocaine, lidocaine



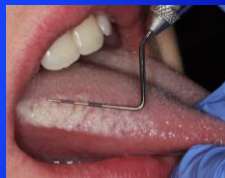## White Lesions in Children

- White Surface Thickening
- White Surface Material



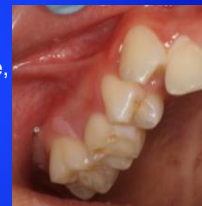## White Surface Thickening Lesions

- Translucent to opaque
- Rough, shredded, wrinkled, pebbly
- Flat or nodular, stuck-on appearance
- Adherent, does not rub off
- +/- Red component
- Plaque, linear or circular
- Asymptomatic but may burn

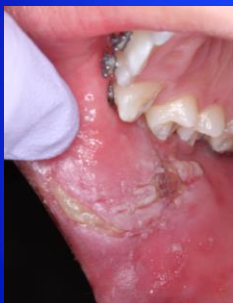

## Frictional Keratosis

- Common reactive lesion
- Chronic low-grade trauma
- Causes: Biting or sucking habits, orthodontic appliance, fractured tooth, toothbrush
- Site: Buccal mucosa, lateral tongue, gingiva
- S/S: Focal, white, adherent, rough patch; nontender
- TX & Prog: Eliminate cause, lesion regresses



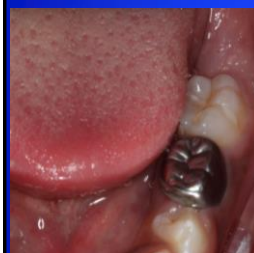## Cheekbiting Keratosis with Ulcers



- Chronic habit
- Increased anxiety
- May be factitial
- Additional trauma with local anesthetic or placement of orthodontic appliances



## BARK

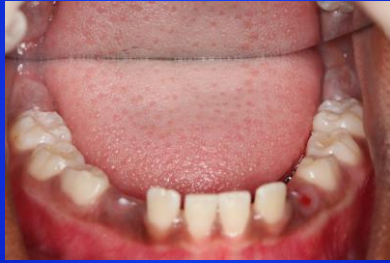

- Benign alveolar ridge keratosis [BARK]
- Variant of frictional keratosis
- Occurs on keratinized site: retromolar pad (usually bilateral), edentulous ridge
- Oral counterpart of lichen simplex chronicus (LSC)
- Has specific histopathology
- Tx: Document and observe

Natarajan et al. J Am Acad Dermatol 2008; 58:151



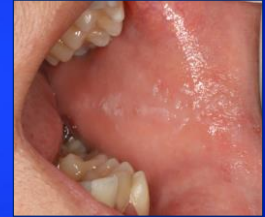## BARK



Bilateral retromolar pads

## What Else Is In The Bag?

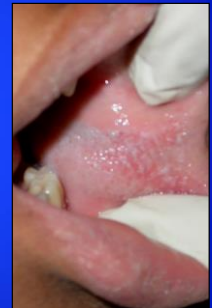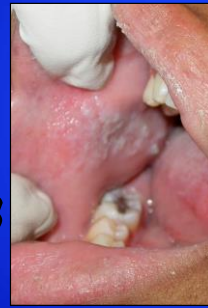- Hairy leukoplakia
- Lichen planus
- Cinnamon reaction
- Frictional keratosis
- Leukoedema
- Linea alba
- Cheekbiting keratosis
- Smokeless tobacco keratosis
- Leukoplakia



## Cinnamon Contact Stomatitis

- Common allergy from cinnamon oil
- Sources: Ice cream, soft drinks, gum, candy, toothpaste, breath freshener, mouthwashes, dental floss
- Site: Gingiva, lips, buccal mucosa, tongue
- S/S: White shaggy patches with erythema; chapped lips; red, swollen gingiva; burning sensation
- TX: DC product – resolve in 1 week; topical steroids, if severe

## Contact Cinnamon Stomatitis



## Toothpaste Allergens

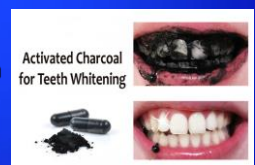- Flavors, unspecified
- Cocamidopropyl betaine
- Propylene glycol
- Essential oils
- Parabens
- Peppermint, Spearmint
- Vitamin E
- Grape extract
- Propolis
- Tee tree oil



Otto S. Journal of Clinical & Aesthetic Dermatology, 2010

## Latest Craze Reviewed

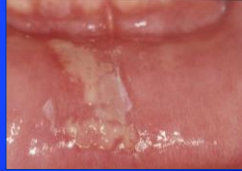- Brooks JK, et al. Charcoal and charcoal-based dentifrices: A literature review. JADA 2017
- Most do not have fluoride
- Bentonite clay (38%) – some are carcinogens
- Betel leaf (1) – carcinogen
- Charcoal is an abrasive





## White Surface Material Lesions

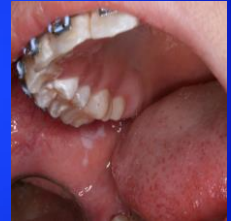- Creamy to filmy white
- Soft surface debris
- Semiadherent or nonadherent
- Raw, red under material
- Plaque or papular pattern
- No surface enlargement



Chemical Burn

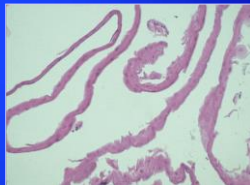
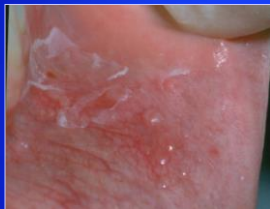## Mucosal Sloughing

- Cause: Sensitivity to dental or OH products; pH
- Factors: ↓ saliva or ↑ viscosity; mouth-breathing
- S/S: Irregular, white semi-adherent patch; rough and mildly tender
- Resolves within 24 hrs
- Mimics: Frictional keratosis, mucosal burn, candidiasis



Cause: bonding etchant

## Mucosal Sloughing

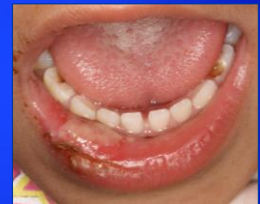

- ✓ Mucosal sloughing
- ✓ Superficial mucoceles

Photo: Dr. Jerry Bouquot

## What Else Is In The Bag?

- Pseudomembranous candidiasis (Thrush)
- Mucosal sloughing
- Chemical burn
- Lip, cheekbiting lesion
- White coated tongue
- Plaque (biofilm)
- Ulcer with necrosis
- Koplik's spots (measles)
- Mucous patch

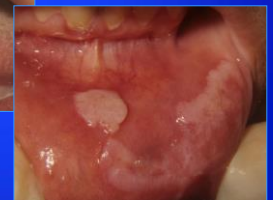
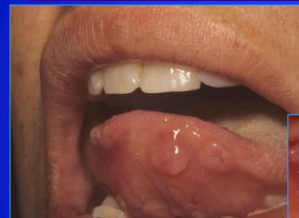
Local Anesthetic Trauma

## Mucous Patch

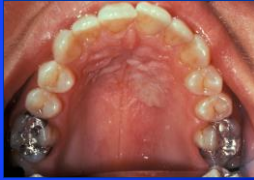- Associated with secondary syphilis
- *Treponema pallidum* → oral sex, deep kissing
- Develops 4-10 wks after initial infection (chancre)
- General S/S: Painless lymphadenopathy, sore throat, malaise, headache, fever, painless rash
- Oral site: Tongue, lip, buccal mucosa, palate
- Oral S/S: Multiple, tender white patches, oval to serpentine; 30% develop these lesions
- Resolve 3-12 weeks; may recur within the year
- TX: Pen G (IM), doxycycline 100 mg BID X 14 d

## Mucous Patch



## Chemical & Thermal Burns

- Causes: Aspirin, phenol, phosphoric acid, heat, chemicals, including topical anesthetics
- Site: Any mucosal site
- S/S: Localized or diffuse, tender white patches that wipes off, leaving a raw, red base
- Tx: Biotene rinse, sodium bicarbonate rinse



## Mucosal Burn & Carious Teeth

