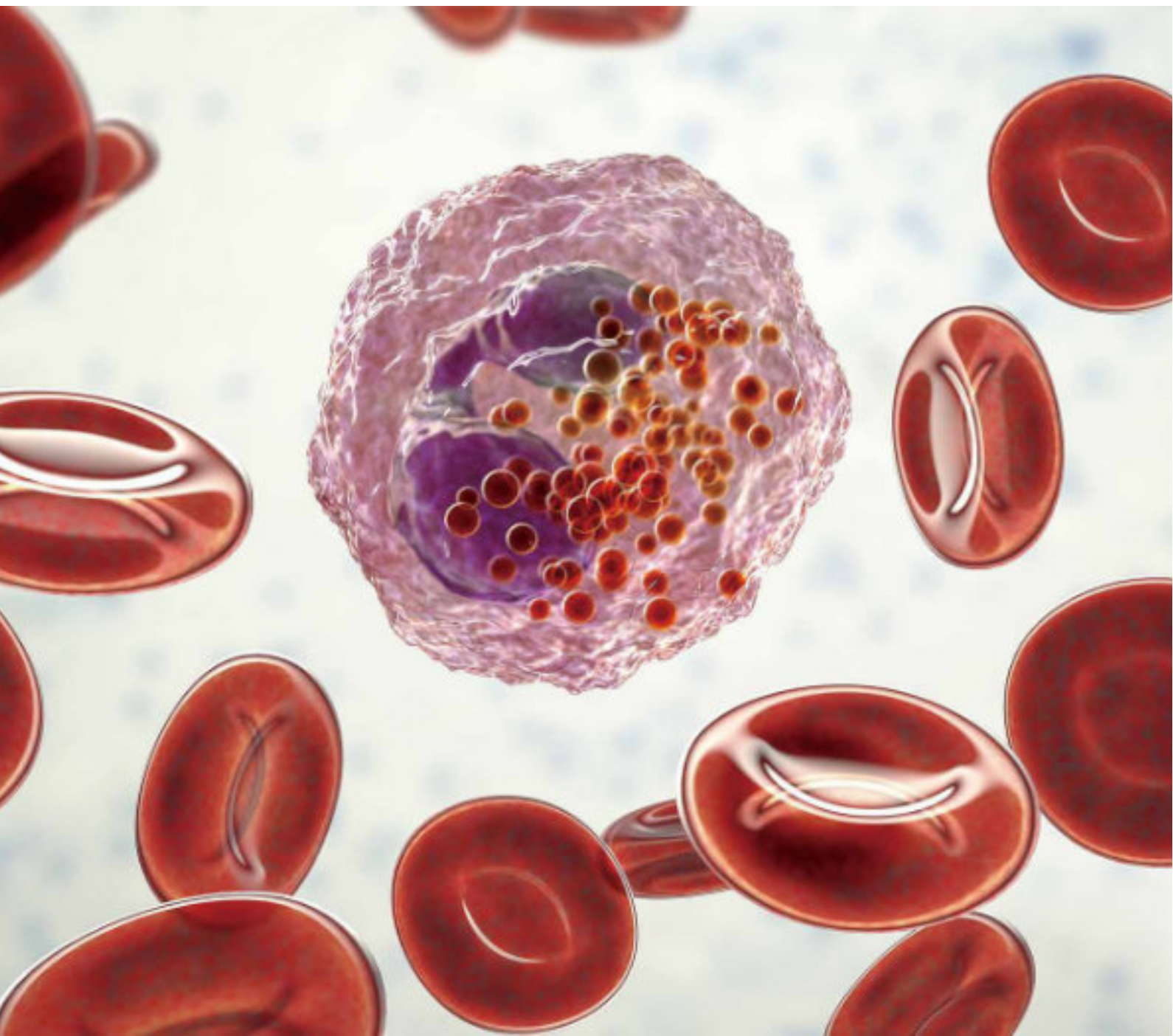


**mindray**

# Blood Cell Atlas



# Introduction

The cell images in this blood cell atlas were photographed by an MC-80 Automated Digital Cell Morphology Analyzer on peripheral blood smears prepared by an SC-120 Slide Maker & Stainer following a standard Romanovsky staining procedure.



# Content

## Normal Peripheral Blood Cells

Band Neutrophil Granulocytes	04
Segmented Neutrophil Granulocytes	06
Lymphocytes	08
Monocytes	10
Eosinophils	12
Basophils	14
Red Blood Cells and Platelets	16

## Abnormal Peripheral Blood Cells

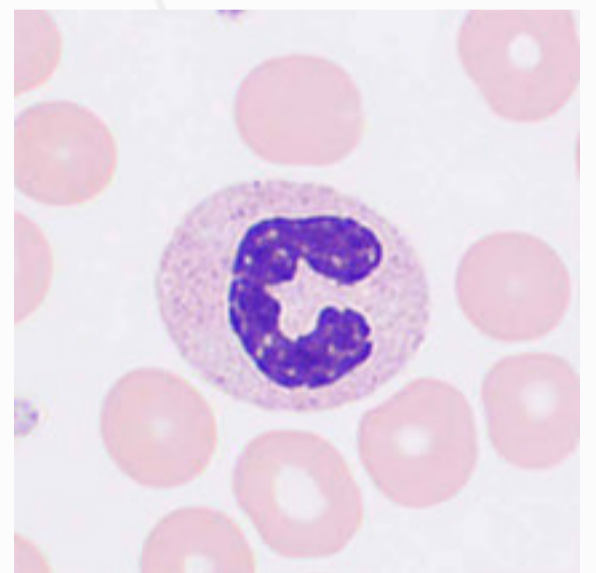
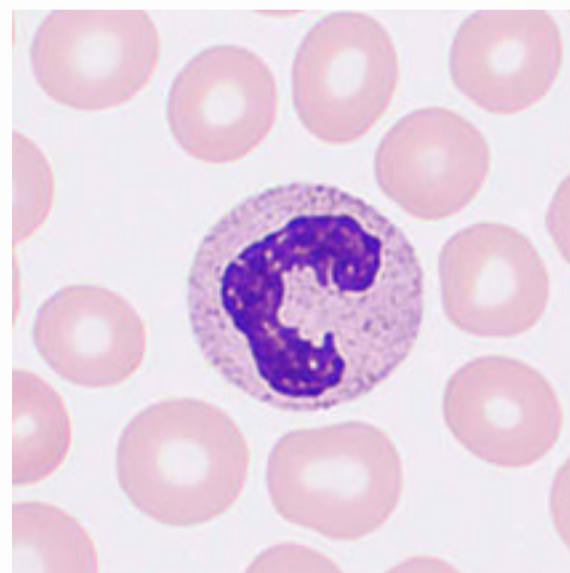
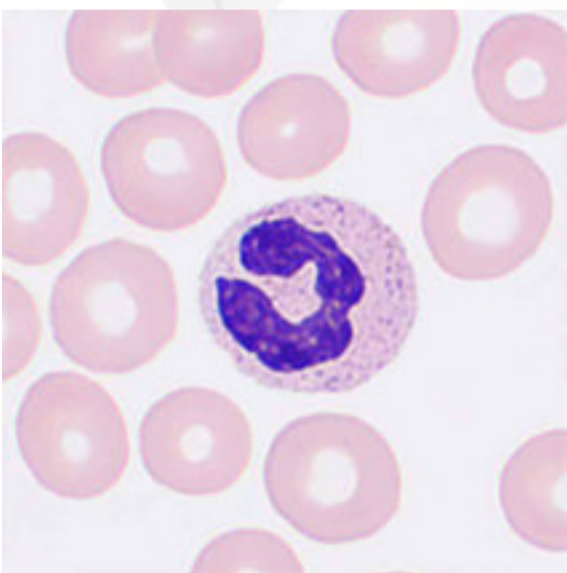
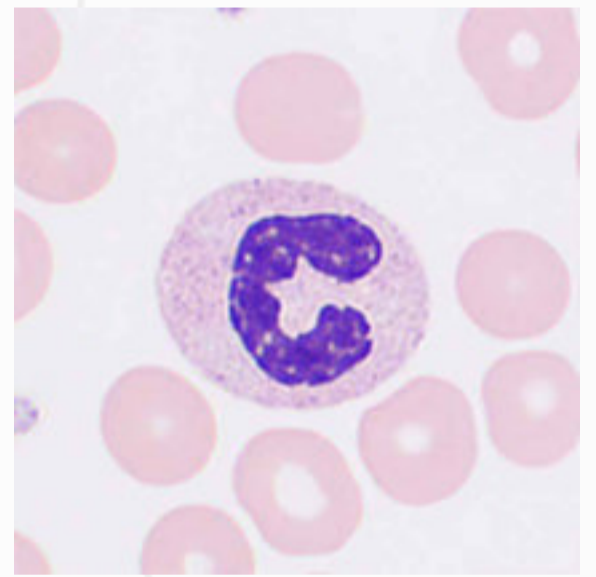
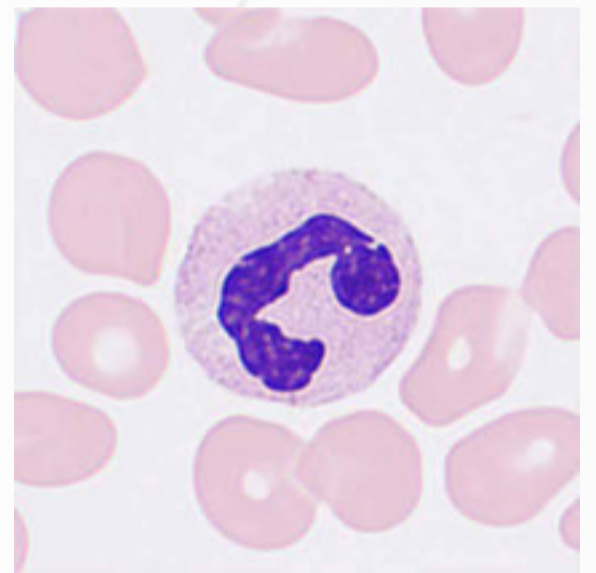
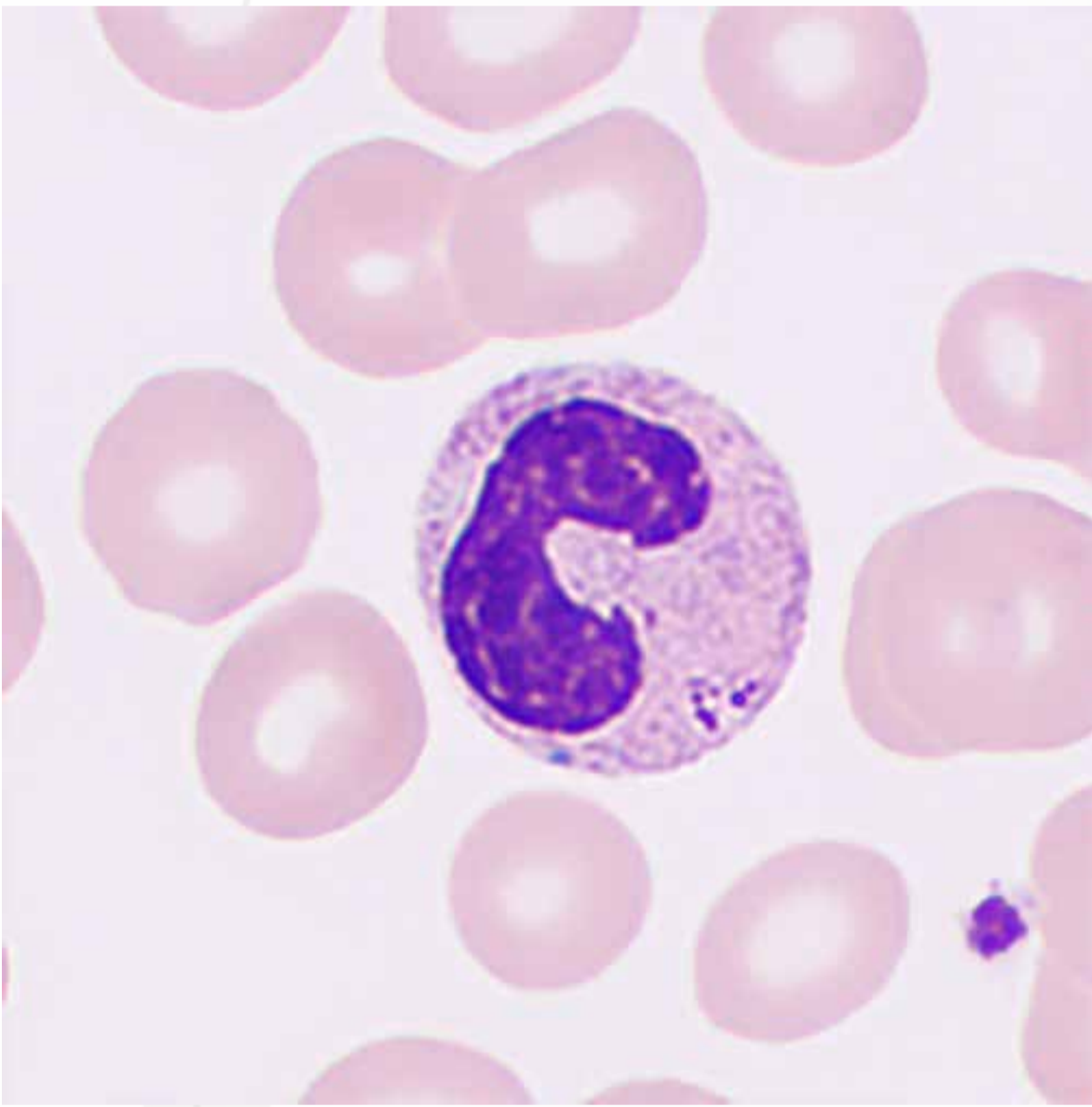
Neutrophil Phagocytosis of Fungi or Parasites	19
Toxic Changes in Neutrophils	20
Blast cells	22
Promyelocytes	24
Abnormal Promyelocytes	26
Neutrophilic Myelocytes	28
Neutrophilic Metamyelocytes	30
Reactive Lymphocytes	32
Abnormal Lymphocytes	34
Plasma Cells	38
Abnormal Platelets	40
Megakaryocytes	42
Nucleated Red Blood Cells	44
Smudge Cells	46
Artefacts	47

# Normal Peripheral Blood Cells

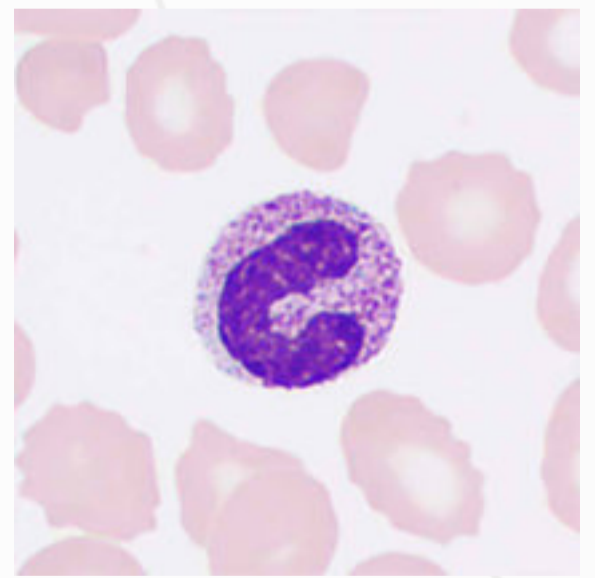
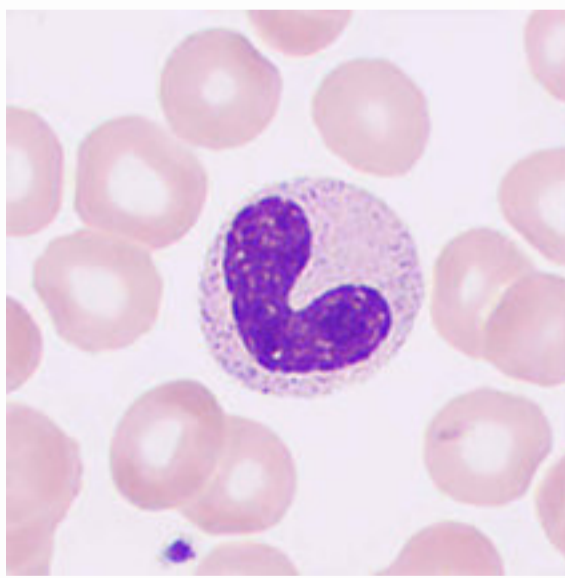
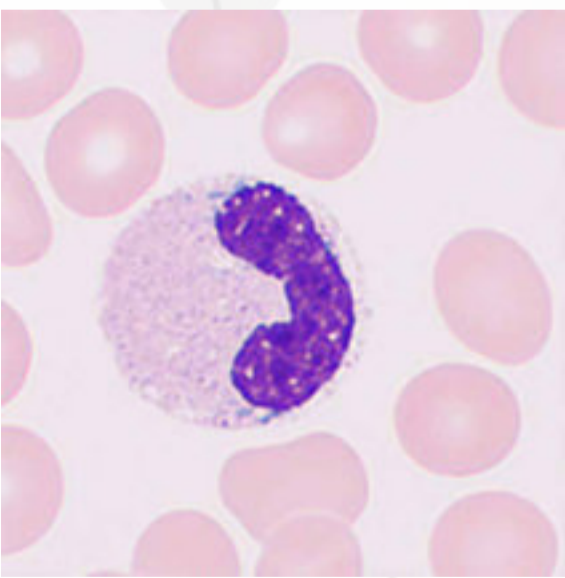
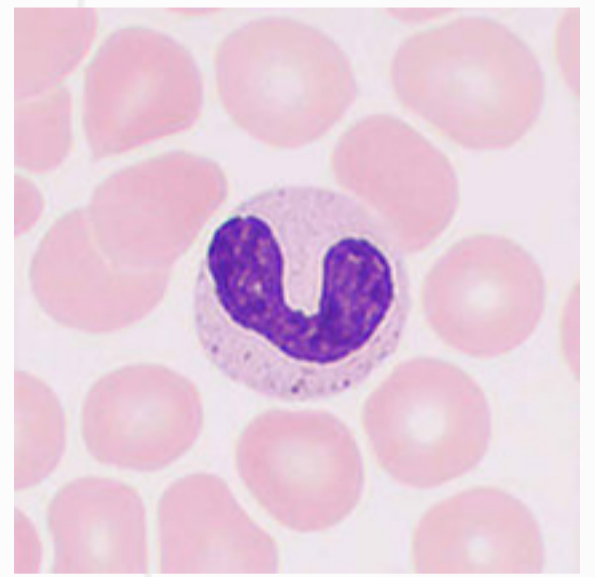
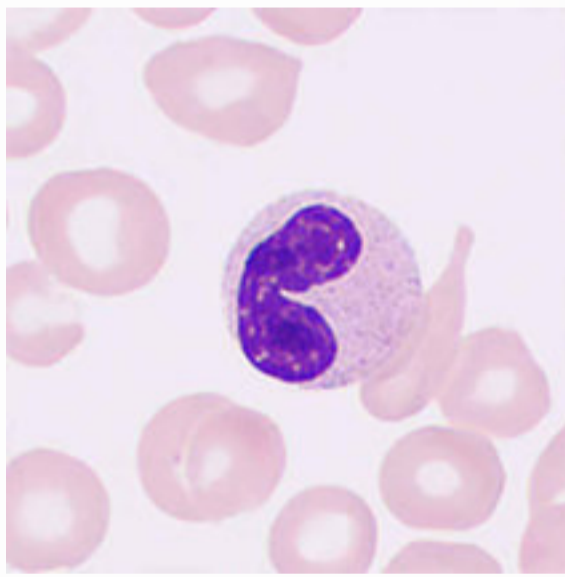
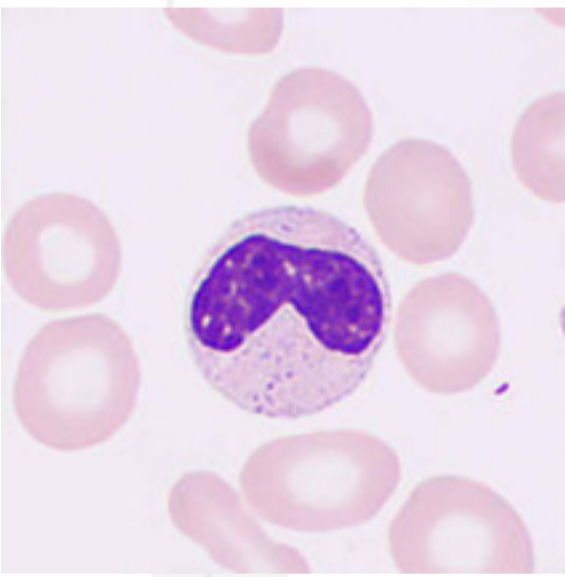
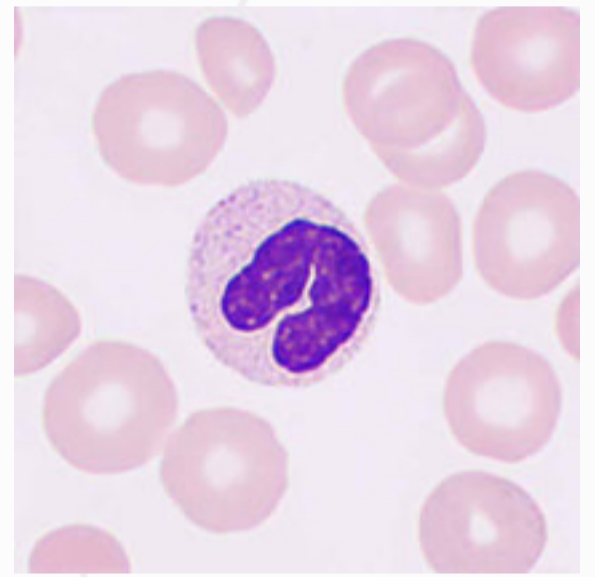
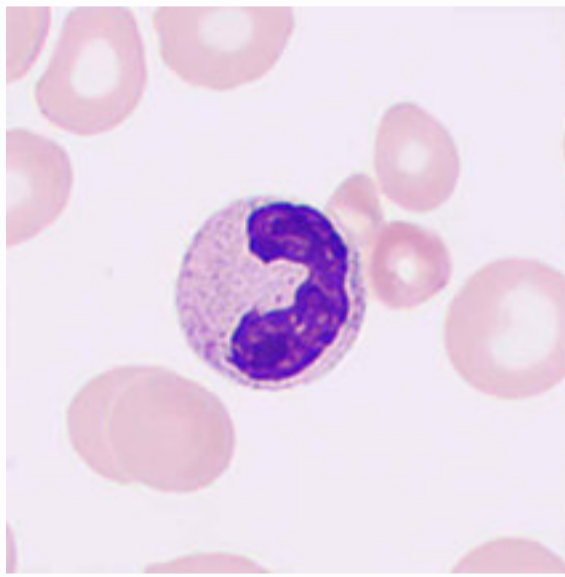
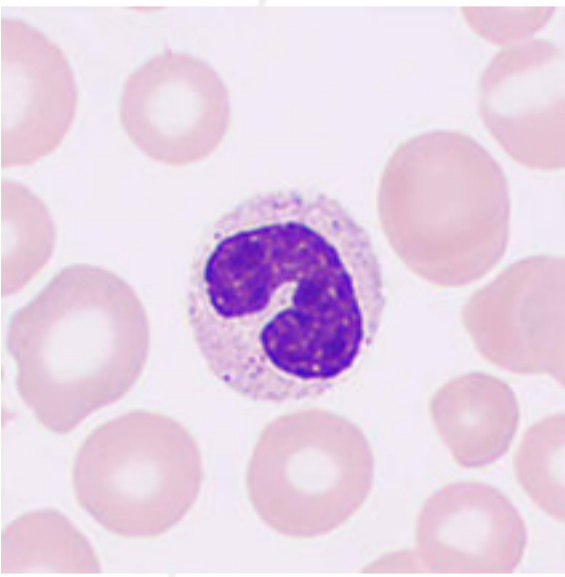


# Band Neutrophil Granulocytes

The cells are 10–15  $\mu\text{m}$  in diameter, round-shaped with typically rod-shaped, band-like, or sausage-like nuclei, having coarse, agglutinated nuclear chromatin in deep violet-pink color. The cytoplasm is abundant and pink, with a large number of small violet-pink granules.

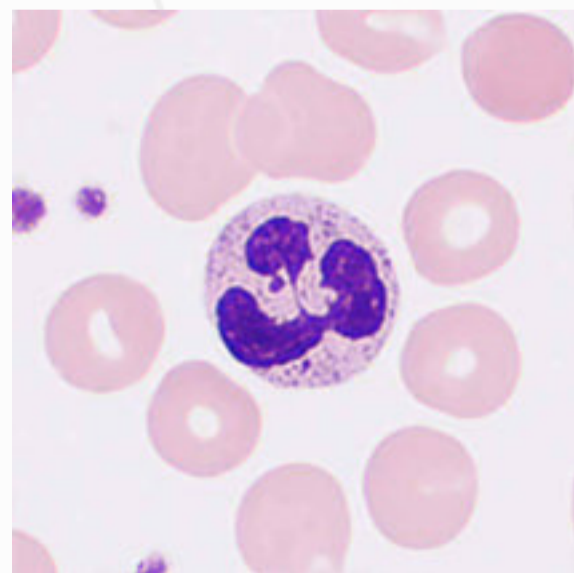
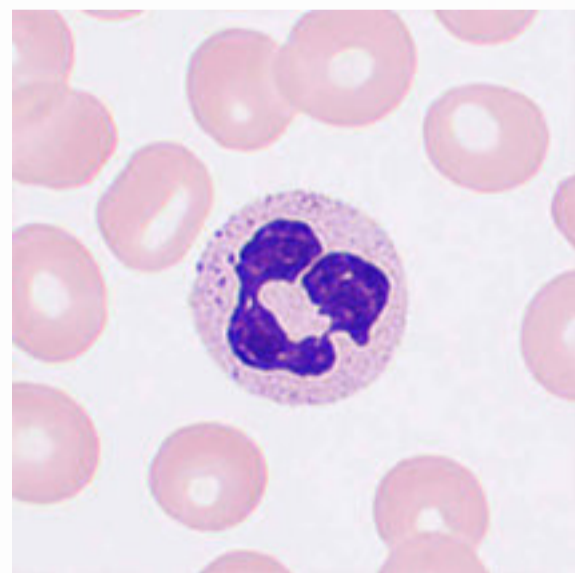
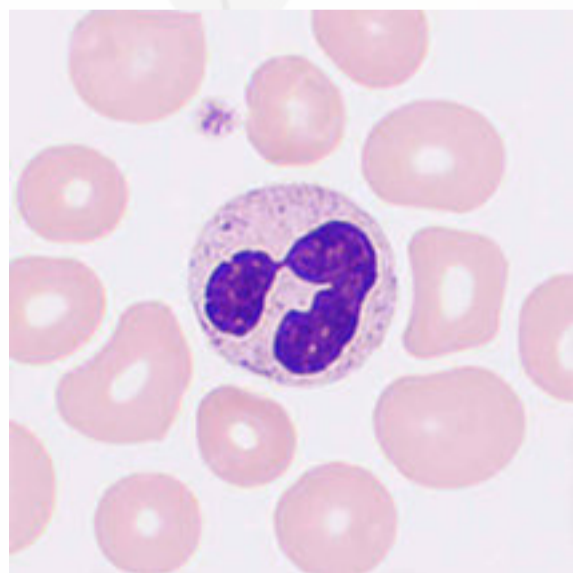
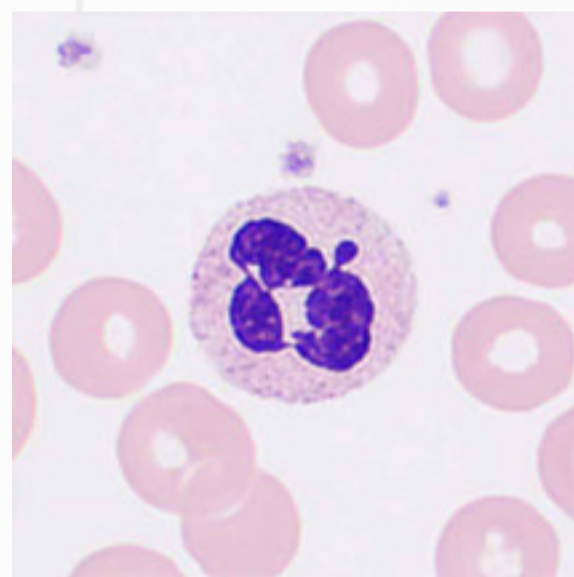
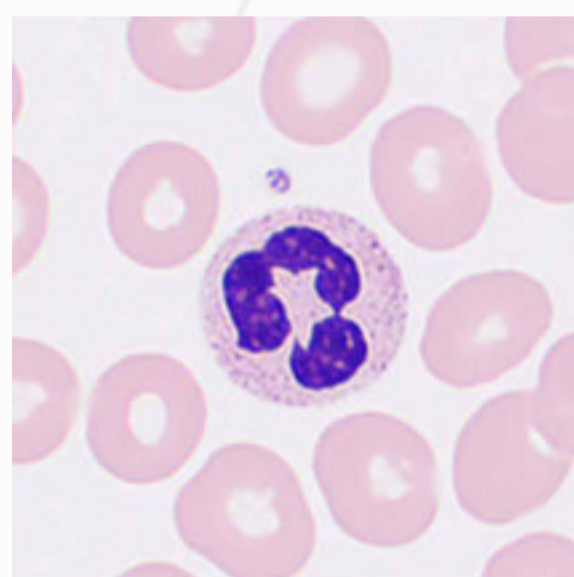
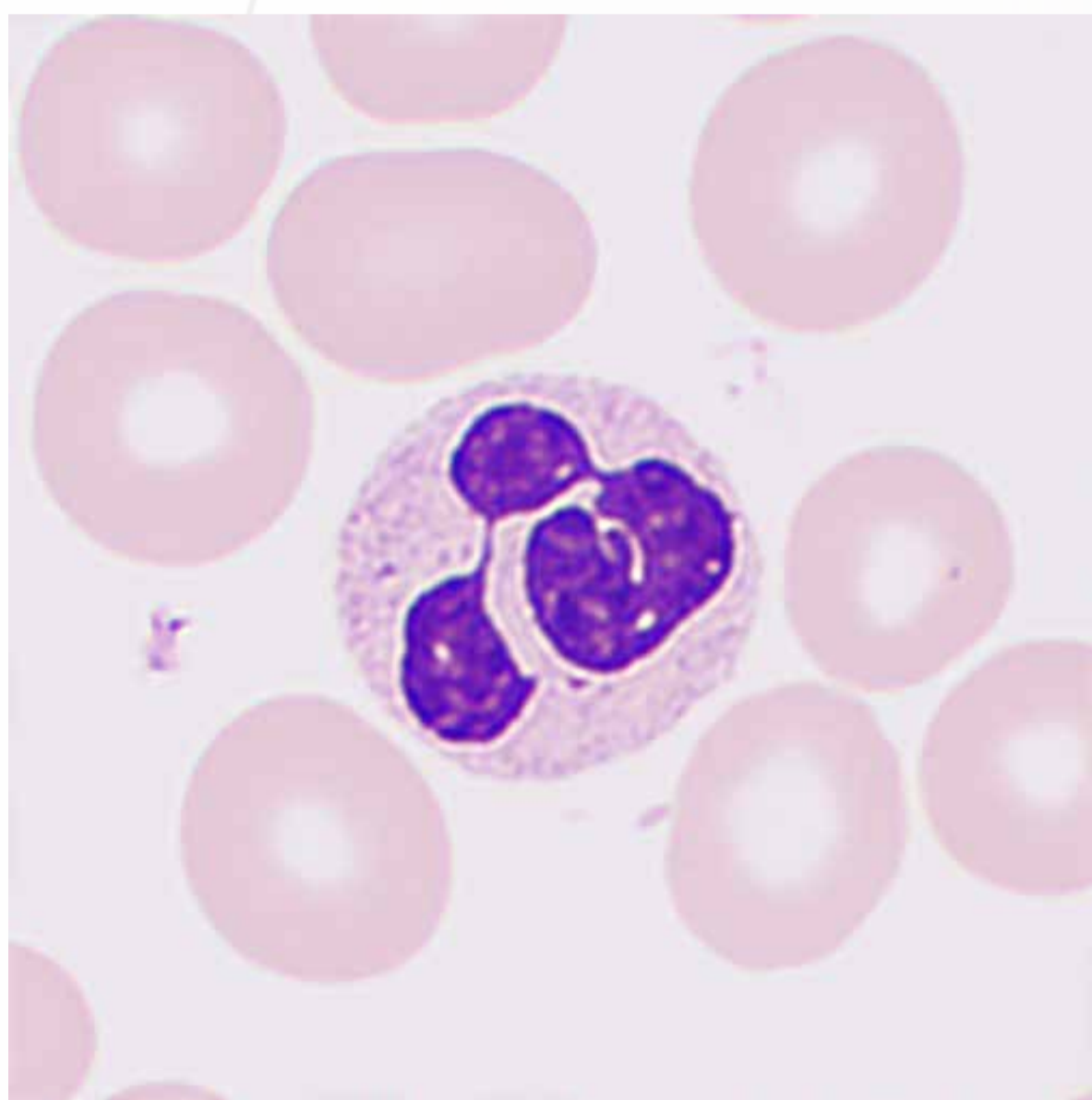


Band neutrophil granulocytes increased or/and the presence of metamyelocytes, myelocytes, or even promyelocytes in peripheral blood are referred to as a "left shift" and commonly seen in infections (especially acute septic infections), acute poisoning, acute blood loss, and aplastic anemia.

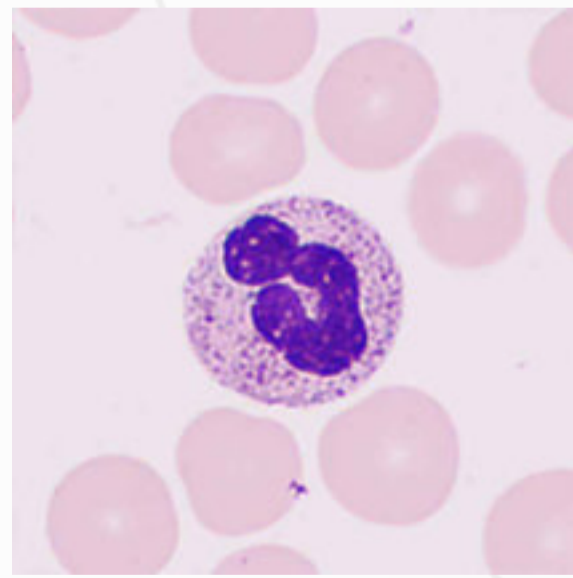
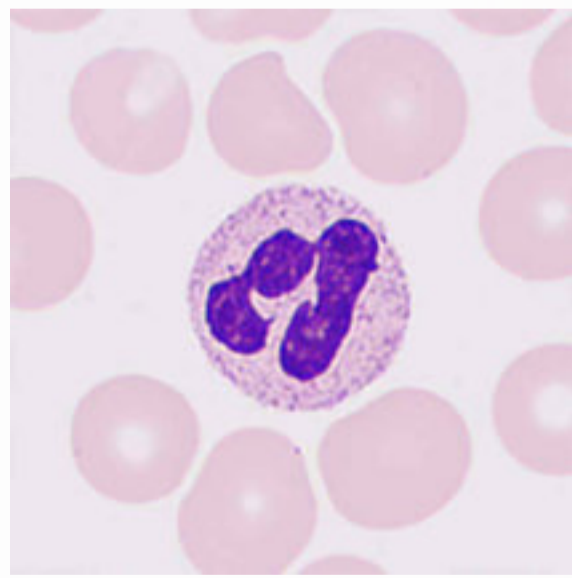
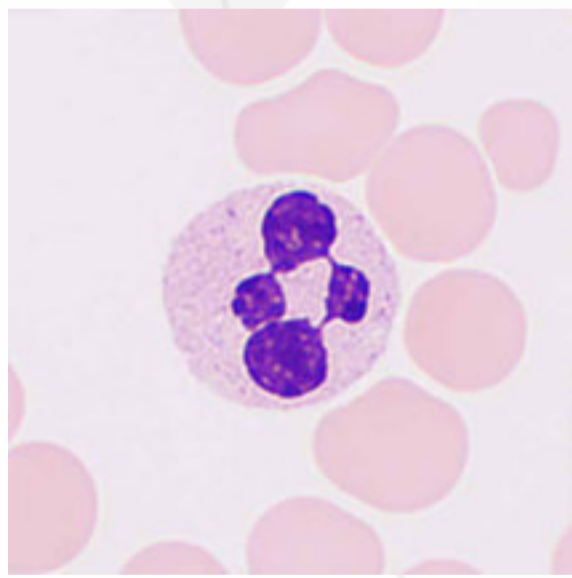
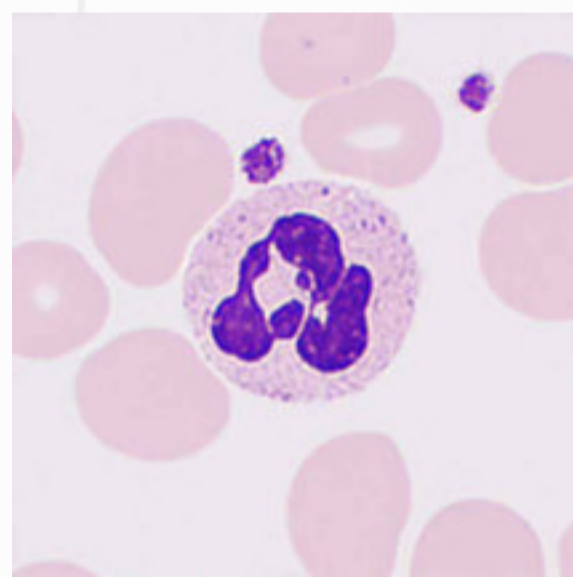
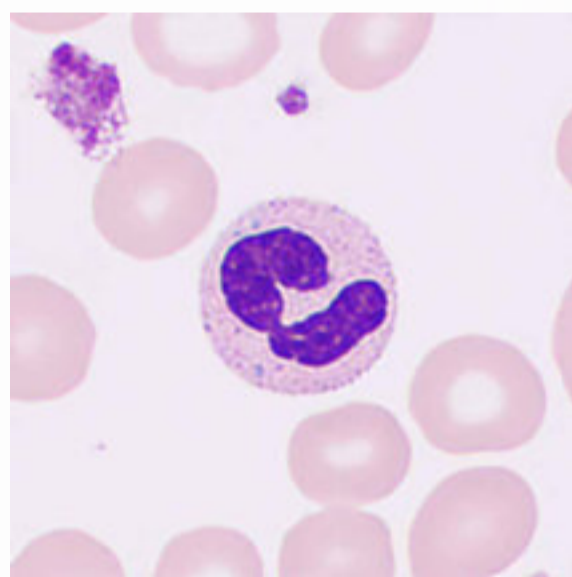
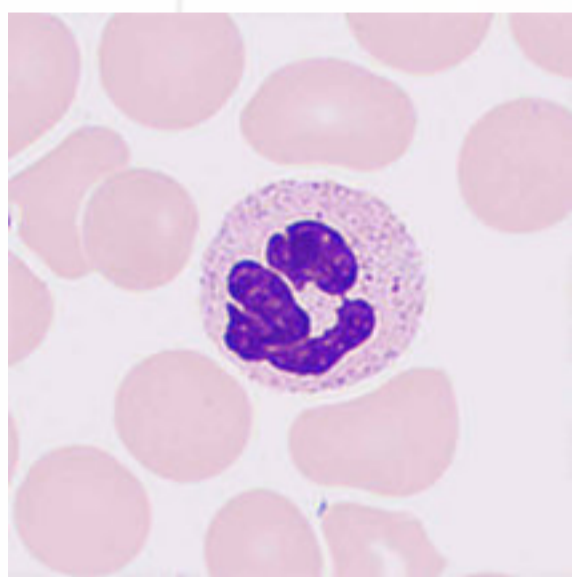
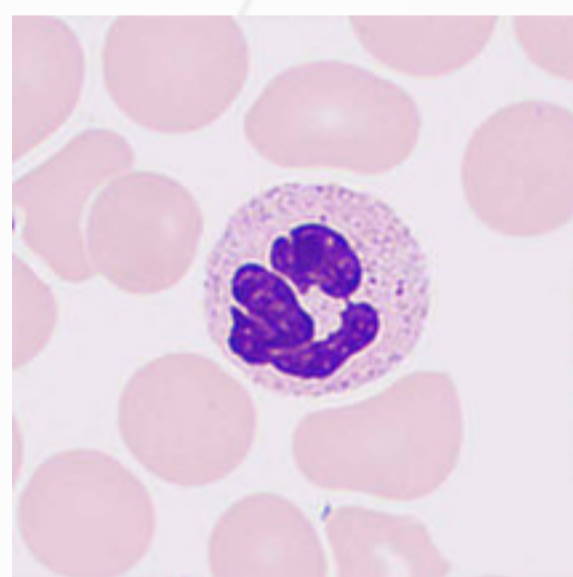
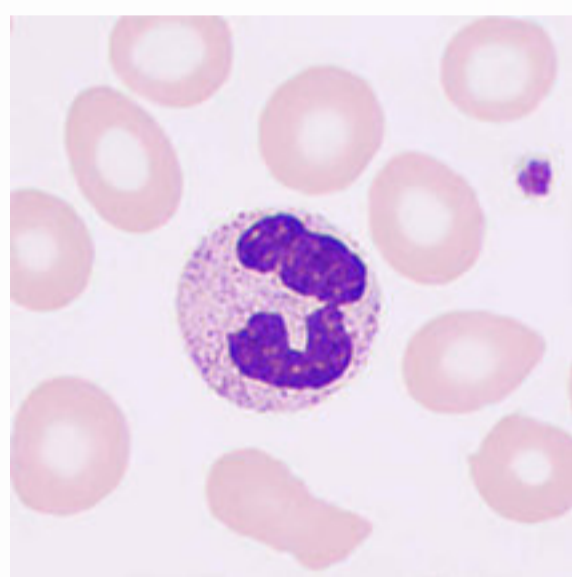
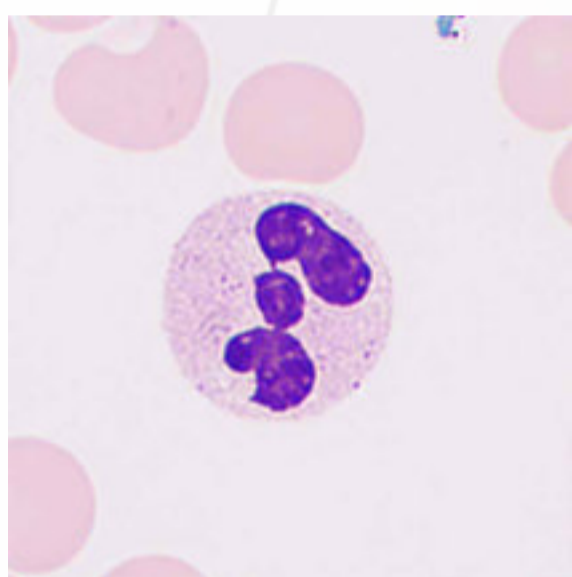


# Segmented Neutrophil Granulocytes

The cells are 10–15  $\mu\text{m}$  in diameter with a lobulated nucleus divided into 2–5 lobes (with 3-lobe nuclei accounting for 40–50%), having deep violet coarse nuclear chromatin with abundant cytoplasm that contains a large number of light pink, small, and uniform neutral granules.



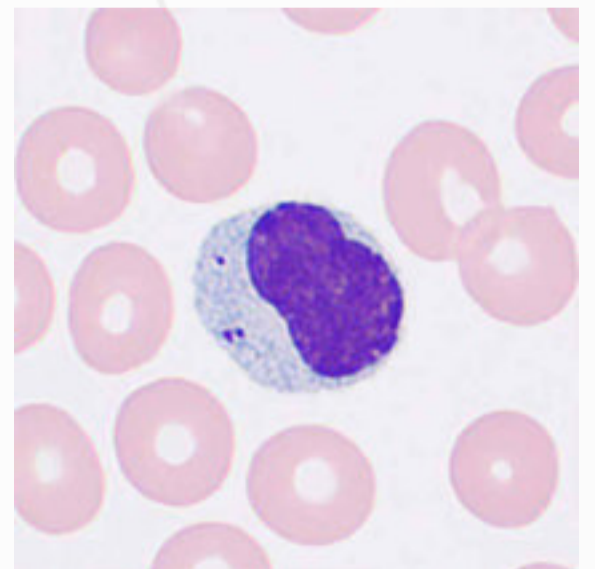
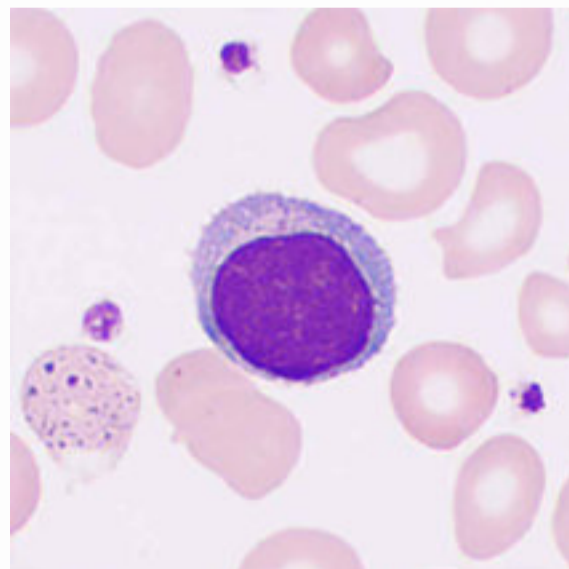
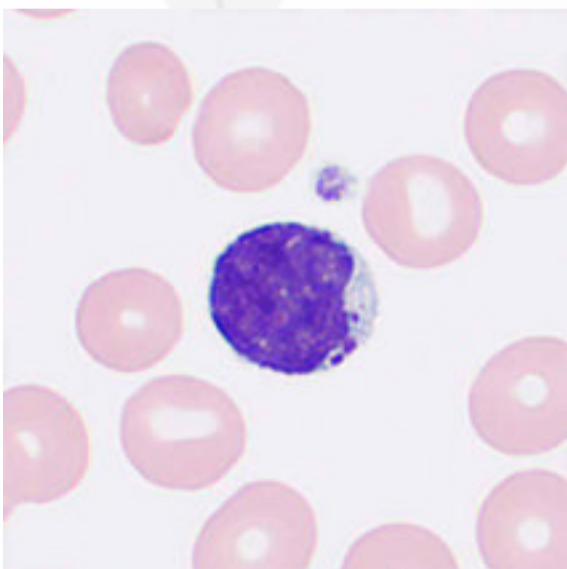
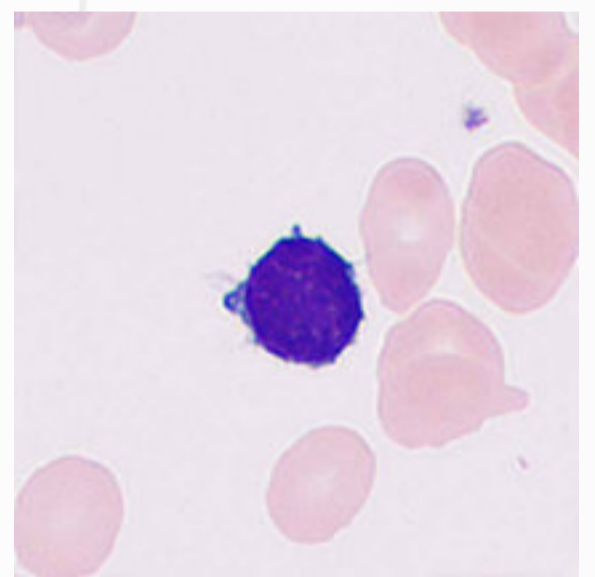
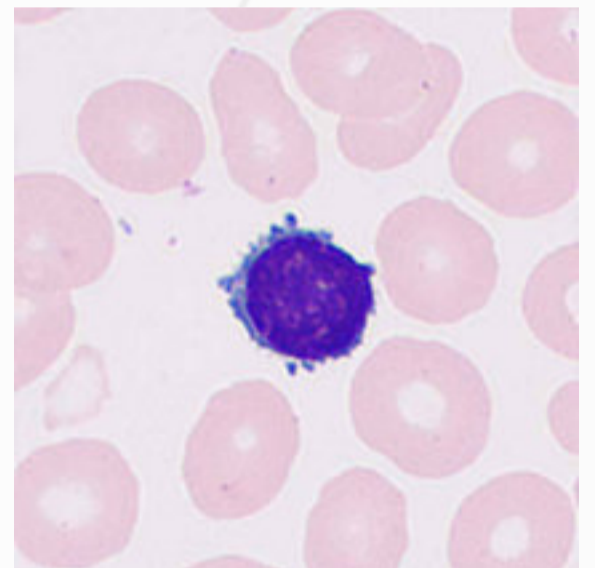
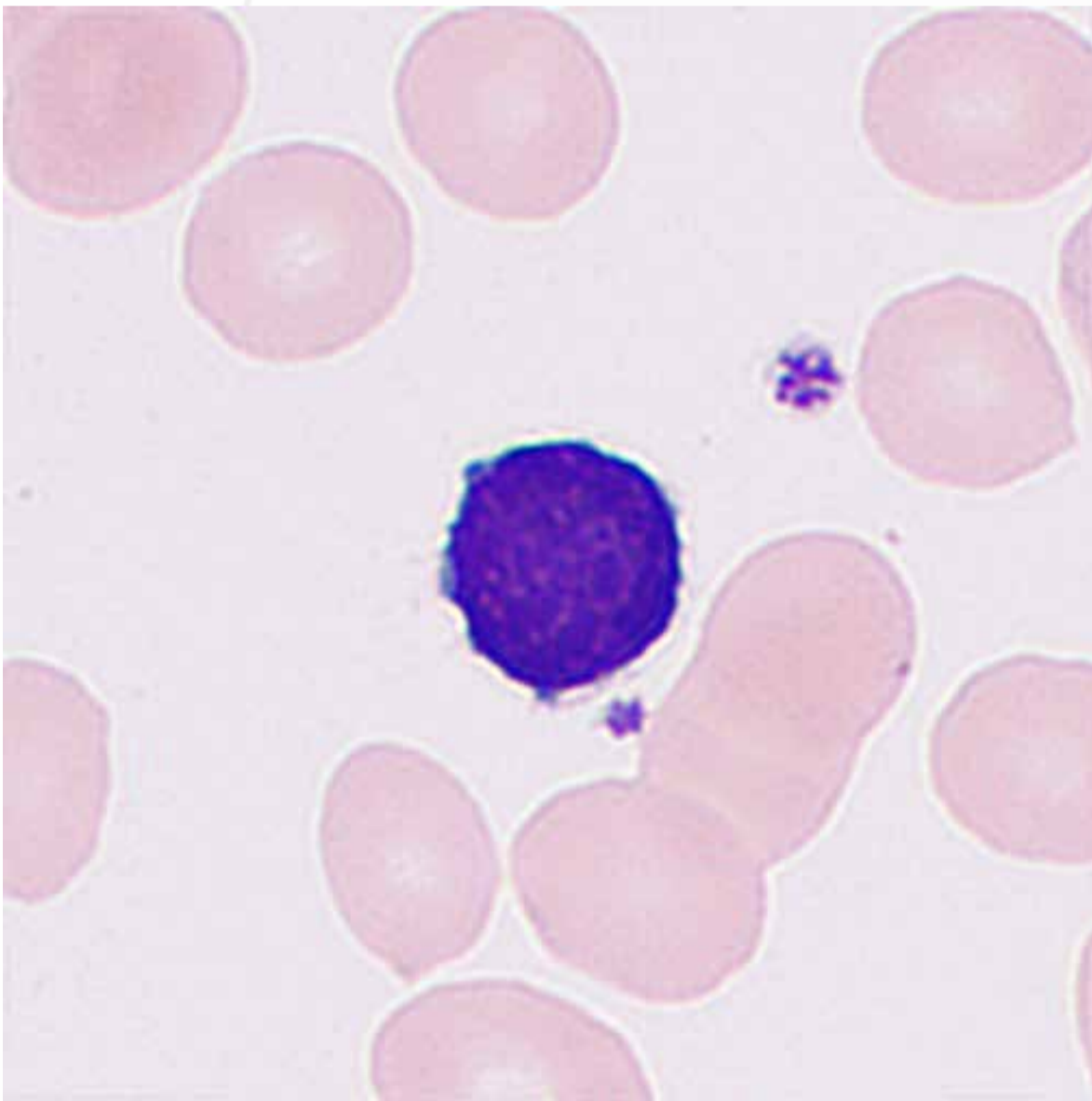
Increased neutrophil count with >3% neutrophils containing 5 or more nuclear lobes in peripheral blood is referred to as a "right shift", commonly observed in patients with nutritional megaloblastic anemia, under anti-metabolic drug treatments, or during recovery from inflammations. A severe right shift of nuclei is often accompanied by a decreased total white blood cell count, suggesting a decline in bone marrow hematopoietic function.

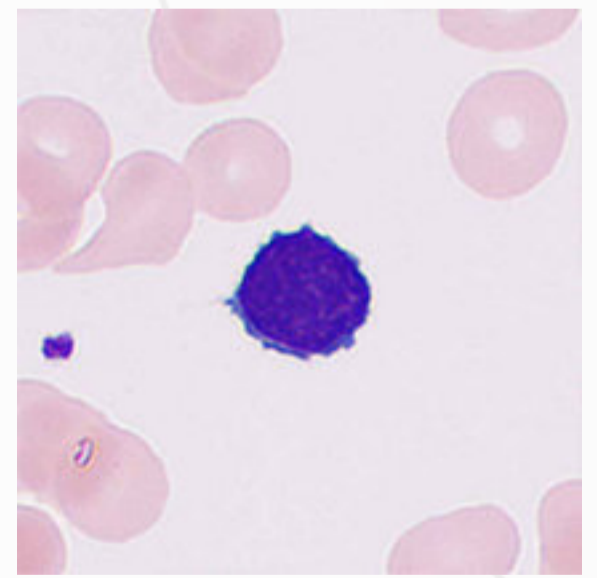
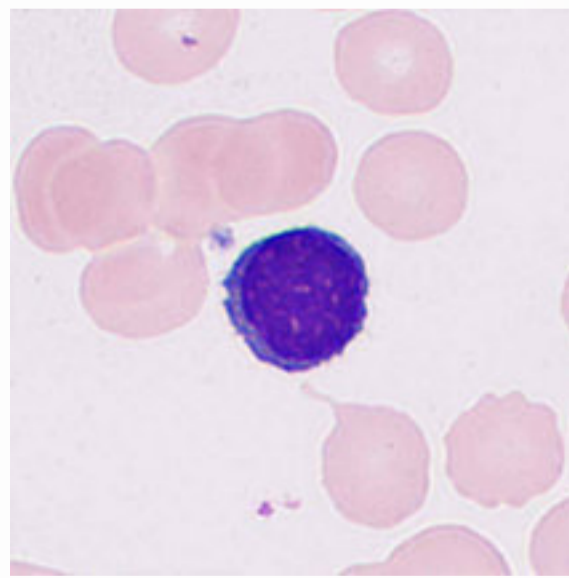
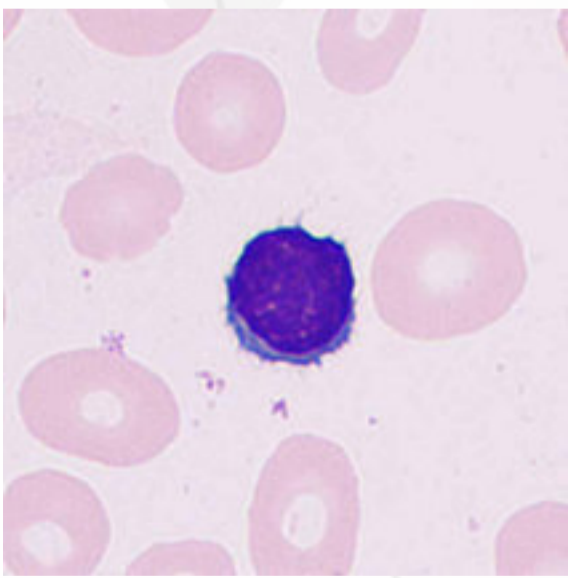
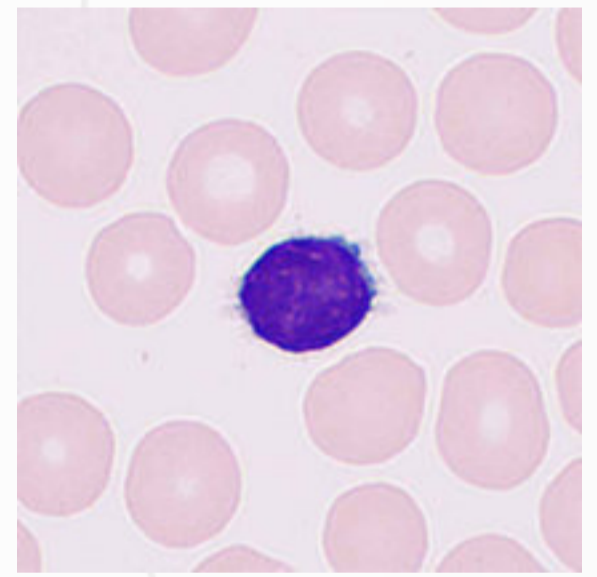
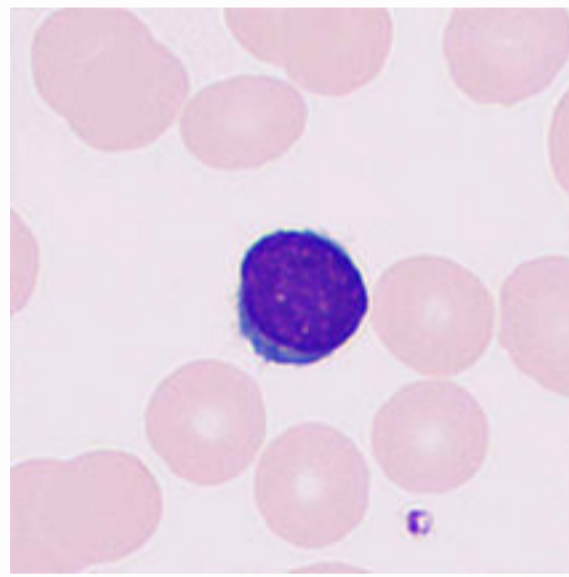
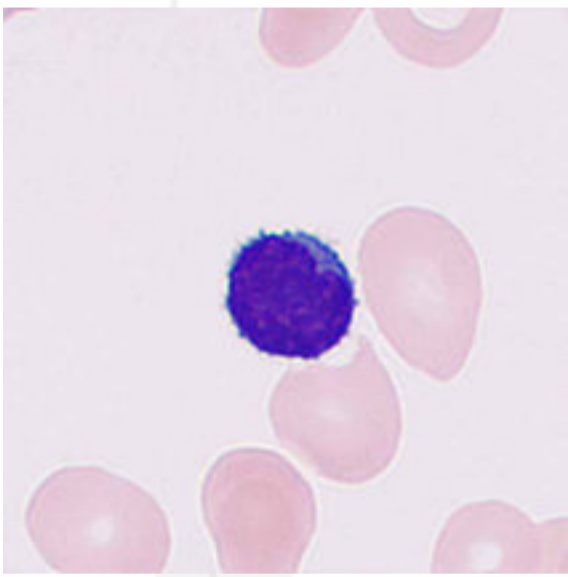
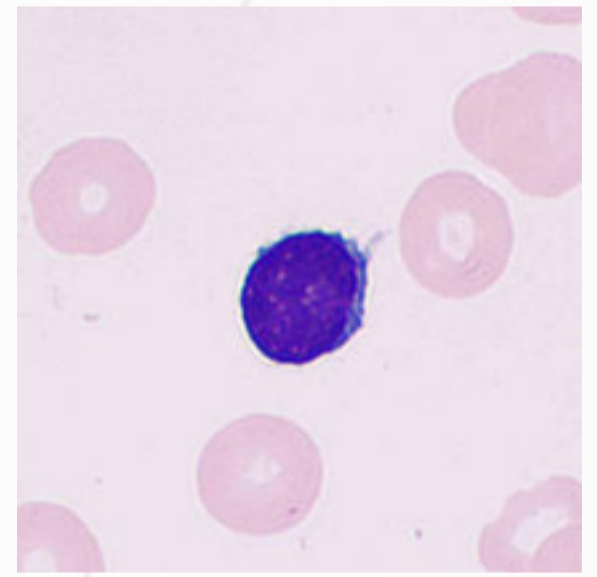
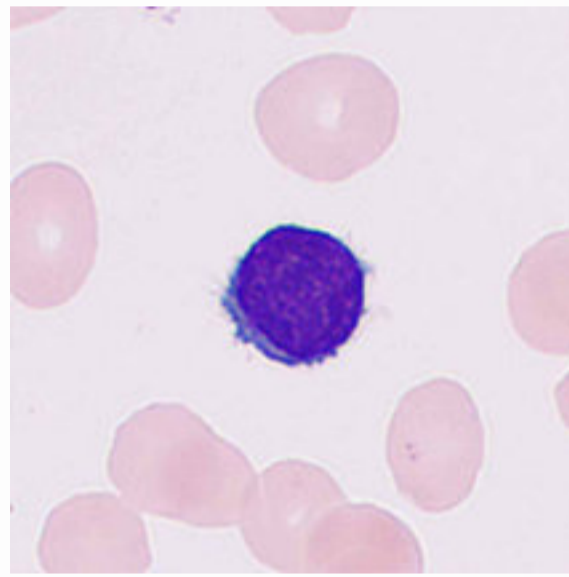
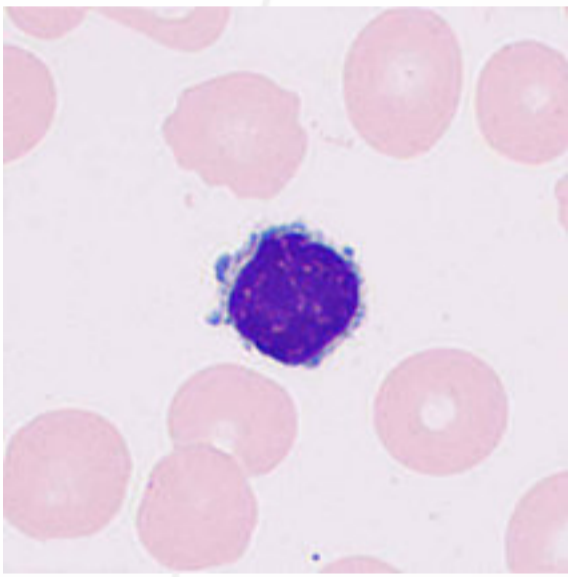




# Lymphocytes

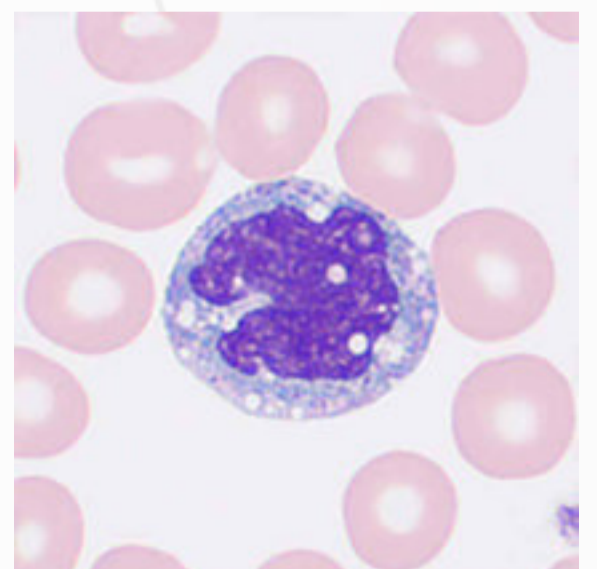
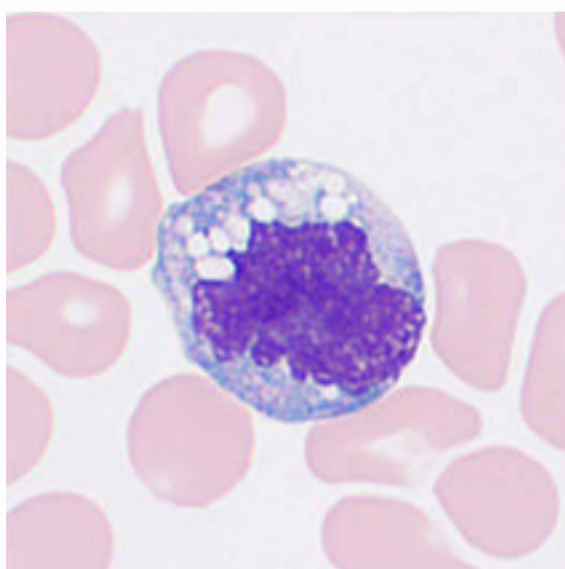
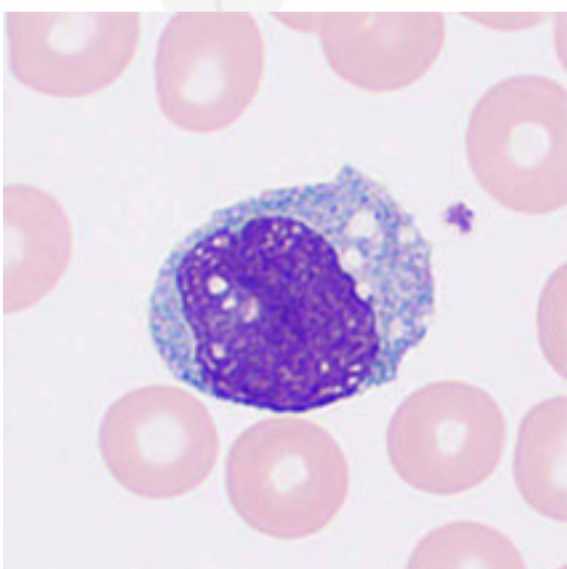
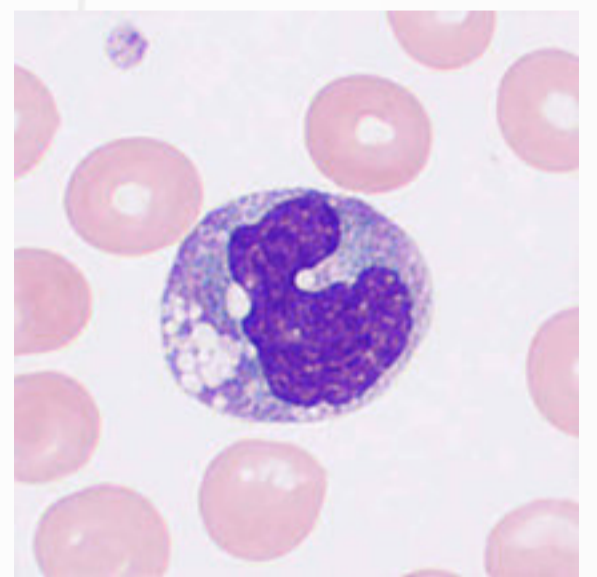
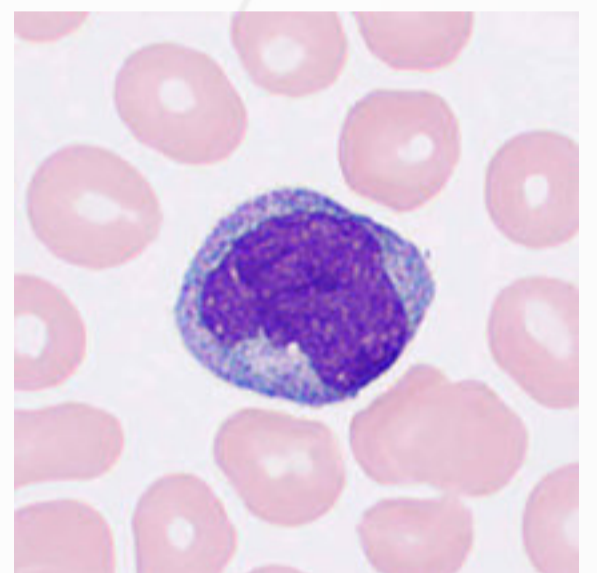
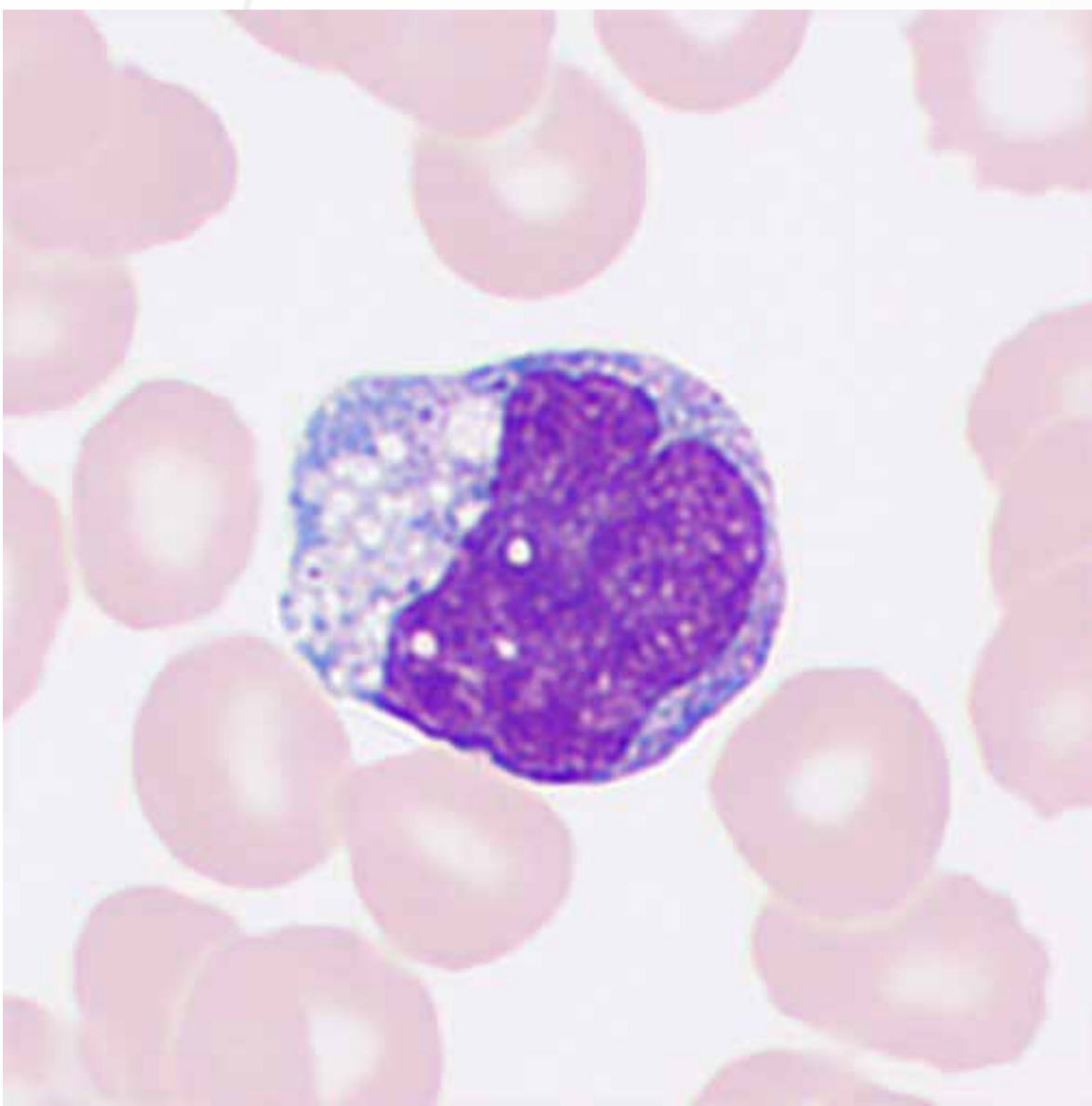
The cells vary sharply in volume, with diameters ranging from 6 to 15  $\mu\text{m}$ . A physiological increase in lymphocytes may occur in children. A pathological increase in lymphocytes is associated with certain infectious diseases induced by viruses or bacteria, such as mumps or infectious mononucleosis, chronic infections during recovery from tuberculosis, and acute and chronic lymphocytic leukemia.



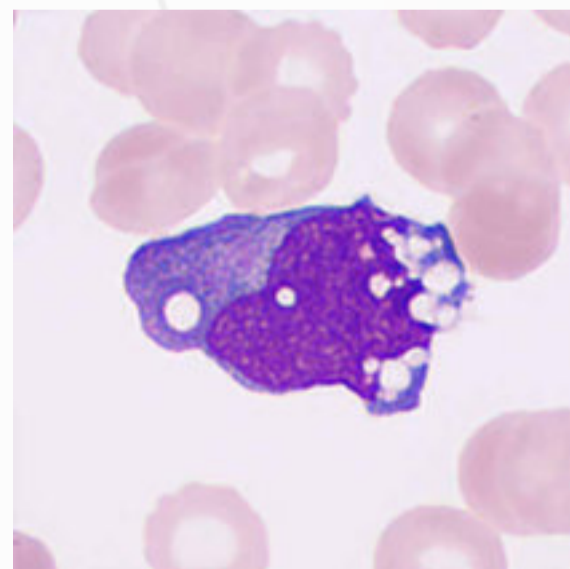
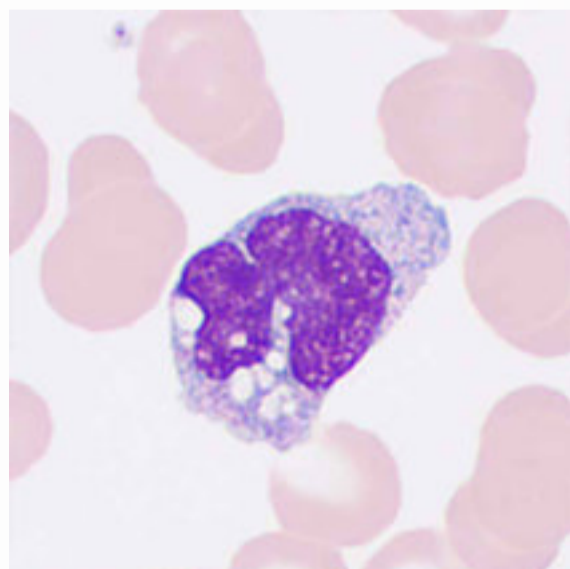
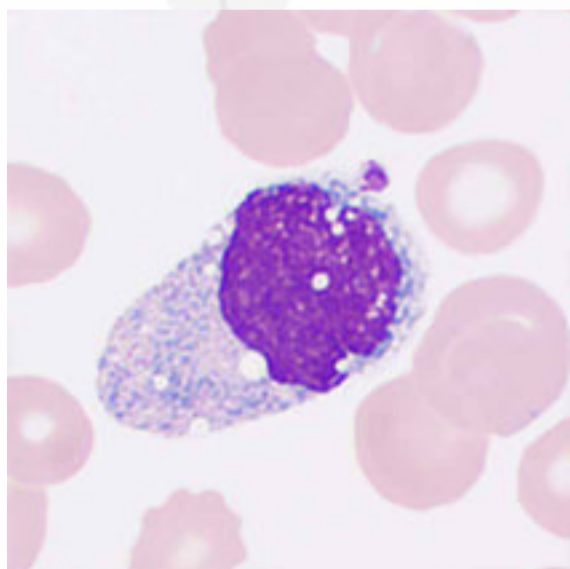
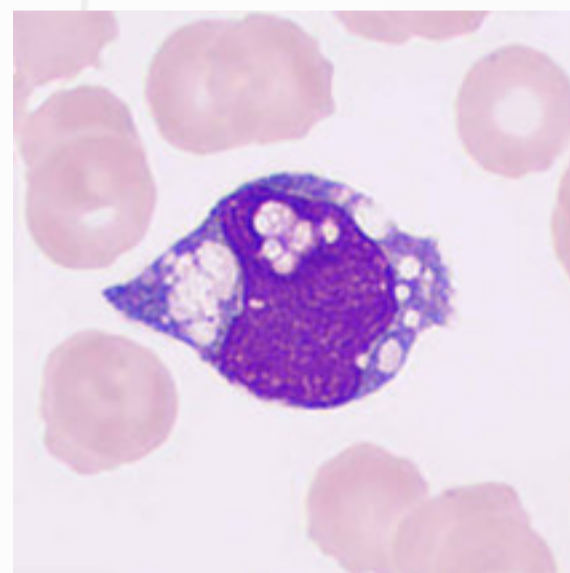
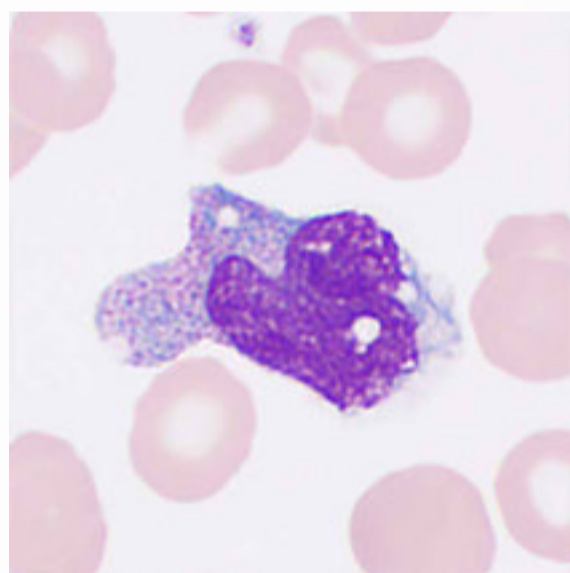
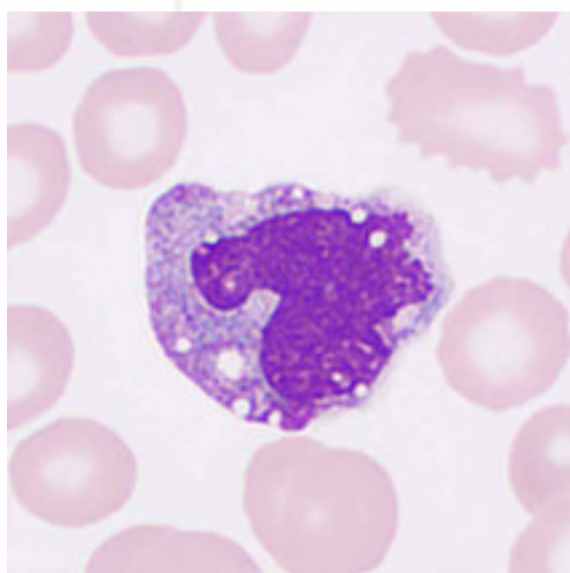
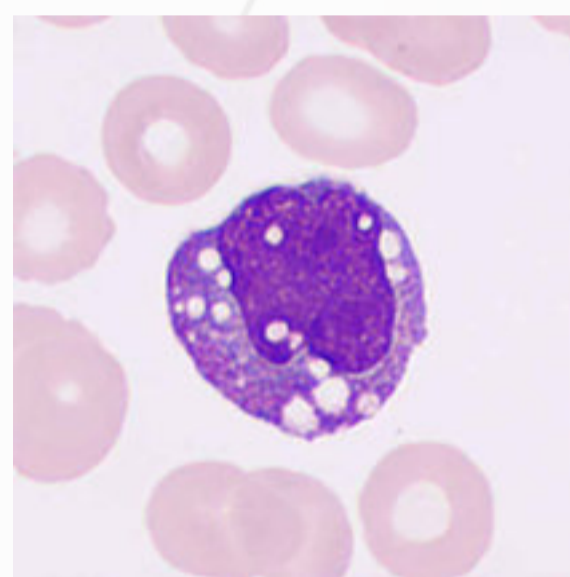
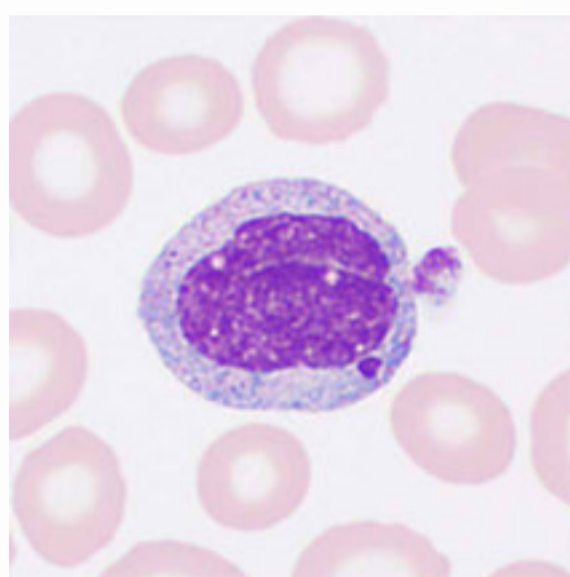
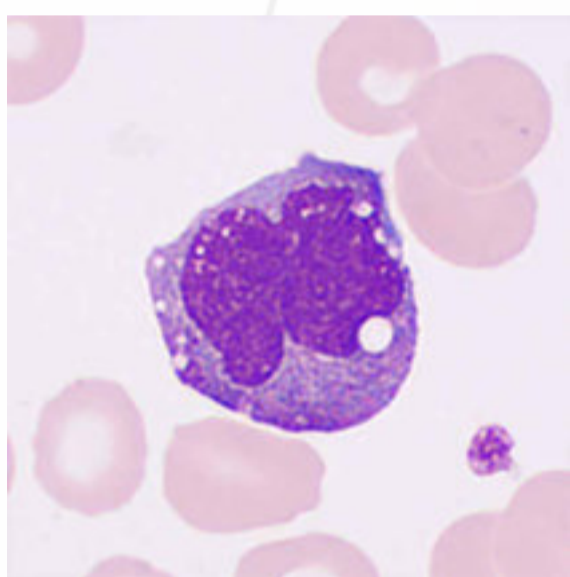


# Monocytes

Monocytes are large cells approximately 12–20  $\mu\text{m}$  in diameter. They are typically round, oval, or irregular in shape, with or without pseudopods. The nucleus is twisted or irregularly folded and sometimes shaped like a kidney, mountain, or horseshoe. The nucleus chromatin is loose and reticulate and stained light violet-red. The cytoplasm is gray-blue or gray-red, translucent, commonly vacuolated, and contains small, dust-like violet-red granules.

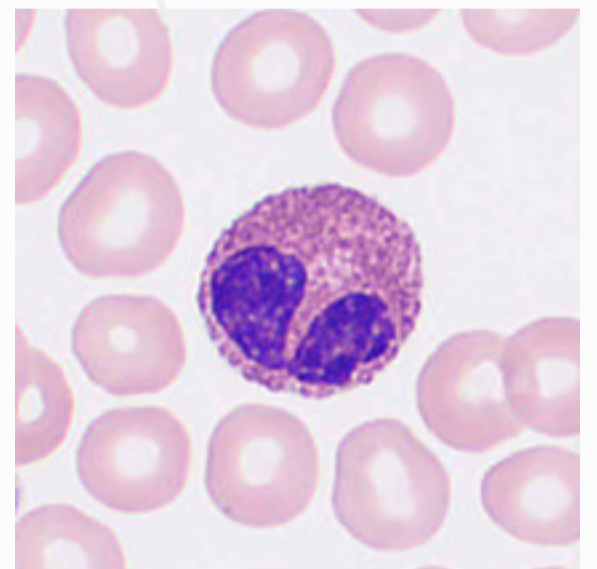
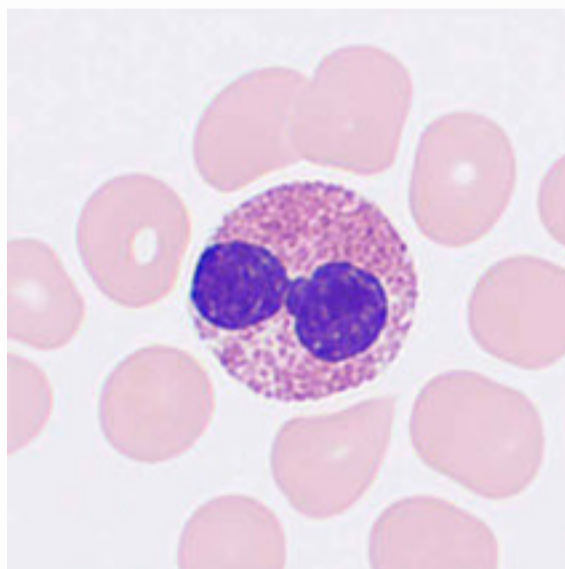
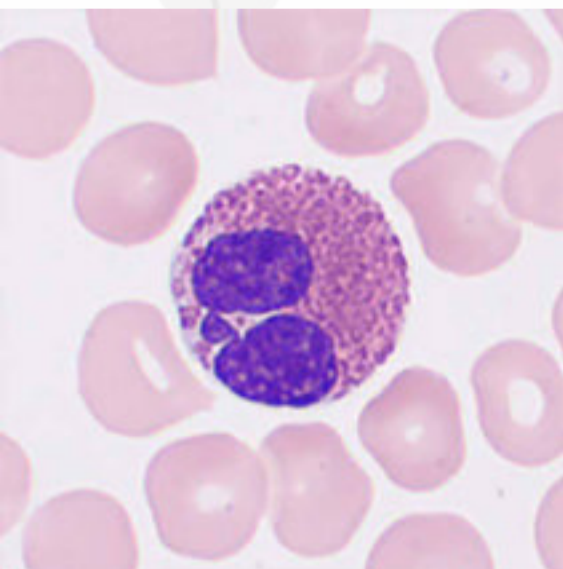
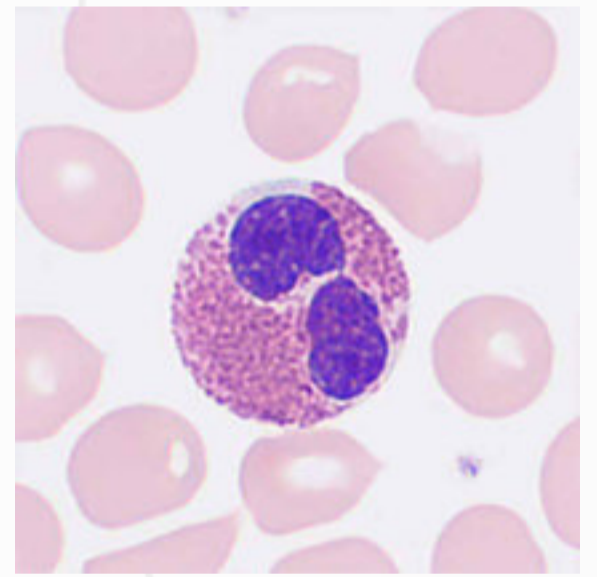
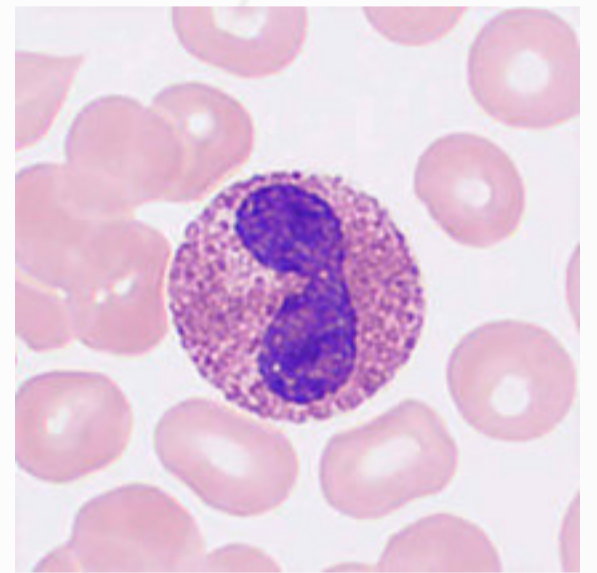
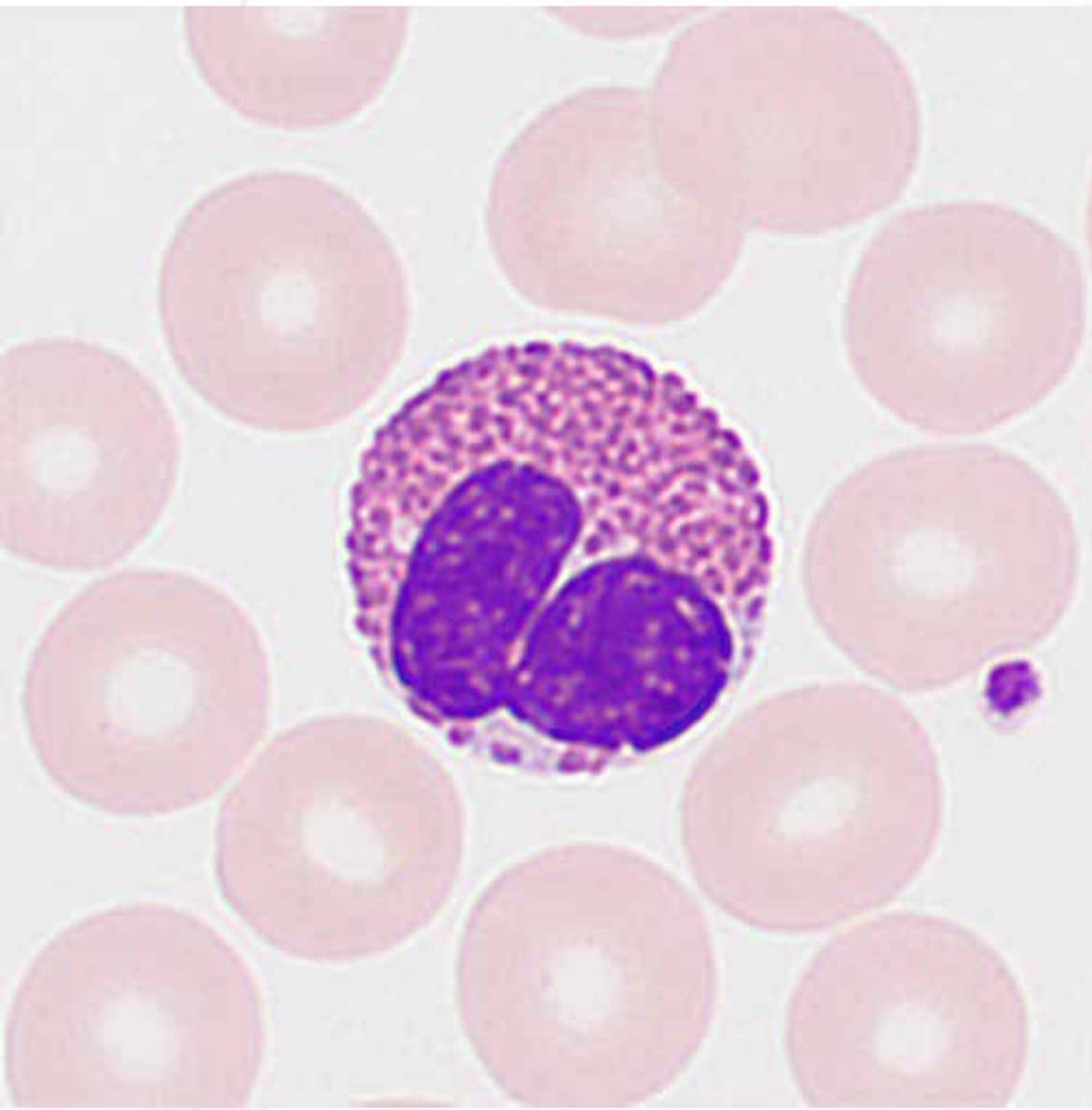


A pathological increase in monocytes may be observed in infectious diseases such as subacute infective endocarditis, malaria, and Kala-azar (visceral leishmaniasis). It could also occur in the recovery phase of acute infections and certain hematological diseases, such as the recovery phase of agranulocytosis, monocytic leukemia, and MDS.

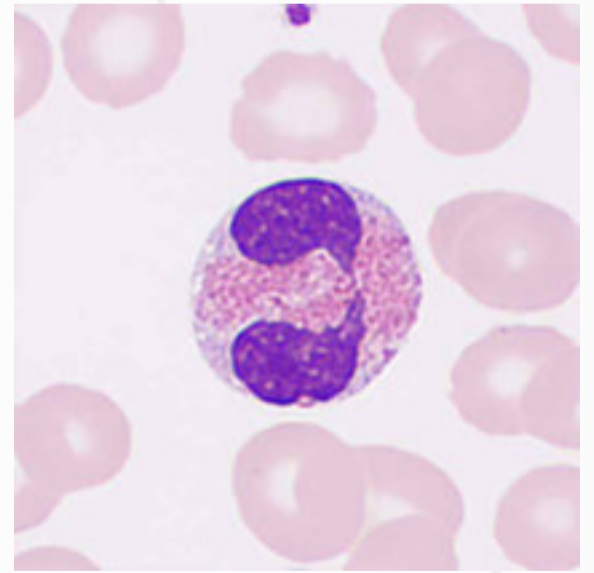
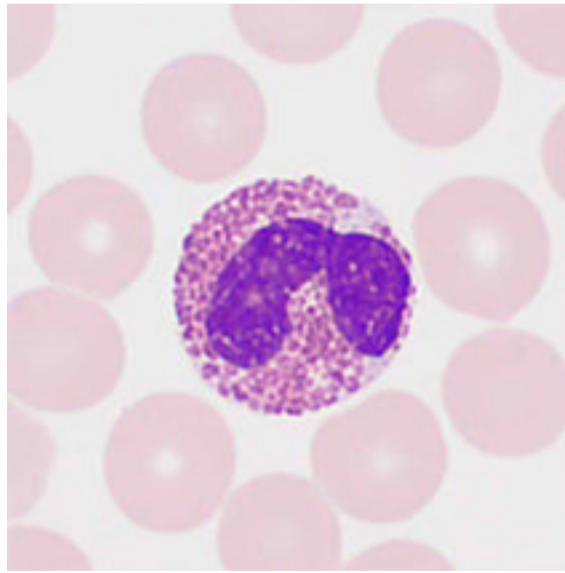
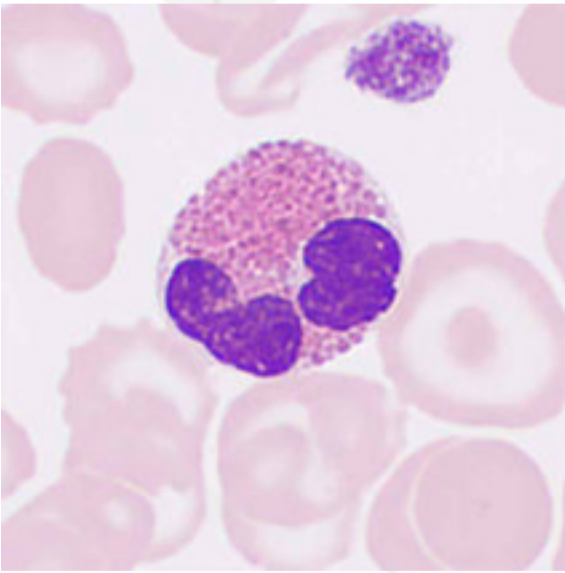
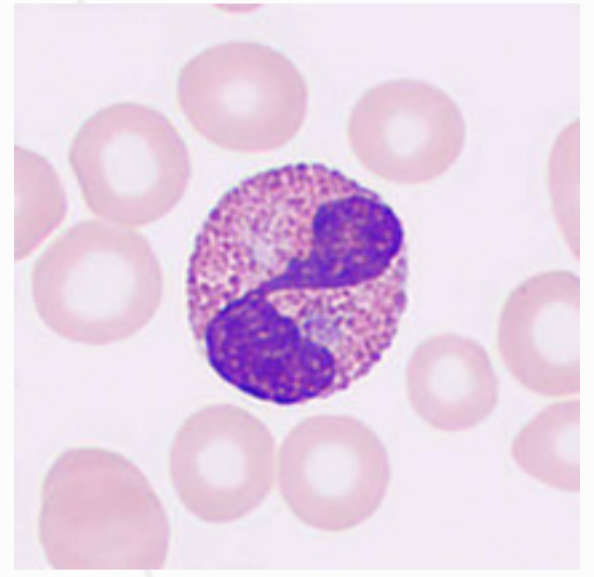
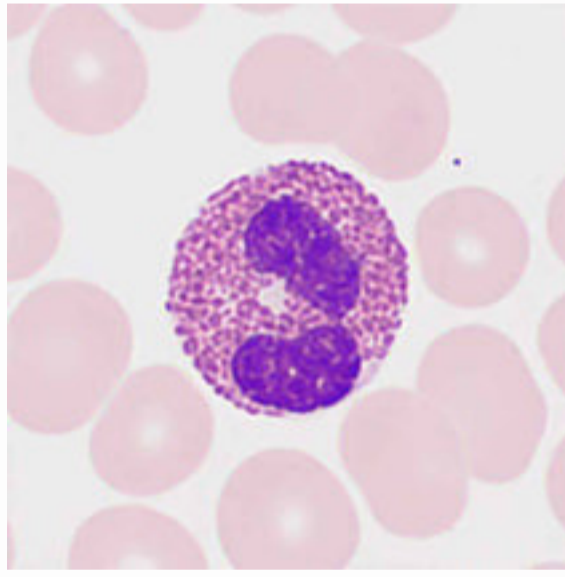
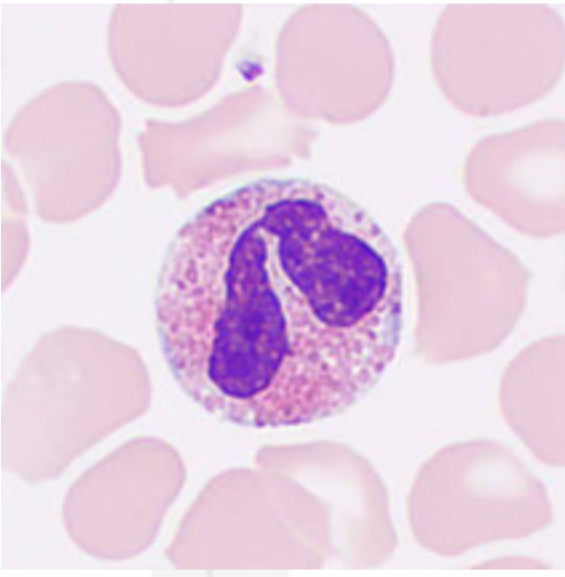
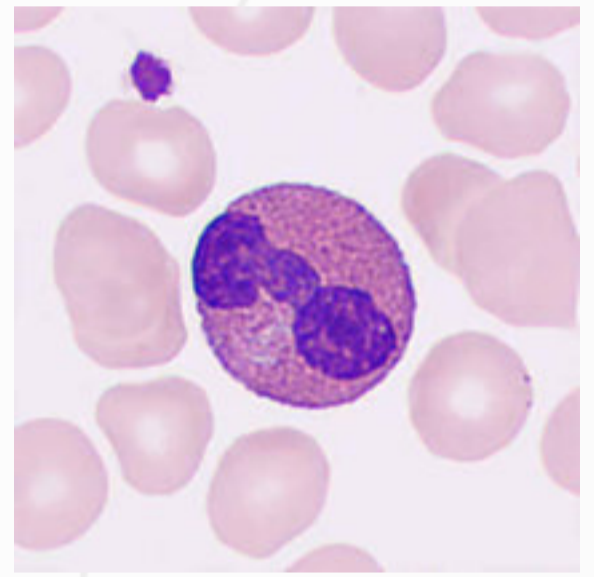
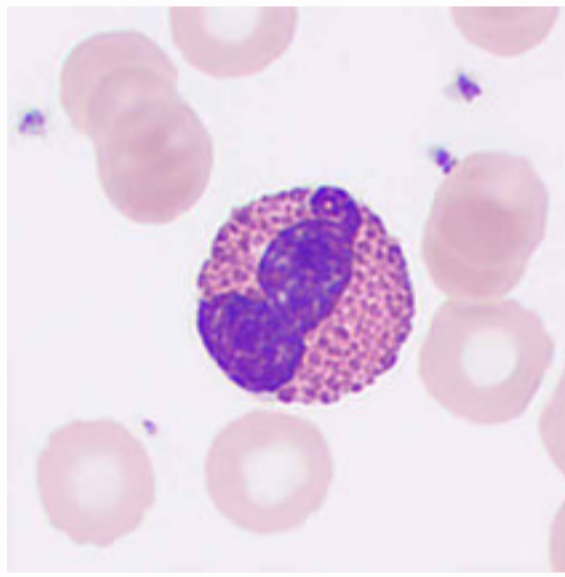
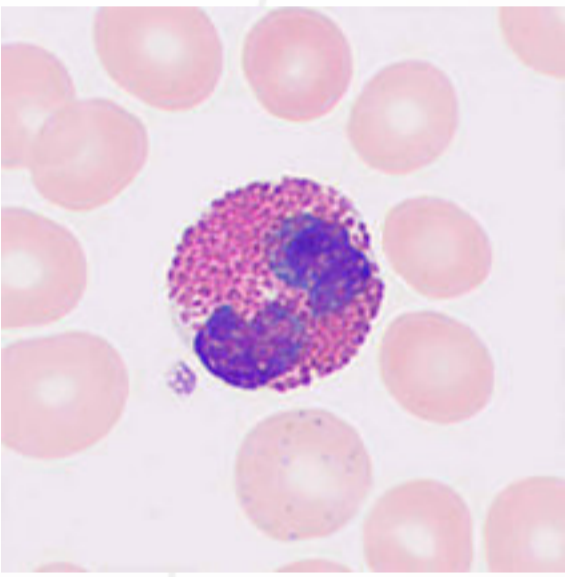


# Eosinophils

The cells are 13–15  $\mu\text{m}$  in diameter, typically round, with a glasses-shaped 2-lobe nucleus and coarse and deep violet-red chromatin. The cytoplasm is stained lightly and filled with coarse and neatly arranged orange granules, which contain a variety of enzymes such as peroxidase, phospholipase D, catalase, and acid phosphatase.

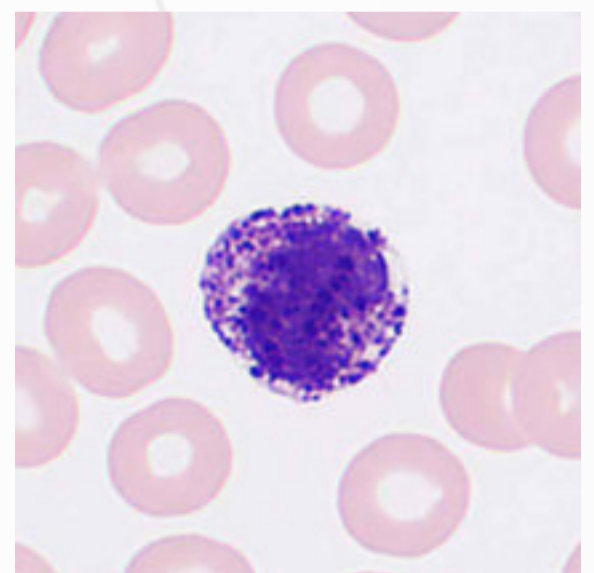
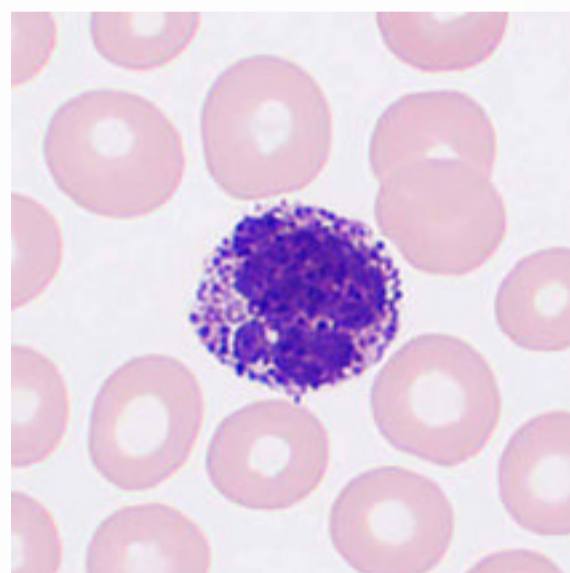
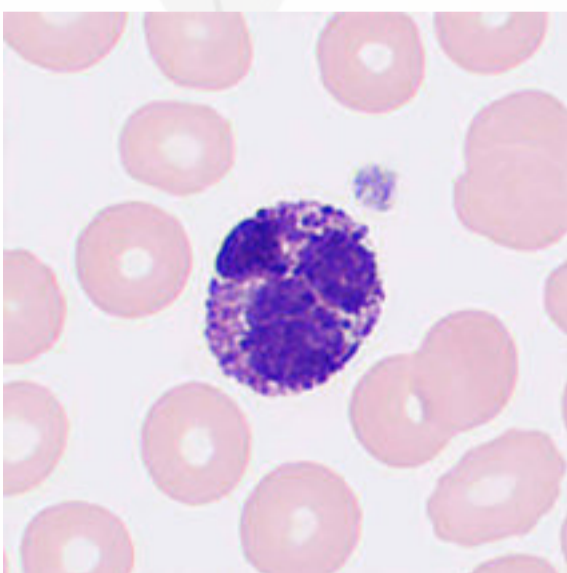
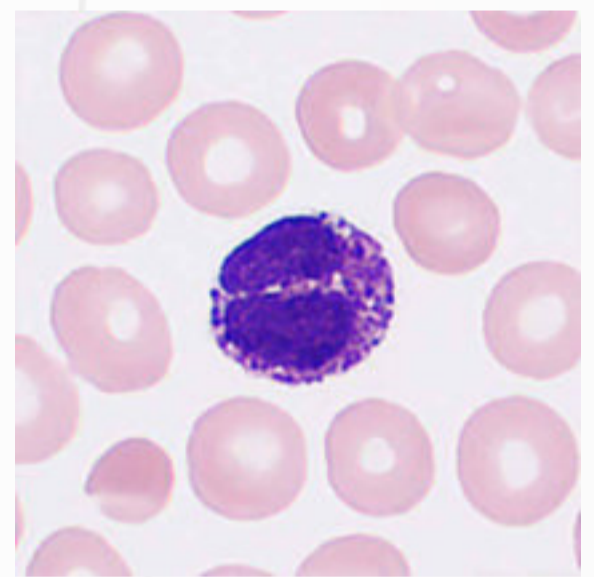
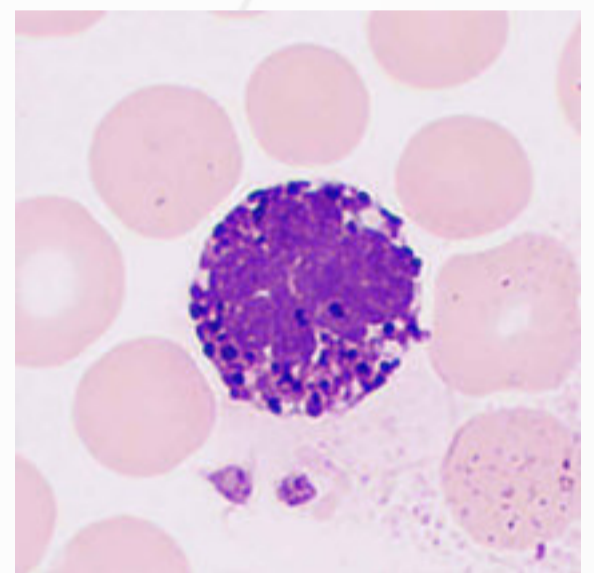
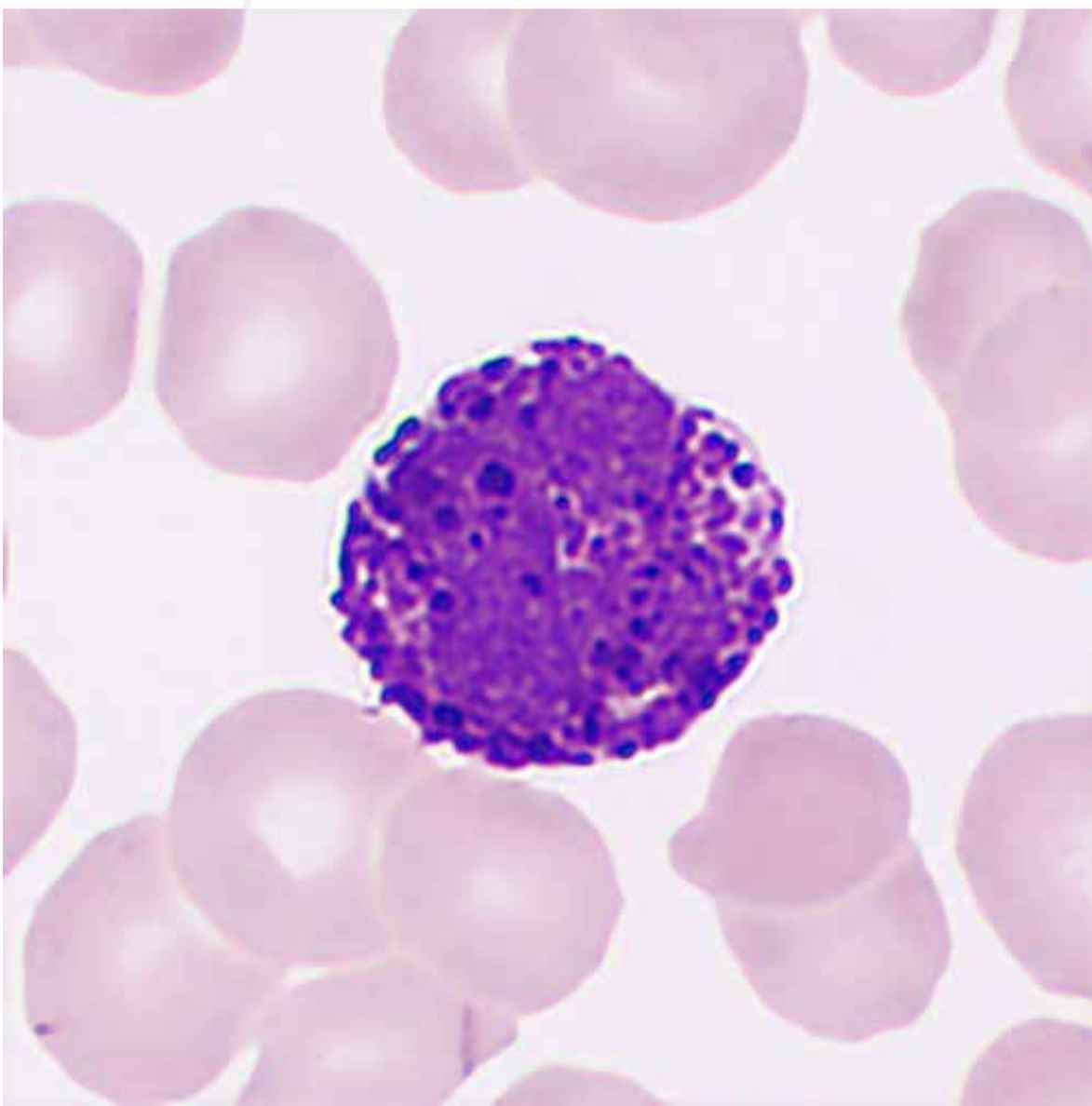


Eosinophils are less capable of killing bacteria than neutrophils, and an increase in eosinophils can be observed in parasitic infections and certain types of allergies.

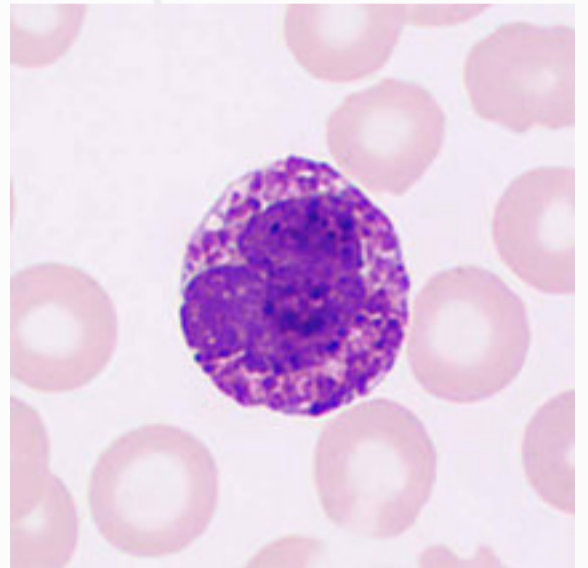
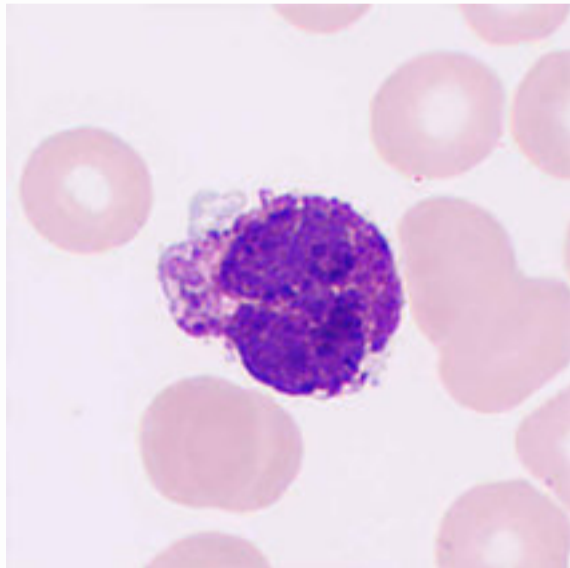
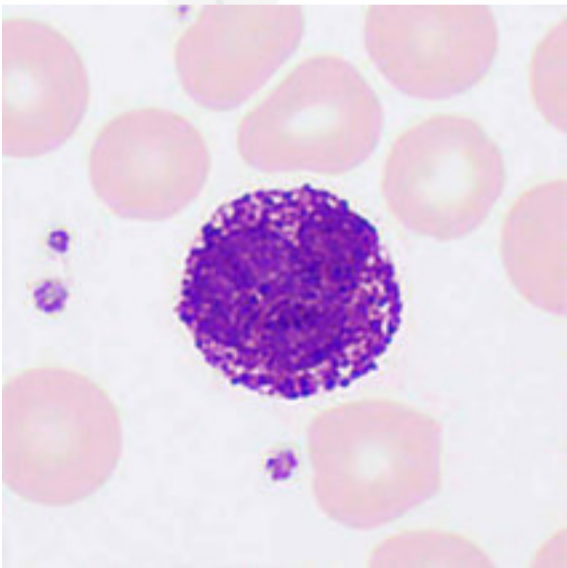
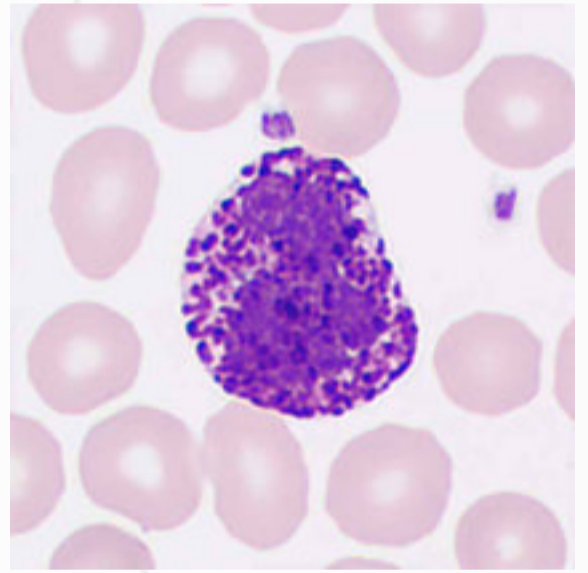
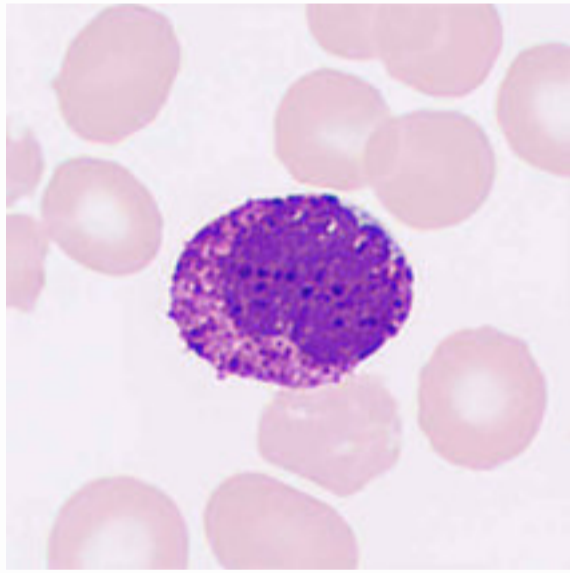
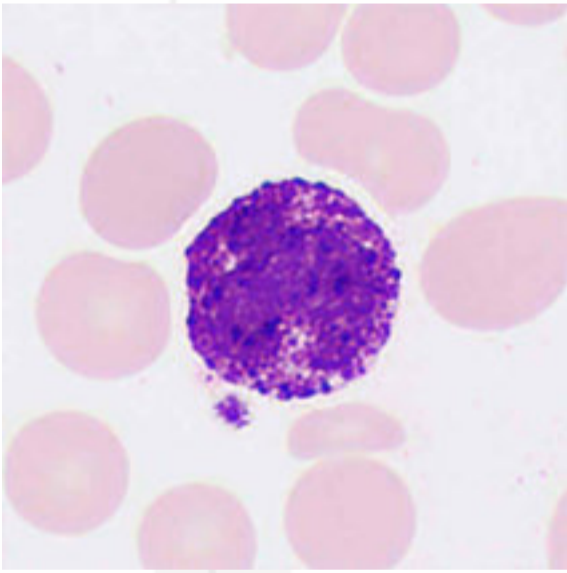
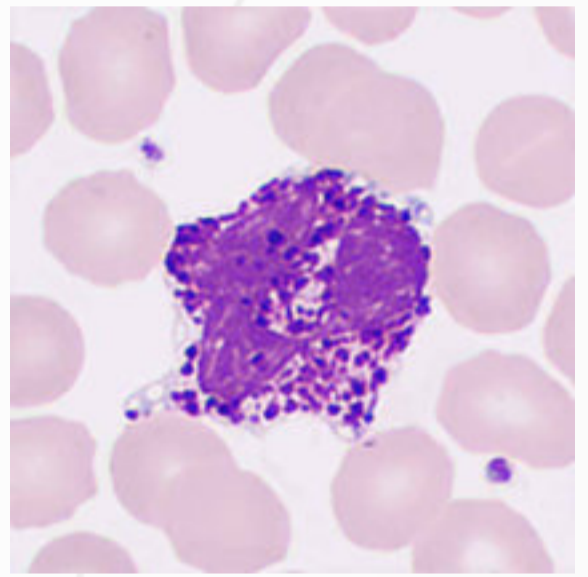
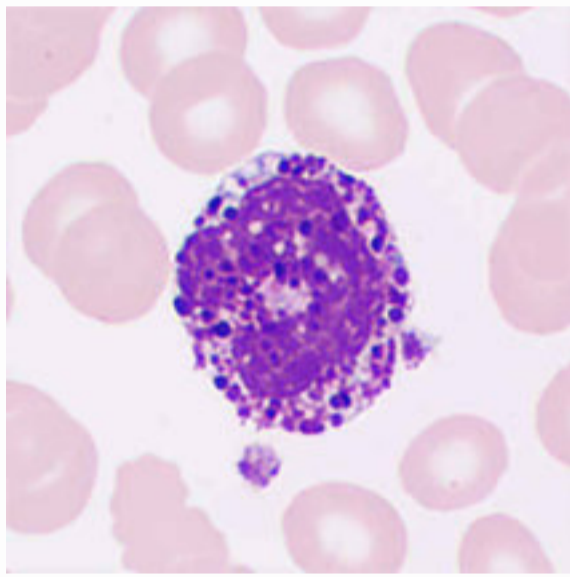
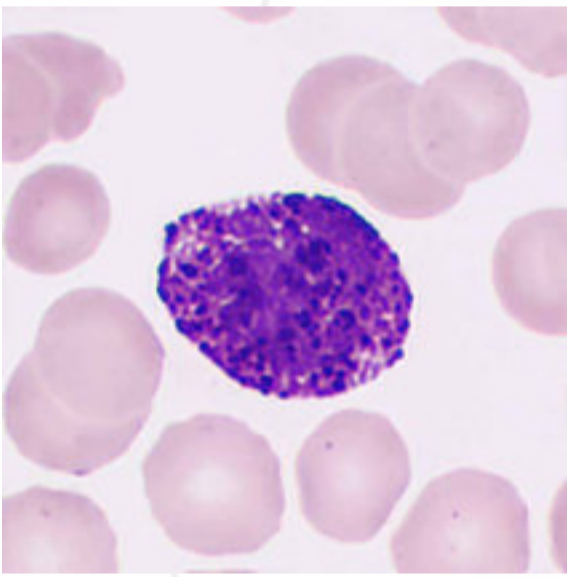


# Basophils

The cells are 10–12  $\mu\text{m}$  in diameter, typically round, and the nucleus is obscured by granules, which are violet-black, varied in sizes, and unevenly distributed in the cells. The chromatin is coarse and violet-red, and the cytoplasm is stained lightly.



An increase in basophils may occur in specific allergies, myeloproliferative disorders, and basophilic leukemia.





A microscopic view of a blood smear. The field is dominated by numerous red blood cells, which appear as uniform, pinkish-purple spheres with a lighter center. Scattered throughout are several small, dark purple platelets. A few larger, more complex cells with dark nuclei are also visible, likely white blood cells.

## Red Blood Cells and Platelets

**Red blood cells:** Normal red blood cells are biconcave disc-shaped, relatively uniform in size, with an average diameter of  $7.2\ \mu\text{m}$  ( $6.7\text{--}7.7\ \mu\text{m}$ ). They turn pink after Wright's staining, with the central lightly stained area accounting for about  $1/3$  of the volume, and no abnormal structures in the cytoplasm. Although normal red blood cell shapes are typically seen in healthy individuals, they are also visible in acute hemorrhagic anemia and some cases of aplastic anemia.

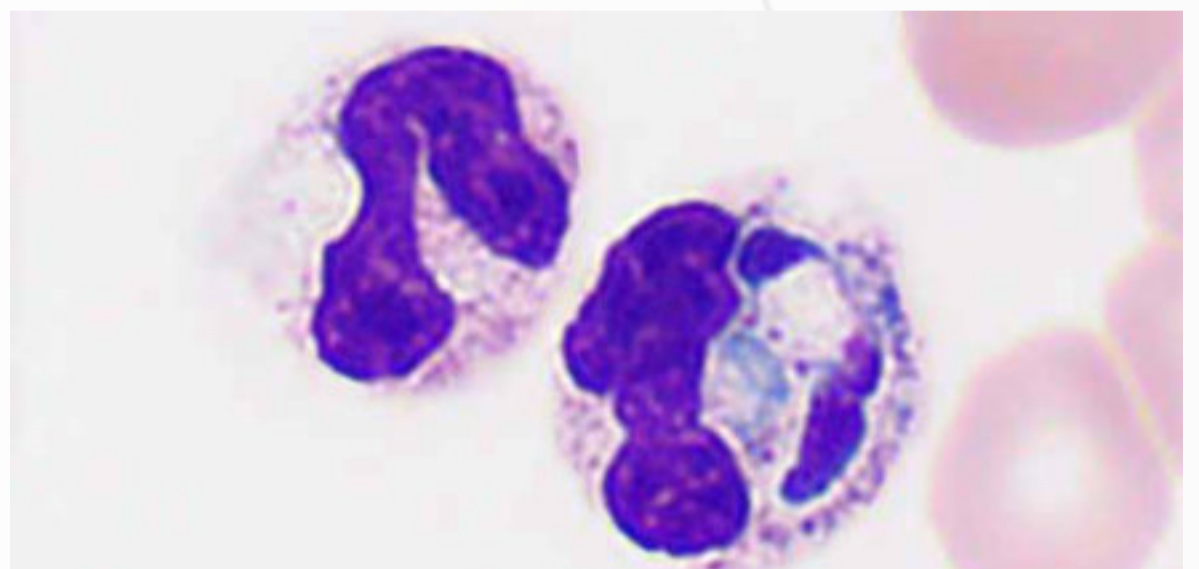
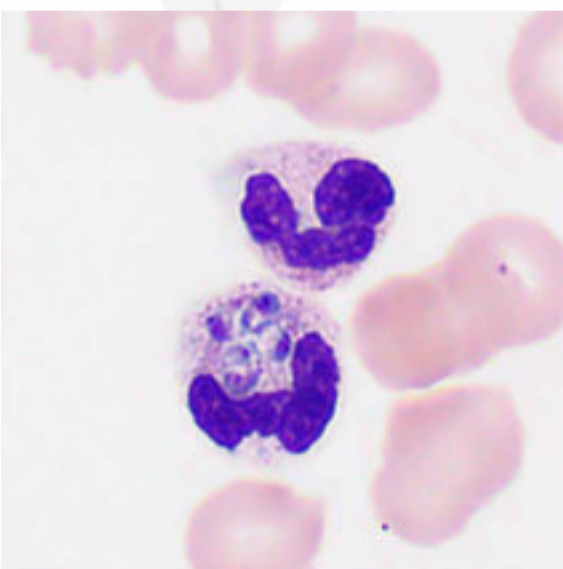
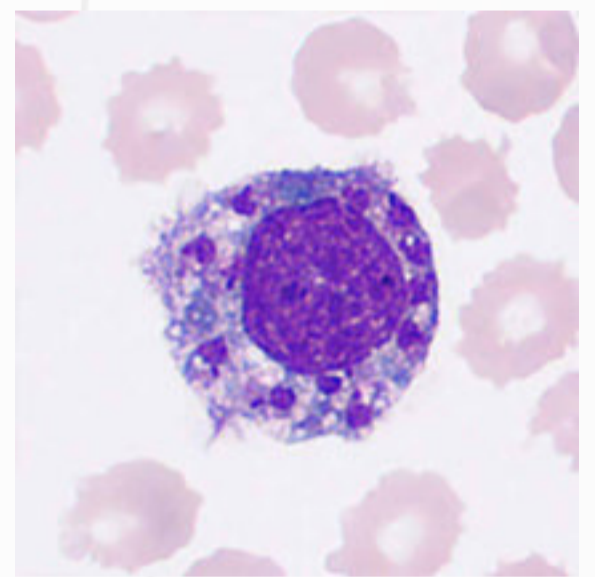
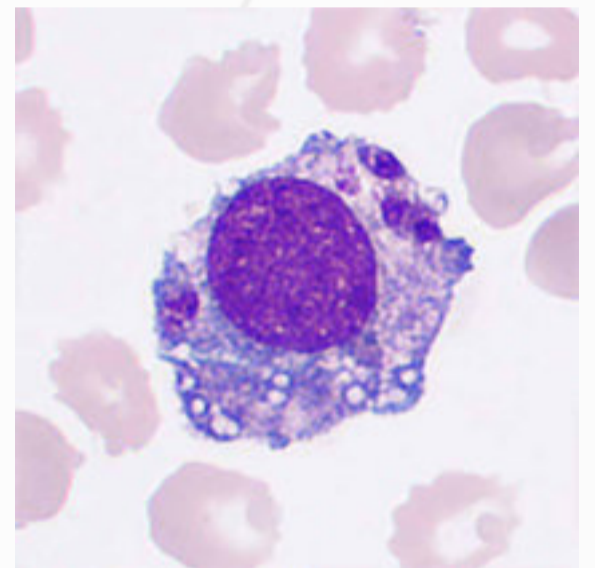
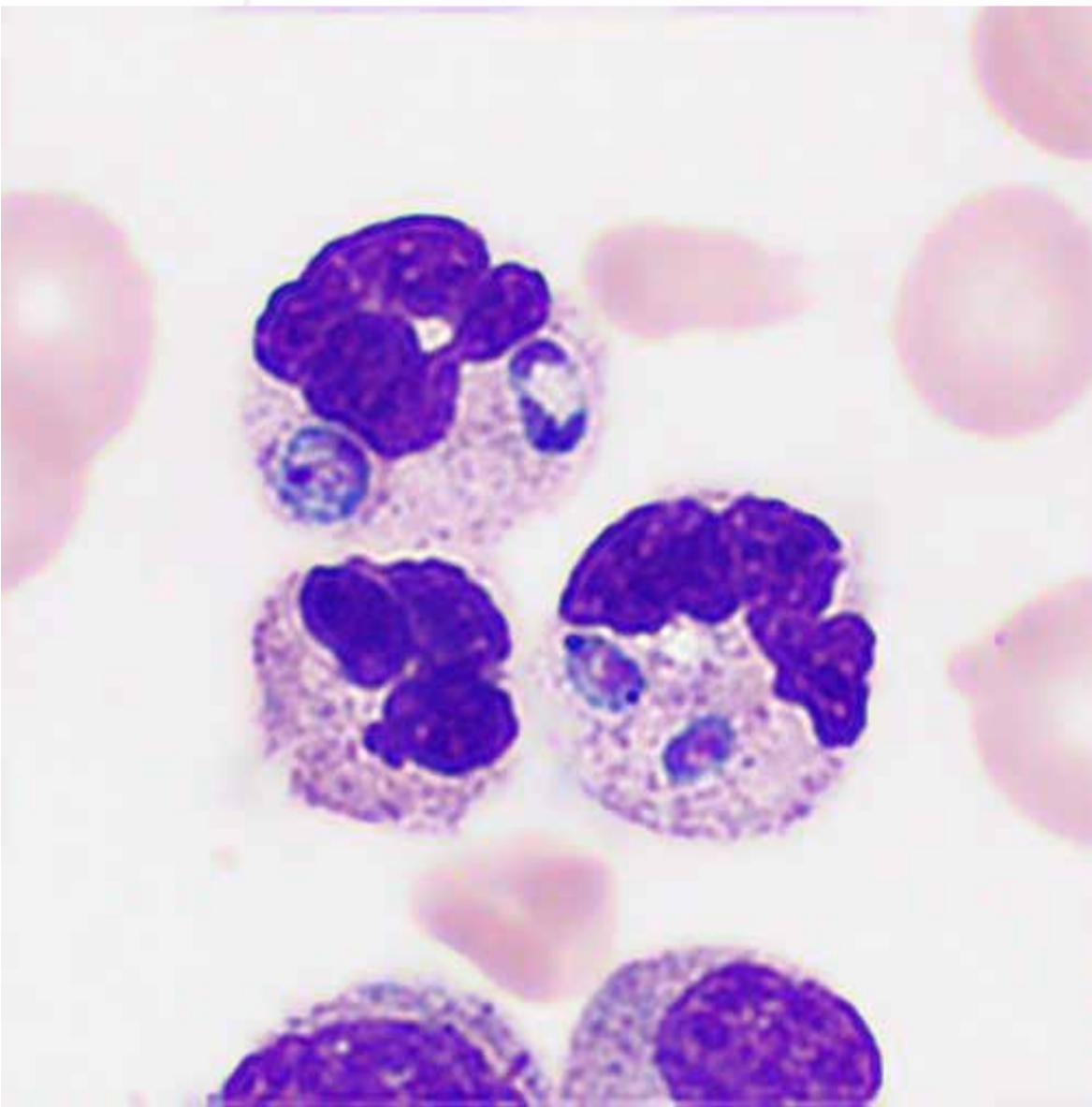
**Platelets:** Normal platelets are about  $1.5\text{--}3\ \mu\text{m}$  in diameter. They come with a slightly biconvex discoid structure, mostly round, oval, or slightly regular, containing no nucleus. Tiny violet-red granules are evenly distributed and clustered or dispersed in the cytoplasm, which is usually light blue or light pink. Platelets are produced by megakaryocytes in the bone marrow hematopoietic tissue and have functions such as maintaining endothelial cell integrity, aggregation, adhesion, release, procoagulation, and clot retraction.

An abstract graphic design featuring three grey circles of varying sizes and two thin, curved grey lines. The circles are positioned at approximately (420, 170), (150, 670), and (780, 730) in a 1000x1000 coordinate system. The lines are smooth, sweeping curves that intersect the circles and each other, creating a sense of movement and flow. The overall aesthetic is clean and modern.

# **Abnormal Peripheral Blood Cells**

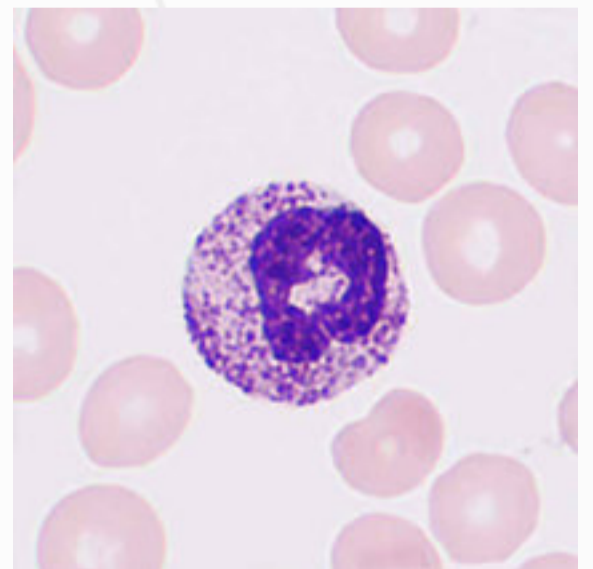
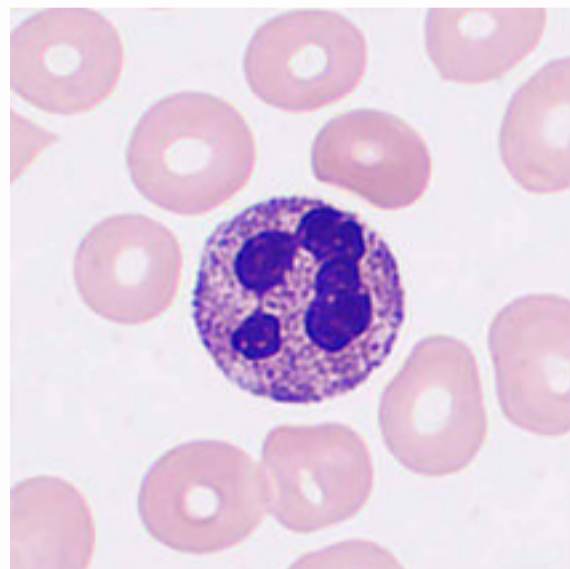
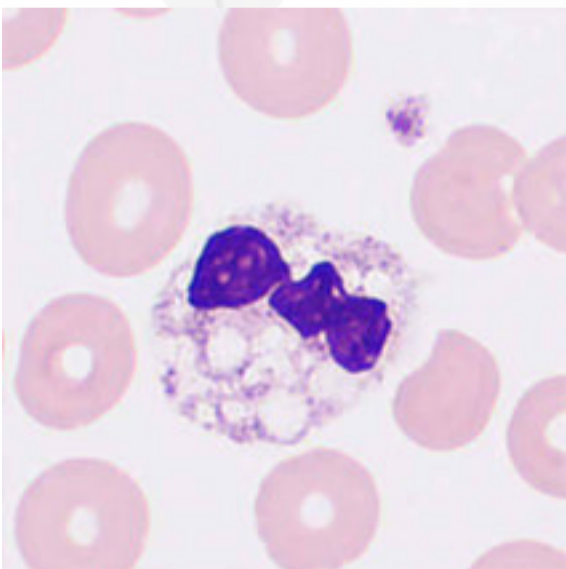
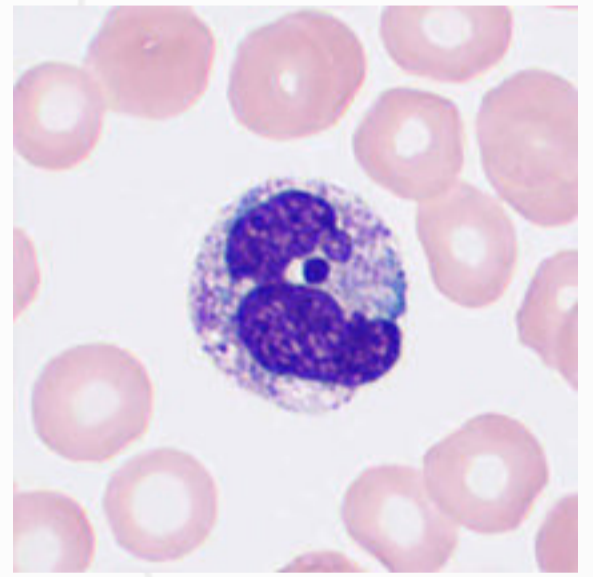
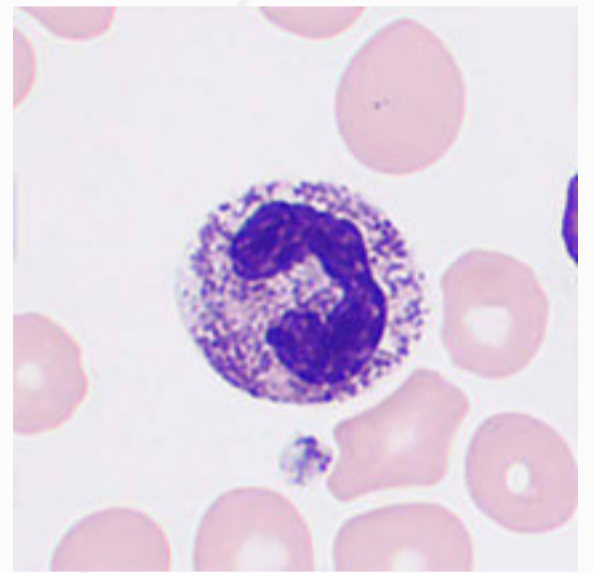
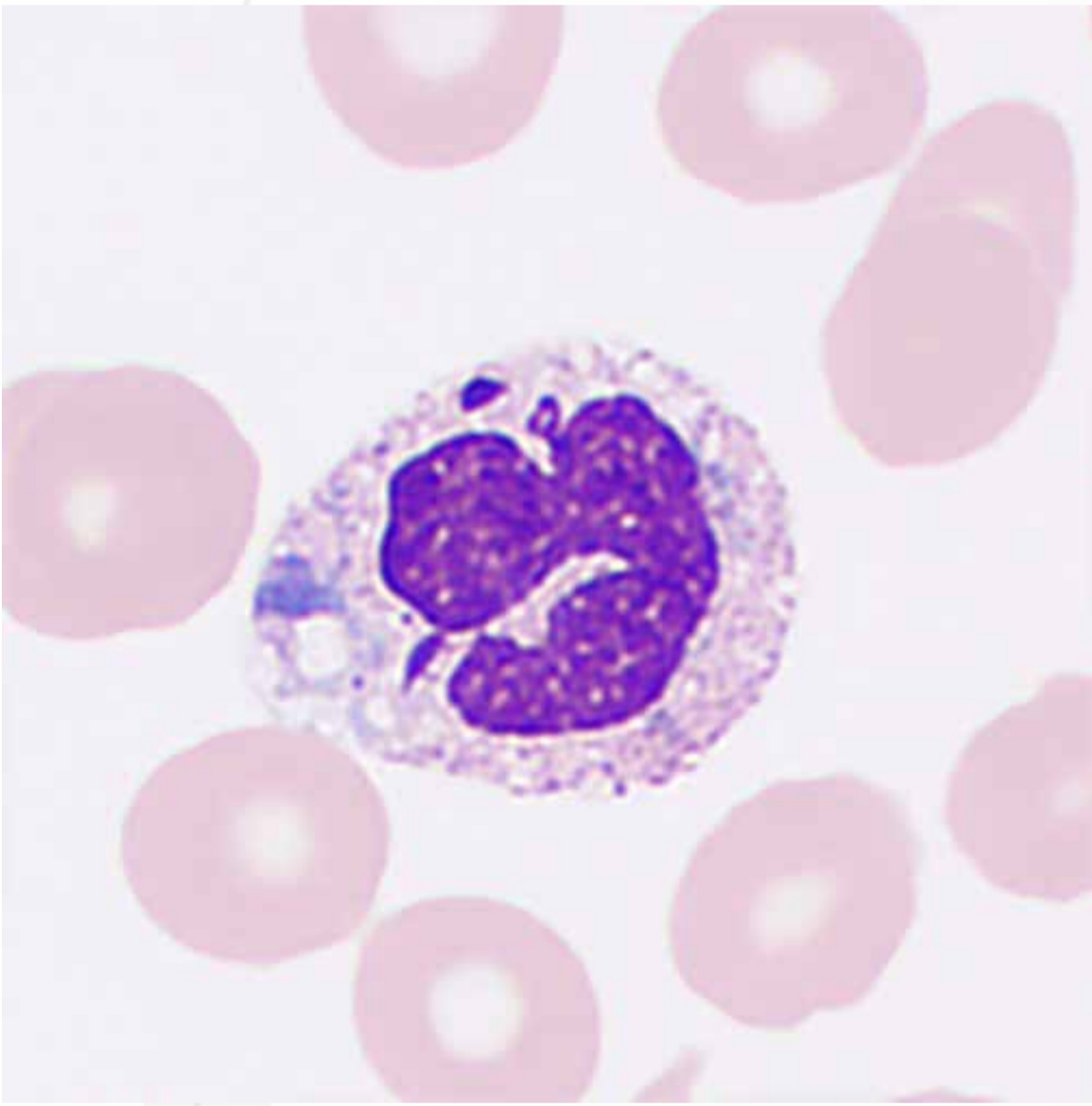
# Neutrophil Phagocytosis of Fungi or Parasites

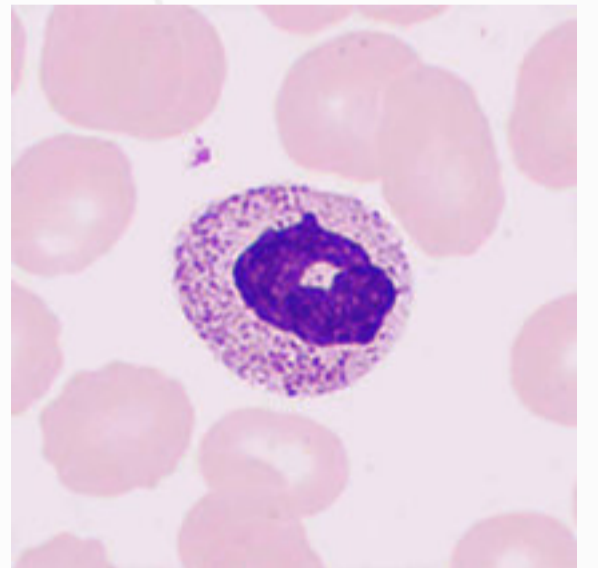
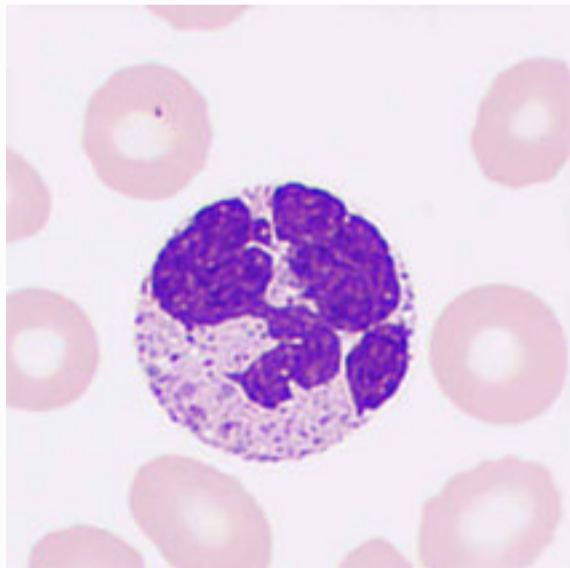
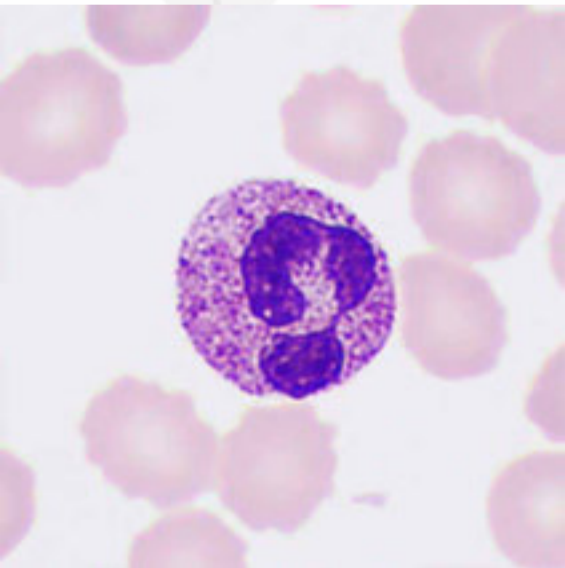
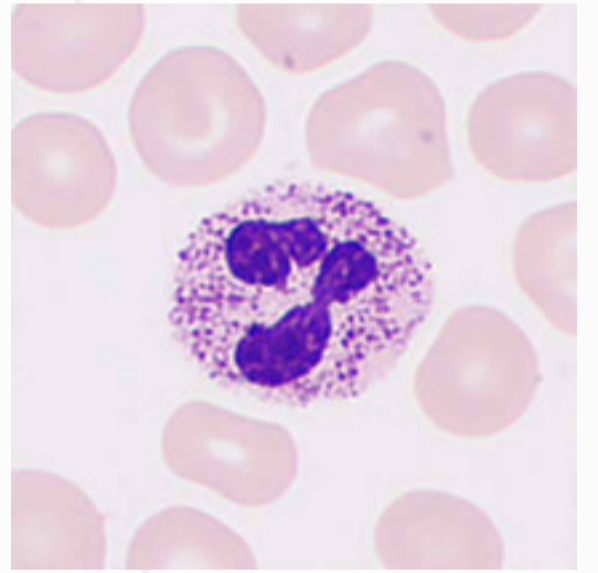
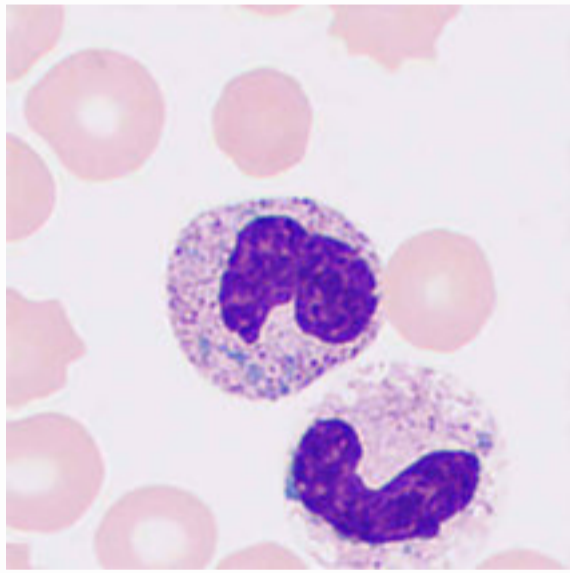
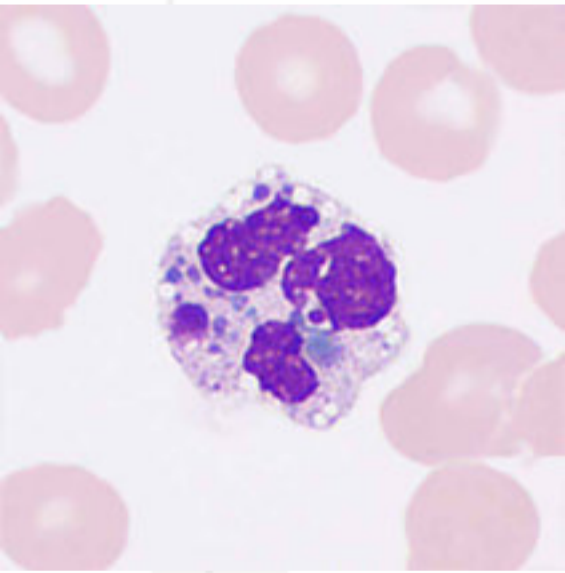
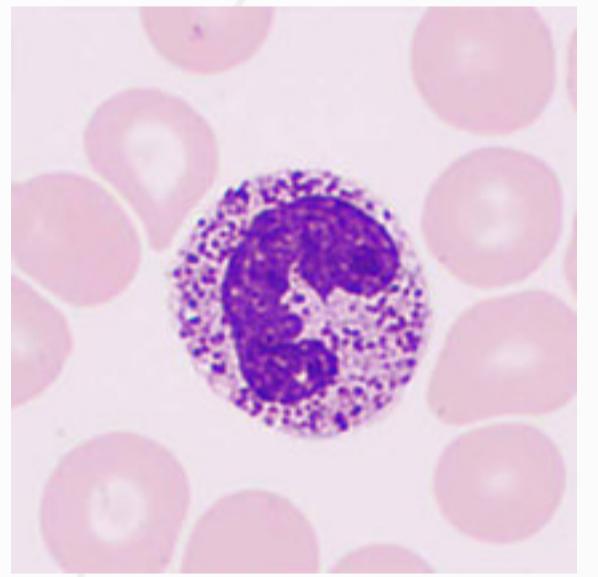
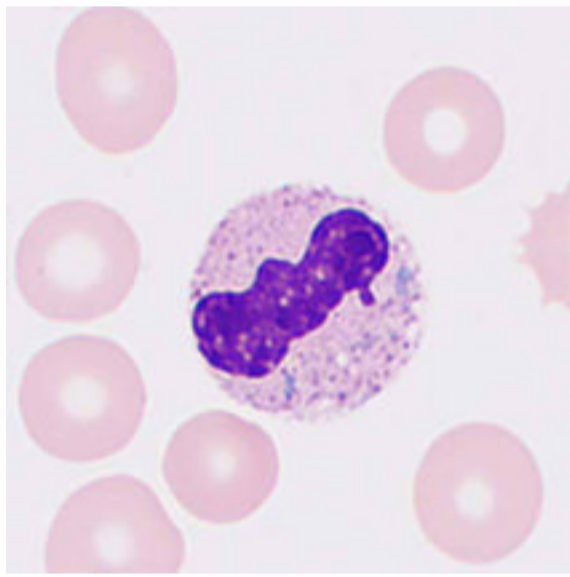
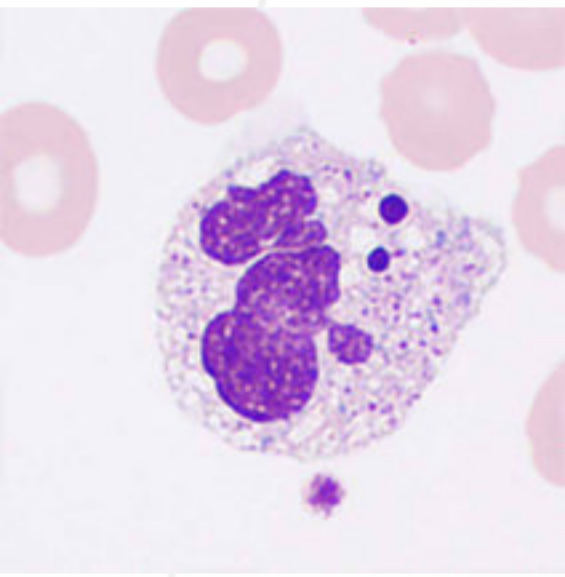
Neutrophils are the primary form of phagocytes with a strong ability to migrate by deformation and high phagocytic activity.



# Toxic Changes in Neutrophils

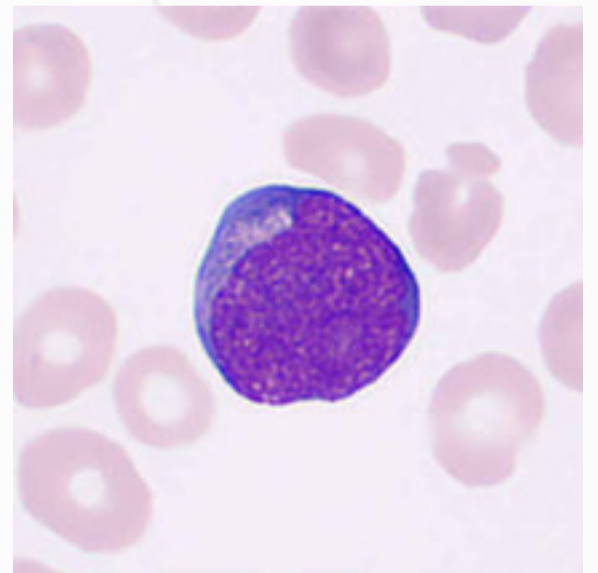
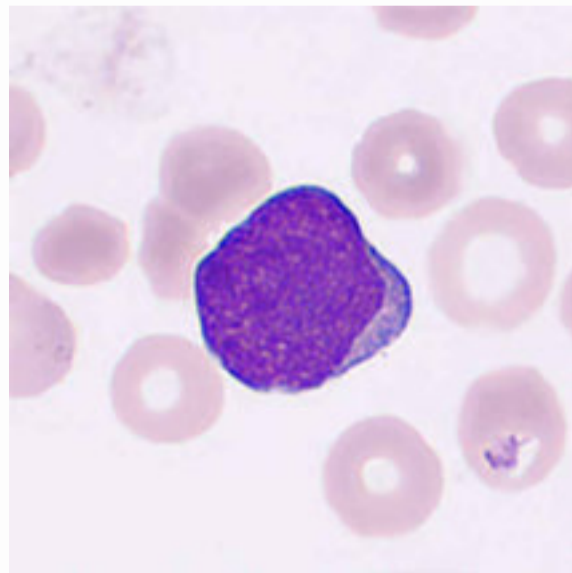
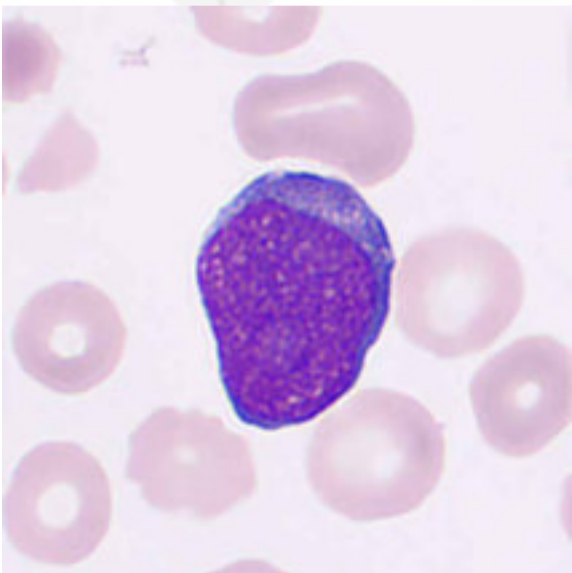
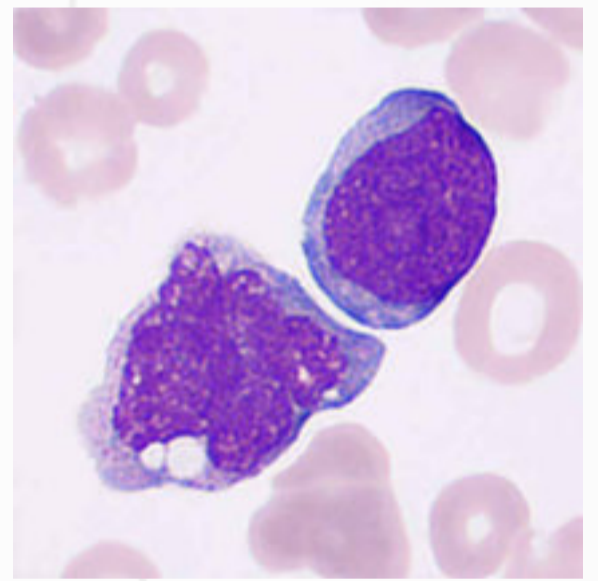
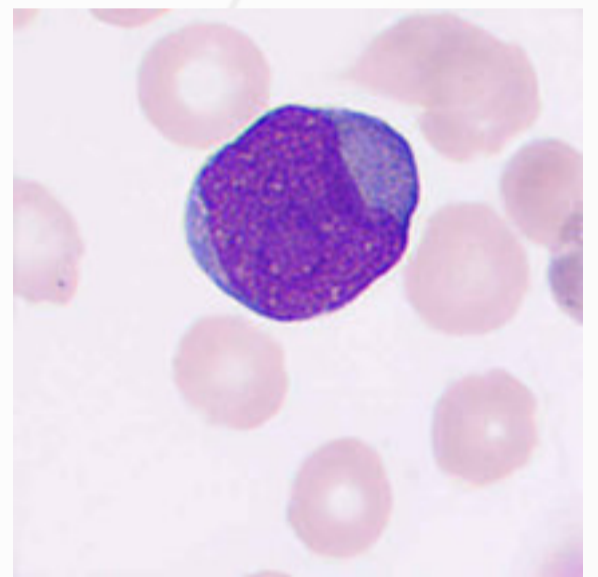
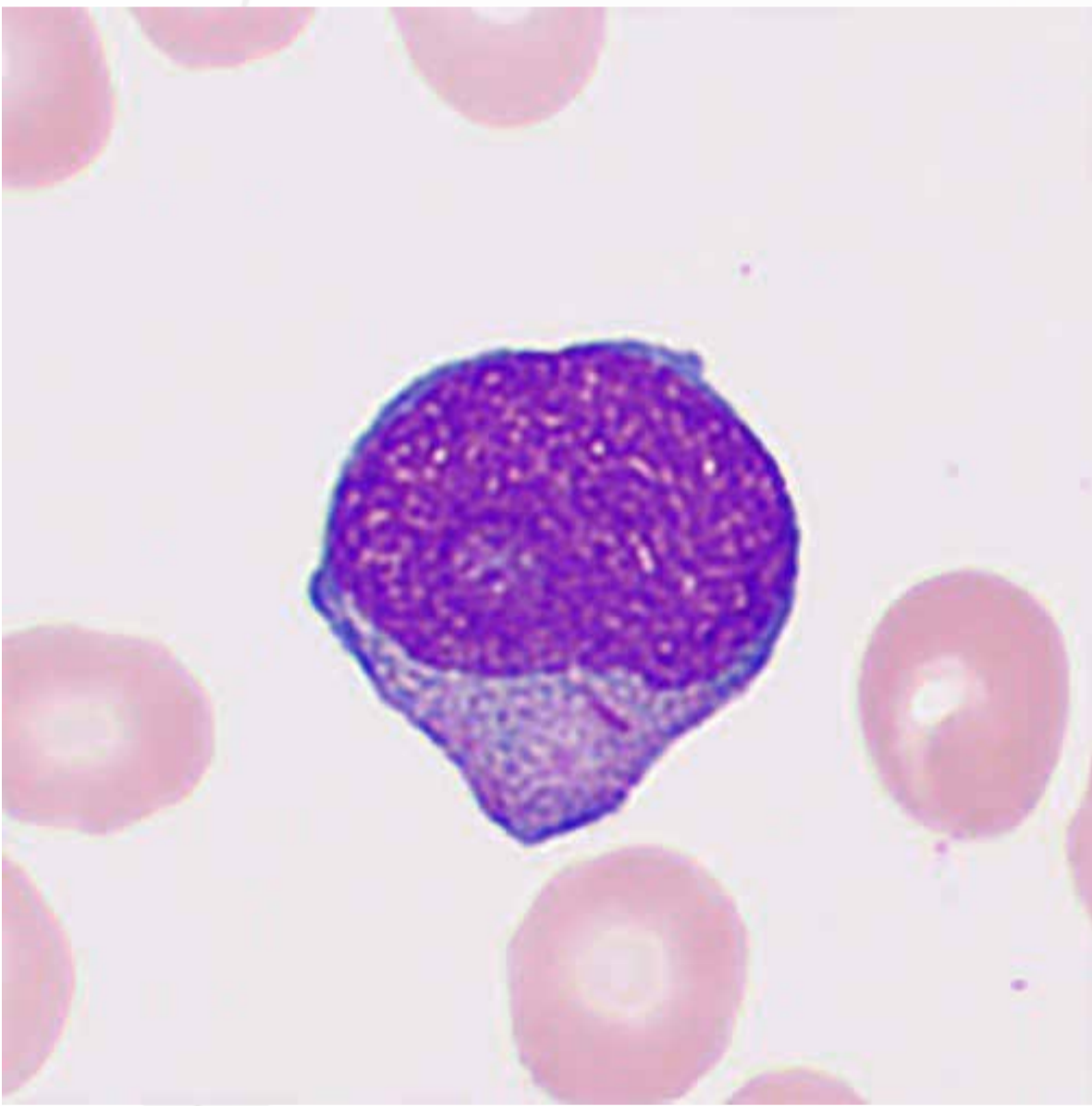
In some severe septic infections, sepsis, extensive burns, malignant tumors, acute poisoning, and other pathological conditions, neutrophils may present various cell sizes, toxic granulation, vacuolation, Döhle bodies, and degenerations. These changes may occur alone or together, and they are helpful indications for disease monitor and prognosis.

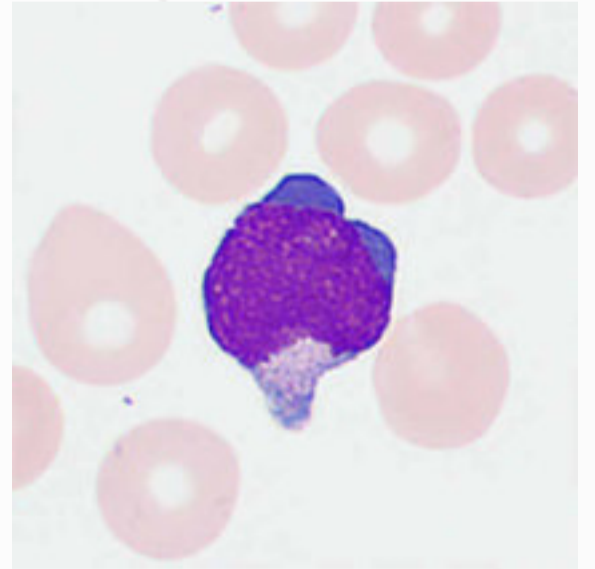
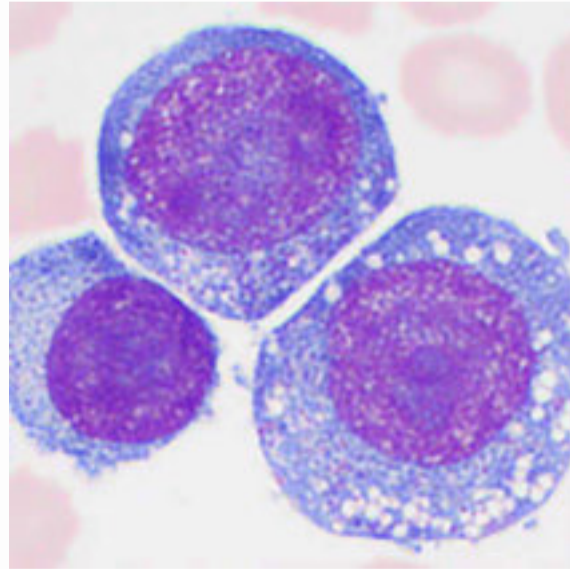
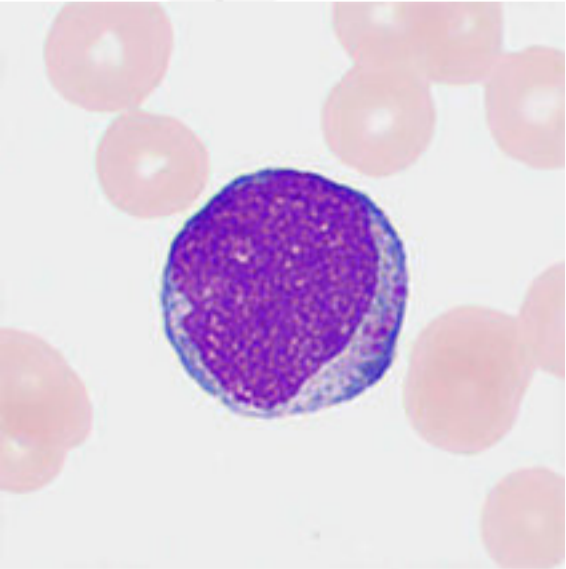
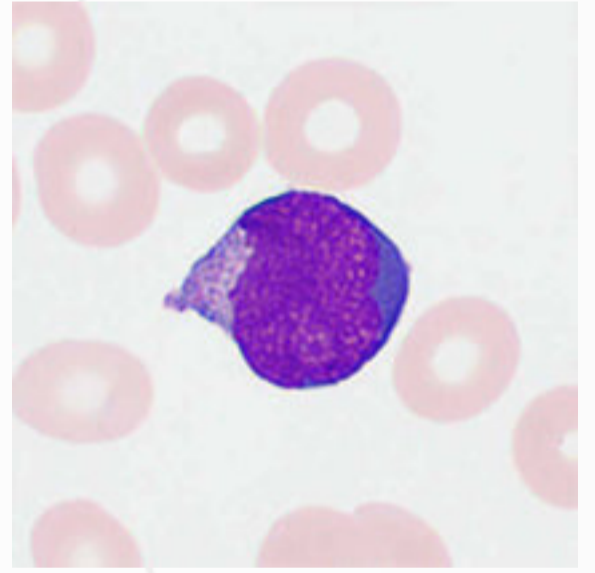
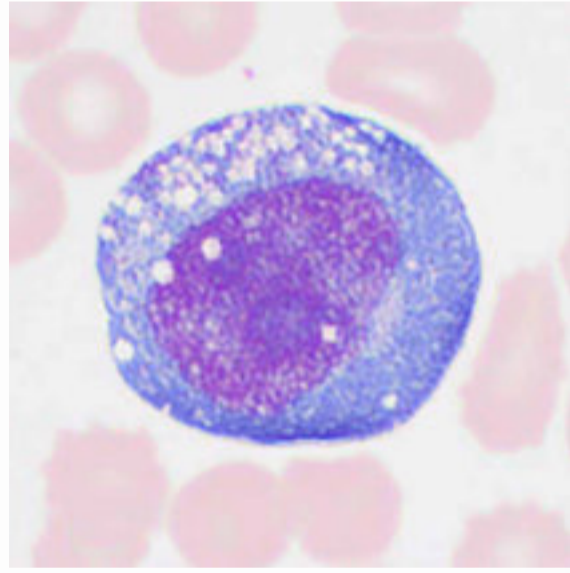
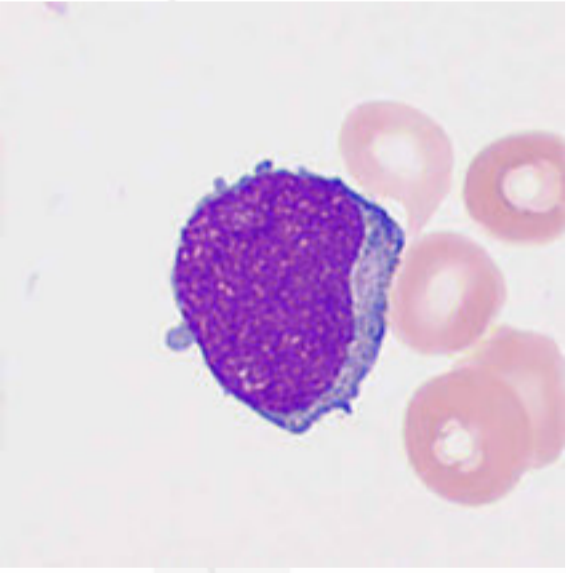
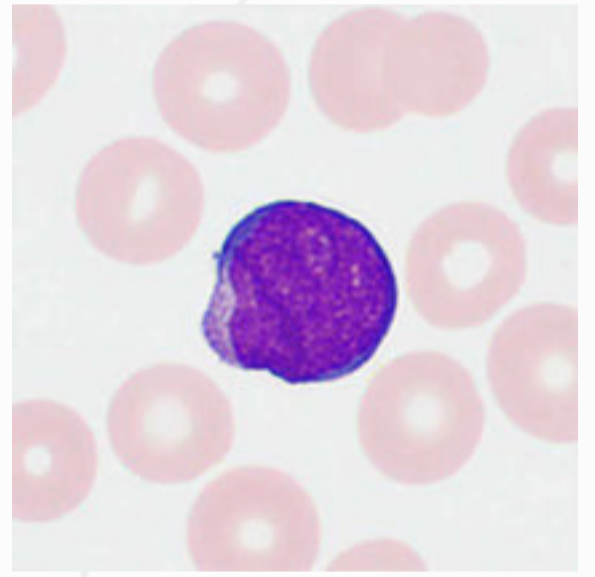
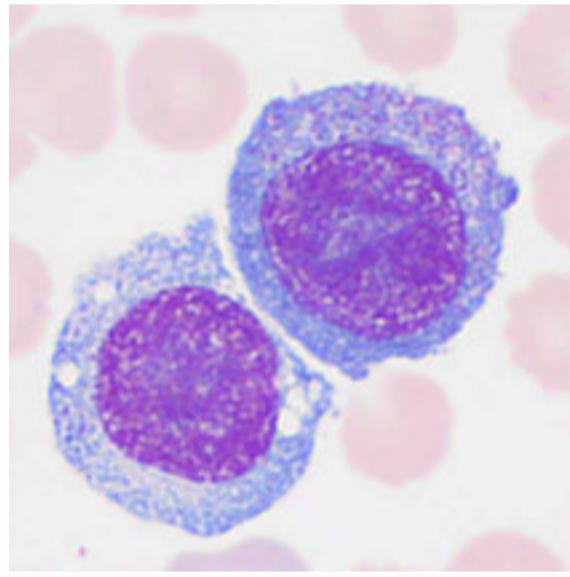
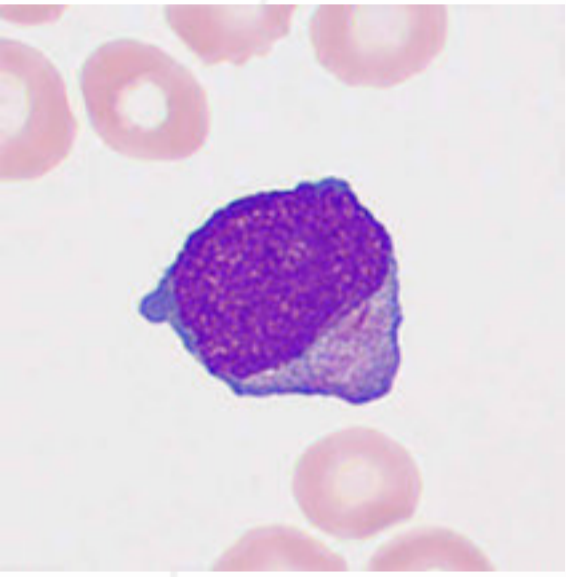




# Blast Cells

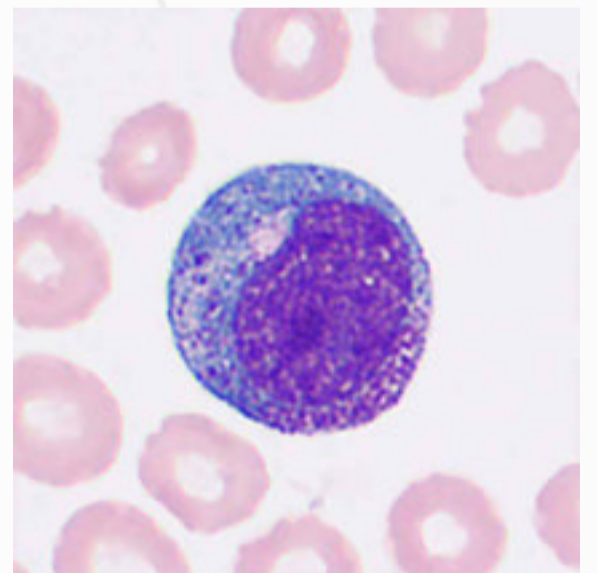
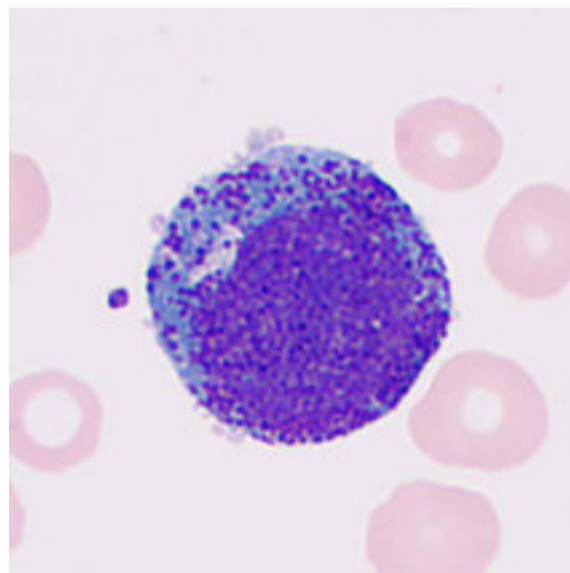
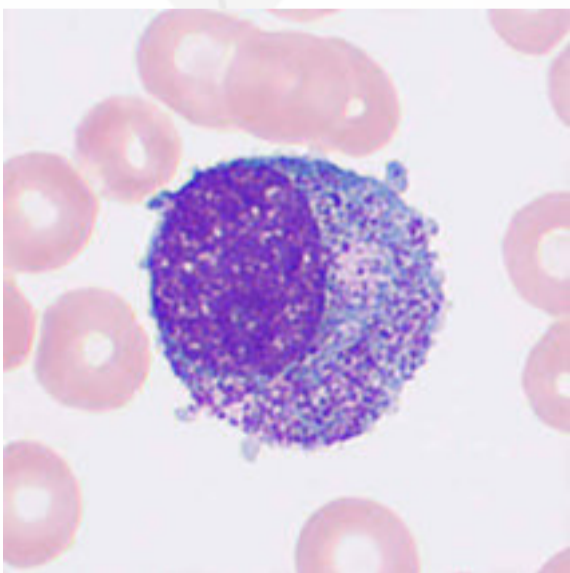
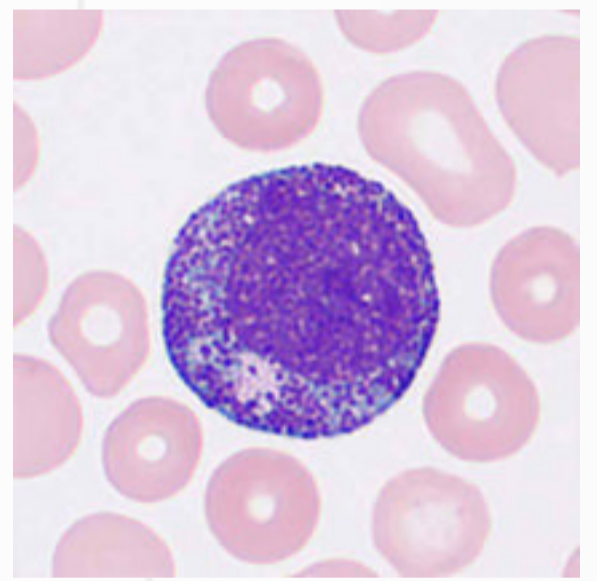
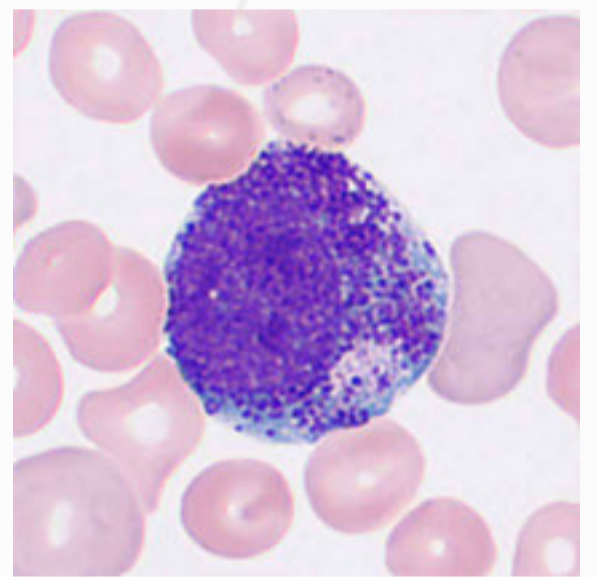
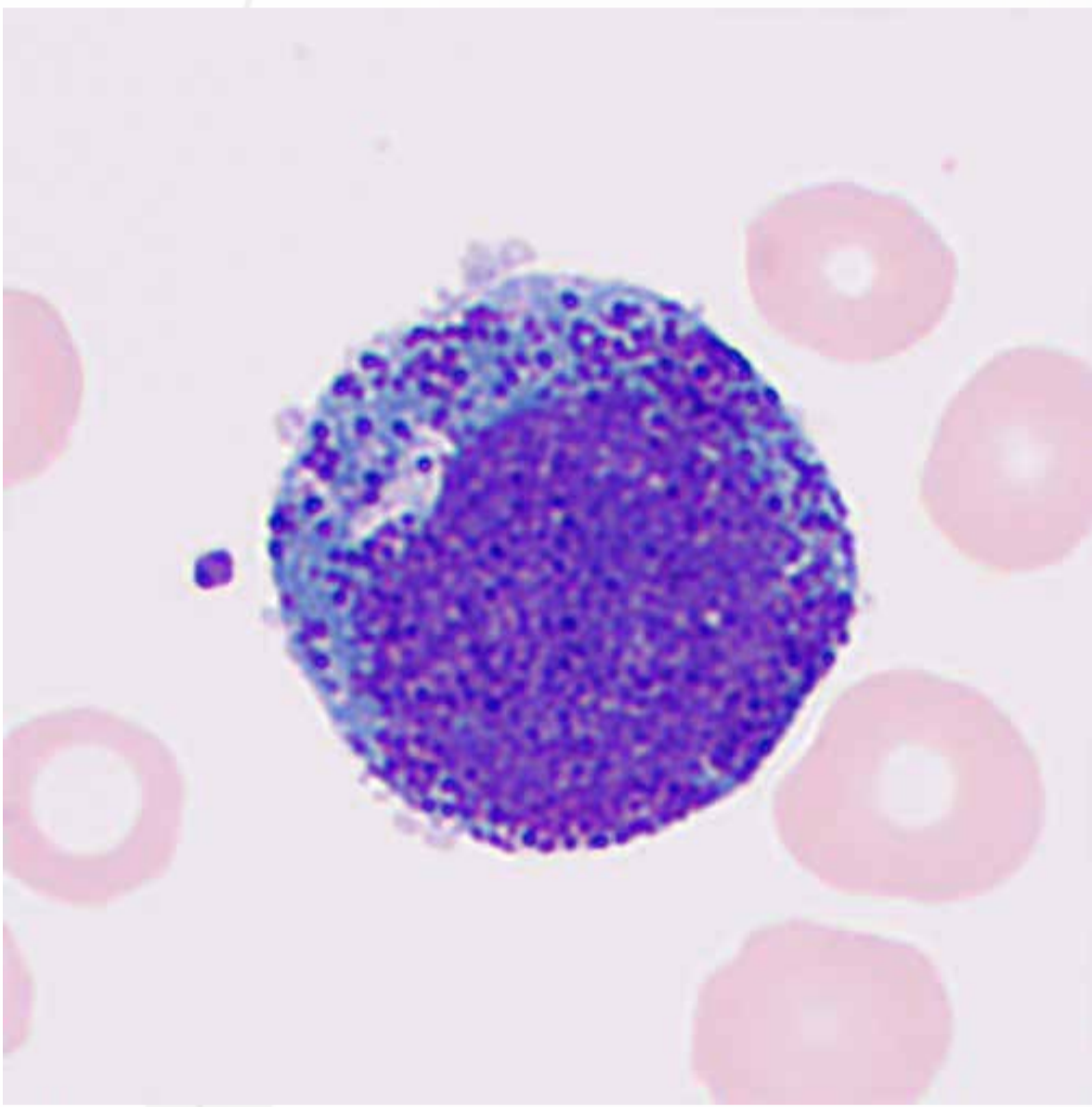
Blasts are medium to large cells with high nuclear to cytoplasmic ratios. They have prominent round or almost round nuclei containing fine-grained chromatin and apparent nucleoli. They also have scant and basophilic cytoplasm stained blue or dark blue.



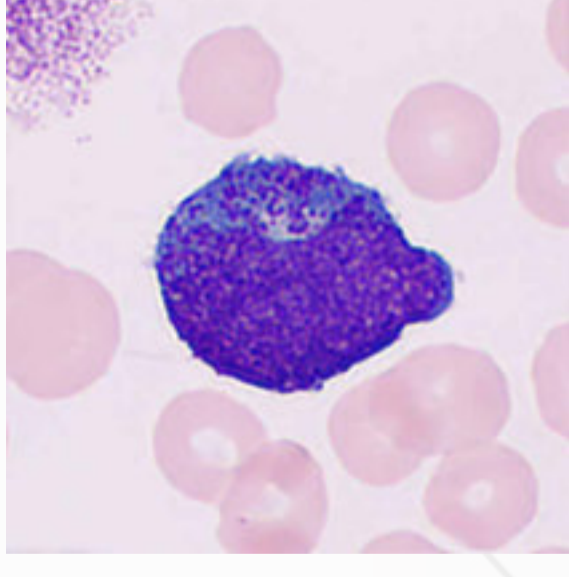
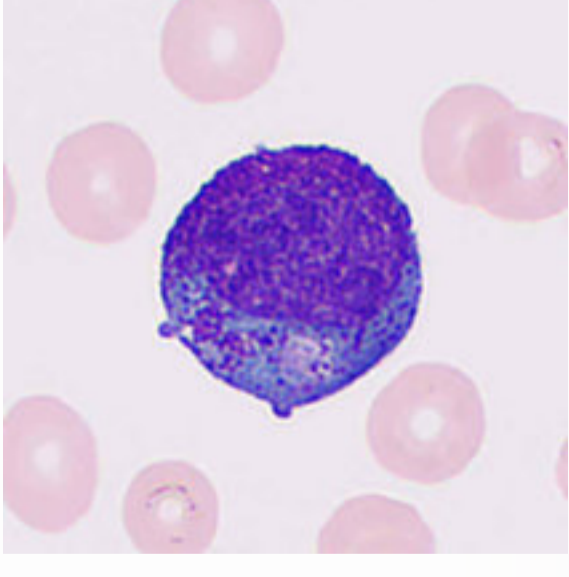
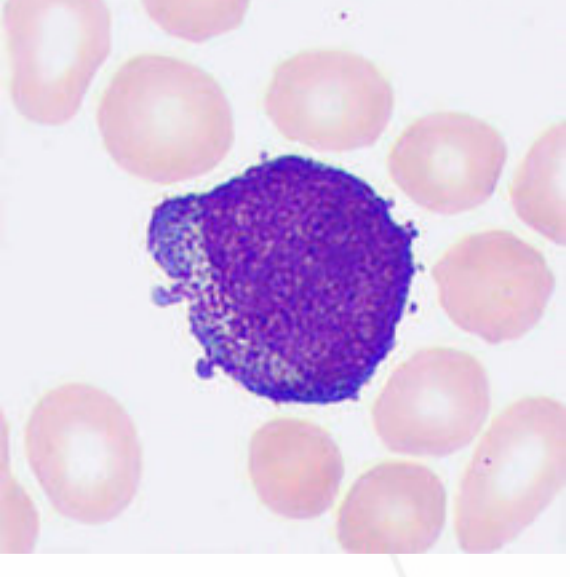
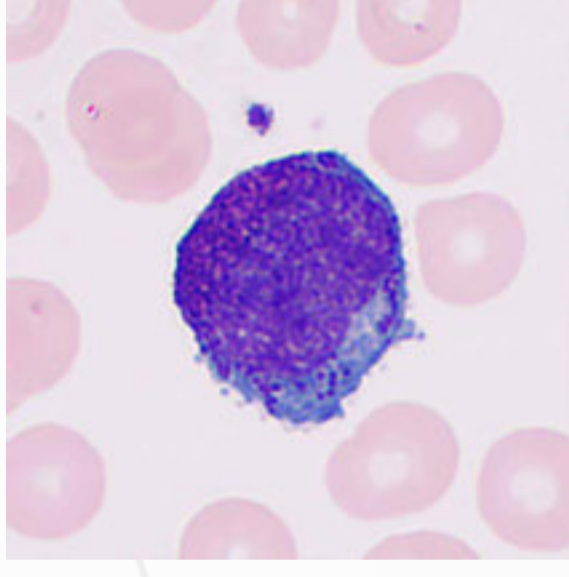
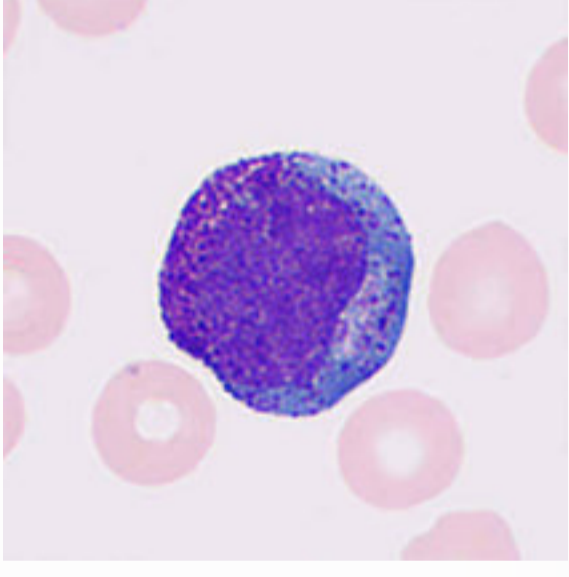
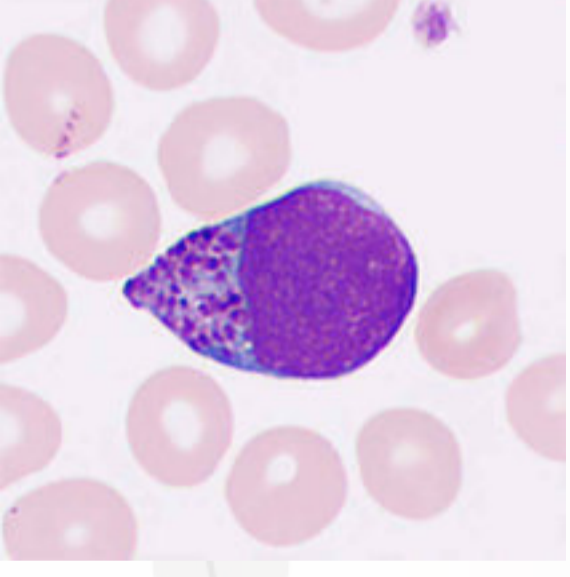
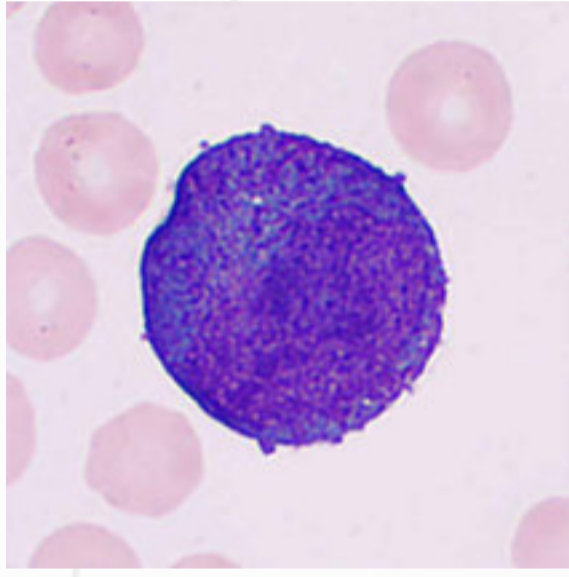
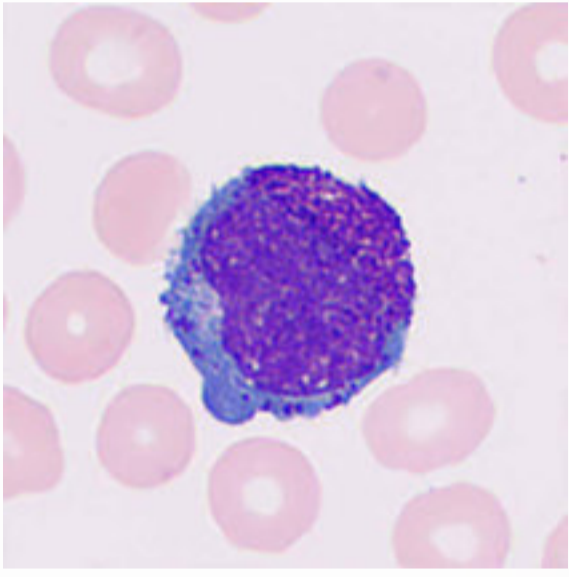
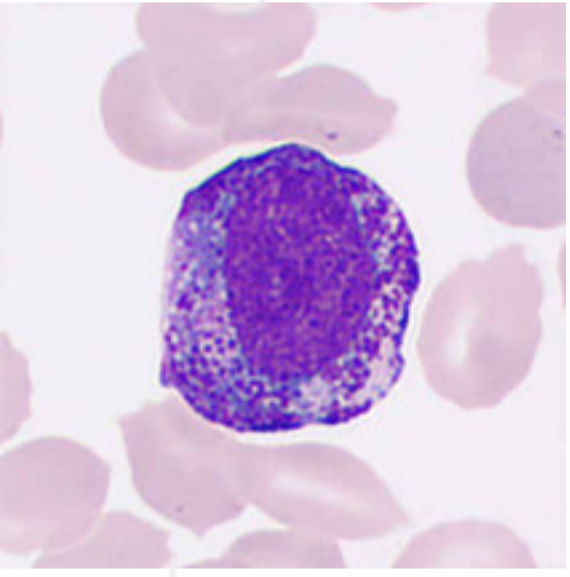


# Promyelocytes

Promyelocytes are round or oval cells 12–25  $\mu\text{m}$  in diameter and larger than myeloblasts. They have a large and slightly indented nucleus that usually deviates to one side with a visible nucleolus, and the chromatin starts to aggregate and is more coarse and clumped than myeloblasts. They have abundant basophilic cytoplasm stained blue or dark blue and contain violet-red or deep violet-red non-specific granules with variable numbers and morphology and are unevenly distributed in the cytoplasm. A paranuclear hof or cleared space may be present.

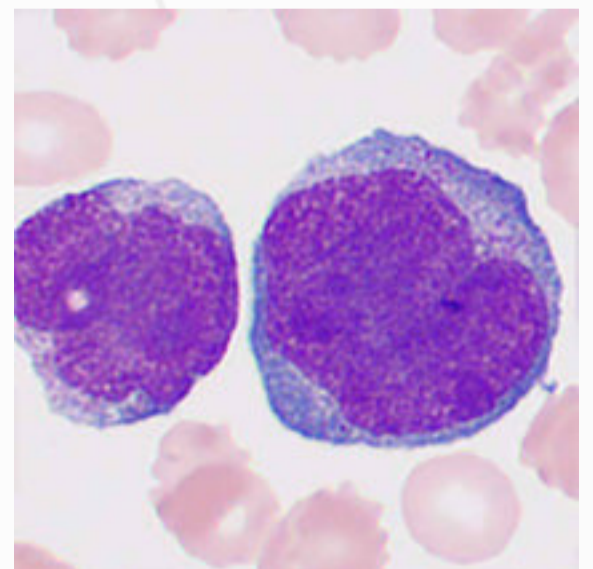
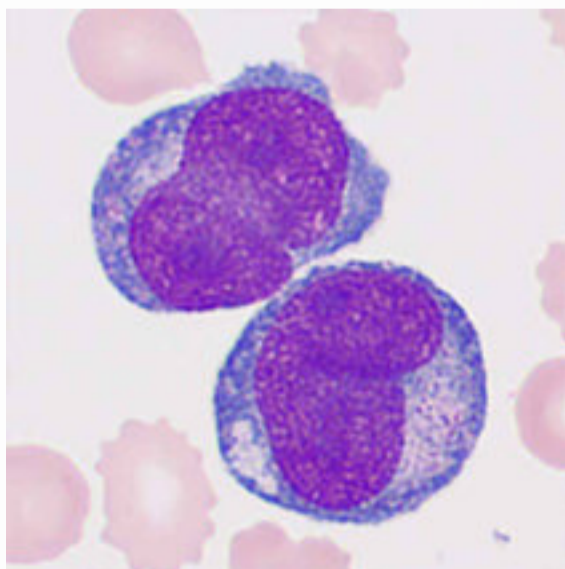
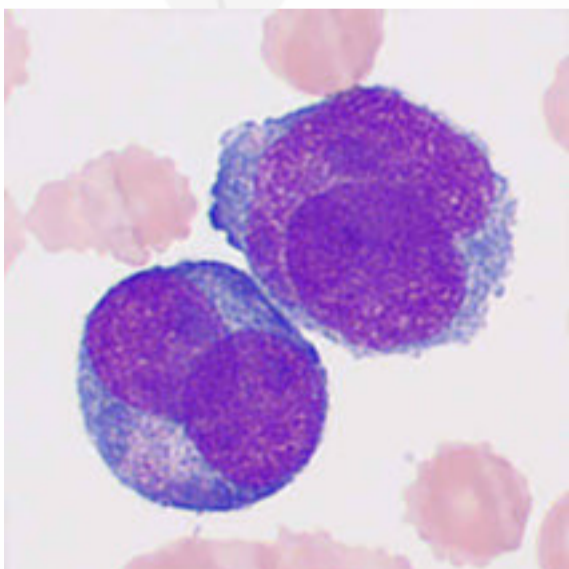
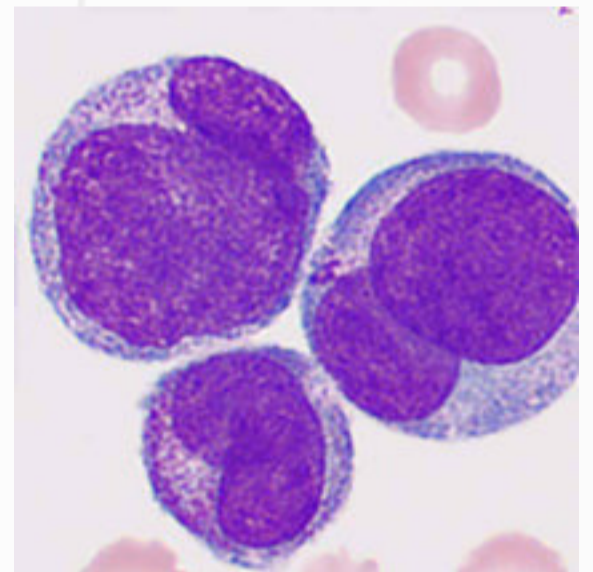
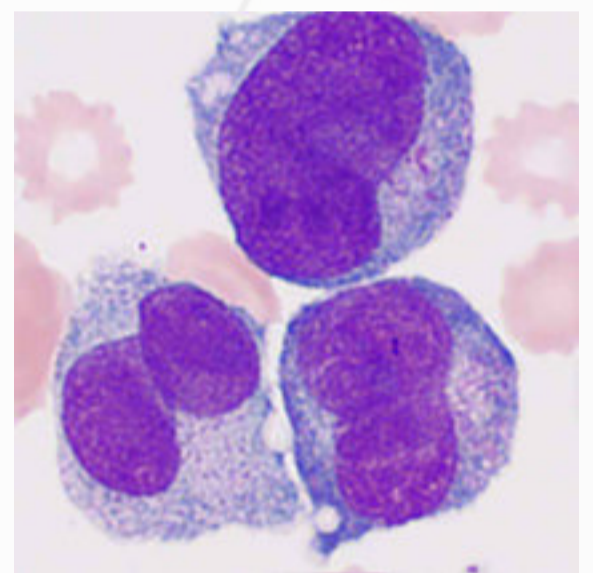
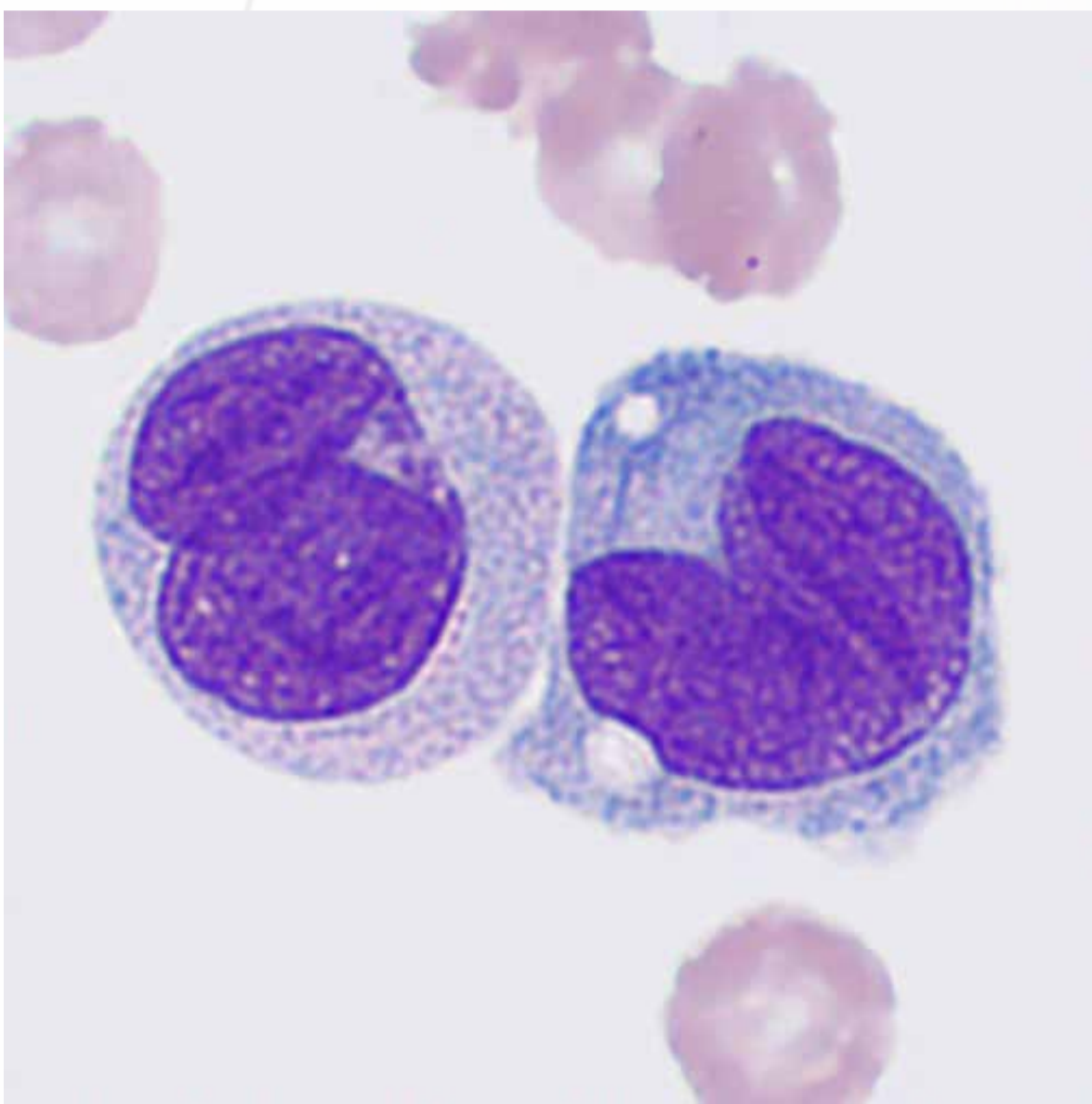




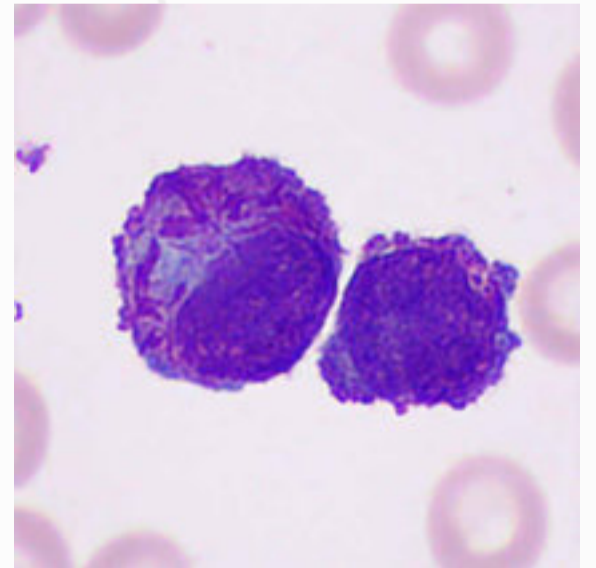
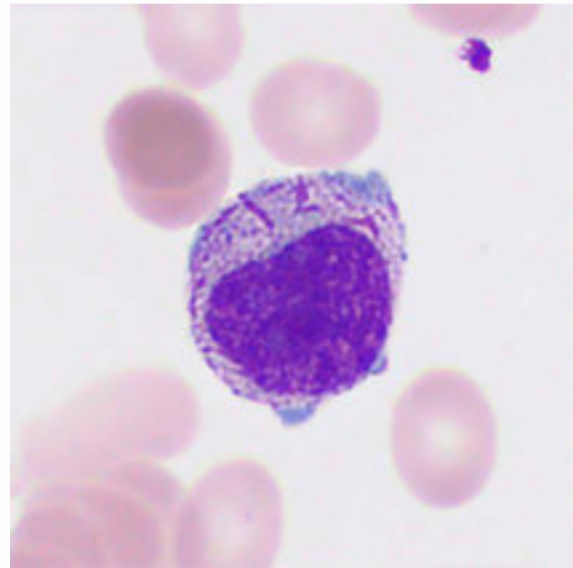
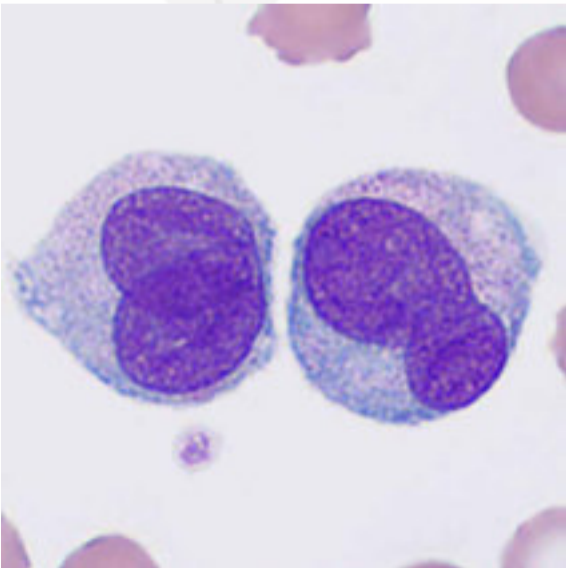
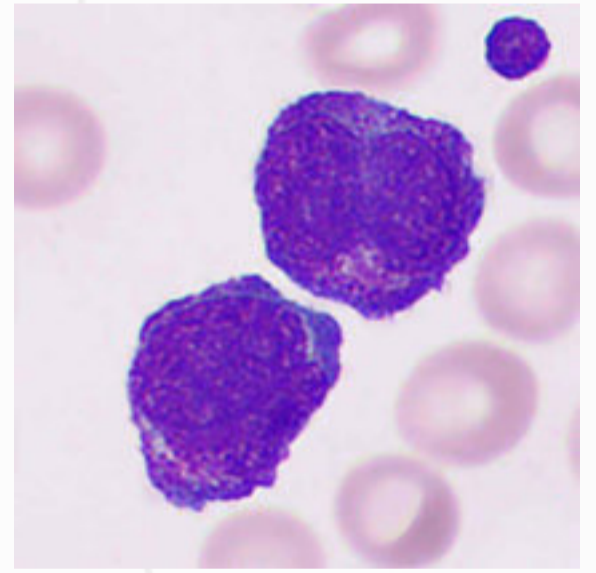
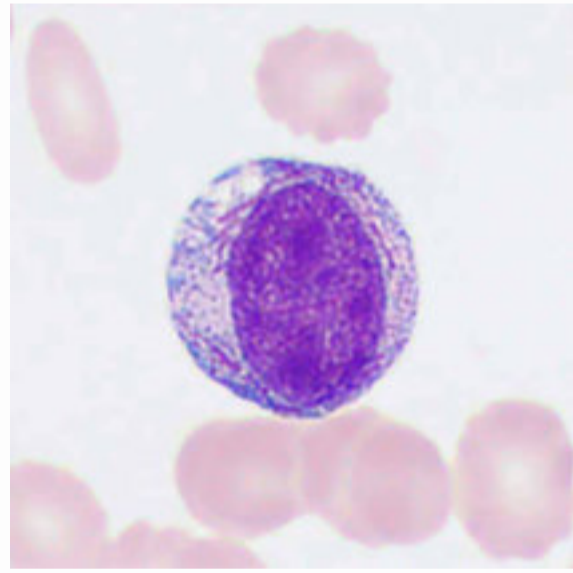
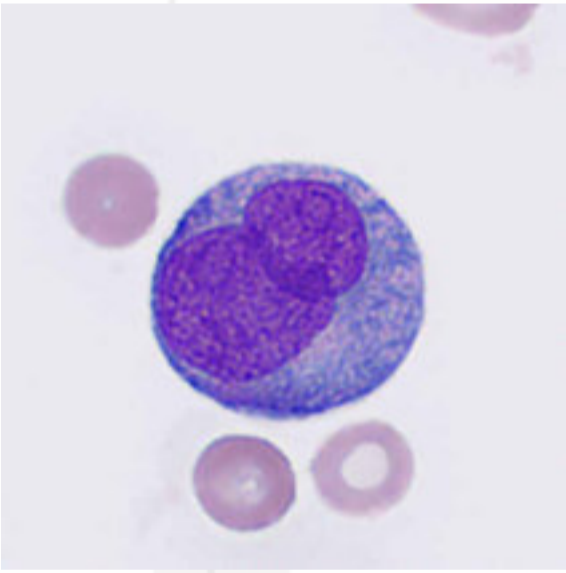
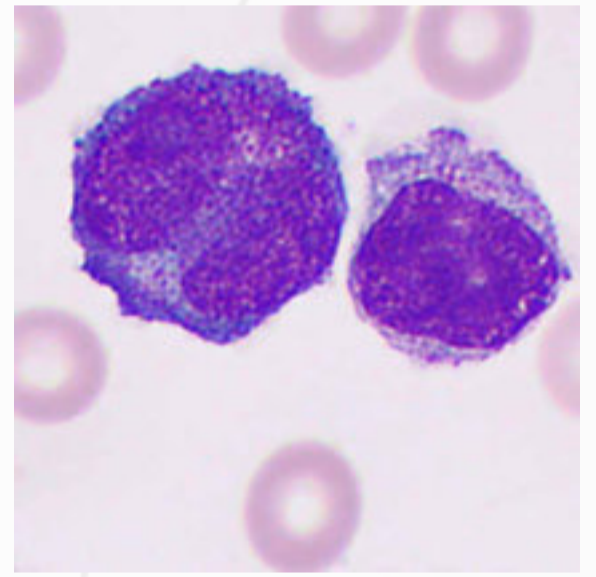
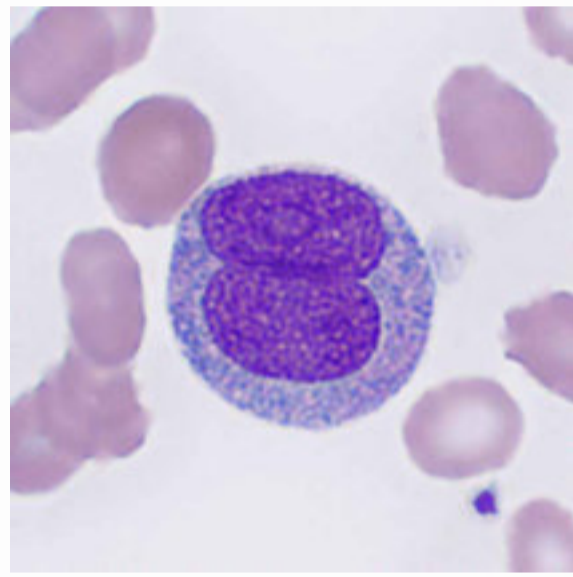
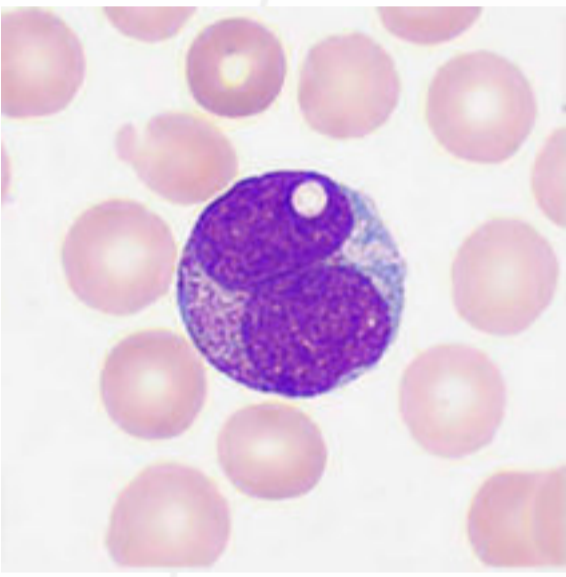


# Abnormal Promyelocytes

Typical abnormal promyelocytes vary in size, with irregular nuclei (generally kidney-shaped or bilobed), dense nuclear chromatin, occasional visible fuzzy nucleoli, abundant cytoplasm, and long and thick Auer rods (i.e. "faggot cells" since they resemble a bundle of sticks or a faggot). Based on the FAB classification scheme as well as the characteristics of intracellular granules and the nuclear shape, acute promyelocytic leukemia (APL; AML-M3) was divided into three subtypes based on the characteristics of intracellular granules and the nuclear shape: M3a (coarse granules), M3b (fine granules), and M3v (micro or invisible granules and twisted or lobulated nuclei).

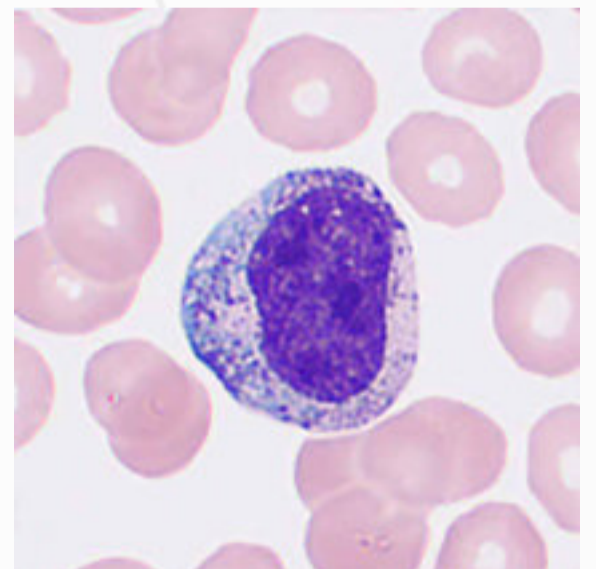
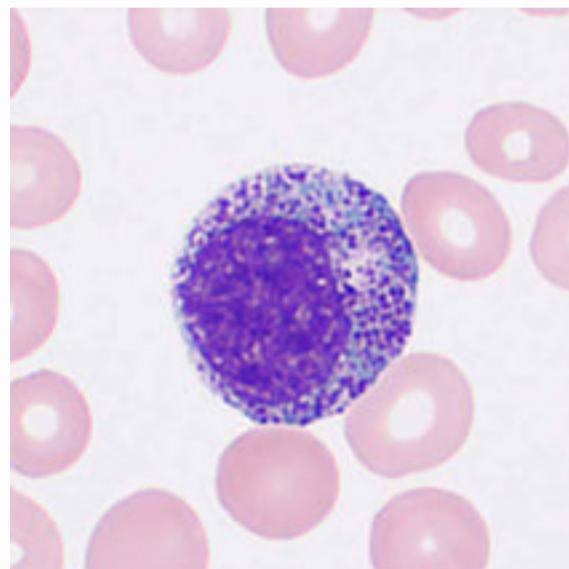
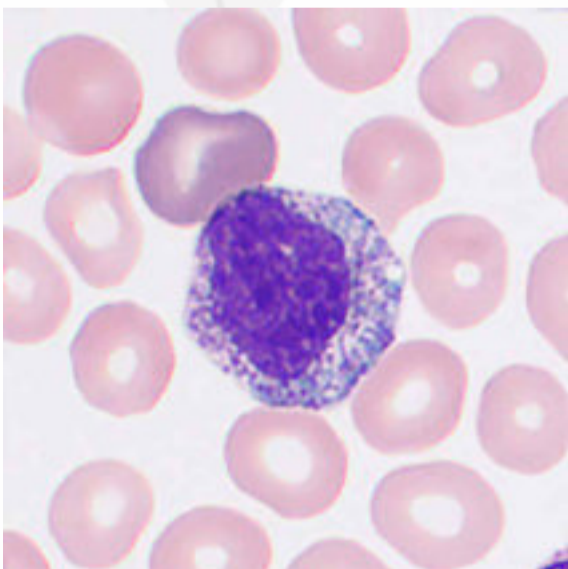
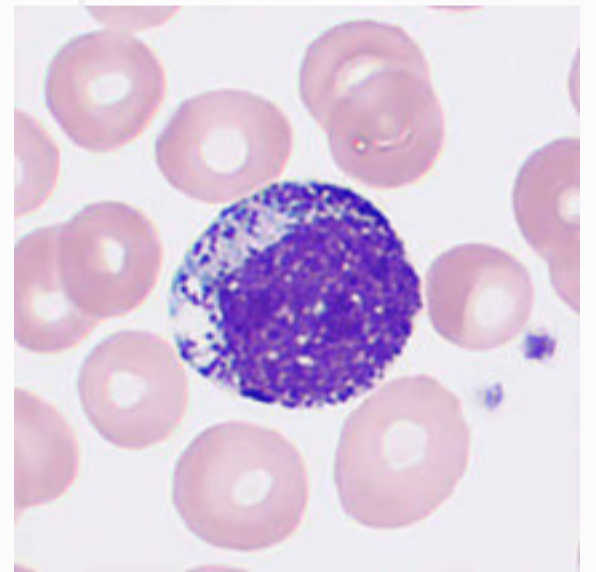
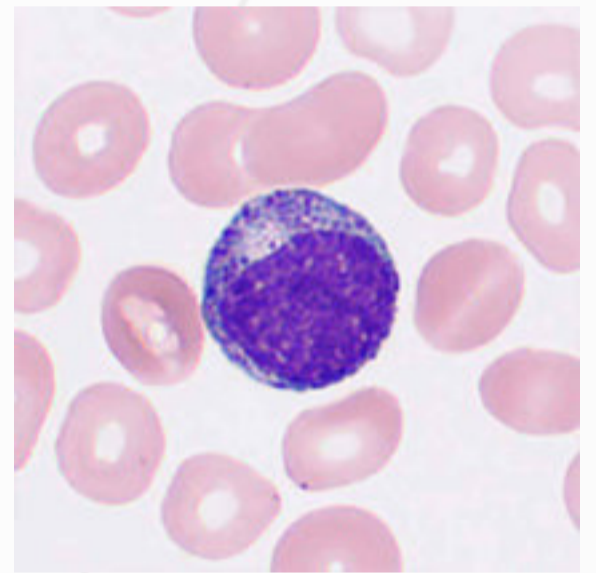
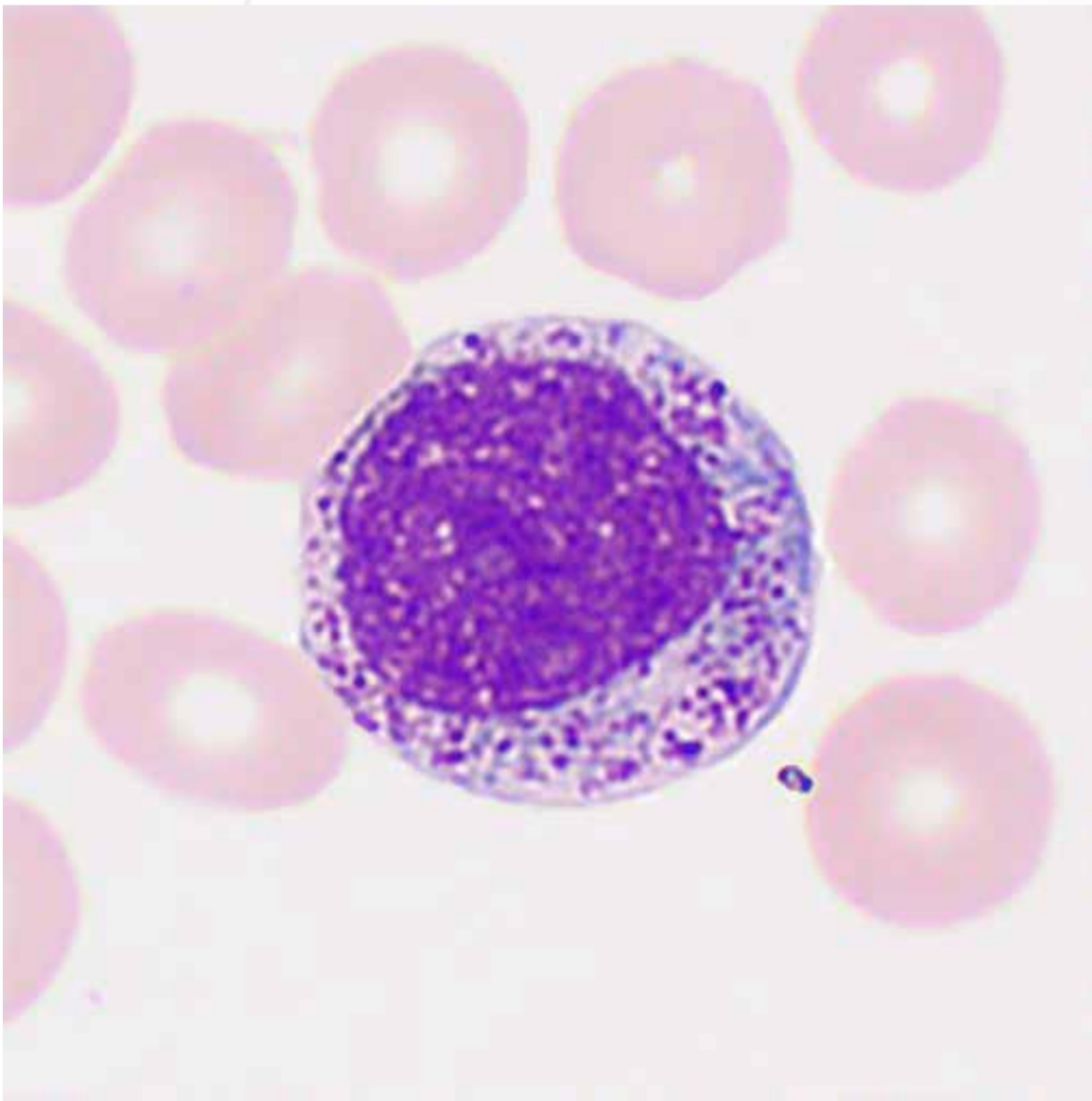


APL is an acute myeloid leukemia with malignant proliferation of abnormal promyelocytes and reproducible genetic abnormalities  $t(15;17)(q22;q12)$  and PML-RAR $\alpha$  with an aggressive clinical presentation. Any abnormal promyelocytes found in the peripheral blood should be noted in the report and notified to the clinician at the earliest time possible for the consideration of APL possibility.

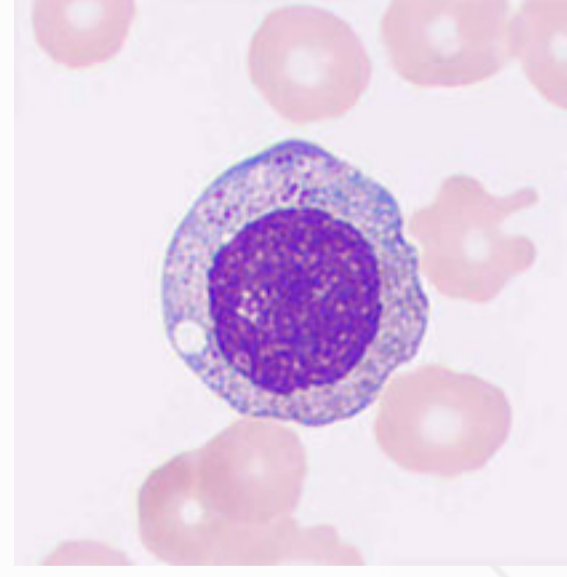
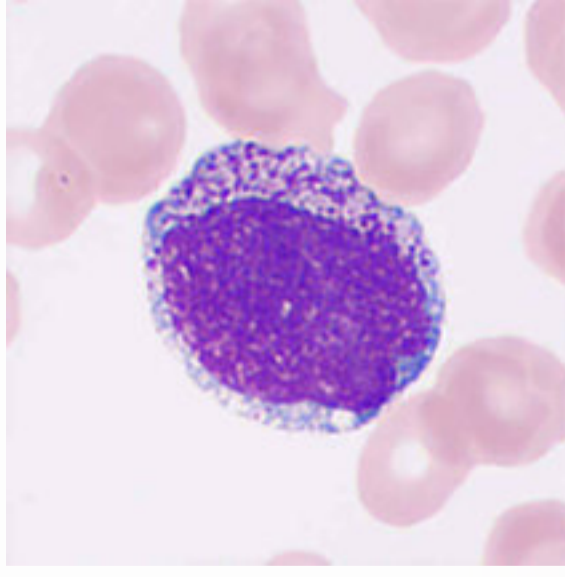
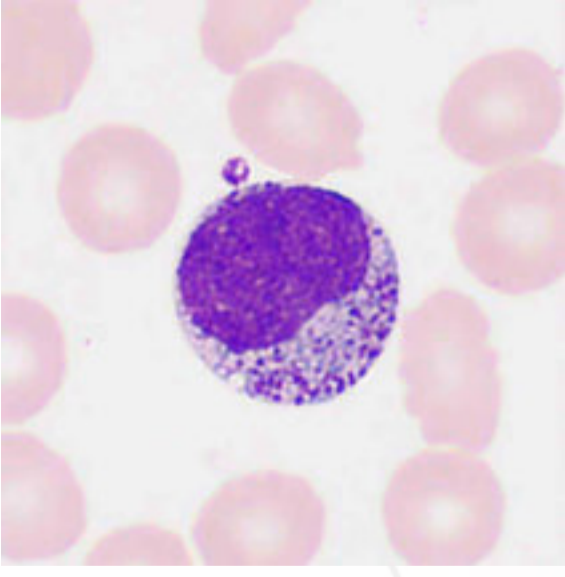
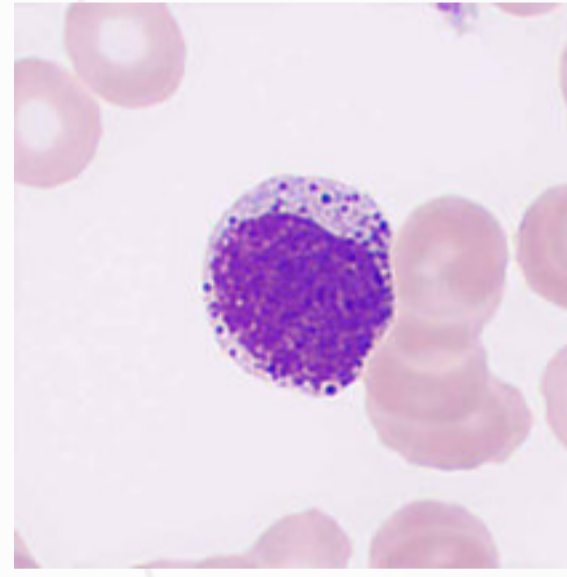
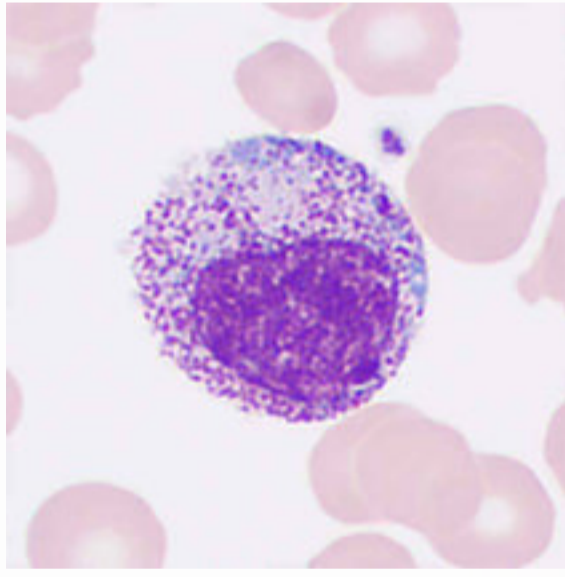
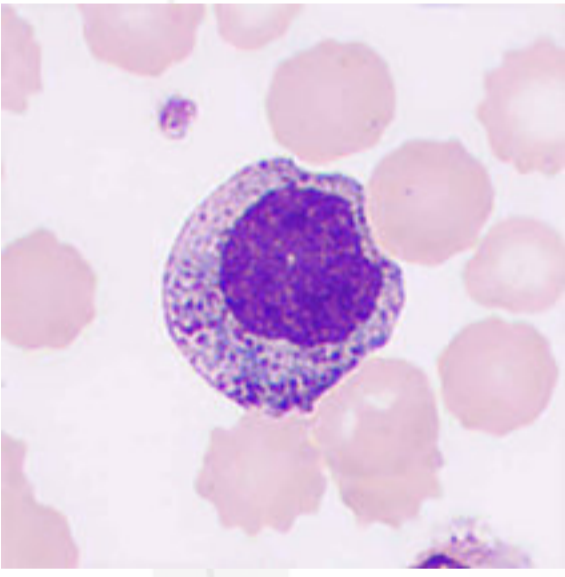
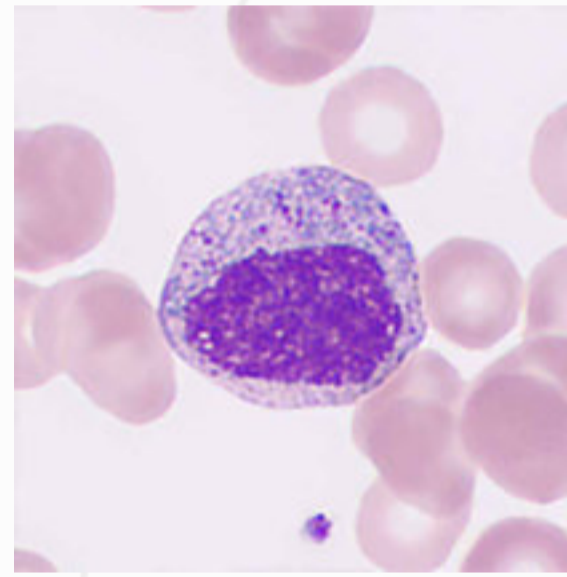
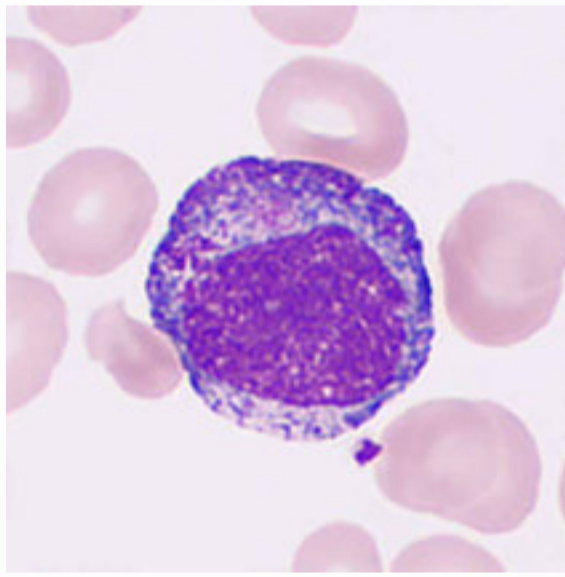
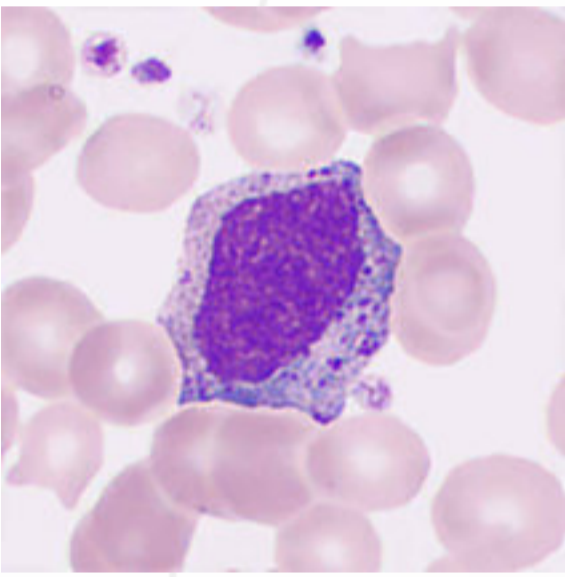


# Neutrophilic Myelocytes

Neutrophilic myelocytes are round cells 10–20  $\mu\text{m}$  in diameter, smaller than promyelocytes. The nucleus is oval, semicircular, flattened or slightly indented on one side, and the indentation is usually less than 1/2 the nucleus diameter when assuming it is round. The nucleus is normally anucleolate and stained with concentrated clusters in the form of rods. The cytoplasm is abundant and stained blue or light blue, and it is heavily filled with fine and light red or violet-red granules.

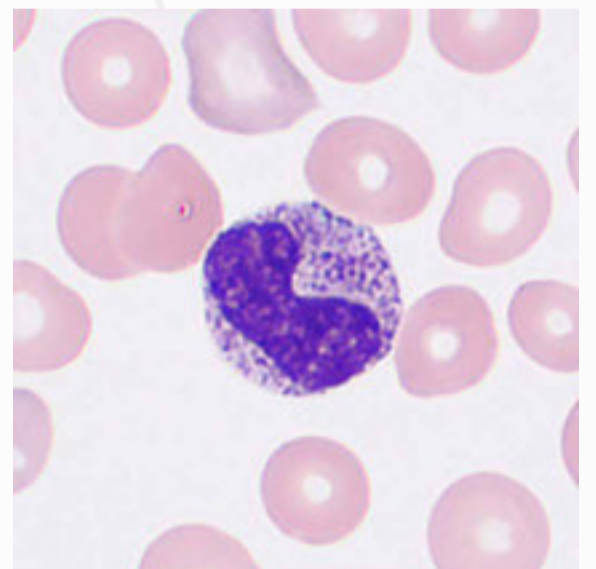
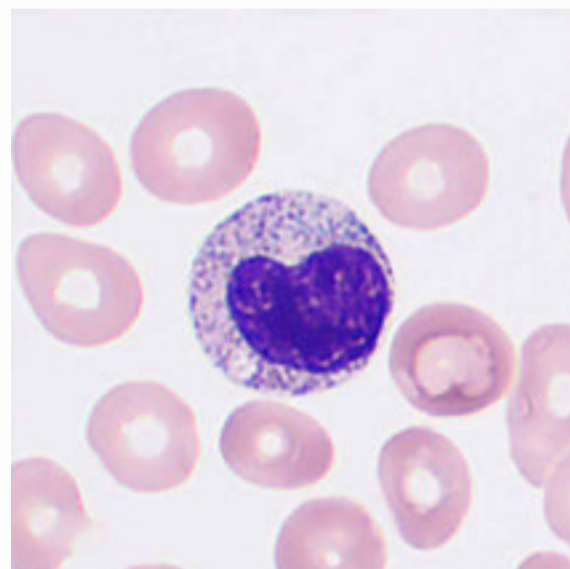
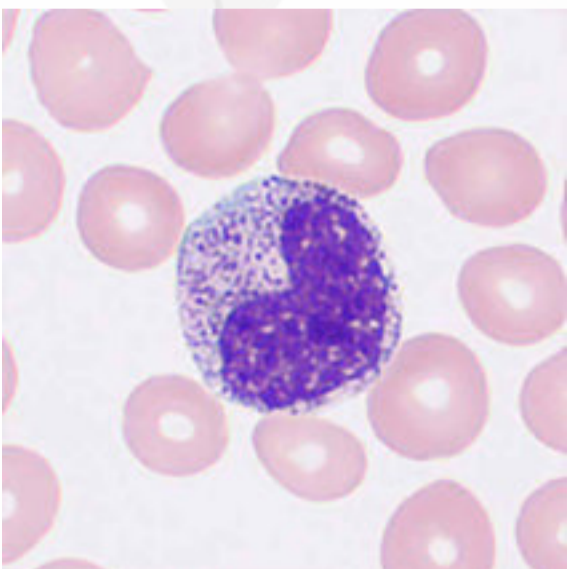
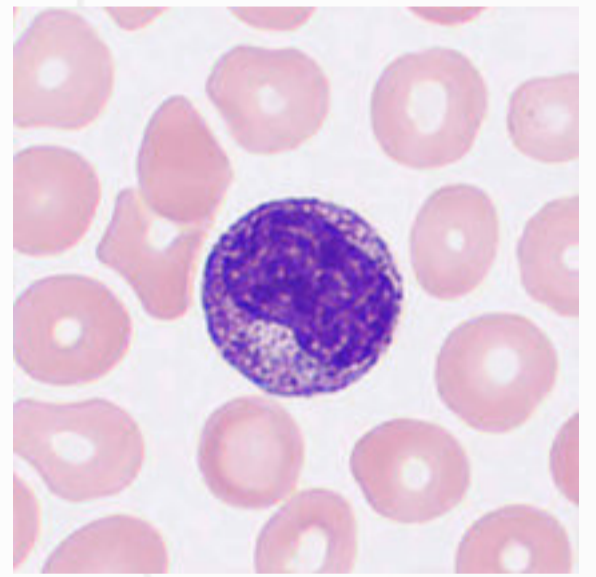
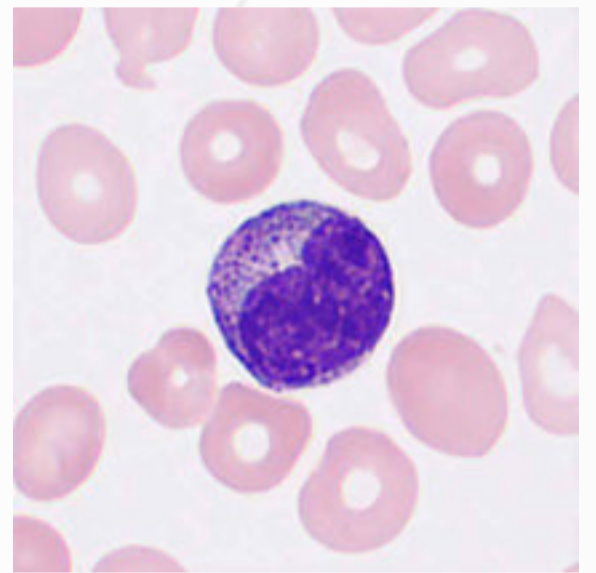
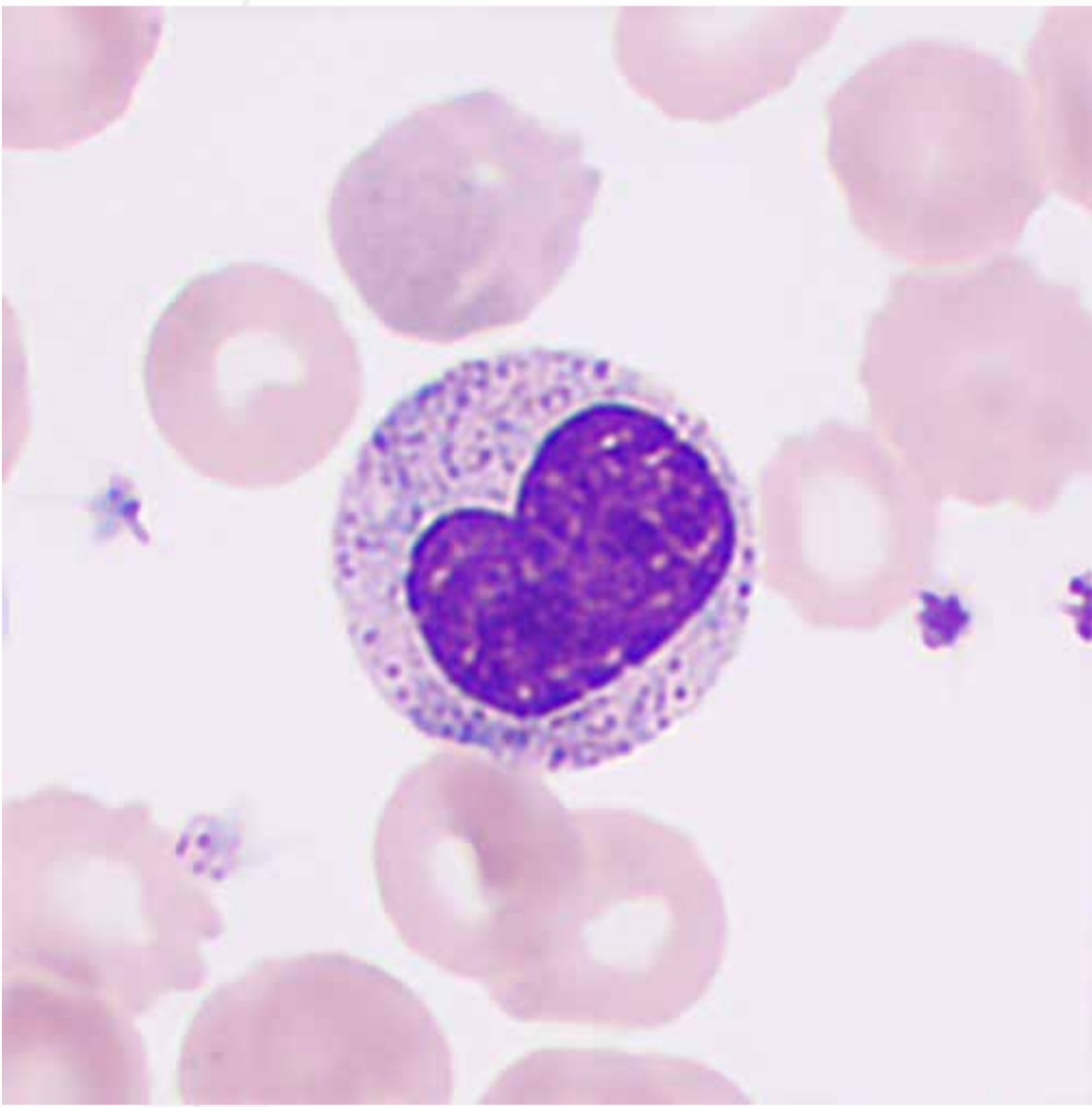


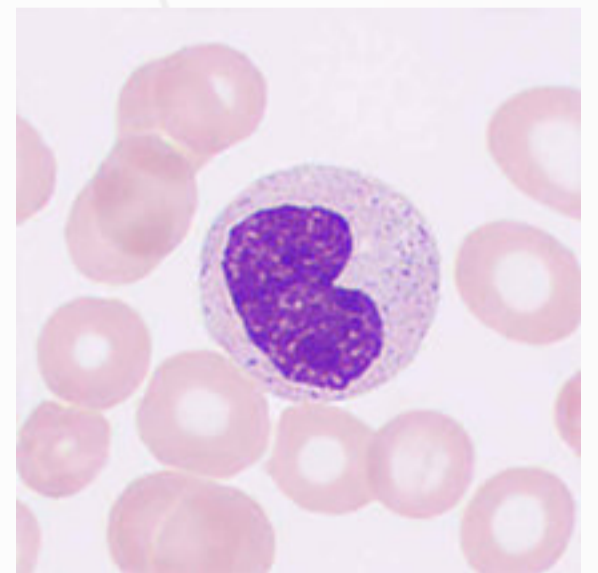
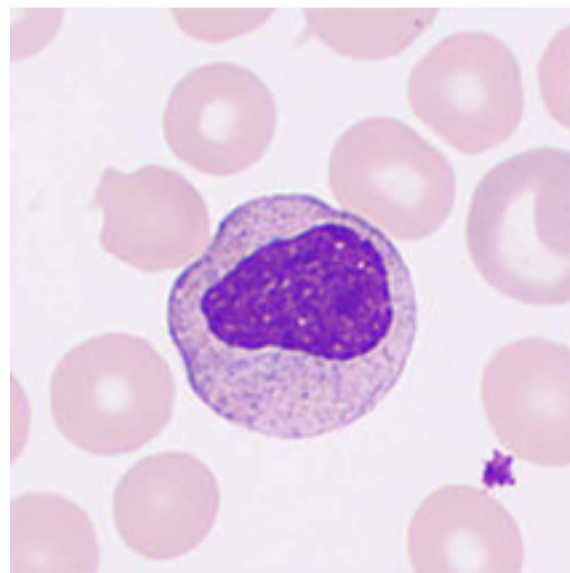
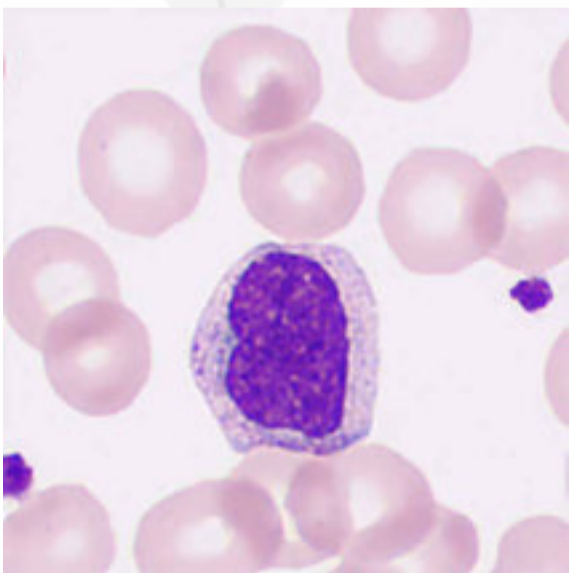
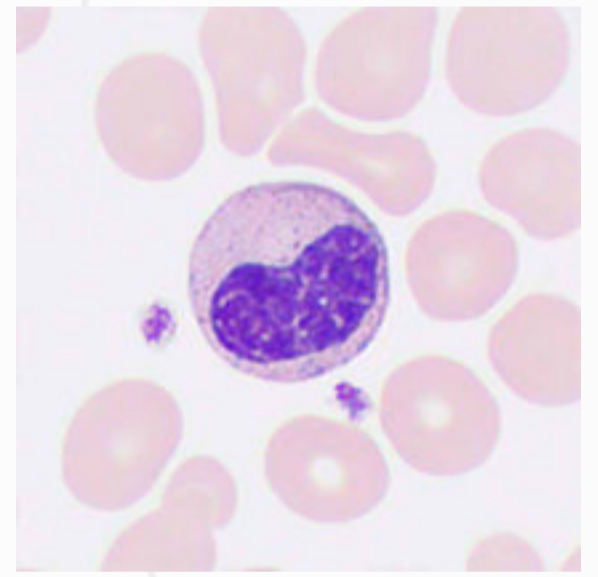
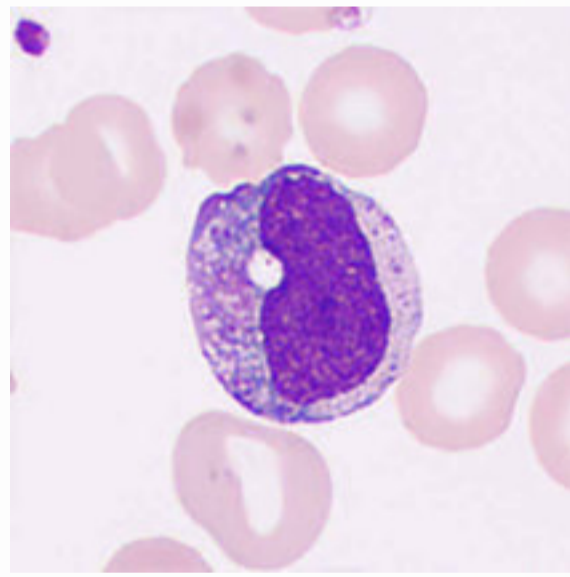
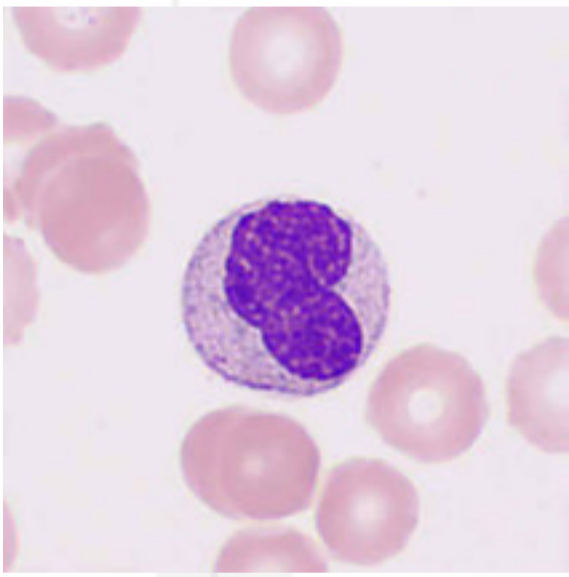
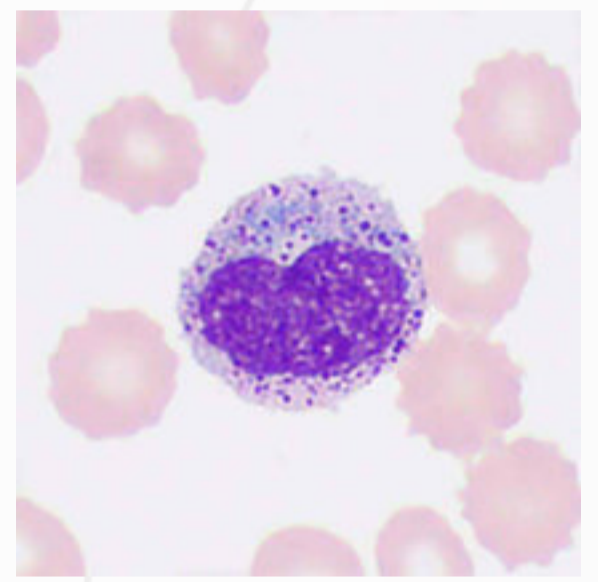
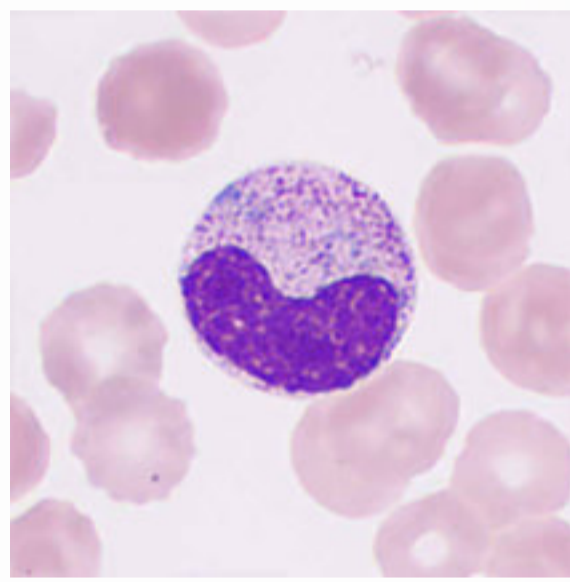
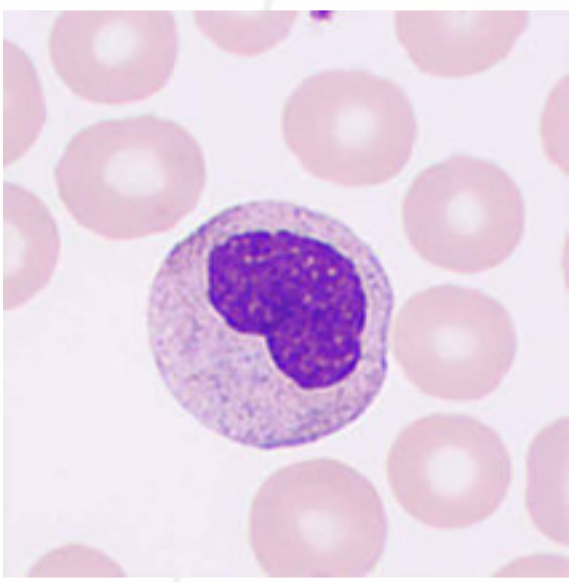
Neutrophilic myelocytes could present in peripheral blood under conditions including AML, CLL, MDS, and severe infections.



# Neutrophilic Metamyelocytes

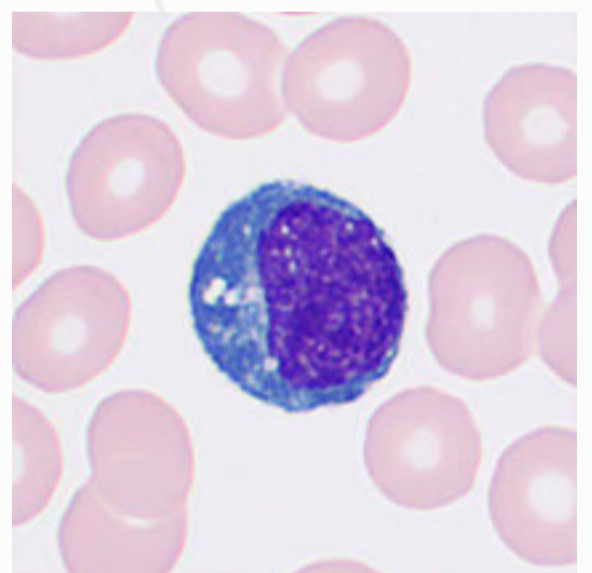
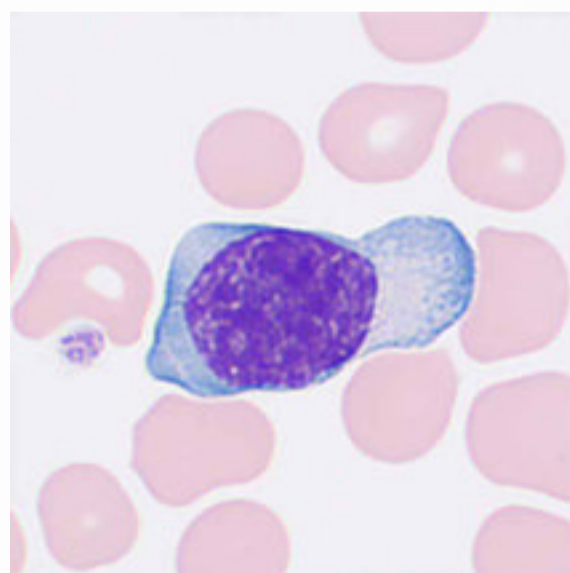
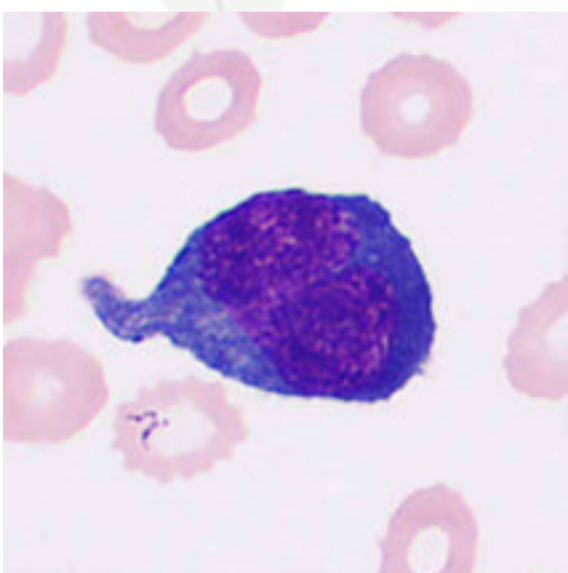
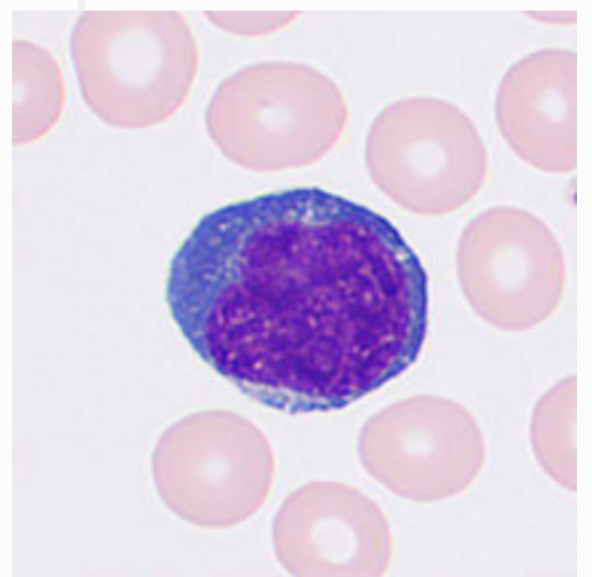
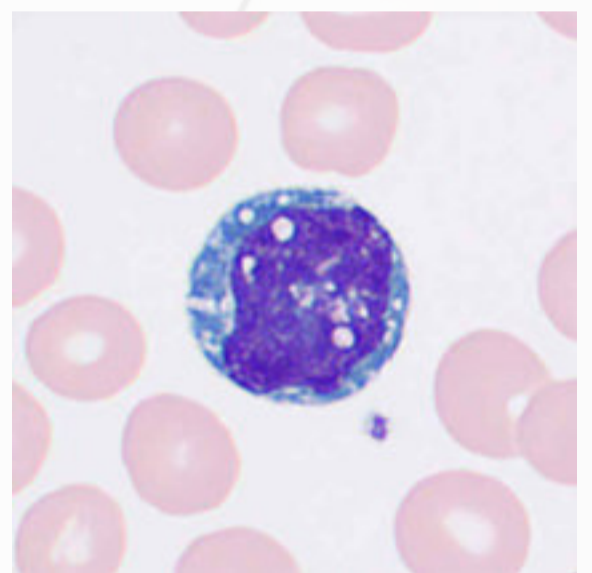
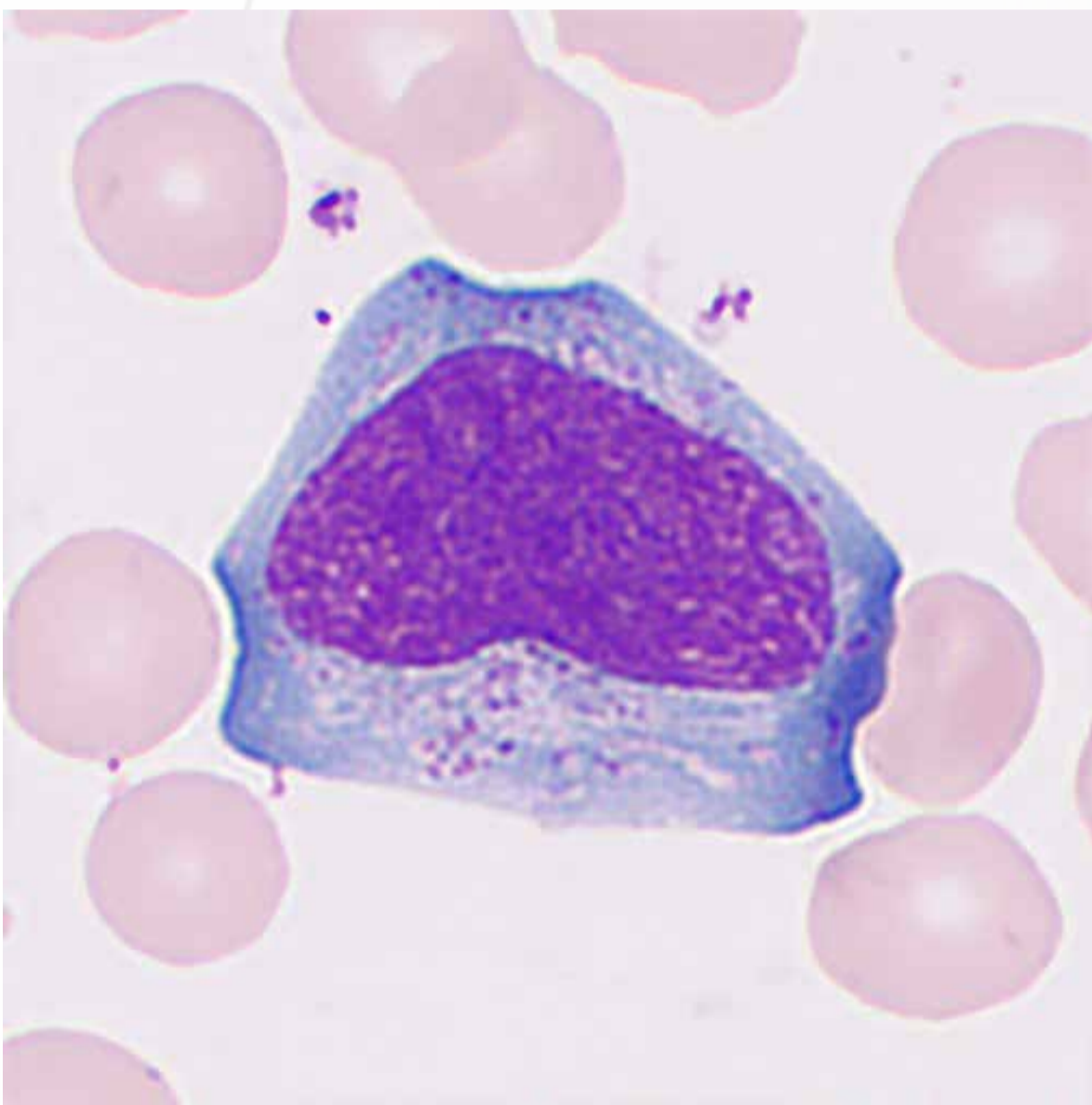
Neutrophilic metamyelocytes are round cells 10–16  $\mu\text{m}$  in diameter. The nucleus is significantly indented and kidney-shaped, semilunar, or horseshoe-shaped. The indentation is less than 1/2 the nucleus diameter and 1/2 to 3/4 the diameter of the nucleus when assuming it is round. The nucleus is often eccentric and anucleolate, with chromatin aggregation in small clusters and visible parachromatin. The cytoplasm is abundant, light blue and filled with neutral granules. Neutrophilic Metamyelocytes could present in peripheral blood under pathological conditions including AML, CLL, MDS, and severe infections.





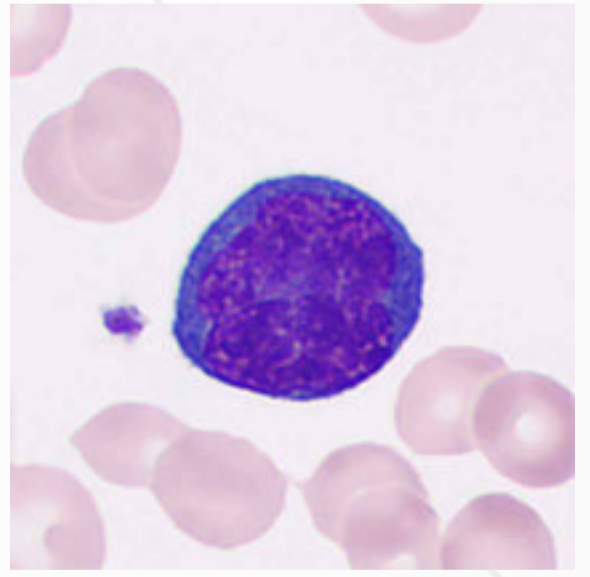
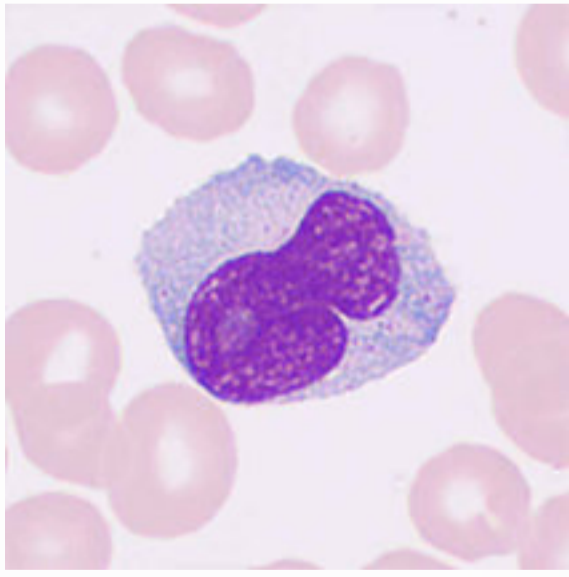
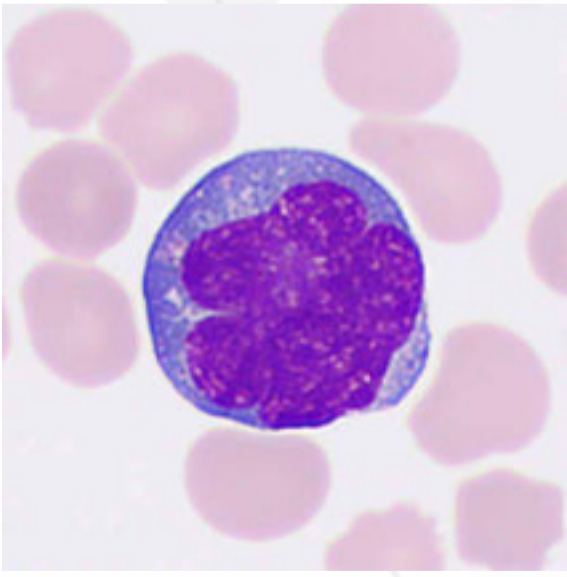
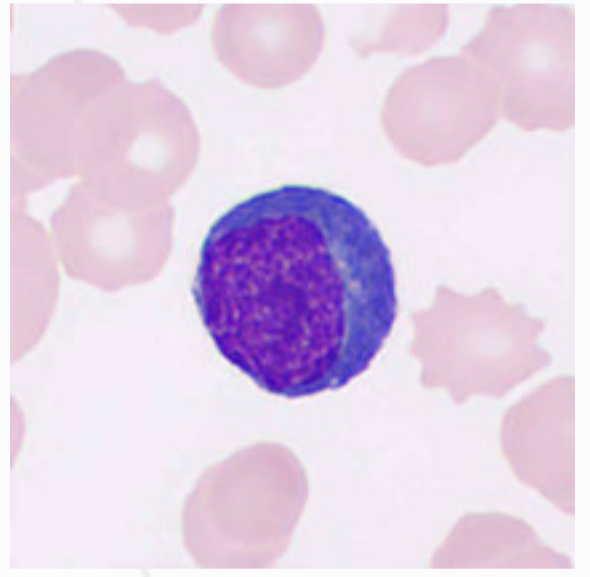
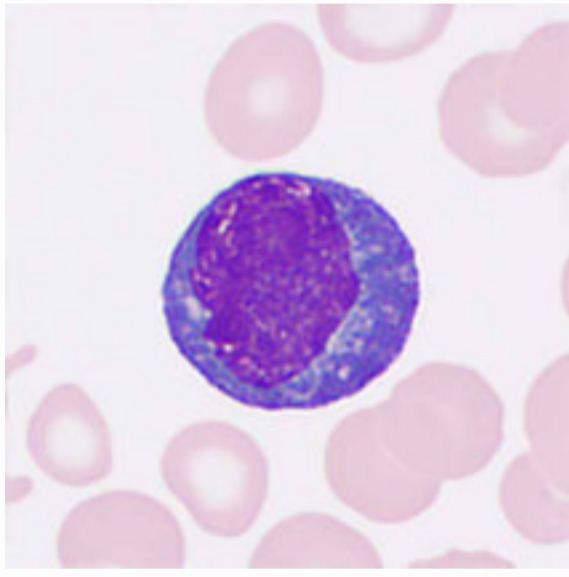
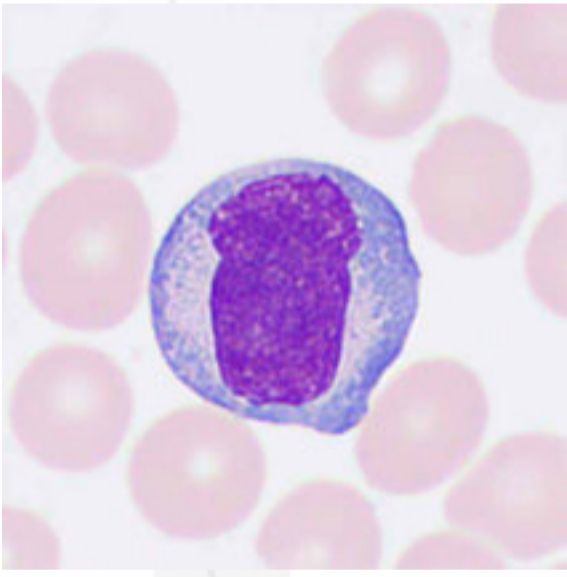
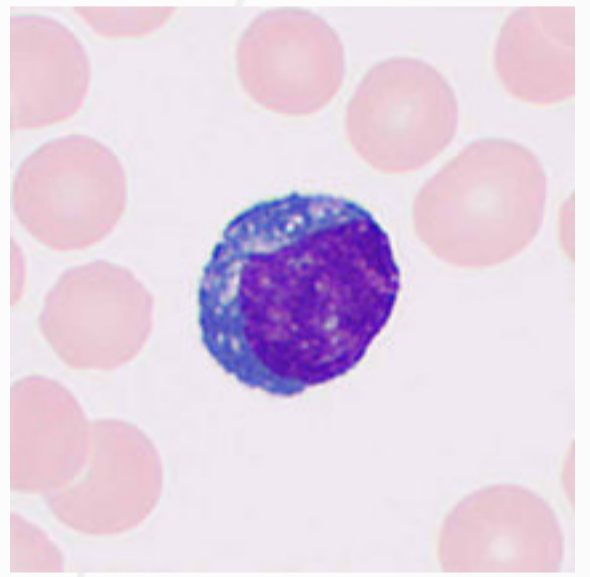
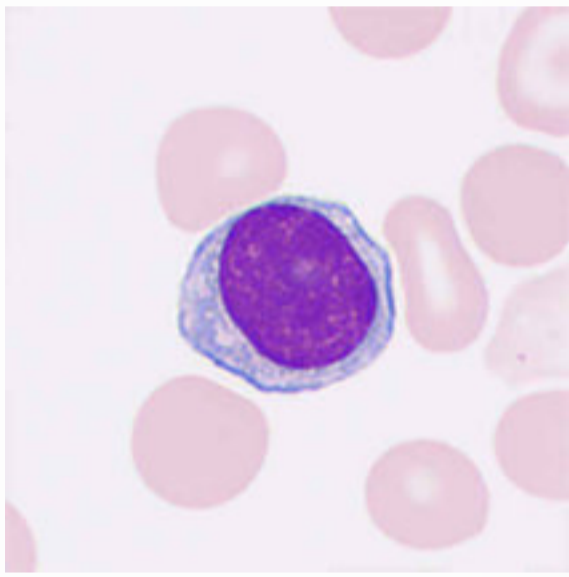
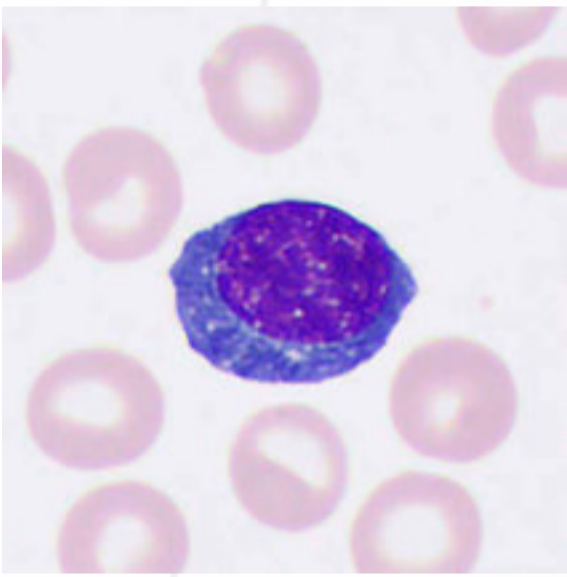
# Reactive Lymphocytes

Upon stimulation by viruses (e.g., adenovirus), protozoa (e.g., *Toxoplasma gondii*), drug reactions, connective tissue diseases, and other stimuli, lymphocytes may undergo proliferation and morphological changes such as cell swelling, increased cytoplasm, enhanced basophilia, and nuclear blastogenesis. Such lymphocytes are referred to as "reactive lymphocytes". They fall into three types depending on the morphological characteristics. Type I (vacuolated) is also known as foam cell or plasma cell type, type II (irregular) as monocytic type, and type III (naive) as immature cell type or prolymphocyte type.





The increase in reactive lymphocytes is typically seen in viral and allergic diseases such as infectious mononucleosis, viral hepatitis, epidemic hemorrhagic fever, and eczema.

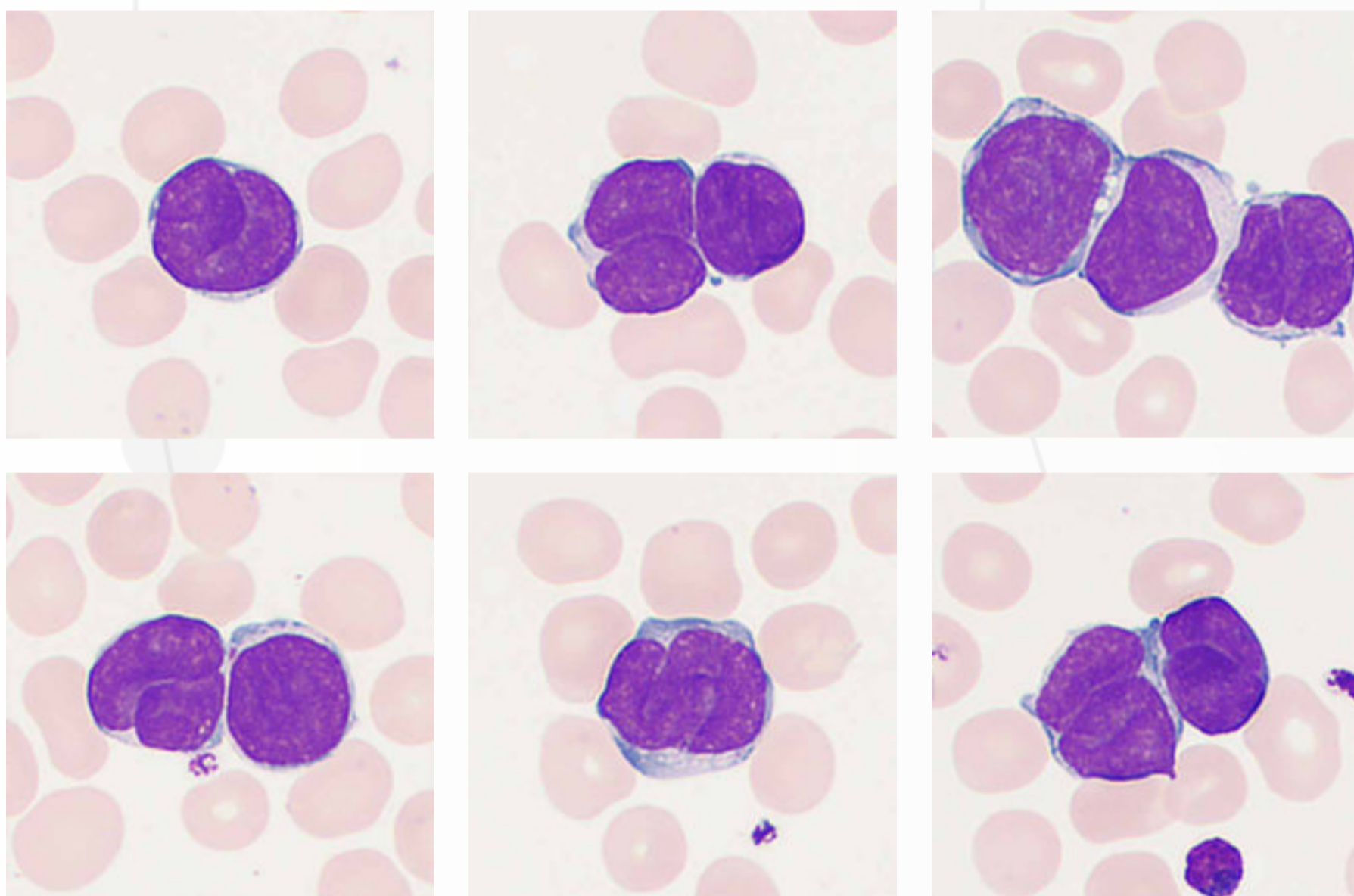


# Abnormal Lymphocytes

Abnormal lymphocytes, or atypical lymphocytes — suspected neoplastic are often used to describe the lymphocytic changes due to suspected malignant and monoclonal etiology. Abnormal lymphocytes are typically seen in Malignancies such as leukemia and lymphoma. These cells tend to exhibit a variable but highly homogeneous morphology in the blood of one patient, making it difficult to distinguish them from reactive lymphocytes. Any peripheral blood smear with suspected hairy cells, lymphoma cells, or prolymphocytes for the first time can be reported as abnormal lymphocytes, which is ultimately determined by flow cytometry immunophenotyping.

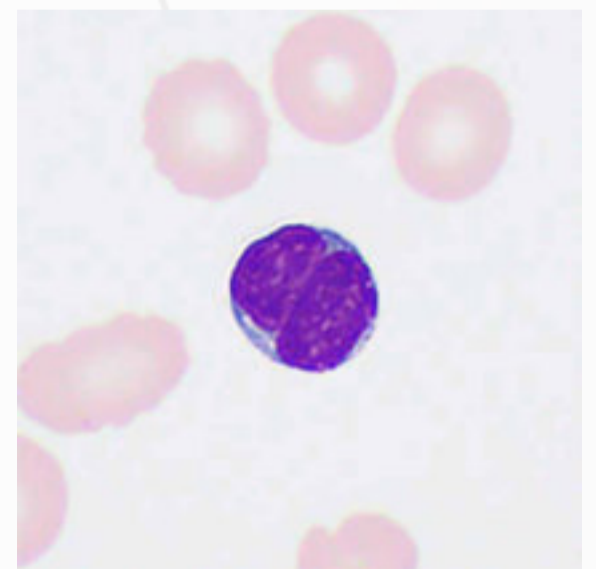
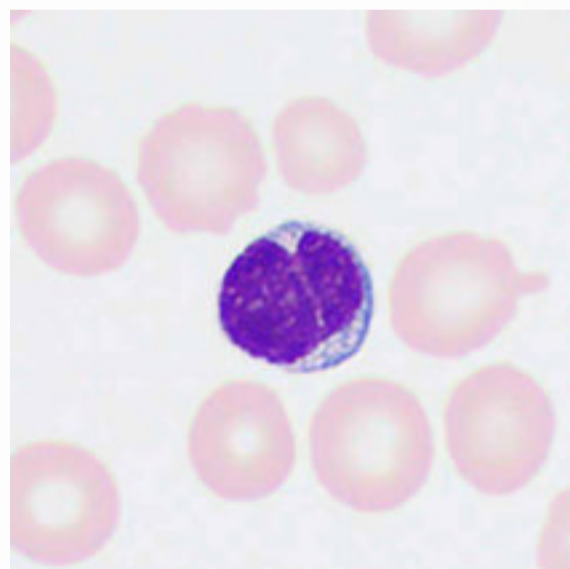
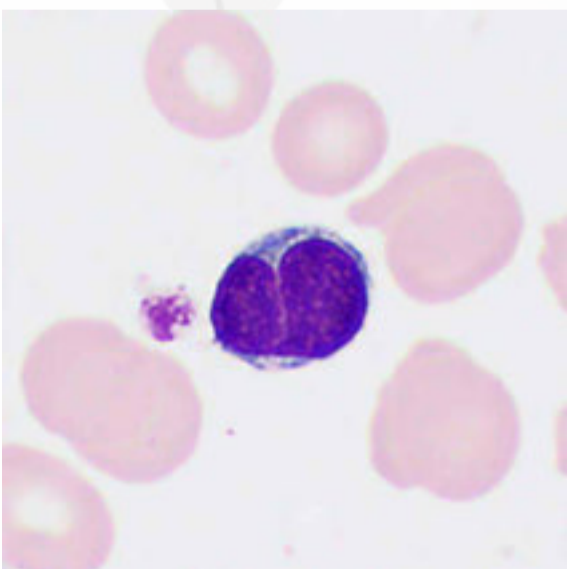
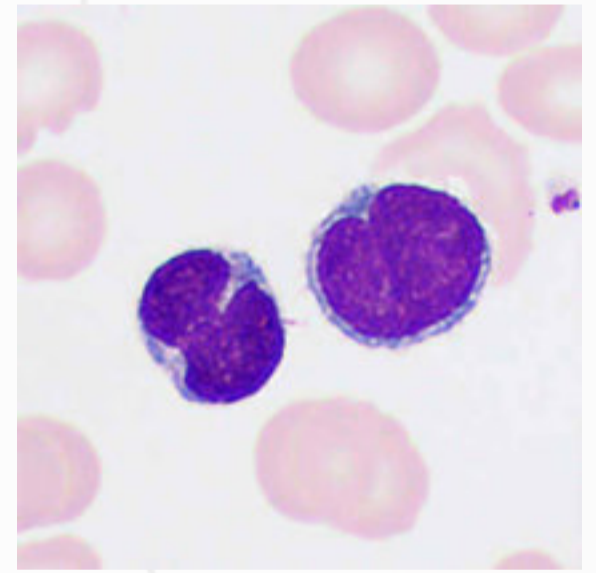
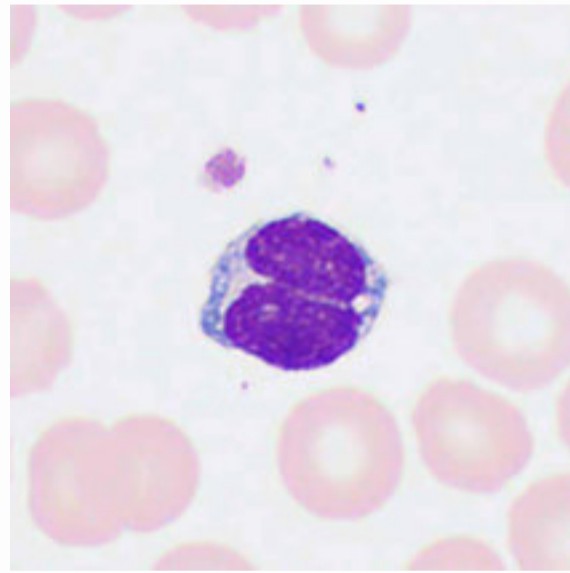
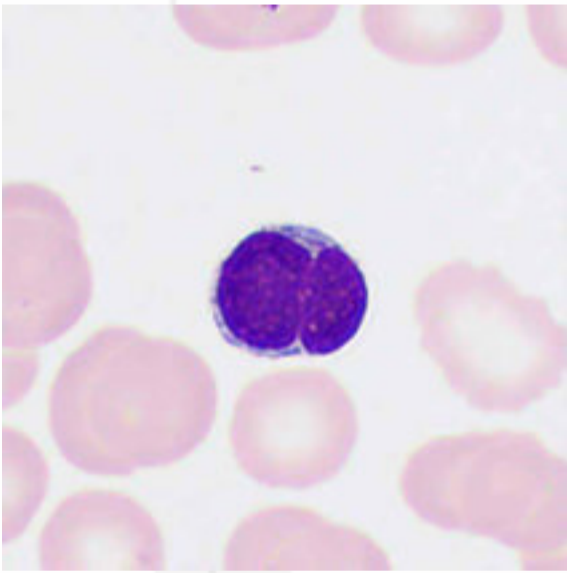
## Sézary Cells

Sézary cells are mature peripheral lymphoma T cells cells. They are anucleated, vary in size, and comprise coarse and dense chromatin. The cells have polymorphic nuclei that are twisted, deformed or lobulated, or folded like "brain gyrus", with scant cytoplasm in a blue or pale blue color.



## Lymphoma Cells

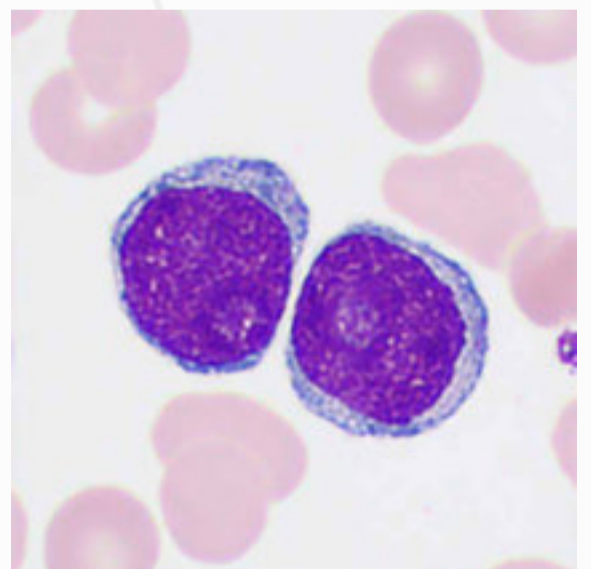
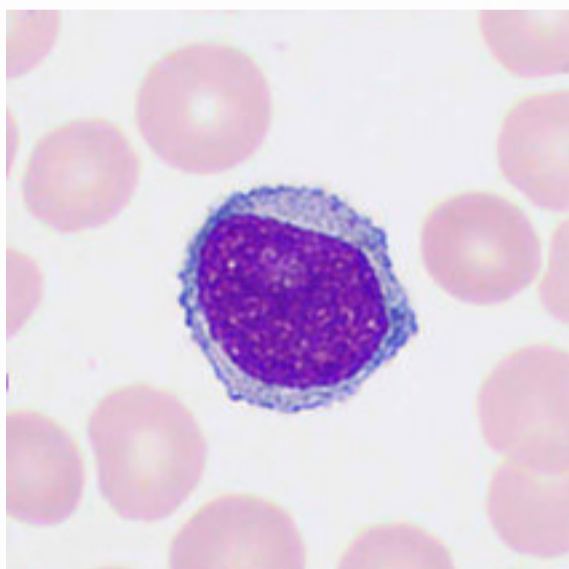
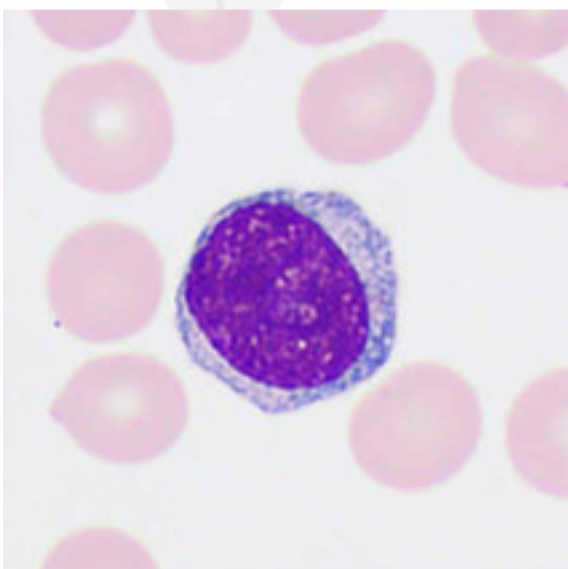
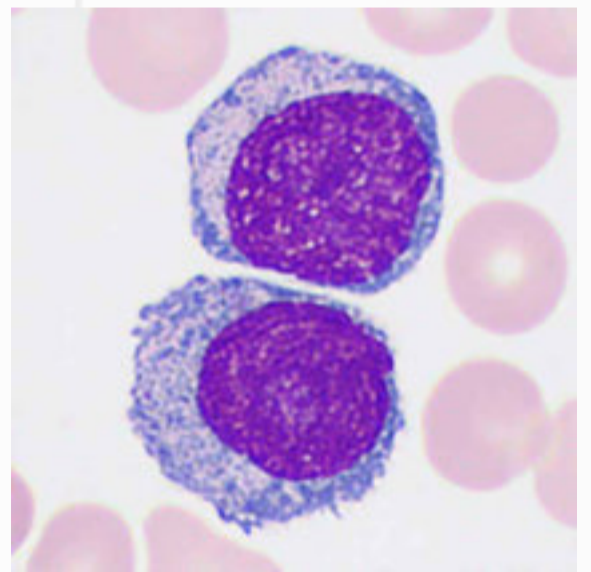
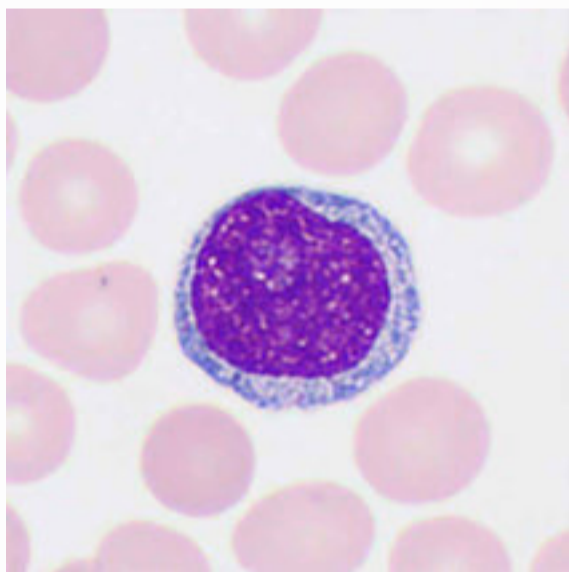
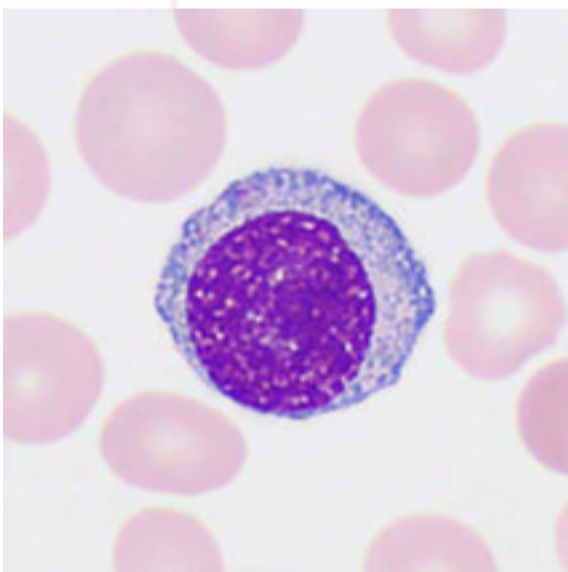
Lymphoma cells are malignant cells originating from T, B, or NK cells. The cell morphology is quite diverse and often exhibits the following characteristics: The cells vary significantly in size with regular or irregular shapes, and the nucleus is typically indented, twisted, folded, or has cut marks. the thickness of the chromatin is variable, with or without nucleolus; the cytoplasm may be abundant or scant, with a deep blue color, and sometimes with visible granules and vacuoles.



# Abnormal Lymphocytes

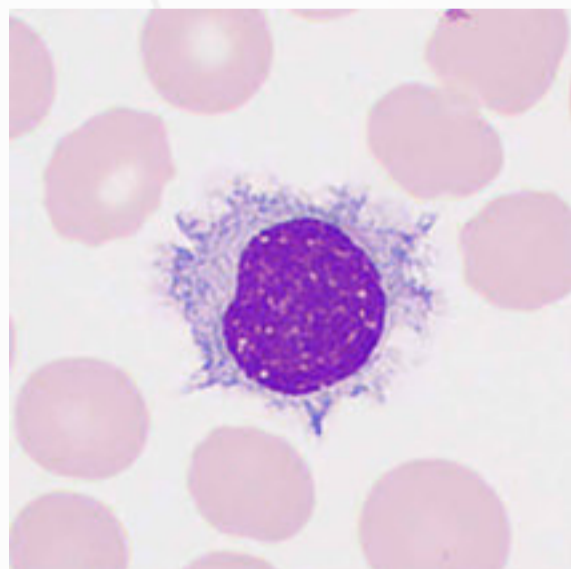
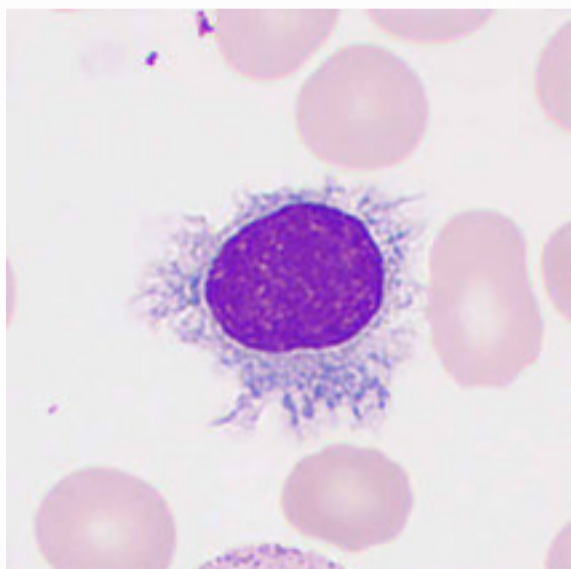
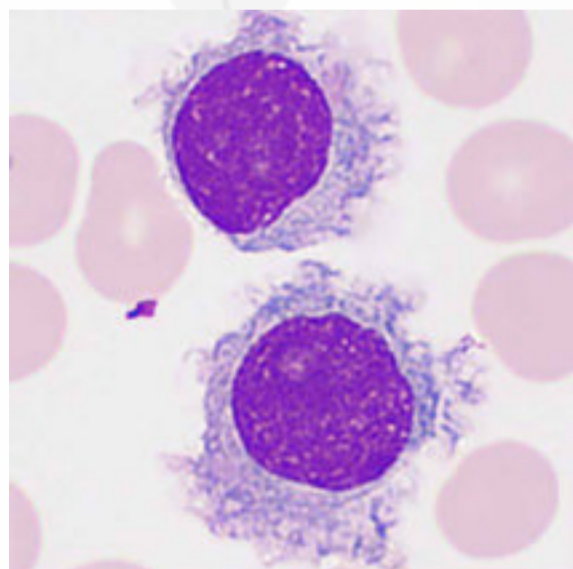
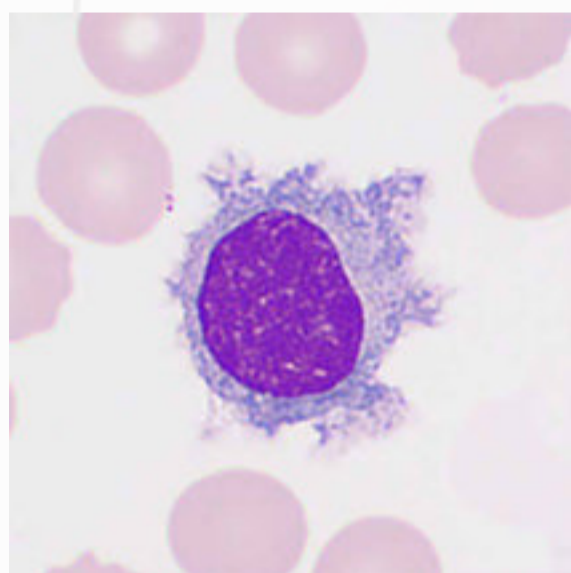
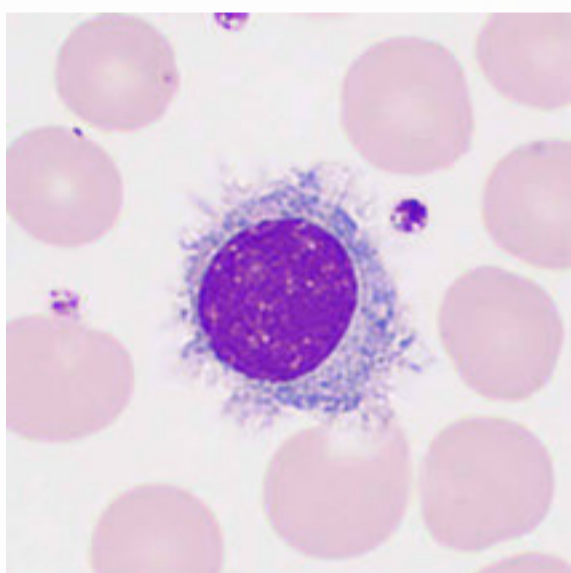
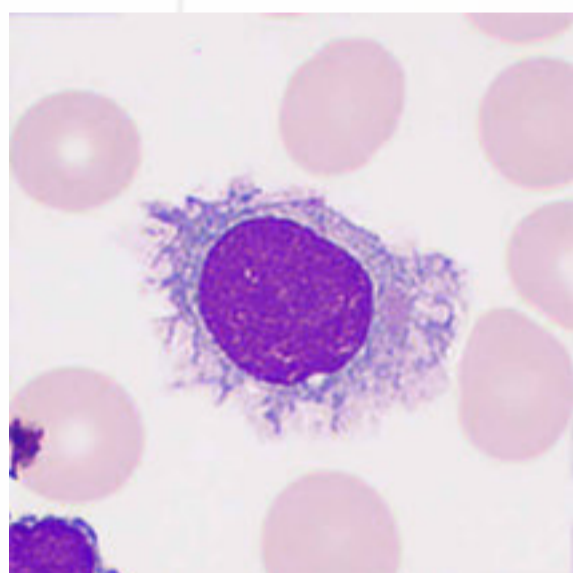
## Prolymphocytes

Lymphoblasts or prolymphocytes are present in the peripheral blood. Prolymphocytes are large cells, 12–14  $\mu\text{m}$  in diameter, with medium amount of cytoplasm in a pale blue color and a decreased nuclear-cytoplasm ratio. Their nucleus is generally round or oval with dense chromatin, either granular or clumpy, coarser than that of lymphoblasts but finer than that of mature lymphocytes. Typically, each prolymphocyte has a single large vesicular nucleolus. Prolymphocytes are typically seen in acute or chronic lymphocytic leukemia, viral infections, and lymphocytic leukemoid reactions.



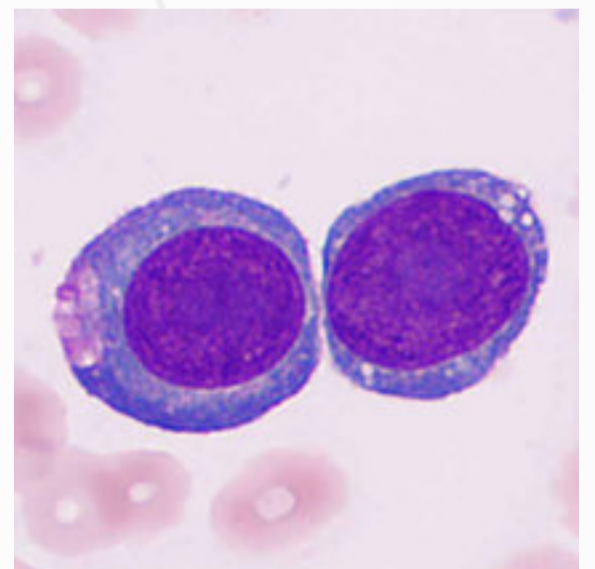
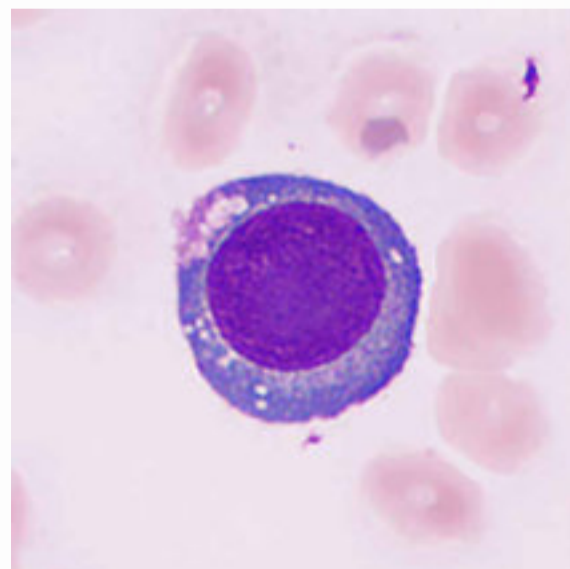
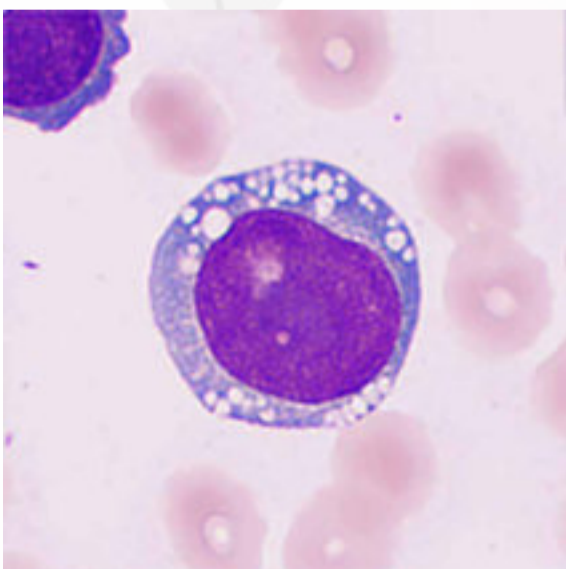
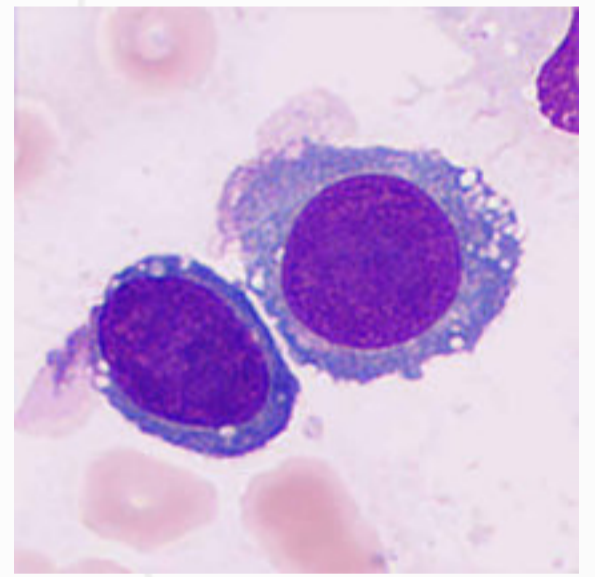
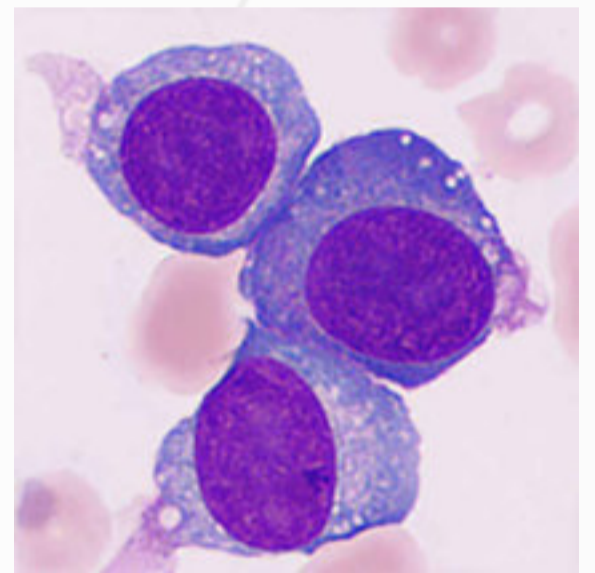
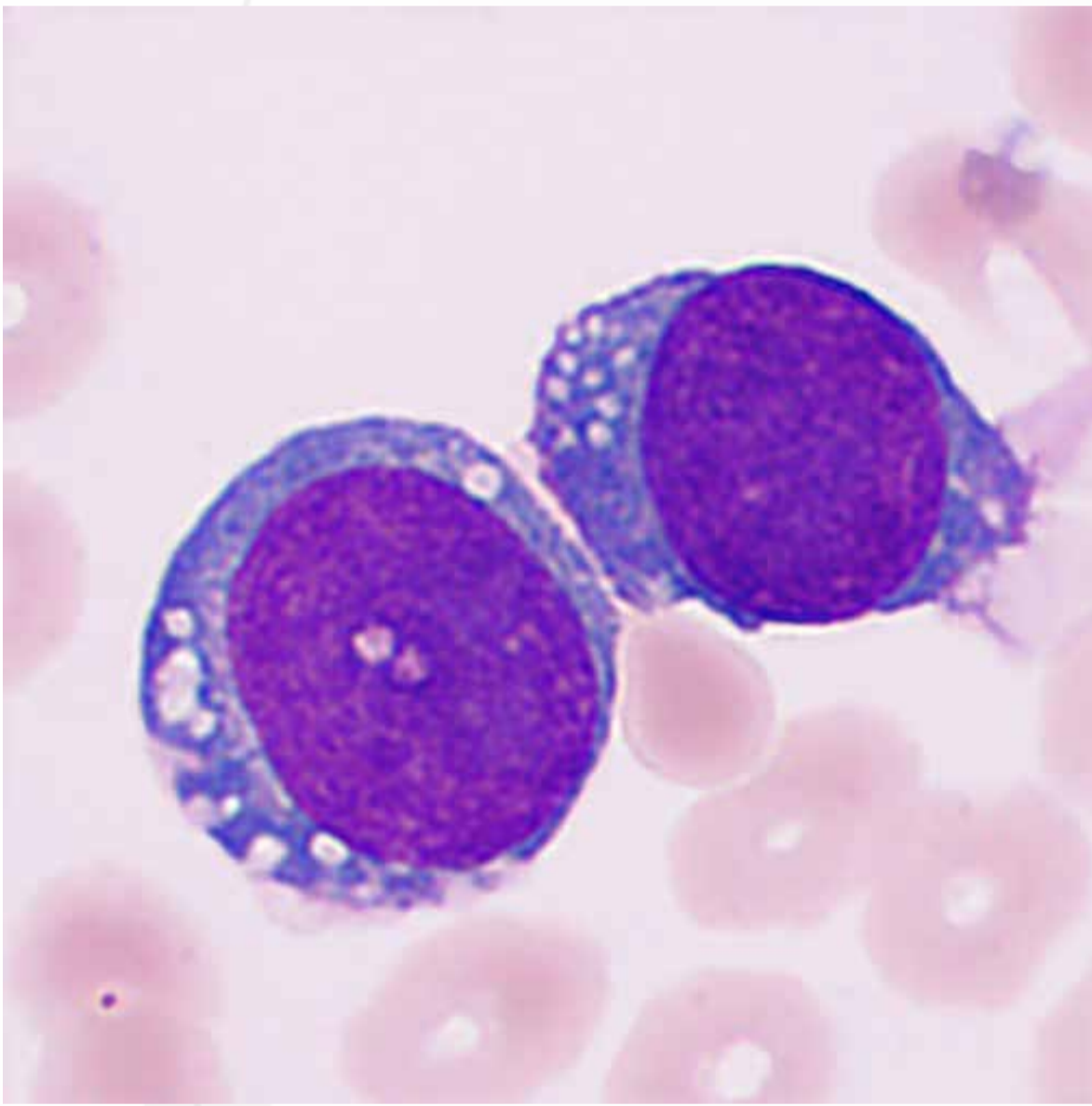
## Hairy Cells

Hairy cells are about two times larger than mature lymphocytes. The nucleus is round, oval, or indented and mildly folded. It is large and in the center of the cell or slightly deviated. Hairy cells have abundant cytoplasm with a blue or pale blue cloudy appearance. A prominent feature of hairy cells is the uneven margins with many irregular ciliated protrusions, also called "hair-like" protrusions, which are apparent when intravital staining is performed. Characteristic hairy cells are present in 90% of hairy cell leukemia. Hairy cells first identified in a blood smear should be counted as abnormal lymphocytes and the morphological features should be described in detail.

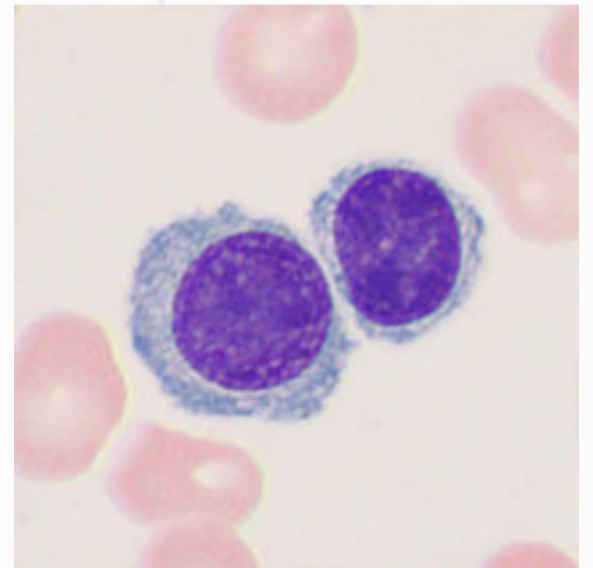
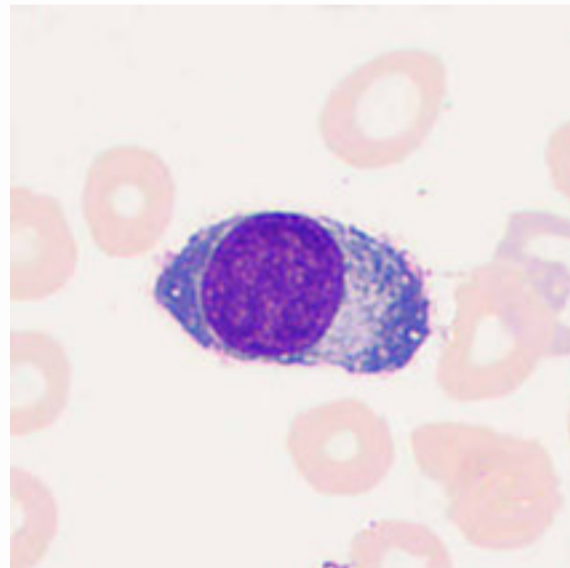
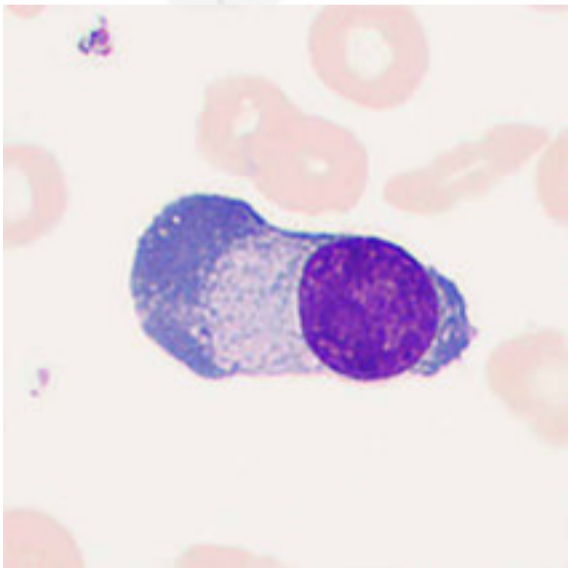
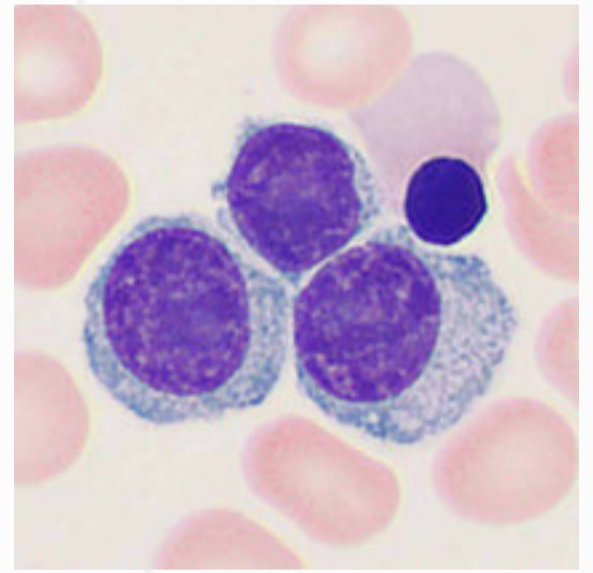
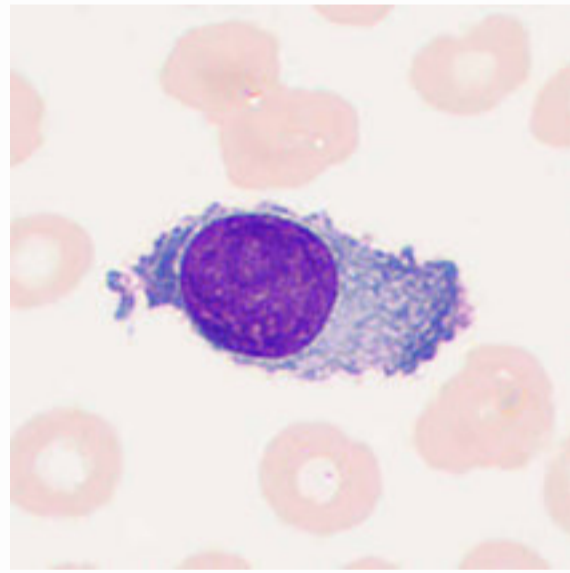
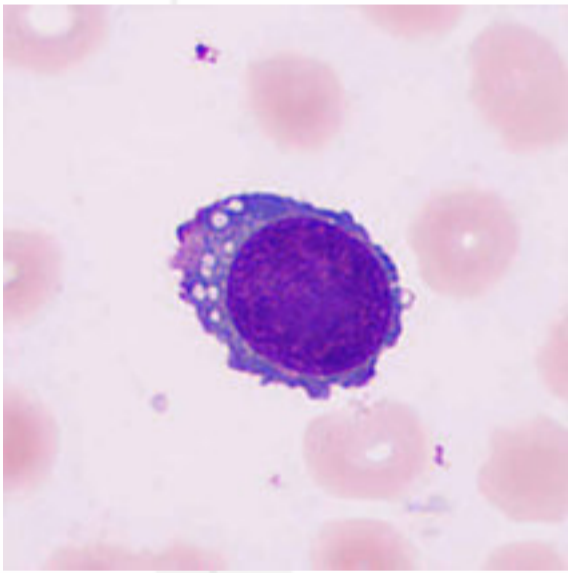
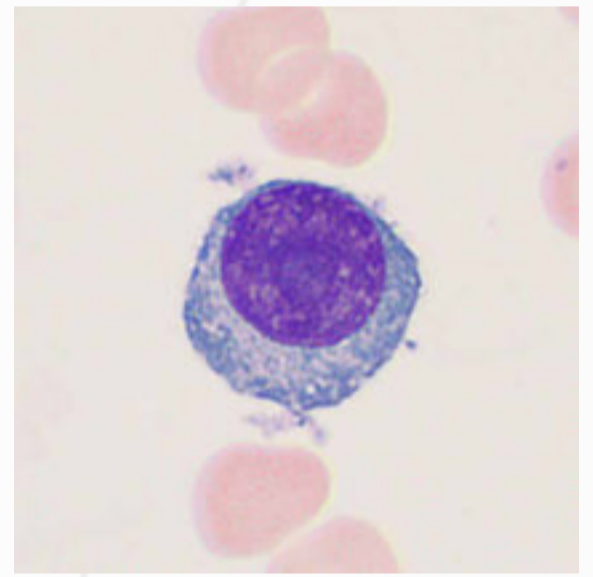
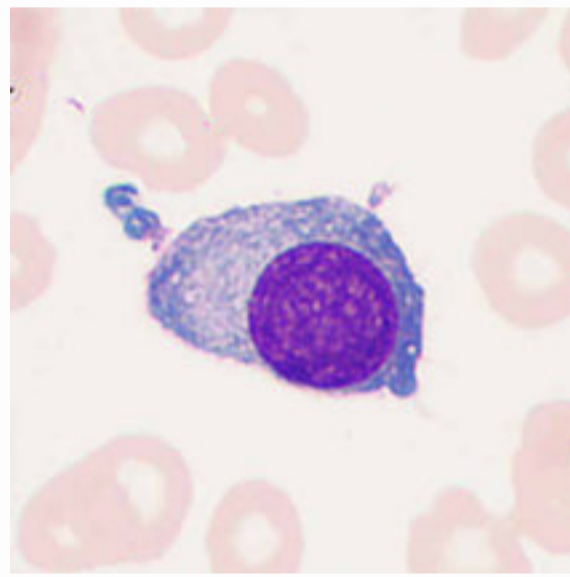
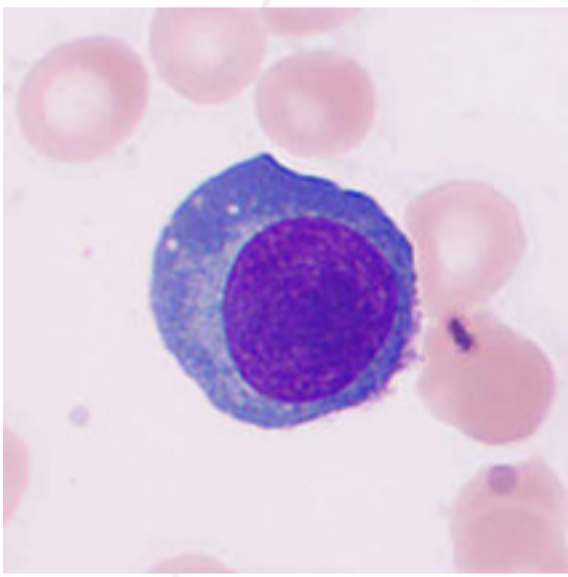


# Plasma Cells

Mature plasma cells vary in size with diameters ranging from 8 to 15  $\mu\text{m}$ . They generally have a small and eccentric nucleus, which is round and accounts for less than 1/3 of the volume. The chromatin is agglomerated into large blocks in which parachromatin is visible. The cells are anucleolate and their cytoplasm is deep blue and opaque, often with numerous vacuoles (foamy cytoplasm). Typically, a distinct perinuclear halo area next to the nucleus is visible.



Plasma cells are generally not found in peripheral blood smears of healthy individuals. A small number of abnormal plasma cells (myeloma cells) are visible in the peripheral blood of patients with multiple myeloma. Typical myeloma cells are larger than mature plasma cells, irregular in shape, and may have pseudopods. The cells have a large nucleus, loose and delicate chromatin, one to two large and obvious nucleoli, and abundant blue cytoplasm. Abnormal plasma cells may also be found in the peripheral blood of patients with plasma cell leukemia.

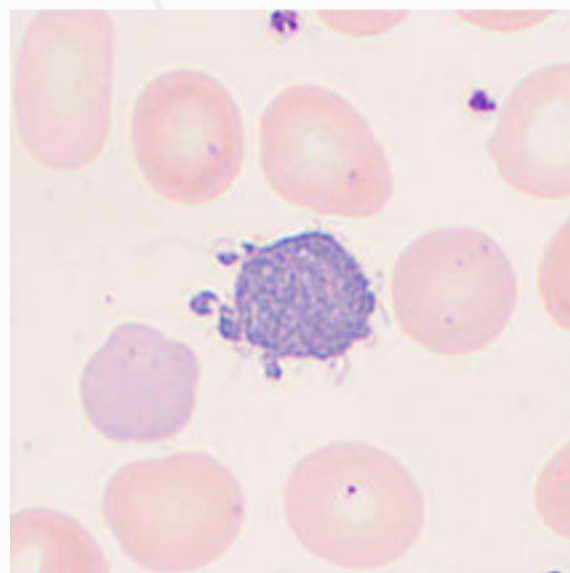
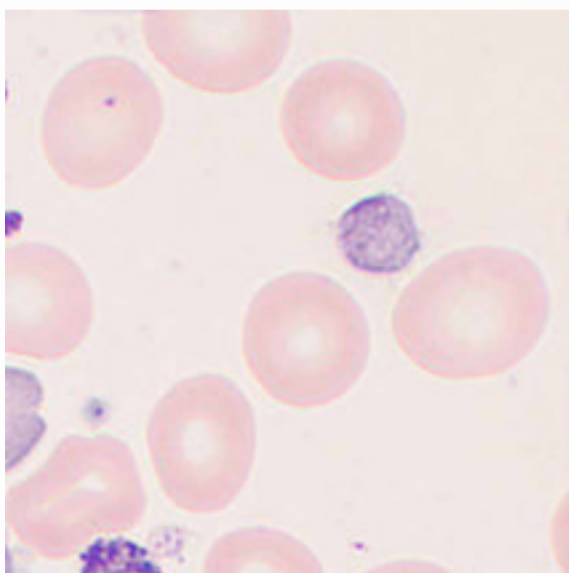
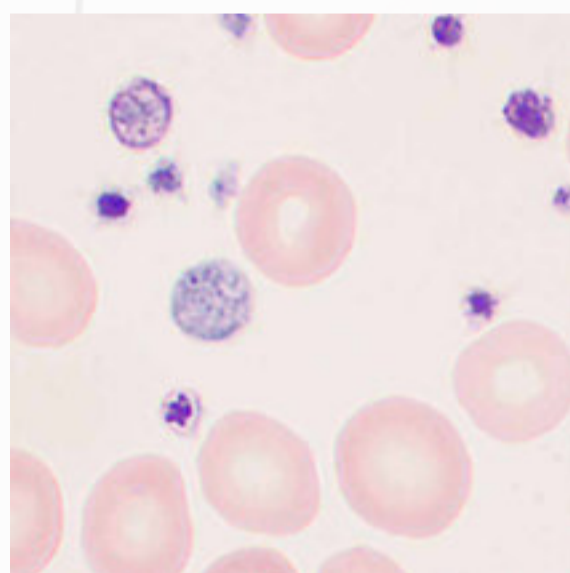
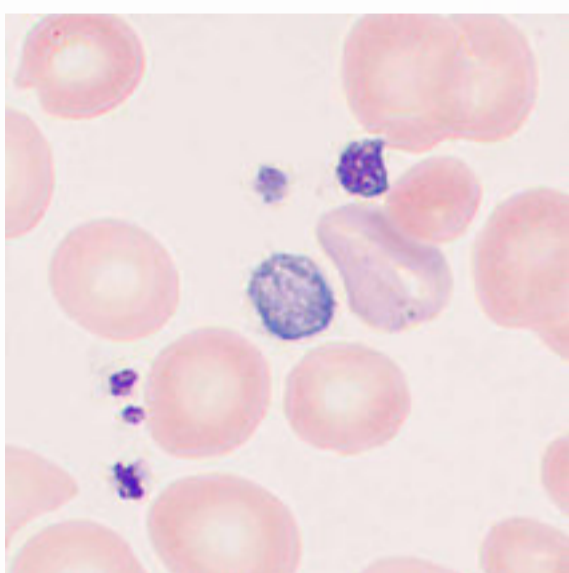
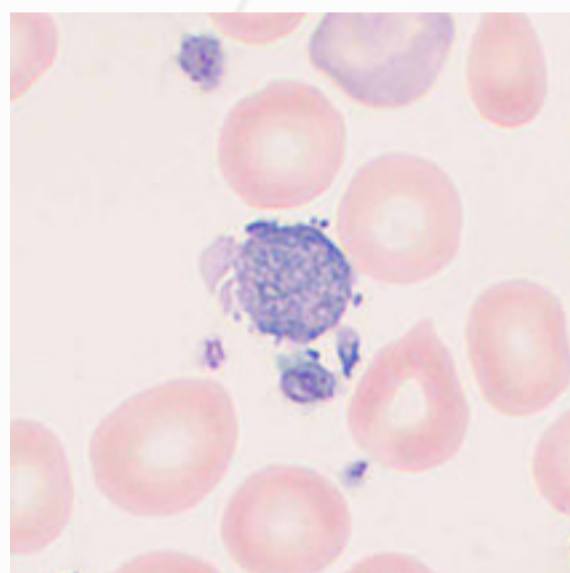
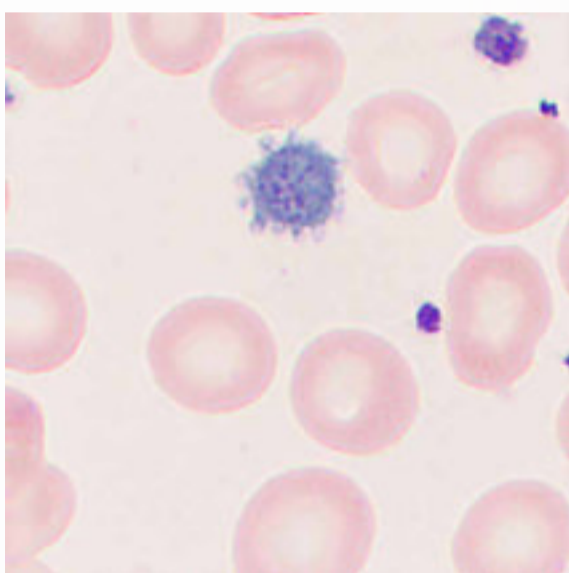


# Abnormal Platelets

Abnormalities of platelets may occur in size, morphology, aggregation, and distribution. In physiological conditions, there are 0.7% to 2.0% giant platelets, 8% to 16% large platelets, 44% to 49% medium platelets, and 33% to 44% small platelets. A low percentage of platelets with morphological abnormalities could be found in peripheral blood, such as rod-, tadpole-, or snake-shaped platelets. Clinical abnormalities should be considered when there are over 10% of irregular and bizarre platelets. Abnormal platelets can be found in MDS, granulocytic leukemia, post-splenectomy complications, TTP, and giant platelet disorders.

## Gray Platelets

The name "gray platelet" derives from the gray appearance of the enlarged platelets under light microscopy after Wright's staining, mainly caused by the reduction or absence of platelet granules and protein contents. These cells are commonly seen in gray platelet syndrome (GPS). The main clinical manifestation is mild to moderate bleeding, which is often accompanied by myelofibrosis and splenomegaly.





---

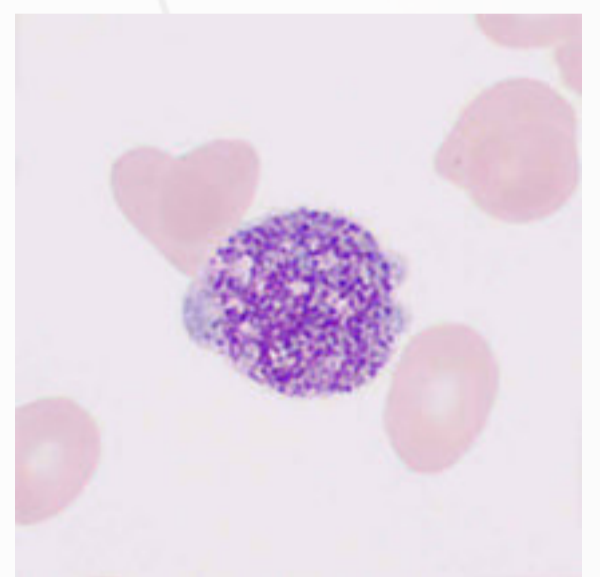
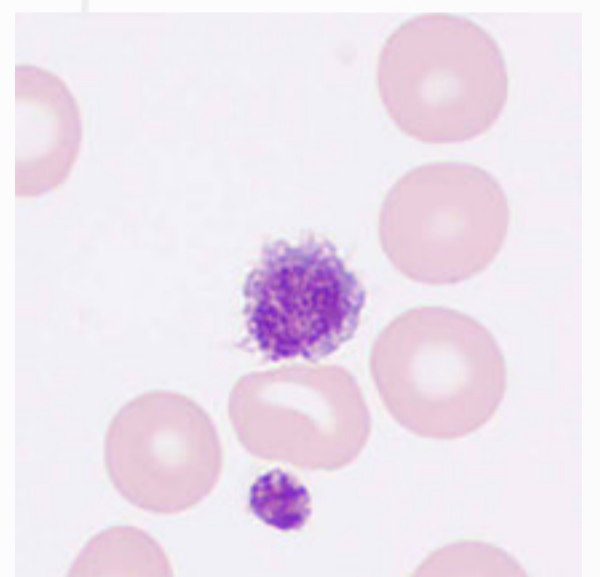
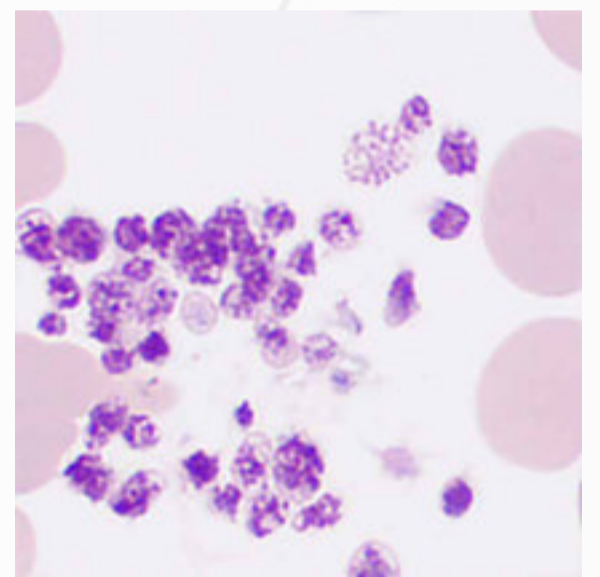
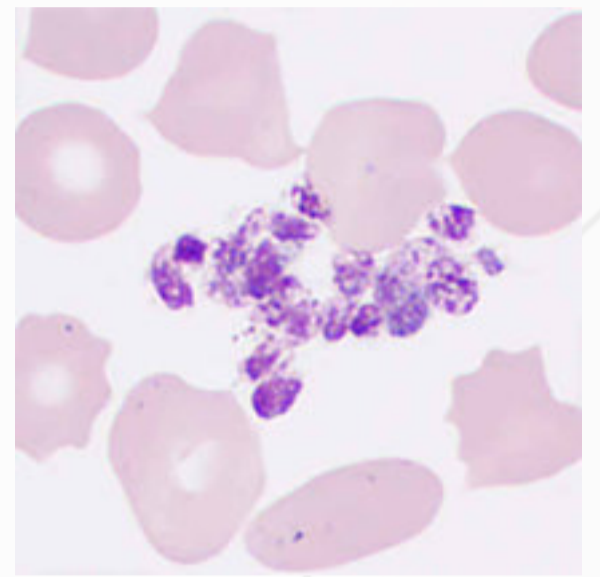
## PLT Aggregation

Platelets are usually distributed scattered in anticoagulated blood smears. Platelet aggregations can result in spurious low platelet counts using the impedance counting method by hematology analyzers. The leading causes of platelet aggregation are thrombocythemia and platelet activation because of myeloproliferative neoplasms or improper blood sampling or mixing methods. It could also be observed in EDTA-PTCP blood samples because the EDTA-dependent antibodies interact with platelet glycoproteins IIb/IIIa. Platelet aggregations in EDTA-PTCP samples could be resolved by re-collecting the blood sample in tubes with non-EDTA anticoagulants (e.g., citrate) or using hematology analyzers with PLT deaggregation functions.

---

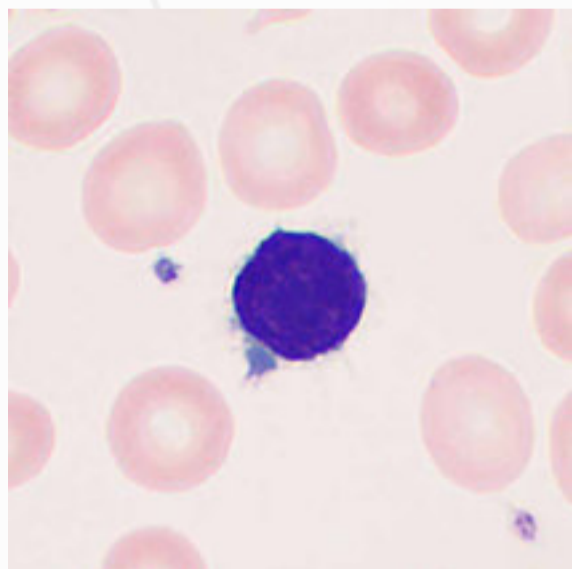
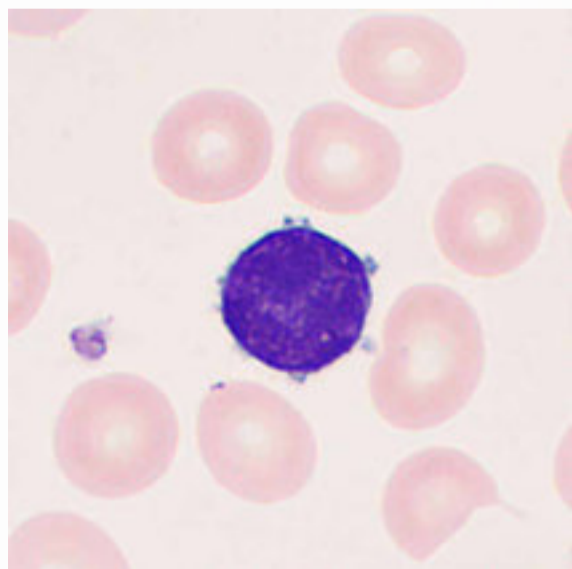
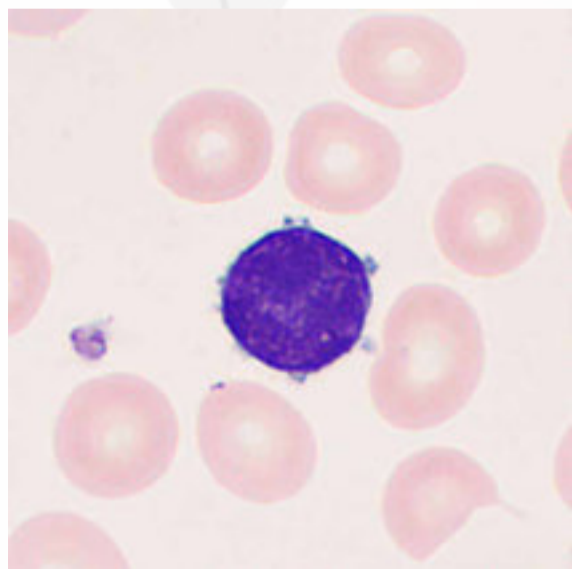
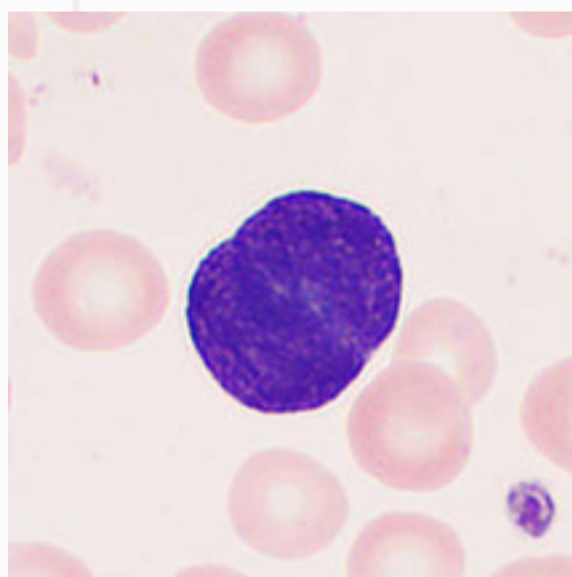
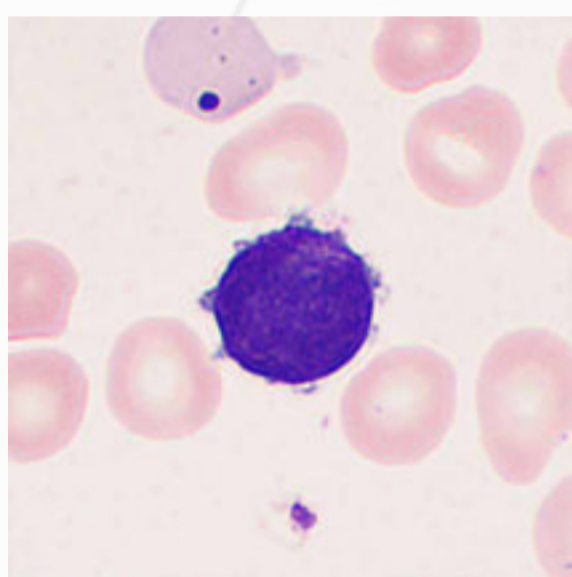
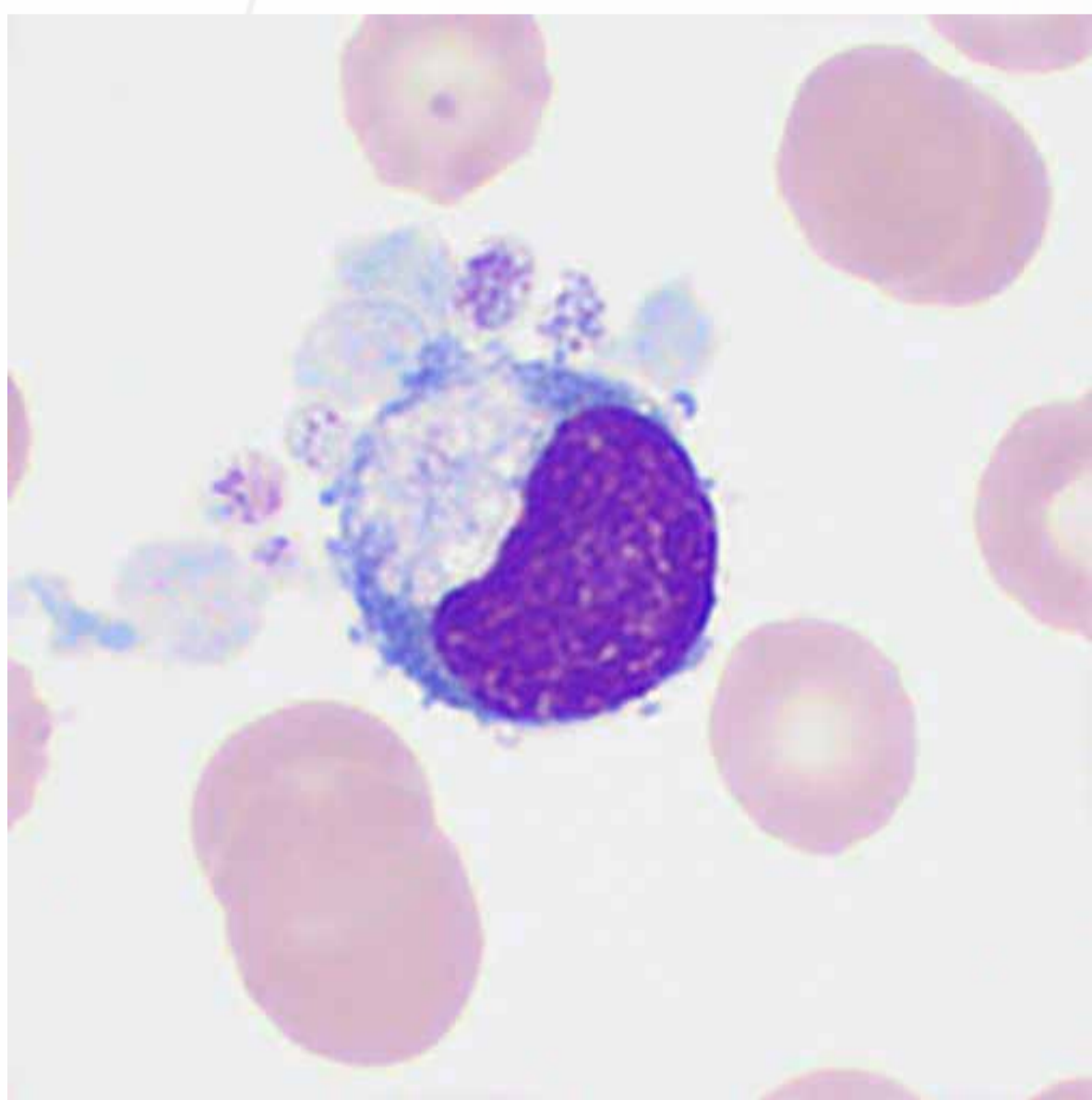
## Large & Giant PLTs

Large platelets are usually 4–7  $\mu\text{m}$  in diameter, similar to or slightly smaller than red blood cells. Giant platelets are generally larger than red blood cells, usually 7–20  $\mu\text{m}$  and sometimes  $> 20 \mu\text{m}$  in diameter. Their cytoplasm generally contains fine azurophilic granules or large fused granules. Large and giant platelets are mainly observed in ITP, MDS, Bernard-Soulier syndrome, Glanzmann thrombasthenia, and post-splenectomy complications. Increasing large and giant platelets can cause spurious low platelet counts when using the impedance counting method by hematology analyzers.

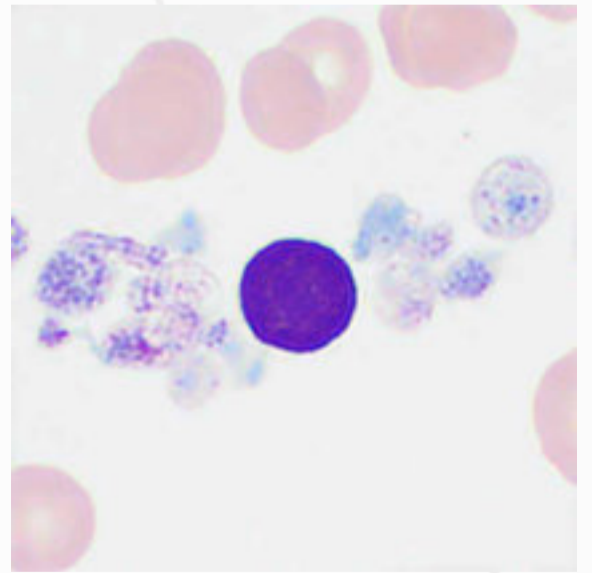
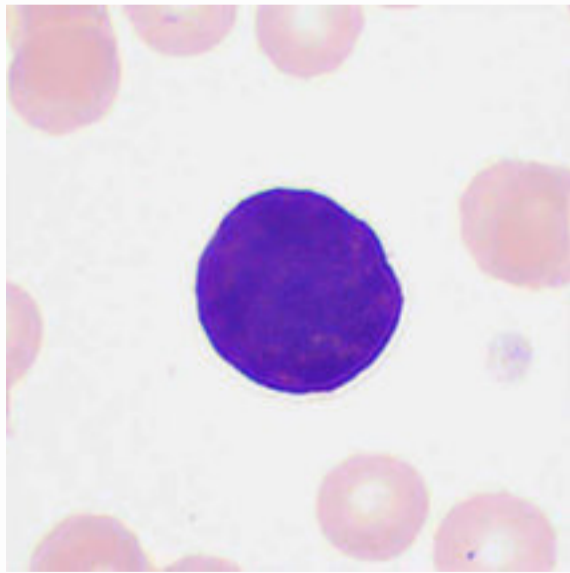
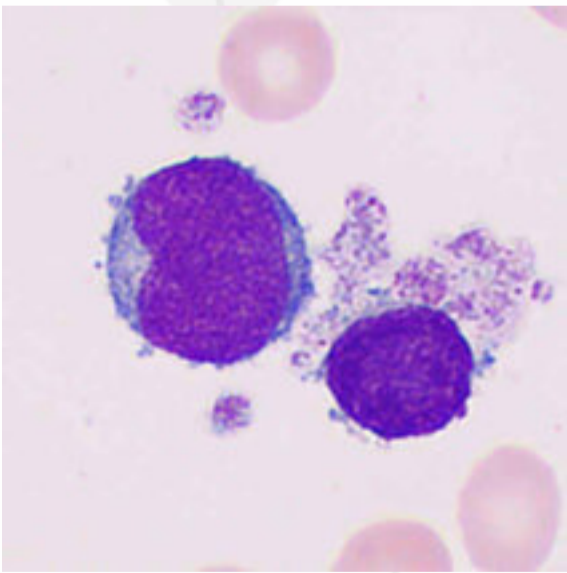
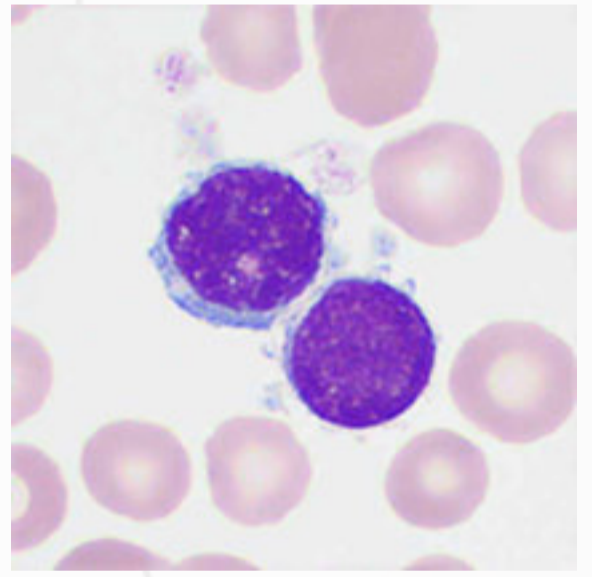
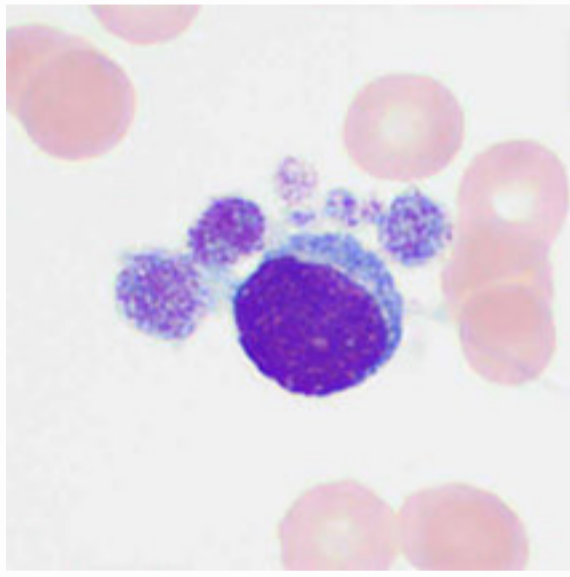
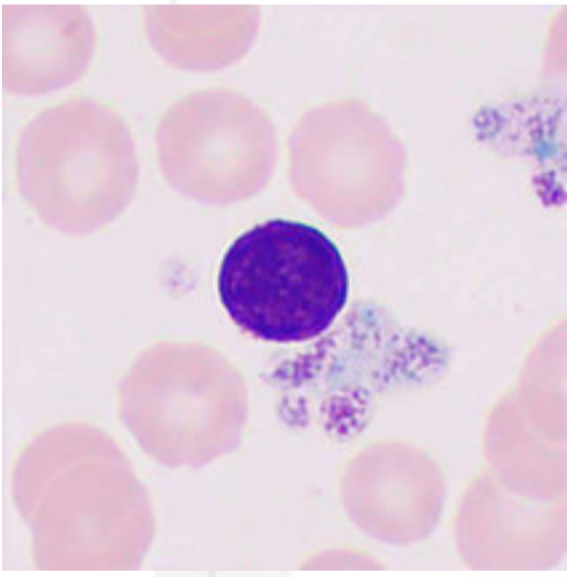
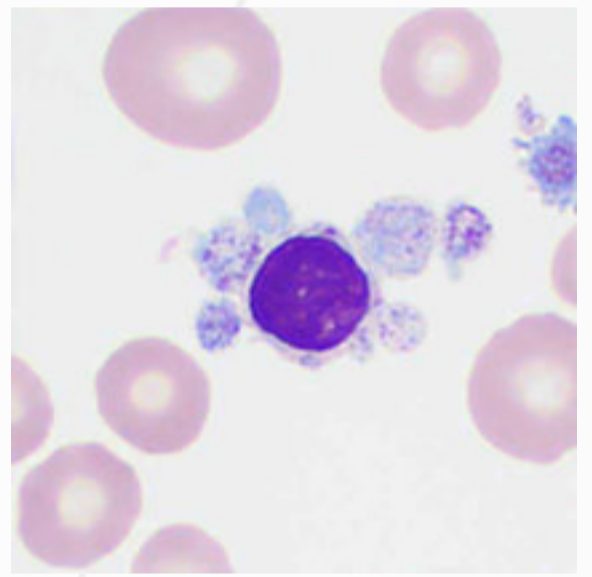
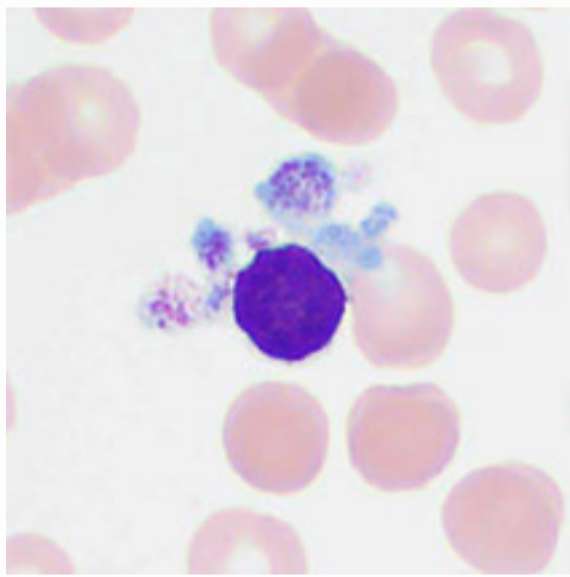
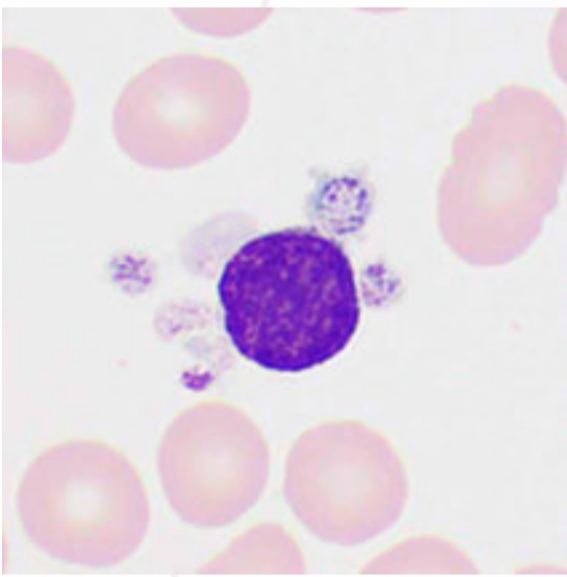


# Megakaryocytes

Generally, megakaryocytes are not found in the peripheral blood of healthy individuals. Some pathological megakaryocytes characterized by abnormal nuclei, such as small megakaryocytes, lymphoid megakaryocytes, and binucleated megakaryocytes, can be observed in patients with acute megakaryocytic leukemia, MDS, MPN, MDS/MPN, AML and malignancies.

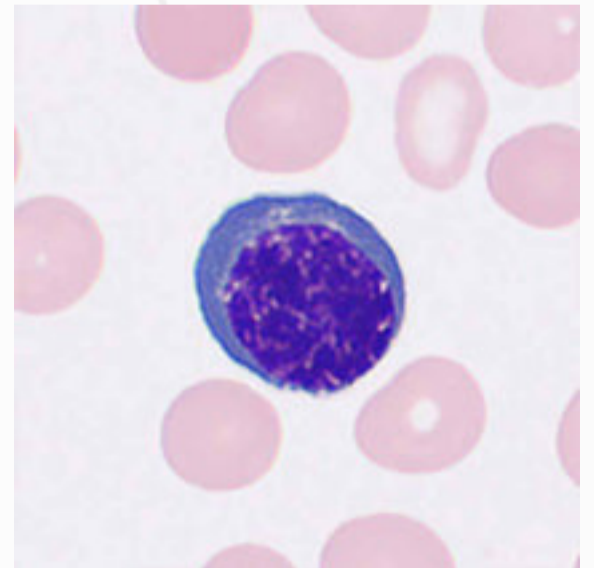
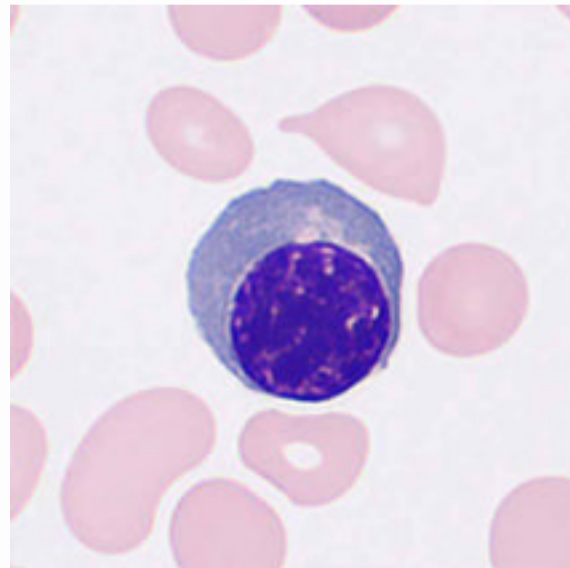
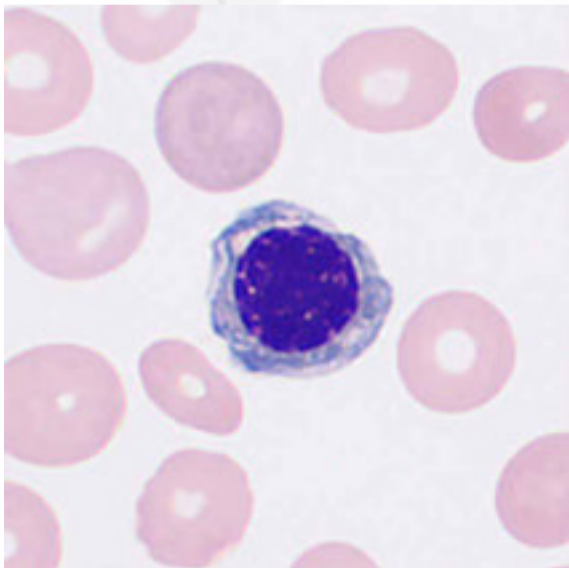
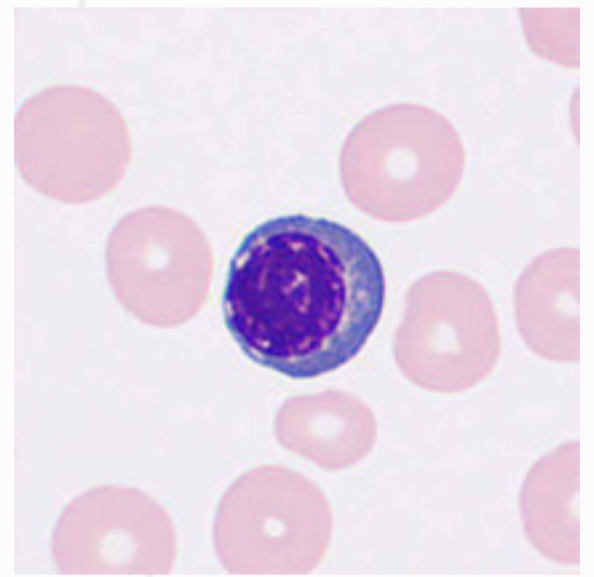
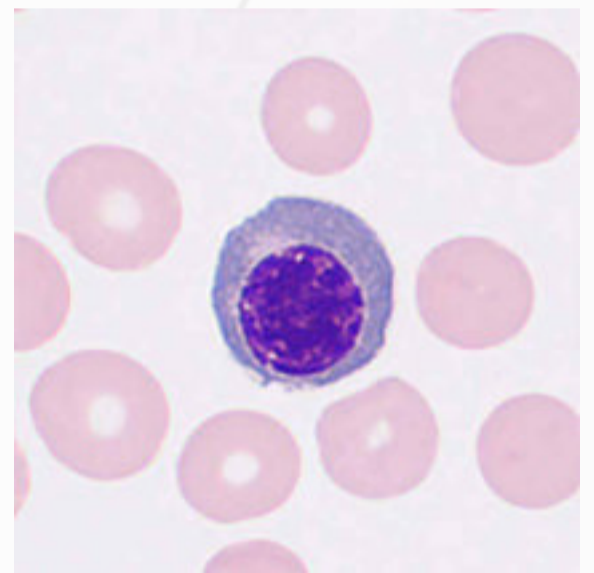
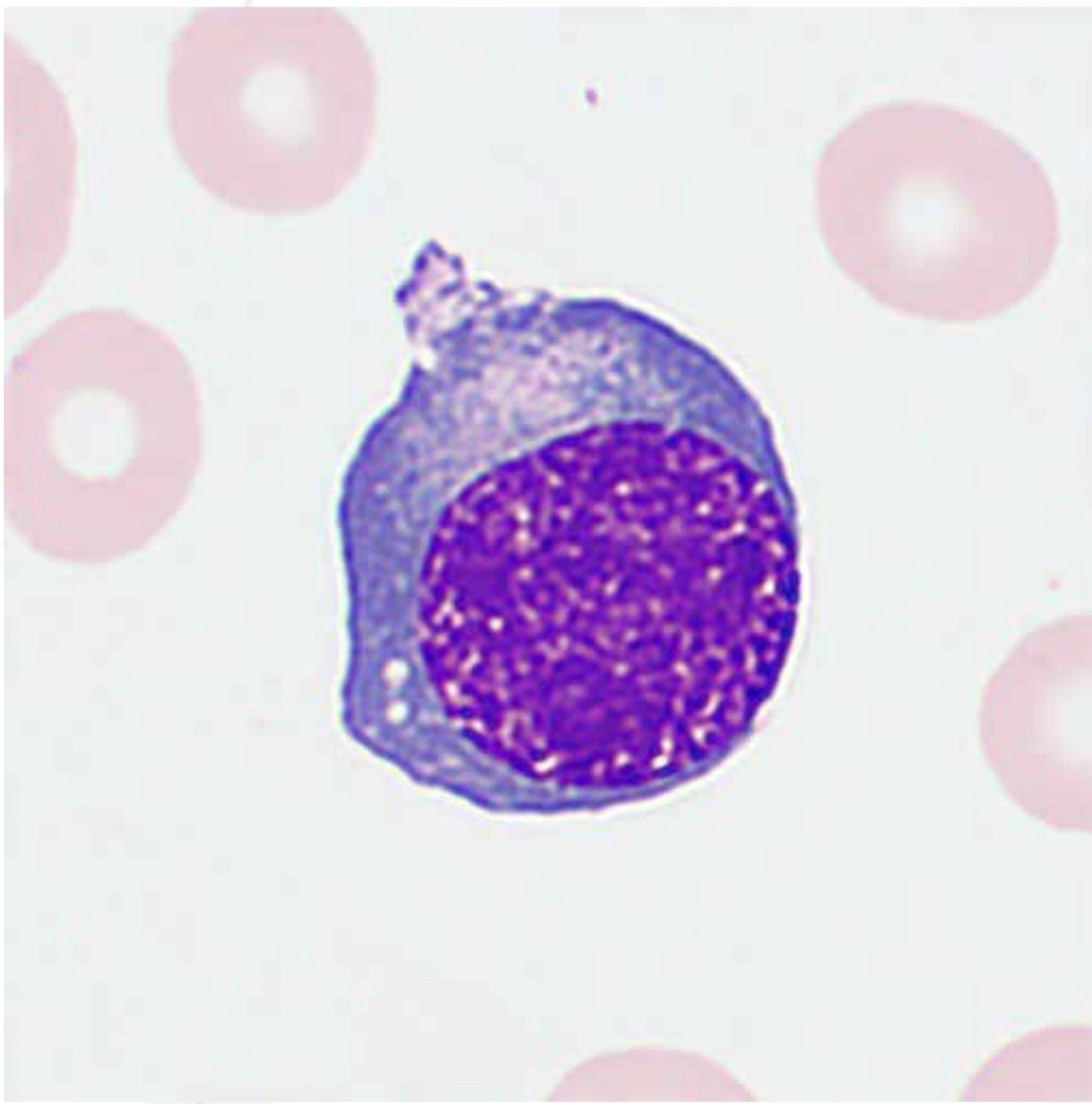


Small megakaryocytes: Some of them are similar to lymphocytes in size (i.e. lymph-like small megakaryocytes), with a diameter of 5–8  $\mu\text{m}$ . They are typically mononucleated and anucleolate, and round or oval in shape, with scanty, pale blue cytoplasm that may contain a variable number of violet-red granules.

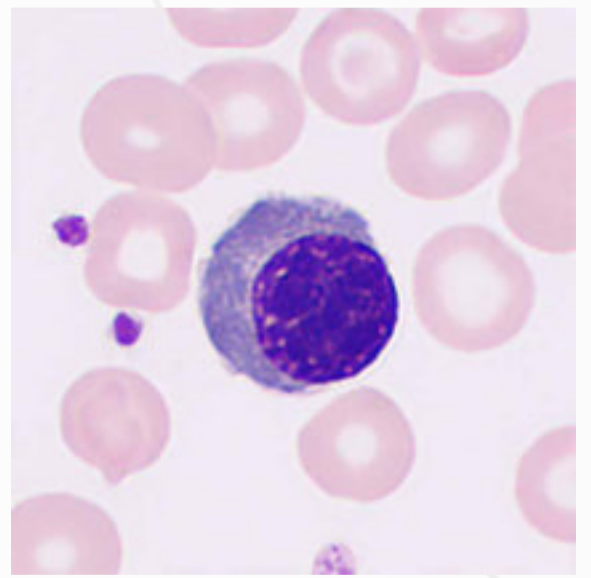
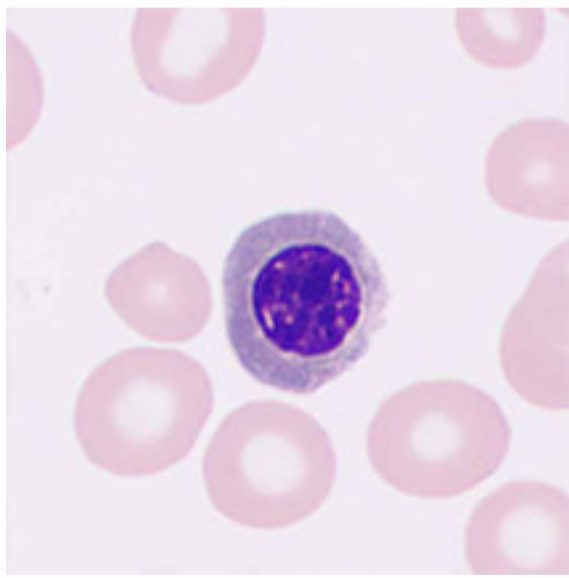
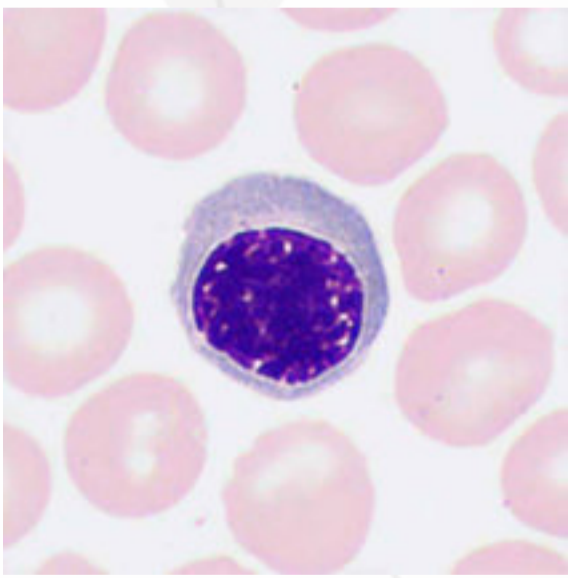
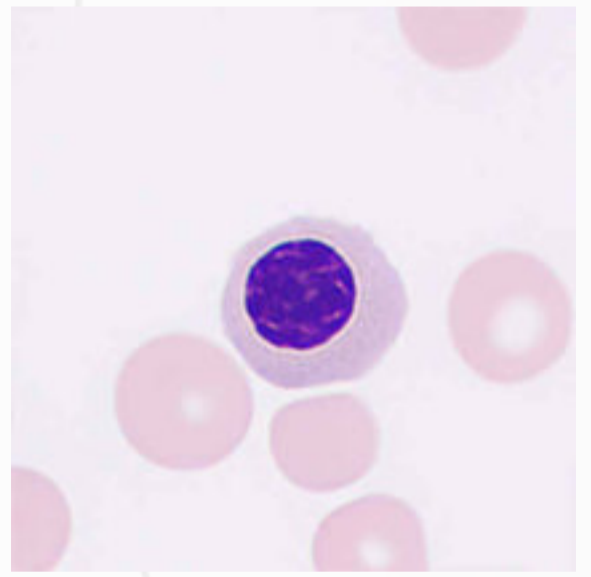
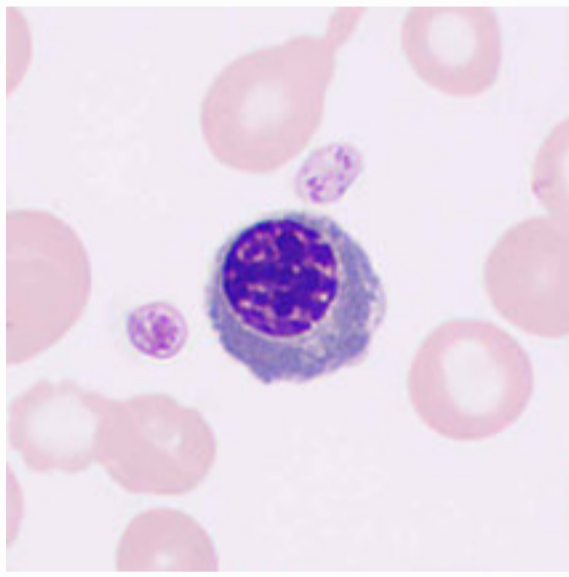
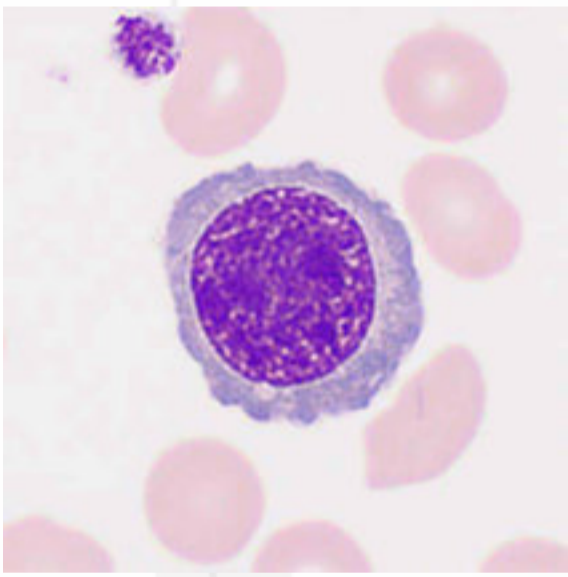
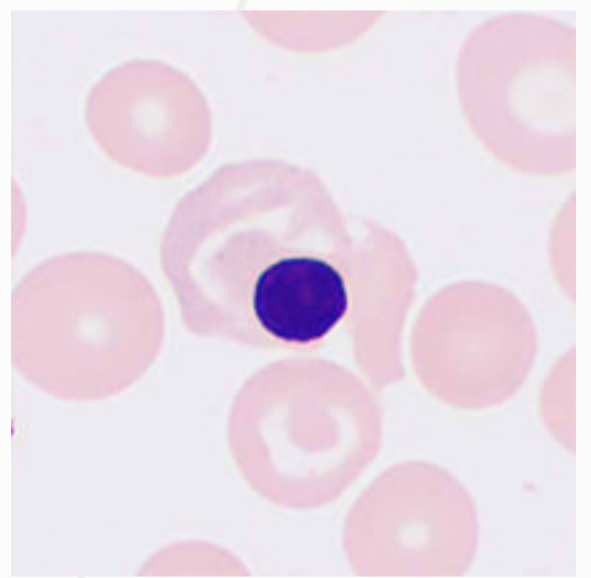
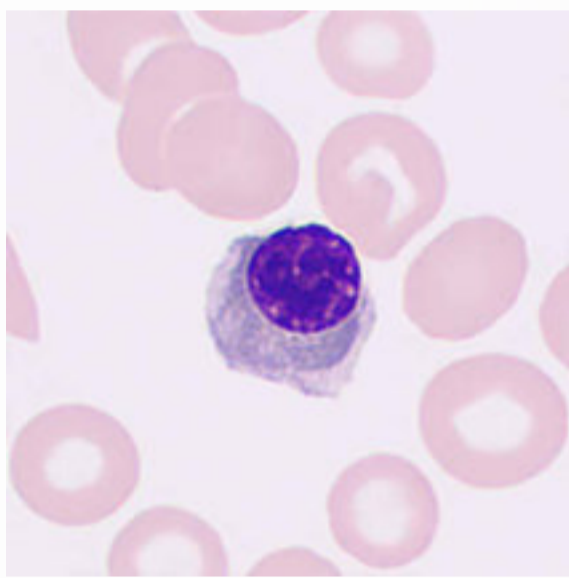
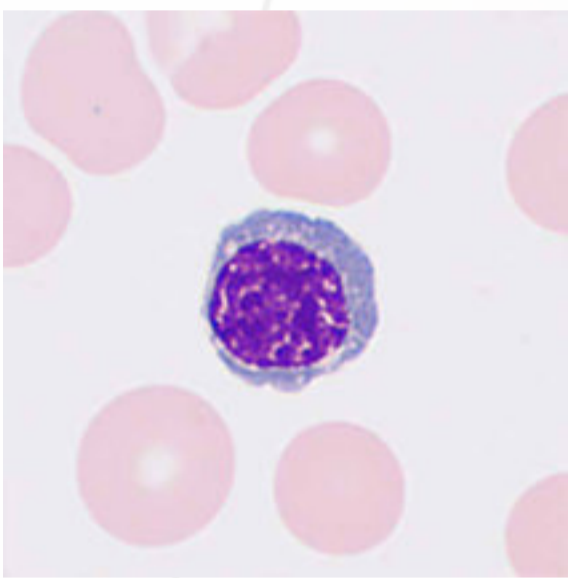


# Nucleated Red Blood Cells

Nucleated red blood cells (nucleated erythrocytes, normoblasts, erythroblasts) refer to red blood cells that undergo four stages, i.e., pronormoblasts, basophilic normoblasts, polychromatic normoblasts, and orthochromatic normoblasts, before they develop into mature cells.

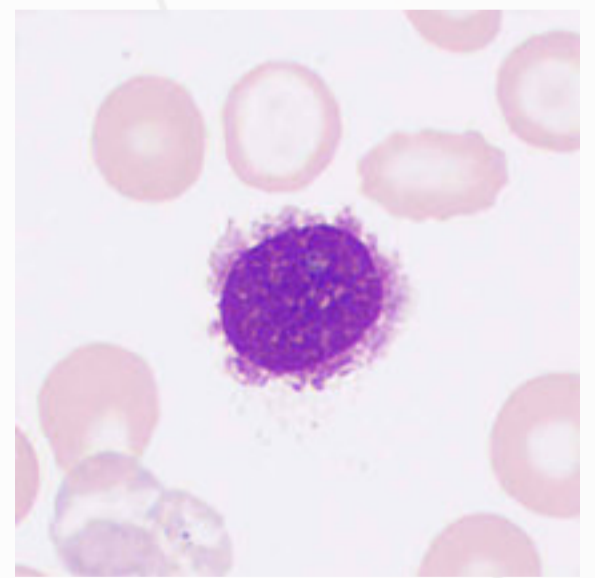
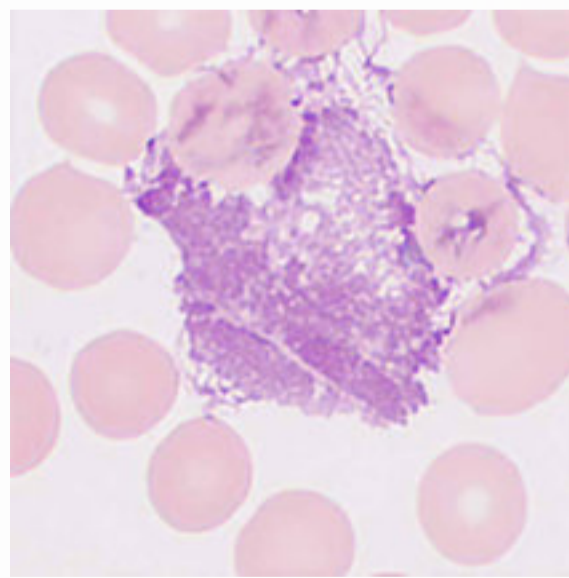
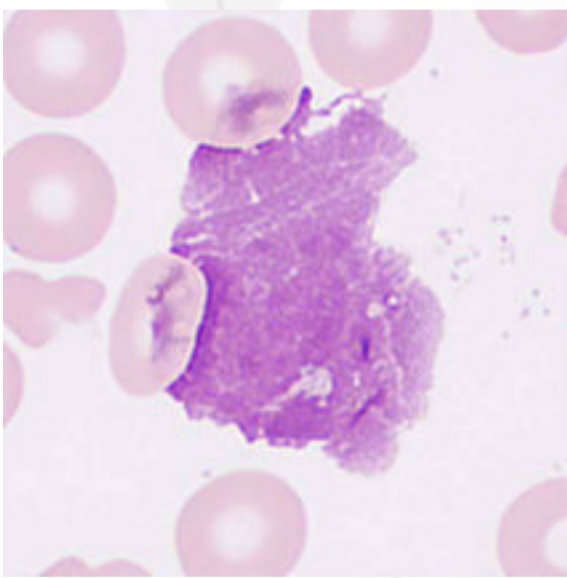
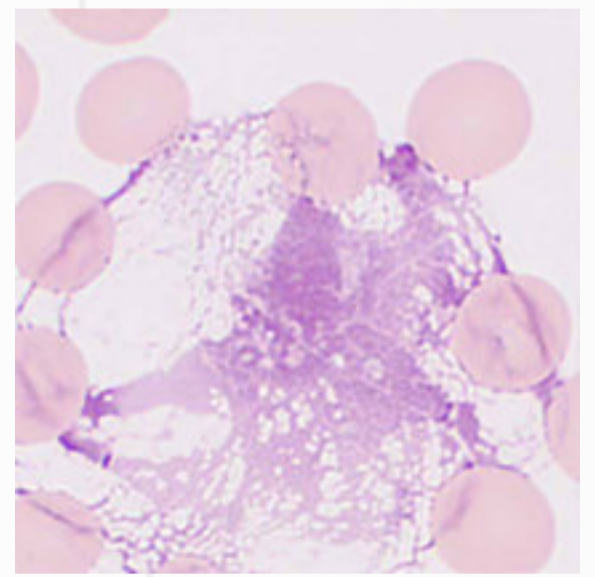
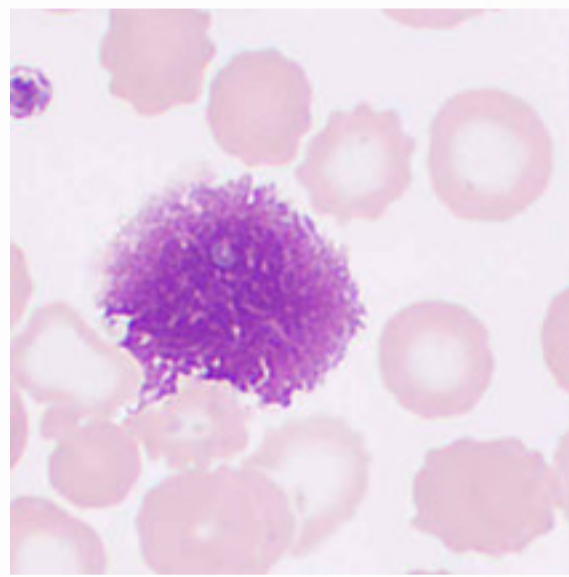
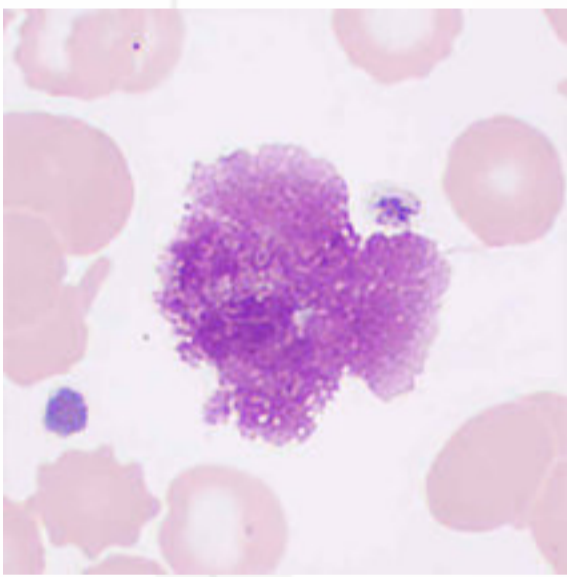
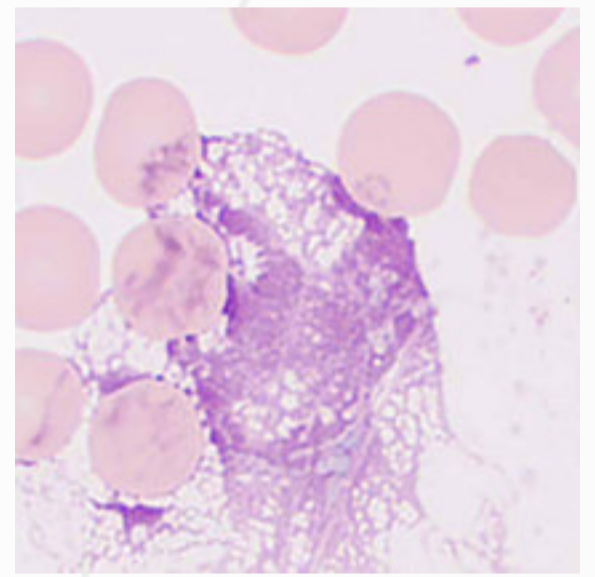
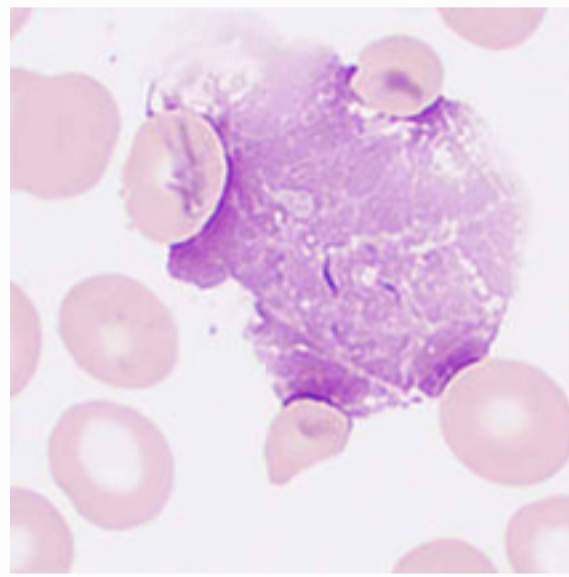
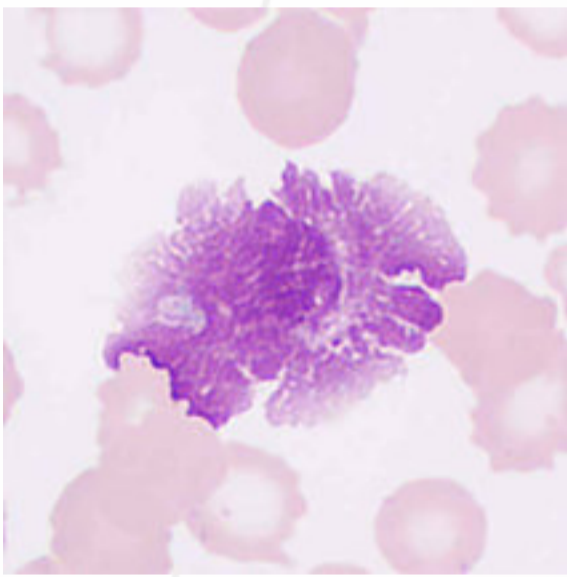


The cells are generally regular, round or round-like, with verrucous protrusions seen in pronormoblasts and basophilic normoblasts. The nucleus is round and generally centered, and denucleation is observed in orthochromatic normoblasts. The cytoplasm changes its color from deep blue → blue-gray → gray-red → pale red, and contains no granules.



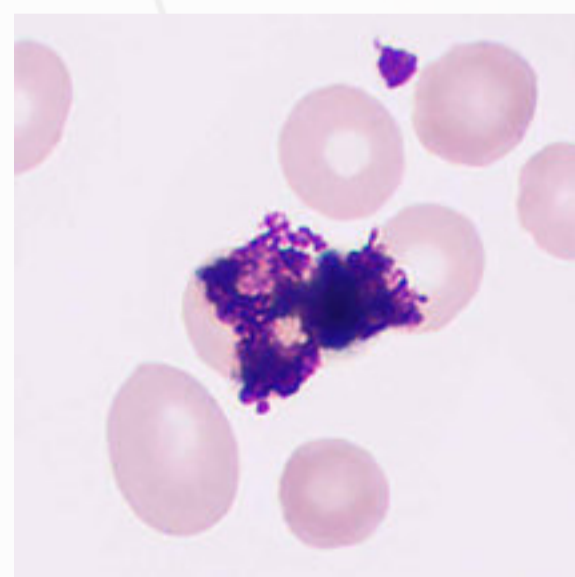
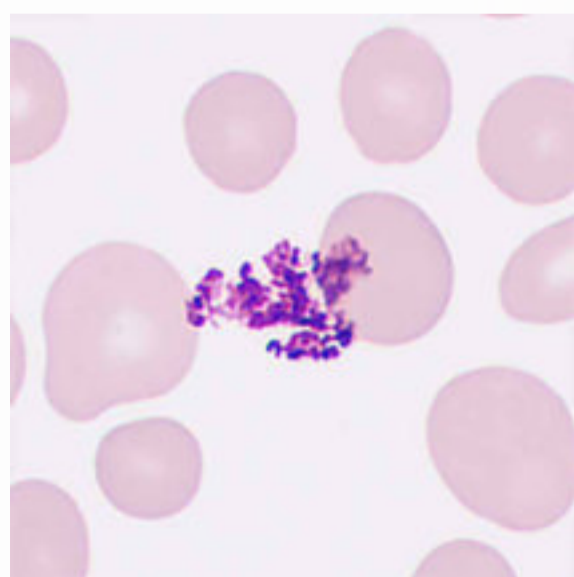
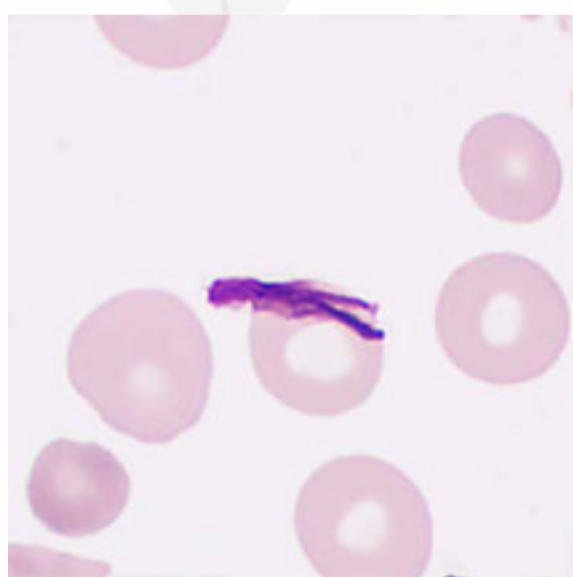
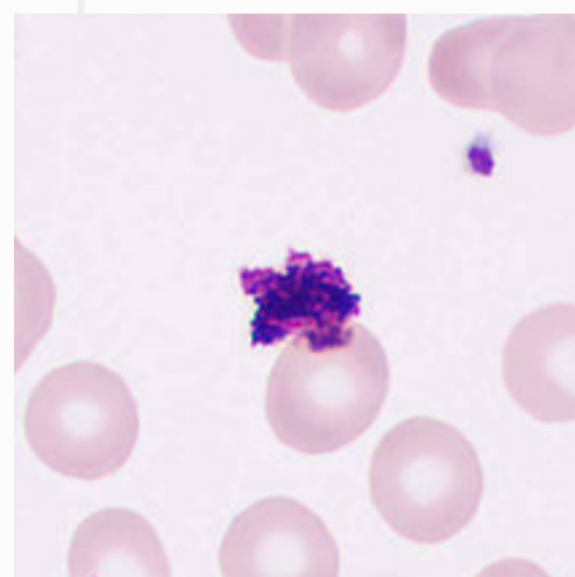
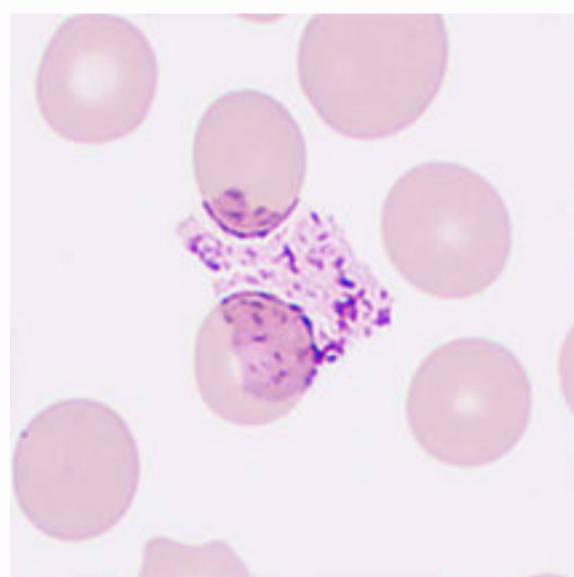
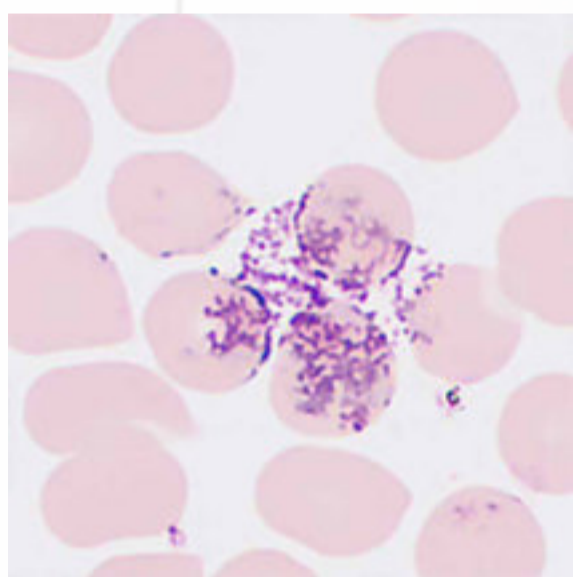
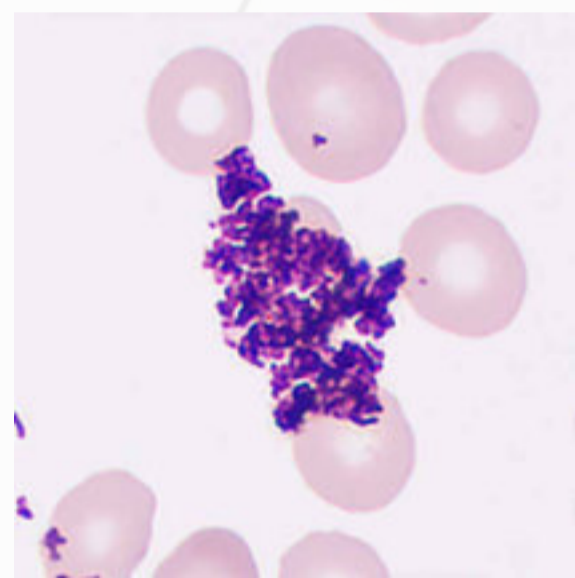
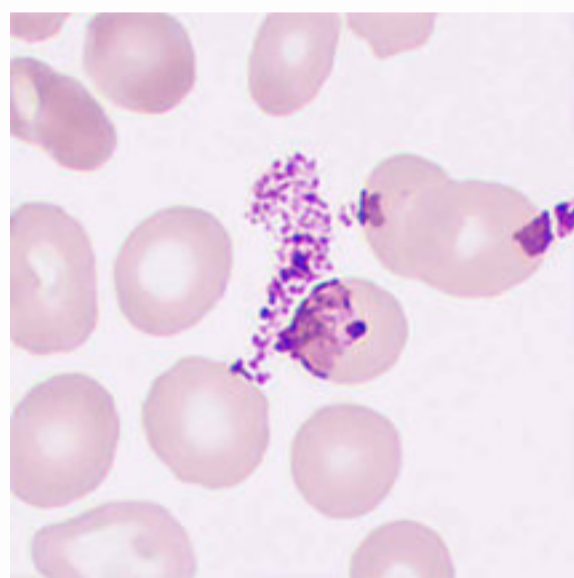
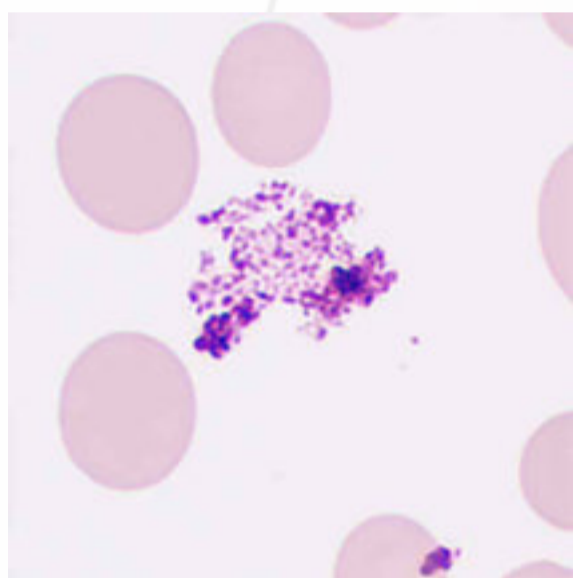
# Smudge Cells

Smudge cells, also known as basket cells or Gumprecht shadows, are remnants of leukocytes damaged during peripheral blood smear preparation. They are stained light violet-red and have a blurred chromatin structure. An increase of smudge cells in peripheral blood is associated with chronic lymphocytic leukemia.



# Artefacts

Improper staining procedures such as blood smear over-drying, inappropriate staining solution-to-buffer ratios, and/or insufficient washing could cause dye adherence, resulting in dye sediment formation. Artefacts could be effectively removed by dissolving the dry blood smears with methanol and rinsing them with water.



# MC-80

Automated Digital Cell Morphology Analyzer

## More Clarity. More Intelligence. More Productivity.

### More Clarity

- Displays the ultra clarity and authenticity of each cell

- Captures comprehensive pathological features of each cell

### More Intelligence

- Reliable cell pre-classification and pre-characterization

- The intelligent analysis mode makes the process easier and requires less manual intervention.

### More Productivity

- 60 slides/h guarantees ultimate efficiency

- Remote review and consultation in multiple locations

- User-friendly and intuitive software optimizes lab workflows

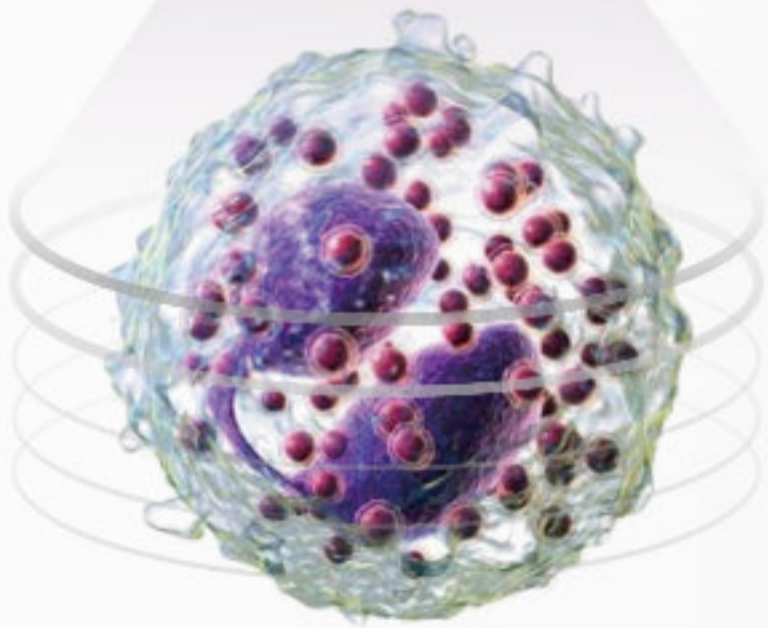




# Multi-layer fusion technology

Simulates manual focus adjustment and accurately restores the pathological features of cells, which is helpful for early screening of blood diseases (such as acute promyelocytic leukemia) and infectious diseases.

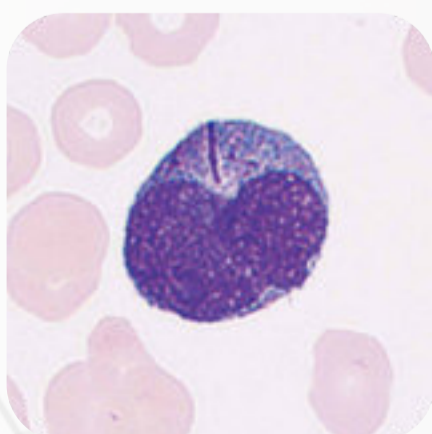
High-speed continuous capturing



Captures all details with more than 20 depths of field



Fuses all images to capture concise pathological features



# Flexible configuration options to meet various needs

MC-80 can be connected with Mindray CAL-6000 or CAL-8000 cellular analysis line for a complete solution

## CAL 6000



• Width×Depth×Height: 2970×1030× 810 (mm)

## CAL 8000



• Width×Depth×Height: 8240×1030×1470 (mm)