

FOCAL SPOT

FS



WINTER 2015 Looking into the past

MALLINCKRODT INSTITUTE OF RADIOLOGY // WASHINGTON UNIVERSITY // ST. LOUIS

CONTENTS



6 MUMMIES DAY OUT

Three mummies on display in the Egyptian galleries of the Saint Louis Art Museum are scanned by Mallinckrodt radiologists in an exciting collaboration



12 FIRE & ICE

The subspecialty of interventional musculoskeletal radiology offers several therapeutic interventions that can relieve the debilitating pain experienced by people with metastatic bone disease.



16 A NEW ERA

Richard L. Wahl, MD, assumed the helm of Mallinckrodt Institute of Radiology in October 2014. He shares his plans for meeting the challenges facing radiology in the decades ahead.



19 RSNA: 100 YEARS


At its 2014 meeting, Radiological Society of North America (RSNA) leadership urged members to couple radiology's historical strength in research and discovery with a new focus on patient-centered care.

ON THE COVER

Sophisticated imaging techniques allow researchers to “see” mummies as never before — gaining details about the health, lifestyle, personal histories, and rituals of these ancient people. In addition to this valuable new research, the images taken by Mallinckrodt Institute of Radiology faculty will be displayed in a 2016 reinstallation of the Saint Louis Art Museum's Egyptian galleries.



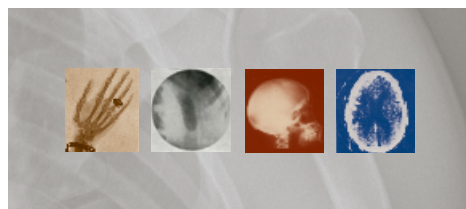
22 ALUMNI SPOTLIGHT




24 FYI

FOCAL SPOT MAGAZINE WINTER 2015

Editor: Holly Edmiston
Photography: MIR Visual Media Center
Design: Enrich Creative
Printing: Advertiser's Printing
©2015 Mallinckrodt Institute of Radiology
mir.wustl.edu



27 LEADING TOGETHER



28 A LOOK BACK

SPOT NEWS

Residency video debuts on Mallinckrodt website

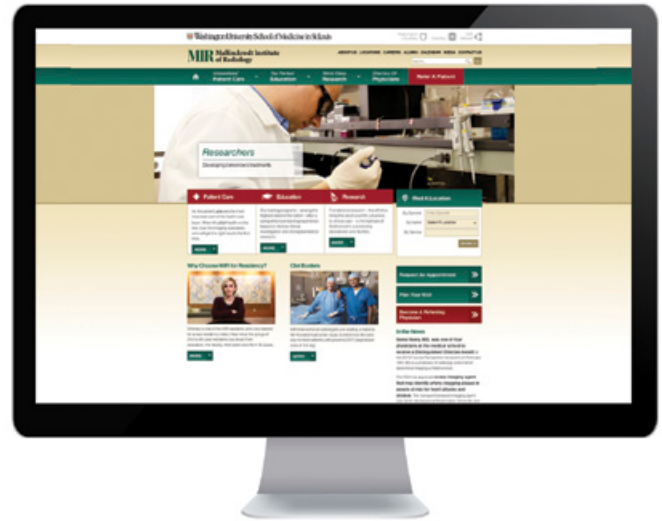Check out the latest addition to the Mallinckrodt Institute of Radiology website — a video about its residency program!

Thirteen residents volunteered to be featured in a video for and about the Mallinckrodt residency program. The four-minute video features residents articulating the benefits of the teaching program, the camaraderie among residents and with faculty, and St. Louis life in general.

Jennifer E. Gould, MD, assistant professor of radiology and residency program coordinator, put the “dream team” together and helped to shape the video’s direction.

The website debuted last July and continues to be a great way to find out what’s new at Mallinckrodt. The site targets future residents, fellows, referring physicians, and

patients, and it showcases research being conducted in Mallinckrodt’s Division of Radiological Sciences.



Please visit the Mallinckrodt Institute of Radiology website (mir.wustl.edu) to learn more and to view what this dynamic group of residents has to say about their education, the faculty, their peers, and life in St. Louis.

Left: Whitney is one of 13 Mallinckrodt Institute of Radiology residents featured in the new residency video

Achilefu is recipient of St. Louis Award

Mallinckrodt imaging scientist Samuel I. Achilefu, PhD, has received a notable local award for his laboratory’s efforts in developing goggles that allow surgeons to better visualize cancer.

At a ceremony held on January 14 at Washington University School of Medicine’s Eric P. Newman Education Center, Achilefu, professor of radiology, was honored for his passion and commitment to medical research, putting St. Louis in the spotlight for advancement in optical engineering technology, and pushing the boundaries of cancer treatment.

“Our efforts start with two words: ‘What if?’ These words may sound simple,” says Achilefu, “but they embody the belief that each person has the potential to make a difference, if only he or she can take the time to understand the problem.”

Achilefu is the 87th recipient of the annual award. The St. Louis Award was established by philanthropist David Wohl in 1931 to honor those who have “performed such services as to bring the greatest honor to the community.”



Above: Samuel I. Achilefu, PhD, receives the St. Louis Award from David Kemper, chairman and CEO of Commerce Bancshares, Inc. and vice chair of the Washington University Board of Trustees // Bob Boston

Narra receives award for clinical excellence

Vamsi R. Narra, MD, professor of radiology, was part of a small group of Washington University School of Medicine faculty recently honored for their dedication, talent, and contributions to the institution and the field of medicine.

Narra received one of four Distinguished Clinician awards at the 2015 Faculty Recognition Event held on February 18 at the school's Eric P. Newman Education Center.

"This is a well-deserved honor for Vamsi's tireless work as director of the abdominal section, director of body MRI, and as chief of radiology at Barnes-Jewish West County Hospital," says Richard L. Wahl, MD, the Elizabeth E. Mallinckrodt Professor and head of radiology and director of Mallinckrodt Institute of Radiology. "Mallinckrodt radiologists are known as outstanding



Above: Vamsi R. Narra, MD, accepts his award from Dean Larry J. Shapiro, MD

clinicians and are integral to care of patients across a wide range of specialties. I am delighted that one of our master clinicians and leaders at MIR was appropriately recognized for this prestigious award."

Recipients of the Distinguished Faculty Awards are nominated by their peers to recognize achievements in clinical care, community service, research, and teaching.

Additional location for pediatric radiology



Above: The St. Louis Children's Specialty Care Center, located one mile west of the I-270 and I-64 interchange in west St. Louis County

Mallinckrodt Institute of Radiology pediatric radiologists soon will be providing services at a new location in west St. Louis County.

The St. Louis Children's Specialty Care Center, scheduled to open in June 2015, will provide advanced pediatric and adolescent care for a range of specialties. Located at Highway

40/Interstate 64 and Mason Road, the new center brings Washington University physicians together with St. Louis Children's pediatric nurses and staff to provide the very best care for its young patients.

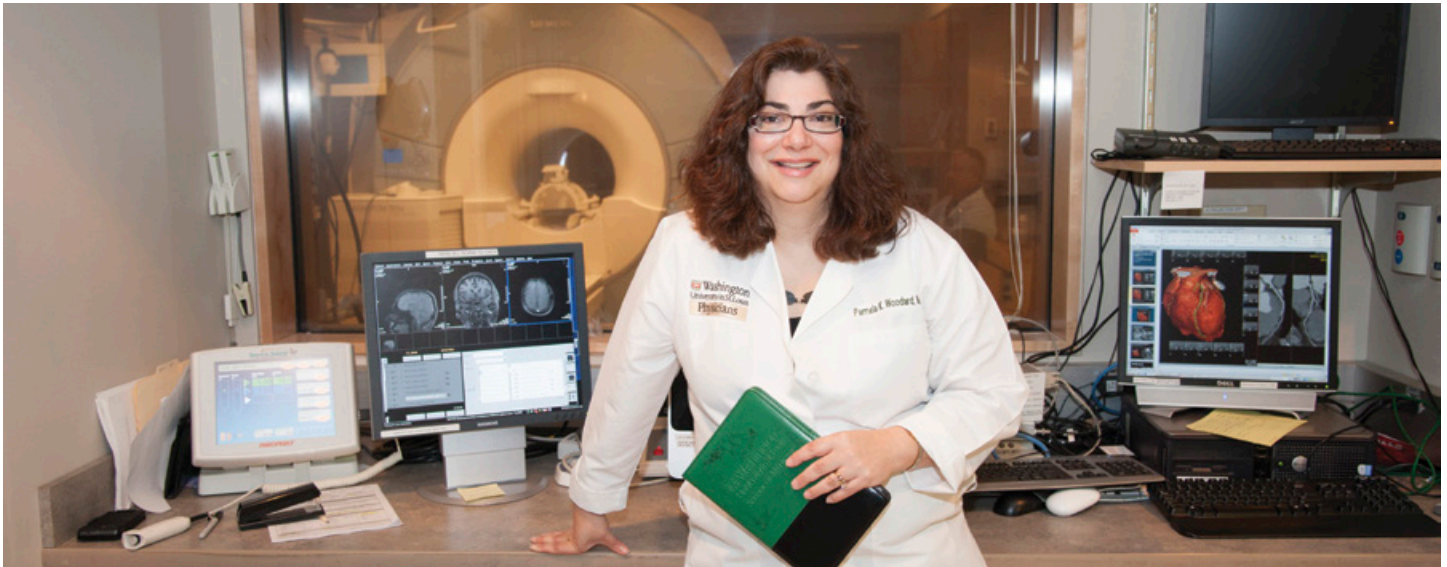In addition to imaging services — including fluoroscopy, MRI, digital radiography, and ultrasound — the new center will include many other outpatient services in one location. Mallinckrodt has recently recruited a pediatric radiologist with subspecialty training in musculoskeletal radiology to enhance the sports medicine practice at the new facility.

"We are excited to be able to bring our subspecialty pediatric radiology practice to West County," says Robert C. McKinstry, MD, PhD, professor of radiology and pediatrics and chief of Mallinckrodt's pediatric radiology service. "We aim to provide superior service at this convenient location."

The three-story, 141,000-square-foot facility also will include a special pick-up area for surgical patients, a Safety Stop at which parents can discuss car seats, helmets, and home safety with trained safety technicians, and a Family Resource Center, an interactive information station that connects families to personalized child health information.

The new center is designed to be a welcoming space for both patients and their families, who will be surrounded by an uplifting and creative environment that reduces stress, promotes healing, and provides a superior patient experience.

Nanoparticle approved for clinical trials



Above: Pamela K. Woodard, MD

A new imaging agent may light up dangerous plaque in arteries, and Mallinckrodt radiologist Pamela K. Woodard, MD, led the team that designed the nanoparticle, which researchers hope will identify patients at high risk of stroke.

Woodard, principal investigator, and colleagues at the University of California, Santa Barbara, in collaboration with Texas A&M University, jointly developed the imaging agent now approved for investigational evaluation in humans by the Food and Drug Administration (FDA).

“This is the first receptor-targeted nanoparticle agent for cardiovascular imaging approved for investigational use in humans,” says Woodard, professor of radiology and of biomedical engineering. “Starting with bench research, then developing and testing the agent and taking it through the FDA process into human patients has involved an extensive team of basic scientists, clinical researchers, and clinicians.”

In patients with atherosclerosis, plaque accumulates on the inner walls of arteries that deliver blood to the body. According to Woodard, also director of Mallinckrodt’s Center for Clinical Imaging Research, these plaques can be stable or progress to a vulnerable phase in which they rupture, leading to stroke or heart attack.

With current technology, researchers can’t tell whether the plaque is vulnerable or stable, and so can’t distinguish

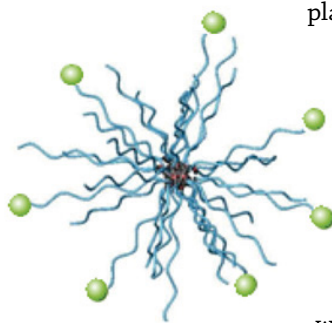
high-risk patients who need surgery from low-risk patients who can be treated with medication alone.

The new nanoparticle is unique in how it is targeted, according to Yongjian Liu, PhD, assistant professor of radiology at Washington University School of Medicine and co-investigator on the project. Previous research demonstrated that a receptor called NPR-C is present on the surface of cells that line blood vessels and is increased in atherosclerotic plaque. So the investigators added a small molecule to the nanoparticle that seeks out and binds to NPR-C, specifically targeting the particle to potentially dangerous plaque.

Once the imaging agent illuminates plaque in any of the body’s arteries, it can be detected with positron emission tomography (PET).

Researchers recently began testing the safety of the nanoparticle in healthy individuals. They next will focus on patients with atherosclerosis who already are scheduled to undergo surgery to remove plaque from their carotid arteries.

“In this way, we’ll be able to see whether the areas that light up in the image because of our nanoparticles are the same areas that contain vulnerable plaque, as assessed from the surgeries,” Woodard says. “Once we show success imaging the carotid arteries, we will evaluate the nanoparticle agent in other vessels such as the coronary arteries, which represent a greater challenge because of their smaller size and complex motion.”



Raichle named Wolff Distinguished Professor

Mallinckrodt neuroscientist Marcus E. Raichle, MD, has been named an inaugural Alan A. and Edith L. Wolff Distinguished Professor of Medicine at Washington University School of Medicine.

Raichle is a professor of radiology, psychology, biomedical engineering, neurobiology, and neurology. His many honors include the 2014 Kavli Prize for Neuroscience; he shared the \$1 million prize with two other neuroscientists for research into the roles brain networks play in memory and cognition.

“Marc Raichle is one of the world’s premier neuroscientists,” says Washington University Chancellor Mark S. Wrighton. “His studies helped uncover the hidden functional architecture of the human brain, and I cannot overstate the importance of these structures to our modern understanding of how the brain works in health and disease.”

After joining the School of Medicine in 1971, Raichle worked with Michel Ter-Pogossian, a pioneer of positron emission tomography (PET), to apply PET and other imaging techniques in groundbreaking studies that revealed key aspects of brain function and organization.

“One of Marc’s key insights was to recognize that many revealing brain activities occur when we’re not consciously doing anything with our minds,” says Larry J. Shapiro, MD, executive vice chancellor for medical affairs and dean of the School of Medicine. “The discovery created a whole field of science and made possible many different branches of research that are leading to new ways to diagnose and treat brain injuries and neurodegenerative disorders.”



Above: Marcus E. Raichle, MD, delivers his inaugural speech, “A Restless Brain”

Raichle, a Washington State native, noted with amusement at the installation ceremony that 43 years ago he and his wife had thought they were coming to St. Louis for just a few years. He called the university a “spectacular place to be” and expressed his thanks to colleagues, staff and students, and for the named professorship.

“Having the kind of support provided by this chair is very



Above: Marcus E. Raichle, MD, was among a group of three 2014 Kavli Prize winners honored with a White House reception last July; Raichle (right) poses with President Obama and neuroscientist and Nobel Prize winner John O’Keefe, PhD, a fellow Kavli Prize honoree

special to any scientist,” Raichle says. “It’s an honor, and it gives me the flexibility to be creative and come up with new ideas, and I’m very grateful to the Wolffs for their exemplary generosity.”


For many years, Raichle and other researchers scanned the brains of volunteers in research studies as the subjects performed mental tasks such as looking for a target, listening for a sound, or reading a word. By tracking changes in brain blood flow during the activities, the researchers identified the brain regions involved in mental tasks.

But Raichle noticed that as subjects focused on mental activities, the changes in blood flow triggered by the tasks only accounted for a fraction of the brain’s oxygen use. In an accidental discovery, his laboratory found that energy use in certain regions of the brain consistently decreased when volunteers began cognitive tasks.

This led them to conduct a series of brain scans with a key difference: They asked the volunteers to just relax.

It soon became clear that certain brain regions were more likely to be abuzz with activity when volunteers did nothing and that this activity dropped as participants took up mental tasks. Raichle and others established that the activity was part of a previously unrecognized brain system they called the default mode network. They have amassed evidence that the network helps the brain organize memories and envision the future, helping the brain to prepare its response for events that may be minutes, days, months or years ahead.

Impairments in the default mode network may be connected to a wide range of neurological disorders, including Alzheimer’s disease, depression, and schizophrenia. The default mode network also is helping scientists understand the complex ways the brain responds to injuries such as stroke and concussion. //



MUMMIES DAY OUT



by Mary Konroy

IT WAS A COLD, DAMP, GRAY SUNDAY MORNING IN OCTOBER...

An unmarked truck with out-of-state plates backed up to the loading bay at the Center for Advanced Medicine (CAM) at Washington University Medical Center. A waiting entourage, which included medical center security, stood quietly nearby.



One by one, three large white boxes with lids were lowered by hydraulic lift, placed on gurneys, and transported in two trips under a shroud of secrecy to the CAM's third floor by professional art handlers. The boxes contained ancient artifacts — three mummies dating to Before the Common Era (BCE) — from the Saint Louis Art Museum. This was their first trip out of the gallery in decades.

Like their living counterparts, the mummies came to the CAM and to the attention of Mallinckrodt Institute of Radiology specialists for an imaging examination. "We want the most up-to-date information about the mummies for a reinstallation of the entire Egyptian collection planned for 2016," says Lisa Ayla Çakmak, PhD, assistant curator of ancient art at the museum. The images acquired by Mallinckrodt, as well as the radiologists' interpretations, will be incorporated into the museum's public display and be available to researchers worldwide.

"It was the opportunity of a lifetime," says Sanjeev Bhalla, MD, professor of radiology and chief of cardiothoracic imaging, who led the Mallinckrodt team



Left: Saint Louis Art Museum staff prepare the mummies for transport
Mummy and researcher photos // Tim Parker



Above: Objects conservator Alice Boccia Paterakis, PhD, examines the mummies for pre-existing damage before the move and subsequent scanning

Michelle M. Miller-Thomas, MD, assistant professor of radiology and a neuroradiologist, Vincent M. Mellnick, MD, assistant professor of radiology and an abdominal imaging specialist, and Pamela K. Woodard, MD, professor of radiology and head of Mallinckrodt's cardiac radiology service.

Not present during the scans but involved in the follow-up image analysis were David A. Rubin, MD, professor of radiology and chief of musculoskeletal imaging, Jonathan E. McConathy, MD, PhD, assistant professor of radiology and nuclear medicine specialist, and Charles F. Hildebolt, DDS, PhD, a former professor of dentistry and present-day professor of radiology and adjunct professor of anthropology.

EGYPTIAN ARTIFACTS, 21ST CENTURY TECHNOLOGY

Two of the mummies — Henut-Wedjebu and Pet-Menekh — are on long-term loan to the city's art museum from Washington University's Mildred Lane Kemper Art Museum. They had not been imaged since they were X-rayed at Mallinckrodt in 1970. The third mummy — Amen-Nestawy-Nakht, part of the Saint Louis Art Museum collection — underwent a CT exam in 1989 at then-Jewish Hospital and an X-ray in 1995 at McDonnell Douglas (now Boeing). The names of the individuals were written on each of their coffins.

So in an unusual juxtaposition spanning three millennia — one mummy dates back to 1350 BCE — the institute scanned its oldest patients ever using its latest

technology. Each mummy underwent three dual-energy CT scans that eventually produced more than 6,000 images per body. What would have taken hours to perform 25 years ago took less than five minutes per mummy.

The resulting images yielded exquisite detail about the mummies, from convolutions on the brain of the only female, Henut-Wedjebu, to a never-before-seen scarab amulet on the body of Amen-Nestawy-Nakht. Apparently grave robbers had not seen the amulet either. There's evidence that his cartonnage, the plaster-like layers of linens wrapping his body, had been bludgeoned on his backside. His upper torso is a jumble of fractures, his skeletal remains significantly shorter than his coffin.

"Our overwhelming theme, once we became involved in this project, was to remember that these mummies were people and we had to treat them respectfully," says Bhalla.

Çakmak, along with Kate Butler, PhD, associate curator at the Kemper Museum, was present during the radiological exams. Çakmak notes that it's easy to objectify mummies.

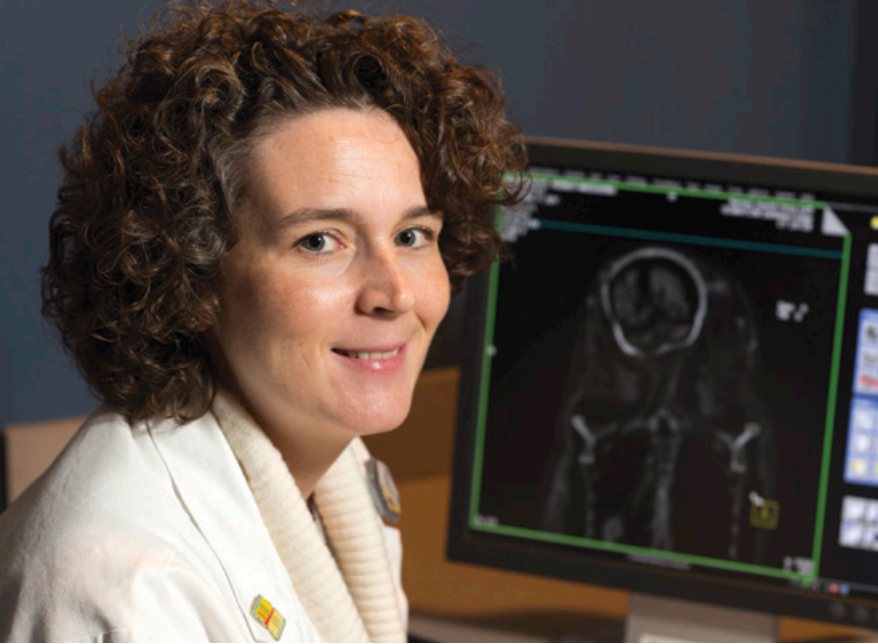
"It was critical for us to listen to them," says Bhalla of both art curators. "In many ways, they became surrogates for the mummies, providing us with useful information about what to look for and the mummification process. They knew more about these patients than we did as physicians. At the end of the day, it's all about scanning people to get a better understanding of their health."

THE PLANNING PROCESS

Planning began months before the event and was led by R. Gilbert Jost, MD, professor of radiology and former director of Mallinckrodt Institute of Radiology.

"Gil communicated with the Saint Louis Art Museum and was the one who got a group [of Mallinckrodt radiologists] together in the summer to talk about mummy imaging. The room barely had a seat available," recalls Bhalla, "because so many people were interested."

Jost began the meeting with a discussion on how to determine the best imaging modality. "Everybody offered their thoughts; it was a very collaborative discussion that concluded CT would be the best way to go," says Bhalla. "No one championed their own technology or put their ego first. Then Gil asked, in a very democratic sort of way, who should be on the core imaging team and solicited volunteers. Typical of how he has operated for



Left: Michelle M. Miller-Thomas, MD **Right:** Sanjeev Bhalla, MD

the past 15 years, he identified the point person. He put the pieces together, and then stepped back.” It was the team’s project and their chance to shine in a high-profile task that would attract the attention of National Public Radio (NPR), the Associated Press and other national and local media.

Three additional meetings followed at the city’s art museum and at Mallinckrodt until all plans were in place, including logistics. Henut-Wedjebu’s body, for example, would have to be lifted out of her case onto the CT table because her sarcophagus was too large to pass through the CT’s wide bore.

A FAKE HEARTBEAT AND A SKULL FRACTURE

The morning of the exams, a fake heartbeat was used to initiate the exams — the CT scanner had to be tricked into believing that it was imaging a live person.

Each mummy underwent three scans: head to toe, head and neck, and body. “No one really knew what was inside these mummies until we took a look,” says Miller-Thomas, who was present that day. “So it was a surprise to everybody to see what happened during the mummification process.”

One of the mummies was filled with resin, an organic tree sap that infiltrated the bones and created a layering effect similar to a parfait. Another was stuffed with packing material after his brain and organs were removed, placed in separate packs, and reinserted into the body cavity.

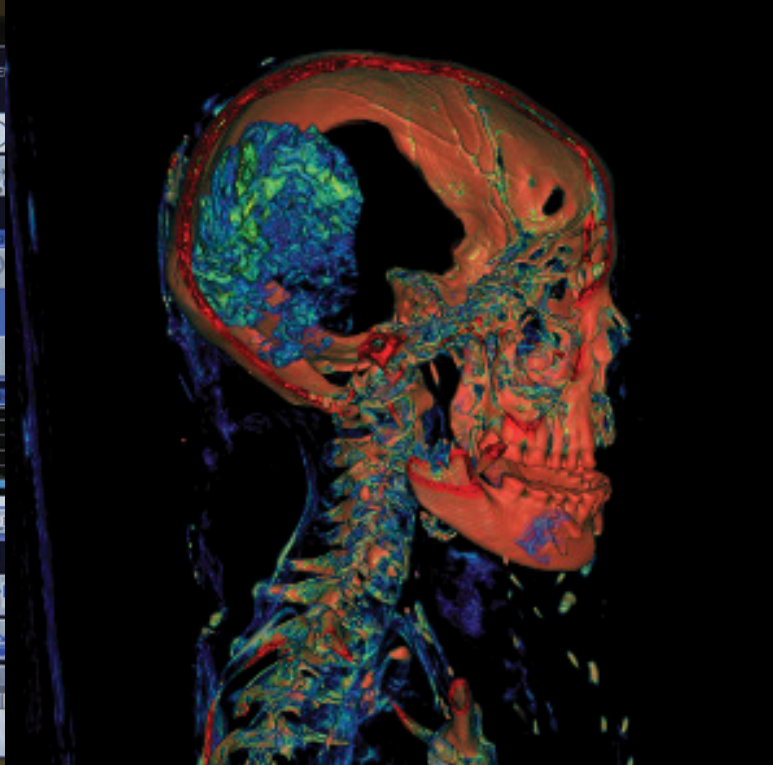
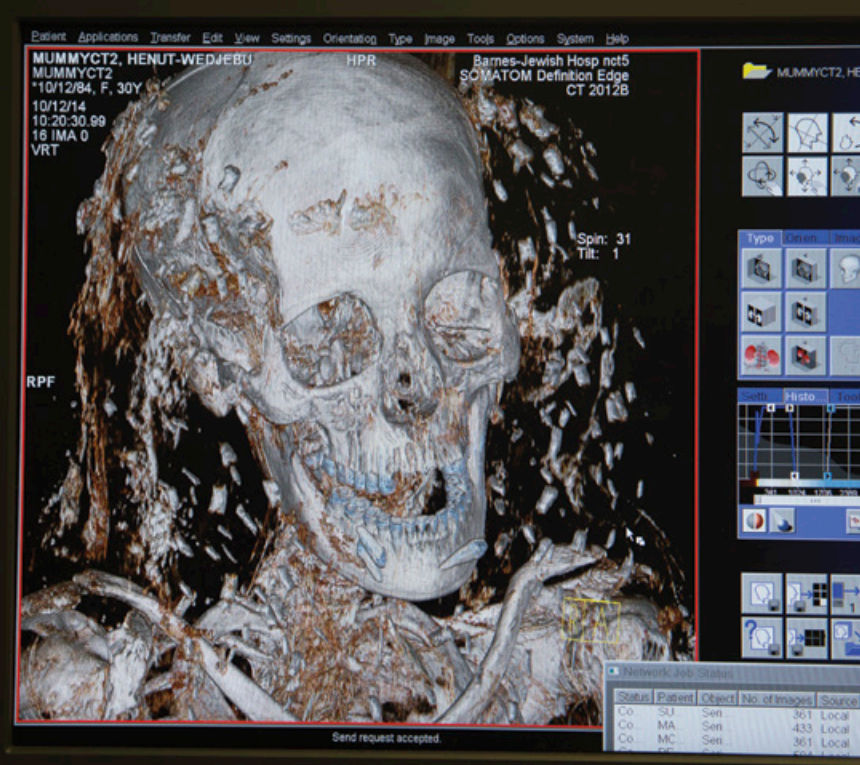“I didn’t fully appreciate at the start of this project how different each one of the mummies would be,” says Miller-Thomas, who was captivated by Henut-Wedjebu. “She has a very sweet position to me. Her hands are kind of in front of her pelvis and they are close together and her head is tilted just a bit.” The CT scans detected what appears to be a wig or headdress embedded with adornments. They also detected a skull fracture.

“If the fracture happened during her life, it would have indicated a very severe head injury that could have caused her death,” says Miller-Thomas. “However, there are some other features that suggest it happened after she died, and even after she was mummified and wrapped.

“She (Henut-Wedjebu) has some signs of trauma to her face: Her front teeth were knocked out and are wrapped within the linens over her mandible. That implies to me that she had some trauma to her head and face post-mummification.”

What makes Henut-Wedjebu unique from the other mummies, however, is that she still has her brain and all her chest and abdominal organs. “They’re typically removed in a fairly well-defined process,” Miller-Thomas says. “Organs were taken out through an incision in the left side of the abdomen, individually wrapped, and often put back into the mummies.”

But curators pointed out that Henut-Wedjebu was the oldest of the three mummies. Mummification practices differed over the years with Amen-Nestawy-Nakht and Pet-Menekh only dating back to the 9th and 4th centuries BCE, respectively.



Above: Female mummy Henut-Wedjebu sports both hair adornments (left) and a brain (right), the latter being an uncommon find amongst mummy specimens

INTERPRETING THE IMAGES

Distinguishing the organs was difficult, as the desiccated body parts have lost their recognizable shapes. Experts at anatomy, the Mallinckrodt radiologists took what they knew about the living and applied it to the mummified remains, with the art curators providing hints along the way.

The team of subspecialty radiologists viewed the images individually and then assembled as a group to re-examine the images together. “The notion was, ‘If we could do it all together, we could capture everybody’s thoughts,’” Bhalla adds. Ultimately, they want to catalogue the findings of each of the subspecialty radiologists.

PRELIMINARY FINDINGS

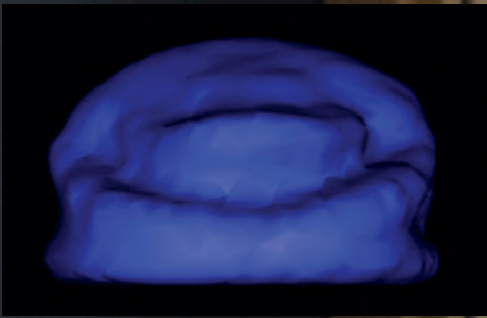Contrary to published reports about mummies scanned elsewhere, the local trio showed no sign of calcification in vessel walls indicative of cardiovascular disease. They also showed minimal joint degeneration. “Most surprising to me,” says Rubin, a musculoskeletal expert, “is that all three had a surprisingly small amount of pre-morbid skeletal trauma and degeneration. There was no osteoarthritis, and only minimal cervical degenerative disc disease.

“Even the hands and feet looked great. I suspect none of these three were involved in manual labor, hunting, or fighting. A ‘typical’ 35-year-old today would have had some sort of injury in the past — maybe a stubbed toe fracture, broken rib, or broken clavicle — just from daily activities and minor accidents.

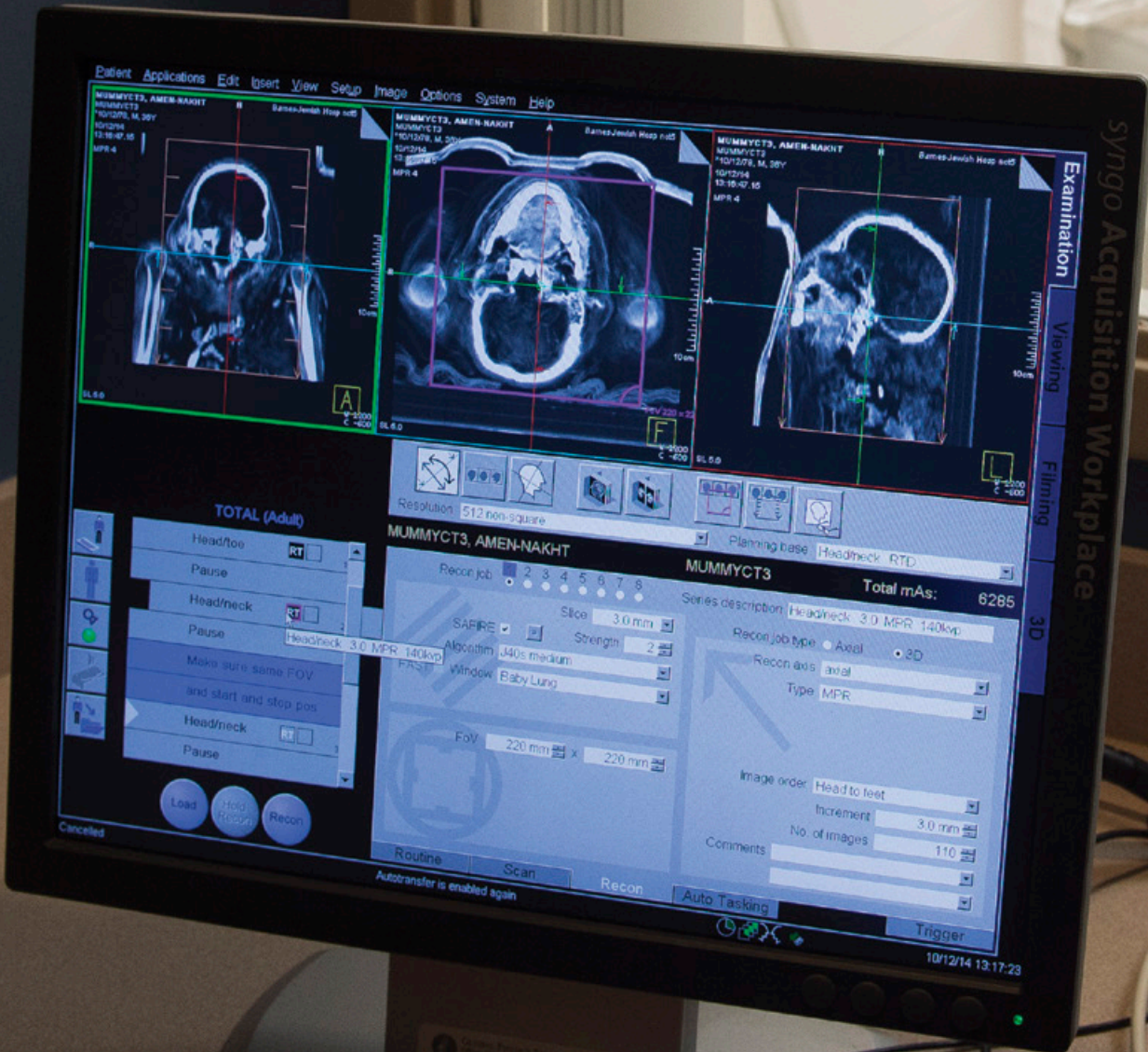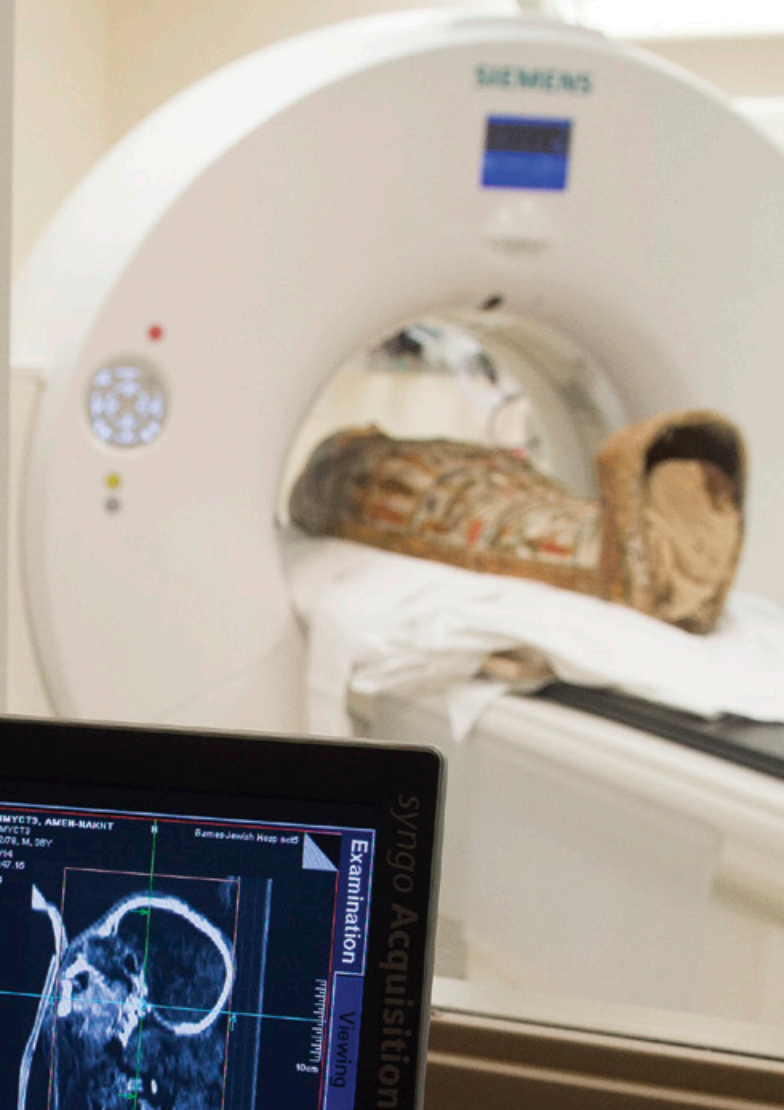“A typical 35-year-old today also would usually have more arthritis in the spine and certain joints. I don’t know if all three of these people led charmed lives — where someone else did everything for them — or whether this is a sampling error,” Rubin says. “I’m guessing that all three also probably had relatively good diets and nutrition based on their bones.”


More findings are expected as the final medical report for each mummy has yet to be written. And when they are finished, the reports will bear the signature of every Mallinckrodt subspecialty radiologist involved in the mummy scanning initiative.

“This project came together because everybody involved in it brought something to the table,” Bhalla says. “The net effect has been this overwhelming sharing across the board, and the histories of these preserved individuals may make important contributions to the field of Egyptology.”



Above: A scarab amulet found on the body of Amen-Nestawy-Nakht.



An X-ray of a human spine, showing the vertebrae and intervertebral discs. The spine is highlighted in a reddish-pink color, while the surrounding skeletal structure is in a light blue/cyan color. The text "FIRE & ICE" is overlaid on the spine. "FIRE" is in red, "&" is in white, and "ICE" is in light blue.

FIRE & ICE

RELIEVING BONE CANCER PAIN THROUGH MUSCULOSKELETAL RADIOLOGY

by Pam McGrath

Shervon Johnson-Lewis has experienced pain so severe that she had to quit her job as a stand attendant at Busch Stadium in St. Louis. She's lived through pain so intense that she lay on the floor, writhing. She's suffered pain that no amount of prescribed medication could alleviate.

And, finally, she's felt relief from her ever-present pain due to the expertise of Jack W. Jennings, MD, PhD, whose specialty is interventional musculoskeletal radiology. Using cryoablation (cold) and radiofrequency ablation (heat), Jennings has helped to reduce or completely alleviate debilitating pain for hundreds of patients like Johnson-Lewis who have metastatic bone disease. He and his colleagues are the only interventional musculoskeletal radiologists in the St. Louis region to perform these procedures. Jennings was mentored by two pioneers in the field: Afshin Gangi, MD, PhD, University Hospital of Strasbourg, France, and Matthew Callstrom, MD, PhD, Mayo Clinic College of Medicine, Rochester, Minnesota.

"Bone disease is common in many patients whose cancer has metastasized, especially those with breast, prostate, lung, thyroid, and kidney cancers," says Jennings, assistant professor of radiology. "One of the first indications that cancer has spread to the bones is pain, which at first can come and go. Eventually, however, the pain can worsen to the point of people being unable to sit comfortably, walk, or easily function in their daily lives. In addition, the cancer can weaken bones so much that they fracture."

In recent years, minimally invasive techniques such as cryoablation and radiofrequency ablation have been developed to provide pain palliation. With cryoablation, a tiny probe about the diameter of a pen tip is used to deliver argon gas to the tumor, freezing and destroying it. Radiofrequency ablation uses radio waves to heat and destroy abnormal cells.

“These procedures are done percutaneously, which means ‘through the skin.’ We make small nicks in the skin that are just a few millimeters in size that allow us to insert the probes,” explains Jennings. “The openings are so small stitches aren’t needed to close them, just a bit of surgical glue. Patients typically go home less than 24 hours after the procedure.”

Once the tumors are destroyed, Jennings often fills the void left with polymethylmethacrylate, a type of bone cement. In the pelvis, this is called cementoplasty, in the spine, vertebral augmentation, and in the sacrum, it’s called sacroplasty.

“Especially in weight-bearing bones, this procedure is important to minimize the risk of fracture,” says Jennings. “It may be done in conjunction with percutaneous ablation therapy or by itself to stabilize bone and thus relieve pain.”

He adds, “Some patients have immediate relief from their pain, while for others it may take a week or so. Most, however, eventually are able to significantly reduce their pain medication and have a better quality of life than was previously possible.”

BACK PAIN = LUNG CANCER

After enduring six months of lower back pain, in late summer 2013 Johnson-Lewis came to the emergency department at Barnes-Jewish Hospital. A CT scan showed she had adenocarcinoma of the lung that had metastasized to the 4th lumbar vertebra (L4). Jennings performed radiofrequency ablation and vertebral augmentation at L4.

By summer 2014, however, Johnson-Lewis was once again experiencing pain.

“My fiancé and I were visiting Springfield, Illinois, where we did a lot of walking. The next day I was in so

much pain I could hardly walk. I thought I had overdone it the day before,” says Johnson-Lewis.

But the intense pain persisted. Johnson-Lewis visited a community hospital, where she was diagnosed first with sciatica and then an abscess. “They gave me all these different types of pain medicine that would only help for a minute, and then here comes the pain again,” she says.

In truth, Johnson-Lewis’ lung cancer had again metastasized, this time to her pelvic bone. Radiation treatments failed to stop the tumor’s growth or the pain.

“The advantage of percutaneous ablation therapy is that it is another option for patients whose tumors don’t respond to radiation or chemotherapy or for whom other treatments such as surgery are not possible,” says Jennings. “It also may be used in conjunction with radiation and chemotherapy to ensure patients receive comprehensive care. We take a multidisciplinary approach to treating metastatic cancer that includes referring oncologists, radiation oncologists, and surgeons working together to determine the best course of treatment for each patient.”

For the tumor in Johnson-Lewis’ ilium, Jennings performed cryoablation and cementoplasty. After a 23-hour period of observation, she was home again.

“That surgery basically was a miracle to me,” says Johnson-Lewis.

“Bone metastasis is a big problem for our patients with lung cancer,” says Ramaswamy Govindan, MD, professor of medicine and co-director of medical oncology at Washington University School of Medicine. “Dr. Jennings and his colleagues provide outstanding service in managing patients with symptomatic bone metastases. I have been very impressed with the dramatic symptom relief some of our patients get right after his procedures.”

Johnson-Lewis currently is enrolled in a chemotherapy trial at the Alvin J. Siteman Cancer Center that has proven effective in stemming the growth and spread of her lung cancer.

INVESTIGATING SOFT TISSUE ABLATION

Over the past few years, Jennings has received an increasing number of requests to use percutaneous ablation therapy for local tumor control in soft tissues.

“This is not a cure for cancer that has metastasized, but it is a therapeutic option for patients with soft tissue



Above: Shervon Johnson-Lewis relaxes at home // *Tim Parker*

lesions that are causing pain,” says Jennings.

Brian A. Van Tine, MD, PhD, assistant professor of medicine at Washington University School of Medicine, has enlisted Jennings’ help with a study titled “Tumor Ablation in Metastatic Sarcoma Stable on Chemotherapy.”

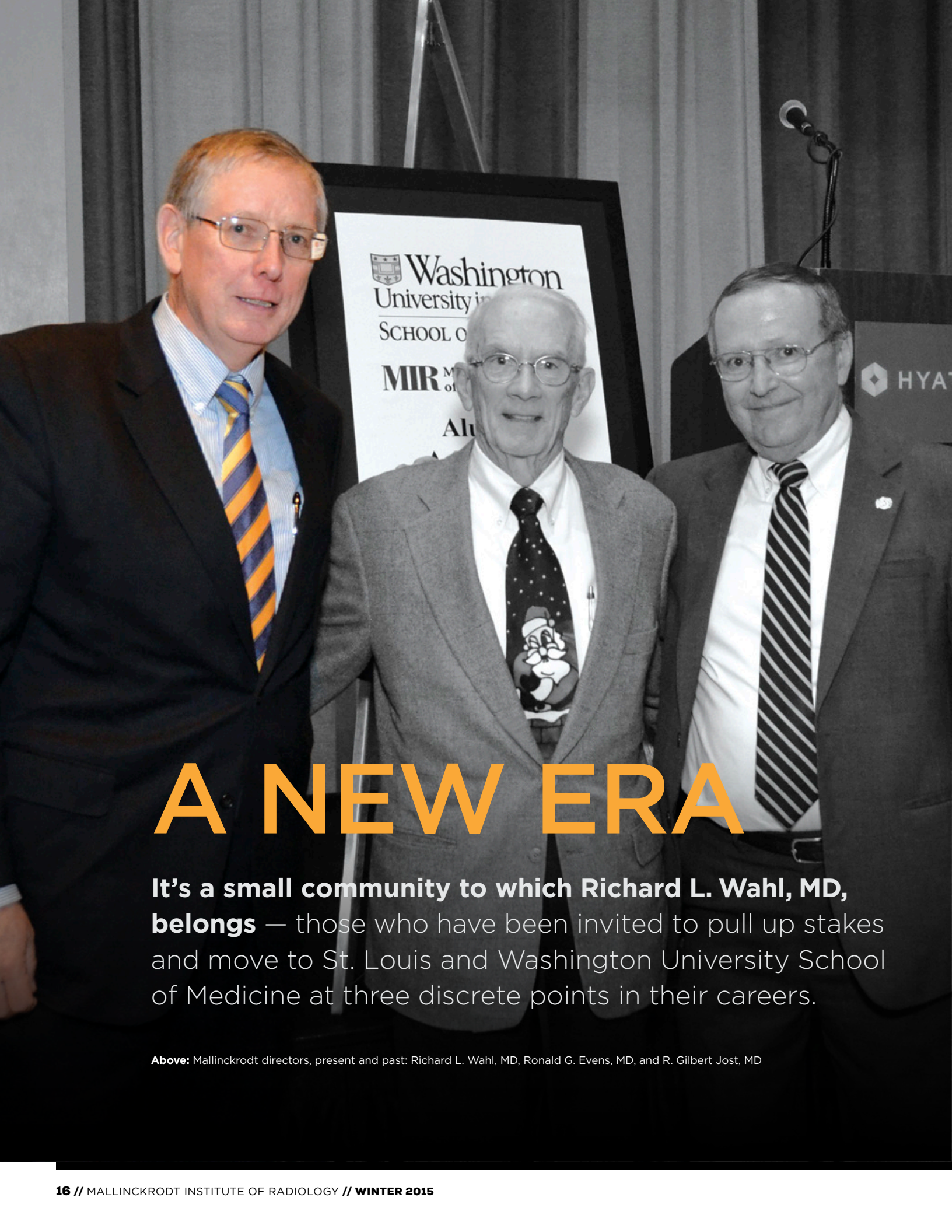
“The current standard of care for patients with metastatic sarcoma is to remain on chemotherapy, which often impedes lifestyle and forces patients to be seen on a regular basis,” says Van Tine. “The goal of our ablation trial is to take patients with limited metastatic disease — 10 or fewer lesions — who are controlled with chemotherapy and then ablate the lesions so that we can stop chemotherapy. Ablation is thought to cause a local killing of tumors as well as to augment the immune response by the release of tumor antigens upon tumor cell killing. We hope that the use of ablation therapy will lead to improved progression-free and chemotherapy-free survival, which will certainly improve quality of life for these patients.”

RELIEF FOR PAIN FROM DIFFUSE METASTATIC DISEASE

For some patients, the metastatic bone disease is so diffuse that ablation therapy is not possible. Even in these cases, Jennings offers alternative treatments that provide many with pain relief.

“Epidurals and joint injections often are given to patients with degenerative back disease and arthritis, respectively,” says Jennings. “These same treatments can be effective for metastatic cancer patients experiencing pain in those areas of the body. A simple, five-minute shot every few months can provide significant pain relief, obviating any need for ablation.

“The bottom line is that for many patients with metastatic bone disease there are options for relieving all or a significant amount of their pain and for reducing or eliminating their dependence on pain medications,” Jennings adds. “This in turn enables them to deal with other aspects of their cancer treatment and their everyday life.”



A NEW ERA

It's a small community to which Richard L. Wahl, MD, belongs — those who have been invited to pull up stakes and move to St. Louis and Washington University School of Medicine at three discrete points in their careers.

Above: Mallinckrodt directors, present and past: Richard L. Wahl, MD, Ronald G. Evens, MD, and R. Gilbert Jost, MD

Wahl came first to attend medical school after graduating in chemistry from Waverly, Iowa's Wartburg College, "the best school I could find within 300 feet of my house," he says. The second time was when he returned to Mallinckrodt Institute of Radiology in 1979 for training in diagnostic radiology and nuclear medicine after an internship at the University of California at San Diego where he lived a mile from the beach and "learned to take care of patients."

This third and decidedly most impactful move has him joining a smaller, more select group. As Wahl assumes the reins from R. Gilbert Jost, MD, he becomes only the sixth person to hold Mallinckrodt's top job in roughly 100 years of the department's history. Jost, who oversaw the operation for 15 years and ushered in the digital revolution in imaging, says, "The time is right for a change. Rich Wahl is extremely bright and has been very successful. He brings with him many new ideas and will do a great job."

Wahl comes back to MIR after spending 17 years at the University of Michigan followed by 14-plus years at Johns Hopkins University. There, he served as director of the Division of Nuclear Medicine and the department's vice chair for technology and new business development. He says several colleagues expressed surprise that he would leave the coast and his home on Baltimore's harbor. Put it down to Mallinckrodt's eminence, the chance to shape the future of radiology even more influentially, and the appeal of the School of Medicine model, where department heads enjoy great autonomy.

At Mallinckrodt, Wahl expects to continue to see patients and interpret images because, he says, "it's crucial to the mission that Mallinckrodt radiologists

be good clinicians," and it will keep him in close touch with residents and daily operations. The research that has shaped Wahl's career and that he continues to love also will be part of his work here; he is establishing his laboratories now.

But from his office on the 12th floor, he says emphatically that priority number one will be to make certain that "all three components of the institute's mission — patient care, teaching, and research — run well."

The biggest challenges he sees for radiology in general, and therefore Mallinckrodt in particular, have to do with the overarching topic of a changing financial environment. They include pioneering new technologies, effectively adding the services that evolve from them, ensuring patient access to those services, and developing emerging revenue streams.

He plans to engage the faculty to pursue patents (he holds 18) and to create and disseminate policies and practices from Mallinckrodt at the medical center to the satellite facilities that have become so important to business. Electronic imaging makes a distributed practice easier for radiology than for many other specialties, Wahl says, an advantage to exploit.

Another big change that he anticipates for the field is a move toward quantitative radiology and away from the qualitative and descriptive model. "No longer will we just be looking at the images," says Wahl. "The trend will be toward putting images from different modalities together, analyzing them, and discerning visual and quantitative patterns that describe the lesions that have been imaged, then using those patterns to arrive at prognosis and treatment."

He also recognizes the potential to advance radiochemistry, radiopharmaceutical therapy, and other innovative imaging techniques that only a few places like Mallinckrodt can offer. That's a natural direction, since he was among the first to explore the potential for using monoclonal antibodies and FDG PET to detect cancers and inflammation. That work, which helps tailor the treatment to the specific patient, is now quite widely deployed clinically.

Wahl also pursues methods for employing molecular imaging to steer biopsies with single-millimeter accuracy

and treatments for lymphoma that use antibodies to guide the delivery of personalized radiopharmaceuticals. That research has already resulted in two FDA-approved lymphoma-specific drugs and several FDA-approved guidance devices.

Under the same general heading of personalized radiology, Wahl works on software to assess tumor response to treatment and predict outcomes. “If we can see that a patient’s tumor is responding well, we can continue giving the same therapy or tailor it to the results — for example, deliver four rather than six cycles. If we don’t see the response we expect, we can change therapies.” The goals: improve patient outcomes, reduce side effects, and lower care costs.

In another research pursuit, Wahl uses positron emission tomography (PET) to image brown fat, the type of adipose tissue that keeps infants warm and once was thought to disappear in adults. He explains that brown fat persists in some adults and that it is metabolically active, burning calories unlike the less desirable white fat to which it is not closely related. He says: “It’s been almost like finding a new organ. It may turn out that the more active brown fat you have, the better.” And he points to emerging connections to weight loss, cancer risk related to obesity, and a potential impact on diabetes.

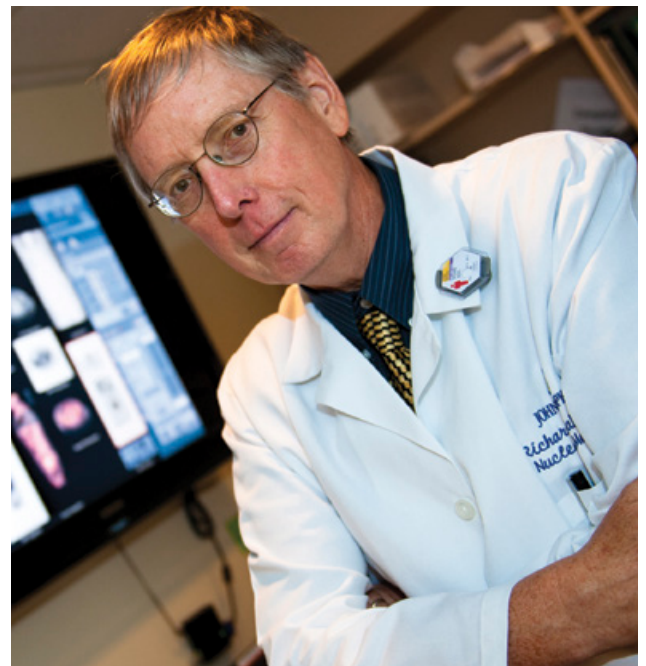
Wahl’s staunch interest in research can be traced to his second stint at Mallinckrodt, when former department head Ronald G. Evens, MD, was his active mentor. “I wasn’t certain, as a medical student, whether I wanted to pursue radiology or cardiology, and I talked with Ron at length about career choices. After selecting radiology, he allowed me to design a research-oriented residency tailored to my interests. I may have been one of the first to take devoted research time as a radiology resident,” Wahl says.

For his part, Evens says, “Rich was a successful medical student, with great interest in a research career. I encouraged him, allowed him flexibility within our residency program, and he flourished. He became one of our best residents, continuing his research and clinical accomplishments in nuclear medicine and radiology at other great medical centers.” Evens also expresses confidence in Wahl as the new director: “He is the first ‘outside’ chair in nearly 50 years and will bring with him experience and ideas from Johns Hopkins and Michigan; yet he is an ‘insider’ as well. I look forward to his leadership.”


Wahl’s earliest interest in medicine arose from a scientific bent and from the experience of witnessing the care that physicians provided for his father in the time before his dad’s death when Wahl was just 15. “I liked what the doctors did for my father, and medicine has allowed me to combine science with humanism,” he says. No family members before him had pursued science or medicine.

But plenty have since. All four of Wahl’s children are involved: One son is an MD/PhD in radiation oncology at the University of Michigan; another is an MD in internal medicine residency training at the University of Utah; a son and a daughter are both BSN/RNs in Minnesota. His wife, most recently a high school math teacher at an inner-city Baltimore school, two daughters-in-law, and two grandchildren round out the clan. One locus for the family is a summer cabin on Lake Michigan, where kayaking and golf are the main pastimes, though Wahl says of leisure and recreational pursuits in general, “I wish.”

Although he believes it’s important to step away occasionally to gain perspective, in the foreseeable future, work will dominate his time. “I’m pleased, honored, and privileged to accept this important role,” Wahl says. “Having trained here, it’s particularly gratifying to come back.” Again. 🍷



CASES OF THE CENTURY




Above: RSNA 2014 attendees looked back at the cases and technology that have marked the evolution of radiology

RSNA 2014

CELEBRATING 100 YEARS

Mallinckrodt Institute of Radiology faculty and staff joined radiology professionals from around the world at the annual meeting of the Radiological Society of North America (RSNA) in Chicago, November 30-December 5. The event — A Century of Transforming Medicine — was held at McCormick Place Convention Center and marked RSNA's centennial anniversary. Participants celebrated successes in discovery, innovation, and research, but were urged to push the boundaries of scientific inquiry. Keynote speaker Francis S. Collins, MD, PhD, director of the NIH (National Institutes of Health), spoke on the need to reinvigorate biomedical research in a time of budgetary constraints. More than 56,000 people attended RSNA. //





Current and former residents, faculty, and friends renewed acquaintances at RSNA 2014 and at the Mallinckrodt reception held at the Hyatt Regency of Chicago's Crystal Ballroom.

A Richard Wahl
B Shannon Farmakis, Becky Hulett
C Gilbert Jost, Sally Schwarz
D David Rubin, Susan Holley
E Faraz Khan, Dave Hovsepian
F Peter Herscovitch, Katie Wahl, Ron Evens
G Nicholas Shavladze, Eduard and Juana Kotlyarov
H Bryan Belikoff and Megan Olson, John Karageorgiou, Hilary Brazeal, Julie Mikus and Adam Sipe, John Symanski
I Kelly Botteron, Bob McKinstry, Richard Wahl
J Laura Ruhrwien Parli, Joy Haven
K Jim Junker, Margaret Junker

RSNA images photographed by Mickey Wynn, MIR Visual Media Center



SEAN D. PIERCE, MD, is chair of the Department of Radiology at Hackensack University Medical Center in Hackensack, New Jersey, and a partner in the Hackensack Radiology Group. As he serves both the physicians and patients at New Jersey's largest provider of inpatient and outpatient services, Pierce draws on lessons he learned during his residency at Mallinckrodt Institute of Radiology.

What attracted you to radiology?

I am a very visual person. And I enjoy technology. For me, radiology was a wonderful way to integrate those interests. From a visual perspective, what we deal with in radiology are images, representations of things that are behind the veil. We are able to see things that other people can't see without opening a patient up. That is a bit of magic. That was something that immediately attracted me — that sense of wonder.

Another thing was the technology. We have great toys in radiology. We're right at the leading edge, and everything is on fast-forward. If there's anything that's true about radiology, it is that things will always change. We're always re-inventing ourselves. Other specialties are beneficiaries of what originates in radiology. It is a great engine of innovation.

Why did you choose Mallinckrodt for your residency training?

When I came for my visit and saw Mallinckrodt, it was eye opening. Frankly, it was a little like Disneyland. Seeing a multistory building dedicated strictly to radiology was extraordinary. The amount of resources dedicated to this one specialty was incredibly impressive to someone entering the field.

Who were some of the instructors at Mallinckrodt who left the greatest impression upon you?

Stuart Sagel was head of chest (cardiothoracic imaging). He was brilliant and an incredibly inspirational person. He could have a strong personality. In days past, we dealt with physical film we'd look at on our view boxes. The instinct would be to reach for it and touch the film. He didn't approve of that. He would ask, "So, what does that feel like?" You realized at that moment you'd made a mistake. Louis Gilula was the orthopedic imaging head. More than anything else, he taught me about the relationship between the radiologist and the referring clinician. In radiology in general, we operate behind closed doors. We tend to fall into our own world and



Above: Sean D. Pierce, MD

own sphere. But truthfully, we are the doctors' doctor. Lou taught me it is incumbent upon us to understand what kind of problem the referring clinician was facing and what we could do, what information we could add, to improve the life of the patient.

How else does your time at Mallinckrodt continue to play a role in your life today?

Several people I met during my time at Mallinckrodt are the people I count as my absolute closest friends. There's Sanjeev Bhalla, who is now chief of chest at Mallinckrodt. Christine "Cooky" Menias is at the Mayo Clinic in Scottsdale, Arizona. Perry Pickhardt is now chief of gastrointestinal imaging at the University of Wisconsin School of Medicine and Public Health in Madison, Wisconsin. All three of these people really helped me so much in my personal growth and in making my time at Mallinckrodt an absolutely positive experience.

CAREER PROFILE

SEAN D. PIERCE, MD

2001 // Neuroradiology Fellow
New York University Medical Center

1999 // Diagnostic Radiology Resident
Mallinckrodt Institute of Radiology,
Washington University School
of Medicine

1995 // Medical Intern
Mount Auburn Hospital
Cambridge, Massachusetts

1994 // MD
Harvard Medical School

1989 // BA
Harvard College

Tell us about your current dual positions as chair of the Department of Radiology for Hackensack University Medical Center and as a partner of Hackensack Radiology Group.

Our practice is in contract with the hospital. I've been in practice 14 years, and I have been chairman at Hackensack for two years. It's a 900-bed hospital, New Jersey's largest. Within the department we have 225 employees. I'm also chair of the Department of Radiology at a satellite location, Hackensack UMC at Pascack Valley, which is a 128-bed hospital. I split my time between administrative tasks at both institutions as well as clinical duties. Several years ago, our practice made the commitment of providing 24-hour, seven-days-a-week radiology internal coverage to the hospital. We have an active pool of around 25 radiologists, who are split between three shifts to provide that coverage. We're a busy group.

What projects have you ushered in as chair?

We've undergone a bit of a technological revolution. We've been very proactive in instituting measures to achieve "meaningful use" compliance ahead of regulatory deadlines and have promoted methods to facilitate direct electronic exchange of images and information between clinicians and patients. We also have achieved some success in leveraging voice recognition technologies and, in the near future, plan to deploy clinical decision support technologies within the electronic health record.

How has your practice changed over time?

Previously, radiologists had seen ourselves primarily responsible for providing interpretative services for a large number of images. Now we find ourselves expanding our value-added qualitative practice; we're morphing into a greater level of service within the context of integrated care. That means we're also participating in the conversation about health care in conferences and in committees at the hospital and other health institutions. It is important for all of us to be aware and present.

What are your interests beyond radiology?

Photography has become a real passion. I know you could say that as a radiologist that I'm all about the image. However, life has taught me in the recent past that at the end of the day, all you have left after any given experience are the photographs and the memories.

Below: Pierce captures the action at an event with friends



LECTURES

Samuel I. Achilefu, PhD, professor of radiology, presented “Molecular Fluorescence Image-Guided Cancer Resection—From Bench to Bedside” at the Research in Progress Seminar held at Emory University’s Winship Cancer Institute on December 17, 2014.

Sanjeev Bhalla, MD, professor of radiology, was a visiting professor at Oregon Health & Science University School of Medicine where he presented on CT protocol and variations for imaging acute aortic syndromes at Radiology Grand Rounds on September 11, 2014.

Colin P. Derdeyn, MD, professor of radiology, presented “Head Positioning in Acute Stroke: Black Box Clinical Trial or Experiment in Physiology?” at the 2nd International Symposium on Collaterals to the Brain in Los Angeles on November 6, 2014. Derdeyn also presented “Long-term Outcomes from SAMMPRIS: Durability of Best Medical Therapy” at the Veith Symposium in New York on November 18, 2014, and “Pial Collaterals and the Collateral Index Score: Implications for Intervention” at the AIM Symposium in New York on November 20, 2014.

Jay P. Heiken, MD, professor of radiology, made several recent presentations: “MDCT Evaluation of Acute Mesenteric Ischemia; Abdominal Aortic Aneurysm Rupture: Critical Findings” at the 37th annual SCBT-MR Masters in Body Imaging course in New Orleans held September 28 to October 1, 2014; “Characterization and Management of Cystic Pancreatic Neoplasms” at the International Cancer Imaging Society Meeting and 13th Annual Teaching

Course in Heidelberg, Germany, from October 9-11, 2014; and “Abdominal Aortic Aneurysm Rupture: Critical Findings; Characterization of Liver Masses with CT and MR: Benign Lesions; Characterization of Liver Masses with CT and MR: Malignant Lesions; Hepatobiliary MR Contrast Agents: Advantages and Pitfalls; LI-RADS; Incidental Pancreatic Cysts: Clinical Management” at the Chilean Congress of Radiology 2014 in Santiago, Chile, from October 23-25, 2014. Heiken also was the James H. Scatliff Visiting Professor – University of North Carolina, in Chapel Hill, North Carolina, on October 31, 2014, where he lectured on “LI-RADS and the Management of Hepatocellular Carcinoma: A Paradigm for the Future of Radiology.”

Robert C. McKinstry III, MD, PhD, professor of radiology and of pediatrics, presented “MR Imaging of Brain Development” at Radiology Grand Rounds at Stanford School of Medicine in Palo Alto, California, on January 15, 2015.

Monica Shokeen, PhD, assistant professor of radiology, presented “Multi Modal Approaches toward Molecular Imaging of Multiple Myeloma” at the University of Pittsburgh Medical Center, Department of Radiology and Pittsburgh Center for Bone & Mineral Research on April 21, 2014. Shokeen also presented “Clinical and Pre-clinical Approaches for Imaging Multiple Myeloma” at the 46th annual meeting of the Society of Nuclear Medicine—India held at The Saha Institute of Nuclear Physics in Kolkata, India, on December 11, 2014.

Barry A. Siegel, MD, professor of radiology and of medicine, and vice chair for nuclear medicine in radiology, presented “Updates in Oncology: Imaging and Therapy, on a Baltic cruise in July 2014. Siegel also presented at the International Society of Radiology and Egyptian Society of Radiology and Nuclear Medicine, 28th International Congress of Radiology, Dubai, United Arab Emirates, from September 9-11, 2014. Siegel served as a visiting professor and radiology grand rounds lecturer at Stanford University School of Medicine in Palo Alto, California, on October 16, 2014.

Marilyn J. Siegel, MD, professor of radiology, presented lectures on pediatric general cases and other issues such as bowel US in gastrointestinal disorders, congenital heart MDCT & MR imaging, diffusion-weighted MRI in pediatric oncology, and whole body MRI of bone marrow disorders, at the International Society of Radiology and Egyptian Society of Radiology and Nuclear Medicine, 28th International Congress of Radiology, in Dubai, United Arab Emirates, from September 9-11, 2014. Siegel also presented “When to use RECIST, WHO, and Disease-Specific Imaging” at the 37th annual meeting of the Society of Computed Body Tomography & Magnetic Resonance on September 28, 2014, in New Orleans. At the National Diagnostic Imaging Symposium on December 8-9, 2014, in Orlando, Siegel presented “Breast Problems in Children and Adolescents,” covering issues such as CT and radiation doses, radiation risks in pregnancy, and low-dose tricks in kids.

RSNA 2014

A complete program of all Mallinckrodt presentations can be viewed at mir.wustl.edu (Education, Continuing Education, RSNA Radiological Society of North America).

GRANTS

Farrokh Dehdashti, MD, professor of radiology, received support for “Assessment of Functional Status of Estrogen Receptors in Breast Cancer by PET” from The Foundation for Barnes-Jewish Hospital’s Cancer Frontier Fund. As principal investigator, Dehdashti will determine if data from a non-invasive imaging test will provide specific information that can be used to provide patients with individualized treatments.

Colin P. Derdeyn, MD, professor of radiology, is co-investigator on two NIH grants: a \$396,898 grant for “Rapid STEMI Fibrinolysis for Underserved Populations” and a \$1,404,000 grant for “Vascular Interfaces for Brain Imaging and Stimulation.” He is co-principal investigator on a \$1,605,610 NIH grant for “Rapid Magnetomotive Thrombolysis for Stroke.”

Yongjian Liu, PhD, assistant professor of radiology, received an NIH RO1 award for “Chemokine Receptors Based Nanoagents Imaging Atherosclerosis.”

Jonathan E. McConathy, MD, PhD, assistant professor of radiology, received support for “FDOPA-PET/MRI for the Pre-operative Evaluation of Gliomas” from The Foundation for Barnes-Jewish Hospital’s Cancer Frontier Fund.

As principal investigator, McConathy will combine imaging techniques to better define brain tumor borders, improve surgical outcomes, and identify patients with aggressive tumors needing more urgent treatment.

Monica Shokeen, PhD, assistant professor of radiology, is the principal investigator for a \$50,000 grant received from the BJHF-ICTS Funding Program for “C-11-Acetate Molecular Imaging of Myeloma-A Novel Paradigm.”

Jinbin Xu, PhD, instructor in radiology and principal investigator, and **Joel S. Perlmutter, MD**, professor of radiology, received a \$152,500 NIH grant for “Dopamine D1, D2, and D3 receptors as biomarkers for imaging nigrostriatal neurons.” Xu and co-investigator Joel Perlmutter also received a \$50,000 grant from the American Parkinson Disease Association, Inc., for “Peripheral benzodiazepine receptor as a biomarker for imaging nigrostriatal neurons.”

HONORS/AWARDS

Jay P. Heiken, MD, professor of radiology, was awarded the Gold Medal of the International Cancer Imaging Society, Heidelberg, Germany, on October 10, 2014.

Second-year resident **Adam Sipe, MD**, received the Novelline Award and *Summa Cum Laude* from the American Society of Emergency Radiology at its 2014 annual meeting for his poster presentation, “Red Connection: A Pictorial Review of Aortic Fistulae.”

APPOINTMENTS/ PROMOTIONS

Tammie Lee Smith Benzinger, MD
Associate Professor of Radiology

Gretchen M. Foltz, MD
Assistant Professor of Radiology

Michael V. Friedman, MD
Assistant Professor of Radiology

Carlos J. Guevara, MD
Assistant Professor of Radiology

Suzanne E. Lapi, PhD
Associate Professor of Radiology

Jeremiah R. Long, MD
Assistant Professor of Radiology

John R. Pruett Jr., MD, PhD
Associate Professor of Radiology
(primary appointment in the
Department of Psychiatry)

Sally W. Schwarz, MS
Professor of Radiology

Koresh I. Shoghi, PhD
Associate Professor of Radiology

Monica Shokeen, PhD
Assistant Professor of Radiology

Motoyo Yano, MD, PhD
Assistant Professor of Radiology

IN THE MIND'S EYE: MIR scientist participates in WUSM Art Show

Parinaz Massoumzadeh, PhD, began sketching trees years ago during a bumpy patch in her marriage. During one counseling session, mental imagery was used and a vision of an old yet strong and sturdy tree appeared in the mind of the Mallinckrodt staff scientist.

The mental image of the tree remained with Massoumzadeh as an iconic guidepost of sorts over the years. And as the tree's appearance evolved in her mind's eye, so have her methods to capture it through illustration. Methods have changed from simple pencil sketches on restaurant napkins to collaborative efforts involving friends, digital tools, and calligraphy. The latest version was recently on display in the first floor of the Farrell Learning and Teaching Center. Massoumzadeh was one of 93 participants in the 2015 Washington University School of Medicine Art Show. Her submission — a thick-trunked black, grey, and teal tree — is called "The Tree of Love and Wisdom." A smaller digitized negative version bearing the same name was also on display.

Regarding what the tree means to her, "As a foreigner and when one gets removed from one place to another, it may be more difficult to take root," says Massoumzadeh, who came to the United States from Iran in 1985 in pursuit of higher education. "The (tree) root represents love. It's not always visible, but it's there. The trunk is compassion and kindness.



Above: Parinaz Massoumzadeh, PhD, with some of her art pieces

"The branches are the good qualities that I look for in my life and in others," says Massoumzadeh. "One of the branches is joy... forgiveness is another branch. Without forgiveness you cannot have complete joy, and you cannot live without trust."

"I think that science is art and art is science; I think science and art are intertwined," says Massoumzadeh. "Art frees you to be creative. That helps you to move forward in science."

For the past several years, Massoumzadeh has been investigating oxygen-sensitive MR techniques to obtain cerebral oxygen extraction fraction maps (OEF-MR) to quantify hypoxia in brain tumors. If proven, the technique could replace triple pack PET scans as a more affordable alternative.

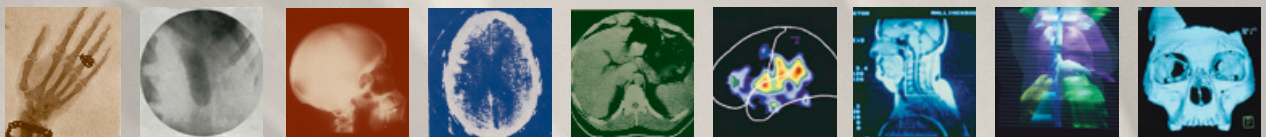
And what about Massoumzadeh's marriage? It's solid as a firmly planted tree, and she and her husband have been taking art lessons together. ▮

"I think that science is art and art is science; I think science and art are intertwined. Art frees you to be creative. That helps you to move forward in science."

LEADING *Together*

Mallinckrodt Institute of Radiology, the Department of Radiology at Washington University School of Medicine, is working to strengthen its reputation for excellence – through outstanding resident and fellow education programs, pioneering research, and innovative advances in patient care. Philanthropic resources play an important part in the continued advancement and future work of Mallinckrodt and those who train in its programs.

There are many ways you can make a gift to support Mallinckrodt Institute of Radiology – from joining the Eliot Society with a gift of \$1,000 or more to a larger gift opportunity, such as supporting an endowed professorship.



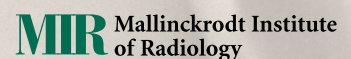
Online donations can be made at gifts.wustl.edu. To ensure that your donation is designated for Mallinckrodt Institute of Radiology, please follow these directions:

- At Designation Options, please choose the fourth box marked “Other”
- Type in Mallinckrodt Institute of Radiology in the space provided

For more information, please contact:

Medical Alumni & Development Programs

Campus Box 1247
7425 Forsyth Blvd., Suite 2100
St. Louis, MO 63105-2161
(314) 935-9691



A LOOK BACK

MODERN INVESTIGATION OF ANCIENT SPECIMENS

Mallinckrodt researchers are often called upon to investigate historical puzzles. In 2005, faculty member Charles F. Hildebolt, DDS, PhD, professor of radiology and adjunct professor of anthropology, was called in to scan the model of an ancient hominid skull — part of a nearly complete female skeleton, some 18,000 years old, discovered on the Indonesian island of Flores. This skeleton, known informally as “the Hobbit,” appeared to be that of a new human-like species, *Homo floresiensis*, only one meter tall and with a brain one-third the size of human brains today.

When a child-sized mummy turned up in 2007 in the storage facility of the Saint Louis Science Center, a Mallinckrodt team — Hildebolt, senior research engineer Kirk Smith, and pediatric radiologist Steven Don, MD — embarked on a yearlong quest to discover more about it. Through CT scanning, DNA testing, and radiocarbon dating, they and other scientists determined that the child was a boy, seven to eight months old, Egyptian, and around 2,000 years old, though they could not determine the cause of death. ▨

A CT scan of child mummy

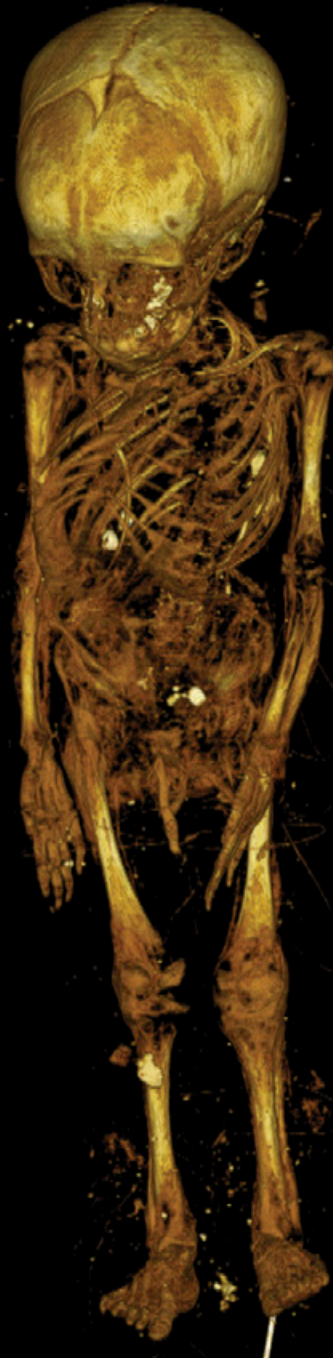
B Child mummy placed in CT scanner

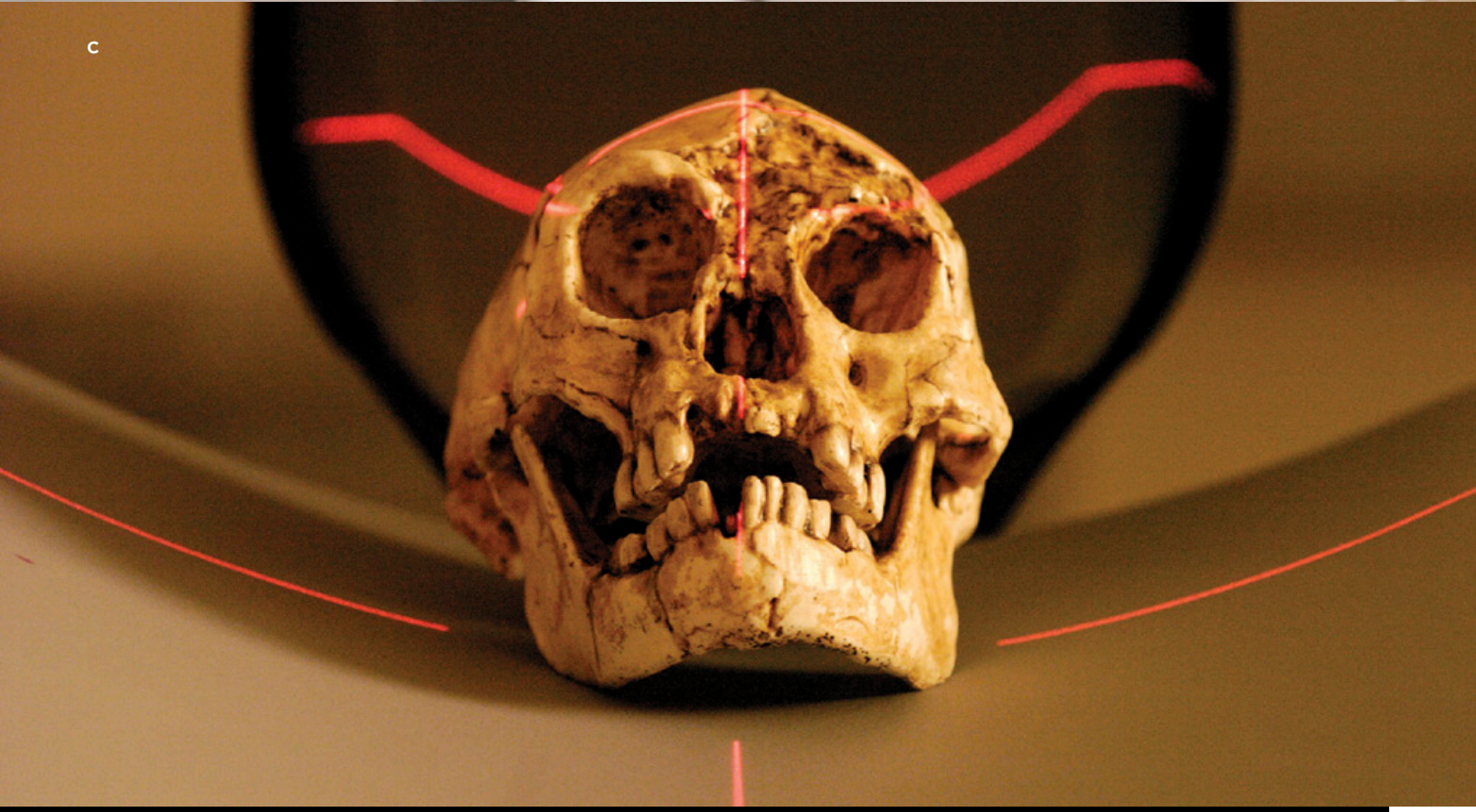
C “The Hobbit” skull is scanned

Images from Mallinckrodt Institute of Radiology Archives

Text from Imaging & Innovation: A History of Mallinckrodt Institute of Radiology by Candace O'Connor

A





FOCAL SPOT

FS

Non-Profit Organization
U.S. Postage PAID
St. Louis, Missouri
Permit No. 2535

Address Service Requested

 Washington
University in St. Louis
SCHOOL OF MEDICINE

MIR Mallinckrodt Institute
of Radiology

Campus Box 8131
660 S. Euclid Avenue
St. Louis, MO 63110

mir.wustl.edu



Below: The Radiological Society of North America (RSNA) recently celebrated its centennial anniversary, and Mallinckrodt Institute of Radiology alumni, faculty, and staff were there to mark the occasion. To learn more about the event, please turn to page 19.

