

Dermatoscopic evaluation of alopecia areata

Qasim S. Al Chalabi* , Anfal L. Al harbawi* , Hala N. Al Salman*

*Department of Medicine, College of Medicine , University of Mosul , Mosul , Iraq
Correspondence: qasimalchalabi@uomosul.edu.iq

(Ann Coll Med Mosul 2021; 43 (2):144-151).

Received: 26th Sept. 2021; Accepted: 24th Octo. 2021.

ABSTRACT

Objective: to assess the dermoscopic characteristics of alopecia areata and their correlations with clinical variants, nail changes, and severity of the disease.

Patients and methods: This is a case-series study, which was carried out on 209 patients with alopecia areata in the Department of Dermatology from January 2020 to January 2021 at Ibn-Sina Teaching Hospital, Mosul, Iraq. After the patient's acceptance to participate in this study, a detailed history was taken. A clinical and dermatological examination was done included hair pulling test, and disease severity was graded according to the severity of alopecia tool (SALT) scoring. Each patch of alopecia areata was examined and assessed using a SKIARY Smartphone Dermatoscope©, photos were taken and evaluated by three dermatologist experts in dermatoscopy separately and their notes were recorded, evaluated, and tabulated. Spearman`s rank-order correlation test was used for data analysis.

Results: Two hundred and nine patients with alopecia areata had participated in this research. The male to female ratio was 1.5:1. The mean age of presentation was of 21 ± 10.64 years. 45% of the patients had Grade S2 severity. Yellow dots were the most common dermatoscopic finding followed by black dots, while perifollicular scales were the least common. Yellow dots, broken hairs, exclamation mark hairs, and nails changes were correlated with the severe form of the disease ($P < 0.05$).

Conclusion: Alopecia areata has many dermatoscopic manifestations which are helpful in the clinical diagnosis and prognosis of the disease. Yellow dots, black dots, exclamation marks hair, broken hairs, and nail changes are related to the severe form of the disease.

Keywords: Alopecia areata, yellow dots, dermatoscopy .

خاصية التنظير الجلدي لداء الثعلبة

قاسم سالم الجليبي* ، انفال ليث الحرباوي* ، هالة نذير السلطان*
*فرع الطب الباطني ، كلية الطب ، جامعة الموصل ، الموصل ، العراق

الخلاصة

الاهداف : تحديد خصائص المنظار الجلدي (درماتسكوب) في مرض داء الثعلبة وارتباطاتها مع المتغيرات السريرية، وتغيرات الأظافر، وشدة المرض.

المرضى وطرق البحث: أجريت دراسة سلسة الحالات ضمت ٢٠٩ مريض مصابين بداء الثعلب في قسم الأمراض الجلدية في مستشفى ابن سينا من يناير ٢٠٢٠ إلى يناير ٢٠٢١ في مدينة الموصل، العراق . بعد موافقه المريض للمشاركة في البحث تم أخذ تاريخ مرضي مفصل ، وإجراء فحص سريري وجلدي شامل وأختبار سحب الشعر ، وصنفت شدة المرض وفقا لشدة نظام تسجيل أدوات الثعلبة (SALT) . ثم فحص كل مريض مصاب بداء الثعلبة باستخدام منظار الجلد SKIARY©، تم التقاط الصور وتقييمها من قبل ثلاثة خبراء الأمراض الجلدية في تنظير الجلد بشكل منفصل وسجلت ملاحظاتهم، وتقييماتهم، و جدولتها. وقد أجريت اختبارات مخبرية مثل خزعة الجلد وغيرها من الاختبارات عند الحاجة. تم استخدام اختبار معامل سبيرمان للارتباط لتحليل البيانات.

النتائج : شارك في هذا البحث مائتان وتسعة مرضى يعانون من داء الثعلبة. وكانت نسبة الذكور إلى الإناث (١.٥ : ١) وكان متوسط عمر المريض 21 ± 10.64 سنة. ٤٥٪ من المرضى لديهم شدة المرض S2. كانت النقاط الصفراء هي النتيجة الأكثر شيوعا تليها النقاط السوداء ، في حين كانت القشره حول جيوب الشعر هي الأقل شيوعا. ارتبطت النقاط الصفراء والشعر المكسور وشعر علامة التعجب وتغيرات الأظافر بالشكل الشديد للمرض ($P < 0.05$).

الاستنتاج : داء الثعلبية لديه العديد من المظاهر التنظيرية التي تساعد في التشخيص السريري وتشخيص المرض. ترتبط النقاط الصفراء والنقاط السوداء وعلامات التعجب والشعر المكسور وتغيرات الأظافر بالشكل الشديد للمرض.

الكلمات المفتاحية : داء الثعلبية ، النقاط الصفراء ، منظار الجلد .

INTRODUCTION

Alopecia areata is one of the commonest autoimmune non-cicatricial hair loss that affects different parts of hair-bearing areas of the body¹. Nearly 2 percent of the population at some stage of their life may be affected by alopecia areata while the prevalence of alopecia areata was reported to be between 0.1% to 0.2%². Both sexes are affected equally and it can occur at any age, although it starts in the first three decades of life in most patients. Alopecia areata can be present clinically as a well-defined patch of hair loss, diffuse hair loss, reticulate hair loss, ophiasis, ophiasis inversus, alopecia totalis (complete loss of scalp hair), or alopecia universalis (hair loss of all over the body)³.

The disease can be diagnosed clinically as well-defined round or oval patches of hair loss with apparent smooth normal skin and exclamation point hair at the border of these lesions, unpigmented hairs can be seen scattered throughout the lesion¹. Nails can be affected in about 10–44% of alopecia areata patients and it is more common in the severe form of the disease³. Alopecia areata is usually associated with pitting of the nails usually fine and stippled; some patients have less well-defined rough accentuated longitudinal ridging of the nail plates (trachyonychia). Other patients may suffer from nail dystrophy that can be the most troublesome aspect of the disease³.

Dermoscopy is a non-invasive diagnostic utility used to evaluate many skin and hair disorders^{4,5}. Dermoscopy may aid in the diagnosis of many uncertain hair disorders one of them is alopecia areata⁶. Different dermoscopic characteristics are seen in alopecia areata that are already mentioned in other studies such as, black dots (BDs), yellow dots (YDs), tapering hairs (exclamation mark hairs) (EHs), broken hairs (BHs), and short vellus hairs (SVHs)⁷⁻¹⁰.

The association of YDs and other dermoscopic findings with the severe form of the disease were documented^{7,9}. However, other studies failed to correlate these dermoscopic findings with the clinical patterns of alopecia areata^{8,10}.

Few studies of dermoscopic manifestation of alopecia areata were conducted in Iraq. Therefore, this study was done to determine the dermoscopic characteristics of alopecia areata and their

correlations with clinical variants, nail changes, and severity of the disease

PATIENTS AND METHODS

This is a case-series study, which was carried out on 209 patients with alopecia areata in the Department of Dermatology at Ibn-Sina Teaching Hospital, Mosul, Iraq. The study was conducted from January 2020 to January 2021. Patients were selected randomly. Both sexes and all ages of alopecia areata patients who were willing to provide informed consent were included in this study. Other patients who had cicatricial and non-cicatricial hair loss including tinea capitis, tractional alopecia, and androgenetic alopecia were excluded from this study.

A detailed history was taken, clinical and dermatological examinations were done included hair pulling test, and disease severity was graded according to the severity of alopecia tool (SALT) scoring¹¹.

The severity of alopecia areata was assessed using severity of alopecia tool (SALT)¹¹. Scalp hair loss ranged from S1 to S5 (S0=no hair loss, S1=less than 25 percent hair loss; S2=26%–50% hair loss, S3=51%–75% hair loss, S4=76%–99% hair loss, S5=total scalp hair loss). The loss of body hair ranged from B0 to B2, where B0 represented no loss, B1 some loss, and B2 complete loss (excluding the scalp), Nail involvement ranged from N0 to N1, N0 represented no nail involvement while N1 represented nail involvement¹¹.

Each patch of alopecia areata was examined and assessed using a SKIARY Smartphone Dermatoscope[®] held by an adaptor on Samsung Note 5[®], photos were taken and evaluated by three dermatologist experts in dermatoscopy separately and their notes were recorded, evaluated, and tabulated. Laboratory tests such as skin biopsy and other tests had been performed when required.

Statistical Analysis

Data are presented as mean \pm SD and were analyzed using Spearman's rank-order correlation test. The data were processed using statistical package IBM[®] SPSS version 26.

RESULTS

Two hundred and nine patients with alopecia areata participated in this study. Males represented 61.3% (128 patients) of the cases while females represented about 38.8% (81 patients) with a male to female ratio was 1.5:1. The patient's age was ranged from 3 to 55 years with a mean age of 21 ± 10.6 years. The most common age group affected was 20-29 years which represented 32% of the patients (Table 1). Duration of illness was varied from 3 weeks to 17 years with a mean ± SD of 16.8 ± 3.7 months (duration of illness was less than 6 months in 126 (60.28%) patients). Family history of alopecia areata was found in 33 (15.78%) patients.

Table 1. The distribution of alopecia areata according to age groups.

| Age groups (Years) | Males | Females | Total number of patients | Percentage | p-value |
|--------------------|-------|---------|--------------------------|------------|---------|
| 1-9 | 17 | 12 | 29 | 13.9% | 0.0001* |
| 10-19 | 43 | 21 | 64 | 30.6% | 0.0001* |
| 20-29 | 37 | 30 | 67 | 32.1% | 0.0001* |
| 30-39 | 24 | 12 | 36 | 17.2% | 0.0001* |
| 40-55 | 7 | 6 | 13 | 6.2% | 0.0001* |
| Total | 128 | 81 | 209 | 100% | |

*p-value is significant (<0.05)

Multiple patches of alopecia areata (more than 3 patches) were the highest pattern, found in 122 (58.37%) patients, while the reticular type was the least common variant (2.8%). Other clinical patterns of alopecia areata are seen in Table 2.

45% of patients had S2 severity according to SALT scoring system, but only 11 (5.3%) patients had S5 severity. YDs (43.5%) were the most common finding followed by BDs (33.9%) and the least sign seen was tulip hairs in 11 (5.3%) of patients, other dermatoscopic findings are shown in Table 2. Dermatoscopic signs of alopecia areata were seen in Figures 1-3

Table 2. Clinical patterns, the severity of alopecia (SALT scoring), and dermatoscopic findings (n=209)

| Parameters | Number of patients | Percentage |
|---------------------------------|--------------------|------------|
| Clinical pattern | | |
| Localized | 62 | 29.6% |
| Multiple | 122 | 58.4% |
| Reticular | 6 | 2.8% |
| Ophiasis | 34 | 16.2% |
| Sisaphio | 15 | 7.1% |
| Alopecia totalis | 14 | 6.7% |
| Alopecia universalis | 11 | 5.3% |
| SALT scoring[#] | | |
| S1 | 65 | 31.1% |
| S2 | 94 | 45% |
| S3 | 25 | 12% |
| S4 | 14 | 6.6% |
| S5 | 11 | 5.3% |
| B1 | 45 | 21.5% |
| B2 | 11 | 5.3% |
| N0 | 181 | 86.6% |
| N1 | 28 | 13.4% |
| Dermatoscopic findings | | |
| Black dots (BDs) | 71 | 33.9% |
| Yellow dots (YDs) | 91 | 43.5% |
| Broken hairs (BHs) | 42 | 20% |
| Exclamation mark hairs (EHs) | 43 | 20.5% |
| Short vellus hairs (SVHs) | 57 | 27.27% |
| Coudability hairs (CHs) | 18 | 8.6% |
| Tulip hairs (THs) | 11 | 5.26% |
| Pigtail hairs (PTHs) | 28 | 13.4% |
| Telangiectasia (T) | 27 | 12.9% |
| Perifollicular scales (PS) | 15 | 7.1% |

[#]SALT: severity of alopecia tool scoring system; S1-S5: severity of scalp hair loss; B1: partial body hair loss; B2: complete body hair loss (excluding the scalp); N0: no nail involvement; N1: nail involvement.

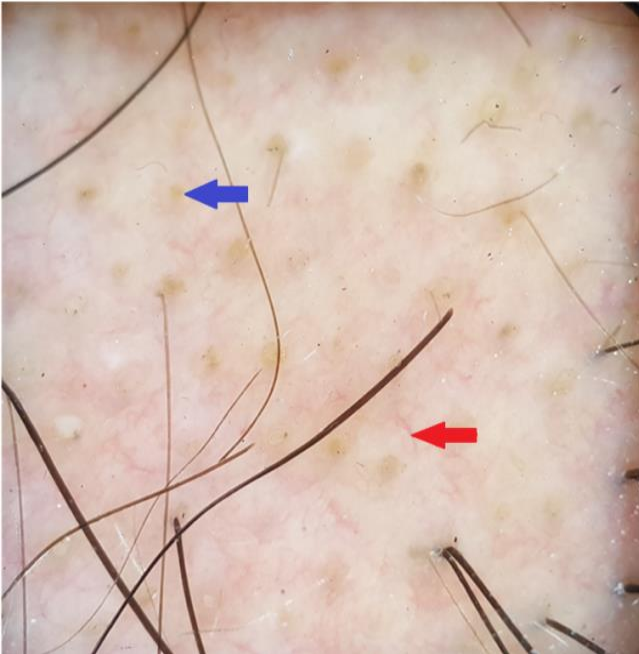


Figure 1. Blue arrow shows yellow dots, red arrow shows telangiectasia.

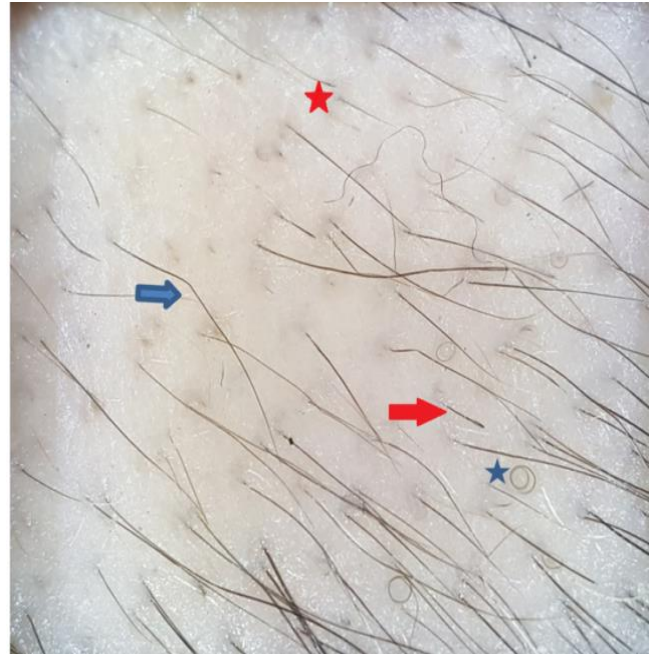


Figure 2. Blue arrow shows coulability hairs, red arrow shows tulip hair, blue star shows pigtail hair, red star shows Short vellus hair.

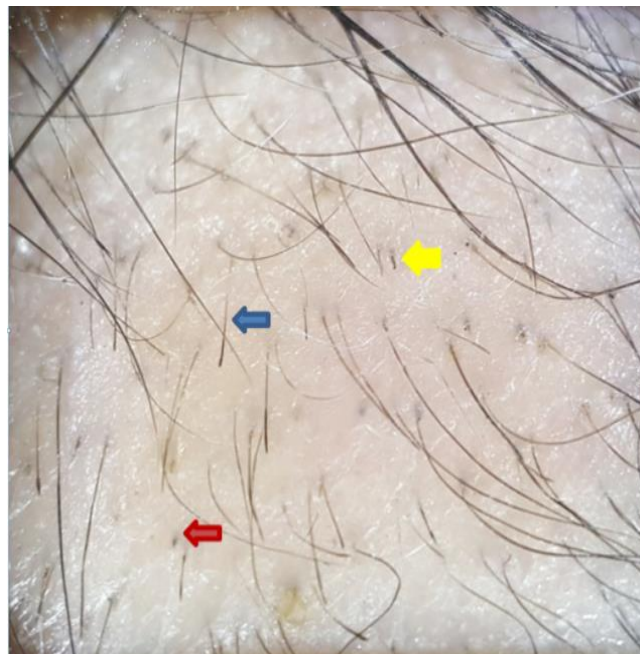

Figure 3. Blue arrow shows exclamation mark hairs, red arrow shows black dot, yellow arrow shows broken hairs.

There was a significant correlation of YDs, BDs, Ehs, and BH with the severity of alopecia areata ($p < 0.01$), as shown by Table 3

Table 3. Correlation between dermoscopic findings and severity of alopecia areata

| SEVERITY OF AA | BDs N(%) | YDs N(%) | BHs N(%) | EHS N(%) | SVHs N(%) | CH N(%) | TH N(%) | PTH N(%) | T N(%) | PS N(%) |
|-----------------|--------------------|--------------------|--------------------|--------------------|-----------|---------|---------|----------|---------|---------|
| S1 (n=65) | 21(32.3) | 20(30.7) | 13(20) | 12(18.4) | 18(27.6) | 7(10.7) | 3(4.6) | 7(10.7) | 9(13.8) | 5(7.7) |
| S2 (n=94) | 27(28.7) | 27(28.7) | 8(8.5) | 14(14.9) | 24(25.5) | 7(7.4) | 4(4.2) | 11(11.7) | 8(8.5) | 6(6.3) |
| S3 (n=25) | 10(40) | 19(76) | 9(36) | 5(20) | 8(32) | 2(8) | 1(4) | 4(16) | 2(8) | 2(8) |
| S4 (n=14) | 12(85.7) | 14(100) | 12(85.7) | 9(64.2) | 7(50) | 2(14.2) | 3(21.4) | 5(35.7) | 6(42.8) | 2(14.2) |
| S5 (n=11) | 1(9) | 11(100) | 1(9) | 3(27.2) | 0 | 0 | 0 | 1(9) | 2(18) | 1(9) |
| B1 (n=45) | 37(82.2) | 34(75.5) | 17(37.7) | 15(33.3) | 22(48.8) | 3(6.6) | 2(4.4) | 9(20) | 6(13.3) | 7(15.5) |
| B2 (n=11) | 1(9) | 11(100) | 1(9) | 3(27.2) | 0 | 0 | 0 | 1(9) | 2(18) | 1(9) |
| <i>p</i> -value | 0.001 ^S | 0.001 ^S | 0.004 ^S | 0.009 ^S | NS | NS | NS | NS | NS | NS |

**p*-value is significant (<0.05)

BDs: black dots; YDs: yellow dots; BHs: broken hair; EHS: exclamation mark hairs; SVHs: short vellus hairs; CH: coudability hairs; TH: tulip hairs; PTH: pigtail hair; T: telangiectasia; PS: perifollicular scaling; S: significant *p*-values; NS: nonsignificant *p*-values.

Nails involvement was seen in 28 patients in the current study, the duration of nails involvement was ranged from 1 to 17 years with a mean of 4 ± 3.7 years. Nails pitting were found in 21 patients, trachyonychia in 4 patients, while longitudinal striation was only seen in 3 patients. Nail changes were correlated with disease severity with *p*-value <0.001 as depicted in Table 4.

Table 4. Correlation between clinical patterns of alopecia areata and nail involvement.

| PATTERNS OF AA | NAIL CHANGES PRESENT | NAIL CHANGES ABSENT | TOTAL NUMBER OF THE PATIENTS [#] |
|------------------|----------------------|---------------------|---|
| Localized Patchy | 4 | 58 | 64 |
| Multiple patchy | 8 | 114 | 122 |
| Ophiasis | 2 | 16 | 18 |
| Totalis | 5 | 9 | 14 |
| Universalis | 10 | 1 | 11 |
| <i>P</i> -VALUE* | 0.001 ^S | 0.001 ^S | |

[#] Patient may had more than one clinical pattern.

The only significant correlation ($p < 0.01$) with the clinical variants of alopecia areata are seen in YDs, BHs, and EHS (Table 5). YDs were found in all patients of alopecia totalis and universalis, while BHs and EHS were found in 85.7% and 64.2% of the patients of alopecia totalis, respectively. Other dermoscopic findings according to clinical variants are seen in Table 5.

Table 5. Correlation between dermoscopic findings and patterns of alopecia areata.

| DERMOSCOPIIC FINDINGS | LOCALIZED PATCHY n=62, N(%) | MULTIPLE PATCHY n=122, N(%) | OPHIASIS n=34 [#] , N(%) | TOTALIS n=14, N(%) | UNIVERSALIS n=11, N(%) | P-VALUE |
|-----------------------|--------------------------------|--------------------------------|--------------------------------------|-----------------------|---------------------------|--------------------|
| BDs | 21(33.8) | 37(30.5) | 10(29.4) | 12(85.7) | 1(9) | 0.57 ^{NS} |
| YDs | 20(32.2) | 46(37.7) | 17(50) | 14(100) | 11(100) | 0.001 ^S |
| BHs | 11(17.7) | 17(13.9) | 9(26.4) | 12(85.7) | 1(9) | 0.011 ^S |
| EHS | 15(24.1) | 16(13.1) | 7(20.5) | 9(64.2) | 3(27.2) | 0.012 ^S |
| SVHs | 18(29) | 32(26.2) | 7(20.5) | 7(50) | 0(0) | 0.46 ^{NS} |
| CH | 7(11.3) | 9(7.3) | 4(11.7) | 2(14.2) | 0(0) | 0.71 ^{NS} |
| TH | 3(4.8) | 5(4.09) | 1(2.9) | 3(21.4) | 0(0) | 0.58 ^{NS} |
| PTH | 7(11.2) | 15(12.3) | 6(17.6) | 5(35.7) | 1(9) | 0.17 ^{NS} |
| T | 8(12.9) | 14(11.4) | 6(17.6) | 4(28.5) | 1(9) | 0.57 ^{NS} |
| PS | 4(6.4) | 8(6.5) | 3(8.8) | 2(14.2) | 1(9) | 0.68 ^{NS} |

*p-value is significant (<0.05)
 BDs: black dots; YDs: yellow dots; BHs: broken hair; EHS: exclamation mark hairs; SVHs: short vellus hairs; CH: coudability hairs; TH: tulip hairs; PTH: pigtail hair; T: telangiectasia; PS: perifollicular scaling; ^S: significant p-values; ^{NS}: nonsignificant p-values.
[#] Patient may had more than one clinical pattern.

DISCUSSION

Alopecia areata is one of the differential diagnoses of non-cicatricial alopecia and the diagnosis can be missed by other hair disorders, however, dermatoscopy which is a simple and non-invasive tool can help to reach a final diagnosis⁵. In the present study, most of the patients were in their second and third decades of life with male predominance, multiple patches of alopecia areata were the most common clinical pattern of the disease that affected more than half of the patients. These results are consistent with other studies^{7,8}. Regarding scalp severity, S2 grade of severity represented 45% of the patients, followed by Grade S1 in 31% of patients, these findings are also documented in other studies^{12,13}.

There are several dermoscopic signs of alopecia areata including YDs, BDs, SVHs, EHS, and BHs (8,9,14). YDs were the commonest dermoscopic sign noticed in this work. YDs were seen as yellow to yellow-pinkish hue, uniform in color, round, or polycyclic dots that vary in size. They represented an accumulation of keratinous material and sebum in the distended hair orifices. YDs were also noticed in other hair disorders¹⁴. The incidence of YDs in this research was 43.5 percent, which is similar to other studies^{15,16}, however, other workers found a higher incidence of YDs^{8,9}. The low frequency in this work might be attributed to the skin tone of the patients, different cleaning habits, and the type of dermatoscopy used since other researchers used an advanced dermatoscopy with a magnification of x32 and x140⁸.

Black dots were seen as destructed hair in the hair follicle orifices in 34 percent of the studied patients, similar to other workers¹⁶. However, other studies showed a higher incidence of BDs in patients who had type III and VI skin^{8,15}. This result might be due to that BDs could not be seen easily in white individuals and cuticle resistance^{8,15}.

In the present study, BHs were shown in about 86% of the patients who scored Grade S4, while Grade S2 only 8% of the patients which gave an indicator for disease severity. Some studies showed similar results^{9,10,12}.

Exclamation marks hair (tapering hairs) represented as an acute phase of the disease, usually seen as fractured hair with a frayed thicker distal end and narrow proximal shaft⁹. In this study, EHS might be correlated with disease severity since they were noticed in about two-thirds of the cases who scored Grade S4 severity. Other studies revealed that tapering hairs didn't correlate with disease severity^{7,16}.

Short vellus hairs are thin non-pigmented small hair which indicates regrowth of the hair and remission of the skin disease. In the current study, only 27% of the cases had SVHs, such a low frequency may be due to most of the patients examined before receiving treatment. These results were consistent with other workers⁹.

Pigtail hairs are thin coiled regrowing hairs that fall in few weeks¹⁰. In the current research, about 13% of the cases had PTHs, this result is consistent with other studies^{10,17}.

Coudability hairs are observed on other hair disorders and presented as normal looking-hair that can easily kink when bent and applying inward pressure¹⁸. About 9% of the cases of this study had CHs. CHs also correlated with the severity of the disease¹⁸. This study failed to find such a correlation due to the low incidence (9%) of this sign among cases.

Telangiectasia was seen in 13% of the present patients in the form of arborizing and tortuous blood vessels. These results might be due to the use of topical and intralesional steroid. This result was also seen in other studies⁷.

Tulip hairs were seen mainly in trichotillomania as diagonal fractures of the hair shaft⁷. This study revealed 5% of the individuals had THs, with a lower frequency than other studies⁷.

Perifollicular scales were noticed in 7% of our patients, this might be due to concurrent scaly disease affect the scalp (psoriasis, tinea capitis, frontal fibrosing alopecia, and seborrheic dermatitis) and irritation from topical treatments. Other studies had a higher frequency of PS⁷.

Nail involvement was seen in about 14% of our patients, nearly half of them suffered from alopecia universalis and totalis for a long duration. This study found a correlation between nail changes and clinical variants of alopecia areata. These results go parallel with other studies^{3,8}.

This study revealed different dermatoscopic findings of alopecia areata and their correlation with clinical patterns of the disease. YDs were seen in all patients with alopecia totalis, universalis, and nearly half of patients who suffered from ophiasis. Since, YDs correlated with disease severity, such association of YDs with alopecia totalis, universalis, and ophiasis were reasonable. These results were reported in other studies^{9,15}. BHs and EHs were mostly seen in patients who had alopecia totalis and also were correlated with the clinical patterns of the disease, similar results were seen in other studies^{9,16}.

Regarding scalp severity, this study found that YDs, BDs, BHs and, EHs, were markers for disease severity. YDs and BDs were correlated with scalp severity according to other studies^{7,12}. BHs were also correlated with disease severity, the same result displayed by other researchers⁷. However, other studies noticed that BHs were markers for disease activity^{9,16}.

This study noticed a correlation between EHs and disease severity, other workers noticed that EHs were associated with active disease¹⁶. Other studies failed to found a correlation with either disease activity or severity^{8,17}. Other studies noticed that SVHs had a negative correlation with disease severity^{12,16} but in this study, we didn't

notice such a correlation due to most of the patients didn't receive treatment.

In conclusion, dermatoscopy is a useful tool that can reveal several signs which are helpful in the clinical diagnosis and prognosis of alopecia areata. YDs, BHs and, EHs are correlated with clinical patterns of the disease. YDs, BDs, EHs, BHs, and nail changes are markers for the severe form of the disease.

Limitation of The Study

The uneven distribution of patients according to clinical varieties and SALT score was a drawback of our research. Similarly, the sample size for comparing certain variables like exclamation mark hairs, coudability hairs, and pigtail hairs was small.

Ethical Issues

The present study was approved by the Medical Research Ethics Committee, College of Medicine, University of Mosul, and Ninevah Health Directorate. Additionally, written informed consent was obtained from all patients before the examination.

Acknowledgment

This study was supported by College of Medicine, University of Mosul, and Ibn Sina Teaching Hospital, Mosul, Iraq.

REFERENCES

1. Pratt CH, King LE Jr, Messenger AG, Christiano AM, Sundberg JP. Alopecia areata. *Nat Rev Dis Primers*. 2017;3:17011. Published 2017 Mar 16. doi:10.1038/nrdp.2017.11
2. Mirzoyev SA, Schrum AG, Davis MD, Torgerson RR. Lifetime incidence risk of alopecia areata estimated at 2.1% by Rochester Epidemiology Project, 1990–2009. *J Invest Dermatol*. 2014;134:1141–1142. doi:10.1038/jid.2013.464.
3. Kasumagic-Halilovic E, Prohic A. Nail changes in alopecia areata: frequency and clinical presentation. *J Eur Acad Dermatol Venereol*. 2009;23:240–241. doi:10.1111/j.1468-3083.2008.02830.x
4. Blum, A., Kreuzsch, J., Stolz, W., Haenssle, H., Braun, R., Hofmann-Wellenhof, et al. Dermatoskopie bei malignen und benignen Hauttumoren : Indikation und standardisierte Terminologie [Dermoscopy for malignant and benign skin tumors : Indication and standardized terminology]. *Hautarzt*. 2017;68(8):653-673. doi:10.1007/s00105-017-4013-5
5. Lallas, A., Kyrgidis, A., Tzellos, T. G., Apalla, Z., Karakyriou, E., Karatolias, A., et al. Accuracy of dermoscopic criteria for the diagnosis of

- psoriasis, dermatitis, lichen planus and pityriasis rosea. *Br J Dermatol.* 2012;166(6):1198-1205. doi:10.1111/j.1365-2133.2012.10868.x
6. Al-Refu K. Clinical Significance of Trichoscopy in Common Causes of Hair Loss in Children: Analysis of 134 Cases. *Int J Trichology.* 2018;10(4):154-161. doi:10.4103/ijt.ijt_101_17
 7. Bains P, Kaur S. The Role of Dermoscopy in Severity Assessment of Alopecia Areata: A Tertiary Care Center Study. *J Clin Aesthet Dermatol.* 2020;13(4):45-50.
 8. Mane M, Nath AK, Thappa DM. Utility of dermoscopy in alopecia areata. *Indian J Dermatol.* 2011;56(4):407-411. doi:10.4103/0019-5154.84768
 9. Mahmoudi H, Salehi M, Moghadas S, Ghandi N, Teimourpour A, Daneshpazhooh M. Dermoscopic Findings in 126 Patients with Alopecia Areata: A Cross-Sectional Study. *Int J Trichology.* 2018;10(3):118-123. doi:10.4103/ijt.ijt_102_17
 10. Guttikonda AS, Aruna C, Ramamurthy DV, Sridevi K, Alagappan SK. Evaluation of Clinical Significance of Dermoscopy in Alopecia Areata. *Indian J Dermatol.* 2016;61(6):628-633. doi:10.4103/0019-5154.193668
 11. Olsen EA, Hordinsky MK, Price VH, Sperling L, Whiting DA, Norris D. Alopecia areata investigational assessment guidelines--Part II. National Alopecia Areata Foundation. *J Am Acad Dermatol.* 2004;51(3):440-447. doi:10.1016/j.jaad.2003.09.032
 12. Bapu NG, Chandrashekar L, Munisamy M, Thappa DM, Mohanan S.. Dermoscopic findings of alopecia areata in dark skinned individuals: an analysis of 116 cases. *Int J Trichol.* 2014;6:156–159. doi: 10.4103/0974-7753.142853
 13. Nikhil N., Mamatha P., Hanumanthayya K. A study of clinical and dermoscopic features in alopecia areata at a tertiary referral center. *Int J Res Dermatol.* 2020 Nov;6(6):744-749. doi: <https://dx.doi.org/10.18203/issn.2455-4529.IntJResDermatol20204457>
 14. Lima CS, Lemes LR, Melo DF. Yellow dots in trichoscopy: relevance, clinical significance and peculiarities. *An Bras Dermatol.* 2017; 92(5): 724–726. doi: 10.1590/abd1806-4841.20176157
 15. Hegde SP, Naveen KN, Athanikar SB, Reshme P. Clinical and dermoscopic patterns of alopecia areata: a tertiary care centre experience. *Int J Trichology.* 2013;5(3):132-136. doi:10.4103/0974-7753.125608
 16. Inui S, Nakajima T, Nakagawa K, Itami S. Clinical significance of dermoscopy in alopecia areata: Analysis of 300 cases. *Int J Dermatol.* 2008;47: 688–693. doi: 10.1111/j.1365-4632.2008.03692.x
 17. Peter D, George L, Pulimood SA. Trichoscopic features of various types of alopecia areata in India: application of a hand-held dermoscope. *Australas J Dermatol.* 2013;54(3):198-200. doi:10.1111/j.1440-0960.2012.00942.x
 18. Inui S, Nakajima T, Itami S. Coudability hairs: a revisited sign of alopecia areata assessed by trichoscopy [published correction appears in *Clin Exp Dermatol.* 2010 Jun;35(4):457]. *Clin Exp Dermatol.* 2010;35(4):361-365. doi:10.1111/j.1365-2230.2009.03510.x