

## SPONDYLOCOSTAL DYSOSTOSIS: REPORT OF THREE PATIENTS

Hirofumi OHASHI, Yoshitsugu SUGIO, and Tadashi KAJII

*Department of Pediatrics, Yamaguchi University School of Medicine,  
Ube, Yamaguchi 755, Japan*

*Summary* Spondylocostal dysostosis was present in three unrelated girls: a newborn with a severe form, a 16-year-old girl and a 17-month-old infant both with a mild form of the disease. They had clinical and radiographic manifestations typical of the syndrome, and in addition, several abnormalities not described previously. The latter included a right ovarian cyst and hypoplasia of the left leg in Patient 1, and aplasia of the left kidney in Patient 2. The three patients, each with different clinical manifestations, illustrate genetic heterogeneity of the syndrome.

### INTRODUCTION

Jarcho and Levin (1938) first described short trunk dwarfism involving skeletal anomalies of vertebrae and ribs in two siblings. At least 45 individuals with the syndrome have since been reported under various terms including spondylocostal dysplasia, spondylothoracic dysplasia, costovertebral dysplasia and Jarcho-Levin syndrome. Aymé and Preus (1986) classified 41 informative patients in the literature and one of their own into three forms: 1) severe form, 2) mild form with either autosomal recessive or dominant inheritance, and 3) the costovertebral segmentation defect with mesomelia (COVESDEM) syndrome. We will here describe three sporadic children, one with the severe form and two with the mild form, who had clinical features typical of the syndrome and several additional abnormalities not described previously.

### CASE REPORTS

**Patient 1.** K.T. (84-263), a girl, was born after an uneventful pregnancy of 36 weeks to a 30-year-old, gravida II, para I mother and a 28-year-old father, both healthy and unrelated. There was no history of viral infection or medication during the pregnancy. There was no family history of malformations.

---

*Received August 3, 1987; Accepted September 1, 1987*

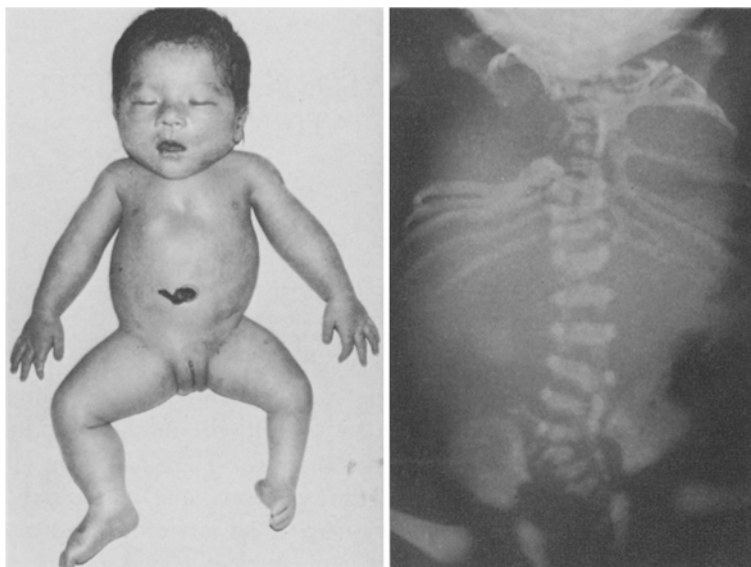


Fig. 1. Patient 1. Short neck and trunk, a short nose, protuberant abdomen, wide-spaced nipples, pectus excavatum, and hypoplasia of the left leg with talipes equinovarus (left). Multiple vertebral and costal anomalies including hemivertebrae, aplasia of several ribs, and posteriorly fused ribs forming a crab-like thorax (right).

At birth, the patient weighed 2,260 g ( $-0.35$  SD) and measured 41 cm ( $-1.12$  SD). An unusual appearance was noted at birth, characterized by short neck with the head fixed to the shoulders, an extremely short thorax and a protuberant abdomen (Fig. 1). Other features noted were low hairline, redundant skin on the neck, wide-spaced nipples, hypotrophy of the left lower extremity with talipes equinovarus. The facial appearance was normal. A cystic mass was palpable in the right part of the abdomen. Echographic examination revealed a large cyst, most likely an ovarian cyst measuring  $66 \times 59 \times 28$  mm, and locating under the right kidney.

A roentgenographic survey showed severe anomalies of the vertebrae including hemivertebrae with marked reduction of the length of the spinal column, especially in its thoracic portion. Seven ribs were present on the right and ten on the left, which showed irregular thickness, and many of which were fused posteriorly.

Severe asphyxia was noted soon after birth, and she died in spite of supportive therapy of respiratory failure at three days of life. No autopsy was granted. G-banded chromosomes in cultured peripheral blood (PB) lymphocytes were normal.

**Patient 2.** K.E. (82-356), a 16-year-old girl, was the product of a normal, 39-week pregnancy. She was born to a 35-year-old, gravida III, para II mother and a 36-year-old father, both healthy and unrelated. Her two elder sisters, 21 and 20 years old, respectively, were normal. There was no family history of malformations.

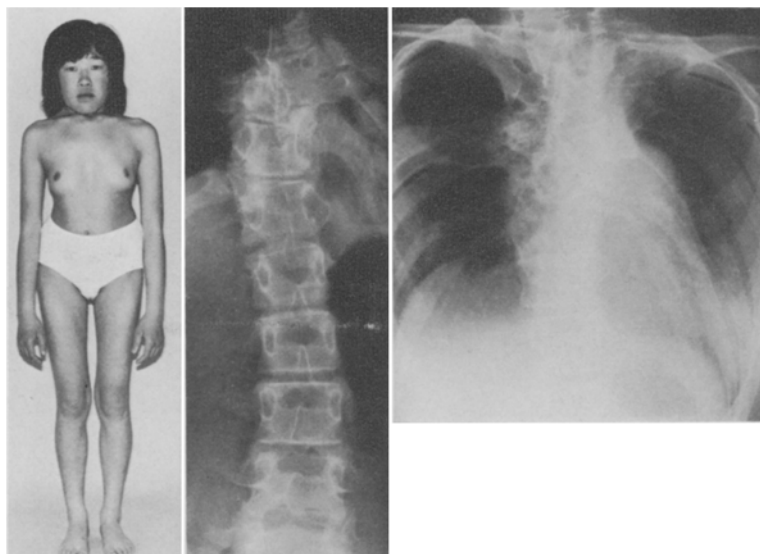


Fig. 2. Patient 2 at age 12 years. Short neck and trunk, relatively long extremities, and wide-spaced nipples (left). Lumbar scoliosis (middle). Malformed thoracic cage with hemivertebrae, fused vertebrae, and posteriorly fused ribs (right).

She had repeated respiratory infections from early infancy, and experienced dyspnea on moderate exercise. At age 12 years, she was admitted to us because of easy fatigability with dyspnea. Her height was 135.1 cm ( $-2.5$  SD) and weight 36.0 kg ( $-0.88$  SD). Her thorax was extremely short, while her extremities were relatively long (Fig. 2).

Roentgenographic survey revealed multiple abnormalities of the vertebral bodies, especially in the thoracic portion, including hemivertebrae and fused vertebrae. The ribs showed irregular thickness and multiple fusions at the posterior ends and appeared to cascade downward from the markedly shortened spine. Mild lumbar scoliosis was noted.

Echocardiography revealed severe pulmonary hypertension with a markedly dilated right ventricle, left ventricular dysfunction and pericardial effusion. No intracardiac anomaly was detected. Thus, heart failure due to severe pulmonary hypertension was present, and the latter probably resulted from severe chest deformity. Digitalization was started and the symptoms of heart failure gradually improved.

Roentgenographic examination revealed a right ectopic kidney located under the right diaphragm, and agenesis of the left kidney. These findings were confirmed by intravenous pylonephrography and computed tomographic examination.

The serum calcium, phosphate and alkaline phosphatase levels were normal. G-banded chromosomes in cultured PB lymphocytes were normal.

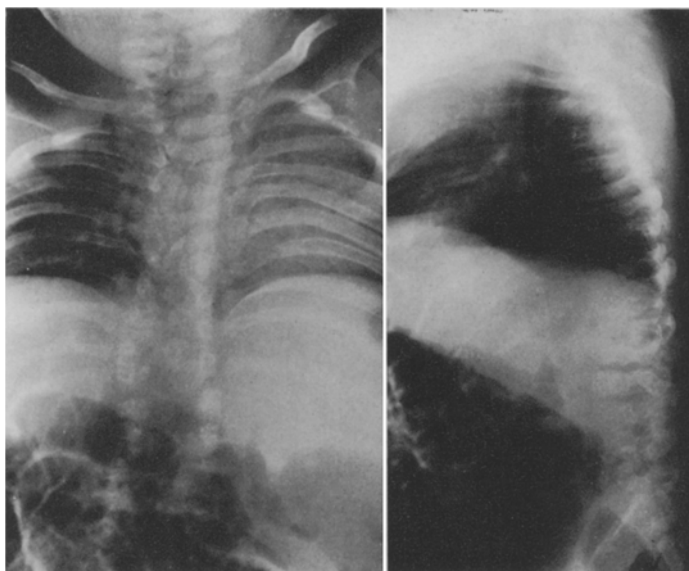


Fig. 3. Patient 3. Deformed vertebral bodies, increased interpediculate distances (left), and dorsolumbar lordosis (right).

**Patient 3.** R.O. (0333-54-3), a girl, was born after an uneventful pregnancy of 39 weeks to a 27-year-old, gravida II, para I mother and a 33-year-old father, both healthy and unrelated. Her 2-year-old brother was free of deformities. There was no family history of malformations.

At age three months, she was referred to us because of short stature. On physical examination, her length was 52.7 cm ( $-3.5$  SD) and weight 3,700 g ( $-3.1$  SD). The neck and trunk were extremely short. She had slanted ears and a funnel chest. A skeletal survey revealed extensive and severe anomalies of the vertebral column including a marked shortening of the vertebral column, marked increase of the interpediculate distances throughout the lower thoracic and lumbar vertebrae, and deformities of the vertebral bodies (Fig. 3). Ten ribs were present on both sides without remarkable malformations.

She suffered from atelectasis of the left lower lobe at age 12 months. Now aged 17 months, she walks unsupported and speaks meaningful words.

#### DISCUSSION

We described three unrelated children with spondylocostal dysostosis, all sporadic cases born to non-consanguineous parents. All three were of short stature with a short neck, a short trunk, and showed multiple vertebral anomalies including hemivertebrae and fused vertebrae, accompanied by deformities of the ribs. They

differed from one another in two aspects. First, they varied in the severity of the condition. Patient 1 had a severe chest deformity and died of respiratory failure at age three days. Patient 2, a 16-year-old girl, had moderate manifestations, including recurrent respiratory infections and heart failure from early infancy. Patient 3, a 17-month-old girl, had a mild form without remarkable complications. Secondly, they differed in additional abnormalities they exhibited. Those included hypoplasia of the left leg with talipes equinovarus and right ovarian cyst in Patient 1, and right ectopic kidney and aplasia of the left kidney in Patient 2.

As mentioned earlier, Aymé and Preus (1986) recently classified 41 informative patients with the syndrome in the literature and one of their own into three phenotypic groups using a cluster analysis method. Cluster 1 included 19 patients with a severe, lethal form with autosomal recessive inheritance; cluster 2 consisted of 20 patients with a mild form, with either autosomal dominant or recessive inheritance; and cluster 3 included three patients with costovertebral segmentation defect with mesomelia (COVESDEM) syndrome. The patients with the severe form of the disease have severe respiratory problems and a severely abnormal chest, and die in infancy of respiratory distress with or without pneumonia. Those with the mild form of the disease survive infancy. Some of them have respiratory infections and severely deformed chests. The patients with the COVESDEM syndrome have short forearms and a triangular opening of the mouth.

Patient 1 we described belongs to the severe form of the disease in view of the fact that she had severe thoracic abnormalities and died of respiratory difficulties in the neonatal period. Patients 2 and 3 are apparently classified into the mild form. While patients with both the severe and mild forms often have a variety of accompanying anomalies, hypoplasia of a leg as observed in Patient 1 and agenesis of a kidney as in Patient 2 have not been described in association with spondylocostal dysostosis. All three patients we described were sporadic instances born to unrelated parents. Thus, it remains to be seen whether the disease in these patients was autosomal recessive, or autosomal dominant with fresh mutation.

*Acknowledgment* We are indebted to Dr. Y. Abe for referring Patient 3.

#### REFERENCES

- Aymé, S. and Preus, M. 1986. Spondylocostal/spondylothoracic dysostosis: The clinical basis for prognosticating and genetic counseling. *Am. J. Med. Genet.* **24**: 599-606.
- Jarcho, S. and Levin, P.M. 1938. Hereditary malformation of the vertebral bodies. *Bull. Johns Hopkins Hosp.* **62**: 216-226.