

## SUDECK'S ATROPHY IN TRAUMATIC QUADRIPLEGIA

By LESLIE G. ANDREWS, M.B., B.S., D.C.H., D.PHYS.MED., C.R.C.P.(C) AND KATHLEEN J. ARMITAGE, B.A., M.D.

*from the G. F. Strong Rehabilitation Centre, Vancouver, British Columbia, Canada*

### INTRODUCTION

MANY spinal injury patients complaining of bizarre painful hands without obvious cause are considered to suffer from paresthesia. A patient with traumatic quadriplegia complaining of painful swollen hands was found to have radiological changes consistent with the appearance of Sudeck's atrophy. In order to determine if similar clinical and radiological findings might co-exist in other patients, a survey was carried out on all traumatic quadriplegic patients admitted to a rehabilitation centre over a one-year period.

A clear definition of Sudeck's atrophy is not easily obtained. Confusion exists as to whether this is a clinical diagnosis supported by radiological findings, or a specific stage in the radiological changes following trauma and part of the process of osteoporosis. Schinz *et al.*, in *Roentgen-Diagnostics*, translated by Case (1951), consider Sudeck-Kienbock's atrophy to be the radiological spotty macular stage of porosis, which may go on to the stage of chronic bone atrophy. For the purposes of this study macular porosis was accepted as the radiological basis for the diagnosis of Sudeck's atrophy.

A search of the literature failed to reveal any previous reference to Sudeck's atrophy as a specific entity in traumatic quadriplegia.

### METHOD

Seventeen male and two female patients with traumatic quadriplegia admitted to the G. F. Strong Rehabilitation Centre over a one-year period, July 1968 to July 1969, were included in the study. Their ages ranged from 20 to 61 years. The neurological injury level was at C1 in 1 patient, C5 in 3, C6 in 6 and C7 in 9. Records were kept of any complaint of bizarre pain in the hands or feet. All patients had X-rays of their hands and feet, serum uric acid estimations and latex fixation tests.

The X-rays of the hands and feet were assessed independently by three radiologists, who came to a majority conclusion as to which of the X-rays showed the appearances of osteoporosis. One of the radiologists then selected those osteoporotic X-rays which showed spotty macular porosis. The radiologists were all unaware of the clinical status of the patients. The X-ray findings were then correlated with the presence or absence of bizarre painful hands or feet.

### RESULTS

Table I correlates the X-ray changes with the presence of symptoms. Eight of 19 patients had normal X-rays of the hands and feet and were asymptomatic. Of the remaining 11, 5 had simple osteoporosis in the hands alone, 3 in the feet alone, and 1 in the hands and feet. Of the total of 6 hands with simple osteoporosis, only 1 had pain and of the 4 feet with simple osteoporosis none had pain.

In addition, spotty macular porosis was present in 3 patients in the hands alone, 5 patients in the feet alone, and 2 patients in the hands and feet. Of the total of 5 hands with spotty macular porosis, 4 were symptomatic, and of the 7 macular porotic feet, 3 were symptomatic. These 3 symptomatic patients had complete cord lesions. In the 4 patients with spotty macular porosis of the feet who were asymptomatic, 3 had a complete and 1 an incomplete cord lesion. Figures 1 and 2 compare normal X-rays with those typical of simple osteoporosis and spotty macular porosis.

TABLE I  
Correlation of Symptoms and Radiological Findings in 19 Traumatic Quadriplegic Cases

X-rays	Symptoms	
	Hands	Feet
Normal	8	8
Simple osteoporosis	6	4
Spotty macular porosis	5	7

Symptoms and abnormal X-ray findings were bilateral in all but one case. He complained of pain in the left hand only and his spotty macular porosis was confined to the left carpus.

Of the 2 patients with spotty macular porosis in the hands and feet, one had symptoms in the hands and feet, the other only in the feet. In both of these patients the neurological level of injury was C7. Six of the 8 patients with spotty macular porosis in the hands *or* feet had a neurological injury level of C7; 2 had a level of C6. In the 6 with coincident spotty macular porosis and pain, the neurological level of injury was C7.

The average time interval between injury and the X-rays was 15 months in both the hands and feet. In cases showing radiological spotty macular porosis, the average time was 12 months in the feet and 9 months in the hands.

The pain described by our patients was commonly a subjective bizarre burning. In two patients there was also pain on palpation. One patient described his pain as due to 'freezing hands'. Another likened the pain to the sensation he imagined he would feel if a truck had driven over his hands. Reflex dystrophic changes were common findings. The hands were often edematous with glossy mottled skin and excessive perspiration (fig. 3). In one case a decrease in hair growth was noted on the affected hands. Raynaud's phenomenon was not observed.

The two female patients had a serum uric acid below 5 per cent. In the male patients, the uric acid level rose with age. Slightly higher levels are not unexpected in view of the known impaired renal function in patients with paraplegia and quadriplegia (Doggart *et al.*, 1966). One of the patients, aged 42 years, had radiological destructive arthritic changes in his feet consistent with gout, but no symptoms referable to his feet. He had the highest uric acid of all with a level greater than 8 mg per cent. on the two occasions he was tested. His hands showed typical

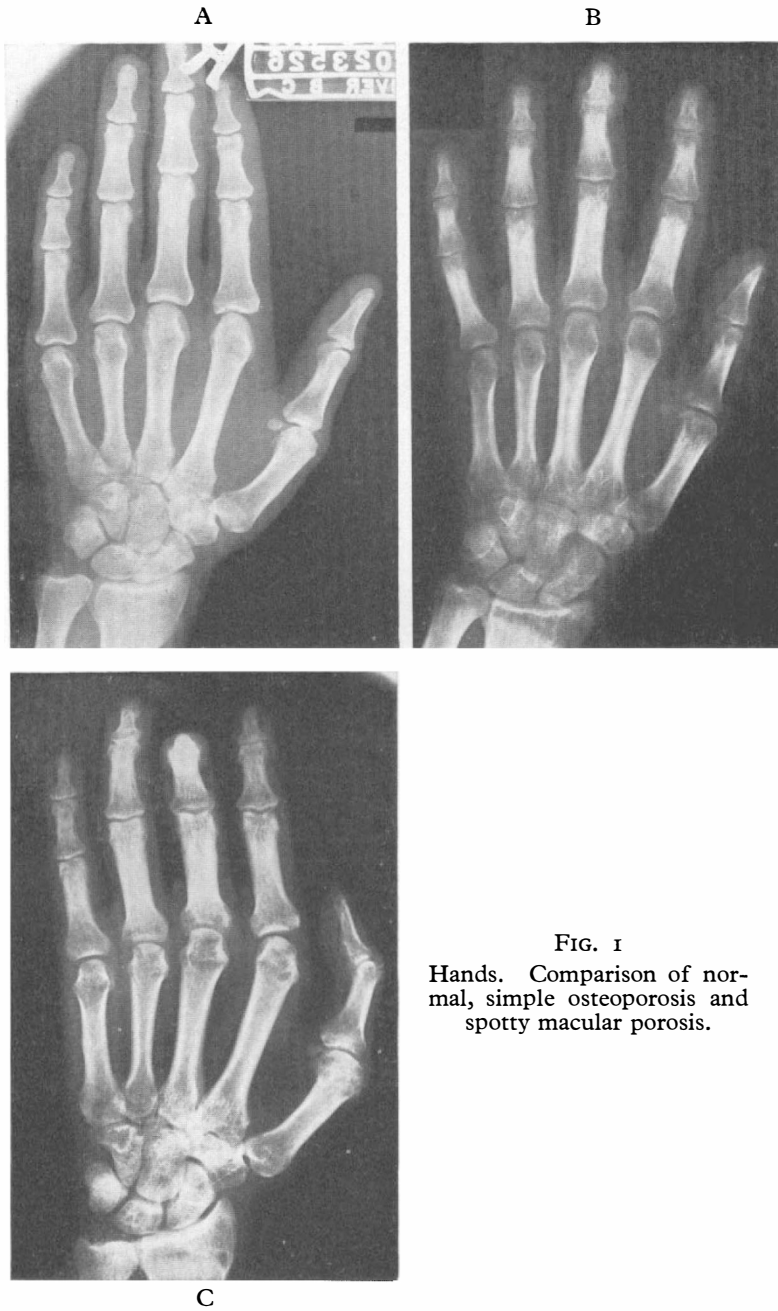


FIG. 1  
Hands. Comparison of normal, simple osteoporosis and spotty macular porosis.

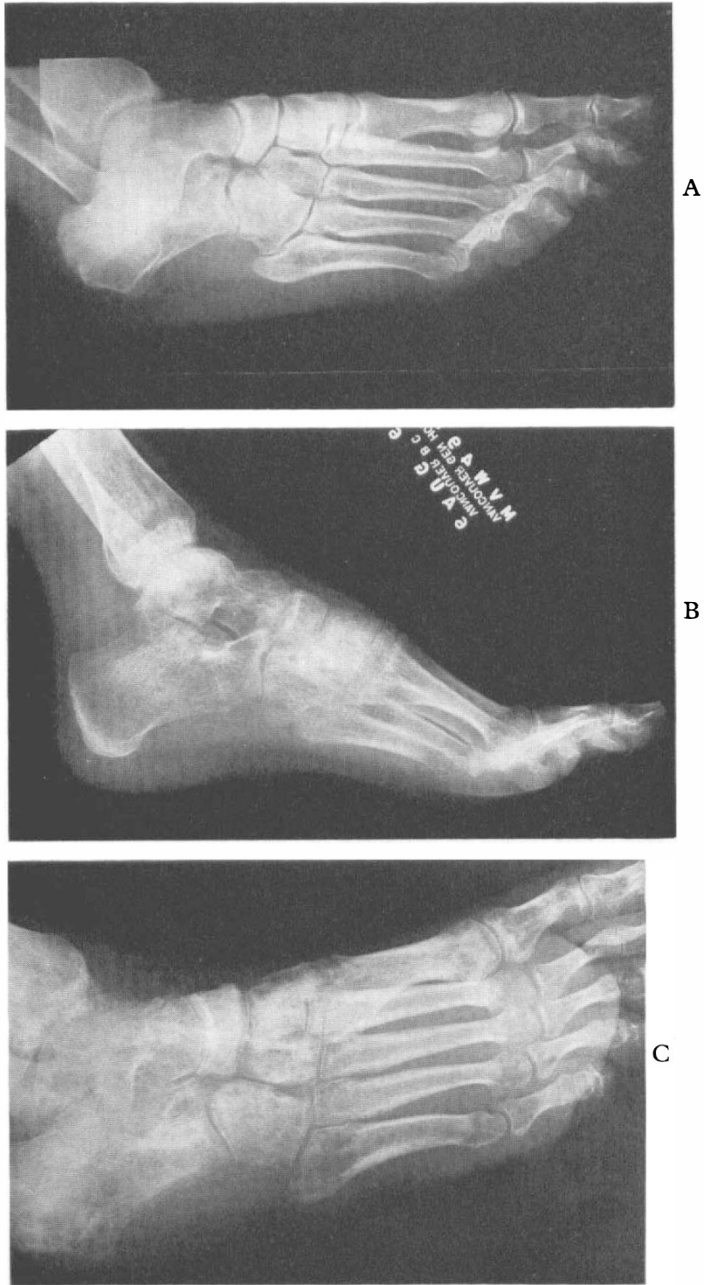


FIG. 2

Feet. Comparison of normal, simple osteoporosis and spotty macular porosis.

spotty macular porosis and he had burning sensation in the hands only. No patients were on salicylates or similar preparation at the time the uric acid levels were determined.

The latex fixation test was negative in all patients.

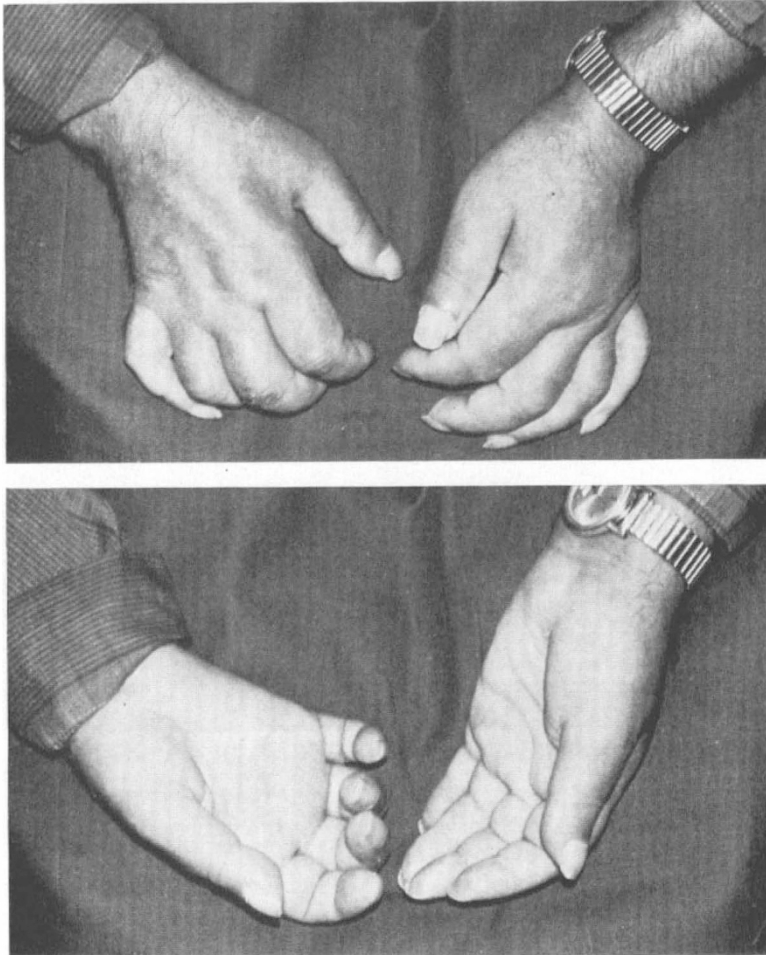


FIG. 3

Hands in the presence of spotty macular porosis.

### DISCUSSION

One patient had two levels of spinal fracture (C7 and D5) as well as a right Colles and left scaphoid fracture. He had neither symptoms nor spotty macular porotic X-rays. Another case complained of a painful right shoulder. The X-rays of this joint were negative and X-rays of the showed osteoporosis. The case in which there was spotty macular porosis and symptoms involving one hand only is of particular interest.

Six of 7 patients with spotty macular porosis in the feet had complete cord lesions, *i.e.* total motor and sensory loss below the level of the lesion. No explanation can be offered for the presence of symptoms in 3 cases and the lack of symptoms in the other 4 cases. During the study, a patient with complete traumatic paraplegia at L1 not included in the survey, volunteered bizarre burning sensation in his feet. His X-rays showed spotty macular porosis.

Treatment of the pain included electric pads, battery heated socks, wax baths, hand activities in a cage heated to  $115^{\circ}$  with hot air (fig. 4) and analgesics. Wax




FIG. 4  
Heat cage.

or the heat cage was the only effective therapy, with a carry-over of up to 3 hours. In one patient the pain was less intense whilst he was on holiday in Hawaii in the height of the summer. His relief was both in the hands and feet. The improvement could have been due to the removal of stress whilst on vacation.

Several of the patients exhibited emotional changes. These were accentuated when they became aware that their hands and/or feet showed radiological changes which might account for their symptoms. Psychological changes are well recognised in Sudeck's Atrophy, and in reflex sympathetic dystrophy psychiatric and emotional changes may precede the onset (Pak *et al.*, 1970). In causalgia, thought by some to be a similar condition, addiction to opiates and even suicides have been reported (Lidz & Payne, 1945; Mayfield, 1951). Perhaps the pain or psychological changes enhance the degree of spotty macular porosis.

Due to the nature of the study there was no specific interval between the time of injury and the date of the X-rays. Serial X-rays taken at regular intervals after spinal trauma might possibly show a greater correlation between hands and feet and spotty macular porosis.

Painful hands and feet are often ascribed to paraesthesia in patients with traumatic spinal cord injury. The observations outlined in this paper suggest these symptoms may be related to the spotty macular stage of osteoporosis.

#### SUMMARY

In a study of 19 patients with traumatic quadriplegia admitted to the G. F. Strong Rehabilitation Centre over a one-year period, there was a high incidence of bizarre painful hands and feet coincident with a particular radiological stage of osteoporosis—spotty macular porosis (Sudeck's atrophy).

Four of 5 patients with spotty macular porosis in the hands and 3 of 7 patients with spotty macular porosis in the feet complained of bizarre pain. In the only instance of unilateral spotty macular porosis, the pain was confined to the affected hand. Where the X-rays of the hands or feet showed simple osteoporosis, 1 patient had painful hands. All patients with normal X-rays of the hands and feet were asymptomatic. The neurological level of injury was at C7 in all 6 patients with coincident pain and spotty macular porosis.

A further prospective study with X-rays taken at regular intervals after spinal trauma might confirm the coincidence of symptomatic painful hands and feet and radiological spotty macular porosis.

*Acknowledgment.* We wish to thank Drs. H. M. Spiro, S. Miller and J. R. McIver for reviewing the X-rays and Drs. L. J. Brunton, W. R. Govan and A. C. Pinkerton for allowing us to study their patients. Dr. A. C. Pinkerton's suggestions in preparing this paper are greatly appreciated.

#### REFERENCES

- DOGGART, J. R., GUTTMANN, SIR L. & SILVER, J. R. (1966). *Int. J. Paraplegia*, **3**, 229-242.  
LIDZ, T. & PAYNE, R. L. (1945). *Arch. Neurol. Psychiat.* **53**, 222-225.  
MAYFIELD, F. H. (1951). *Causalgia*. American Lecture Series Publication. Charles C. Thomas, Springfield, Illinois. Number **58**. pp. 14-20.  
PAK, T. J., MARTIN, G. M., MAGNESS, J. L. & KAVANAUGH, G. J. (1970). *Minnesota Medicine*, **53**, 507-512.  
SCHINZ, H. R., BAENSCH, W. E., FRIEDL, E. & UEHLINGER, E. (1951). *Roentgen-Diagnostics*. (First American Edition based on the Fifth German Edition Translated by Case, J. T.) Grune & Stratton, New York. Vol. **1**, Part **1**, 228-232.