

***Appendix 3.1***  
***Birth Defects Descriptions***  
***for NBDPN Core, Recommended, and Extended Conditions***  
*Updated March 2017*

*Participating members of the Birth Defects Definitions Group:*

*Lorenzo Botto (UT)*  
*John Carey (UT)*  
*Cynthia Cassell (CDC)*  
*Tiffany Colarusso (CDC)*  
*Janet Cragan (CDC)*  
*Marcia Feldkamp (UT)*  
*Jamie Frias (CDC)*  
*Angela Lin (MA)*  
*Cara Mai (CDC)*  
*Richard Olney (CDC)*  
*Carol Stanton (CO)*  
*Csaba Siffel (GA)*

# Table of Contents

<b>LIST OF BIRTH DEFECTS .....</b>	<b>1</b>
<b>DETAILED DESCRIPTIONS OF BIRTH DEFECTS .....</b>	<b>1</b>
FORMAT FOR BIRTH DEFECT DESCRIPTIONS .....	1
<b>CENTRAL NERVOUS SYSTEM .....</b>	<b>2</b>
ANENCEPHALY .....	2
ENCEPHALOCELE .....	3
HOLOPROSENCEPHALY.....	4
SPINA BIFIDA WITHOUT ANENCEPHALY .....	5
<b>EYE.....</b>	<b>7</b>
ANOPHTHALMIA/MICROPHthalmIA .....	7
CONGENITAL CATARACT.....	8
<b>EAR .....</b>	<b>9</b>
ANOTIA/MICROTIA.....	9
<b>CARDIOVASCULAR .....</b>	<b>11</b>
AORTIC VALVE STENOSIS .....	11
ATRIAL SEPTAL DEFECT (ASD).....	12
ATRIOVENTRICULAR SEPTAL DEFECT.....	13
(ATRIOVENTRICULAR CANAL DEFECT; ENDOCARDIAL CUSHION DEFECT) .....	13
COARCTATION OF THE AORTA.....	15
COMMON TRUNCUS (TRUNCUS ARTERIOSUS OR TA).....	16
DOUBLE OUTLET RIGHT VENTRICLE (DORV).....	17
EBSTEIN ANOMALY .....	18
HYPOPLASTIC LEFT HEART SYNDROME (HLHS).....	19
INTERRUPTED AORTIC ARCH (IAA).....	20
PULMONARY VALVE ATRESIA AND STENOSIS.....	21
SINGLE VENTRICLE .....	23
TETRALOGY OF FALLOT (TOF) .....	24
TOTAL ANOMALOUS PULMONARY VENOUS CONNECTION (TAPVC).....	26
TRANSPOSITION OF THE GREAT ARTERIES (TGA).....	27
TRICUSPID VALVE ATRESIA AND STENOSIS .....	29
VENTRICULAR SEPTAL DEFECT (VSD).....	30
<b>OROFACIAL .....</b>	<b>31</b>
CHOANAL ATRESIA.....	31
CLEFT LIP ALONE (WITHOUT CLEFT PALATE).....	32
CLEFT LIP WITH CLEFT PALATE .....	33
CLEFT PALATE ALONE (WITHOUT CLEFT LIP).....	34
<b>GASTROINTESTINAL .....</b>	<b>34</b>
BILIARY ATRESIA .....	35
ESOPHAGEAL ATRESIA/TRACHEOESOPHAGEAL FISTULA .....	36
RECTAL AND LARGE INTESTINAL ATRESIA/STENOSIS .....	37
SMALL INTESTINAL ATRESIA/STENOSIS .....	38
<b>GENITOURINARY.....</b>	<b>39</b>
BLADDER EXSTROPHY .....	39

CLOACAL EXSTROPHY .....	41
CONGENITAL POSTERIOR URETHRAL VALVES .....	42
HYPOSPADIAS .....	43
RENAL AGENESIS/HYPOPLASIA .....	45
<b>MUSCULOSKELETAL .....</b>	<b>47</b>
CLUBFOOT .....	47
CRANIOSYNOSTOSIS .....	48
DIAPHRAGMATIC HERNIA .....	49
GASTROSCHISIS .....	50
LIMB DEFICIENCIES (REDUCTION DEFECTS) .....	52
OMPHALOCELE .....	55
<b>CHROMOSOMAL .....</b>	<b>57</b>
DELETION 22Q11.2 .....	57
TRISOMY 13 .....	59
TRISOMY 18 .....	61
TRISOMY 21 (DOWN SYNDROME) .....	63
TURNER SYNDROME .....	65

**Note: As of January 2014, the following conditions were dropped from the NBDPN list:**

- Amniotic bands
- Aniridia
- Congenital hip dislocation
- Epispadias
- Fetus or newborn affected by maternal alcohol use
- Hirschsprung disease (congenital megacolon)
- Hydrocephalus without spina bifida
- Microcephalus
- Patent ductus arteriosus
- Pyloric stenosis

The following conditions were **added**:

- Clubfoot
- Cloacal exstrophy
- Congenital posterior urethral valves
- Craniosynostosis
- Deletion 22q11.2
- Double outlet right ventricle (DORV)
- Holoprosencephaly
- Interrupted aortic arch (IAA)
- Single ventricle
- Small intestine atresia/stenosis
- Turner syndrome

The following conditions were **merged**:

- Reduction deformity, lower limbs; reduction deformity, upper limbs. Merged to limb deficiencies (reduction defects).

The following conditions were **separated**:

- Cleft lip with and without cleft palate separated to cleft lip with cleft palate; cleft lip alone (without cleft palate).

## List of Birth Defects

Birth Defects	ICD-9-CM Codes	CDC/BPA Codes	ICD-10-CM Codes	Standard Level*		
				Core	Recommended	Extended
<b>CNS</b>						
<a href="#">Anencephalus</a>	740.0 – 740.1	740.00 – 740.10	Q00.0 - Q00.1	Core		
<a href="#">Spina bifida without anencephalus</a>	741.0, 741.9 w/o 740.0 - 740.10	741.00 – 741.99 w/o 740.0 – 740.10	Q05.0 - Q05.9, Q07.01, Q07.03 w/o Q00.0 - Q00.1	Core		
<a href="#">Encephalocele</a>	742.0	742.00 – 742.09	Q01.0 – Q01.9		Recommended	
<a href="#">Holoencephaly</a>	742.2	742.26	Q04.2			Extended
<b>Eye</b>						
<a href="#">Anophthalmia / microphthalmia</a>	743.0, 743.1	743.00 – 743.10	Q11.0 – Q11.2		Recommended	
<a href="#">Congenital cataract</a>	743.30 – 743.34	743.32	Q12.0			Extended
<b>Ear</b>						
<a href="#">Anotia/microtia</a>	744.01, 744.23	744.01, 744.21	Q16.0, Q17.2		Recommended	
<b>Cardiovascular</b>						
<a href="#">Aortic valve stenosis</a>	746.3	746.3	Q23.0		Recommended	
<a href="#">Atrial septal defect</a>	745.5	745.51 – 745.59	Q21.1		Recommended	
<a href="#">Atrioventricular septal defect (Endocardial cushion defect)</a>	745.60, .61, .69	745.60 – 745.69	Q21.2	Core		
<a href="#">Coarctation of the aorta<sup>2</sup></a>	747.10	747.10 – 747.19	Q25.1		Recommended	

Birth Defects	ICD-9-CM Codes	CDC/BPA Codes	ICD-10-CM Codes	Standard Level*		
<a href="#">Common truncus (truncus arteriosus or TA)</a> <sup>1</sup>	745.0	745.00 only (excluding 745.01)	Q20.0	Core		
<a href="#">Double outlet right ventricle (DORV)</a> <sup>2</sup>	745.11	745.13 – 745.15	Q20.1		Recommended	
<a href="#">Ebstein anomaly</a> <sup>2</sup>	746.2	746.20	Q22.5		Recommended	
<a href="#">Hypoplastic left heart syndrome</a> <sup>1</sup>	746.7	746.7	Q23.4	Core		
<a href="#">Interrupted aortic arch (IAA)</a> <sup>2</sup>	747.11	747.215 - 747.217, 747.285	Q25.2, Q25.4		Recommended	
<a href="#">Pulmonary valve atresia and stenosis</a> <sup>1</sup>	746.01 (pulmonary valve atresia), 746.02 (pulmonary valve stenosis) Note: for CCHD, 746.01 only (pulmonary atresia, intact ventricular septum)	746.00 (pulmonary valve atresia), 746.01 (pulmonary valve stenosis) Note: for CCHD, 746.00 only (pulmonary atresia, intact ventricular septum)	Q22.0, Q22.1 (Note: for CCHD, Q22.0 only (pulmonary atresia, intact ventricular septum))		Recommended	
<a href="#">Single Ventricle</a> <sup>2</sup>	745.3	745.3	Q20.4		Recommended	
<a href="#">Tetralogy of Fallot (TOF)</a> <sup>1</sup>	745.2	745.20 – 745.21, 747.31 Note: code 746.84 has been removed)	Q21.3	Core		

Birth Defects	ICD-9-CM Codes	CDC/BPA Codes	ICD-10-CM Codes	Standard Level*		
<a href="#">Total anomalous pulmonary venous connection (TAPVC)</a> <sup>1</sup>	747.41	747.42	Q26.2	Core		
<a href="#">Transposition of the great arteries (TGA)</a> <sup>1</sup>	745.10, 745.12, 745.19 (Note: for CCHD, 745.10 only (d-TGA only))	745.10 – 745.12, 745.18 – 745.19 (Note: for CCHD, 745.10 (TGA complete, no VSD), 745.11 (TGA incomplete, with VSD), 749.18 (other specified TGA), 745.19 (unspecified TGA))	Q20.3, Q20.5 (Note: for CCHD, Q20.3 only)	Core		
<a href="#">Tricuspid valve atresia and stenosis</a> <sup>3</sup>	746.1 <sup>2</sup>	746.100 <sup>1</sup> (tricuspid atresia), 746.106 (tricuspid stenosis) (excl. 746.105 – tricuspid insufficiency) Note: for CCHD, 746.100 only. Only tricuspid atresia is a CCHD. Many cases of tricuspid stenosis are not critical.	Q22.4 <sup>2</sup>		Recommended	
<a href="#">Ventricular septal defect</a>	745.4	745.40 – 745.49 (excl. 745.487, 745.498)	Q21.0		Recommended	
<b>Orofacial</b>						

Birth Defects	ICD-9-CM Codes	CDC/BPA Codes	ICD-10-CM Codes	Standard Level*		
<a href="#">Choanal atresia</a>	748.0	748.0	Q30.0		Recommended	
<a href="#">Cleft lip with cleft palate</a>	749.2	749.20 – 749.29	Q37.0 – Q37.9	Core		
<a href="#">Cleft lip alone (without cleft palate)</a>	749.1	749.10-749.19	Q36.0 – Q36.9	Core		
<a href="#">Cleft palate alone (without cleft lip)</a>	749.0	749.00 – 749.09	Q35.1 – Q35.9	Core		
<b>Gastrointestinal</b>						
<a href="#">Biliary atresia</a>	751.61	751.65	Q44.2 - Q44.3			Extended
<a href="#">Esophageal atresia/tracheoesophageal fistula</a>	750.3	750.30 – 750.35	Q39.0 – Q39.4		Recommended	
<a href="#">Rectal and large intestinal atresia/stenosis</a>	751.2	751.20 – 751.24	Q42.0 – Q42.9		Recommended	
<a href="#">Small intestinal atresia/stenosis</a>	751.1	751.10-751.19	Q41.0 – Q41.9		Recommended	
<b>Genitourinary</b>						
<a href="#">Bladder exstrophy</a>	753.5	753.5	Q64.10, Q64.19		Recommended	
<a href="#">Cloacal exstrophy</a>	751.5	751.555	Q64.12		Recommended	
<a href="#">Congenital Posterior Urethral Valves</a>	753.6	753.60	Q64.2		Recommended	
<a href="#">Hypospadias</a>	752.61	752.60 – 752.62 (excluding 752.61 and 752.621)	Q54.0 – Q54.9 (excluding Q54.4)		Recommended	
<a href="#">Renal agenesis/hypoplasia</a>	753.0	753.00 – 753.01	Q60.0 – Q60.6		Recommended	
<b>Musculoskeletal</b>						
<a href="#">Clubfoot</a>	754.51, 754.70	754.50, 754.73	Q66.0, Q66.89		Recommended	
<a href="#">Craniosynostosis</a>	No specific code	756.00-756.03	Q75.0			Extended



Birth Defects	ICD-9-CM Codes	CDC/BPA Codes	ICD-10-CM Codes	Standard Level*		
<a href="#">Diaphragmatic hernia</a>	756.6	756.61	Q79.0, Q79.1		Recommended	
<a href="#">Gastroschisis</a>	756.73 (as of 10/1/09; previously a shared code 756.79 with omphalocele)	756.71	Q79.3	Core		
<a href="#">Limb deficiencies (reduction defects)</a>	755.2 – 755.4	755.20 – 755.49	Q71.0 – Q71.9, Q72.0 – Q72.9, Q73.0 – Q73.8	Core		
<a href="#">Omphalocele</a>	756.72 (as of 10/1/09; previously a shared code 756.79 with gastroschisis)	756.70	Q79.2		Recommended	
<b>Chromosomal</b>						
<a href="#">Deletion 22 q11</a>	758.32	758.37	Q93.81			Extended
<a href="#">Trisomy 13</a>	758.1	758.10 – 758.19	Q91.4 – Q91.7		Recommended	
<a href="#">Trisomy 18</a>	758.2	758.20 – 758.29	Q91.0 – Q91.3		Recommended	
<a href="#">Trisomy 21 (Down syndrome)</a>	758.0	758.00 – 758.09	Q90.0 – Q90.9	Core		
<a href="#">Turner syndrome</a>	758.6	758.60-758.69	Q96.0 – Q96.9			Extended

<sup>1</sup>Critical Congenital Heart Defect (CCHD) primary target

<sup>2</sup>Critical Congenital Heart Defect (CCHD) secondary target

<sup>3</sup>Tricuspid valve atresia is a Critical Congenital Heart Defect (CCHD) target; however, many cases of tricuspid valve stenosis are not critical. The ICD-9-CM and ICD-10-CM codes do not distinguish between these conditions. In order not to artificially inflate the counts for CCHD primary targets, the ICD-9-CM and ICD-10-CM codes are designated as CCHD secondary targets.

---

## Detailed Descriptions of Birth Defects

---

### Format for Birth Defect Descriptions

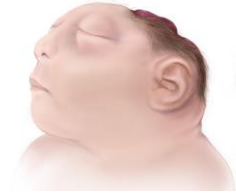	<b>Defect Name</b>
<b>Description</b>	Description of the defect.  Standard level (SL): Each condition is listed as core (SL 1), recommended (SL 2) or extended (SL 3). In order to meet the standard level specified, a program needs to ascertain that condition.
<b>Inclusions</b>	Other names or conditions that should be included in the code for the defect.
<b>Exclusions</b>	Other names or conditions that should not be included in the code for the defect.
<b>ICD-9-CM Codes</b>	Applicable ICD-9-CM codes for the defect.
<b>ICD-10-CM Codes</b>	Applicable ICD-10-CM codes for the defect.
<b>CDC/BPA Codes</b>	Applicable CDC/BPA codes for the defect.
<b>Diagnostic Methods</b>	Postnatal procedures by which the defect may be accurately and reliably diagnosed.
<b>Prenatal Diagnoses Not Confirmed Postnatally</b>	Guidance on whether cases with only a prenatal diagnosis should be included in the defect code.
<b>Additional Information</b>	Tips and useful information about the defect.

## Central Nervous System

### Anencephaly

(Core Condition)

**Description** Partial or complete absence of the brain and skull.



**Inclusions** Acrania – Absence of skull bones with some brain tissue present.  
Absent brain, with or without skull bones present.  
Anencephaly  
Anencephaly  
Craniorachischisis – Anencephaly continuous with an open posterior spinal defect with no meninges covering the neural tissue.  
Exencephaly

**Exclusions** Encephalocele  
Iniencephaly  
Rachischisis – When used alone, this term refers only to the spinal defect and should be coded as spina bifida without anencephaly.

**ICD-9-CM Codes** 740.0 – 740.1

**ICD-10-CM Codes** Q00.0 - Q00.1

**CDC/BPA Codes** 740.00 – 740.10

**Diagnostic Methods** Anencephaly is easily recognized on physical examination at delivery.

**Prenatal Diagnoses Not Confirmed Postnatally** Anencephaly may be included when only diagnosed prenatally. However, if it is possible to ascertain the degree of certainty of the prenatal diagnosis, this should factor into the decision as to whether or not to include an individual case in the surveillance data.

#### **Additional Information:**

Anencephaly is one of a group of defects that result from failure of the neural tube to close.

Maternal serum alfafetoprotein (MSAFP) and/or amniotic fluid alfafetoprotein (AFAFP) and amniotic fluid acetylcholinesterase (ACHE) may be elevated with anencephaly. However, these screening tests alone are not sufficient to diagnose the condition.

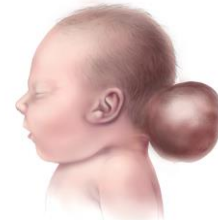In cases where both anencephaly and spina bifida are present but are not continuous (i.e., not craniorachischisis), both anencephaly and spina bifida should be coded.

## Encephalocele

(Recommended Condition)

### Description

Herniation of brain tissue and/or meninges through a defect in the skull. The hernia sac is usually covered by skin.



### Inclusions

Cephalocele  
Cranial meningocele – Herniation of meninges only.  
Encephalocele  
Encephalomyelocele - Herniation through a defect in a portion of both the skull and the upper spine.  
  
Encephalocystomeningocele  
Hydranencephalocele  
Meningoencephalocele  
Ventriculocele

### Exclusions

NA

### ICD-9-CM Codes

742.0

### ICD-10-CM Codes

Q01.0 – Q01.9

### CDC/BPA Codes

742.00 – 742.09

### Diagnostic Methods

Most cases of encephalocele are recognizable on physical examination after delivery. However, they may be conclusively diagnosed only through direct visualization of the brain by cranial ultrasound, CT or MRI scan, surgery, or autopsy. This is particularly true for internal herniations through the sphenoid, maxillary, or ethmoid bones, the orbit, or pharynx.

### Prenatal Diagnoses Not Confirmed Postnatally

Encephalocele may be included when only diagnosed prenatally. However, if it is possible to ascertain the degree of certainty of the prenatal diagnosis, this should factor into the decision as to whether or not to include an individual case in the surveillance data. In addition, the absence of a small encephalocele on prenatal ultrasound does not necessarily mean that it will not be diagnosed after delivery.

### Additional Information:

Encephaloceles are often included as one of a group of defects that result from failure of the neural tube to close. Maternal serum alphafetoprotein (MSAFP) and/or amniotic fluid alphafetoprotein (AFAFP) and amniotic fluid acetylcholinesterase (ACHE) may be elevated with encephaloceles. However, these screening tests alone are not sufficient to diagnose the condition. Occipital encephalocele is a component of Meckel-Gruber syndrome.

## Holoprosencephaly

(Extended Condition)

<b>Description</b>	Structural brain anomaly that results from variable degrees of incomplete cleavage of the prosencephalon (embryonic forebrain), which fails to cleave sagittally into the right and left cerebral hemispheres and transversely into telencephalon and diencephalon.
<b>Inclusions</b>	Alobar holoprosencephaly, semilobar holoprosencephaly, lobar holoprosencephaly, middle interhemispheric variant (MIHV), holotelencephaly, cyclopia, cebocephaly, ethmocephaly.
<b>Exclusions</b>	Aprosencephaly, atelencephaly, hydranencephaly, porencephaly, arhinencephaly without holoprosencephaly
<b>ICD-9-CM Codes</b>	742.2
<b>ICD-10-CM Codes</b>	Q04.2
<b>CDC/BPA Codes</b>	742.26
<b>Diagnostic Methods</b>	Confirmation of a diagnosis of holoprosencephaly is by CT, MRI, or autopsy.
<b>Prenatal Diagnoses Not Confirmed Postnatally</b>	Holoprosencephaly may be included when only diagnosed prenatally. However, if it is possible to ascertain the degree of certainty of the prenatal diagnosis, this should factor into the decision as to whether or not to include an individual case in the surveillance data. For example, clear diagnoses of cyclopia, ethmocephaly, or cebocephaly are virtually always associated with holoprosencephaly, but prenatal diagnoses of lobar holoprosencephaly and middle interhemispheric variants are more problematic without postnatal imaging or autopsy confirmation.

### **Additional Information:**

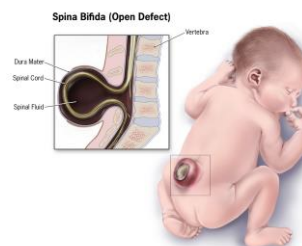
Holoprosencephaly, especially the alobar type, is commonly associated with facial anomalies that range from hypotelorism and median cleft lip (premaxillary agenesis) to cyclopia, a rare abnormality characterized by a single central eye in the low frontal area and a missing nose or a proboscis (a tubular-shaped nose) located above the eye. Other similarly uncommon facial anomalies include ethmocephaly, in which a proboscis is found close to the root of the nose, and cebocephaly, characterized by a small nose with a single nostril situated below underdeveloped eyes.

## Spina Bifida without Anencephaly

(Core Condition)

### Description

Incomplete closure of the vertebral spine (usually posteriorly) through which spinal cord tissue and/or the membranes covering the spine (meninges) herniate.



### Inclusions

Lipomeningocele  
Lipomyelomeningocele  
Meningocele – Herniation of meninges only.  
Meningomyelocele, Myelomeningocele – Herniation of meninges and spinal cord tissue  
Myelocystocele  
Myelodysplasia  
Myeloschisis  
Open spina bifida  
Rachischisis – Open spina bifida without meninges covering the spinal cord tissue  
Spina bifida aperta  
Spina bifida cystica

### Exclusions

Diastematomyelia  
Diplomyelia  
Hydromyelia  
Spina bifida with coexisting anencephaly – Code only as anencephaly  
Spina bifida occulta  
Syringomyelia  
Tethered spinal cord

### ICD-9-CM Codes

741.0 or 741.9 without 740.0 – 740.1

### ICD-10-CM Codes

Q05.0 - Q05.9 or Q07.01 or Q07.03 without Q00.0 - Q00.1

### CDC/BPA Codes

741.00 – 741.99 without 740.00 – 740.10

### Diagnostic Methods

The majority of defects result in a direct opening on the infant's back that is easily recognized on physical examination at delivery. However, the exact nature of the defect (meningocele vs. myelomeningocele) may only be distinguished by CT or MRI scan, at surgery, or at autopsy.

### Prenatal Diagnoses Not Confirmed Postnatally

Spina bifida may be included when only diagnosed prenatally. However, if it is possible to ascertain the degree of certainty of the prenatal diagnosis, this should factor into the decision as to whether or not to include an individual case in the surveillance data. In addition, the absence of spina bifida on prenatal ultrasound does not necessarily mean that it will not be diagnosed after delivery.

**Additional Information:**

Spina bifida is one of a group of defects that result from failure of the neural tube to close.

Open lesions (spina bifida cystica, spina bifida aperta) are those with no covering or with only meninges covering the neural tissue. They usually leak cerebrospinal fluid. Closed lesions are covered by normal skin.

Hydrocephalus and Arnold-Chiari malformation of the brain frequently, though not always, result from spina bifida. When present, there is no need to code them separately from the spina bifida.

Maternal serum alphafetoprotein (MSAFP) and/or amniotic fluid alphafetoprotein (AFAFP) and amniotic fluid acetylcholinesterase (ACHE) may be elevated in spina bifida. However, these screening tests alone are not sufficient to diagnose the condition.

In cases where both anencephaly and spina bifida are present but are not continuous (i.e., not craniorachischisis), both anencephaly and spina bifida should be coded.

If the defect coding system includes unique codes for different levels of spina bifida (cervical; thoracic; lumbar; sacral) and a defect involves more than one level (cervicothoracic; thoracolumbar; lumbosacral), the highest level at which it occurs should be coded (i.e., cervical; thoracic; lumbar). The highest level of involvement determines the degree of associated neurologic impairment.

## Eye

### Anophthalmia/Microphthalmia

(Recommended Condition)

<b>Description</b>	<p>Anophthalmia – Total absence of eye tissue or apparent absence of the globe in an otherwise normal orbit.</p> <p>Microphthalmia – Reduced volume of the eye. The corneal diameter is usually less than 10 millimeters, or the anteroposterior globe diameter is less than 20 millimeters.</p>
<b>Inclusions</b>	<p>Anophthalmia Microphthalmia Nanophthalmia – Microphthalmia with normal internal eye (intraocular) structures. This is a distinct genetic condition.</p>
<b>Exclusions</b>	<p>Small eyes or small palpebral fissures for which the diagnosis of microphthalmia or anophthalmia has not been made.</p> <p>Microcornea with otherwise normal eye size.</p>
<b>ICD-9-CM Codes</b>	743.0, 743.1
<b>ICD-10-CM Codes</b>	Q11.0 – Q11.2
<b>CDC/BPA Codes</b>	743.00 – 743.10
<b>Diagnostic Methods</b>	<p>These conditions are usually recognized on physical examination after delivery, especially by an ophthalmologist. However, the anteroposterior diameter of the globe may be measured only by ultrasound, CT or MRI scan, or at autopsy.</p>
<b>Prenatal Diagnoses Not Confirmed Postnatally</b>	<p>While these conditions may be identified by prenatal ultrasound, they should not be included in surveillance data without postnatal confirmation. In addition, the absence of anophthalmia or microphthalmia on prenatal ultrasound does not necessarily mean that it will not be diagnosed after delivery.</p>

#### **Additional Information:**

Microphthalmia may occur in association with colobomas (gaps) in the uvea, iris, choroid and/or optic nerve (colobomatous microphthalmia).

Anophthalmia and microphthalmia often are accompanied by malformations of the brain and face, and frequently are components of genetic syndromes.



## Congenital Cataract

(Extended Condition)

<b>Description</b>	An opacity of the lens of the eye that has its origin prenatally.
<b>Inclusions</b>	Anterior polar cataract Cataract, type not specified Infantile cataract Lamellar cataract Nuclear cataract Posterior lentiglobus/lenticonus cataract Posterior cortical cataract Sectoral cataract Zonular cataract
<b>Exclusions</b>	Any of the above types of cataract that has its origin after birth Corneal opacities
<b>ICD-9-CM Codes</b>	743.30 – 743.34
<b>ICD-10-CM Codes</b>	Q12.0
<b>CDC/BPA Codes</b>	743.32
<b>Diagnostic Methods</b>	Some cataracts are readily apparent on physical examination. Others are visible with an ophthalmoscope. However, they may be conclusively diagnosed only through examination by an ophthalmologist.
<b>Prenatal Diagnoses Not Confirmed Postnatally</b>	While this condition may be identified by prenatal ultrasound, it should not be included in surveillance data without postnatal confirmation. In addition, the absence of a cataract on prenatal ultrasound does not necessarily mean that it will not be diagnosed after delivery.

### **Additional Information:**

Cataracts may be congenital, acquired, or inherited. They may involve all or only part of the lens of either or both eyes. They may be an isolated finding in an otherwise normal eye, or may be part of a more general eye malformation. They may be seen with metabolic disorders, such as galactosemia; genetic syndromes, such as chondrodysplasia punctata; chromosomal abnormalities, such as Trisomy 21; intrauterine infection, such as congenital rubella; or trauma.

In some instances, the severity of the cataract progresses over time. The need for surgical treatment depends on the degree of visual impairment.

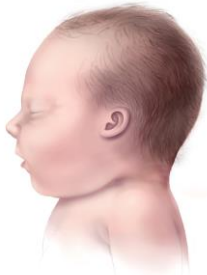When congenital cataract occurs with microphthalmia in the same infant, both conditions should be coded.

## Ear

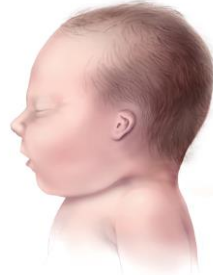### Anotia/Microtia

(Recommended Condition)

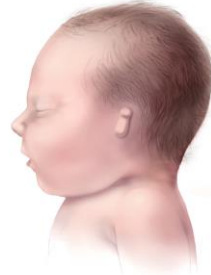**Description**                      Anotia – Total absence of the external ear and canal.  
Microtia – Malformation or hypoplasia of the external ear (auricle, pinna).



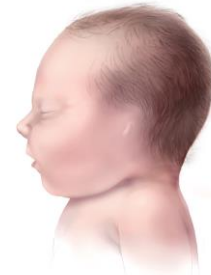Microtia – 1<sup>st</sup> degree



Microtia – 2<sup>nd</sup> degree



Microtia – 3<sup>rd</sup> degree



Anotia

**Inclusions**                              Anotia  
Microtia

**Exclusions**                              Small ears that retain most of the overall structure of the normal auricle, including lop or cup ear defects. In these, the auditory meatus is usually patent and defects of the ossicular chain of the middle ear are infrequent. However, these defects are sometimes designated as Type I Microtia.

Isolated absence, atresia, stenosis or malformation of the ear canal with a normal external ear.

Congenital absence of the ear not diagnosed as anotia or microtia.

**ICD-9-CM Codes**                      744.01, 744.23

**ICD-10-CM Codes**                    Q16.0, Q17.2

**CDC/BPA Codes**                      744.01, 744.21

**Diagnostic Methods**                    Anotia and microtia are usually easily recognized on physical examination after delivery. However, abnormalities of the middle and inner ear may be conclusively diagnosed only by CT or MRI scan, surgery, or autopsy.

**Prenatal Diagnoses Not Confirmed Postnatally**              While these conditions may be identified by prenatal ultrasound, they should not be included in surveillance data without postnatal confirmation. In addition, the absence of anotia or microtia on prenatal ultrasound does not necessarily mean that they will not be diagnosed after delivery.

**Additional Information:**

The spectrum of severity of microtia may range from a measurably small external ear with minimal structural abnormality to major structural alteration of the external ear with an absent or blind-ending canal. Following is the classification system of Meurman (modified from Marks):

Type I B – Generally small ears that retain most of the overall structure of the normal auricle. These should not be coded as microtia.

Type II B – A moderately severe anomaly with a longitudinal mass of cartilage with some resemblance to a pinna. The rudimentary auricle may be hook-shaped, have an S-shape, or the appearance of a question mark.

Type III B – The ear is a rudiment of soft tissue and the auricle has no resemblance to a normal pinna.

Type IV B – Complete absence of all external ear structures (anotia).

Abnormalities that may be associated with anotia/microtia include anomalies of the middle and/or inner ear, the mandible and face, and hearing loss.

Anotia/microtia may be a component of Goldenhar and other syndromes.

## Cardiovascular

### Aortic Valve Stenosis

(Recommended Condition)

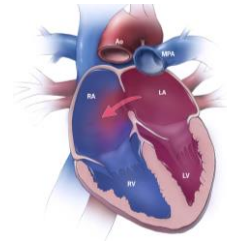
<b>Description</b>	Obstruction or narrowing of the aortic valve, which may impair blood flow from the left ventricle to the aorta.
<b>Inclusions</b>	Stenosis of the aortic valve
<b>Exclusions</b>	Stenosis of the aorta without mention of the aortic valve. Supra-valvular or sub-valvular aortic stenosis.
<b>ICD-9-CM Codes</b>	746.3
<b>ICD-10-CM Codes</b>	Q23.0
<b>CDC/BPA Codes</b>	746.30
<b>Diagnostic Methods</b>	While aortic valve stenosis may be suspected by clinical presentation, it may be conclusively diagnosed only through direct visualization of the heart by cardiac echo (echocardiography), catheterization, surgery, or autopsy.
<b>Prenatal Diagnoses Not Confirmed Postnatally</b>	While this condition may be identified by prenatal ultrasound, it should not be included in surveillance data without postnatal confirmation. In addition, the absence of aortic valve stenosis on prenatal ultrasound does not necessarily mean that it will not be diagnosed after delivery.
<b>Additional Information</b>	NA

## Atrial Septal Defect (ASD)

(Recommended Condition)

### Description

An opening in the wall (septum) that separates the left and right top chambers (atria) of the heart.



### Inclusions

Atrial septal defect (ASD), type not specified (NOS)  
ASD other specified (OS) – which includes sinus venosus type  
ASD secundum type (ASD 2 or ASD II)

ASD vs. PFO – In the first days of life, it may not be possible to distinguish whether the opening in the atrial septum is a true ASD or a patent foramen ovale that has not yet closed (see below). ASD vs. PFO should be included only if the exact nature of the condition was never resolved.

### Exclusions

Atrioventricular septal defects (AVSD)  
ASD primum type (1° ASD) – This is included under atrioventricular septal defects (see below).  
Patent foramen ovale (PFO) – A PFO is normal *in utero* to allow blood to flow properly during fetal circulation. This usually closes shortly after birth, but frequently does not close until 24 to 48 hours after birth.

### ICD-9-CM Codes

745.5

### ICD-10-CM Codes

Q21.1

### CDC/BPA Codes

745.51 – 745.59

### Diagnostic Methods

Some isolated ASDs may be diagnosed based on physical examination and/or EKG without direct imaging of the heart. However, many ASDs may be conclusively diagnosed only through direct visualization of the heart by cardiac echo (echocardiography), catheterization, surgery, or autopsy.

### Prenatal Diagnoses Not Confirmed Postnatally

While ASDs may be identified by prenatal ultrasound, they may close spontaneously before delivery. For this reason, ASDs that are diagnosed prenatally should not be included unless they have been confirmed postnatally. In addition, the absence of an ASD on prenatal ultrasound does not necessarily mean that an ASD will not be diagnosed after delivery, as it is not always possible to accurately visualize the entire atrial septum by prenatal ultrasound.

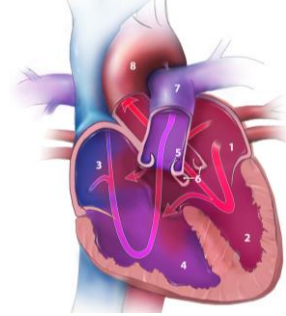
### Additional Information:

Types of ASDs are denoted by location on the septum and when they formed in utero. Secundum ASDs are usually located toward the middle of the atrial septum. Some close spontaneously without treatment. Primum ASDs are located in the lower portion of the atrial septum near the atrioventricular valves, are etiologically related to atrioventricular septal defects, and never close spontaneously.

## Atrioventricular Septal Defect (Atrioventricular Canal Defect; Endocardial Cushion Defect) (Core Condition)

### Description

A defect in both the lower portion of the atrial septum and the upper portion of the ventricular septum. In extreme cases, virtually the entire atrial and ventricular septae may be missing. The valves controlling blood flow from the atria to the ventricles, the tricuspid and mitral valves may also be abnormal. They may not form from the endocardial cushions during cardiac development into two separate valves, and thus be a single common atrioventricular valve.



Together, these defects producing a large opening (canal) in the central part of the heart.

### Inclusions

Atrioventricular septal defect (AVSD)  
Common or complete atrioventricular (AV) canal  
Endocardial cushion defect

Primum type atrial septal defect (1° ASD) – A defect only in the lower portion of the atrial septum. While this does not involve a defect in the upper portion of the ventricular septum, it is etiologically related to the more complete form of AVSD. A cleft mitral valve is often present with a primum type ASD (see partial AVC).

Common atrium – Near absence of the atrial septum.  
Partial AV canal (partial endocardial cushion defect) – Refers to a primum ASD with cleft mitral valve.

Inflow-type, subtricuspid, or canal-type ventricular septal defect (VSDAVC) – A defect in the upper (inflow) portion of the ventricular septum. While this does not also involve a defect in the lower portion of the atrial septum, it is etiologically related to the more complete form.

### Exclusions

Secundum ASDs that coexist with a VSD. In this instance, both the ASD and the VSD should be coded.

### ICD-9-CM Codes

745.60, 745.61, 745.69

### ICD-10-CM Codes

Q21.2

### CDC/BPA Codes

745.60 – 745.69, 745.487

### Diagnostic Methods

While atrioventricular septal defects may be suspected by clinical presentation, examination, and EKG changes, it may be conclusively diagnosed only through direct visualization of the heart by cardiac echo (echocardiography), catheterization, surgery, or autopsy.

### Prenatal Diagnoses Not

These conditions may be included as cases when only diagnosed prenatally.

**Confirmed Postnatally**      However, if it is possible to ascertain the degree of certainty of the prenatal diagnosis, this should factor into the decision as to whether or not to include an individual case in the surveillance data, as it may be difficult to distinguish this condition from other abnormalities of the cardiac septae prenatally. Live-born children who survive should always have confirmation of the defect postnatally.

**Additional Information:**

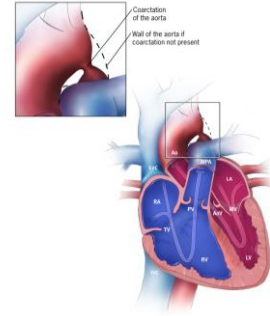
Atrioventricular septal defects are known to be associated with Down syndrome. Approximately 40% of children with Down syndrome have some type of CHD, 20% have an atrioventricular septal defect. Conversely, approximately 70% of children with an atrioventricular septal defect have Down syndrome.

## Coarctation of the Aorta

(Recommended Condition)

### Description

Narrowing of the descending aorta, which may obstruct blood flow from the heart to the rest of the body. The most common site of coarctation occurs distal to the origin of the left subclavian artery in the region of the ductus arteriosus. If there is complete loss of communication in this location, it is a form of interruption of the aorta (Type A).



### Inclusions

Coarctation of the aorta, type not specified  
Preductal, juxtaductal, and postductal coarctations – These terms refer to the exact placement of the segment of coarctation relative to the insertion of the ductus arteriosus.

### Exclusions

NA

### ICD-9-CM Codes

747.10

### ICD-10-CM Codes

Q25.1

### CDC/BPA Codes

747.10 – 747.19

### Diagnostic Methods

While coarctation of the aorta may be suspected by clinical presentation and examination, it may be conclusively diagnosed only through direct visualization of the heart by cardiac echo (echocardiography), catheterization, surgery, or autopsy.

### Prenatal Diagnoses Not Confirmed Postnatally

While this condition may be identified by prenatal ultrasound, it should not be included in surveillance data without postnatal confirmation. In addition, the absence of coarctation of the aorta on prenatal ultrasound does not necessarily mean that it will not be diagnosed after delivery.

### Additional Information:

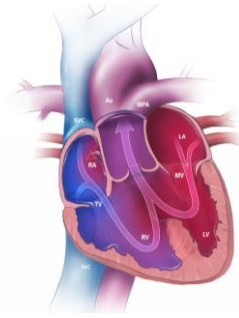
Left-sided obstructive lesions of the heart, such as coarctation, have been associated with Turner syndrome (karyotype 45,X and other variants).



## Common Truncus (Truncus Arteriosus or TA) (Core Condition)

### Description

Failure of separation of the aorta and the pulmonary artery during development, resulting in a single common arterial trunk carrying blood from the heart to both the body and lungs.



### Inclusions

Common truncus  
Truncus arteriosus (TA)  
Persistent truncus arteriosus

### Exclusions

Aorto-pulmonary window. In ICD-9-CM, this related defect is not distinguished from truncus. An AP window is a hole (aka “window”) between a separate aorta and pulmonary artery. This is distinct from truncus, when neither vessel forms separately.

### ICD-9-CM Codes

745.0

### ICD-10-CM Codes

Q20.0

### CDC/BPA Codes

745.00 only (excluding 745.01, aortic septal defect which including aorto-pulmonary window)

### Diagnostic Methods

Truncus arteriosus is conclusively diagnosed only through direct visualization of the heart by cardiac imaging (typically echocardiography but also MRI), catheterization, surgery, or autopsy. A clinical diagnosis is considered insufficient to make the diagnosis.

### Prenatal Diagnoses Not Confirmed Postnatally

These conditions may be included as cases when only diagnosed prenatally by a pediatric cardiologist through fetal echocardiography. However, if it is possible to ascertain the degree of certainty of the prenatal diagnosis, this should factor into the decision as to whether or not to include an individual case in the surveillance data. Live-born children who survive should always have confirmation of the defect postnatally.

### Additional Information:

A ventricular septal defect is often present in association with truncus defects and should be coded separately. Truncus arteriosus is one of several abnormalities of the outflow tract of the heart known as conotruncal defects. Some infants (1 in 5 to 1 in 3) with these defects have a deletion on the short arm of chromosome 22 (deletion 22q11.2). This deletion may not necessarily be detected on a routine karyotype analysis and is more reliably diagnosed by fluorescent *in situ* hybridization (FISH) or microarray technology.

## Double Outlet Right Ventricle (DORV)

(Recommended Condition)

<b>Description</b>	Both the pulmonary artery and the aorta arise from the right ventricle, usually accompanied by a ventricular septal defect (VSD). DORV subtypes are usually distinguished by the great artery anatomic relationship: DORV with normally related great arteries and DORV with “transposed” or malposed or side-by-side great arteries. Actually, the arteries are not truly “transposed”, which refers to the aorta arising from the right ventricle and pulmonary artery from the left ventricle, since in DORV both great arteries arise from the right ventricle.
<b>Inclusions</b>	Double outlet right ventricle (DORV) with normally related great vessels DORV with transposed great vessels DORV with unknown relationship of great vessels Taussig-Bing syndrome –  If a case has separate codes for DORV and TGA, include case in the DORV category only and not in the TGA category.
<b>Exclusions</b>	NA
<b>ICD-9-CM Codes</b>	745.11
<b>ICD-10-CM Codes</b>	Q20.1
<b>CDC/BPA Codes</b>	745.13 -745.15
<b>Diagnostic Methods</b>	DORV is conclusively diagnosed through direct visualization of the heart by cardiac echo (echocardiography), catheterization, surgery, or autopsy.
<b>Prenatal Diagnoses Not Confirmed Postnatally</b>	These conditions may be included as cases when only diagnosed prenatally. However, if it is possible to ascertain the degree of certainty of the prenatal diagnosis, this should factor into the decision as to whether or not to include an individual case in the surveillance data. Live-born children who survive should always have confirmation of the defect postnatally.

### Additional Information:

Distinction of types of DORV is often done on the basis of the anatomic relationship of the great arteries/vessels, which can be malposed, side-by-side, normal or undetermined. However, the coding systems are somewhat confusing in representing these anatomic distinctions. In ICD-9-CM, the single code for DORV is contained under the broader category of Transposition of Great Arteries (TGA). Actually, the arteries are not truly “transposed”, which refers to the aorta arising from the right ventricle and pulmonary artery from the left ventricle, since in DORV both great arteries arise from the right ventricle, regardless of how they are related positionally. In ICD-10-CM, there also is no distinction for great artery relationship, but the single code for DORV is no longer a subtype under TGA. In the latest version of modified CDC/BPA codes there are separate DORV codes depended on knowledge of the great artery relationship.

Previously, for surveillance guidelines, all DORV was included in the TGA category, following the coding system structure. However, now there is a new separate category for all types of DORV.

## **Ebstein Anomaly** (Recommended Condition)

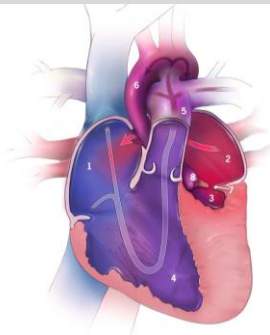
<b>Description</b>	Abnormal formation and downward displacement of the tricuspid valve into the right ventricle. The tricuspid valve is usually hypoplastic and regurgitant. As a result, the right atrium is enlarged and the right ventricle is small. There may also be associated pulmonary stenosis as the abnormal tricuspid valve tissue obstructs blood flow out of the pulmonary valve.
<b>Inclusions</b>	Ebstein's anomaly Ebstein malformation
<b>Exclusions</b>	NA
<b>ICD-9-CM Codes</b>	746.2
<b>ICD-10-CM Codes</b>	Q22.5
<b>CDC/BPA Codes</b>	746.20
<b>Diagnostic Methods</b>	While Ebstein's anomaly may be suspected by clinical presentation, it may be conclusively diagnosed only through direct visualization of the heart by cardiac echo (echocardiography), catheterization, surgery, or autopsy.
<b>Prenatal Diagnoses Not Confirmed Postnatally</b>	While this condition may be identified by prenatal ultrasound, it should not be included in surveillance data without postnatal confirmation. In addition, the absence of Ebstein's anomaly on prenatal ultrasound does not necessarily mean that it will not be diagnosed after delivery.

### **Additional Information:**

Ebstein's anomaly has been associated with lithium exposure during gestation. However, the magnitude of this association is probably very small.

## Hypoplastic Left Heart Syndrome (HLHS)

(Core Condition)

<b>Description</b>	<p>A condition in which the structures on the left side of the heart and the aorta are extremely small, insufficient to support systemic circulation and with normally related great arteries. Classically, this condition includes hypoplasia of the left ventricle, atresia or severe hypoplasia of both the mitral and aortic valves, hypoplasia of the aortic arch, and coarctation of the aorta.</p>	
<b>Inclusions</b>	<p>Any diagnosis of hypoplastic left heart syndrome, regardless of whether all conditions in the classical definition are present.</p>	
<b>Exclusions</b>	<p>Hypoplasia or diminished size of the left ventricle alone without involvement of other structures on the left side of the heart or the aorta.</p> <p>Hypoplastic left heart or small left ventricle that occurs as part of another complex heart defect, such as atrioventricular septal defect.</p>	
<b>ICD-9-CM Codes</b>	746.7	
<b>ICD-10-CM Codes</b>	Q23.4	
<b>CDC/BPA Codes</b>	746.70	
<b>Diagnostic Methods</b>	<p>While hypoplastic left heart may be suspected by clinical presentation, examination, and EKG changes, it may be conclusively diagnosed only through direct visualization of the heart by cardiac echo (echocardiography), catheterization, surgery, or autopsy.</p>	
<b>Prenatal Diagnoses Not Confirmed Postnatally</b>	<p>These conditions may be included as cases when only diagnosed prenatally. However, if it is possible to ascertain the degree of certainty of the prenatal diagnosis, this should factor into the decision as to whether or not to include an individual case in the surveillance data, as it may be difficult to distinguish this condition from other abnormalities of the left ventricle prenatally. Live-born children who survive should always have confirmation of the defect postnatally before being included.</p>	
<b>Additional Information</b>	NA	

## Interrupted Aortic Arch (IAA)

(Recommended Condition)

<b>Description</b>	Complete loss of communication (interruption) between the ascending and descending aorta, usually associated with a malalignment-type ventricular septal defect (VSD). Types of IAA are defined by where the interruption occurs along the arch from the conotruncus to the descending aorta. Type A involves the distal descending aorta distal to the left subclavian artery in the same region as coarctation of the aorta, and is considered an extreme version of that obstructive defect. Type B interruption occurs between the left carotid and subclavian, and is considered a conotruncal heart defect; it is the more common form of interrupted aortic arch.
<b>Inclusions</b>	IAA types A, B or C, or all IAA if type unknown or not otherwise specified (NOS).
<b>Exclusions</b>	NA
<b>ICD-9-CM Codes</b>	747.11
<b>ICD-10-CM Codes</b>	Q25.2, Q25.4
<b>CDC/BPA Codes</b>	747.215 - 747.217, 747.285
<b>Diagnostic Methods</b>	IAA is conclusively diagnosed through direct visualization of the heart by cardiac echo (echocardiography), catheterization, surgery, or autopsy.
<b>Prenatal Diagnoses Not Confirmed Postnatally</b>	These conditions may be included as cases when only diagnosed prenatally. However, if it is possible to ascertain the degree of certainty of the prenatal diagnosis, this should factor into the decision as to whether or not to include an individual case in the surveillance data. Live-born children who survive should always have confirmation of the defect postnatally.
<b>Additional Information</b>	NA

## Pulmonary Valve Atresia and Stenosis

(Recommended Condition)

<b>Description</b>	<p>Pulmonary valve atresia – Lack of patency, or failure of formation altogether, of the pulmonary valve, resulting in obstruction of blood flow from the right ventricle to the pulmonary artery.</p> <p>Pulmonary valve stenosis – Obstruction or narrowing of the pulmonary valve, which may impair blood flow from the right ventricle to the pulmonary artery.</p>
<b>Inclusions</b>	<p>Pulmonary valve atresia with intact ventricular septum Pulmonary valve stenosis (PS) (most cases of PS) Pulmonic stenosis (PS)</p>
<b>Exclusions</b>	<p>Atresia or stenosis of the main or branch (right or left) pulmonary arteries, not involving the pulmonary valve. Pulmonary stenosis that occurs as part of Tetralogy or Pentalogy of Fallot. Supra-valvular or sub-valvular pulmonic stenosis.</p>
<b>ICD-9-CM Codes For CCHD Screening</b>	<p>746.01 (pulmonary valve atresia), 746.02 (pulmonary valve stenosis) 746.01 only (pulmonary atresia, intact ventricular septum)</p>
<b>ICD-10-CM Codes For CCHD Screening</b>	<p>Q22.0, Q22.1 Q22.0 only (pulmonary atresia, intact ventricular septum)</p>
<b>CDC/BPA Codes For CCHD Screening</b>	<p>746.00 (pulmonary valve atresia), 746.01 (pulmonary valve stenosis) 746.00 only (pulmonary atresia, intact ventricular septum)</p>
<b>Diagnostic Methods</b>	<p>While pulmonary valve atresia or stenosis may be suspected by clinical presentation, it may be conclusively diagnosed only through direct visualization of the heart by cardiac echo (echocardiography), catheterization, surgery, or autopsy.</p>
<b>Prenatal Diagnoses Not Confirmed Postnatally</b>	<p>While these conditions may be identified by prenatal ultrasound, they should not be included in surveillance data without postnatal confirmation. In addition, the absence of pulmonary valve atresia or stenosis on prenatal ultrasound does not necessarily mean that it will not be diagnosed after delivery.</p>

**Additional Information:**

These defects have important physiological and coding differences among systems as seen here in the Table, which is also discussed in the Tetralogy of Fallot section.

CCHD	ICD-9	CDC/BPA
PVS	746.02	746.01
PA, IVS	746.01	746.00
PA, VSD (TOF)	--	747.31
TOF	745.2	745.20 - 21

Pulmonary valve atresia or stenosis may occur with or without a coexisting ventricular septal defect. For pulmonary valve atresia without a VSD (intact ventricular septum), the CDC/BPA code 746.00 (“atresia, hypoplasia of pulmonary valve”) is used, corresponding to the ICD-9-CM code 746.01. In CDC/BPA,

746.01 refers to pulmonary valve stenosis.

Pulmonary atresia with a VSD is similar to severe forms of Tetralogy of Fallot, and is included in Tetralogy of Fallot for surveillance (see below). There is no good code depicting *valvular* pulmonary atresia with VSD; hence in CDC/BPA the code 747.31 (“pulmonary *artery* atresia with septal defect”) is used.

## Single Ventricle

(Recommended Condition)

<b>Description</b>	Instead of two separate ventricles, there is only one morphological ventricle, most commonly a double-inlet left ventricle. This is always a complex heart with several associated heart defects.
<b>Inclusions</b>	Single ventricle or common ventricle <b>WITHOUT</b> more specific diagnosis related to hypoplastic ventricle or atrioventricular valve (e.g. Hypoplastic left heart syndrome or tricuspid atresia). Forms include double-inlet left ventricle (most common), double inlet right ventricle, single ventricle indeterminate morphology, and other specified type of single ventricle.
<b>Exclusions</b>	“Functional” single ventricles, which have 2 ventricles, one of which is very small, so the heart functions as a single ventricle; these are usually due to atresia of one of the atrioventricular valves. Single/common ventricle <b>WITH</b> more specific diagnosis related to hypoplastic ventricle or atrioventricular valves (e.g. hypoplastic left heart syndrome or tricuspid atresia) are excluded from this category but included elsewhere: <ul style="list-style-type: none"><li>• Hypoplastic Left Heart Syndrome (single right ventricle)</li><li>• Tricuspid Atresia (single left ventricle)</li><li>• Complete atrioventricular canal with malalignment of the AV valves to either the right or left side (creating a single ventricle)</li><li>• Some severe forms of DORV (single right ventricle)</li></ul>
<b>ICD-9-CM Codes</b>	745.3
<b>ICD-10-CM Codes</b>	Q20.4
<b>CDC/BPA Codes</b>	745.3
<b>Diagnostic Methods</b>	Single ventricle is conclusively diagnosed through direct visualization of the heart by cardiac echo (echocardiography), catheterization, surgery, or autopsy.
<b>Prenatal Diagnoses Not Confirmed Postnatally</b>	These conditions may be included as cases when only diagnosed prenatally. However, if it is possible to ascertain the degree of certainty of the prenatal diagnosis, this should factor into the decision as to whether or not to include an individual case in the surveillance data or which category to include the case in. Live-born children who survive should always have confirmation of the defect postnatally.

### Additional Information

These are very difficult hearts to code and categorize, as they often have many different descriptions. Forms include double-inlet left ventricle (most common), double inlet right ventricle, single ventricle indeterminate morphology, and other specified type of single ventricle. Other associated heart defects may include transposed/malposed great vessels, pulmonary stenosis, coarctation of aorta, and rudimentary outlet chambers (the tiny second ventricle).

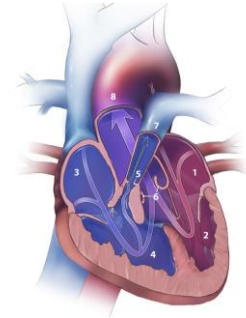


## Tetralogy of Fallot (TOF)

(Core Condition)

### Description

The simultaneous presence of a ventricular septal defect (VSD), pulmonic and subpulmonic stenosis, a malpositioned aorta that overrides the ventricular septum, and right ventricular hypertrophy.



### Inclusions

Pentalogy of Fallot – Tetralogy of Fallot with an associated inter-atrial communication, either a patent foramen ovale (PFO) or an atrial septal defect (ASD).

Tetralogy of Fallot (TOF)

Tet

Pulmonary atresia with VSD (see ‘Additional information’)

### Exclusions

Simultaneous occurrence of a VSD and pulmonary stenosis that has TOF physiology but has not been diagnosed as Tetralogy of Fallot. Also, some coding systems may also include Trilogy of Fallot, or Fallot’s Triad – the simultaneous presence of an atrial septal defect, pulmonic stenosis, and right ventricular hypertrophy. This is not to be included as TOF.

### ICD-9-CM Codes

745.2

### ICD-10-CM Codes

Q21.3

### CDC/BPA Codes

745.20 – 745.21, 747.31

(Note: code 746.84 (trilogy of Fallot) has been removed)

### Diagnostic Methods

While Tetralogy of Fallot may be suspected by clinical presentation, it may be conclusively diagnosed only through direct visualization of the heart by cardiac echo (echocardiography), catheterization, surgery, or autopsy.

### Prenatal Diagnoses Not Confirmed Postnatally

These conditions may be included as cases when only diagnosed prenatally. However, if it is possible to ascertain the degree of certainty of the prenatal diagnosis, this should factor into the decision as to whether or not to include an individual case in the surveillance data. Live-born children who survive should always have confirmation of the defect postnatally.

### Additional Information:

Children with Tetralogy of Fallot may experience episodes of cyanosis or hypoxia that result from shunting of unoxygenated blood across the VSD from the right to the left ventricle. Children who have a coexisting VSD and pulmonary stenosis, but do not have Tetralogy of Fallot, may experience similar episodes. Thus, the occurrence of cyanosis or hypoxia does not necessarily mean a child has been diagnosed with Tetralogy of Fallot.

Tetralogy of Fallot is one of several abnormalities of the outflow tract of the heart known as conotruncal defects. Some infants (approximately 1 in 7) with these defects have a deletion on the short arm of

chromosome 22 (deletion 22q11.2). This deletion is diagnosed using fluorescent *in situ* hybridization (FISH) and will not necessarily be detected on a routine karyotype analysis.

Tetralogy of Fallot is on a spectrum with other defects having important physiological and coding differences among systems as seen here in the table.

<b>CCHD</b>	<b>ICD-9</b>	<b>CDC/BPA</b>
PVS	746.02	746.01
PA, IVS	746.01	746.00
PA, VSD (TOF)	--	747.31
TOF	745.2	745.20 - 21

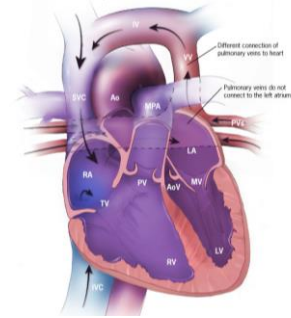
Pulmonary atresia with a VSD is similar to severe forms of Tetralogy of Fallot and is included here for surveillance. There is no good code depicting *valvular* pulmonary atresia with VSD; hence in CDC/BPA the code 747.31 (“pulmonary *artery* atresia with septal defect”) is used. For pulmonary valvular atresia without a VSD (intact ventricular septum), the code 746.00 (“atresia, hypoplasia of pulmonary valve”) is used – see separate section on Pulmonary valve atresia/stenosis.

When pulmonary valve atresia occurs with a VSD, the child may experience episodes of cyanosis or hypoxia similar to those seen in children with Tetralogy of Fallot. This results from shunting of unoxygenated blood across the VSD from the right to the left ventricle. Thus, the occurrence of cyanosis or hypoxia does not necessarily mean that the child has Tetralogy of Fallot.

## Total Anomalous Pulmonary Venous Connection (TAPVC) (Core Condition)

### Description

A condition in which all 4 pulmonary veins connect anomalously into the systemic venous circulation to the right atrium or the body (systemic veins) instead of the left atrium; often occurs with other cardiac defects.



### Inclusions

TAPVC (total anomalous pulmonary venous connection)  
TAPVR (total anomalous pulmonary venous return)  
TAPVD (total anomalous pulmonary venous drainage)

### Exclusions

If not all 4 veins are visibly connecting/draining anomalously (e.g. Partial Anomalous Venous Return, ICD-9-CM code 747.42 or CDC/BPA code 747.41 or Q26.3)

### ICD-9-CM Codes

747.41

### ICD-10-CM Codes

Q26.2

### CDC/BPA Codes

747.42

### Diagnostic Methods

While TAPVR may be suspected by clinical presentation, it may be conclusively diagnosed only through direct visualization of the heart by cardiac echo (echocardiography), catheterization, surgery, or autopsy. The difficulty in viewing all 4 veins may mean that several echocardiograms may be needed to confirm the diagnosis.

### Prenatal Diagnoses Not Confirmed Postnatally

TAPVR is difficult to identify prenatally. If identified by prenatal ultrasound, it should not be included in surveillance data without postnatal confirmation. In addition, the absence of TAPVR on prenatal ultrasound does not necessarily mean that it will not be diagnosed after delivery.

### Additional Information:

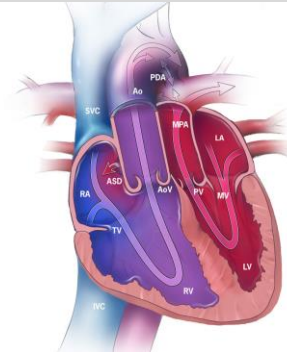
Total anomalous pulmonary venous return and partial anomalous pulmonary venous return have not been shown to be developmentally related, although they share a similar description. Also, there are subtle differences in the meaning of anomalous venous connection, return, and drainage, but the terms are often used interchangeably.

## Transposition of the Great Arteries (TGA)

(Core Condition)

**Description**

Transposition of the aorta and the pulmonary artery such that the aorta arises from the right ventricle (instead of the left) and the pulmonary artery arises from the left ventricle (instead of the right).



**Inclusions**

Complete or “dextro” transposition (d-TGA without a VSD)  
Corrected, or “levo”transposition (l-TGA) (but exclude for CCHD screening)  
Incomplete transposition (d-TGA with a VSD)  
Transposition of the Great Arteries (TGA), not otherwise specified  
Transposition of the Great Vessels (TGV)

**Exclusions**

Cases with codes for both DORV and TGA are counted in the DORV category. DORV subtype with malposed/”transposed” great arteries (CDC/BPA 745.14 are also counted in the DORV category , along with 745.13, and 745.15.

**ICD-9-CM Codes For CCHD Screening**

745.10, 745.12, 745.19  
745.10 (d-TGA only)

**ICD-10-CM Codes For CCHD Screening**

Q20.3, Q20.5  
Q20.3 only

**CDC/BPA Codes For CCHD Screening**

745.10 – 745.12, 745.18 – 745.19  
745.10 (TGA complete, no VSD), 745.11 (TGA incomplete, with VSD), 745.18 (Other specified TGA), 745.19 (Unspecified TGA)

**Diagnostic Methods**

d-TGA is conclusively diagnosed through direct visualization of the heart by cardiac echo (echocardiography), catheterization, surgery, or autopsy.

**Prenatal Diagnoses Not Confirmed Postnatally**

These conditions may be included as cases when only diagnosed prenatally. However, if it is possible to ascertain the degree of certainty of the prenatal diagnosis, this should factor into the decision as to whether or not to include an individual case in the surveillance data. Live-born children who survive should always have confirmation of the defect postnatally.

**Additional Information:**

In order for a child with d-TGA to survive, a communication must be present between the pulmonary and systemic circulations to allow oxygenated blood from the lungs to reach the right ventricle for distribution to the rest of the body through the abnormally placed aorta. In most instances, this communication is through a ventricular septal defect (incomplete TGA). If a VSD is not present, oxygenated blood from the lungs is returned directly to the lungs without being distributed to the rest of the body (complete TGA).

If the defect coding system does not include unique codes to differentiate TGA with and without a VSD (complete vs. incomplete), the VSD should be coded separately when present.

l-TGA (corrected transposition or “levo” transposition) is a defect in which the ventricle on the right side of the heart has the anatomic appearance of the left ventricle, and the ventricle on the left side of the heart has the anatomic appearance of the right ventricle (ventricular inversion). The pulmonary artery arises from the anatomic left ventricle and the aorta arises from the anatomic right ventricle (hence the designation of transposition). Because blood from the ventricle on the right flows through the pulmonary artery, and that from the ventricle on the left flows through the aorta, circulation is normal as long as there are no other defects.

Transposition of the great arteries is one of several abnormalities of the outflow tract of the heart known as conotruncal defects. Very few infants with these defects have a deletion on the short arm of chromosome 22 (deletion 22q11.2). This deletion is diagnosed using fluorescent *in situ* hybridization (FISH) and will not necessarily be detected on a routine karyotype analysis.

## Tricuspid Valve Atresia and Stenosis

(Recommended Condition)

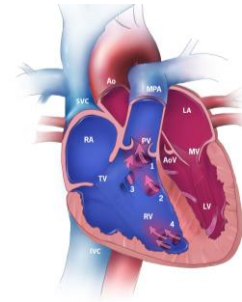
<b>Description</b>	<p>Tricuspid valve atresia – Lack of patency, or failure of formation altogether, of the tricuspid valve, resulting in obstruction of blood flow from the right atrium to the right ventricle.</p> <p>Tricuspid valve stenosis – Obstruction or narrowing of the tricuspid valve, which may impair blood flow from the right atrium to the right ventricle.</p>
<b>Inclusions</b>	<p>Tricuspid atresia Tricuspid stenosis</p>
<b>Exclusions</b>	<p>Tricuspid regurgitation without specific mention of tricuspid atresia or stenosis.</p>
<b>ICD-9-CM Codes</b>	<p>746.1</p>
<b>ICD-10-CM Codes</b>	<p>Q22.4</p>
<b>CDC/BPA Codes</b>	<p>746.100 (tricuspid atresia), 746.106 (tricuspid stenosis) (excluding 746.105 – tricuspid insufficiency),</p>
<b>For CCHD Screening</b>	<p>746.100 only Note: Only the tricuspid atresia is a CCHD. Many cases of tricuspid stenosis are not critical.</p>
<b>Diagnostic Methods</b>	<p>While tricuspid valve atresia or stenosis may be suspected by clinical presentation, it may be conclusively diagnosed only through direct visualization of the heart by cardiac echo (echocardiography), catheterization, surgery, or autopsy.</p>
<b>Prenatal Diagnoses Not Confirmed Postnatally</b>	<p>While these conditions may be identified by prenatal ultrasound, they should not be included in surveillance data without postnatal confirmation. In addition, the absence of tricuspid valve atresia or stenosis on prenatal ultrasound does not necessarily mean that it will not be diagnosed after delivery.</p>
<b>Additional Information</b>	<p>NA</p>

## Ventricular Septal Defect (VSD)

(Recommended Condition)

### Description

An opening in the wall (septum) that separates the left and right ventricles of the heart.



### Inclusions

Ventricular septal defect  
VSD

### Exclusions

Ventricular septal defects that occur as part of Tetralogy of Fallot or an atrioventricular septal defect. Inflow-type, subtricuspid, and canal-type VSDs are assumed to be part of an atrioventricular septal defect and should not be coded separately .

### ICD-9-CM Codes

745.4

### ICD-10-CM Codes

Q21.0

### CDC/BPA Codes

745.40 – 745.49 (excluding 745.487 (inlet VSD in AVSD category), 745.498 (possible VSD))

### Diagnostic Methods

Some isolated VSDs may be diagnosed on physical examination and/or EKG without direct imaging of the heart. However, many VSDs may be conclusively diagnosed only through direct visualization of the heart by cardiac echo (echocardiography), catheterization, surgery, or autopsy.

### Prenatal Diagnoses Not Confirmed Postnatally

While VSDs may be identified by prenatal ultrasound, many close spontaneously before delivery. For this reason, VSDs that are diagnosed prenatally should not be included unless they have been confirmed postnatally. In addition, the absence of a VSD on prenatal ultrasound does not necessarily mean that a VSD will not be diagnosed after delivery, as it is not always possible to accurately visualize the entire ventricular septum by prenatal ultrasound.

### Additional Information:

VSDs may be of several types, depending on the location of the opening along the ventricular septum. The most common are: Muscular, Membranous, Perimembranous.

However, in many instances the type of VSD may not be specified in the medical record. Many muscular, membranous and perimembranous VSDs may close spontaneously in the first weeks or months of life without treatment. An aneurysm of the ventricular septum indicates a membranous or perimembranous VSD that is in the process of closing.

## Orofacial

### Choanal Atresia

(Recommended Condition)

<b>Description</b>	Congenital obstruction of the opening of the nasal cavity into the nasopharynx on either side. This prevents communication of the nasal cavity with the pharynx.
<b>Inclusions</b>	Choanal atresia, type not specified Choanal stenosis Membranous choanal atresia, with or without a bony rim Completely bony choanal atresia
<b>Exclusions</b>	NA
<b>ICD-9-CM Codes</b>	748.0
<b>ICD-10-CM Codes</b>	Q30.0
<b>CDC/BPA Codes</b>	748.00
<b>Diagnostic Methods</b>	Bilateral choanal atresia is usually easily recognized at birth from the clinical presentation of obligate mouth-breathing. Unilateral choanal atresia may be suspected by clinical examination. Both conditions may be diagnosed by the inability to pass a feeding tube from the nasal passage(s) into the posterior pharynx. Both conditions may also be seen on CT or MRI scan, at surgery or autopsy.
<b>Prenatal Diagnoses Not Confirmed Postnatally</b>	While these conditions may be identified by prenatal ultrasound, they should not be included in birth defects surveillance data without postnatal confirmation. In addition, the absence of choanal atresia on prenatal ultrasound does not necessarily mean that it will not be diagnosed after delivery.

#### **Additional Information:**

Choanal atresia or stenosis may be unilateral or bilateral. If the defect coding system includes unique codes for these different types, the location should be coded.

Choanal atresia is one of the defects reported as part of the CHARGE association, which may also include colobomas, heart defects, retarded growth and development, genital hypoplasia, and ear anomalies and/or deafness.

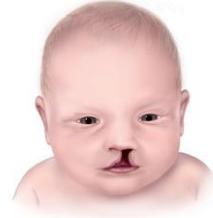

## Cleft Lip Alone (without Cleft Palate)

(Core Condition)

### Description

A defect in the upper lip resulting from incomplete fusion of the parts of the lip.



### Inclusions

Complete cleft lip – The defect extends through the entire lip into the floor of the nose.  
Incomplete cleft lip – The defect extends through part of the lip but not into the floor of the nose.  
Cheiloschisis

### Exclusions

Pseudocleft lip – An abnormal linear thickening, depressed groove, or scar-like pigmentary change on the skin of the lip without an actual cleft.

Oblique facial clefts  
Cleft palate without an associated cleft lip

### ICD-9-CM Codes

749.1

### ICD-10-CM Codes

Q36.0 – Q36.9

### CDC/BPA Codes

749.10-749.19

### Diagnostic Methods

Cleft lip is usually easily recognized on physical examination after delivery. It may also be seen on CT or MRI scan, at surgery or autopsy; plastic surgery consultation reports are often useful.

### Prenatal Diagnoses Not Confirmed Postnatally

While this condition may be identified by prenatal ultrasound, it should not be included in birth defects surveillance data without postnatal confirmation. In addition, the absence of cleft lip on prenatal ultrasound does not necessarily mean that it will not be diagnosed after delivery.

### Additional Information:

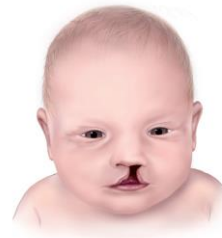Cleft lip may be unilateral, bilateral, or central in location, or not otherwise specified, as well as incomplete and complete. If the defect coding system includes unique codes for these different types, the location of the cleft should be coded.

## Cleft Lip with Cleft Palate

(Core Condition)

### Description

A defect in the upper lip resulting from incomplete fusion of the parts of the lip, with an opening in the roof of the mouth.



### Inclusions

Cleft lip with cleft of the hard and soft palate  
Cleft lip with cleft of the hard palate  
Cleft lip with cleft of the soft palate  
Cleft lip with cleft palate, not otherwise specified  
Cheilopalatoschisis

### Exclusions

Pseudocleft lip with cleft palate – An abnormal linear thickening, depressed groove, or scar-like pigmentary change on the skin of the lip without an actual cleft.

Oblique facial clefts with cleft palate  
Cleft palate without an associated cleft lip  
Cleft lip without an associated cleft palate

### ICD-9-CM Codes

749.20 - 749.25 (only these combined cleft palate with cleft lip codes should be used, not cleft lip or cleft palate codes individually)

### ICD-10-CM Codes

Q37.0 – Q37.9 (only these combined cleft palate with cleft lip codes should be used, not cleft lip or cleft palate codes individually)

### CDC/BPA Codes

749.20 – 749.29 (only these combined cleft lip with cleft palate codes should be used, not cleft lip or cleft palate codes individually)

### Diagnostic Methods

Cleft lip is usually easily recognized on physical examination after delivery. It may also be seen on CT or MRI scan, at surgery or autopsy; plastic surgery consultation reports are often useful.

### Prenatal Diagnoses Not Confirmed Postnatally

While this condition may be identified by prenatal ultrasound, it should not be included in birth defects surveillance data without postnatal confirmation. In addition, the absence of cleft lip on prenatal ultrasound does not necessarily mean that it will not be diagnosed after delivery.

### Additional Information:

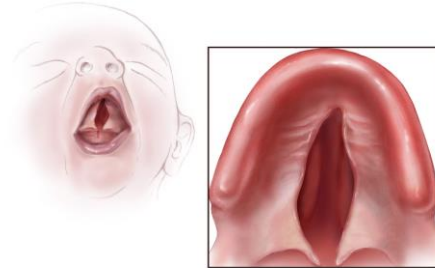Cleft lip with cleft palate may be unilateral, bilateral, or central in location, or not otherwise specified. If the defect coding system includes unique codes for these different types, the location of the cleft should be coded

## Cleft Palate Alone (without Cleft Lip)

(Core Condition)

### Description

An opening in the roof of the mouth resulting from incomplete fusion of the shelves of the palate. The opening may involve the hard palate only, the soft palate only, or both.



### Inclusions

Bifid or cleft uvula  
Cleft palate, type not specified  
Cleft hard palate  
Cleft soft palate  
Submucous cleft palate – A cleft in the soft palate that is covered by the mucosa or a thin muscle layer.

### Exclusions

Cleft palate that coexists with a cleft lip. These should be coded as cleft lip with cleft palate (see above).

### ICD-9-CM Codes

749.0

### ICD-10-CM Codes

Q35.1 – Q35.9

### CDC/BPA Codes

749.00 – 749.09

### Diagnostic Methods

Cleft palate is usually recognized on physical examination by direct visualization of the pharynx after delivery. It may also be seen on CT or MRI scan, at surgery or autopsy; plastic surgery consultation reports are often useful. However, submucous cleft palate and bifid uvula may be difficult to diagnose by physical examination during the first year of life.

### Prenatal Diagnoses Not Confirmed Postnatally

This condition should not be included in birth defects surveillance data without postnatal confirmation.

### Additional Information:

Cleft palate may be unilateral, bilateral, or central in location. If the defect coding system includes unique codes for these different types, the location of the cleft should be coded. Cleft palate sometimes may be described as U-shaped or V-shaped. This distinction is not clinically meaningful and these conditions should not be coded differently.

Bifid uvula is often seen in association with a submucous cleft palate. However, bifid uvula also may occur alone. The presence of submucous cleft palate does not necessarily mean that a bifid uvula is present. Cleft palate is one component of the Pierre Robin sequence, which also includes micrognathia and glossoptosis (when the tongue falls backward into the posterior pharynx). When diagnosed, Pierre Robin sequence should be coded separately.

## Gastrointestinal

## Biliary Atresia

(Extended Condition)

<b>Description</b>	Congenital absence of the lumen of the extrahepatic bile ducts.
<b>Inclusions</b>	Agensis, absence, hypoplasia, obstruction or stricture of the bile duct(s)
<b>Exclusions</b>	Congenital or neonatal hepatitis Intrahepatic biliary atresia (absence or paucity of bile ducts within the liver) not associated with extrahepatic biliary atresia
<b>ICD-9-CM Codes</b>	751.61
<b>ICD-10-CM Codes</b>	Q44.2 - Q44.3
<b>CDC/BPA Codes</b>	751.65
<b>Diagnostic Methods</b>	Biliary atresia may be suspected by the clinical presentation and the presence of elevated direct bilirubin and liver function tests. However, it may be conclusively diagnosed only through direct assessment of the bile ducts by abdominal ultrasound, CT or MRI scan, biliary excretion study (HIDA scan), surgery, or autopsy.
<b>Prenatal Diagnoses Not Confirmed Postnatally</b>	While biliary atresia may be suspected by prenatal ultrasound, it should not be included in surveillance data without postnatal confirmation. In addition, the absence of biliary atresia on prenatal ultrasound does not necessarily mean that it will not be diagnosed after delivery.

### Additional Information:

The liver contains within its substance intrahepatic bile ducts and passages that join and coalesce to form two main ducts that carry bile out of the liver.

The extrahepatic bile ducts include the hepatic duct (formed by the two main ducts that carry bile out of the liver), the cystic duct (which carries bile out of the gallbladder where it is stored), and the common bile duct (formed by the junction of the hepatic duct and the cystic duct), which carries bile into the duodenum for excretion.

When extrahepatic biliary atresia is present, the intrahepatic bile ducts may also be abnormal or atretic.

Patients with biliary atresia may have jaundice due to direct hyperbilirubinemia, which is not treated with phototherapy. The more common type of neonatal jaundice due to indirect hyperbilirubinemia may be treated with phototherapy and does not indicate the presence of biliary atresia.

## Esophageal Atresia/Tracheoesophageal Fistula (Recommended Condition)

<b>Description</b>	Esophageal atresia – A condition in which the esophagus ends in a blind pouch and fails to connect with the stomach.  Tracheoesophageal fistula – An abnormal communication between the esophagus and the trachea. This is almost always associated with some form of esophageal atresia.
<b>Inclusions</b>	Esophageal atresia alone Esophageal atresia with tracheoesophageal (TE) fistula Esophageal stenosis, stricture, ring, or web TE fistula Tracheoesophageal fistula, all types
<b>Exclusions</b>	Tracheal atresia Tracheoesophageal cleft
<b>ICD-9-CM Codes</b>	750.3
<b>ICD-10-CM Codes</b>	Q39.0 – Q39.4
<b>CDC/BPA Codes</b>	750.30 – 750.35
<b>Diagnostic Methods</b>	The diagnosis may be suspected by the clinical presentation of polyhydramnios, vomiting, or respiratory distress. Esophageal atresia may be diagnosed by x-ray documentation of failure of a feeding tube to pass from the pharynx into the stomach. Tracheoesophageal atresia may be conclusively diagnosed only by CT or MRI scan, surgery, or autopsy.
<b>Prenatal Diagnoses Not Confirmed Postnatally</b>	These conditions may be included when only diagnosed prenatally. However, if it is possible to ascertain the degree of certainty of the prenatal diagnosis, this should factor into the decision as to whether or not to include an individual case in the surveillance data. Live-born children who survive should always have confirmation of the defect postnatally before being included.

### **Additional Information:**

In some instances, TE fistula without esophageal atresia may not be diagnosed until weeks, months, or even a year or more after birth if the communication between the esophagus and stomach remains patent.

TE fistula is one of the defects reported as part of the VATER, or VACTERL, association, which may also include vertebral and cardiac defects, anal atresia, renal defects, and limb anomalies.

## Rectal and Large Intestinal Atresia/Stenosis

(Recommended Condition)

<b>Description</b>	Complete or partial occlusion of the lumen of one or more segments of the large intestine and/or rectum.
<b>Inclusions</b>	Anal atresia or stenosis Colonic atresia or stenosis Imperforate anus Large intestinal atresia or stenosis Rectal atresia or stenosis
<b>Exclusions</b>	Apple peel intestinal atresia Duodenal atresia or stenosis Ileal atresia or stenosis Jejunal atresia or stenosis Small intestinal atresia or stenosis
<b>ICD-9-CM Codes</b>	751.2
<b>ICD-10-CM Codes</b>	Q42.0 – Q42.9
<b>CDC/BPA Codes</b>	751.20 – 751.24
<b>Diagnostic Methods</b>	Anal atresia (imperforate anus) is usually easily recognized at birth by physical examination. While large intestinal and rectal atresia or stenosis may be suspected by the clinical presentation of failure to pass meconium or stool, they may be conclusively diagnosed only through direct imaging of the bowel by x-ray, barium enema, surgery, or autopsy.
<b>Prenatal Diagnoses Not Confirmed Postnatally</b>	While these conditions may be identified by prenatal ultrasound, they should not be included in surveillance data without postnatal confirmation. In addition, the absence of intestinal, rectal or anal atresia or stenosis on prenatal ultrasound does not necessarily mean that it will not be diagnosed after delivery.

### Additional Information:

These conditions may occur with or without a fistula.

Anal atresia is one of the defects reported as part of the VATER, or VACTERL, association, which may also include vertebral and cardiac defects, TE fistula, renal defects, and limb anomalies.

## Small Intestinal Atresia/Stenosis

(Recommended Condition)

<b>Description</b>	Complete or partial occlusion of the lumen of one or more segments of the small intestine. Small intestinal atresias are often assigned a type descriptor in the surgical or autopsy report, depending upon the severity of the atresia (types include I, II, IIIA, IIIB, and VI).
<b>Inclusions</b>	Duodenal atresia or stenosis (also include duodenal web, membrane, diaphragm, or windsock); include all types: I, II, IIIA, IIIB, VI, and not stated Jejunal atresia or stenosis (also include jejunal web or membrane); include all types: I, II, IIIA, IIIB, VI, and not stated Ileal atresia or stenosis also (include ileal web or membrane); include all types: I, II, IIIA, IIIB, VI, and not stated Small intestinal atresia or stenosis, not otherwise specified; include all types: I, II, IIIA, IIIB, VI, and not stated
<b>Exclusions</b>	Intestinal atresia/stenosis in an infant with cystic fibrosis Sirenomelia Anal atresia or stenosis Anal stenosis, anteriorly displaced anus Colonic atresia or stenosis Imperforate anus Large intestinal atresia or stenosis Rectal atresia or stenosis
<b>ICD-9-CM Codes</b>	751.1
<b>ICD-10-CM Codes</b>	Q41.0 – Q41.9
<b>CDC/BPA Codes</b>	751.10-751.19
<b>Diagnostic Methods</b>	While the diagnosis may be suspected by clinical presentation of abdominal distension, vomiting, lack of passage of meconium, “double bubble” sign on abdominal ultrasound, dilated loops of bowel on abdominal x-ray, or failure of contrast to advance on upper GI or barium enema studies, small intestinal atresia or stenosis requires conclusive diagnosis through surgery or autopsy.
<b>Prenatal Diagnoses Not Confirmed Postnatally</b>	While these conditions may be suspected by prenatal ultrasound, they should not be included in surveillance data without postnatal confirmation; postnatal diagnosis of the small intestinal atresia or stenosis requires a surgical or autopsy report (i.e., ultrasound or abdominal x-ray studies, such as an upper GI or barium enema, are not sufficient). In addition, the absence of small intestinal atresia or stenosis on prenatal ultrasound does not necessarily mean that it will not be diagnosed after delivery.

### Additional Information:

If contiguous regions of the small intestine are involved, a compound descriptor may be used, e.g., jejunoileal atresia; codes for both affected areas should be included, but the descriptor should indicate whether these are contiguous or non-contiguous regions. One-third of all infants with duodenal atresia or stenosis have Down syndrome.

## Genitourinary

### Bladder Exstrophy

(Recommended Condition)

<b>Description</b>	A defect in the lower abdominal wall and anterior wall of the bladder through which the lining of the bladder is exposed to the outside.
<b>Inclusions</b>	Classic bladder exstrophy Ectopia vesicae Epispadias-exstrophy complex Extroversion of the bladder Variants of bladder exstrophy Vesical exstrophy
<b>Exclusions</b>	Ambiguous genitalia without mention of bladder exstrophy Cloacal exstrophy Isolated epispadias
<b>ICD-9-CM Codes</b>	753.5
<b>ICD-10-CM Codes</b>	Q64.10, Q64.19
<b>CDC/BPA Codes</b>	753.50
<b>Diagnostic Methods</b>	Bladder exstrophy is easily recognized on physical examination at delivery. However, the exact nature of the defect and associated anomalies may only be distinguished by abdominal ultrasound, contrast x-ray studies, CT or MRI scan, surgery, or autopsy.
<b>Prenatal Diagnoses Not Confirmed Postnatally</b>	These conditions may be included when only diagnosed prenatally. However, if it is possible to ascertain the degree of certainty of the prenatal diagnosis, this should factor into the decision as to whether or not to include an individual case in the surveillance data, as it may be difficult to distinguish bladder exstrophy from cloacal exstrophy. Live-born children who survive should always have confirmation of the defect postnatally before being included.

#### **Additional Information:**

In the classic form of bladder exstrophy, the entire urinary tract is open anteriorly from the urethral meatus to the umbilicus. The pubic bones are widely separated, as are the abdominal muscles and fascia. There is eversion/exposure of the posterior bladder wall. The genitalia of either gender may be involved and may be bifid or duplicated. The classic form of bladder exstrophy occurs more frequently in males.

Variants of bladder exstrophy occur more rarely and affect females more often than males. Included among these variants are superior vesical fistula, closed exstrophy, duplicate exstrophy, pseudoexstrophy, inferior vesicle. Epispadias is almost uniformly present, but should not be coded separately.

Ambiguous genitalia may be noted in patients with bladder exstrophy if an obvious scrotum and testes are not present. However, ambiguous genitalia should not be coded as a separate defect in these instances.



Bladder exstrophy should be distinguished from cloacal exstrophy, in which the urinary, intestinal, and genital structures open into a common cavity (the cloaca). The distinction may only be possible with detailed diagnostic studies, surgery, or at autopsy. In cloacal exstrophy, bladder exstrophy and imperforate anus are also present. In bladder exstrophy without cloacal exstrophy, the anus is patent. When both bladder and cloacal exstrophy are present, only cloacal exstrophy should be coded.

## **Cloacal Exstrophy** (Recommended Condition)

<b>Description</b>	Congenital persistence of a common cloacal cavity into which gut, urethra, and reproductive tracts open with exstrophy of the cavity: usually accompanied by a low omphalocele, imperforate anus, and a (closed) neural tube defect.
<b>Inclusions</b>	cloacal exstrophy OEIS complex ( <b>O</b> mphalocele, <b>E</b> xstrophy, <b>I</b> mperforate anus, <b>S</b> pinal defects)
<b>Exclusions</b>	persistent cloaca (urorectal septum malformation sequence) bladder exstrophy without omphalocele/imperforate anus
<b>ICD-9-CM Codes</b>	751.5
<b>ICD-10-CM Codes</b>	Q64.12
<b>CDC/BPA Codes</b>	751.555
<b>Diagnostic Methods</b>	Cloacal exstrophy is easily recognized on physical examination at delivery. However, the exact nature of the defect and associated anomalies may only be distinguished by abdominal ultrasound, contrast x-ray studies, CT or MRI scan, surgery, or autopsy.
<b>Prenatal Diagnoses Not Confirmed Postnatally</b>	This condition may be included when only diagnosed prenatally. However, if it is possible to ascertain the degree of certainty of the prenatal diagnosis, this should factor into the decision as to whether or not to include an individual case in the surveillance data, as it may be difficult to distinguish cloacal exstrophy from bladder exstrophy. Live-born children who survive should always have confirmation of the defect postnatally before being included. At a minimum, omphalocele with bladder exstrophy (which cannot be distinguished from cloacal exstrophy prenatally) must be evident.
<b>Additional Information:</b>	<p>In the classic form of cloacal exstrophy, the entire bladder is open anteriorly from the urethral meatus to the low placed omphalocele. The pubic bones are widely separated, as are the abdominal muscles and fascia. The genitalia of either gender may be involved and may be bifid or duplicated.</p> <p>Ambiguous genitalia may be noted in patients with cloacal exstrophy if an obvious scrotum and testes are not present. However, ambiguous genitalia should not be coded as a separate defect in these instances.</p> <p>Cloacal exstrophy should be distinguished from bladder exstrophy. The distinction may only be possible with detailed diagnostic studies, surgery, or at autopsy. In cloacal exstrophy, bladder exstrophy and imperforate anus are also present. When both bladder and cloacal exstrophy are present, only cloacal exstrophy should be coded.</p>

## Congenital Posterior Urethral Valves

(Recommended Condition)

<b>Description</b>	Posterior urethral valves (PUV) are tissue folds of the posterior urethra and function as valves obstructing urine outflow. Congenital PUV is an abnormal congenital obstructing membrane that is located within the posterior male urethra; this valve is the most common cause of bladder outlet obstruction in male children. Congenital PUV can also be found in virilized females and rarely in normal females. Obstruction could vary from mild to severe.
<b>Inclusions</b>	Posterior urethral valves
<b>Exclusions</b>	Inhibition of urinary flow at any of the above sites resulting solely from neurologic impairment.
<b>ICD-9-CM Codes</b>	753.6
<b>ICD-10-CM Codes</b>	Q64.2
<b>CDC/BPA Codes</b>	753.60
<b>Diagnostic Methods</b>	Congenital PUV may be suspected by the clinical presentation. Newborns can present at birth with abdominal masses, distended bladder, hydronephrosis, or with respiratory distress, oligohydramnions, and Potter facies. However, the exact nature of the defect and PUV may only be distinguished by direct visualization such as cystoscopy or urethral endoscopy, or with contrast studies such as voiding cystourethrogram (VCUG). With routine obstetric ultrasonography the prenatal diagnosis of PUV is becoming increasingly common. PUV also may be diagnosed at surgery or autopsy.
<b>Prenatal Diagnoses Not Confirmed Postnatally</b>	While obstructive genitourinary defects including congenital PUV may be identified by prenatal ultrasound, many lesions diminish or resolve spontaneously prior to birth. For this reason, PUV should not be included in surveillance data without postnatal confirmation. In addition, the absence of genitourinary obstruction on prenatal ultrasound does not necessarily mean that an obstructive defect such as PUV will not be diagnosed after delivery.

### **Additional Information:**

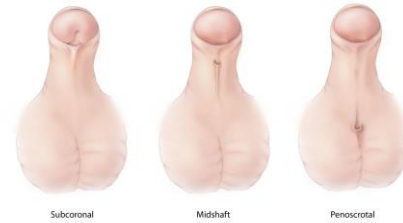When urine flow is obstructed, the portion of the genitourinary tract proximal to the affected area may become enlarged and dilated with urine. Mild lesions may produce only partial or intermittent urinary obstruction without permanent damage. More severe lesions may substantially or completely obstruct urine flow, resulting in permanent damage to proximal structures, and sometimes impaired kidney function, if not relieved by surgery.

## Hypospadias (Recommended Condition)

### Description

Hypospadias – Displacement of the opening of the urethra (urethral meatus) ventrally and proximally (underneath and closer to the body) in relation to the tip of the glans of the penis.

Types of Hypospadias



### Inclusions

First-degree hypospadias – The urethral meatus is located on the glans of the penis. Also called primary, 1°, glandular, or coronal hypospadias.

Second-degree hypospadias – The urethral meatus is located on the shaft of the penis. Also called secondary, 2°, or penile hypospadias.

Third-degree hypospadias – The urethral meatus is located at the base of the penis on the scrotum or perineum. Also called tertiary, 3°, scrotal, penoscrotal, or perineal hypospadias.

Hypospadias, degree not specified  
Hypospadias of any type with chordee

### Exclusions

Chordee alone without associated hypospadias  
Ambiguous genitalia  
Epispadias

### ICD-9-CM Codes

Hypospadias 752.61

### ICD-10-CM Codes

Q54.0 – Q54.9 (excluding Q54.4)

### CDC/BPA Codes

Hypospadias 752.60 – 752.62 (excluding 752.61 and 752.621)

### Diagnostic Methods

Hypospadias is usually easily recognized on physical examination at delivery. They may also be seen on contrast x-rays of the urinary tract, at surgery or autopsy.

### Prenatal Diagnoses Not Confirmed Postnatally

While this condition may be diagnosed by prenatal ultrasound, it should not be included in surveillance data without postnatal confirmation. In addition, the absence of hypospadias on prenatal ultrasound does not necessarily mean that they will not be diagnosed after delivery.

### Additional Information:

Chordee indicates a ventral (downward) curve of the penis, which may result from cutaneous or fibrous restriction. It is present in approximately 35% to 50% of cases of hypospadias.

In mild forms of first-degree hypospadias, the foreskin may appear hooded but there may be no overt

clinical symptoms.

In contrast, third-degree hypospadias may be described as ambiguous genitalia. In this instance, it is important to search the medical record for detailed information (including chromosome, molecular, and hormone analyses; genetics and endocrinology consultations; surgery or autopsy reports) that may clarify the anatomy and/or indicate whether an underlying genetic condition or endocrinopathy associated with ambiguous genitalia is present. Ambiguous genitalia should not be coded if hypospadias is the only diagnosis. Hypospadias generally should not be coded if a normal female karyotype (46,XX) is reported.

## Renal Agenesis/Hypoplasia

(Recommended Condition)

<b>Description</b>	Renal agenesis – Complete absence of the kidney Renal hypoplasia – Incomplete development of the kidney
<b>Inclusions</b>	Renal agenesis, dysgenesis, aplasia, or hypoplasia Potter syndrome secondary to renal agenesis/hypoplasia
<b>Exclusions</b>	Cystic renal dysplasia Cystic kidney disease Multicystic kidney Multicystic dysplastic kidney Polycystic kidney Renal cysts Renal dysplasia Small kidney
<b>ICD-9-CM Codes</b>	753.0
<b>ICD-10-CM Codes</b>	Q60.0 – Q60.6
<b>CDC/BPA Codes</b>	753.00 – 753.01
<b>Diagnostic Methods</b>	<p>Bilateral renal agenesis is often suspected on physical examination after delivery because of the Potter phenotype: low-set cartilage-deficient ears, prominent epicanthal folds, flattened “parrot-beaked” nose, recessed chin, limb contractures, malformed hands, and clubbed feet. Bilateral renal hypoplasia may or may not be recognized after delivery, depending on the severity and degree of residual kidney function.</p> <p>Unilateral renal agenesis or hypoplasia may not be symptomatic at delivery if the contralateral kidney is not impaired.</p> <p>Each of these diagnoses may be conclusively diagnosed only through direct assessment by abdominal ultrasound, CT or MRI scan, surgery, or autopsy.</p>
<b>Prenatal Diagnoses Not Confirmed Postnatally</b>	<p>Bilateral renal agenesis may be included when only diagnosed prenatally. However, if it is possible to ascertain the degree of certainty of the prenatal diagnosis, this should factor into the decision as to whether or not to include an individual case in the surveillance data. Live-born children who survive should always have confirmation of the defect postnatally before being included.</p> <p>While bilateral renal hypoplasia and unilateral renal agenesis/hypoplasia may be suspected by prenatal ultrasound, they should not be included in surveillance data without postnatal confirmation. Lack of visualization of a kidney on prenatal ultrasound does not always indicate that the kidney is truly absent.</p>

**Additional Information:**

Renal agenesis and hypoplasia may be unilateral or bilateral. If the defect coding system includes unique codes for these different types, the location should be coded.

Bilateral renal agenesis, or any condition that significantly impairs the function of both kidneys *in utero*, may lead to the oligohydramnios sequence (Potter syndrome) due to lack of fetal urine production and the resulting decreased amniotic fluid volume. The sequence includes minor facial dysmorphism (flat face, small chin, large ears), pulmonary hypoplasia, and joint contractures.

Bilateral renal agenesis is incompatible with long-term survival unless a kidney transplant is performed. In contrast, unilateral renal agenesis/hypoplasia may not be diagnosed until weeks, months, or even years after birth if the contralateral kidney function is normal. Some unilateral cases may be diagnosed only as incidental findings during evaluation for other conditions, and some may never be recognized.

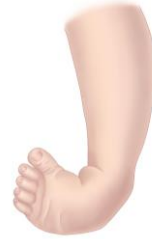## Musculoskeletal

### Clubfoot

(Recommended Condition)

**Description**

An abnormality consisting of plantar flexion (downward pointing of the foot and toes), inversion (varus, or internal rotation), and metatarsus adductus (deviation of the forefoot toward the body) of the foot. An abnormally high arch (pes cavus) and midfoot flexion crease usually are also present.



**Inclusions**

Talipes equinovarus (including congenital, idiopathic, and neurogenic), talipes not otherwise specified, clubfoot not otherwise specified.

**Exclusions**

Talipes equinovarus, talipes calcaneovarus, talipes calcaneovalgus, talipes varus, talipes valgus, vertical talus, metatarsus adductus alone, metatarsus varus alone, pes varus, pes valgus, pes planus, rocker-bottom foot, positional or postural clubfoot.

**ICD-9-CM Codes**

754.51, 754.70

**ICD-10-CM Codes**

Q66.0, Q66.89

**CDC/BPA Codes**

754.50, 754.73 excluding 754.735

**Diagnostic Methods**

Clubfoot is diagnosed by physical exam. X-rays and imaging studies may provide supplemental information but are not necessary for diagnosis.

**Prenatal Diagnoses Not Confirmed Postnatally**

Clubfoot can be identified or suspected on prenatal ultrasound; however, it should not be included in birth defects surveillance data without postnatal confirmation. The primary utility of prenatal diagnosis of clubfoot is in its indication for additional genetic counseling and testing through amniocentesis or other means.

**Additional Information:**

Clubfoot can occur on either side alone or in both feet. The calf muscles on the affected side are permanently small. While in some instances the affected foot can be moved passively to a normal or near-normal position (so-called positional clubfoot), more commonly there is a component of rigidity which can be severe.

Clubfoot often occurs alone, but can be associated with other musculoskeletal abnormalities such as torticollis or developmental dysplasia of the hip, and with genetic syndromes such as triploidy, Larsen syndrome, or Moebius sequence. Neurogenic clubfoot results from impaired innervation of the foot during development. Examples of conditions that can result in such impairment include spina bifida, arthrogryposis, sacral agenesis, spinal muscular atrophy, and other paralytic states.



## Craniosynostosis

(Extended Condition)

<b>Description</b>	Premature closure (fusion) of one or several cranial sutures (connective tissue membranes that separate the bones of the developing skull)
<b>Inclusions</b>	<p>Craniosynostosis subtypes are typically named by the cranial sutures involved: sagittal, coronal, lambdoidal, or metopic craniosynostoses are the most common conditions. Mixed or multiple sutures can be involved, and rarely basilar or squamosal sutures fuse prematurely.</p> <p>Cranial shapes that may or may not result from craniosynostosis:</p> <ul style="list-style-type: none"><li>• DOLICHOCEPHALY/SCAPHOCEPHALY--long, wedge-shaped skull with a prominent forehead and occiput resulting from premature closure of sagittal suture</li><li>• BRACHYCEPHALY--high, wide, short skull resulting from premature fusion of coronal sutures</li><li>• OXYCEPHALY/TURRICEPHALY/ACROCEPHALY--tall, tower-like skull (sometimes pointed) resulting from premature fusion of coronal and usually sagittal sutures</li><li>• PLAGIOCEPHALY--asymmetric skull shape which can result from unilateral closure of coronal and/or lambdoidal suture</li><li>• TRIGONOCEPHALY--triangular-shaped skull resulting from premature closure of metopic suture</li></ul>
<b>Exclusions</b>	<p>Deformational plagiocephaly without synostosis</p> <p>Other abnormal head shapes described above without craniosynostosis</p>
<b>ICD-9-CM Codes</b>	No specific code; 756.0 includes craniosynostosis and “other anomalies of skull and face bones”
<b>ICD-10-CM Codes</b>	Q75.0
<b>CDC/BPA Codes</b>	756.00-756.03
<b>Diagnostic Methods</b>	Confirmation of a diagnosis of craniosynostosis is by postnatal skull X-ray and/or tomography (CT or CAT scan, the “gold standard”), operative/pathology reports, or autopsy; plastic surgery or neurosurgery consultation reports are often useful
<b>Prenatal Diagnoses Not Confirmed Postnatally</b>	Craniosynostosis can be identified or suspected on prenatal ultrasound; however, it should not be included in birth defects surveillance data without postnatal confirmation.

### Additional Information:

Craniosynostosis is seen in many syndromes such as the acrocephalosyndactylies, in which there are limb abnormalities such as syndactyly. A particularly severe form of craniosynostosis of multiple sutures is called cloverleaf skull or Kleeblattschädel; this condition is usually associated with a syndrome diagnosis.

## Diaphragmatic Hernia

(Recommended Condition)

<b>Description</b>	Incomplete formation of the diaphragm through which a portion of the abdominal contents herniate into the thoracic cavity.
<b>Inclusions</b>	Absence of the diaphragm Bochdalek hernia – Herniation through a defect in the posterolateral portion of the diaphragm.  Diaphragmatic hernia, type not specified Hemidiaphragm  Morgagni hernia – Herniation through a defect in the anterior portion of the diaphragm.  Paraesophageal hernia – Herniation through a defect in the central portion of the diaphragm surrounding the esophagus.
<b>Exclusions</b>	Eventration of the diaphragm – Weakness in, or absence of, the muscles of the diaphragm which allows upward displacement of a portion of the abdominal contents. However, there is no true herniation of contents through the diaphragm into the thoracic cavity.
<b>ICD-9-CM Codes</b>	756.6
<b>ICD-10-CM Codes</b>	Q79.0, Q79.1
<b>CDC/BPA Codes</b>	756.610 – 756.617
<b>Diagnostic Methods</b>	While diaphragmatic hernia may be suspected by the clinical presentation of respiratory distress, feeding intolerance, and/or cardiac compromise, it may be conclusively diagnosed only through x-ray, contrast study of the bowel, CT or MRI scan, surgery, or autopsy.
<b>Prenatal Diagnoses Not Confirmed Postnatally</b>	Diaphragmatic hernia may be included in surveillance data when only diagnosed prenatally. However, if it is possible to ascertain the degree of certainty of the prenatal diagnosis, this should factor into the decision as to whether or not to include an individual case in the surveillance data. Live-born children who survive should always have confirmation of the defect postnatally before being included.

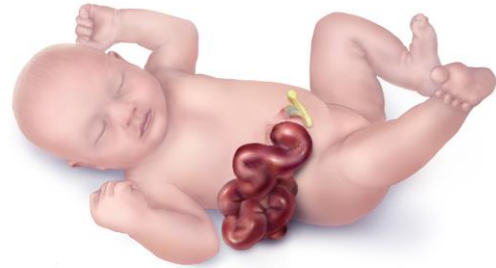### Additional Information:

Children with diaphragmatic hernia often have accompanying abnormalities of the heart, intestine, and lungs, including hypoplastic lungs, which result from the abnormal location of abdominal organs within the thoracic cavity during development.

## Gastroschisis (Core Condition)

### Description

A congenital opening or fissure in the anterior abdominal wall lateral to the umbilicus through which the small intestine, part of the large intestine, and occasionally the liver and spleen, may herniate. The opening is separated from the umbilicus by a small bridge of skin, and the herniating organs are not covered by a protective membrane. Gastroschisis usually occurs on the right side of the umbilicus, although it may occur on the left.



### Inclusions

Gastroschisis

### Exclusions

Omphalocele

### ICD-9-CM Codes

Prior to October 1, 2009 - 756.79 (shared code with omphalocele)  
October 1, 2009 and later – 756.73

### ICD-10-CM Codes

Q79.3

### CDC/BPA Codes

756.71

### Diagnostic Methods

Gastroschisis is usually easily recognized on physical examination after delivery. However, in some instances, it may be conclusively distinguished from omphalocele only at surgery or autopsy.

### Prenatal Diagnoses Not Confirmed Postnatally

Gastroschisis may be included when only diagnosed prenatally. However, it may be difficult to distinguish gastroschisis from omphalocele on prenatal ultrasound, and the terms sometimes are used interchangeably. If it is possible to ascertain the degree of certainty of the prenatal diagnosis and the location of the umbilical cord insertion relative to the abdominal defect, this should factor into the decision as to whether or not to include an individual case in the surveillance data. Live-born children who survive should always have confirmation of the defect postnatally before being included. In addition, the absence of gastroschisis on prenatal ultrasound does not necessarily mean that it will not be diagnosed after delivery.

### Additional Information:

The distinction between gastroschisis and omphalocele is important because they have different etiologies and different implications for treatment and long-term survival.

In gastroschisis, the umbilicus and cord are normal and separated from the abdominal wall defect by a small bridge of skin. The herniating organs are not covered by a protective membrane. However, they may

appear matted and covered by a thick fibrous material as a result of prolonged exposure to amniotic fluid *in utero*.

In omphalocele, abdominal organs herniate through the umbilicus into the umbilical cord. There is no bridge of skin between the abdominal wall defect and the umbilicus and cord. While the herniating organs are covered by a protective membrane, this may rupture before, during, or after delivery.

Gastroschisis may be one of the defects reported as part of the Limb-Body Wall complex. This is a disruption complex of the lateral body wall, which may also include limb reductions, neural tube defects, heart defects, and other anomalies.

Maternal serum alphafetoprotein (MSAFP) and/or amniotic fluid alphafetoprotein (AFAFP) may be elevated with gastroschisis. However, these screening tests alone are not sufficient to diagnose the condition.

## Limb Deficiencies (Reduction Defects)

(Core Condition)

### Description

Complete or partial absence of the upper arm (humerus), lower arm (radius and/or ulna), wrist (carpals), hand (metacarpals), fingers (phalanges), thigh (femur), lower leg (tibia and/or fibula), ankle (tarsals), foot (metatarsals), or toes (phalanges).

### Inclusions

Transverse limb deficiency (reduction) – Complete or partial absence of the distal (furthest from the body) structures of the arm or leg in a transverse (cross-wise) plane at the point where the deficiency begins. Structures proximal to the point where the deficiency begins remain essentially intact.

Selected terms used for types of transverse limb deficiencies include:

- Acheiria – Absence of a hand
- Adactyly – Absence of digits (fingers or toes), excluding isolated missing thumb (see below)
- Aphyalangia – Absence of phalanges. Fingers contain 3 phalanges each. The thumb (pollex) and big toe (hallux) contain 2 phalanges. The other toes contain 3 phalanges each.
- Amelia – Complete absence of the upper limb (humerus, radius, ulna, wrist, hand and fingers) or complete absence of the lower limb (femur, tibia, fibula, ankle, foot, and toes).
- Hemimelia, Meromelia – Partial absence of a limb. This may refer to either transverse or longitudinal deficiency (reduction).
- Oligodactyly – Deficiency of fewer than 5 digits.

Transverse terminal deficiency (reduction) – Complete absence of the distal structures of the arm with the proximal structures intact. This term usually refers to deficiency below the elbow, or complete absence of the distal structures of the leg with the proximal structures intact.

Congenital amputation, type not specified.

Longitudinal limb deficiency (reduction) – Partial absence of the upper limb in parallel with the long axis of the arm or partial absence of the lower limb in parallel with the long axis of the leg. These may involve preaxial (on the thumb side/ on the big toe side), postaxial (on the fifth finger side/ on the fifth toe side), or central parts of the arm or leg. Selected terms used for types of longitudinal limb reductions include:

- Ectrodactyly
- Ectromelia
- Isolated missing thumb
- Lobster claw hand
- Radial, ulnar, tibial, or fibular aplasia or hypoplasia
- Radial, ulnar, tibial, or fibular ray deficiency

Split-hand malformation (split hand/split foot malformation, SHSF) – A central longitudinal limb deficiency (reduction) in which there is complete or partial absence of one or more of the central rays (second through fourth fingers and their associated metacarpal bones) of the hand.

Split-foot malformation (split hand/split foot malformation, SHSF) – A central longitudinal limb deficiency (reduction) in which there is complete or partial absence of one or more of the central rays (second through fourth toes and their associated metatarsal bones) of the foot.

Intercalary limb reduction – Complete or partial absence of the proximal (closest to the body) or middle segments of the upper limb or lower limb with all or part of the distal segment present.

Phocomelia is a general term used for any type of intercalary limb reduction.

Deficiency (reduction defect) of the upper limb or lower limb not elsewhere coded or of unspecified type – Complete or partial absence of the upper limb or lower limb that does not fall within the above categories or for which there is no specific description.

**Exclusions**

Shortened arms, forearms, hands, upper and/or lower legs, feet, toes or fingers that have all of their component parts, including those that are part of a generalized chondrodystrophy, osteodystrophy, or dwarfism.

Hypoplastic nails

**ICD-9-CM Codes**

755.2 – 755.4

**ICD-10-CM Codes**

Q71.0 – Q71.9, Q72.0 – Q72.9, Q73.0 – Q73.8

**CDC/BPA Codes**

755.20 – 755.49

**Diagnostic Methods**

Limb deficiencies (reductions) are usually easily recognized on physical examination at delivery. However, the exact nature of the defect may only be distinguished by x-ray, surgery, or autopsy.

**Prenatal Diagnoses Not Confirmed Postnatally**

While these conditions may be identified by prenatal ultrasound, they generally should not be included in surveillance data without postnatal confirmation. However, if it is possible to ascertain the degree of certainty of the prenatal diagnosis, this should factor into the decision as to whether or not to include an individual case in the surveillance data. Lack of visualization of a bone or limb on prenatal ultrasound does not necessarily mean that the bone or limb truly is not present. Live-born children who survive should always have confirmation of the defect postnatally before being included.

**Additional Information:**

The terminology for limb deficiency (reduction) is often confusing. Some terms (such as “phocomelia”) have been misused and others (such as “ectrodactyly”) have been used for both longitudinal and transverse defects. If medical record review is available, it is important to look for a complete description of all structures that are present and absent in order to verify the diagnosis.

Transverse limb deficiency (reduction) may be seen in association with amniotic bands. When both are present, both conditions should be coded.

Rudimentary or nubbin toes may be present at the distal end of a transverse limb deficiency (reduction).

Their presence alone does not change the classification of the defect as transverse.

Joint contractures or clubfoot/clubhand are commonly seen in association with longitudinal limb deficiencies.

Intercalary deficiency (phocomelia) has been associated with the use of thalidomide during early pregnancy. However, thalidomide use may result in a number of other defects, including longitudinal deficiency. Intercalary defects also may occur without exposure to thalidomide.

Limb deficiency is one of the defects that may be reported as part of:

The VATER or VACTERL association, which also may include vertebral, cardiac and renal defects, TE fistula, and anal atresia.

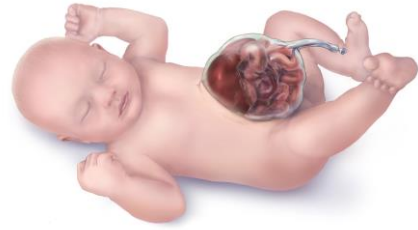Oromandibular-Limb Hypogenesis spectrum, which also may include a small mouth, small chin (micrognathia), small tongue (hypoglossia), and sixth and seventh cranial nerve palsies (Moebius sequence).

## Omphalocele

(Recommended Condition)

**Description**

A defect in the anterior abdominal wall in which the umbilical ring is widened, allowing herniation of abdominal organs, including the small intestine, part of the large intestine, and occasionally the liver and spleen, into the umbilical cord. The herniating organs are covered by a nearly transparent membranous sac.



**Inclusions**

Omphalocele

**Exclusions**

Gastroschisis  
Umbilical hernia

**ICD-9-CM Codes**

Prior to October 1, 2009 - 756.79 (shared code with gastroschisis)  
After October 1, 2009 – 756.72

**ICD-10-CM Codes**

Q79.2

**CDC/BPA Codes**

756.70

**Diagnostic Methods**

Omphalocele is usually easily recognized on physical examination after delivery. However, in some instances, it may be conclusively distinguished from gastroschisis only at surgery or autopsy.

**Prenatal Diagnoses Not Confirmed Postnatally**

Omphalocele may be included when only diagnosed prenatally. However, it may be difficult to distinguish omphalocele from gastroschisis on prenatal ultrasound, and the terms sometimes are used interchangeably. If it is possible to ascertain the degree of certainty of the prenatal diagnosis and the location of the umbilical cord insertion relative to the abdominal defect, this should factor into the decision as to whether or not to include an individual case in the surveillance data. Live-born children who survive should always have confirmation of the defect postnatally before being included. In addition, the absence of omphalocele on prenatal ultrasound does not necessarily mean that it will not be diagnosed after delivery.

**Additional Information:**

The distinction between omphalocele and gastroschisis is important because they have different etiologies and different implications for treatment and long-term survival.

In omphalocele, abdominal organs herniate through the umbilicus into the umbilical cord. There is no bridge of skin between the abdominal wall defect and the umbilicus and cord. While the herniating organs are covered by a protective membrane, this may rupture before, during, or after delivery.

In gastroschisis, the umbilicus and cord are normal and separated from the abdominal wall defect by a small bridge of skin. The herniating organs are not covered by a protective membrane. However, they may appear matted and covered by a thick fibrous material as a result of prolonged exposure to amniotic fluid *in*



*utero.*

Omphalocele is one of the defects reported as part of the Omphalocele-Exstrophy-Imperforate Anus-Spina Bifida (OEIS) complex.

Maternal serum alphafetoprotein (MSAFP) and/or amniotic fluid alphafetoprotein (AFAFP) may be elevated with omphalocele. However, these screening tests alone are not sufficient to diagnose the condition.

In contrast to omphalocele, umbilical hernias are completely covered by normal skin.

## Chromosomal

### Deletion 22q11.2

(Extended Condition)

<b>Description</b>	Chromosome abnormality resulting from genomic microdeletions within a critical region on the long arm of chromosome 22 (22q11.2)
<b>Inclusions</b>	Deletion 22q11.2 syndrome Chromosome deletion 22q11.2 DiGeorge syndrome with chromosome 22q11.2 deletion Thymic aplasia syndrome with chromosome 22q11.2 deletion Velo-cardio-facial (VCF) syndrome with chromosome 22q11.2 deletion Conotruncal anomaly face (CTAF) syndrome with chromosome 22q11.2 deletion Cayler cardiofacial (asymmetric crying facies) syndrome with chromosome 22q11.2 deletion Shprintzen syndrome with chromosome 22q11.2 deletion Sedlackova (velofacial hypoplasia) syndrome with chromosome 22q11.2 deletion Takao syndrome with chromosome 22q11.2 deletion
<b>Exclusions</b>	Named phenotypes without cytogenetic abnormalities <i>TBX1</i> mutations without cytogenetic abnormalities Deletion 22q13.3 Duplication 22q11.2 Shprintzen-Goldberg syndrome
<b>ICD-9-CM Codes</b>	758.32
<b>ICD-10-CM Codes</b>	Q93.81
<b>CDC/BPA Codes</b>	758.37
<b>Diagnostic Methods</b>	Deletion 22q11.2 syndrome might be suspected on physical examination. However, it is diagnosed conclusively only through molecular cytogenetic analysis (typically chromosomal microarray or fluorescence in situ hybridization). Rarely, direct analysis of the child's chromosomes (karyotype) can suggest a 22q11.2 deletion associated with an unbalanced translocation involving another chromosome, but molecular cytogenetic analysis would be used to confirm the 22q11.2 deletion. All of these laboratory techniques may be done with blood or tissue cells.
<b>Prenatal Diagnoses Not Confirmed Postnatally</b>	Deletion 22q11.2 can be included only when diagnosed through molecular cytogenetic analysis obtained from amniocentesis, chorionic villus sampling (CVS), or percutaneous umbilical blood sampling (PUBS).

#### Additional Information:

The deletion 22q11.2 syndrome phenotype can include cardiac abnormalities, abnormal or dysmorphic facial features, thymic aplasia, cleft palate or velopharyngeal insufficiency, or hypocalcemia due to hypoparathyroidism; the "CATCH" acronym appeared in the literature previously to describe these cardinal

features, but this term is no longer used. Chromosome 22q11.2 deletions can be found with any of these features in isolation, and is sometimes not diagnosed until adulthood, e.g., in subtly affected parents of children with deletion 22q11.2 syndrome phenotypes or defects.

The term “DiGeorge syndrome” was used originally (before 22q11.2 deletions were described) for children with the combination of thymic and parathyroid defects; the ICD-9-CM code 279.11 or ICD-10-CM code D82.1 is sometimes still found in medical records with this diagnosis, but should be used in combination with the chromosomal codes listed above for individuals with documented 22q11.2 deletions.

The most common 22q11.2 deletions can be detected by commercially-available fluorescence in situ hybridization (FISH) probes, but normal FISH results with smaller 22q11.2 deletions seen on chromosomal microarrays are occasionally reported. These findings are sometimes called “atypical” deletions and labelled with specific letters (e.g., “C-D” deletion) or numbers describing the chromosomal loci; such cases should be included for surveillance purposes if the microarray interpretation is consistent with a pathogenic or clinically-significant 22q11.2 deletion.

## **Trisomy 13** (Recommended Condition)

<b>Description</b>	The presence of three copies of all or a large part of chromosome 13.
<b>Inclusions</b>	Patau syndrome Mosaic Patau syndrome Mosaic trisomy 13 Translocation Patau syndrome Translocation trisomy 13 Trisomy 13, not otherwise specified Trisomy D <sub>1</sub> , not otherwise specified
<b>Exclusions</b>	Balanced translocations involving chromosome 13
<b>ICD-9-CM Codes</b>	758.1
<b>ICD-10-CM Codes</b>	Q91.4 – Q91.7
<b>CDC/BPA Codes</b>	758.10 – 758.19
<b>Diagnostic Methods</b>	Trisomy 13 may be suspected on physical examination. However, it may be diagnosed conclusively only through direct analysis of the infant's chromosomes (karyotype). The chromosomes may be obtained from blood or tissue cells.
<b>Prenatal Diagnoses Not Confirmed Postnatally</b>	Trisomy 13 may be included when only diagnosed through direct analysis of fetal chromosomes or molecular cytogenetic analysis (typically chromosomal microarray or fluorescence in situ hybridization) of cells obtained from amniocentesis, chorionic villus sampling (CVS), or percutaneous umbilical blood sampling (PUBS). However, when mosaic trisomy 13 is noted, the defect should be confirmed postnatally on a specimen obtained directly from the infant or fetus after birth (see below).

### **Additional Information:**

When the two copies of chromosome 13 from one parent do not separate during egg or sperm formation, three copies of the entire chromosome 13 will be present in the fetus. In this instance, the karyotype is written as 47,XX,+13 or 47,XY,+13. This is the most common type of trisomy 13 and is associated with advanced maternal age, particularly of 35 years or greater.

Translocation trisomy 13 occurs when two separate copies of chromosome 13 are present, but a third copy of part of chromosome 13 is attached to another chromosome. In this instance, there are 46 total chromosomes present, but 3 copies of part of chromosome 13.

Mosaic trisomy 13 occurs when some, but not all, of the cells in the body contain three copies of all or a large part of chromosome 13. In this instance, the karyotype is written as 46,XY/47,XY,+13, for example. Because the placenta may contain mosaic cell lines not present in the fetus, mosaic trisomy 13 diagnosed through chorionic villus sampling should always be confirmed by direct examination of fetal chromosomes from amniocentesis, PUBS, or preferably postnatal blood or tissue samples.

Approximately 80% of infants with trisomy 13 do not survive beyond the first month of life. Major

malformations associated with trisomy 13 may include holoprosencephaly, microcephaly, meningomyelocele, cleft lip and/or palate, microphthalmia, retinal dysplasia, polydactyly, heart defects (most commonly a VSD), omphalocele, and genitourinary defects, among others. Among children who survive the newborn period, severe developmental delay is virtually always present as may be deafness, visual impairment, minor motor seizures, and apneic spells.

Infants with mosaic trisomy 13 may be less severely affected with variable degrees of developmental delay and longer survival. Infants with partial trisomy for the proximal segment of chromosome 13 (13pter→q14) exhibit a nonspecific pattern of abnormalities with near-normal survival. Approximately 25% of infants with partial trisomy for the distal segment of chromosome 13 (13q14→qter) die during early postnatal life.

Children who survive exhibit severe developmental delay and specific abnormalities.

Major malformations that occur with trisomy 13 in the same infant should be coded separately, as their presence may vary among affected individuals.

## **Trisomy 18** (Recommended Condition)

<b>Description</b>	The presence of three copies of all or a large part of chromosome 18.
<b>Inclusions</b>	Edwards syndrome Mosaic Edwards syndrome Mosaic trisomy 18 Translocation Edwards syndrome Translocation trisomy 18 Trisomy 18, not otherwise specified
<b>Exclusions</b>	Balanced translocations involving chromosome 18
<b>ICD-9-CM Codes</b>	758.2
<b>ICD-10-CM Codes</b>	Q91.0 – Q91.3
<b>CDC/BPA Codes</b>	758.20 – 758.29
<b>Diagnostic Methods</b>	Trisomy 18 may be suspected on physical examination. However, it may be diagnosed conclusively only through direct analysis of the infant's chromosomes (karyotype). The chromosomes may be obtained from blood or tissue cells.
<b>Prenatal Diagnoses Not Confirmed Postnatally</b>	Trisomy 18 may be included when only diagnosed through direct analysis of fetal chromosomes or molecular cytogenetic analysis (typically chromosomal microarray or fluorescence in situ hybridization) of cells obtained from amniocentesis, chorionic villus sampling (CVS), or percutaneous umbilical blood sampling (PUBS). However, when mosaic trisomy 13 is noted, the defect should be confirmed postnatally on a specimen obtained directly from the infant or fetus after birth (see below).

### **Additional Information:**

When the two copies of chromosome 18 from one parent do not separate during egg or sperm formation, three copies of the entire chromosome 18 will be present in the fetus. In this instance, the karyotype is written as 47,XX,+18 or 47,XY,+18. This is the most common type of trisomy 18 and is associated with advanced maternal age, particularly of 35 years or greater.

Translocation trisomy 18 occurs when two separate copies of chromosome 18 are present, but a third copy of part of chromosome 18 is attached to another chromosome. In this instance, there are 46 total chromosomes present, but 3 copies of part of chromosome 18.

Mosaic trisomy 18 occurs when some, but not all, of the cells in the body contain three copies of all or a large part of chromosome 18. In this instance, the karyotype is written as 46,XY/47,XY,+18, for example. Because the placenta may contain mosaic cell lines not present in the fetus, mosaic trisomy 18 diagnosed through chorionic villus sampling should always be confirmed by direct examination of fetal chromosomes from amniocentesis, PUBS, or preferably postnatal blood or tissue samples.

Most pregnancies affected with trisomy 18 result in spontaneous abortion. Approximately 50% of live-born infants with trisomy 18 do not survive beyond the first week of life. Only 5% to 10% survive beyond the

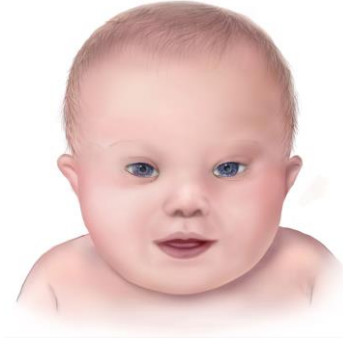first year of life. Major malformations associated with trisomy 18 may include microcephaly, micrognathia, cleft lip and/or palate, heart defects, omphalocele, and renal defects, among others. Minor anomalies associated with trisomy 18 may include low-set malformed auricles (external ears), overlapping of the index and fifth fingers over the third and fourth fingers, absent distal crease on the fifth finger, hirsutism (excess hair) of the forehead and back, lateral deviation of the hands, a hypoplastic thumb, a single transverse palmar crease, and rocker-bottom feet, among others. Developmental delay is virtually always present, as may be hypertonicity, a weak cry, growth retardation, hypoplasia of skeletal muscle and subcutaneous fat, and clenched hands.

Infants with mosaic trisomy 18 may be less severely affected, with variable degrees of developmental delay and longer survival. Infants with trisomy of only the short arm of chromosome 18 (partial trisomy 18) exhibit a nonspecific pattern of abnormalities with mild to no developmental delay. Infants with trisomy of the short arm, centromere, and proximal third of the long arm of chromosome 18 exhibit features of trisomy 18 but not the entire spectrum of abnormalities. Infants with trisomy of only one-third to one-half of the long arm of chromosome 18 exhibit features of trisomy 18 but have longer survival and less severe developmental delays.

Major malformations that occur with trisomy 18 in the same infant should be coded separately, as their presence varies among affected individuals.

## Trisomy 21 (Down Syndrome) (Core Condition)

**Description** The presence of three copies of all or a large part of chromosome 21.



**Inclusions** Down syndrome  
Mosaic Down syndrome  
Mosaic trisomy 21  
Translocation Down syndrome  
Translocation trisomy 21  
Trisomy 21, not otherwise specified

**Exclusions** Balanced translocations involving chromosome 21  
“Downs facies” without associated trisomy 21.

**ICD-9-CM Codes** 758.0

**ICD-10-CM Codes** Q90.0 – Q90.9

**CDC/BPA Codes** 758.00 – 758.09

**Diagnostic Methods** Down syndrome may be suspected on physical examination. However, it may be diagnosed conclusively only through direct analysis of the infant’s chromosomes (karyotype). The chromosomes may be obtained from blood or tissue cells.

**Prenatal Diagnoses Not Confirmed Postnatally** Down syndrome may be included when only diagnosed through direct analysis of fetal chromosomes or molecular cytogenetic analysis (typically chromosomal microarray or fluorescence in situ hybridization) of cells obtained from amniocentesis, chorionic villus sampling (CVS), or percutaneous umbilical blood sampling (PUBS). However, when mosaic trisomy 21 is noted, the defect should be confirmed postnatally on a specimen obtained directly from the infant or fetus after birth (see below).

### Additional Information:

When the two copies of chromosome 21 from one parent do not separate during egg or sperm formation, three copies of the entire chromosome 21 will be present in the fetus. In this instance, the karyotype is written as 47,XX,+21 or 47,XY,+21. This is the most common type of trisomy 21 and is associated with advanced maternal age, particularly of 35 years or greater.

Translocation trisomy 21 occurs when two separate copies of chromosome 21 are present, but a third copy of part of chromosome 21 is attached to another chromosome. In this instance, there are 46 total



chromosomes present, but 3 copies of part of chromosome 21.

Mosaic trisomy 21 occurs when some, but not all, of the cells in the body contain three copies of all or a large part of chromosome 21. In this instance, the karyotype is written as 46,XY/47,XY,+21, for example. Because the placenta may contain mosaic cell lines not present in the fetus, mosaic trisomy 21 diagnosed through chorionic villus sampling should always be confirmed by direct examination of fetal chromosomes from amniocentesis, PUBS, or preferably postnatal blood or tissue samples.

Infants with Down syndrome have a typical appearance and other characteristics, including decreased muscle tone (hypotonia), a weak startle (Moro) reflex, hyperflexible joints, a flattened facial profile, upslanting eyes, abnormally shaped external ears (auricles), loose skin on the back of the neck, dysplasia of the pelvic bones, incurving of the fifth finger (clinodactyly), and a single transverse crease in the palm of the hand (Simian crease). Developmental delay is virtually always present. Major malformations associated with Down syndrome include heart defects (most notably atrioventricular septal defects), gastrointestinal defects, and vertebral abnormalities, among others.

Major malformations that occur with Down syndrome in the same infant should be coded separately, as their presence may vary among affected individuals.

Mongolism is an outdated term for Down syndrome.

## Turner Syndrome

(Extended Condition)

<b>Description</b>	Presence of an absent or structurally abnormal second X chromosome in a phenotypic female.
<b>Inclusions</b>	Turner syndrome Turner syndrome mosaicism (45,X with 46,XX, 46,XY, 47,XXX, autosomal translocation, or combinations of the above) Turner syndrome with a ring X chromosome Turner syndrome with an isochromosome X Turner syndrome with Xp deletion Gonadal dysgenesis, many forms
<b>Exclusions</b>	Chromosome Xq24 deletions without Turner syndrome phenotype Chromosomal deletions distal to Xp22.3 without Turner syndrome phenotype Males, e.g., with 46,XY/45,X mosaicism
<b>ICD-9-CM Codes</b>	758.6
<b>ICD-10-CM Codes</b>	Q96.0- Q96.9
<b>CDC/BPA Codes</b>	758.60-758.69
<b>Diagnostic Methods</b>	Physical examination often provides a strong clinical suspicion of Turner syndrome. However, it is diagnosed conclusively only through direct analysis of the infant's chromosomes (karyotype). The chromosomes may be obtained from blood (lymphocytes), or tissue cells (skin fibroblasts, chorionic villi). Cheek (buccal) swab analysis is inadequate for diagnosis, although it is useful to evaluate mosaicism. Molecular cytogenetic analysis (typically chromosomal microarray or fluorescence in situ hybridization) is not the standard type of laboratory investigation for Turner syndrome, but recent studies show that chromosomal microarray can detect the missing X chromosome for both complete and mosaic forms. Fluorescence in situ hybridization (FISH) performed prenatally can detect 45,X but not other forms; if Turner syndrome is strongly suspected in the fetus and FISH is negative, postnatal blood karyotyping must be performed.
<b>Prenatal Diagnoses Not Confirmed Postnatally</b>	Turner syndrome can be included only when diagnosed through direct analysis of fetal chromosomes (karyotype) or molecular cytogenetic analysis of cells obtained from amniocentesis, chorionic villus sampling (CVS), or percutaneous umbilical blood sampling (PUBS). However, when mosaic Turner syndrome is noted, the abnormality should be confirmed postnatally on a specimen obtained directly from the infant or fetus after birth (see below).

### Additional Information:

The appearance of a fetus or infant with Turner syndrome varies greatly from a severely hydropic nonviable fetus to a normal appearing infant. The classic phenotype includes physical features that represent the residual of fetal lymphatic distention (body edema, neck edema, low hairline, low-set ears, downslanted eyes, loose neck skin, puffy hands and feet), and congenital heart defects (coarctation, other forms of left-heart

obstruction). The facial appearance might include wide-spaced eyes and small chin. Renal anomalies are seen in 30% (horseshoe kidney, absent kidney). Although short stature occurs in most children with Turner syndrome, infants usually have normal size.

There are different causes of the different chromosome types of Turner syndrome. When 45,X is present, the chromosomal abnormality occurred as a random event during the formation of reproductive cells (eggs and sperm) in the affected person's parent. An error in cell division called nondisjunction resulted in reproductive cells with an abnormal number of chromosomes.

Mosaic Turner syndrome occurs as a random event during cell division in early fetal development. As a result, some of an affected person's cells have the usual two sex chromosomes, and other cells have only one copy of the X chromosome. Other sex chromosome abnormalities are also possible in females with X chromosome mosaicism. Rarely, Turner syndrome caused by a partial deletion of the X chromosome can be passed from one generation to the next.

Birth defects, especially heart and kidney defects, that occur with Turner syndrome should be coded separately, as their presence may vary among affected individuals.

Bonnevie-Ullrich and Ullrich-Turner are outdated terms for Turner syndrome.