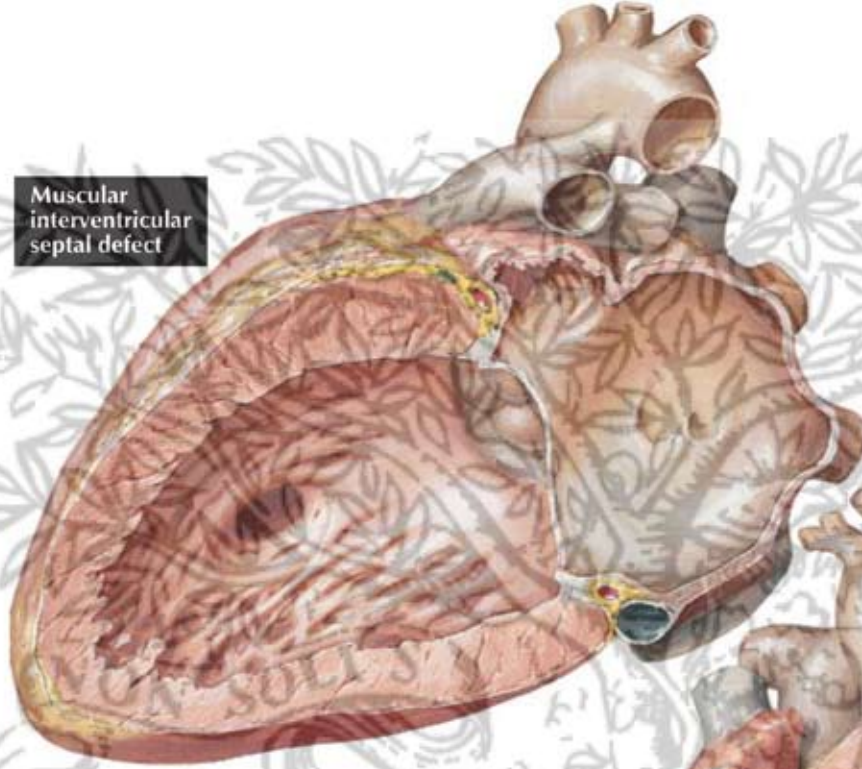
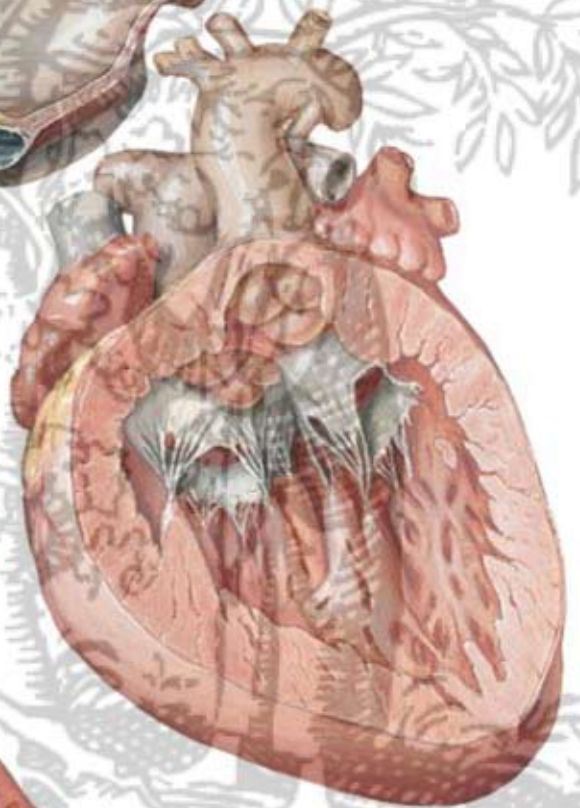


Muscular
interventricular
septal defect



Common ventricle



Subpulmonic
defect

