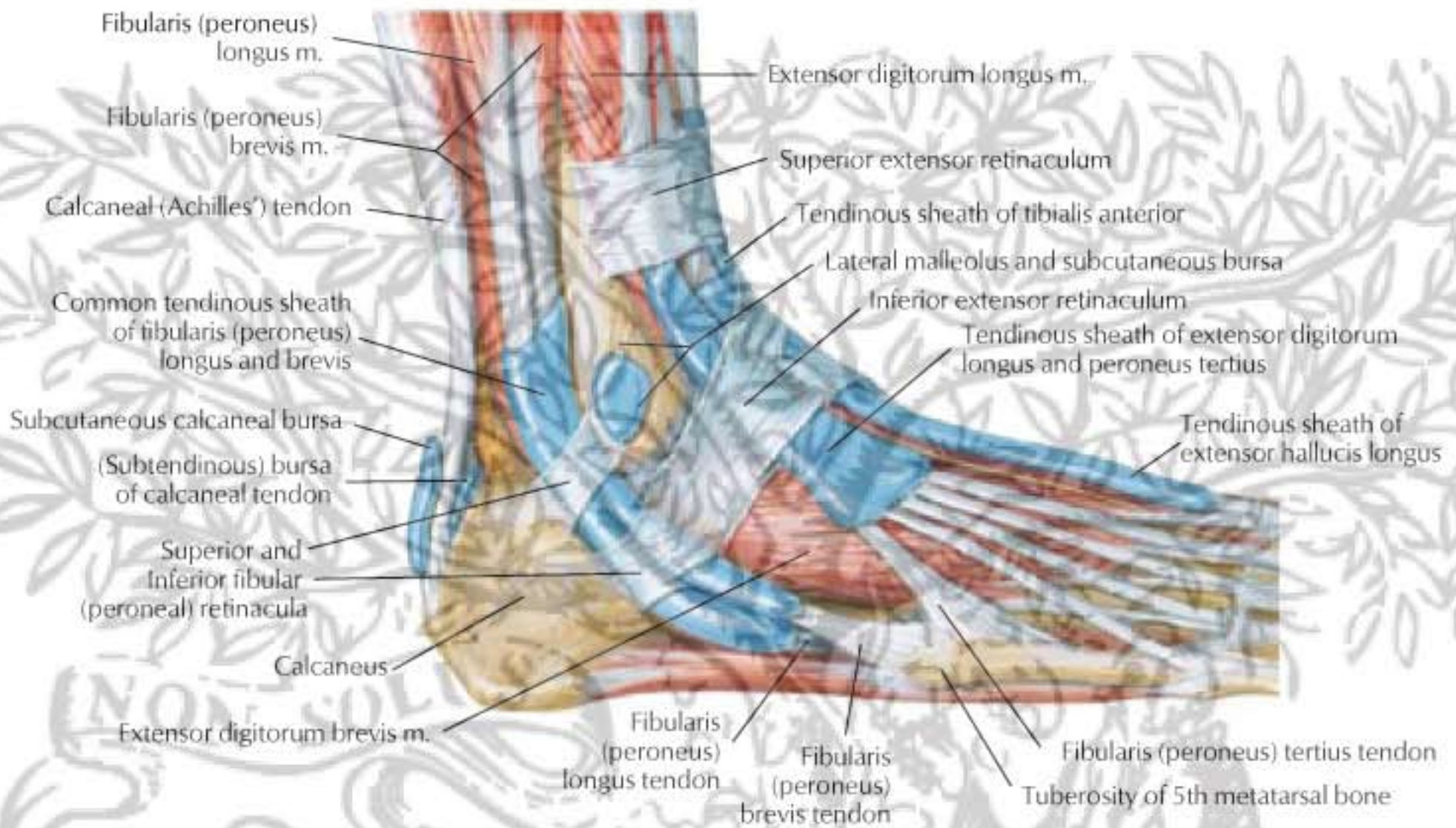
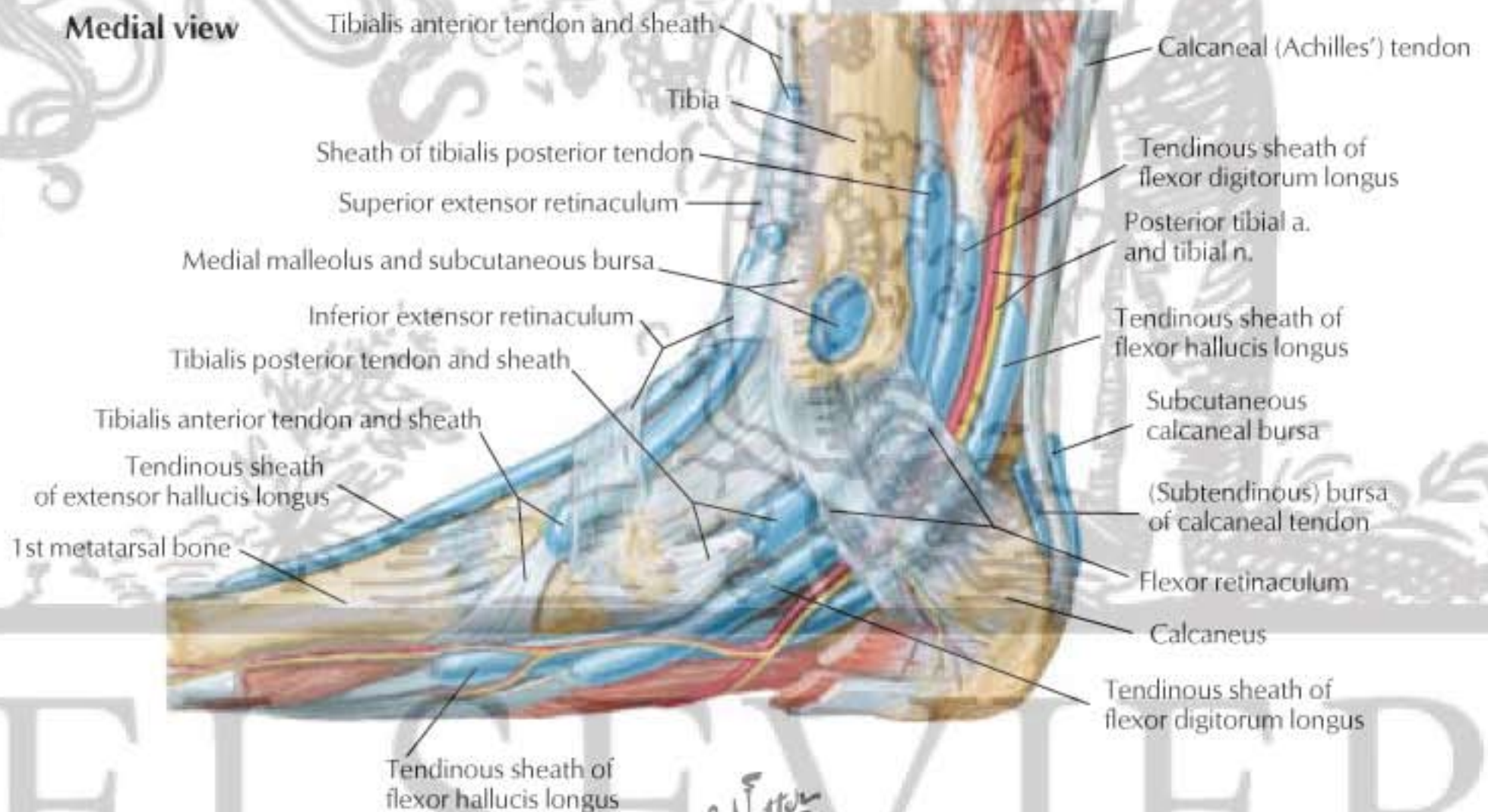


Lateral view



Medial view



F. Netter M.D.