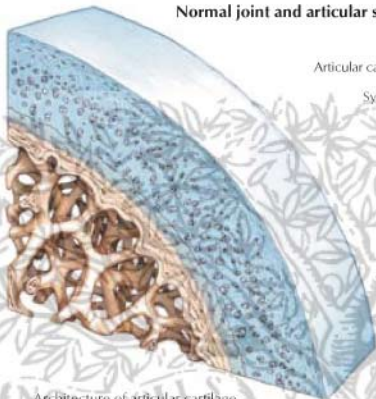


Normal joint and articular surface

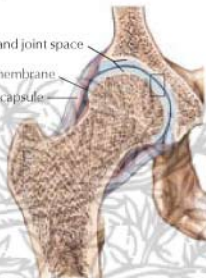


Architecture of articular cartilage and subchondral bone

Articular cartilage and joint space

Synovial membrane

Joint capsule



Hip joint with normal space and cartilage-covered articular surfaces

Early degenerative changes

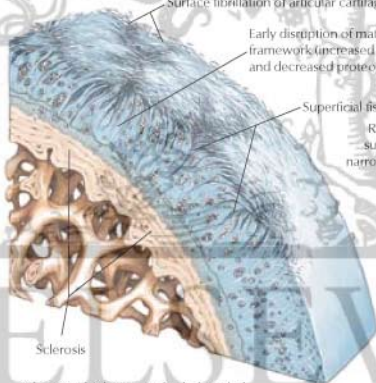
C. Machado
— M.D.

Surface fibrillation of articular cartilage

Early disruption of matrix-molecular framework (increased water content and decreased proteoglycans)

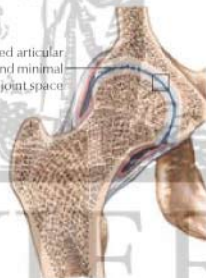
Superficial fissures

Roughened articular surfaces and minimal narrowing of joint space



Sclerosis

Sclerosis (thickening) of subchondral bone early sign of degeneration



Narrowing of upper portion of joint space with early degeneration of articular cartilage