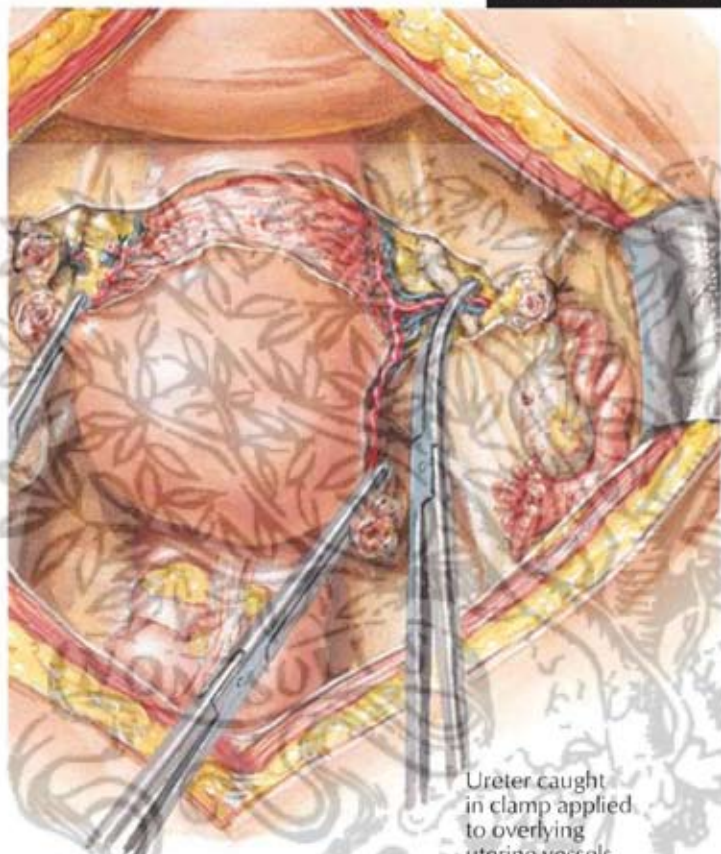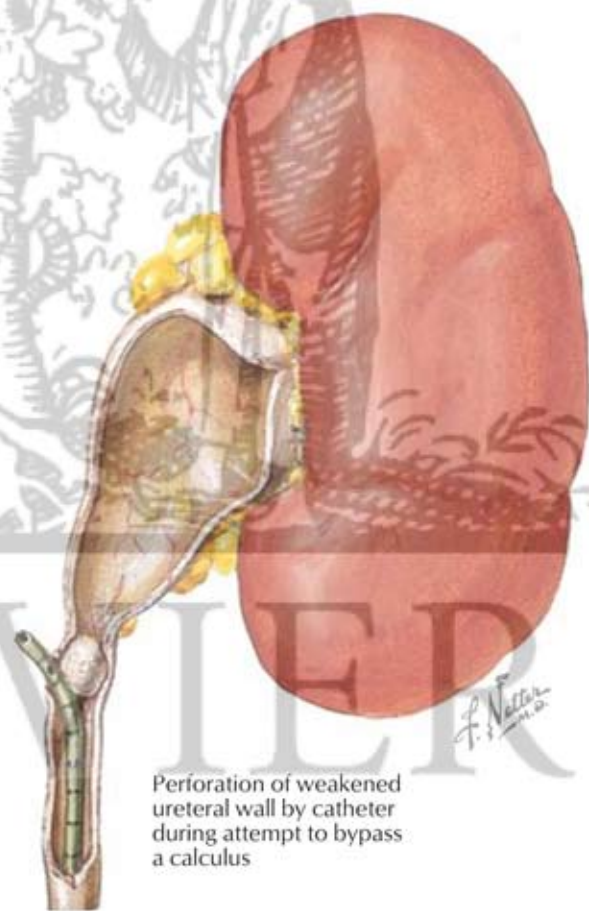


Ureter caught in clamp applied to overlying uterine vessels in course of hysterectomy.



Perforation of weakened ureteral wall by catheter during attempt to bypass a calculus

ELSEVIER