

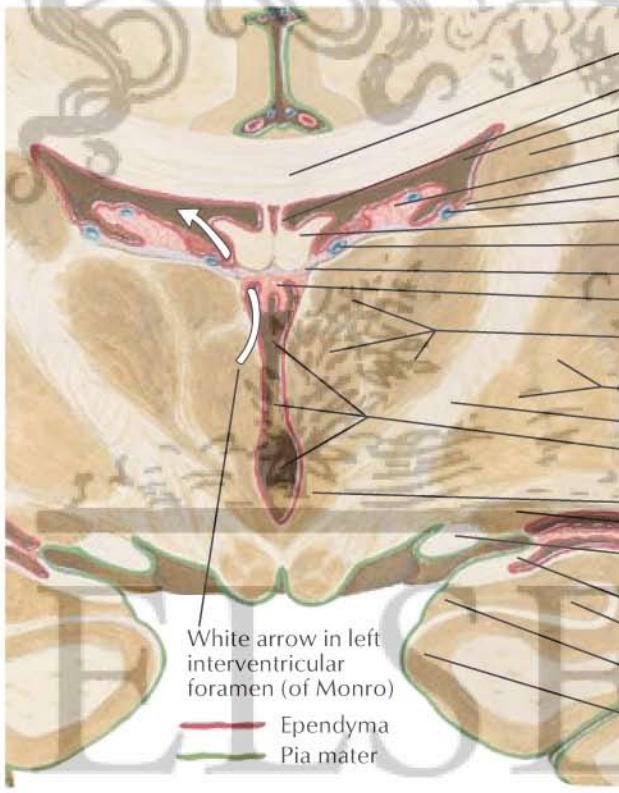
# Left lateral phantom view

Right lateral ventricle

Frontal (anterior) horn  
 Central part  
 Temporal (inferior) horn  
 Occipital (posterior) horn  
 } Left lateral ventricle

Left interventricular foramen (of Monro)  
 3rd ventricle  
 Supraoptic recess  
 Interthalamic adhesion  
 Infundibular recess  
 Pineal recess  
 Suprapineal recess

Cerebral aqueduct (of Sylvius)  
 4th ventricle  
 Left lateral aperture (foramen of Luschka)  
 Left lateral recess  
 Median aperture (foramen of Magendie)  
 Central canal of spinal cord



Corpus callosum  
 Septum pellucidum  
 Lateral ventricle  
 Body of caudate nucleus  
 Choroid plexus of lateral ventricle  
 Stria terminalis  
 Superior thalamostriate vein  
 Body of fornix  
 Internal cerebral vein  
 Tela choroidea of 3rd ventricle  
 Choroid plexus of 3rd ventricle  
 Thalamus  
 Putamen  
 Globus pallidus } Lentiform nucleus  
 Internal capsule  
 3rd ventricle and interthalamic adhesion  
 Hypothalamus  
 Tail of caudate nucleus  
 Optic tract  
 Choroid plexus of lateral ventricle  
 Temporal (inferior) horn of lateral ventricle  
 Fimbria of hippocampus  
 Hippocampus  
 Dentate gyrus  
 Parahippocampal gyrus

White arrow in left interventricular foramen (of Monro)  
 Ependyma  
 Pia mater

**Coronal section of brain: posterior view**

