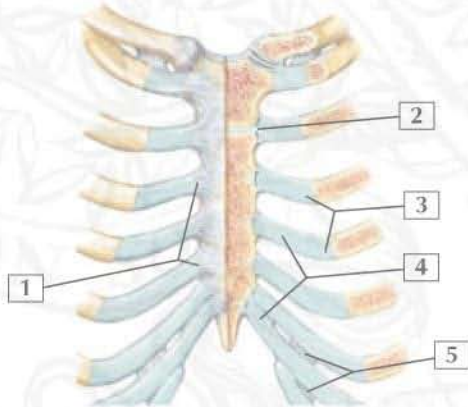
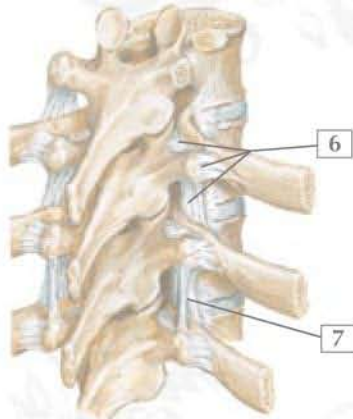


Conditions: Costochondral and Costovertebral Joints



Sternocostal articulations: anterior view



Right posterior

1. Radiate sternocostal ligaments
2. Sternocostal ligament
3. Costochondral joint
4. Costal cartilage
5. Interchondral joint
6. Costotransverse ligament
7. Intertransverse ligament

	Costochondral Injury (Rib Separation)	Costochondritis (Tietze Syndrome)	Costovertebral Joint Dislocation
Mechanism	Direct trauma, crush injury	Inflammatory process of the costochondral joint	Rare but from high-velocity trauma
Signs and Symptoms	Focal pain and deformity, pain with inspiration; neurovascular integrity should be evaluated	Focal pain and tenderness that is not exertional	Focal tenderness; other trauma extremely common
Imaging	Anteroposterior (AP) and lateral chest radiographs	Usually none, but bone scan may help pinpoint injury	AP lateral radiograph, computed tomography (CT)
Treatment	Generally conservative	Nonsteroidal antiinflammatory drugs (NSAIDs); corticosteroid injections in refractory cases	Usually conservative with focus on other injuries

F. Netter
M.D.

ELSEVIER