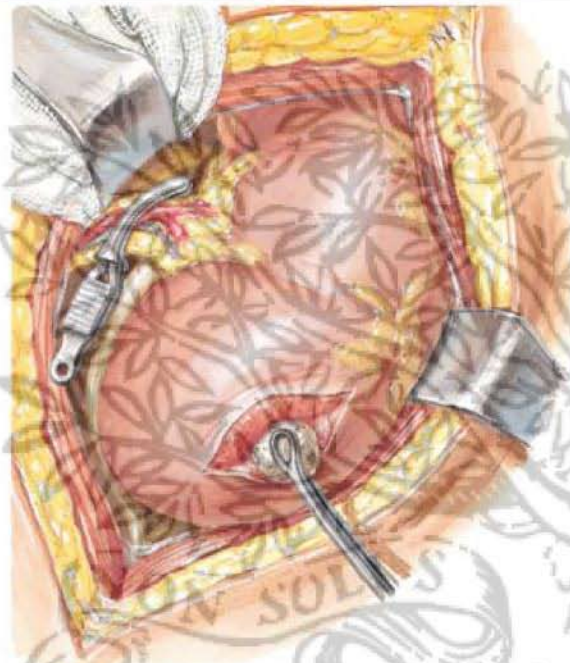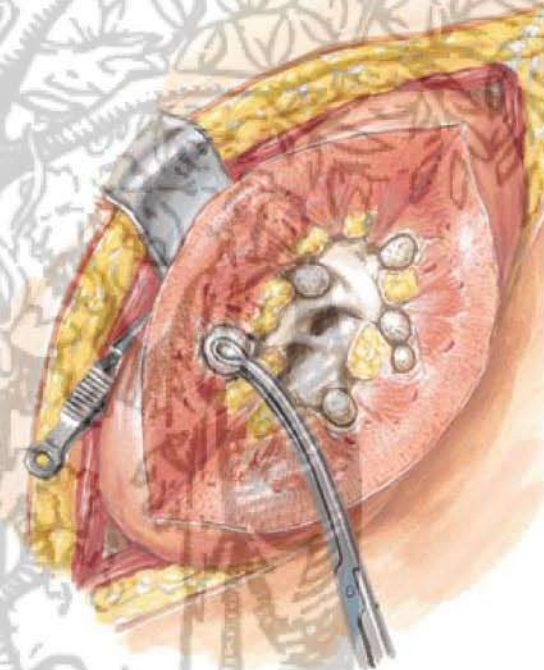
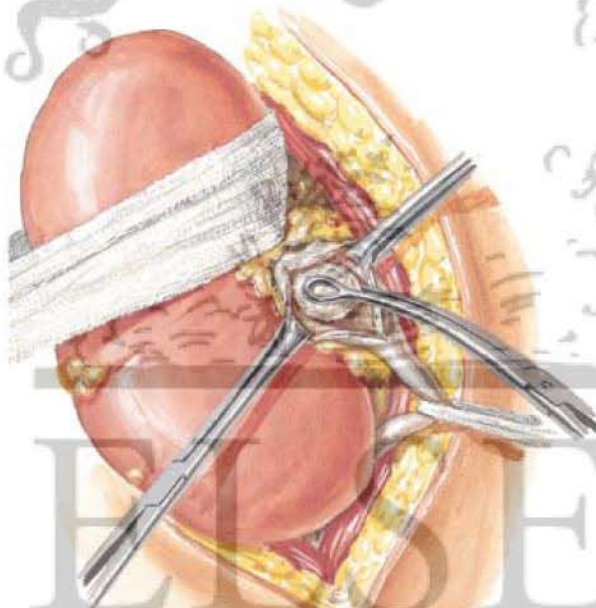


Stone removed via incision in lateral margin of kidney pole; renal vascular pedicle compressed by bulldog clamp to control bleeding



Kidney split and widely laid open for removal of multiple stones



Stone removed via incision in renal pelvis