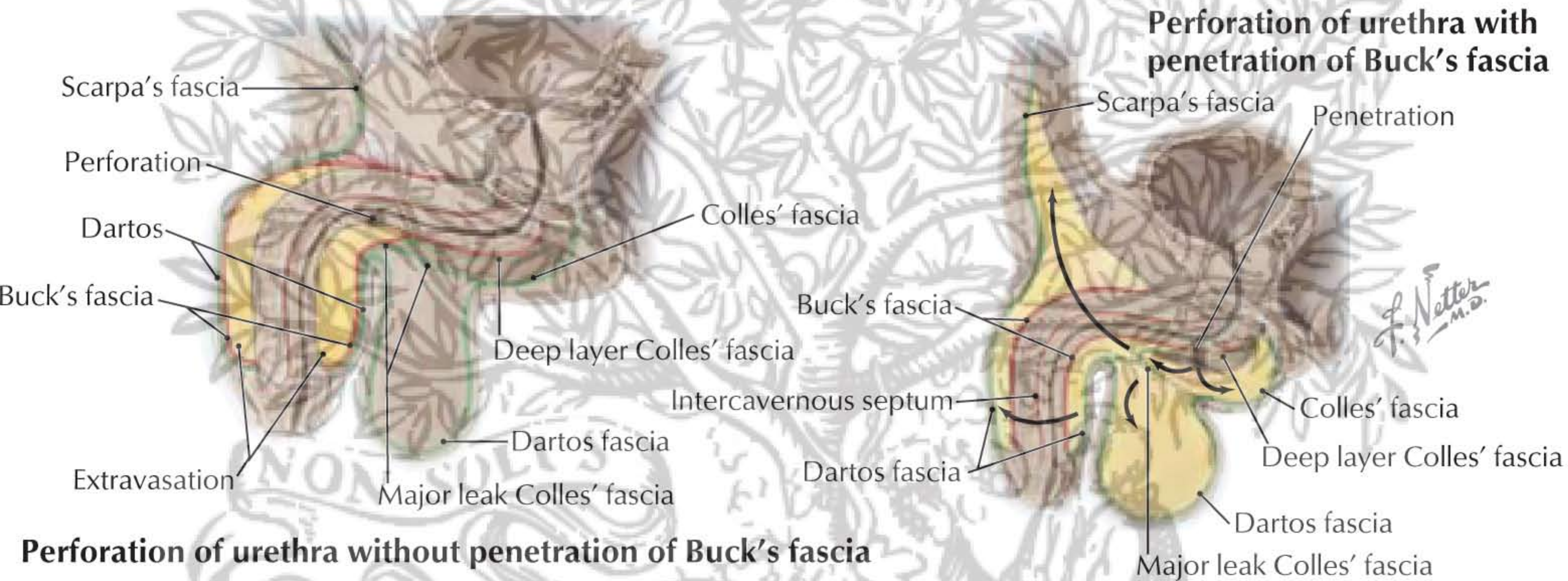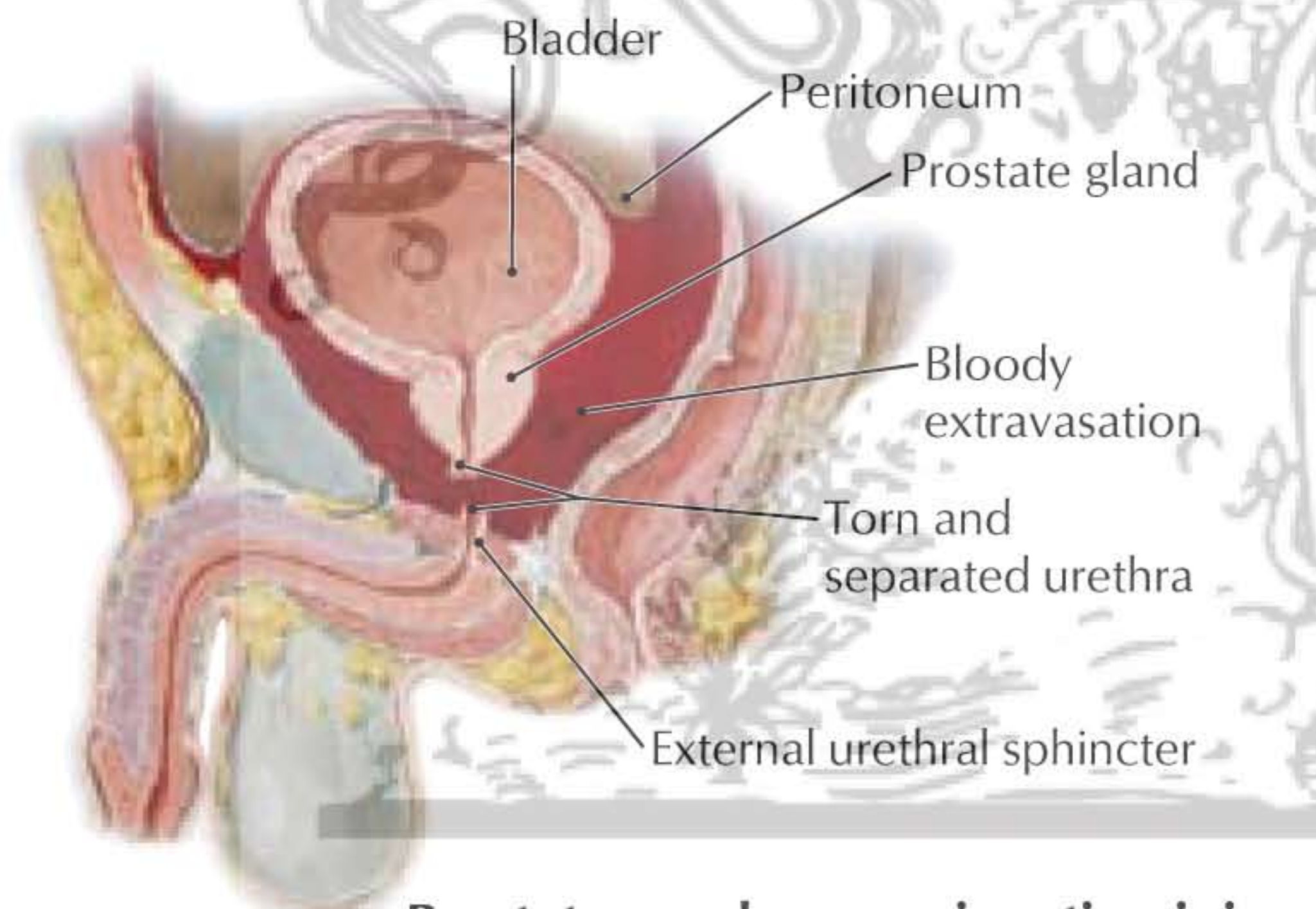


**Perforation of urethra without penetration of Buck's fascia**



**Prostatomembranous junction injury**

Injury site	Consequences
Penile urethra, Buck's fascia intact	Localized swelling confined to penis
Penile urethra, Buck's fascia ruptured	Eventual collection of urine deep to Colles' fascia (superficial perineal fascia); perineum: superficial pouch; penis; scrotum: deep to dartos (superficial) fascia; lower abdominal wall: deep to Scarpa's fascia
Prostatomembranous junction	Potential injury with anterior pelvic fractures, which may lead to retroperitoneal hematoma and urine extravasation