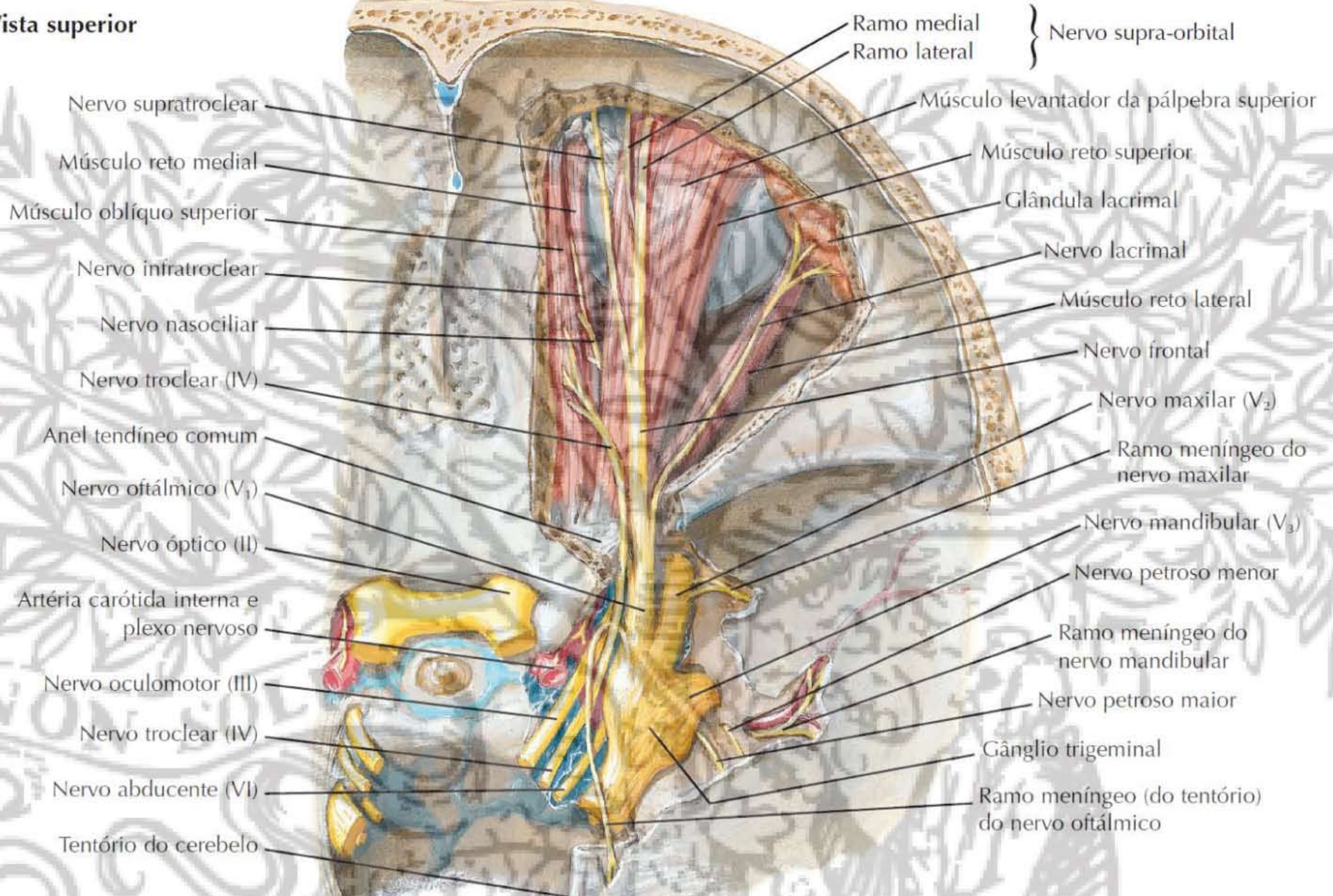
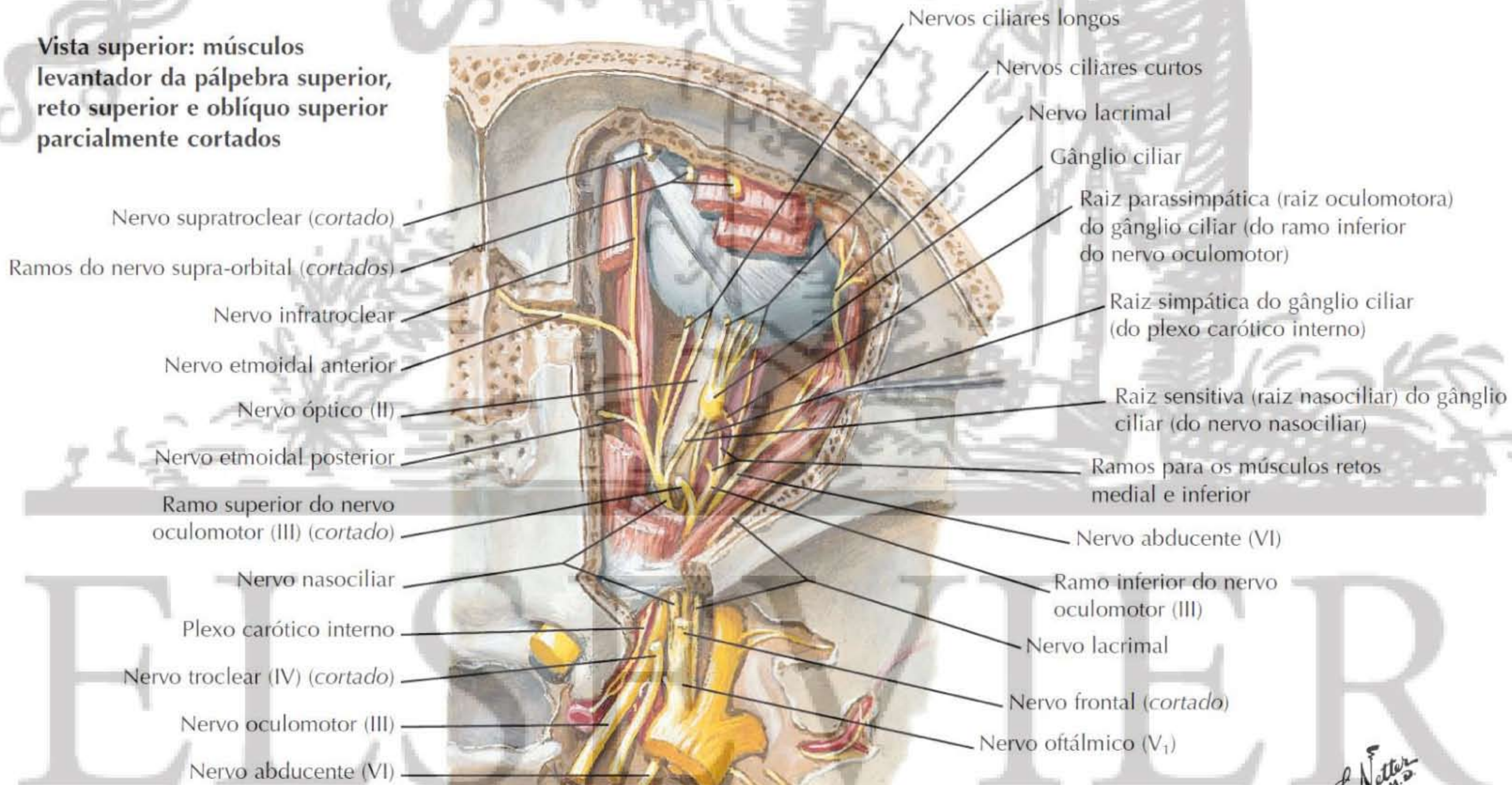


**Vista superior**



**Vista superior: músculos levantador da pálpebra superior, reto superior e oblíquo superior parcialmente cortados**



*F. Netter M.D.*