

A study on neurological manifestations of primary varicella zoster virus infection

Kannan Vangiliappan, Chandramouleeswaran Venkatraman, Balasubramanian Samivel, Lakshmi Narasimhan Ranganathan, Sarala Govindarajan

Institute of Neurology, Madras medical college, Chennai, India

Abstract

Background & Objective: About 95% of the adult population has been infected with varicella zoster virus (VZV). It can involve any part of the nervous system. This study aimed to determine the spectrum of neurological manifestations in patients with primary varicella zoster virus infection, its clinical course and prognosis. **Methods:** This was an observational study of patients who presented with primary VZV infection in the Institute of Neurology, Madras Medical college, Chennai between August 2015 and February 2018. Patients with neurological manifestations due to VZV reactivation were not included in the study. Detailed history, clinical examination, blood investigations, MRI brain and whole spine, CSF analysis including viral studies, nerve conduction studies, EEG were analysed. All primary VZV patients were found to have characteristic chickenpox rash and/or its scar. The course of disease and clinical outcome after treatment were studied. **Results:** Among the 22 patients, 10 patients presented with VZV meningoencephalitis, 4 patients with Guillain-Barré syndrome (GBS), 2 patients with meningoencephalitis with cerebellitis, 2 patients with cerebellitis, 1 patient as acute disseminated encephalomyelitis (ADEM), 1 patient as neuromyelitis optica (NMO), Two patients had acute stroke like deficits due to VZV vasculopathy. GBS and ADEM patients were treated with intravenous immunoglobulin and NMO patient was treated with intravenous methylprednisolone and they clinically improved after 4 weeks. There were two mortalities (9%).

Conclusion: Meningoencephalitis followed by GBS were the main manifestations of primary VZV from Chennai, India.

Keywords: Primary varicella zoster virus infection, neurological manifestations, VZV, chickenpox.

INTRODUCTION

Varicella zoster virus (VZV) is a human neurotropic alpha herpes virus.¹ Humans are the only reservoir for VZV.² About 95% of the adult population are infected with VZV.³ Infection can involve any part of the nervous system. The incidence of neurological manifestations associated with VZV is 1-3 per 10,000 cases. Both primary VZV infection (chickenpox) and VZV reactivation can cause various neurological manifestation (Table 1) Neurological manifestations following primary VZV infection are uncommon (0.01-0.03%).^{5,9}

After 14 to 21 days following exposure, chickenpox manifests as fine erythematous macular rash, which progresses to vesicular eruptions and then to pustules in a centripetal distribution. These pustules then crust. Infectivity lasts until crusts separate. Even though primary VZV infection results in immunity and protection

from further infection, VZV remains latent within cranial nerve ganglia, sensory dorsal root ganglia and autonomic ganglia. Upon reactivation it manifests as herpes zoster (shingles). Primary infection of VZV in adult is usually more severe than in children.¹⁰

This study aims to determine the spectrum of neurological manifestations in patients with primary varicella zoster virus infection and its prognosis.

METHODS

This was an observational study was performed in patients who presented with neurological manifestation due to primary VZV infection in the Institute of Neurology, Madras Medical college, Chennai between August 2015 and February 2018. In this duration of study, only 22 patients presented with neurological manifestation due

Table 1: VZV neurological manifestations^{1,4-8}

Primary VZV manifestations	Manifestations of VZV reactivations
Meningoencephalitis	Herpes zoster
Cerebellitis	Postherpetic neuralgia
Guillain barre syndrome	Cranial nerve palsies zoster paresis
Neuromyelitis optica	Vasculopathy
Acute disseminated encephalomyelitis	Meningoencephalitis
Vasculopathy	Cerebellitis
	Myelopathy
	Multiple ocular disorders
	Zoster sine herpette and Retinitis.

to primary varicella zoster virus infection. All of them were included in this study. Patients who had neurological manifestations due to VZV reactivation were not included. Detailed history, clinical examination, blood investigations, MRI brain and whole spine, CSF analysis including viral studies, nerve conduction studies, EEG were performed. All primary VZV patients had characteristic chickenpox rash and/or its scar. The course of disease and clinical outcome after treatment were studied with 6 months follow up. Blood and CSF IgM and PCR for VZV were done at King Institute of Preventive Medicine and Research, Chennai, India.

RESULTS

Among primary VZV infections(22 patients), 10 patients presented with VZV meningoencephalitis, 4 patients with Guillain-Barré syndrome(GBS), 2 patients with meningoencephalitis with

cerebellitis, 2 patients as cerebellitis, 1 patient as acute disseminated encephalomyelitis (ADEM), 1 patient as neuromyelitis optica (NMO) and 2 patients as acute stroke like deficits due to VZV vasculopathy. GBS and ADEM patients were treated with intravenous immunoglobulin and the NMO patient with intravenous methylprednisolone and they clinically improved after four weeks.

All the 22 patients were not previously vaccinated for VZV. Seven patients with primary varicella zoster virus infection presented with altered sensorium and seizures. Three patients presented with altered sensorium without seizure. All of them had rashes typical for varicella zoster virus infection (chicken pox). EEG and MRI brain were normal. Cerebrospinal fluid analysis by PCR and IgM for VZV were positive in all these patients. These 10 patients were diagnosed as primary varicella zoster virus meningoencephalitis (Table 2). All of them were

Table 2: Primary varicella zoster virus meningoencephalitis

Age of the patients in years	Sex	Duration of onset of neurological symptoms after the onset of rash	PCR and IgM for VZV in CSF	Altered sensorium	Seizure
12	Female	4 days	Positive	Present	Present
18	Male	4 days	Positive	Present	Absent
13	Female	4 days	Positive	Present	Present
21	Male	6 days	Positive	Present	Absent
18	Male	5 days	Positive	Present	Present
42	Male	10 days	Positive	Present	Present
19	Female	8 days	Positive	Present	Present
17	Male	8 days	Positive	Present	Present
23	Male	7 days	Positive	Present	Present
15	Female	9 days	Positive	Present	Absent

Table 3: Primary VZV presenting as GBS

Age of the patients in years	Sex	Duration of onset of neurological symptoms after the onset of rash in days	Nerve conduction studies	CSF-Albuminocytologic dissociation	PCR and IgM for VZV in CSF
15	Male	15	AMSAN	Present	Negative
17	Female	17	AMAN	Present	Negative
28	Female	22	AMAN	Present	Negative
23	Male	19	AMAN	Present	Negative

treated with acyclovir 500mg intravenous 8 hourly for 10 days. Their sensorium improved and they did not have any further episode of seizure. All of them recovered after 7-10 days.

Four patients presented with acute onset progressive flaccid quadriparesis with areflexia, bilateral lower motor neuron type of facial weakness with difficulty in swallowing without any sensory abnormality and without bladder disturbances (Table 3). All of them had scars typical for varicella zoster virus infection (chicken pox). In 3 patients nerve conduction study (NCS) was suggestive of acute motor axonal neuropathy (AMAN) and in 1 patient acute motor and sensory axonal neuropathy (AMSAN), a variant of GBS and CSF analysis showed albuminocytologic dissociation. In all the 4 patients MRI brain and spinal cord were normal. All of them were treated with 5 days course of intravenous immunoglobulin (IVIg) 400mg/kg/day and physiotherapy. In all the 4 patients, CSF analysis for PCR and IgM for VZV were negative. Three of them improved after 4 weeks (from power 1/5 to 4/5 in 2 patients and power 2/5 to 4/5 in 1 patient) and were discharged with advice for further follow up. One patient (AMSAN variant) developed respiratory failure, autonomic dysfunction and expired after 2 weeks of treatment.

Two patients presented with chickenpox rash, generalized tonic clonic seizure with altered sensorium and after hospitalisation developed bilateral cerebellar signs with ataxic gait and were diagnosed to have meningoencephalitis with cerebellitis. PCR and IgM for VZV were positive in CSF analysis. EEG and MRI brain were normal. Both of them recovered after treatment with intravenous acyclovir 500mg 8 hourly for 10 days.

Two patients (14 years male and 17 years male) presented on the second day and fifth day after the onset of chickenpox rash with ataxic gait and

bilateral cerebellar signs and was diagnosed to have cerebellitis. PCR and IgM for VZV were positive in CSF analysis. Both of them recovered after treatment with intravenous acyclovir 500mg 8 hourly for 10 days.

A 26 years old female patient presented on 20th day after the onset of chickenpox rash with altered sensorium, generalized tonic-clonic seizure, constipation, difficulty in bladder emptying, which was acute in onset but progressive to quadriparesis with neck and truncal weakness, pain over trunk and all four limbs and abnormal sweating. MRI brain showed multiple T2 FLAIR hyperintense lesions involving right temporal, left occipital, bilateral middle cerebellar peduncles with some of the lesions showing diffusion restriction (Figure 1). MRI cervical spine showed enlarged cervical cord from C1 to C7 level with long segment cord hyperintensity in C2-C3, C3-C4, C4-C5 and C5-C6 levels (Figure 2). She was diagnosed to have ADEM. PCR and IgM for VZV was positive in CSF analysis. The patient was treated with 5 days course of intravenous immunoglobulin (IVIg) 400mg/kg/day and physiotherapy. She improved after 8 weeks (from power 0/5 to 4/5), recovered consciousness and orientation without further episode of seizure and was discharged with further follow up.

A 17 years old female patient presented on 18th day after the onset of chickenpox rash with acute onset but progressive quadriparesis with blurring of vision in the left eye. She was diagnosed to have left optic neuritis with myelitis. VEP showed prolonged P₁₀₀ latency in the left eye. Aquaporin-4 antibody was negative. MRI brain was normal. MRI whole spine with contrast showed multiple discrete, patchy T2/STIR hyperintensity in the cervical, dorsal and lumbar spinal cord extending to the conus with patchy enhancement suggestive of demyelinating disease. She was diagnosed to have NMO. PCR and IgM for VZV were positive

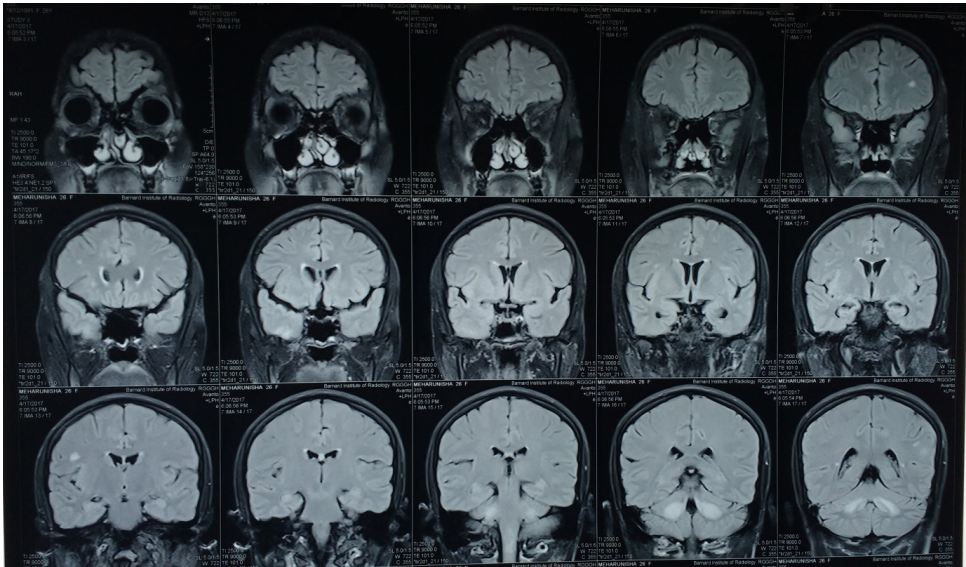


Figure 1. MRI brain coronal T2 FLAIR sequence showed multiple hyperintense lesions involving right temporal, left occipital and bilateral middle cerebellar peduncles.

in CSF analysis. She was treated with intravenous methylprednisolone 1 gram daily for 5 days followed by oral steroids with physiotherapy. She improved after 3 weeks with complete recovery of vision and power from 1/5 to 4/5 and was discharged with further follow up.

A 54 years old male patient presented on 16th day after the onset of chickenpox rash with 1 episode of generalized tonic-clonic seizure, right hemiparesis with right side upper motor neuron facial palsy, with giddiness and hiccups. His sensorium worsened to GCS of 7/15. MRI brain showed multiple infarcts in the left anterior and middle cerebral artery, right anterior cerebral artery and bilateral posterior circulation territories with surrounding edema and mass effect (Figure 3). PCR and IgM for VZV were positive in CSF analysis. Patient was intubated and mechanically ventilated. He was diagnosed to have acute stroke caused by VZV vasculopathy. Intravenous acyclovir and steroid therapy were given.¹¹ He developed pneumonia, respiratory failure and expired.

A 28 years old female patient presented on second day after the onset of rash with weakness of the left upper and lower limb with deviation of angle of mouth to right side. MRI brain showed acute infarct in the right middle cerebral artery territory. Patient was diagnosed to have VZV vasculopathy with acute right middle cerebral artery infarct and was treated with intravenous acyclovir and steroid.¹¹ She improved symptomatically after 2 weeks and was discharged.

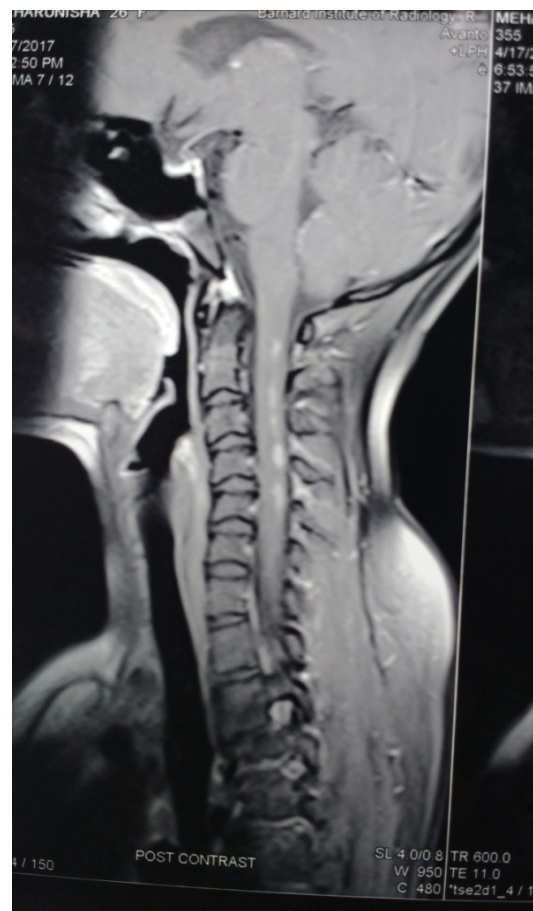

Figure 2. MRI cervical spine T1 sagittal post contrast sequence showed enlarged cervical cord from C1 to C7 level with long segment cord hyperintensity in C2-C3, C3-C4, C4-C5 and C5-C6 levels.

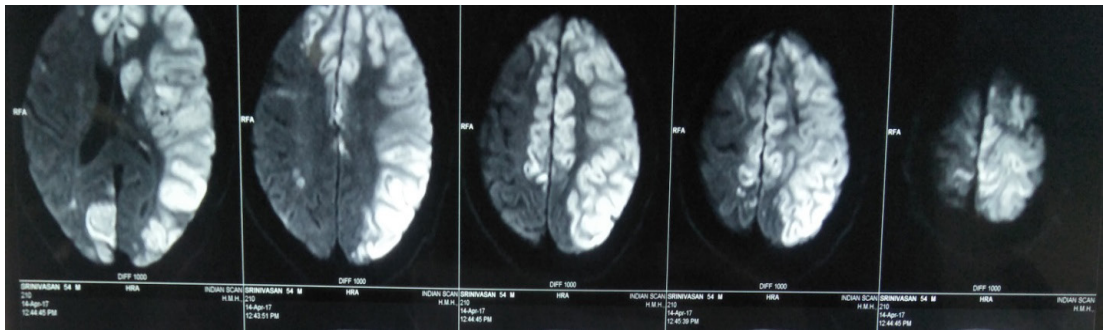


Figure 3. MRI brain axial DWI sequence showed high DWI signal (multiple infarcts) in the left anterior and middle cerebral artery, right anterior cerebral artery and bilateral posterior circulation territories.

In our study among 22 patients, PCR and IgM for VZV were positive in CSF analysis in 18 patients and 4 patients showed negative PCR and IgM for VZV in CSF analysis. All 4 GBS patients who had negative PCR and IgM for VZV in CSF analysis was suggestive of immunological mechanism due to VZV responsible for its pathogenesis.¹²

The neurological manifestations due to primary VZV infection showed seasonal variation. In our study among 22 patients, 17 patients presented during the months of March, April and May. Five patients presented during November and December.

DISCUSSION

Gnannet *et al.*¹³ and Cvjetkovic *et al.*¹⁴ found that pregnant women and immunocompromised patients were more prone to suffer from severe complications following primary varicella zoster virus infection.^{13,14} However, none of our patients had malnourishment, alcohol consumption or other causes of immunocompromised or pregnancy.

Gnannet *et al.*¹³ found that the most common CNS manifestations of VZV infection were cerebellar ataxia and meningoencephalitis. However, in our study meningoencephalitis and not cerebellar ataxia was more common. GBS was considered a rare neurological complication but in our study 4 patients presented with GBS. NMO, seen in one of our patients, has not been mentioned in any other studies.

Paul *et al.*⁹ presented 3 cases following primary VZV infection. Their first patient had meningitis, cerebellitis and polyradiculopathy, the second GBS and the third, acute transverse myelitis. Their study showed prolonged morbidity in spite of aggressive treatment. Our patients generally had good prognosis except for 2 (1 with VZV vasculopathy and the other GBS – AMSAN variant) who expired. Meningoencephalitis

and acute cerebellar ataxia¹⁵, which affect 1 in 4000 children infected with chicken pox¹⁶ were reportedly the most common neurological manifestation of primary VZV infection. However, we found meningoencephalitis more common than cerebellitis.

According to Wohlwillet *et al.*¹⁷, association of chickenpox with GBS was rare, though in this study we found 4 cases presented as GBS.

In a case series by Miller *et al.*¹⁸, encephalitis accounted for 90% of cases and 37% of those with cerebellar involvement. In our study 45% of our cases presented with meningoencephalitis, 9% had both meningoencephalitis and cerebellitis and 9% of patients had cerebellitis only.

Mueller *et al.*¹⁰ reported that strokes due to VZV vasculopathy occurs months after VZV infection. But in our study patients with VZV vasculopathy presented on the second day and sixteenth day after the onset of chickenpox rash. In contrast to the reported deep seated ischemic or hemorrhagic infarcts¹⁰, our patients had ischemic infarcts involving the cortical region and gray white matter junction. VZV vasculopathy can occur without the typical rash¹⁰, therefore, VZV vasculopathy should be suspected for in any vasculopathy of unknown etiology.

Jenkins *et al.*¹⁹ opined that central nervous system complications due to chickenpox were mild and had good prognosis with very low mortality. In this study though patients presented with severe complications, with appropriate treatment the prognosis was good with a mortality of 9%.

In conclusion, neurological manifestation due to primary VZV infection primarily affects immunocompetent young and/or immunocompromised patients of any age. NMO can also rarely be a complication of primary VZV infection. With early diagnosis and appropriate treatment the neurological manifestations due to primary VZV infection had good prognosis.

Live attenuated varicella vaccine, varicella zoster immunoglobulin, prophylaxis with antiviral therapy will help in preventing VZV infection and reducing the complications associated with it.

ACKNOWLEDGEMENT

Blood and CSF PCR and IgM for VZV were done at King Institute of Preventive Medicine and Research, Chennai, India.

DISCLOSURE

Financial support: None

Conflicts of Interest: None

REFERENCES

- Gilden D, Nagel MA, Cohrs R, Mahalingam R. The varicellaneurological manifestations of varicella zoster virus infection. *Curr Neurol Neurosci Rep* 2013;13(9):374.
- Longo DL, Fauci AS, Kasper DL, Hauser SL, Jameson JL, Loscalzo JL. Harrison's principles of internal medicine. 18th ed. McGraw-Hill Medical, 2012:1462-6.
- Daroff RB, Jankovic J, Mazziotta JC, Pomeroy SL. Bradley's Neurology in clinical practice. 7th ed. Elsevier. 2016:1128-9.
- Gilden D, Mahalingam R, Nagel MA, Pugazhenti S, Cohrs RJ. The neurobiology of varicella zoster virus infection. *Neuropathol Appl Neurobiol* 2011;37:441-63.
- Wilson RE, Ford FR. The nervous complications of variola, vaccinia and varicella with report of cases. *Bull John Hopkins Hosp* 1927;40:337.
- Celik Y. Transverse myelitis caused by varicella. *Clin Neurol Neurosurg* 2001;103:260-1.
- Whitley RJ. Varicella-zoster virus. In: Fauci AS, ed: Harrison's principles of internal medicine. 17th ed. McGraw-Hill Medical, 2008:Chapter 173, 1103.
- Gnann JW Jr. Varicella –zoster virus: Atypical presentations and unusual complications. *J Infect Dis* 2002;186(Suppl 1):S91-8.
- Paul R, Singhanian P, Hashmi MA, Bandyopadhyay R, Banerjee AK. Post chicken pox neurological sequelae: Three distinct presentations. *J Neurosci Rural Pract* 2010;1(2):92-6.
- Mueller NH, Gilden DH, Cohrs RJ, Mahalingam R, Nagel MA. Varicella zoster virus infection: Clinical features, molecular pathogenesis of disease and latency. *Neurol Clin* 2008;26(3):675-viii.
- Gilden D. Varicella zoster virus and central nervous system syndromes. *Herpes* 2004;11:89A-94A.
- Helfgott SM, Picard DA, Cook JS. Herpes zoster radiculopathy. *Spine* 1993;18:2523-4.
- Gnann JW, Whitley RJ. Herpes zoster. *N Engl J Med* 2002;347:340-6.
- Cvjetkovic D, Jovanovic J, Hrnjakovic-Cvjetkovic I, Brkic S, Bogdanovic M. Reactivation of herpes zoster infection by varicella zoster virus. *Med Pregl* 1999;52(3):125-8.
- Osoegawa M, Arakawa K, Araki E, Taniwaki T, Yamada T, Kira J. A case of radiculomyelitis following chicken pox in adulthood. *Rinsho Shinkeigaku* 1999;39:817-20.
- Guess HA. Population-based studies of varicella complications. *Pediatrics* 1986;78:723-7.
- Wohlwill F. Zur pathologischen Anatomie des nerven systems beim herpes zoster. *Z Gesamte Neurol Psychiatr* 1924;89:171.
- Müller HG, Stanton JB, Gibbons JL. Parainfectious encephalomyelitis and related syndromes: Critical review of neurological complications of certain fevers. *Q J Med* 1956;25:427-505.
- Jenkins RB. Severe chicken-pox encephalopathy: Treatment with intravenous urea, hypothermia and dexamethasone. *Am J Dis Child* 1965;110:137-9.