

Electrophysiological abnormalities in iatrogenic botulism: two case reports and review of the literature.

Luca Leonardi¹, Shalom Haggiag², Ludovico Lispi²

1) Department of Neuroscience, Mental Health and Sensory Organs, Sapienza University, Rome, Italy

2) Neurology dept, San Camillo-Forlanini Hospital, Rome, Italy

SISTEMA SANITARIO REGIONALE

AZIENDA OSPEDALIERA
SAN CAMILLO FORLANINI

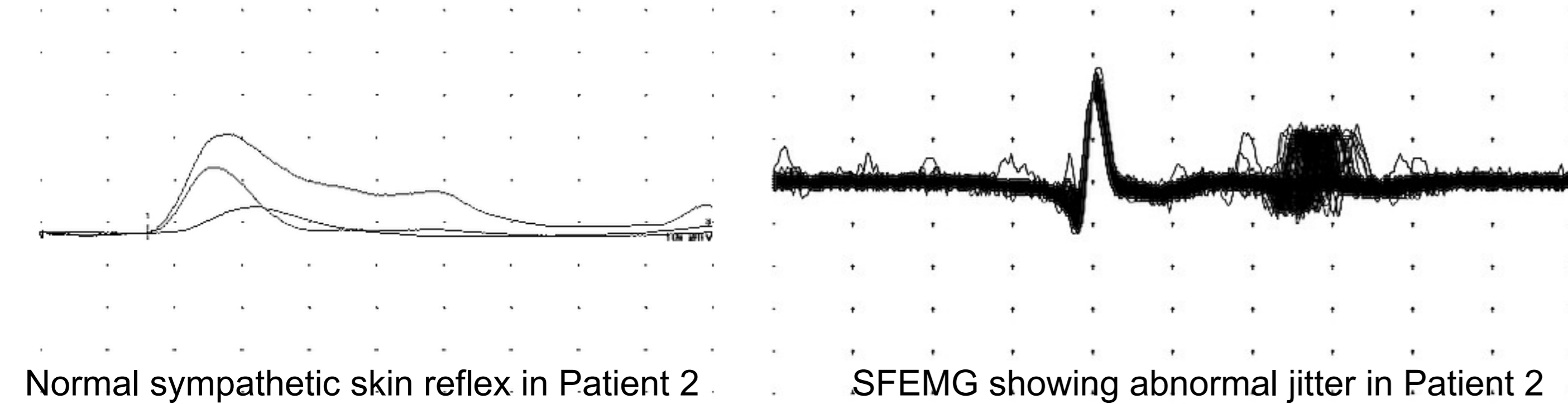
Therapeutic use of botulinum toxin type A (BoNT/A) is effective, and generally safe. Nevertheless Iatrogenic Botulism (IB) is rarely reported as a result of systemic spread of the BoNT/A, causing general weakness, bulbar symptoms and dysautonomia. Suggestive clinical features are decisive to raise the diagnostic suspicion, which however needs a confirmation in the electrodiagnostic study, above all to exclude other treatable diseases. In this study, we report 2 patients who developed IB after receiving therapeutic doses of BT/A for spasticity.

Conclusions:

- There is no highly specific pattern of electrophysiological abnormalities in IB.
- Literature review and our findings suggest both decrement and increment as unexpected changes in IB.
- If there is clinical suspicion, the lack of altered response after RNS in weak muscle, represents a highly suggestive clue for the diagnosis of IB.

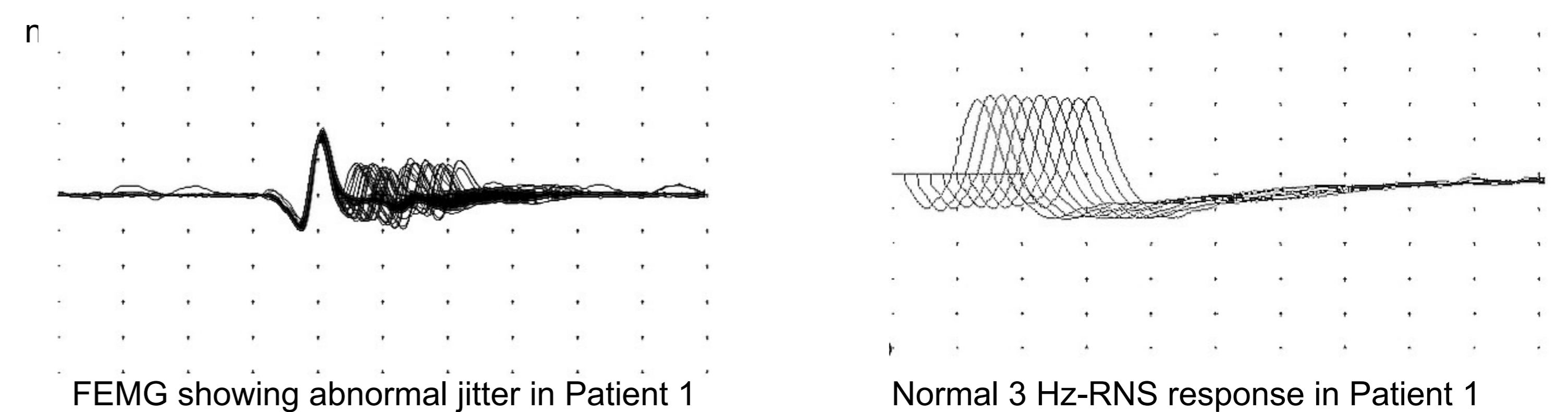
Patient 2

A 32-year-old Caucasian man with lower-limb spasticity due to infantile cerebral palsy, was treated at our clinic with a dose of 2000 U of BoNT-A (Dysport®) divided between quadriceps and adductors muscles bilaterally. Ten days later, he complained of difficulty swallowing, hoarse voice, blurred vision, and generalized weakness. At neurological examination, he showed multi-directional diplopia, impaired accommodation, bilateral facial weakness, and proximal tetraparesis. Neurophysiological assessment was consistent for diffuse small amplitude cMAP, abnormal spontaneous activity (PSWs and fibrillations), small and brief, but not polyphasic, MUAPs, with impaired recruitment. SFEMG of right extensor digitorum communis showed abnormal jitter (75.6 µsecs) and blocks occurrence (Fig1). Neither decremental response, nor facilitation were observed at 3Hz and 30 Hz RNS respectively. Sympathetic skin reflex test showed normal response (Fig 1). The symptoms and the neurophysiological alterations fully resolved over three months, with no treatment.



Patient 1

A 48-year-old Caucasian woman was initially treated with 400 U of BoNT-A (Botox®) for lower limbs spasticity due to Multiple Sclerosis, in another clinic. A second treatment with BoNTs-A was performed two months later, at a higher dosage of 600 U. Two weeks after injection, the patient complained of double vision, dysphonia, dysphagia, generalized weakness, and dry mouth. Based on a suspected diagnosis of seronegative myasthenia gravis, a treatment with pyridostigmine was initiated without benefit. Five months later, following a third treatment with 400 U of Botox®, the patient referred to our ER for the appearance of general weakness and bulbar symptoms. At neurological examination, she presented multidirectional diplopia, bilateral ptosis, slow reactive pupils, accommodation deficit, dysphonia, dysphagia, and tetraparesis prevalent proximally and in the upper limbs. Nerve conduction study (NCS) demonstrated a diffuse mild reduction of cMAP amplitude, with normal conduction velocity and no sensory abnormalities. Low frequency repetitive nerve stimulation (RNS) at 3 Hz in the right deltoid and the right orbicular oculi showed no decrement (Fig 1). No facilitation was seen after 10 secs of maximal contraction, nor at 30 Hz -RNS in the weak muscles. Standard needle EMG of the left deltoid showed fibrillations and positive sharp waves (PSWs), as well as polyphasic and unstable muscle unit action potentials (MUAPs), with normal amplitude and duration. The recruitment pattern was mildly reduced. Single-fiber EMG (SFEMG) demonstrated an abnormally increased jitter (111.4 µsecs) with occurrence of blocks (Fig 1). Based on clinical and neurophysiological findings, a diagnosis of Botulism was suspected. Once we shared our diagnostic hypothesis with the patient, she reported that she had recently undergone treatment with infiltration of BoNT-A, and a diagnosis of IB was made. Symptoms spontaneously resolved in two months, and a new



Report	Age/ Sex	Muscles injected/tot dosage and type	Primary diagnosis	Distribution of weakness	Electrophysiology (available data)
Bakeit <i>et al.</i> 1997	67/F	Left leg/250U Dysport®	MS (spasticity)	Generalized, LL>UL, ptosis, dysphagia, ptosis	EMG: "denervation", SFEMG: increased jitter, blocks
	34/F	SCM, Splenius/250 U Dysport®	MSA (torcicolis)	Generalized, dysphagia	EMG "denervation"
Bhatia <i>et al.</i> 1999	45 F	SCM, Splenii/650 U Dysport®	Cervical dystonia	Generalized, UL>LL, dysphagia	EMG: fibrillations, short and small MUAPs; SFEMG: increased jitter, blocks
	57/F	Left arm/900 U Dysport®	Symptomatic hemidystonia	Generalized, UL>LL	RNS: mild decrement; SFEMG: increased jitter, blocks
	32/F	Left leg/600 U Dysport®	Symptomatic hemidystonia	Generalized, UL>LL, dysphagia	EMG: normal; SFEMG: normal
Tugnoli <i>et al.</i> 2002	25/F	Axillae, hand palms/1400 U Dysport®	Hyperhidrosis	Generalized, UL, diplopia, ptosis	SFEMG: increased jitter, blocks
Crowner <i>et al.</i> 2010	16/M	Left flexor carpi radialis, flexor carpi ulnaris, pronator teres, flexor digitorum superficialis, biceps, brachioradialis, quadriceps/ 640 U Botox®	Post-haemorrhagic stroke hemiparesis	Generalized, LL, dysarthria	RNS: 26% decrement
	21/F	Bilateral erector spinae and orbicularis oculi/ 760 U Botox®	Generalized dystonia, leukodystrophy	Generalized, LL, dysphagia	EMG: mild generalized acute denervation
	38/F	Left pronator teres, flexor digitorum superficialis, gastrocnemius/soleus, tibialis posterior, and hamstring muscles/ 700U Botox®	Left hemiparesis, posterior fossa meningioma resection	Generalized, ptosis, dysphagia, hypophonia, facial, tongue, and neck muscles	EMG: fibrillation, PSW, short small polyphasic MUAPs with neurogenic recruitment (early only in deltoid)
Coban <i>et al.</i> 2010	30/F	Bilateral Gastrocnemius, tibialis posterior/1500 U Dysport®	Hereditary spastic paraparesis	Generalized, respiratory muscles, UL, neck muscles, dysphagia, dysarthria	SFEMG: increased jitter, no blocks
	74/F	Orbicularis oculi bilat/120 U Dysport®	Blepharospasm	Generalized, fatigue, diplopia, ptosis	SFEMG: "abnormal"
Ghasemi <i>et al.</i> 2012	42/F	Right axilla/30 U Botox®	Hyperhidrosis	UL, bulbar muscles	NCS: diffuse low cMAP; 3 Hz RNS: decrement; post-exercise (10s) cMAP: increment (50-160%); EMG: fibrillations, PSW, short small polyphasic and instable MUAPs with normal recruitment
	22/F	Hand palms/30 U Botox®	Hyperhidrosis	Generalized, UL, neck, and bulbar muscles	NCS: "similar to those of the first case".
Thomas <i>et al.</i> 2012	43/F	Right triceps, FDS, FDP, lumbricals, opponens pollicis, FPB, FPL, EHL, gastrocnemius, tibialis posterior, soleus /700 U Botox®	Post-haemorrhagic stroke hemiparesis	Left (contralateral) UL weakness	NCS: normal; 3 Hz RNS: decrement (23%); post-exercise (10s) cMAP: no increment; EMG: abnormal spontaneous activity, polyphasic MUAPs with reduced recruitment
	21/F	Left triceps, FCU, FPL, FPB, opponens pollicis, gastrocnemius, soleus, FDL, FDB/600 U Botox®	Post-ischemic stroke hemiparesis		NCS: normal; 2 Hz RNS: decrement (23%); post-exercise (10s) cMAP: no increment; EMG: abnormal spontaneous activity, polyphasic MUAPs with reduced recruitment
Szuch <i>et al.</i> 2016	72/F	Right EHL, FDL, gastrocnemius, peroneus longus/600 U Dysport®	PD (foot dystonia)	Generalized, UL, LL, neck muscles, dysphagia, diplopia	NCS: normal; 3Hz RNS: decrement of 14%, post-exercise (10s) cMAP: no increment; EMG: PSW, short small polyphasic and instable MUAPs; SFEMG: increased jitter (66.23 µs), blocks; sSFEMG: increased jitter (52.74 µs), blocks

Iatrogenic botulism – case reports in literature.

Legend: MS-multiple sclerosis, LL-lower limbs, UL-upper limbs, EMG-electromyography, SFEMG-single fiber electromyography, MSA-multiple system atrophy, MUAP-muscle unit action potential, RNS-repetitive nerve stimulation, BoNT-A-botulinum neurotoxin type A, NCS-nerve conduction study, cMAP-compound muscle action potential, PSW-positive sharp wave, FDS-flexor digitorum sublimis, FDP-flexor digitorum profundus, FPB-flexor pollicis brevis, FPL-flexor pollicis longus, EHL-extensor hallucis longus, FCU-flexor carpi ulnaris, FDL-flexor digitorum longus, FDB-flexor digitorum brevis, PD-Parkinson's disease, sSFEMG-stimulated single fiber electromyography.