

School of Health Sciences

Cardiology Teaching Package

A Beginners Guide to Normal Heart Function, Sinus Rhythm & Common Cardiac Arrhythmias
Welcome

This document extends subjects covered in the Cardiology Teaching Package which can be found online at the following address:

<http://www.nottingham.ac.uk/nursing/practice/resources/cardiology/index.php>

This package and document has been designed for student nurses who know nothing at all about Cardiology.

Written by Greg Moran, Clinical Facilitator, Cardiology, DRI

© 2006 School of Health Sciences, University of Nottingham

6. INTRODUCTION TO HEART BLOCK or ATRIO-VENTRICULAR (AV) BLOCK

Atrio-ventricular block (AV block), more commonly referred to as **Heart Block**, is an intermittent, persistent or complete blockage of the conduction pathways between the atria and the ventricles.

As usual with cardiology, there are some strange names associated with these occurrences, but they all fall into **3 distinct categories**:

- First degree AV block
- Second degree AV block
- Third degree (complete) AV block

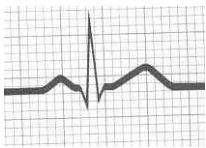
Whichever type of blockage occurs, it is within the junction made up of the Atrio-Ventricular (AV) node and Bundle of His.

This particular type of heart block is distinct from Bundle Branch Block, which occurs in one, or both, of the bundle branches.

This section of the teaching package will only discuss AV block.

Before proceeding, it might be useful to have a reminder about what constitutes sinus rhythm, as sinus rhythm is the “norm” against which abnormal rhythms are measured.

Sinus Rhythm



Here is a sinus complex....one heart beat showing PQRST.

Look at the complex above and test what you have learned so far. The complex is made up of:

- **P wave** representing atrial depolarisation. (contraction of the atria)
- **Small Q wave** representing depolarisation of the ventricular septum
- **Tall R wave** representing ventricular depolarisation
- **Small S wave** representing depolarisation of the Purkinje Fibres
- **T wave** representing ventricular repolarisation
- **P-R interval** is between 3-5 small squares
- **QRS complex** is less than 3 small squares

Some of these values change in AV block. Let's see which ones do.

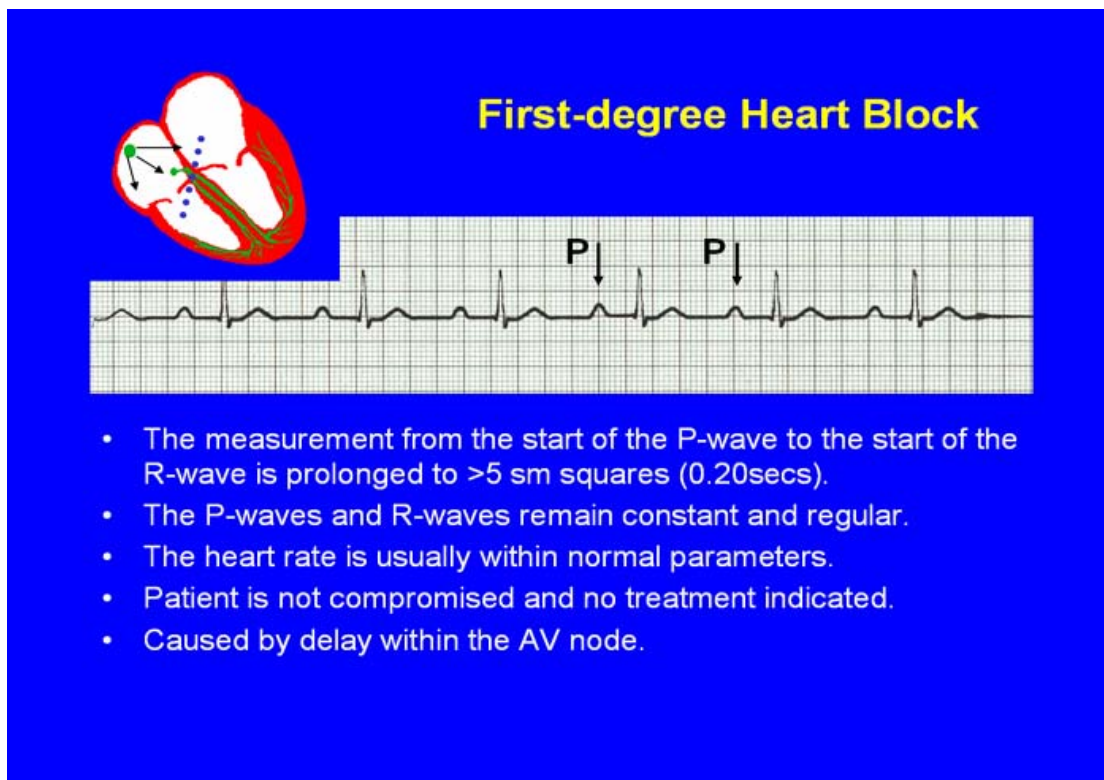
7. First Degree Heart Block

In the introduction, it was pointed out that, in sinus rhythm, the P-R interval should be 3-5 small squares. (Some books will say up to 5½ small squares)

This measurement represents the time it takes for the atria to depolarise (P wave), and the delay of the stimulus in the AV node (the flat line following the P wave) prior to depolarisation of the ventricles (QRS complex).

In the following example you can see that the distance from the beginning of the P wave to the beginning of the R wave is more than 5 small squares, in fact it is 8 small squares.

You can also see from this diagram that the P-R interval remains identical for every complex, the distance between the P waves is constant, as is the distance between the R waves, so the rhythm is regular.



So, apart from the **prolonged P-R interval**, this rhythm is identical to sinus rhythm.

Risks to the patient

- There are no symptoms associated with 1st degree AV block. All stimuli from the SA node are conducted to the ventricles and the ventricles contract as normal.
- There is no loss of output from the heart.
- There is no treatment required for 1st degree AV block.
- It can be a natural occurrence in some individuals.

However

- It also occurs in up to 13% of patients following Acute Myocardial Infarction (usually inferior MI).

- 75 % of these patients subsequently develop more severe AV block
- Half of this group go on to require a permanent pacemaker.

Common causes of prolonged P-R interval

Increased vagal tone	Idiopathic (unknown cause)
Ischaemic heart disease	Rheumatic carditis
Digoxin toxicity	Electrolyte disturbances

Therefore

Patients with a new 1st degree AV block need to remain monitored for possible deterioration of the rhythm.

Also, drugs such as Beta-blockers need to be avoided as these drugs can both cause, and worsen, AV block.

Questions for 1st degree heart block will appear in the next 2 sections, don't worry.

Second degree Heart Block

There is a lot of debate and confusion with regard to 2nd degree AV block, and there are also a few names and terms used which are definite ingredients for confusion, especially amongst those new to cardiology and arrhythmias.

Some of the terms you will hear are: type I; type II; nodal; high-grade; periodicity and others. The names you will hear associated with 2nd degree AV block are Wenckebach and Mobitz. I will be using the most commonly used terms and names. But some history may be helpful.

History

There are two types of 2nd degree AV block.

Both were described by **Wenckebach** at the turn of the century on the basis of impulses monitored on the jugular vein.

Both were also described by **Mobitz** in 1924, who labelled them **type I and type II**.

The most common labelling these days is to either refer to them as **Type I and Type II 2nd degree AV block**, or to refer to **Type I as Wenckebach**, and **Type II as Mobitz**.

Wenckebach Type I 2nd degree AV block

Mobitz Type II 2nd degree AV block

8. 2nd Degree (AV) Heart block

Type I Wenckebach

In 1st degree heart block, the P-R interval is prolonged, it is greater than 5 small squares in duration. The P-R interval remains constant and the rhythm is regular.

In **Wenckebach**, the P-R interval becomes increasingly prolonged, causing the rhythm to become irregular.

Cause.

You will most likely see Wenckebach following a myocardial infarction but it is not commonly seen. It is due to a sluggish recovery of the conduction pathway through the AV node/Bundle of His.

The impulses from the SA node initially depolarise the ventricles as per usual.

The next impulse from the SA node reaches the AV node and is delayed slightly longer than normal in the AV node / Bundle of His, leading to a slightly longer P-R interval.


The delay of the next impulse within the AV node / Bundle of His is even longer leading to a further prolongation of the P-R interval.

This gradual prolongation of the P-R interval continues to grow until it is so long that there is enough time for the SA node to release a second stimulus which depolarises the ventricles.

The first stimulus does not depolarise the ventricles and therefore it appears on the rhythm strip as a P wave but it is not followed by a QRS complex.

See rhythm strip below.

Second-degree Heart Block Mobitz type I (Wenckebach)



- The P-R interval becomes *progressively* elongated with each heart beat; eventually conduction fails completely.
- The cycle then repeats itself once again.
- May be seen in individuals with high vagal tone especial during sleep.
- Where it occurs in complication of inferior MI, it does not usually require a pacemaker and often may be reversed with myocardial reperfusion.

In the above rhythm strip there are 2 **non-conducted P waves**. Follow the arrows indicating the P waves and you can clearly see the P-R interval getting longer and longer.

The question mark “?” shows you where a ventricular contraction should have occurred.

A feature of Wenckebach rhythm is the appearance of “grouping” of the QRS complexes.

It is important to understand this rhythm in the context of overall cardiac function and blood supply.

Loss of a QRS on ECG represents loss of ventricular contraction and, therefore, **loss of output from the heart**. In this example, ventricular contraction is lost every 4th beat. This represents a potential 25% loss of output from the heart.

Because this rhythm usually occurs following an inferior MI, the patient will be on bed rest and therefore symptoms may not occur, but if symptoms do occur they will be predictable:

- Chest pain
- Shortness of breath

Although symptoms are treated as they occur, there is no standard treatment for this arrhythmia. The patient should remain monitored until the patient returns to sinus rhythm. Any drugs such as Beta-blockers and Digoxin, which can cause heart block, should be omitted.

Common causes of Wenckebach Type I


Inferior myocardial infarction
Drug toxicity (Digoxin, beta-blockers, calcium channel blockers)
Heightened vagal tone (eg. In athletes)

Type II Mobitz

So far we have said that 1st degree AV block has a **prolonged P-R interval** that remains constant and the rhythm remains regular.

2nd degree AV block Type I (Wenckebach) has an **increasingly prolonged P-R interval** and the rhythm is irregular with “grouping” of QRS complexes.

2nd degree AV block Type II (Mobitz) is a rhythm where the SA node releases regular stimuli that are conducted through the AV node without a delay (so it is regular), but occasionally an impulse from the SA node is not conducted, so there is no QRS complex to follow the P wave. (a non-conducted P wave)



**Second-degree Heart Block
Mobitz type II**

- Most P-waves conducted as normal - followed by QRS.
- The P-R interval is normal and usually constant.
- Occasionally, the atrial conduction is not followed by a QRS complex.
- Thought to be caused by an abnormality in the bundle of His.
- Considered more serious than type I block in that it can progress to complete heart block without warning.

In the above example, you can clearly see the 3 complexes in the middle look just like sinus rhythm but the fourth P wave, marked by the question mark, is non-conducted.

This does not affect the distance between the P waves so the rhythm remains regular.

This loss of conduction, again, represents a loss of output from the heart as the ventricles do not receive an impulse from the SA node and, therefore, do not contract.

Common causes of Mobitz Type II

Degenerative disease of the conduction system

Antero-septal myocardial infarction

Symptoms

Symptoms associated with this type of AV block are due to severity and are predictable:

- Chest pain
- Shortness of breath

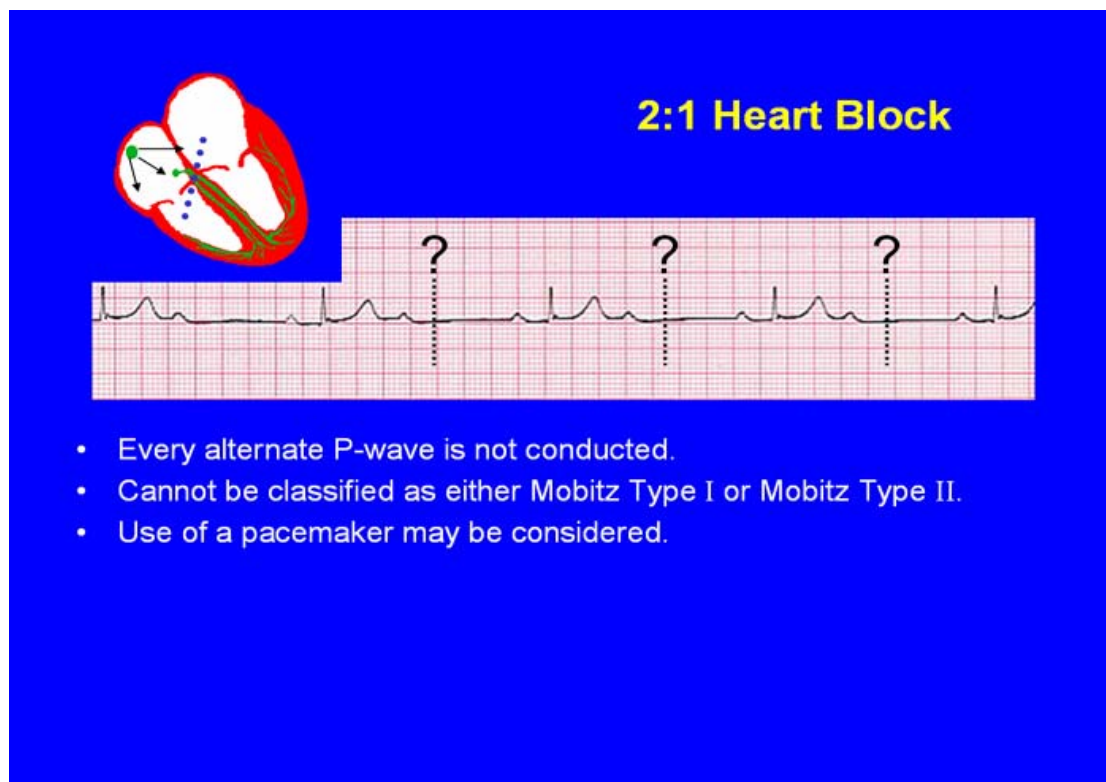
Severity refers to the number of ventricular contractions that are lost. The above example shows a non-conducted P wave every 4 beats. If this remained constant it would represent a 25% loss of output from the heart.

However, the frequency of the non-conducted P waves will dictate symptoms.

A loss of ventricular contraction every 10 beats is unlikely to cause any symptoms.

A loss of output every 3 beats is more likely to cause symptoms as it represents a 33% loss of cardiac output, which means 33% less blood and oxygen circulating around the heart and body.

If every 2nd impulse from the SA node is non-conducted then there is a 50% reduction in cardiac output. (see example below)



Some cardiologists believe that the above rhythm does not fall into the category of Mobitz Type II due to complexities in the underlying cause.

However, at this level it is acceptable to differentiate between Type I and Type II in the way suggested above:

- **Type I (Wenckebach):** The P-R interval is increasingly prolonged; the distance between the P waves is irregular; the distance between consecutive QRS complexes is irregular, and eventually the P-R interval is prolonged to such a time that the next impulse from the SA node depolarises the AV node and a ventricular contraction is lost.
- **Type II (Mobitz):** the P-R interval is constant; the distance between the P waves is the same (regular); the distance between consecutive QRS complexes is the same (regular), and occasionally a P wave is non-conducted representing a loss of ventricular contraction.

The major difference between the two rhythms is that :

- **Type I Wenckebach** tends to resolve on its own without treatment, although it can deteriorate into Type II.
- **Type II Mobitz** is indicative of a severe underlying heart disease and a large majority of these patients go on to develop Complete Heart Block requiring the implantation of a cardiac pacemaker.

Multiple Choice Questionnaire

how does 1st degree block differ from sinus rhythm?

- Prolonged P-R interval
- Short P-R interval
- P-R interval unchanged
- Widened QRS complex

What symptoms are associated with 1st degree heart block?

- Chest pain
- Shortness of breath
- Palpitations
- None

In Wenckebach, the P-R interval:

- Gets progressively shorter
- Gets progressively longer
- Disappears
- Is regular

in Mobitz Type II second degree heart block, the P-P interval:

- remains constant
- goes up and down
- gets progressively shorter
- disappears

a distinguishing characteristic of Wenckebach is:

- double P waves
- pointed P waves
- grouping of QRS complexes
- T wave inversion.

In 2nd degree heart block, a patient is likely to become symptomatic:

- The more often a non-conducted P wave occurs
- If they drink too much water
- If the P-R interval increases
- If a P wave is non-conducted occasionally

When evaluating both Type I and Type II 2nd degree heart block:

- Type I is more serious than Type II
- Type II is more serious than Type I !
- Neither is very serious
- Both are life threatening

Treatment for Wenckebach is:

- a. Permanent pacemaker insertion
- b. Beta-blockers
- c. ACE –Inhibitors
- d. Monitor and treat symptoms

In heart block, which type of drugs need omitting?

- a. Beta-blockers and Digoxin
- b. Antibiotics
- c. Aspirin and Clopidogrel
- d. Diuretics

In (Type II) 2:1 heart block, (see earlier example), the potential loss of cardiac output is:

- a. 50%
- b. 33%
- c. 20%
- d. 10%

9. 3rd Degree (complete) Heart block

The last 3 sections on heart block have all concerned a periodic block of, or slowing down of the conduction through, the AV node.

Complete heart block is different in the sense that, whatever happens within the atria, nothing is conducted through the AV node to the ventricles.

So, from what you know so far, if the AV node does not receive any signals from the SA node or atria, it can't work and therefore, logically, the patient's heart should stop.

But this is not the case. There is a condition called complete heart block and a patient can survive in this rhythm. So there must be something we don't know yet.

What we haven't discussed so far is that there are a number of sites of conduction in the heart. There is also a chain of command.

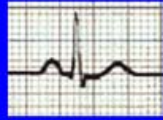This time we will use a military analogy. A General gives orders and the loyal lieutenant carries out those orders without deviation. The lieutenant has to have orders to work efficiently and would never dream of acting independently of the General's orders. This works well until the General is killed and the lieutenant becomes the senior officer and has to start giving orders.

The SA node is the General within the conduction system in the heart. It sends stimuli which are conducted by the AV node down the bundle branches and around the ventricles via the Purkinje fibres. So the AV node is the lieutenant.

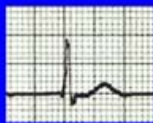
The AV node can conduct impulses independently but only if it has to. It is like a back-up generator, it kicks in when the normal system breaks down. (see below)

Potential Pacemaker sites of the Heart

1. The resting heart rate from the SA node is usually 60 - 70 bpm

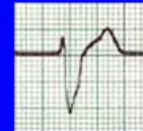

2. The AV junctional region intrinsic rate is about 40 bpm



Narrow QRS
(no preceding P wave)

3. The intrinsic rate of the Purkinje cells is about 0 - 30 bpm



Broad QRS
(no preceding P wave)

When the heart is working normally, it will work to the fastest rate available. This will almost always be the rate set by the SA node. The ECG trace will show a P wave, QRS complex and a T wave, as in point 1 in the diagram above.

When conduction between the atria and ventricles is completely blocked, conduction will start to be generated in the ventricular conduction network, normally the AV node, and at a much slower rate than is possible from the SA node. (see point 2 above)

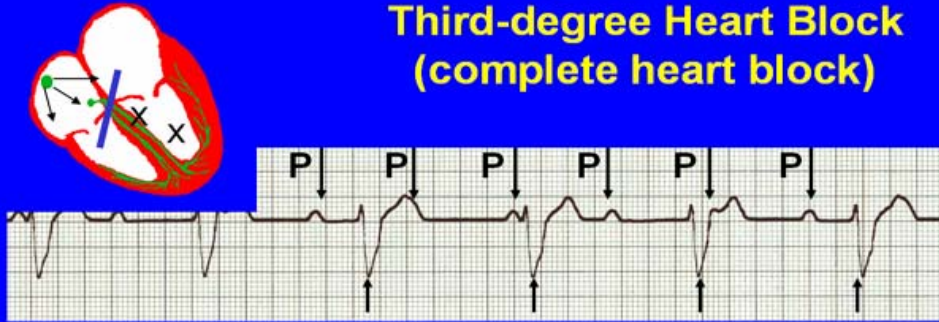
The conduction rate from the AV node is usually around 30-40 beats per minute, although in some cases it can be faster. And don't forget that it is only a back-up generator and will not maintain function long-term.

Conduction can also be generated by the Purkinje fibres but at a much slower rate, 1-30 beats per minute, which is not really conducive with short-term survival. (see point 3 above)

You will also see on the above examples that, when conduction from the ventricles is initiated, the shape of the QRS complex can change. The further down the ventricular conduction system the impulse emanates from, the more wide and bizarre the QRS complex will appear.

Now let's look at an example of 3rd degree (complete) heart block.

Third-degree Heart Block (complete heart block)



- The P-P and R-R intervals are each usually regular but have no relation to each other.
- This dissociation is due to a block at the AV junction.

What you will immediately spot is that there are P waves on this rhythm strip. Although no impulses are being conducted through the AV node, **they are still being generated by the SA node.**

The role of the ECG machine is to record **any** electrical activity in the heart. If the SA node is releasing stimuli, the ECG machine will record them. (regardless of whether they are conducted into the ventricles)

Similarly, whenever a stimulus depolarises the ventricles, the ECG machine will record it. (regardless of whether or not it came from the SA node initially)

So, what you see on a rhythm strip of complete heart block are **two completely independent rates:**

1. rate of atrial contraction
2. rate of ventricular contraction

The atria and ventricles are working independently of each other.

The above example shows:

*A regular **atrial** rate of around 85 contractions per minute

*A regular **ventricular** rate of 50 contractions per minute.

What you can also see in this rhythm strip is the combination of waves. Because the SA node and AV node are working independently of each other, the P waves can fall anywhere.

So what you can see above is P waves :

falling on the T wave and changing it's shape
falling between the QRS complex and T wave
falling on the S wave
falling at changing intervals before the QRS complex

You can also see a wide and bizarre QRS complex.

Treatment

The ventricular rate is the functional heart rate as this represents ventricular contraction and cardiac output.

A patient with complete heart block and a ventricular rate of 30-40 bpm may well be compromised, especially if the heart block has occurred prior to hospital admission. The symptoms will be predictable:

- chest pain
- shortness of breath
- possibly dizziness and collapse

Once a patient is on bed rest, the symptoms may improve due to reduced activity.

If a patient with complete heart block is asymptomatic, they will be monitored.

If drug overdose is suspected then the patient will be monitored until the drug works it's way out of the system or an antidote could be given.

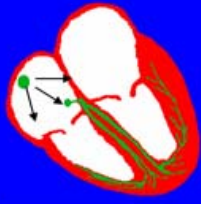
Causes of 3rd degree (complete) heart block

Infranodal degenerative fibrosis	Myocardial infarction
Drugs-Digoxin, beta-blockers	Congenital (rare)

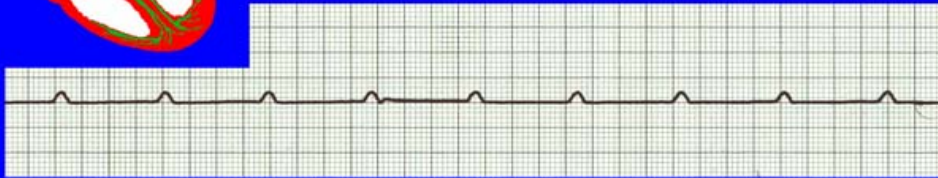
If the condition is due to a myocardial infarction then it is likely that the patient will require a permanent pacemaker (PPM) as the underlying damage to heart is rarely reversible.

Pacing of the heart can be done in 3 different ways:

1. If the patient is asymptomatic then they would go on an in-patient waiting list for a PPM.
2. If a patient is symptomatic (chest pain and/or shortness of breath) then a temporary pacing wire (TPW) with external control can be inserted as an emergency.
3. If a patient's ventricular rate deteriorates dramatically or stops (see below), then external pacing is required until the patient can be transferred urgently to theatre for a TPW.



Ventricular Standstill



- No ventricular response to atrial depolarisation.
- There is no cardiac output and the patient is in cardiac arrest.
- Pacing is required. It is usually effective if atrial activity is present.

Multiple Choice Questionnaire

Which of the following are sites for conduction?

- Sino-atrial node
- Atrio-ventricular node
- Purkinje fibres
- All of the above

What is the expected ventricular rate in complete heart block?

- 80-90
- 60-70
- 30-40
- 110-140

What happens to the SA node in complete heart block?

- It continues to function normally
- It gets faster
- It gets slower
- It stops working

What symptoms might a patient with complete heart block suffer with prior to hospital admission?

- Shortness of breath
- Chest pain
- Collapse
- All of the above

What would you most likely see on an ECG of complete heart block?

- a. More QRS complexes than P waves
- b. More P waves than QRS complexes
- c. No P waves
- d. No QRS complexes

How is the QRS most likely to appear on an ECG of complete heart block?

- a. Narrow QRS complex
- b. Broad QRS complex
- c. Small QRS complex
- d. Large QRS complex

What are the potential causes of complete heart block?

- a. Myocardial Infarction
- b. Beta-blocker overdose
- c. Digoxin toxicity
- d. All of the above

What is the most common treatment for complete heart block?

- a. Beta-blocker
- b. Digoxin
- c. Permanent pacemaker
- d. Cough medicine

In complete heart block, which rate represents cardiac output?

- a. Atrial rate (P waves)
- b. Ventricular rate (QRS complexes)
- c. Drip rate
- d. None of the above

In complete heart block, the P waves:

- a. Have no relationship with the QRS complexes
- b. Have a great relationship with the QRS complexes
- c. Are irregular
- d. Are absent

10. ECTOPIC BEATS in the ATRIA and VENTRICLES

Atrial Ectopic Beats (premature atrial contractions or PACs)

Atrial ectopic beats, or premature atrial contractions (PACs), are not always easy to detect as they do not look dissimilar to normal complexes.

The QRS looks the same, as does the T wave, and it is only the premature nature of the contraction that gives a clue. Usually they will be occurring regularly before they are picked up by the naked eye.

Create a picture in your mind of normal conduction within the atria. Firstly, the sino-atrial node releases an electrical stimulus which spreads through the myocardial cells causing a wave of contraction within the atria.

The same impulse eventually reaches the atrio-ventricular node, passes through it into the bundle of His, bundle branches and Purkinje fibres, causing a wave of contraction through the ventricles.

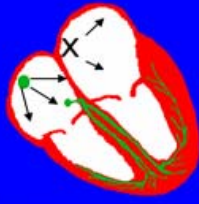
So we have atrial depolarisation represented on ECG by a P wave, and ventricular depolarisation represented by a QRS complex.

The conduction network mentioned above is made up of specialised conductive cells that facilitate rapid depolarisation.

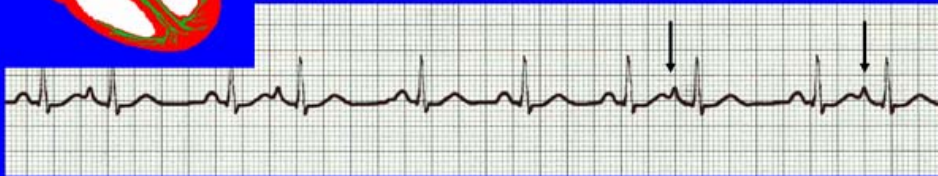However, all myocardial cells have the capacity to release an electrical stimulus. Normally these cells simply wait for the stimulus for depolarisation but, in the presence of localised ischaemia and irritation, can become the focus of an ectopic stimulus.

(ectopic simply means outside the normal structure)

In this situation the ectopic focus starts to release its own stimulus. It may be random or frequent and can take over the depolarisation of the atria if it achieves a regular rate faster than that of the SA node.



Atrial extrasystoles (AE)



- AE's are a common form of supraventricular extrasystole.
- Cause is atrial beat arising outside the sinus node.
- Patients are generally asymptomatic and there is no treatment indicated.
- A trial extrasystole falling on a critical time of atrial repolarisation may trigger atrial fibrillation (AF) in some vulnerable patients.

Extrasystole is another term for ectopic beat

Look at the rhythm strip above. It is a run of sinus rhythm with atrial ectopic beats indicated. (you can find the other two)

This rhythm strip is often mistaken for atrial fibrillation by nurses new to cardiology because it looks irregular at first glance.

So lets talk through what is actually happening inside the atria. The picture of the heart above shows the normal conduction pathways intact, and the ectopic focus.

The first thing to remember is that the SA node keeps working regularly. But only one stimulus can depolarise the atria.

Because the atrial ectopic stimulus is released earlier than the stimulus from the SA node, it is the ectopic stimulus that reaches the AV node first and depolarises the ventricles. The SA node still releases a stimulus but by this time the AV node has entered it's **refractory period** and does not let the stimulus through.

Look again at the rhythm strip above. In the middle of the strip there are 3 normal sinus beats. Measure the distance between the 1st and 2nd P waves (P to P interval). **About 3 ³/₄ large squares.** Now measure the distance between the 1st and 3rd P waves. About **7 ¹/₂ large squares.**

Now, measure the distance between the P wave coming before the first arrow and the P wave coming before the second arrow.

The distance is about **7 ¹/₂ large squares.**

This shows that the regularity of the SA node impulse is unaffected by the atrial ectopic beat.

If you look at one of the ectopic beats and measure where the P wave would have come in, it is exactly where the ventricles are depolarising and therefore:

- a. It would have no effect on the AV node
- b. It is completely obscured by the QRS complex

Despite this, the SA node continues to work as normal and, when it next releases a stimulus, it depolarises the ventricles in the usual fashion.

In this example, the ectopic stimulus is represented by a pointed, taller P wave. The changed shape is due to the fact that the stimulus is emanating from a different source and location within the atria.

Quite often, there is no discernable P wave with an atrial ectopic beat as it is absorbed into the preceding T wave giving the T wave itself an abnormal shape.

Common causes of atrial ectopics and atrial rhythm

Sino-atrial node dysfunction	Ischaemic heart disease
Electrolyte imbalance	Drugs
Structural atrial disease	

Treatment

There is no treatment for atrial ectopic beats. If an atrial rhythm emerges then drugs such as Adenosine and Digoxin may be used to slow it down if it is a tachycardia.

The aim would be to treat the underlying cause of the atrial rhythm.

Ventricular ectopic beats.

(Premature Ventricular Contractions/PVCs)

Unlike atrial ectopics (PACs), ventricular ectopic beats are extremely noticeable and usually have a very bizarre shape.

Their cause is similar to those emanating from the atria but, because the ventricles are so much bigger than the atria, a lot more electricity is generated within the ventricles.

The major difference between atrial and ventricular ectopic beats is that, with ventricular ectopics, the AV node (and its refractory period) has been taken out of the equation and therefore cannot protect the ventricles. If the ventricular ectopic focus begins to release a stimulus at a rate of 200 per minute, the ventricles will contract at that rate.

However, like atrial ectopics, the normal conduction system is intact and working normally. What has changed is that an ectopic focus has developed within the wall of the ventricles and is releasing its own stimulus.

Ectopic stimulation of the ventricles does not pass through the AV node. It spreads directly into the walls of the ventricles.

The stimulus is not part of the normal conduction system and therefore has to spread through normal myocardial tissue, which is slower.

So the impulse takes longer to travel through the ventricles.

Now remember what was said in section 1 about conduction.

On an ECG rhythm strip, a wave going up or down from the iso-electric line measures voltage.

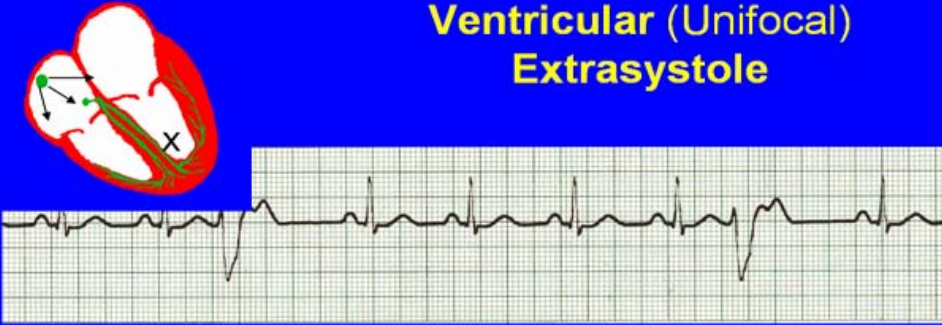
The distance between the beginning and the end of a wave measured horizontally indicates the duration of the conduction, in other words, **it measures time**.

When a stimulus is generated by an ectopic focus in the ventricles, it travels more slowly as it is outside the normal "rapid" conduction system and therefore its duration is longer. So the QRS complex for a ventricular ectopic beat **will be more than 3 small squares**.

Also, because the ectopic focus is in the wall of the ventricles, it is coming from a different direction than a normally conducted beat and therefore it will be seen by the ECG leads differently.

Look at the example below and note the difference.

Ventricular (Unifocal) Extrasystole



- Occasional extrasystoles are common in healthy adults.
- 3 or more in a row may be described as VT, but shorter runs are usually called salvos.
- The morphology of each ectopic is unchanged if depolarisation originates from a *single* focus.

("extrasystole" is another term for ectopics, not commonly used)

The above example shows sinus rhythm, but with two ventricular ectopic beats (3rd and 8th beats).

Note that the ectopics are:

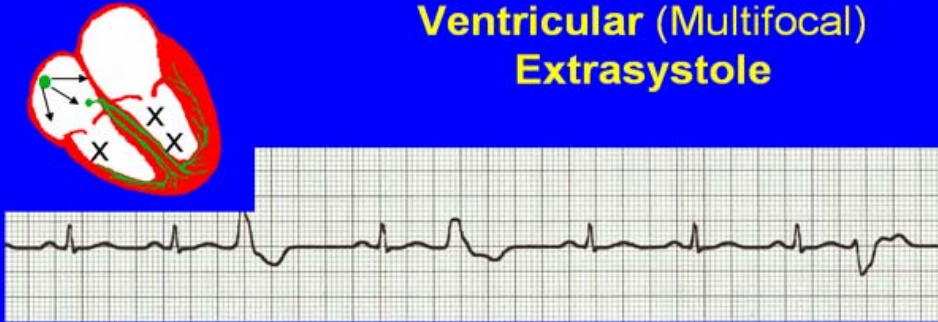
- Wider than 3 small squares
- Travelling in a different direction to the sinus beats
- Bizarre in shape
- Occurring earlier than a normal sinus beat
- Identical to each other

If the ectopics are identical then they are known as "**unifocal**".

If they are different shapes then it indicates that they are emanating from 2 or more different foci. These ectopics are known as "**multifocal**".

See the example below and compare the two.

Ventricular (Multifocal) Extrasystole



- Where the origin of the ectopic beat originates from differing foci within the ventricle.
- This may signify a high degree of ventricular excitability.
- Although extrasystoles may occasionally precipitate more malignant arrhythmias, any decision on treatment should be made only after considering the risk of anti-arrhythmic drugs.

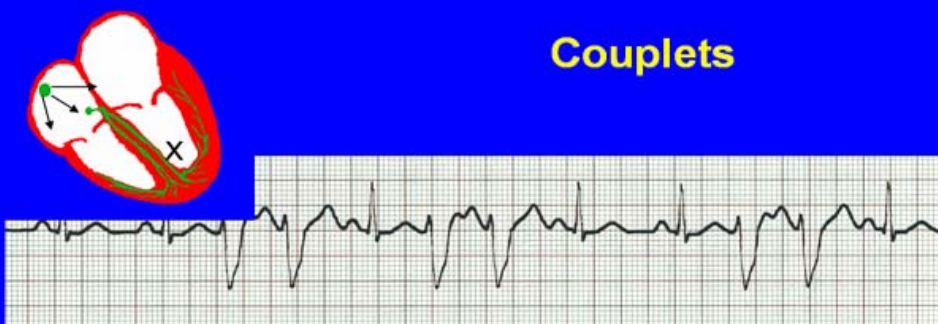The underlying rhythm is sinus rhythm, but the 3rd, 5th and 9th beats are ventricular ectopics.

All three are shaped differently from each other, indicating that each is arising from a different focus within the ventricles. “**multifocal**”.

Cardiac monitors do not alarm for ectopic beats unless they occur rapidly.

2 ventricular ectopic beats occurring consecutively will cause a “**VT**” alarm to sound. This is known as a couplet. (see Below)

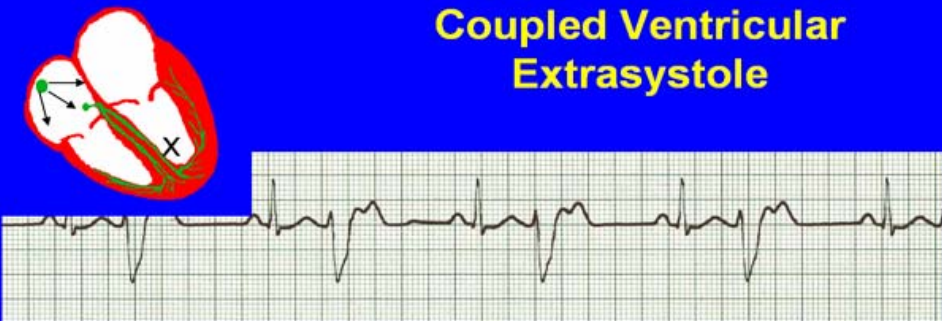
Couplets



- A couplet is where there are 2 ventricular ectopics in a row.
- Not usually treated except in circumstances that make the patient vulnerable to more serious arrhythmias

Again, the underlying rhythm is sinus rhythm but with 3 couplets. Also note that they are “**unifocal**”.

Then there is “**Bigeminy**”. This is where ventricular ectopics alternate with normally conducted beats.



Coupled Ventricular Extrasystole

- This is the term used when every alternate beat is an extrasystole.
- Treated only in exceptional circumstances.
- Coupled extrasystole may cause bigeminy: the condition in which alternate ectopic beats of the heart are transmitted to the pulse and felt as a double pulse beat followed by a pause.

Again, the terminology is a bit dated, but you can clearly see the sinus beats followed by the bizarre-looking ventricular ectopics.

Now, let’s look back at these examples, what do they all have in common?

If you look at all 4 examples: unifocal; multifocal; couplets and bigeminy, you will see that the underlying sinus rhythm remains regular.

Pick any of the 4 examples. Now measure the distance between 2 consecutive sinus beats. Once you have this, measure the distance between a sinus beat before and after an ectopic (or couplet).

What you will find is that the distance measured from either side of an ectopic (or couplet) is exactly double the distance between 2 sinus beats. This indicates that the SA node continues to depolarise the atria regularly but that, when an ectopic focus depolarises the ventricles, it occurs earlier than the normal depolarisation and absorbs any other electrical activity that might normally show up on the ECG at that time. (the P wave)

Common causes of ventricular ectopics

Can occur normally	Ischaemic heart disease
Digoxin toxicity	Left ventricular dysfunction

Basic rules apply

Ventricular ectopic beats are commonly seen in cardiology, usually following cardiac damage from Acute Coronary Syndrome.

There is no treatment usually initiated for periodic ventricular ectopics, but the nurse in particular has a crucial role to play in monitoring any changes in frequency or focus (uni- to multi-focal).

- A rhythm with multi-focal ectopics is considered to be more unstable than a rhythm with uni-focal ectopics.
- If ectopics are becoming more frequent then the patient needs observing more closely for symptoms
- The doctor needs to be kept informed of an increase in frequency of ventricular ectopics (even if they are not on the ward).
- Because ventricular ectopic stimuli do not pass through the AV node, regular ventricular ectopics can rapidly turn into VT.

Treatment

Occasional ventricular ectopics are rarely treated.

If ventricular ectopic beats are persistent, particularly if the patient is symptomatic, beta-blockers such as Metoprolol may be used.

If the rhythm degenerates into VT then Lignocaine is still the drug of choice for emergency treatment.

Amiodarone is also used but only when all other treatment has failed.

Multiple choice questionnaire

Do atrial ectopic beats come:

- Earlier than normal SA node conduction
- Later than normal SA node conduction
- At the same time as normal SA node conduction
- None of the above

Do ventricular ectopic beats come:

- Earlier than normal AV node conduction
- Later than normal AV node conduction
- At the same time as normal AV node conduction
- None of the above

when a patient is experiencing atrial or ventricular ectopics, what has happened to the normal conduction system? Is it:

- functioning normally

- b. functioning erratically
- c. functioning slowly
- d. functioning abnormally

What is a “couplet”?

- a. An occasional ectopic
- b. A regular ectopic
- c. 2 ectopic beats occurring consecutively
- d. a dropped beat

When discussing ventricular ectopic beats, which indicates the most instability?

- a. Occasional ectopics
- b. Multi-focal ectopics
- c. Uni-focal ectopics
- d. No ectopics

Visually, how would you describe ventricular ectopic beats?

- a. Small
- b. Big
- c. Ugly looking
- d. Wide and bizarre

Which of the following is a common cause of atrial ectopics?

- a. Structural atrial disease
- b. Electrolyte imbalance
- c. Ischaemic heart disease
- d. All of the above

Which of the following are common causes of ventricular ectopics?

- a. Ischaemic heart disease
- b. Digoxin toxicity
- c. Left ventricular dysfunction
- d. All of the above

What role does the AV node play in relation to ventricular ectopics?

- a. It controls the rate
- b. It controls the shape
- c. It controls the width
- d. It has no control at all

Newcomers to cardiology often mistake sinus rhythm with atrial ectopics for:

- a. Atrial flutter
- b. Ventricular fibrillation
- c. Ventricular bigeminy
- d. Atrial fibrillation

11. FATAL ARRHYTHMIAS

The word “fatal” is used to describe an event which will lead to death. It may be a “fatal injury”, or a “fatal car crash”, or a “fatal wound”. They all indicate that the event will lead to a person’s death.

Fatal arrhythmias are abnormal rhythms which do not support life. This is completely different to “asystole” where the heart has stopped functioning.

Let’s think about this logically. What do we know about the heart? The heart is a pump and it has 1 purpose, **to pump blood and oxygen into the coronary and arterial circulation.** It’s efficient function depends on a specialised conduction network which causes contraction of the chambers of the heart in a synchronised fashion, allowing blood and oxygen to be pumped around the cardiovascular system.

This in turn enables the organs, muscles and tissues to receive blood and oxygen, to function efficiently and, thus, sustain life.

An arrhythmia, where the rhythm of the heart has changed and the function of the heart is impaired (leading to loss of cardiac output), leads to a potential reduction in efficiency of organs, muscles and tissues, leading to symptoms we have discussed in other sections.

A fatal arrhythmia is where the function of the heart is impaired to such an extent that there is not enough cardiac output to support the function of organs, muscles and tissues...and the patient starts to die.

Initially, the brain shuts down and the patient becomes unconscious. But if the arrhythmia is not terminated then multiple organ shutdown, including the heart, will follow....and then death.

In this section we will be discussing **Ventricular Tachycardia (VT) and Ventricular Fibrillation (VF)**. These are the fatal arrhythmias that every ward has an algorithm poster for.

What you will realise (hopefully) is that VF sounds very much like AF, and that VT sounds very much like Atrial Tachycardia in that they all originate from ectopic beats, although the outcomes are very different. This difference is very much to do with the AV node. So let’s look at it again.

The AV node

The analogy used earlier is of a car park barrier.

Every time the the AV node conducts a stimulus from the atria there is a brief pause, a refractory period. During this period the AV node cannot conduct another impulse, no matter how many are generated. This is similar to cars going into a car park.

Every time a car goes into the car park, a barrier comes down and delays the next car for a brief period.

The car park may be empty or full, and there may be a long queue or just one or two cars, the barrier will still come down after each car and briefly delay the next one.

In this analogy, if the barrier stayed up then every car would enter the car park until it was overflowing and chaos would follow.

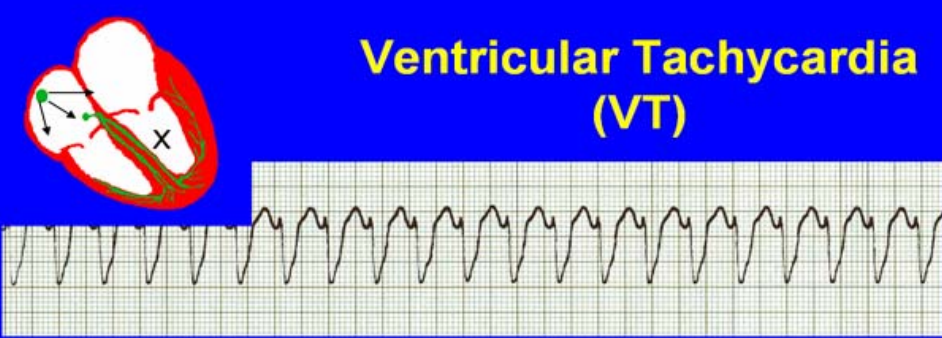
From the point of view of the heart, if the AV node did not restrict the number of impulses conducted into the ventricles then all cases of AF would immediately cause VF, and any atrial tachycardic rhythm would immediately cause VT.

So the AV node protects the Ventricles.

However, when stimuli are being generated within the ventricles then the AV node plays no role and the ventricles will go as fast as the ectopic focus dictates.

So, let's look at VT.

Ventricular Tachycardia



Ventricular Tachycardia (VT)

- The origin of the heartbeat is in the ventricles, producing a QRS complex >0.12 secs.
- 3 ventricular beats in succession may be called VT (or salvoes).
- VT can range in rate from 100-300bpm and the patient may be conscious and asymptomatic, symptomatic, or unconscious. Treatment will depend principally on the patients' clinical status.

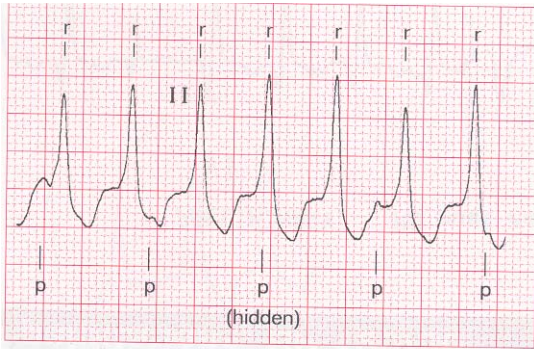
Previously we looked at “unifocal” ectopic beats. When seen individually they stand out in stark contrast to other more normal looking complexes. However, seen as a rhythm in themselves, identification can be quite daunting.

Look at the rhythm strip above. The deep “V” shaped complex is the QRS complex representing ventricular contraction.

It is wide because, as we discussed in the section on ectopics, it is emanating from an ectopic focus outside the normal conduction pathways and it takes longer to travel through the non-specialised cells of the ventricles.

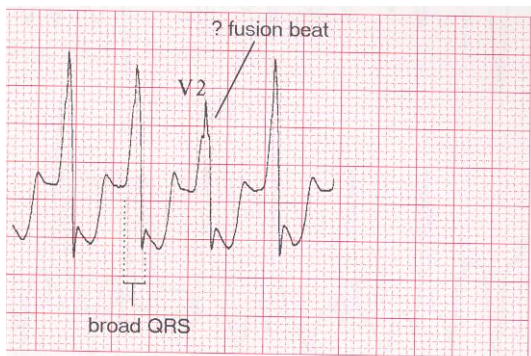
It is constant because the stimuli from the ectopic focus is so rapid that the SA node cannot compete and the ectopic focus has **taken over** pacing the heart.

In VT it is possible to see the odd **P wave** but this would only be to the experienced eye.



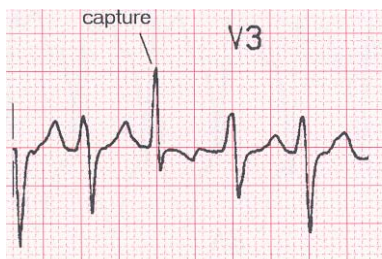
The P waves appearing above are evidence that the SA node is still working normally, even though the rhythm is ventricular.

It is possible to see a “**fusion beat**” where a P wave merges or fuses with a QRS complex to alter its shape slightly.



In this example, although the rhythm is ventricular, a P wave has been generated that has “fused” with the QRS complex

It is also possible (though rare) to see a “**capture beat**”. This is where the impulse from the SA node manages to depolarise the ventricles normally leading to a more normal-looking complex in the midst of ongoing VT.



In this example, an impulse from the SA node has managed to arrive at the AV node prior to it being depolarised by the ventricular ectopic stimulus and , in effect, “capturing” control of heart function for just one heart beat.

Confused?

The rule is...**If you think it is VT but you are not sure...Treat it as VT!**

Look at the algorithm again. It asks the question:
Is it VT with or without a pulse?

This is because a ventricular rhythm only has to go over 100 bpm for it to be described as tachycardia.

A ventricular Rhythm of 120bpm would probably still supply enough blood and oxygen to the heart and brain to keep the patient conscious with shortness of breath and chest pain.

However, once the ventricular rate approaches 200bpm the patient is more likely to be unconscious.

The only way to terminate pulseless VT is to delivery a shock to the heart with a defibrillator.

CPR will help to keep the patient alive if there is no defibrillator immediately to hand, but the patient will die unless the VT can be terminated.

Causes of VT

Ventricular ectopic beats	Impaired left ventricular function
Ischaemic heart disease	Acute myocardial infarction
Electrolyte abnormalities	Long QT interval

Treatment

Depends on the condition of the patient.

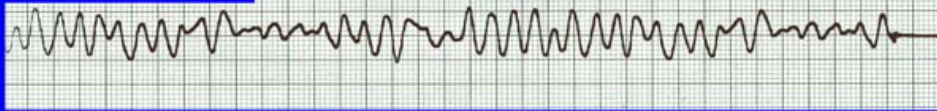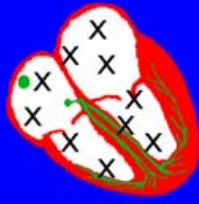In VT with a pulse, (where the patient is conscious), an IV **lignocaine** infusion remains first-line treatment. **Amiodarone** infusion is used if lignocaine fails.

In VT without a pulse, (where the patient is unconscious), defibrillation **ASAP**.

Medics also need to treat underlying cause.

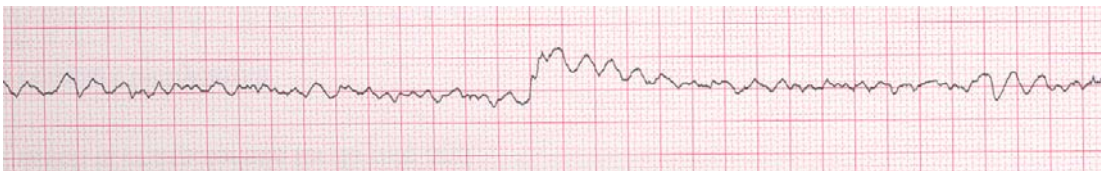Ventricular Fibrillation

Ventricular Fibrillation (VF)



- The ventricles are 'quivering', leading to a complete loss of cardiac output.
- Bizarre complexes are characteristic, but are variable amplitude (course / fine VF).
- The most common arrhythmia causing cardiac arrest, but becomes finer as minutes pass and soon becomes indistinguishable with asystole.
- Patient will require *immediate* defibrillation (10% reduction in success rate as each minute passes).
- Most common cause of death in early acute MI.

In contrast to VT, ventricular fibrillation has a number of ectopic focuses that create chaos within the ventricles. Impulses are so rapid that depolarisation and repolarisation are impossible and the ventricles merely quiver, making it impossible to achieve any cardiac output.



Another example of VF. The longer VF lasts, the smaller, or "finer", the waves become.

VF is the most common cause of death in the early stages of an MI. Up to a third of people experiencing a myocardial infarction die in the first few hours, and most of these deaths are due to ventricular fibrillation (VF).

However, most of these deaths occur out of hospital. In hospital, providing the patient is defibrillated successfully, the occurrence of VF does not have a significantly negative effect on long-term survival.

Causes of VF

Wolff-Parkinson-White Syndrome
Sustained ventricular tachycardia
Preceded by tachycardia of some sort in 90% of cases
Can be a primary event
Acute myocardial infarction

Treatment

There is no medication to treat VF. The only treatment is defibrillation. Once the patient is out of VF then the underlying cause can be treated.

The earlier defibrillation occurs, the more likely it is to be successful and the better the long-term prognosis of the patient.

For this reason, do not delay defibrillation in order to do a 12-lead ECG.

Multiple choice questionnaire

Is a patient in ventricular fibrillation likely to be unconscious?

- a. Definitely
- b. Possibly
- c. Sometimes
- d. Never

What is the first-line drug of choice for a conscious patient with VT?

- a. Amiodarone
- b. Sotalol
- c. Frusemide
- d. Lignocaine

What is the treatment for pulseless VT?

1. ECG
2. Cup of tea
3. Aspirin
4. Immediate DC shock to the heart

Which of the following is a cause of VF?

1. Sustained VT
2. Acute myocardial infarction
3. Wolff-Parkinson-White syndrome
4. All of the above

In VT, what causes a capture beat?

1. SA node stimulus depolarising the ventricles
2. AV node depolarising the ventricles
3. Purkinje fibres depolarising the ventricles
4. All of the above

In VF and VT, why can't the AV node protect the ventricles?

1. Because it is not working
2. Because it is malfunctioning
3. Because a ventricular stimulus does not pass through the AV node

4. Because it is not strong enough

Which of the following are causes of VT?

1. Ventricular ectopic beats
2. Acute myocardial infarction
3. Electrolyte imbalance
4. All of the above

In VF and pulseless VT, would you perform CPR?

1. Yes, for 5 minutes
2. Only if a cardiac defibrillator is not immediately available
3. Yes, for 10 minutes
4. No, it won't do any good

If you are not completely convinced that a patient is in a pulsed VT, what action would you take?

1. Assume it is VT, and follow the algorithm
2. Watch the monitor for a while to see what happens
3. Assume that the patient is fidgeting and causing artefact
4. Wait for the patient to become unconscious so that you can shock them.

In VT, if you can recognise P waves within the rhythm, what does this indicate?

1. That the patient is also in AF
2. That the SA node is still functioning normally
3. That it is not actually VT
4. That this is sinus rhythm

12.Acknowledgements

Roche &
Boehringer-Ingelheim for use of CD-Roms

Nurses
HCAs
Tutors
CFSNs