

# Diagnosis and treatment of cutaneous leukocytoclastic vasculitis

We review the terminology used in the context of cutaneous vasculitis with discussion of cutaneous leukocytoclastic vasculitis, its clinical approach, differential diagnosis and treatment algorithm. Cutaneous vasculitis encompasses a wide spectrum of conditions of very different severity and urgency, from limited skin disease to severe systemic life-threatening vasculitis. This review will empower the reader with tools for rapid evaluation of patients suspected of cutaneous vasculitis such as a correct interpretation of skin biopsies, an effective high yield laboratory and imaging testing approach, a simple practical evaluation procedure to ensure that severe organ involvement by a systemic vasculitis is not missed, as well as an easy diagnostic algorithm for identification of the cause of vasculitis.

**KEYWORDS:** cutaneous leukocytoclastic vasculitis ■ cutaneous vasculitis ■ differential diagnosis ■ hypersensitivity angiitis ■ leukocytoclastic vasculitis ■ purpura ■ skin biopsy ■ treatment

Carmen E Gota\*<sup>1</sup>  
& Leonard H Calabrese<sup>1</sup>

<sup>1</sup>Center for Vasculitis Care & Research  
Cleveland Clinic Foundation, Desk A50,  
9500 Euclid Avenue, Cleveland Clinic,  
Cleveland, OH 44195, USA

\*Author for correspondence:  
gotac@ccf.org

## Definition of terms

Vasculitis defines an inflammatory disease of the blood vessels that can be primary or secondary (accompanying another disease) and that can present as systemic or isolated to one organ [1].

Purpura means purple in Latin. In a medical context it refers to a nonblanching rash of the same color, which is the result of extravasations of red blood cells caused by a malfunction in one or more of the mechanisms that preserve vessel wall integrity (Box 1).

Cutaneous vasculitis refers to inflammation of the blood vessels present in the dermis and subcutaneous tissue. It is not a distinct nosologic entity – for vasculitis to be considered limited to the skin, systemic organ involvement should have been sought but not found. It should also be kept in mind that systemic involvement may occur at a later time (Table 1).

Hypersensitivity angiitis was the term originally used by Pearl Zeek in 1948 to separate small vessel necrotizing vasculitis attributed to a hypersensitivity reaction from the classic polyarteritis nodosa [1,2]. Distinguishing features included prominent involvement of the skin and the observation that the condition frequently appeared to be precipitated by the use of serum or drugs, hence the term ‘hypersensitivity’. In many cases, however, no inciting cause can be found, and a similar clinical and histological picture can be observed in diseases with mechanisms other than hypersensitivity [3].

Over the years, the term hypersensitivity vasculitis has been used interchangeably with

drug-induced or allergic vasculitis, with a variety of primary and secondary vasculitides confined largely to the skin, and with any disease entity associated with leukocytoclastic vasculitis (LCV).

LCV is a histopathologic term that defines vasculitis of the small vessels in which the inflammatory infiltrate is composed of neutrophils. After degranulation, neutrophils undergo death and breakdown, a process named leukocytoclasia, releasing nuclear debris, also described as nuclear dust. One must keep in mind that not all small-vessel vasculitides are neutrophilic, other types of infiltrates such as lymphocytes or granulomatous are described. In addition, LCV is not specific to the skin, but can affect small vessels in any other organ. Last, but not least, leukocytoclasia occurs not only in vasculitis, but also whenever neutrophils are important partakers in the inflammatory process. The term LCV thus gives no information on etiology or pathogenetic mechanism:

- Cutaneous leukocytoclastic vasculitis is the term coined by consensus by the Chapel Hill Conference in 1994 as “an isolated cutaneous leukocytoclastic angiitis without systemic vasculitis or glomerulonephritis,” thought to equate best with the most common usage of the defunct hypersensitivity vasculitis [4].

## How does LCV present?

The most common presentation of LCV is that of palpable purpuric (nonblanching) lesions that

**Box 1. Differential diagnosis of purpura.**

**Noninflammatory vessel wall abnormalities (nonpalpable purpura)**

- Disorders of collagen production and increased capillary fragility: scurvy, Ehlers–Danlos syndrome, solar purpura, steroid purpura, amyloidosis and trauma

**Inflammatory vessel wall abnormalities or damage to the vessel wall by intravascular thrombi or emboli (palpable purpura)**

- Vasculitis
- Pigmented purpuric dermatoses [8]
- Infectious emboli, acute meningococemia, disseminated gonococcal infection, Rocky mountain spotted fever
- Thrombi formation within the vessels: disseminated intravascular coagulation, monoclonal paraproteinemias, thrombotic thrombocytopenic purpura, Gardner–Diamond syndrome
- Emboli: cardiac myxoma, cholesterol emboli, septic emboli

**Coagulation, platelet and other intravascular abnormalities (nonpalpable purpura)**

- Abnormal platelet count (thrombocytopenia) and platelet dysfunction disorders
- Clotting factor defects

Data taken from [57].

occur predominantly on dependent areas, mostly as petechiae. Lesions are also commonly seen on the feet and lower extremities (FIGURES 1 & 2). the forearms and hands, but it is unusual to find Lesions smaller than 3 mm are usually referred to lesions on the upper part of the trunk. A patient

**Table 1. Classification of cutaneous vasculitis.**

Classification criteria	Classification of vasculitis according to criteria	Example
Clinical presentation/vessel size	Small vessels (nonmuscular arterioles, capillaries, postcapillary venules)	Purpura, urticaria
	Medium-sized vessels	Nodular lesions, ulcers, livedo reticularis
Type of inflammatory infiltrate	Neutrophilic inflammation	Polyarteritis nodosa, LCV primary or secondary to drugs, infections, malignancy, autoimmune diseases such as systemic lupus erythematosus, Sjogren’s syndrome, rheumatoid arthritis, cryoglobulinemia ANCA-associated vasculitides, HSP, urticarial vasculitis and so on
	Lymphocytic	Systemic lupus erythematosus, Sjogren’s syndrome, viral infections, Rickettsial, rare drug reactions
	Eosinophilic	Allergic reaction, Churg–Strauss syndrome, parasitic infections
	Granulomatous	Granulomatosis with polyangiitis, sarcoidosis, Crohn’s disease, Infectious: fungal, tuberculosis
Pathogenetic mechanism	Immune complex mediated	HSP, cryoglobulinemic vasculitis, drug-induced, subacute endocarditis
	Pauci-immune (nonimmune complex-mediated neutrophil activation)	Granulomatosis with polyangiitis, microscopic polyangiitis, Churg–Strauss syndrome
Etiology	Infections	Bacterial, viral, mycobacterial, parasitic
	Drugs	Any drug category
	Chemicals, environmental agents	
	Systemic inflammatory diseases	Systemic lupus erythematosus Rheumatoid arthritis, Sjogren’s syndrome, dermatomyositis/polymyositis
	Malignancies	Solid tumors, hematologic malignancies: lymphomas, leukemias, myeloproliferative, myelodysplastic
	Other	Ulcerative colitis, Crohn’s disease
	Idiopathic	Systemic vasculitides

ANCA: Antineutrophil cytoplasmic antibody; HSP: Henoch–Schönlein purpura; LCV: Leukocytoclastic vasculitis. Data taken from [58].

who is bedridden may develop lesions on the back or on one side. Other cutaneous presentations of LCV include urticarial wheals, erythematous plaques, bullous hemorrhagic lesions or ulcers. Livedo reticularis, deep skin ulcers and nodules have also been described in patients with LCV but occur less often [5,6] and are a reflection of involvement of medium-sized arteries.

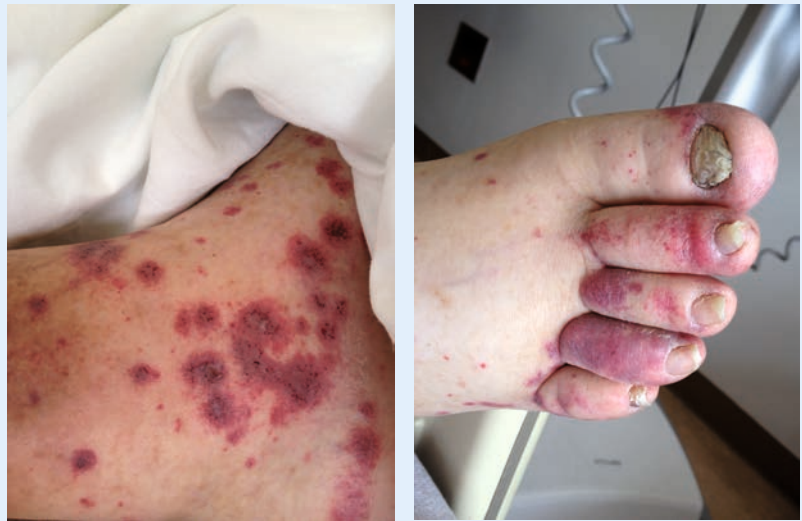Several patterns of disease evolution have been described. A single acute simultaneous appearance of vasculitic lesions (all lesions of the same age) is often associated with a drug or infection. Recurrent purpura with symptom-free intervals can be seen in the setting of HSP or other connective diseases. Chronic, persistent occurrence of LCV lesions is observed in patients with malignancy, cryoglobulinemia and systemic small-vessel vasculitis [5,7].

### Role of tissue biopsy in the diagnosis of cutaneous LCV

The main reason to perform a skin biopsy is to confirm that vasculitis and no other process is causing the cutaneous lesion in question. Several other questions can be answered by the skin biopsy: which size vessels are affected (small, medium or both)? What type of inflammatory cells are present? Are there immune globulins deposited in the vessel wall, and which ones?

The procedure is superficial, simple and entails minimum risk of bleeding, ulceration or infection. On the other hand, finding vasculitis on skin biopsy is not the end of the road in the diagnostic algorithm, as it needs to be part of a careful history, examination and laboratory and imaging studies to reach the definite, specific diagnosis [8]. A positive skin biopsy for vasculitis may not preclude the need to obtain biopsy of other organs that are presumed to be involved, as that may provide additional information about the type of vasculitis, severity of organ involvement and reversibility of the process versus damage.

For a correct interpretation of a pathology report one must be aware of the essential features of LCV, and when in doubt, be able to review the biopsy specimens with a dermatopathologist. To ensure the highest yield, biopsy should be carried out within 24–48 h of the onset of the lesion. The preferred technique is a deep punch biopsy, which will sample not only the epidermis and superficial dermis, but also the deep dermis and part of subcutis since medium-sized vessels lie above and within the subcutaneous fat. Shave biopsies are not recommended. Whenever possible two biopsies should be obtained: one to be sent for hematoxylin eosin



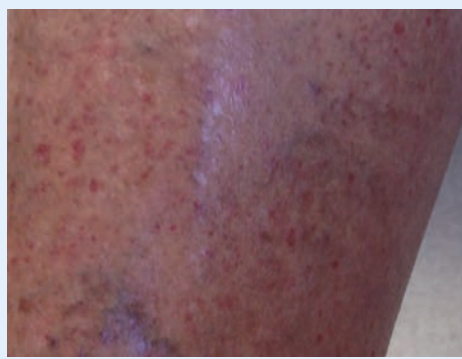**Figure 1. Palpable purpura in a patient with myelodysplastic syndrome.** Biopsy was consistent with leukocytoclastic vasculitis.

staining and a separate fresh sample for direct immunofluorescence (DIF) staining [9]. Skin biopsy may not be necessary in cases where the diagnosis of systemic vasculitis has already been made by extracutaneous manifestations and testing, or biopsy.

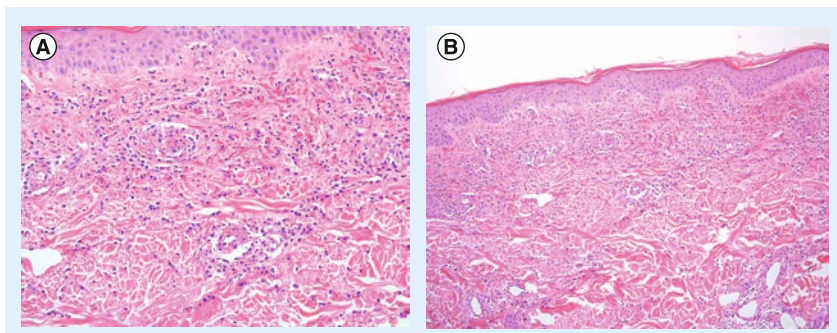
### Histologic findings in LCV

The vessels affected by LCV include arterioles, capillaries and postcapillary venules.

The core features of LCV are: evidence of neutrophilic infiltration within and around the vessel wall with signs of activation, degranulation and death of neutrophils, illustrated by leukocytoclasia (nuclear dust); fibrinoid necrosis (fibrin deposition within and around the vessel walls); and signs of damage (extravasated red blood cells, damaged endothelial cells) of the vessel wall and



**Figure 2. Palpable purpura in a patient with chronic hepatitis C and cryoglobulinemia.**



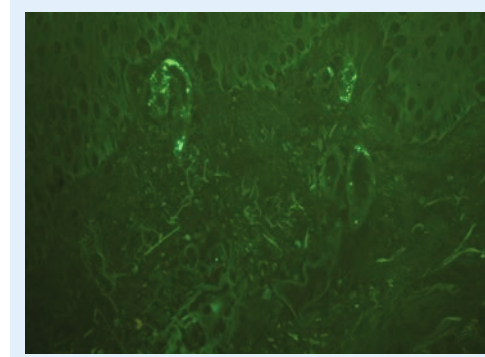
**Figure 3. Skin biopsy showing leukocytoclastic vasculitis.**

**(A)** Leukocytoclastic vasculitis 200× magnification, showing neutrophilic perivascular infiltrates, leukocytoclasia and fibrinoid necrosis. **(B)** Low power image of skin biopsy showing perivascular neutrophilic infiltration and fibrinoid necrosis. Courtesy of Dr Steven Billings, Cleveland Clinic (OH, USA).

surrounding tissue [8]. The diagnosis of LCV can be made with certainty if the first two are present (FIGURE 3) [4]. Thrombi in the lumina of blood vessels can be detected in patients with severe lesions [10].

The histologic changes in LCV evolve and thus the findings depend on the timing of the biopsy in relationship to the appearance of the lesion. Early on there is focal destruction of capillary blood vessels and a mild granulocytic infiltrate with small foci of nuclear dust (leukocytoclasia). The fully developed LCV includes more prominent damage to blood vessel walls, a dense inflammatory infiltrate and nuclear dust. As the lesions age, the neutrophil-rich infiltrate is replaced by lymphocytes [10,11]. The proportion of mononuclear cells seems to correlate with the age of the lesion [11].

Two important comments need to be made. First, leukocytoclasia is not specific to vasculitis. It is just a marker of activation, degranulation and death of neutrophils, and a common feature of other neutrophilic inflammatory conditions,



**Figure 4. Direct immunofluorescence showing IgA small-vessel deposition in a patient with leukocytoclastic vasculitis.**

Courtesy of Dr Steven Billings, Cleveland Clinic (OH, USA).

such as Sweets syndrome for example. Second, the term fibrinoid necrosis, although frequently used, has no clearly defined meaning. Does it mean collagen destruction and cellular death, or does it refer to the accumulation of fibrin and fibrin products, or all of the above? Is it possible that in different situations the same name refers to one or the other or both? The term ‘fibrinoid’ was used for the first time by Neumann in 1880 to describe substances resembling fibrin in their tinctorial behavior [12,13]. Many attempts have been made to establish the nature of ‘fibrinoid’ [13–16]. In 1962, Ruiter [13] studied the skin biopsy specimens from 15 cases with ‘arteriolitis allergica cutis’, the term used at the time to describe LCV. Histochemical staining methods showed that the fibrinoid material in and around the vessel wall consists mainly of fibrin [13]. Studies of the nature of fibrinoid in biopsy samples from patients with rheumatoid arthritis, systemic lupus erythematosus, glomerulonephritis, dermatomyositis and polyarteritis nodosa have also suggested that fibrinoid is, at least in part, an insoluble derivative of fibrinogen [16].

#### Role of immunofluorescence for the diagnosis of LCV

Vascular deposition of immunoreactants by DIF is noted [16–19] in up to 92% of the vasculitic biopsy specimens [20]. Immune globulin deposition occurs early, in the first hours of the onset of the lesion [21]. Destruction and removal of immunoglobulins deposited in the affected dermal vessels begins in less than 48 h, and DIF studies of vasculitic lesions older than 24–48 h may be less likely to be positive [22,23].

There is controversy regarding the classes of immunoglobulins most commonly seen, and the specificity of IgA deposition for Henoch Schonlein purpura [24]. Some authors have reported IgA deposition to occur more often than other classes [7,25]. IgA deposition alone, in the absence of other immunoglobulins, was noted in patients with HSP (FIGURE 4), while IgA deposition in combination with IgM was found in systemic, drug-related and idiopathic LCV [26,27]. Recently, a retrospective review found IgA deposition to yield a positive predictive value of 83% for HSP [17]. Others [18,19] have found IgG or IgM deposition [20,26] to be the predominant immunoglobulins deposited in the vessel walls of patients with LCV [18,23,28]. In addition, C3 has been found to be deposited more frequently and persist longer than immunoglobulins in the vessel walls affected by vasculitis [20,26,29], probably as a reflection of an amplification



step in the complement cascade [30]. ANCA-associated vasculitides are considered ‘pauci-immune’ owing to lack of immunoglobulin deposition in kidney biopsies; while in most cases the skin biopsy is also pauci-immune, there are reports of immunoglobulin deposition in some patients with active disease [31,32].

**How common is cutaneous LCV?**

The incidence of cutaneous vasculitis and LCV is not known. Difficulties in establishing the incidence of LCV arise from variability in definition, the fact that most studies come from tertiary referral centers, and the denominator population is not clearly defined [33]. Watts *et al.* reported an overall annual incidence of biopsy-proven cutaneous vasculitis of 38.6 per million [33]. A retrospective study in Norway found an overall prevalence of hypersensitivity vasculitis of 2.7 per million [34]. Another study in Spain found an annual prevalence of hypersensitivity vasculitis of 29.7 per million population [35]. Using the Chapel Hill definition of cutaneous leukocytoclastic angiitis, the annual incidence in Norfolk (UK) was found to be 15.4 cases per million population.

Men seemed to be affected slightly more often than women [35], while others have found an equal distribution between genders [33]. No seasonal predilection was noted [35]. The

incidence of LCV appears to increase with age, with a peak in the 65–74-year-old age group [33].

**What is the pathogenesis of LCV?**

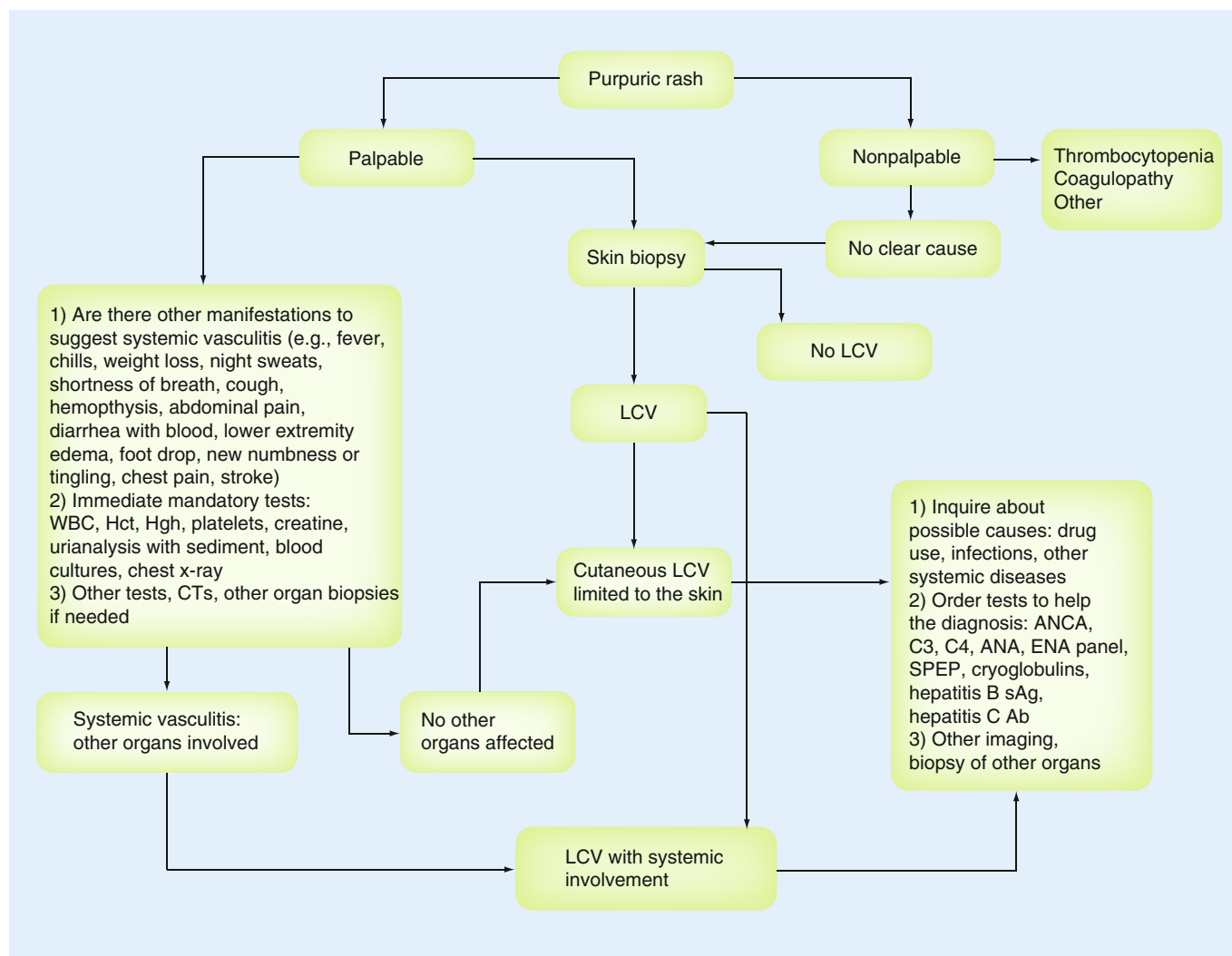
The occurrence of vasculitic lesions is the result of the interplay between injury, triggered by infections, drugs, immune complexes, inflammatory cells and the endothelium.

The skin vascular system is unique in the ability to respond to exogenous and endogenous stimuli. The postcapillary venules are the almost exclusive site of attachment, rolling, arrest and transmigration of leukocytes and permeability in states of inflammation [36,37]. The endothelial cells at this level also show the ability to express a specific repertoire of procoagulants and anticoagulants, constitutively express HLA class II molecules, which implies that endothelial cells play a role in antigen presentation, and express Toll-like receptor (TLR) family members (which are innate pattern recognition receptors stimulated by invading microorganisms), CD32 molecules (FCRIIa, which bind complexed immunoglobulin G and have a role in type III hypersensitivity reactions and immune complex clearing) and histamine H1 receptors (which upon stimulation results in vasodilatation and increased albumin leakage). Thus, LCV is the common response to different aggressors, from microorganisms to circulating

**Table 2. Etiology of leukocytoclastic vasculitis.**

Etiology		Reported frequency of various causes from case series/cohorts of patients with cutaneous vasculitis	Ref.
No etiology found		30–70	[5,26,35,59–62]
Drugs		8.6–36	[5–7,24,42,60,63]
Primary systemic vasculitis	Idiopathic vasculitis	15.4–29.7	[64]
	Henoch–Schonlein purpura	5.2–15	[24,35]
	Churg–Strauss syndrome	1–2	[6,24,35]
	Granulomatosis with polyangiitis	2–4.9	[35,64]
	Microscopic polyangiitis	≤1	[64]
Connective tissue diseases	Sjogren’s syndrome, rheumatoid arthritis, MCTD and so on	6.4–25	[5–7,24,35,41,60]
Malignancies	All malignancies	2.3–8	[6,7,35,41,42,60]
	Lymphoproliferative diseases	2–8	[60]
Infections	All infections	9–36	[42,60,63]
	Bacterial	1–11	[5–7,35,41]
	Viral	3.17	[7]
	Hepatitis C	19	[24]
	Hepatitis B	5	[24]
Paraproteins cryoglobulinemia <sup>†</sup>	Cryoglobulinemia	2–4.8	[6,42,64]

<sup>†</sup>Nonhepatitis B and C related.  
MCTD: Mixed connective tissue disease.



**Figure 5. Algorithm of diagnosis of cutaneous leukocytoclastic vasculitis.**

Ab: Antibody; Ag: Antigen; ANCA: Anti-neutrophil cytoplasmic antibody; ANA: Anti-nuclear antibody; C3: Complement component 3; C4: Complement component 4; CT: Computed tomography; ENA: Extractable nuclear antigen; Hct: Hematocrit; Hgh: Human growth hormone; LCV: Leukocytoclastic vasculitis; SPEP: Serum protein electrophoresis; WBC: White blood cell.

immune complexes – possibly influenced by the heterogeneity of the endothelial receptors present at the level of the postcapillary venules.

The pathogenesis of LCV is poorly understood. As is the case for many other autoimmune diseases, complex interactions between genetic and environmental factors are at play: loss of self-tolerance and triggering environmental exposures. Most authors consider immune complex deposition in the vessel walls to be the initial step in the development of the disease. This is supported by the detection, in many cases, of immunoglobulins and complement deposition in the affected blood vessels. Animal and human experimental evidence suggests a pathological process similar to experimental Arthus reaction [38]. In the case of antigen excess, circulating antigen antibody immune complexes eventually deposit in the blood vessel walls. The complement

components are activated and generate chemotactic factors (C3a, C5a) that attract neutrophils and basophils. Activated neutrophils release adhesion molecules and cytokines, collagenases and elastases, along with free oxygen radicals, leading to vessel wall destruction. Other types of Gell and Coombs immune responses have been described in various small-vessel vasculitides. For example, other mechanisms that lead to activation of neutrophils must be at play in cases of LCV, such as ANCA-associated vasculitides illustrated by a complex interplay between known (silica, *Staphylococcus aureus* infection) and unknown environmental factors, and an activated immune system that involves both T- and B-cell response as well as a pathogenetic role of ANCA antibodies and alternative complement pathways [39]. Biopsy specimens in these patients generally do not show immune complex deposition in the vessel walls,

hence the term ‘pauci-immune’. Antineutrophil cytoplasmic antibodies have the ability to activate neutrophils and endothelial cells and trigger endothelial damage and neutrophilic infiltrate migration through the vessel wall [40].

**Etiology of cutaneous LCV**

LCV is a diagnostic and therapeutic challenge, because it is the result of any number of disorders. It may be a primary disorder without an identifiable cause, isolated to the skin or involving other organs in the body, or it may be secondary to other autoimmune diseases, various types of infections, drugs or malignancies.

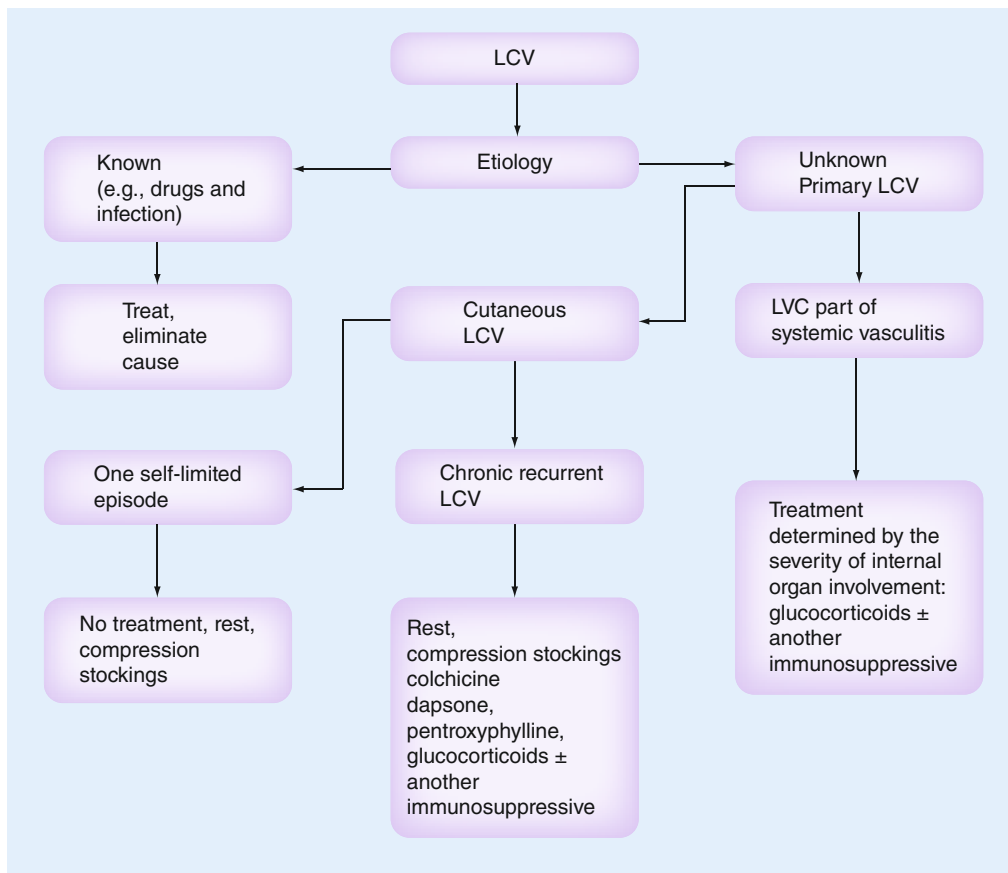
The etiologic spectrum of LCV is different in children and adults. The most common cause of LCV in children is by far Henoch Schonlein purpura [41]. In adults, the etiology of LCV is distributed between systemic vasculitis, autoimmune diseases, malignancies, systemic bacterial infections and drugs; each of these being reported with variable frequencies depending on the selection criteria of vasculitis cases, and the definitions used (TABLE 2). A causal agent or an associated condition is identified in 54–67.2% of LCV patients [7,24].

**How to evaluate a patient presenting with a purpuric rash**

When interviewing a patient with purpura the clinician has to answer the following questions: is the purpura due to vasculitis or not? If it is due to vasculitis, what is the cause, and are there any internal organs involved?

The history and physical examination thus have two main goals: screen for systemic, life-threatening or organ-threatening vasculitis; and inquire about possible etiology (drugs, infections or systemic diseases).

It is imperative that a thorough review of systems and a detailed physical examination is performed the first time the patient presents with purpura in order to establish whether the cutaneous manifestations are isolated to the skin or part of a systemic vasculitic process. The clinician should pay special attention to target organs (lungs, kidneys, peripheral nervous system, heart and GI tract) that can be affected by systemic small-vessel vasculitis and damaged rapidly and irreversibly, leading to life-threatening situations. This should be immediately followed by a urinalysis to screen for glomerulonephritis, a chest x-ray



**Figure 6. Schematic approach to the treatment of leukocytoclastic vasculitis.**

LCV: Leukocytoclastic vasculitis.

Table 3. Summary of treatments used for patients with cutaneous vasculitis.

Measure	Dose	Level of evidence/ comment	Ref.
Leg elevation when supine and compression stockings		Level III: no studies	
Antihistamines		Level III: no benefit	[65]
Prednisone	Up to 1 mg/kg/day with slow taper to prevent rebound (4–6 weeks)	Level II–III: benefit	[65]
Colchicine	0.6 mg One- to three-times a day	Level I–III: benefit No benefit	[29,47,50] [29]
Dapsone	50–200 mg/kg/day [51]	Level III: benefit No benefit	[51,66–70] [65]
Pentoxifylline	400 mg three-times daily	Level III: benefit	[71,72]
Azathioprine	Up to 2 mg/kg/day	Level III: benefit	[73]
Hydroxychloroquine	200–400 mg per day	Level III: benefit	[74] <sup>†</sup>
Rituximab	1000 mg iv. at 2-week intervals	Level I–III: benefit <sup>†</sup>	[43,53–55,75–78] <sup>†‡§¶</sup>
iv. immunoglobulin		Level III: benefit	[79–81] <sup>#</sup>

<sup>†</sup>In urticarial vasculitis.  
<sup>‡</sup>In cryoglobulinemic vasculitis.  
<sup>§</sup>Rheumatoid arthritis vasculitic ulcers.  
<sup>¶</sup>Anti-neutrophil cytoplasmic antibody-associated vasculitis.  
<sup>#</sup>Partial response.  
*Evidence level: level III – opinion of respected authorities, descriptive studies; Level II – one controlled trial no randomization; Level II – two well-designed cohorts, case-control studies; Level II – three multiple series, dramatic results in uncontrolled studies; Level I – at least one well-designed randomized controlled study.*  
 iv.: Intravenous.

to exclude bilateral infiltrates suggestive of alveolar hemorrhage and basic blood work, which should include a white cell count, hemoglobin (to screen for hemorrhage) and platelets (usually elevated or normal but not low in patients with primary vasculitides), as well as creatinine.

While a difficult task, it is recommended that a drug history going back to the past 6 months should be elicited (FIGURE 5).

### Prognosis of cutaneous LCV

When systemic cases are excluded, skin-limited LCV is thought to have a good prognosis [35], albeit not by all. Several studies have described a less favorable course, with complete remission recorded in approximately half of the patients at 6 months to 1 year, and persistence of symptoms in a chronic relapsing course for months and years in others [25,42]. Chronicity was predicted by the presence of arthralgias and cryoglobulinemia and absence of fever [24].

### Treatment

The treatment of LCV depends on two major factors: the etiology and the extent of disease (FIGURE 6).

When LCV is a manifestation of a defined condition such as an infection (i.e., subacute bacterial endocarditis, hepatitis C or a known drug) eliminating or treating the cause when possible is essential. When LCV is a manifestation of a systemic vasculitic process (i.e., granulomatosis with polyangiitis, Churg–Strauss syndrome), the treatment will often be determined by the severity of internal organ involvement and will generally require a combination of steroids and another immunosuppressive drug. The number of drugs available is increasing. In the current era of biologic therapies, rituximab now has an established role in the treatment of ANCA-associated vasculitides, as well as in cryoglobulinemic vasculitis [43], while other drugs targeting various cytokines, such as IL-6 [44] and IL-5 [45], offer promise for the future.

### How do we approach patients in whom LCV is the only clinical manifestation & no inciting agent is found?

There are no controlled studies to guide the treatment of patients with chronic recurrent cutaneous LCV.



Chronic and recurrent cases of LCV require treatment strategies that are effective and with minimal side effects [46]. Open-label studies and expert opinion have suggested a variety of possibilities for therapies (TABLE 3) in various types of cutaneous vasculitides, and at this time we can only extrapolate from the scant information they provide.

Bed rest, elevation of the lower extremities, NSAIDs, analgesics and antihistamines are used to treat the associated symptoms of burning and/or pruritis without altering the course of the disease or preventing recurrences.

When the vasculitic rash is more aggressive (i.e., bullous, ulcerative or nodular) and/or recurrent, the addition of other medications is required.

Drugs effective in dermatoses with abnormal neutrophilic accumulation, such as colchicine and

dapsone, have been found useful in the treatment of LCV, HSP and urticarial vasculitis in some, but not all, patients [29,47–51]. If colchicine fails, dapsone can be substituted or sometimes added. In nonresponders with persistent lesions, low-dose corticosteroids such as prednisone 10–20 mg daily can be added. Higher doses (0.5–1 mg/kg) have occasionally to be used for blistering, necrotizing lesions prone to ulceration [52]. Prednisone should be tapered slowly to prevent a rebound of the vasculitic rash. Persistent chronic cases may resolve with the addition of daily azathioprine [52]. Most recently rituximab, a biologic monoclonal antibody directed against CD20-positive cells, has been proven to be very effective in the treatment of LCV in conjunction with cryoglobulinemia, primary, or secondary in the setting of hepatitis C infection or Sjogren's syndrome and ANCA-associated vasculitides [53–55].

### Executive summary

#### **Purpura**

- Purpura is a cutaneous nonblanching rash, due to extravasated red blood cells, caused by a failure of one or more of the mechanisms that maintain the integrity of the vessel wall.

#### **Cutaneous leukocytoclastic vasculitis**

- Cutaneous leukocytoclastic vasculitis is a histopathologic term that refers to vasculitis limited to the small vessels in the skin in which the inflammatory infiltrate is composed of neutrophils and accompanied by leukocytoclasia, fibrinoid necrosis, damage of endothelial cells and extravasation of red blood cells.
- This term was introduced by consensus in 1994 by the Chapel Hill International Consensus Conference to replace the previously used term of hypersensitivity angitis.

#### **Diagnosis of cutaneous leukocytoclastic vasculitis**

- The first goal when approaching a patient with cutaneous leukocytoclastic vasculitis is to exclude systemic organ involvement.
- The second goal when approaching a patient with cutaneous leukocytoclastic vasculitis is to try to establish the etiology.

#### **Simple tests to be carried out immediately that help exclude severe organ disease in patients presenting with cutaneous vasculitis**

- Urinalysis, white blood cell, red cell and platelet counts, creatinine, albumin and chest x-ray are immediate mandatory tests.
- When suspicion is high, blood cultures should be obtained.

#### **Additional testing to help establish the etiology of leukocytoclastic vasculitis**

- Anti-neutrophil cytoplasmic antibody, hepatitis B and C serologies, cryoglobulins, rheumatoid factor, protein electrophoresis, ANA, SSA and SSB antibodies, C3 and C4 complement.

#### **Role of skin biopsy in the diagnosis of leukocytoclastic vasculitis**

- Biopsy a fresh lesion (< 48 h old).
- Two deep skin biopsies should be performed, one for histology and one for direct immunofluorescence staining.

#### **Treatment of leukocytoclastic vasculitis depends on the cause, severity & extent of skin & systemic involvement**

- Once the clinician has established that the leukocytoclastic vasculitis (LCV) is limited to the skin the clinical approach should be directed at eliminating the cause if possible. Stepwise treatment approach should include: leg elevation, compression stockings, colchicine, dapsone, pentoxifylline and low-dose steroids. Additional immunosuppressive therapy is indicated in persistent cases along with a continued search for a cause/associated disease.
- For those cases of LCV in the setting of systemic disease the treatment is determined by the most severe organ involved. The clinician should try to eliminate cause if known as well as treat, usually with a combination of steroids and another immunosuppressive agent.

#### **Conclusion**

- Cutaneous LCV can present as isolated or part of systemic disease.
- Always exclude internal organ involvement/systemic disease in patients with cutaneous vasculitis.
- The future may bring clarification on whether cutaneous LCV is a true separate entity, as well as the role played by the vascular endothelium in this process.

### Future perspective

Despite numerous attempts at naming and classification it remains to be proven that cutaneous LCV is a separate entity and not a limited presentation of a variety of different small-vessel vasculitides. In other words, is the endothelium of the small vessels in the skin a mere responder to an overwhelming insult (therefore, is cutaneous vasculitis always 'secondary') or are there instances when the vascular endothelium in the small cutaneous vessel is in itself the inciting agent to an inflammatory attack? Further studies are necessary and these should include and longitudinally follow patients with idiopathic LCV limited to the skin in order to prove whether this is truly a specific entity.

The future also holds promise for new biologic therapies targeted more precisely to the pathogenetic mechanism responsible for vasculitis. Further studies are needed to establish the role of targeting IL-5, IL-6 and IFN- $\gamma$  in granulomatous vasculitides [56].

### Financial & competing interests disclosure

*The authors have no relevant affiliations or financial involvement with any organization or entity with a financial interest in or financial conflict with the subject matter or materials discussed in the manuscript. This includes employment, consultancies, honoraria, stock ownership or options, expert testimony, grants or patents received or pending, or royalties.*

*No writing assistance was utilized in the production of this manuscript.*

### References

- Lie JT. Nomenclature and classification of vasculitis: plus ca change, plus c'est la meme chose. *Arthritis Rheum.* 37, 181–186 (1994).
- Zeek PM, Smith CC, Weeter JC. Studies on periarteritis nodosa. The differentiation between the vascular lesions of periarteritis nodosa and hypersensitivity. *Am. J. Pathol.* 24, 889–917 (1948).
- Michel BA, Hunder GG, Bloch DA, Calabrese LH. Hypersensitivity vasculitis and Henoch-Schonlein purpura: a comparison between the two disorders. *J. Rheum.* 19, 721–728 (1992).
- Jennette JC, Falk RJ, Andrassy K *et al.* Nomenclature of systemic vasculitides. Proposal of an international consensus conference. *Arthritis Rheum.* 37, 187–192 (1994).
- Ekenstam E, Callen JP. Cutaneous leukocytoclastic vasculitis. Clinical and laboratory features of 82 patients seen in private practice. *Arch. Dermatol.* 120, 484–489 (1984).
- Sanchez NP, Van Hale HM, Su D. Clinical and histopathological spectrum of necrotizing vasculitis. *Arch. Dermatol.* 122(1), 220–224 (1985).
- Herrmann WA, Kauffmann RH, van Es LA, Daha MR, Meijer JLM. Allergic vasculitis. A histological and immunofluorescent study of lesional and nonlesional skin in relation to circulating immune complexes. *Arch. Dermatol.* 269, 179–187 (1980).
- Carlson JA. The histological assessment of cutaneous vasculitis. *Histopathology* 56(1), 3–23 (2010).
- Stone JH, Nousari HC. 'Essential' cutaneous vasculitis: what every rheumatologist should know about vasculitis of the skin. *Curr. Opin. Rheumatol.* 13, 23–34 (2001).
- Fiorentino DF. Cutaneous vasculitis. *J. Am. Acad. Dermatol.* 48, 311–340 (2003).
- Russel Jones R, Eady RA. Endothelial cell pathology as a marker for urticarial vasculitis. A light microscopic study. *Br. J. Dermatol.* 110, 139–149 (1984).
- Neumann E. Die Picrorocarminfärbung und ihre Anwendung auf die Entzündungslehre. *Arch. Microsk. Anat. Entwicklungsmech* 25, 130–150 (1880).
- Ruiter M. Vascular fibrinoid in cutaneous 'allergic' arteriolaritis. *J. Invest. Dermatol.* 38, 85–92 (1962).
- Montgomery PO'B, Muirhead EE. A differentiation of certain types of fibrinoid and hyalin. *Am. J. Pathol.* 33, 285–291 (1957).
- Gitlin D, Craig JM. Variations in the staining characteristics of human fibrin. *Am. J. Pathol.* 33, 267–282 (1957).
- Gitlin D, Craig JM, Janeway CA. Studies on the nature of fibrinoid in the collagen diseases. *Am. J. Pathol.* 33, 55–77 (1957).
- Linskey KR, Kroshinsky D, Mihm MC Jr, Hoang MP. Immunoglobulin A-associated small-vessel vasculitis: a 10-year experience at the Massachusetts General Hospital. *J. Am. Acad. Dermatol.* 66(5), 813–822 (2012).
- Schroeter AL, Copeman PWM, Jordan RE, Sams WM, Winkelmann RK. Immunofluorescence of cutaneous vasculitis associated with systemic disease. *Arch. Dermatol.* 104, 254–259 (1971).
- Gibson LE. Cutaneous vasculitis: approach to diagnosis and systemic associations. *Mayo Clin. Proc.* 65, 221–229 (1990).
- Grunwald MH, Avinoach I, Amichai B, Halevy S. Leukocytoclastic vasculitis – correlation between different histologic stages and direct immunofluorescence results. *Int. J. Dermatol.* 36, 349–352 (1997).
- Gower RG, Sams WM, Thorne EG, Kohler PF, Claman HN. Leukocytoclastic vasculitis: sequential appearance of immunoreactants and cellular changes in serial biopsies. *J. Invest. Dermatol.* 69, 477–484 (1977).
- Braverman IM, Yen A. Demonstration of immune complexes in spontaneous and histamine – induced lesions and in normal skin of patients with leukocytoclastic angiitis. *J. Invest. Dermatol.* 64, 105–112 (1975).
- Kulthanan K, Pinkaew S, Jiamton S, Mahaisavariya P, Suthipinittharm P. Cutaneous leukocytoclastic vasculitis: the yield of direct immunofluorescence study. *J. Med. Assoc. Thai.* 87, 531–535 (2004).
- Sais G, Vidaller A, Jucgla A, Servitje O, Condom E, Peyri J. Prognostic factors in leukocytoclastic vasculitis. *Arch. Dermatol.* 134, 309–315 (1998).
- Barnadas MA, Perez E, Gich I *et al.* Diagnostic, prognostic and pathogenetic value of the direct immunofluorescence test in cutaneous leukocytoclastic vasculitis. *Int. J. Dermatol.* 43, 19–26 (2004).
- Mackel SE, Jordan RE. Leukocytoclastic vasculitis. *Arch. Dermatol.* 18, 296–301 (1982).
- Magro C, Crowson AN. A clinical and histologic study of 37 cases of immunoglobulin A associated vasculitis. *Am. J. Dermatol.* 21, 234–240 (1999).
- Claudy A. Pathogenesis of leukocytoclastic vasculitis. *Eur. J. Dermatol.* 8, 75–79 (1998).
- Sais G, Vidaller A, Jucgla A, Gallardo F, Jordi P. Colchicine in the treatment of cutaneous leukocytoclastic vasculitis: results of a prospective, randomized controlled trial. *Arch. Dermatol.* 131, 1399–1402 (1995).
- Sams WM, Thorne EG, Small P, Mass MF, McIntosh RM, Stanford RE. Leukocytoclastic vasculitis. *Arch. Dermatol.* 112, 219–226 (1976).

- 31 Brons RH, de Jong MC, de Boer NK, Stegeman CA, Kallenberg CG, Tervaert JW. Detection of immune deposits in skin lesions of patients with Wegener's granulomatosis. *Ann. Rheum. Dis.* 60(12), 1097–1102 (2001).
- 32 Chhabra S, Minz RW, Rani L, Sharma N, Sakhuja V, Sharma A. Immune deposits in cutaneous lesions of Wegener's granulomatosis: predictor of an active disease. *Indian J. Dermatol.* 56(6), 758–762 (2011).
- 33 Watts RA, Jolliffe VA, Grattan CEH, Elliott J, Lockwood M, Scott DGI. Cutaneous vasculitis in a defined population – clinical and epidemiological associations. *J. Rheum.* 25, 920–924 (1998).
- 34 Haugeberg G, Bie R, Bendvold A, Storm Larsen A, Johnsen V. Primary vasculitis in a Norwegian community hospital: a retrospective study. *Clin. Rheum.* 17, 364–368 (1998).
- 35 Garcia-Porrúa C, Gonzales-Gay MA. Comparative clinical and epidemiologic study of hypersensitivity vasculitis versus Henoch–Schonlein purpura in adults. *Semin. Arthritis Rheum.* 28, 404–412 (1999).
- 36 Aird WC. Phenotypic heterogeneity of the endothelium: II. Representative vascular beds. *Circ. Res.* 100(2), 174–190 (2007).
- 37 Aird WC. Phenotypic heterogeneity of the endothelium: I. Structure, function, and mechanisms. *Circ. Res.* 100(2), 158–173 (2007).
- 38 Chochrane CG, Weigle WO. The cutaneous reaction to soluble antigen–antibody complexes. *J. Exp. Med.* 108, 591–604 (1958).
- 39 Cartin-Ceba R, Peikert T, Specks U. Pathogenesis of ANCA-associated vasculitis. *Curr. Rheumatol. Rep.* 14(6), 481–493 (2012).
- 40 Gomez-Puerta JA, Bosch X. Antineutrophil cytoplasmic antibody pathogenesis in small-vessel vasculitis: an update. *Am. J. Pathol.* 175(5), 1790–1798 (2009).
- 41 Blanco R, Martinez-Taboada VM, Rodriguez-Vaverde V, Garcia-Fuentes M. Cutaneous vasculitis in children and adults. Associated diseases and etiologic factors in 303 patients. *Medicine (Baltimore)* 77, 403–418 (1998).
- 42 Bernard C, Couilliet D, Meyer P, Grosshans E. The severity of histopathological changes of leukocytoclastic vasculitis is not predictive of extracutaneous involvement. *Am. J. Dermatol.* 21, 532–540 (1999).
- 43 De Vita S, Quartuccio L, Isola M *et al.* A randomized controlled trial of rituximab for the treatment of severe cryoglobulinemic vasculitis. *Arthritis Rheum.* 64(3), 843–853 (2012).
- 44 Sumida K, Ubara Y, Takemoto F, Takaichi K. Successful treatment with humanised anti-interleukin-6 receptor antibody for multidrug-refractory and anti-tumour necrosis factor-resistant systemic rheumatoid vasculitis. *Clin. Exp. Rheumatol.* 29(1 Suppl. 64), S133 (2011).
- 45 Kim S, Marigowda G, Oren E, Israel E, Wechsler ME. Mepolizumab as a steroid-sparing treatment option in patients with Churg–Strauss syndrome. *J. Allergy Clin. Immunol.* 125(6), 1336–1343 (2010).
- 46 Callen JP. Cutaneous vasculitis. What have we learned in the past 20 years? *Arch. Dermatol.* 134, 355–357 (1998).
- 47 Callen JP. Colchicine is effective in controlling chronic cutaneous leukocytoclastic vasculitis. *J. Am. Acad. Rheum.* 13, 193–200 (1985).
- 48 Zhu YI, Stiller MJ. Dapsone and sulfones in dermatology: overview and update. *J. Am. Acad. Dermatol.* 45, 420–434 (2001).
- 49 Iqbal H, A E. Dapsone for Henoch–Schonlein purpura: a case series. *Arch. Dis. Child.* 90, 985–986 (2005).
- 50 Hazen PG, Michel B. Management of necrotizing vasculitis with colchicine. Improvement in patients with cutaneous lesions and Behcet's syndrome. *Arch. Dermatol.* 115, 1303–1306 (1979).
- 51 Fredenberg MF, Malkinson FD. Sulfone therapy in the treatment of leukocytoclastic vasculitis. *J. Am. Acad. Dermatol.* 16, 772–778 (1987).
- 52 Sunderkotter C, Bonsmann G, Sindrilyar A, Luger T. Management of leukocytoclastic vasculitis. *J. Dermatolog. Treat.* 16, 193–206 (2005).
- 53 Terrier B, Krastinova E, Marie I *et al.* Management of noninfectious mixed cryoglobulinemia vasculitis: data from 242 cases included in the CryoVas survey. *Blood* 119(25), 5996–6004 (2012).
- 54 Ferri C, Cacoub P, Mazzaro C *et al.* Treatment with rituximab in patients with mixed cryoglobulinemia syndrome: results of multicenter cohort study and review of the literature. *Autoimmun. Rev.* 11(1), 48–55 (2011).
- 55 Ferri C, Sebastiani M, Antonelli A, Colaci M, Manfredi A, Giuggioli D. Current treatment of hepatitis C-associated rheumatic diseases. *Arthritis Res. Ther.* 14(3), 215 (2012).
- 56 Hoffman GS. What does the future hold for clinical studies in vasculitis? *Clin. Exp. Immunol.* 164(Suppl. 1), 35–38 (2011).
- 57 Bologna JL, Braverman IM. Skin manifestations of internal disease. In: *Harrison's Principles of Internal Medicine*. Fauci AS, Braunwald E, Isselbacher KJ *et al.* (Eds). McGraw-Hill, NY, USA, 326–3267 (1998).
- 58 Carlson JA, Chen K-R. Cutaneous vasculitis update: neutrophilic muscular vessel and eosinophilic, granulomatous, and lymphocytic vasculitic syndromes. *Am. J. Dermatopathol.* 29, 32–43 (2007).
- 59 Callen JP. Cutaneous vasculitis and other neutrophilic dermatosis. *Curr. Opin. Rheum.* 5, 33–40 (1993).
- 60 Jessop SJ. Cutaneous leukocytoclastic vasculitis: a clinical and etiological study. *Br. J. Rheum.* 34, 942–945 (1995).
- 61 Martinez-Taboada Vm, Blanco R, Garcia-Fuentes M, Rodriguez-Valverde V. Clinical features and outcome of 95 patients with hypersensitivity vasculitis. *Am. J. Med.* 102, 186–191 (1997).
- 62 Chua SH, Lim JTE, Ang CB. Cutaneous vasculitis seen at a skin referral center in Singapore. *Singapore Med. J.* 40, 147–150 (1999).
- 63 McCombs RP. Systemic 'allergic' vasculitis. *JAMA* 194, 157–161 (1965).
- 64 Carlson JA, Ng BT, Chen K-R. Cutaneous vasculitis update: diagnostic criteria, classification, epidemiology, etiology, pathogenesis, evaluation and prognosis. *Am. J. Dermatopathol.* 27, 504–528 (2005).
- 65 Callen JP, Ekenstam E. Cutaneous leukocytoclastic vasculitis: clinical experience in 44 patients. *South. Med. J.* 80, 848–851 (1987).
- 66 Ramelli GP, Bianchetti MG. Dapsone in cutaneous Henoch–Schonlein syndrome – worth a trial. *Acta Paediatr.* 86, 337 (1997).
- 67 Sarma PS. Dapsone in Henoch-Schonlein purpura. *Postgrad. Med. J.* 70, 464–465 (1994).
- 68 Eiser AR, Singh P, Shanies HM. Sustained dapsone-induced remission of hypocomplementemic urticarial vasculitis – a case report. *Angiology* 48, 1019–1022 (1997).
- 69 Fortson JS, Zone JJ, Hammond ME, Groggel GC. Hypocomplementemic urticarial vasculitis syndrome responsive to dapsone. *J. Am. Acad. Dermatol.* 15, 1137–1142 (1986).
- 70 Harris MJ, McWhinney P, Melsom R. Recurrent Henoch–Schonlein purpura controlled with ciclosporin. *J. R. Soc. Med.* 97, 184–185 (2004).
- 71 Wahba-Yahav AV. Chronic leukocytoclastic vasculitis associated with polycythemia vera: effective control with pentoxifylline. *J. Am. Acad. Dermatol.* 26, 1006–1007 (1992).
- 72 Nurenberg W, Grabbe J, Czarnetzki BM. Synergistic effects of pentoxifylline and dapsone in leukocytoclastic vasculitis. *Lancet* 343(8895), 491 (1994).
- 73 Callen JP, Spencer LV, Bhatnagar Burruss J, Holtman J. Azathioprine. An effective,

- corticosteroid-sparing therapy for patients with recalcitrant cutaneous lupus erythematosus or with recalcitrant cutaneous leukocytoclastic vasculitis. *Arch. Dermatol.* 127, 515–522 (1991).
- 74 Lopez LR, Davis KC, Kohler PF, Schocket AL. The hypocomplementemic urticarial-vasculitic syndrome: therapeutic response to hydroxychloroquine. *J. Allergy Clin. Immunol.* 73, 600–603 (1984).
- 75 Swaminath A, Magro CM, Dwyer E. Refractory urticarial vasculitis as a complication of ulcerative colitis successfully treated with rituximab. *J. Clin. Rheum.* 17(5), 281–283 (2011).
- 76 Mukhtyar C, Misbah S, Wilkinson J, Wordsworth P. Refractory urticarial vasculitis responsive to anti-B-cell therapy. *Br. J. Dermatol.* 160(2), 470–472 (2009).
- 77 Assmann G, Pfreundschuh M, Voswinkel J. Rituximab in patients with rheumatoid arthritis and vasculitis-associated cutaneous ulcers. *Clin. Exp. Rheumatol.* 28(1 Suppl. 57), 81–83 (2010).
- 78 Stone JH, Merkel PA, Spiera R *et al.* Rituximab versus cyclophosphamide for ANCA-associated vasculitis. *N. Engl. J. Med.* 363(3), 221–232 (2010).
- 79 Wetter DA, Davis MDP, Yiannias JA *et al.* Effectiveness of intravenous immunoglobulin therapy for skin disease other than toxic epidermal necrolysis: a retrospective review of Mayo Clinic experience. *Mayo Clin. Proc.* 80, 41–47 (2005).
- 80 Ong CS, Benson EM. Successful treatment of chronic leukocytoclastic vasculitis and persistent ulceration with intravenous immunoglobulin. *Br. J. Dermatol.* 143, 447–449 (2000).
- 81 Sais G, Vidaller A, Servitje O, Jugla A, Peyri J. Leukocytoclastic vasculitis and common variable immunodeficiency: successful treatment with intravenous immune globulin. *J. Allergy Clin. Immunol.* 98, 232–233 (1996).