

# Testicular Tumors: What Radiologists Need to Know—Differential Diagnosis, Staging, and Management<sup>1</sup>

Courtney Coursey Moreno, MD  
William C. Small, MD, PhD  
Juan C. Camacho, MD  
Viraj Master, MD, PhD  
Nima Kokabi, MD  
Melinda Lewis, MD  
Matthew Hartman, MD  
Pardeep K. Mittal, MD

**Abbreviations:** AFP =  $\alpha$ -fetoprotein,  $\beta$ -hCG = beta subunit of human chorionic gonadotropin, H-E = hematoxylin-eosin, LDH = lactate dehydrogenase, NSGCT = nonseminomatous germ cell tumor

**RadioGraphics** 2015; 35:400–415

**Published online** 10.1148/rg.352140097

**Content Codes:** **CT** **GU** **MR** **OI** **US**

<sup>1</sup>From the Departments of Radiology and Imaging Sciences (C.C.M., W.C.S., J.C.C., N.K., P.K.M.), Urology (V.M.), and Pathology (M.L.), Emory University School of Medicine, 1364 Clifton Rd NE, Atlanta, GA 30322; and Department of Radiology, West Penn Allegheny Health System, Pittsburgh, Pa (M.H.). Presented as an education exhibit at the 2013 RSNA Annual Meeting. Received March 21, 2014; revision requested June 25 and received July 14; accepted August 12. For this journal-based SA-CME activity, the authors, editor, and reviewers have disclosed no relevant relationships. **Address correspondence to** P.K.M. (e-mail: [pmittal@emory.edu](mailto:pmittal@emory.edu)).

## SA-CME LEARNING OBJECTIVES

After completing this journal-based SA-CME activity, participants will be able to:

- Describe testicular vascular and lymphatic anatomy.
- Discuss the differential diagnosis of solid testicular lesions.
- Describe the TNMS staging system for testicular cancer.

See [www.rsna.org/education/search/RG](http://www.rsna.org/education/search/RG).

Cryptorchidism, family history, and infertility are risk factors for testicular cancer. Most testicular cancers occur in young men aged 18–35 years, and seminoma is the most common cell type. Testicular tumors are usually diagnosed at ultrasonography (US) and are staged at computed tomography (CT) or magnetic resonance (MR) imaging. At US, testicular tumors usually appear as a solid intratesticular mass. Because the differential diagnosis includes infarct and infection, correlation with patient history and symptoms is important. At staging CT or MR imaging, retroperitoneal lymph nodes are considered regional lymph nodes, and the greatest nodal diameter is used to distinguish among N1–N3 disease. The right testicular vein drains into the inferior vena cava, and the left testicular vein drains into the left renal vein. Because of venous and lymphatic drainage pathways, retroperitoneal lymph nodes are the initial landing station for testicular cancers. Enlarged lymph nodes in the supraclavicular region, chest, and pelvis are considered distant metastases. Testicular cancer is initially treated with orchiectomy. The patient may then undergo active surveillance, chemotherapy, radiation therapy, or retroperitoneal lymph node resection, depending primarily on the clinical stage. Radiologists play an important role in initial diagnosis, staging, and imaging surveillance of testicular malignancies.

©RSNA, 2015 • [radiographics.rsna.org](http://radiographics.rsna.org)

## Introduction

The management of testicular cancer is considered an oncologic success story because most cases are curable as a result of advances in chemotherapy (1). The American Cancer Society estimated that 8820 new cases of testicular cancer would be diagnosed in the United States in 2014 but that only about 380 individuals would die of the disease (2). Testicular cancer is the most common tumor in young adult men (3), and the majority of cases occur in young men aged 15–35 (1,4). Radiologists play an important role in identifying the primary tumor, accurately staging disease, and conducting follow-up imaging surveillance. We describe the anatomy of the testes and review the risk factors for testicular cancer. An approach to the differential diagnosis of a testicular mass is presented, with a review of the staging and management of testicular malignancies.

## TEACHING POINTS

- The management of testicular cancer is considered an oncologic success story because most cases are curable as a result of advances in chemotherapy.
- Lymphatic drainage follows venous drainage, such that the testes drain into paraaortic and paracaval lymph nodes.
- In young men, approximately 95% of testicular cancers are germ cell tumors, and 5% are sex cord–stromal tumors. Approximately 50% of germ cell tumors are seminomas, and approximately 50% are NSGCTs.
- US is used to distinguish between intratesticular masses, which are more commonly malignant, and extratesticular masses, which are more commonly benign. US can also be used to accurately differentiate intratesticular solid masses, which are often malignant, from cystic lesions, which are usually benign.
- Overlap exists between the imaging appearances of testicular tumors and those of nontumorous conditions such as focal infarction, hematoma, and infection, which can also appear as hypoechoic masslike areas with variable internal blood flow. Therefore, correlation with the patient's clinical history is critical to avoid unnecessary surgery.

## Embryology, Anatomy, and Histology

The human testes initially form in the lumbar region of the abdomen. Approximately 21 weeks after conception, the testes begin to migrate into the inguinal canal (5). By 30 weeks after conception, nearly all testes have reached the scrotum (5). In some individuals, the testes fail to descend into the scrotum, a condition termed *cryptorchidism*. In approximately 97% of full-term male infants, the testes are located in the scrotum at birth (6). Most testes that are undescended at birth move into the scrotum during the first 3 months after birth (6).

Each adult testis measures approximately 3 × 3 × 5 cm (7). Each testicular artery arises directly from the aorta, below the origin of the renal arteries (7). The right testicular vein drains into the inferior vena cava, and the left testicular vein drains into the left renal vein (7). Lymphatic drainage follows venous drainage, such that the testes drain into paraaortic and paracaval lymph nodes (7). The lymphatic and venous drainage pathways of the testes explain why paraaortic and paracaval lymph nodes at the level of the kidneys are the initial nodal stations affected by testicular malignancies.

The testes are derived from three sources: mesothelium, mesenchyme, and primordial germ cells (6). Mesothelial cells give rise to the tunica vaginalis, which is the serous covering of the testis (8). Mesenchymal cells give rise to the supporting stromal cells of the testicular interstitium, including endothelial cells and vascular smooth muscle cells. Primordial germ

**Table 1: Classification of Testicular Tumors**

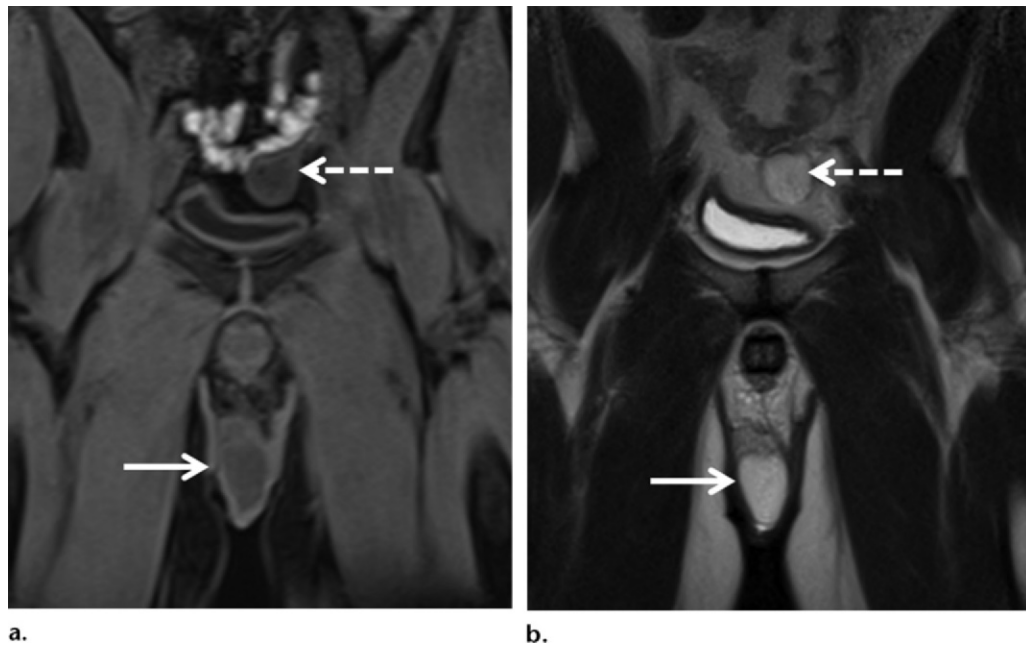
<b>Germ cell tumors</b>
Seminoma
Embryonal carcinoma
Yolk sac tumor
Choriocarcinoma
Teratoma
Mixed germ cell tumor
<b>Sex cord–stromal tumors</b>
Leydig cell tumor
Sertoli cell tumor
Granulosa cell tumor
Thecoma-fibroma
<b>Miscellaneous tumors</b>
Lymphoma
Leukemia
Sarcoma
Leiomyoma
Vascular tumors
Fibroma
Neurofibroma

cells are the pluripotent stem cells that give rise to most testicular tumors (9).

## Types of Testicular Cancers

A classification of testicular tumors is presented in Table 1 (10–12). In young men, approximately 95% of testicular cancers are germ cell tumors, and 5% are sex cord–stromal tumors (13). Approximately 50% of germ cell tumors are seminomas, and approximately 50% are nonseminomatous germ cell tumors (NSGCTs) (14). Of the NSGCTs, 33% are mixed germ cell tumors, 10% are pure embryonal carcinomas, 4% are teratomas, 1% are yolk sac tumors, and 0.3% are choriocarcinomas (14). Sex cord–stromal tumors include Leydig cell tumors, Sertoli cell tumors, granulosa cell tumors, and thecomas.

In men older than 60 years, lymphoma is the most common testicular malignancy (15). Testicular lymphoma is usually a non-Hodgkin lymphoma and carries a poor prognosis (16). Other rare testicular tumors include leukemia, sarcoma, leiomyoma, vascular tumors, fibroma, and neurofibroma (17–19). Metastases to the testes are uncommon. The tumors that most commonly metastasize to the testicle are cancers of the prostate, lung, kidney, and colon; melanoma; and leukemia (20,21). Metastases are bilateral in 8%–15% of cases, and the mean age at presentation was 55 years in one large series (20).



**Figure 1.** Undescended left testicle. **(a)** Coronal nonenhanced T1-weighted MR image shows the low-signal-intensity right testicle (solid arrow) in the scrotal sac and the low-signal-intensity left testicle (dashed arrow) in the left pelvis. **(b)** Coronal T2-weighted MR image shows the high-signal-intensity right testicle (solid arrow) in the scrotal sac and the high-signal-intensity left testicle (dashed arrow) in the left pelvis.

### Risk Factors and Associated Features

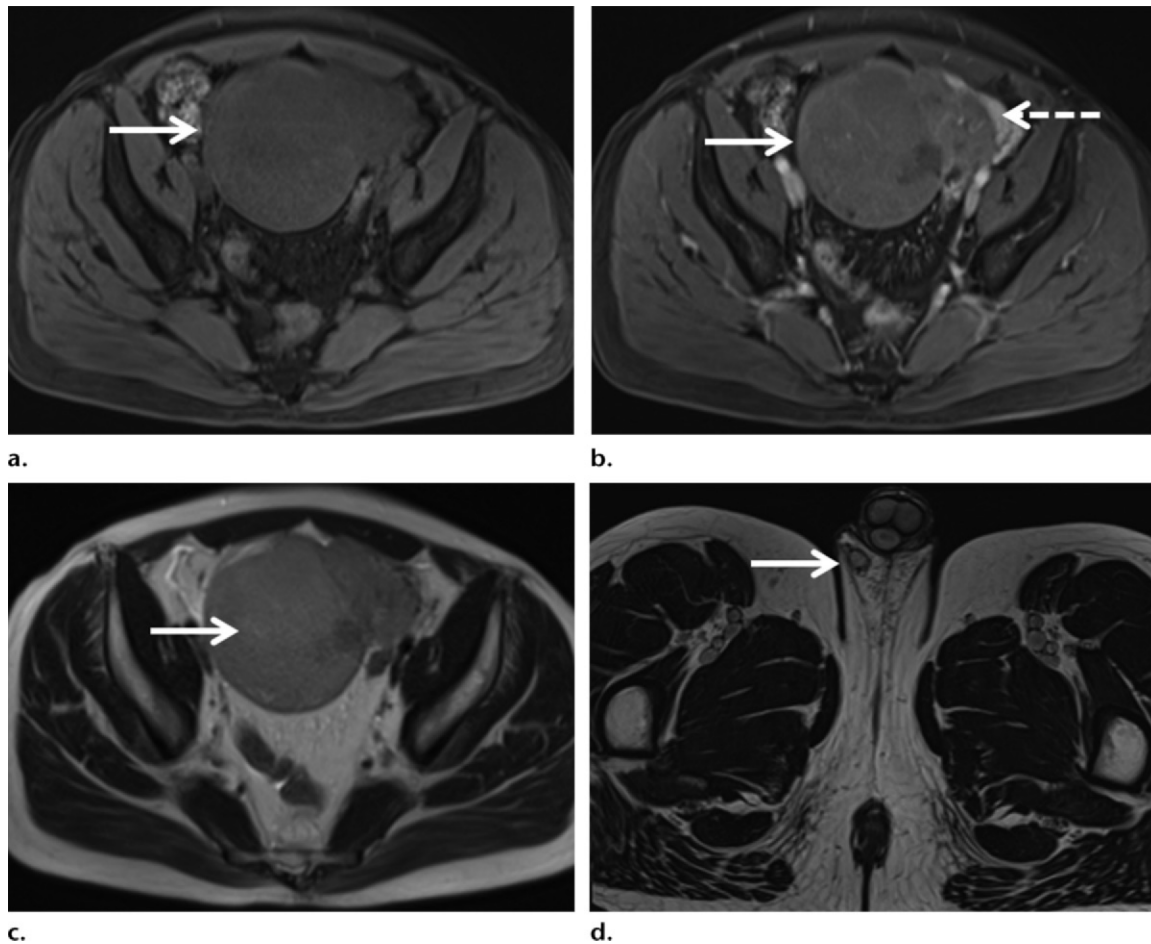
Risk factors for testicular cancer include testicular maldescension (22), family history (23), previous history of testicular cancer, and infertility (24,25). Maldescended testes are usually surgically moved into the scrotum because this reduces the risk of testicular cancer and also allows increased physical examination surveillance for testicular masses (26). This procedure is termed *orchiopexy*. In infants and young children, preoperative ultrasonography (US) is often performed to localize an undescended testis. US has a 45% sensitivity, 78% specificity, and 88% accuracy (27,28) for localization of undescended testes and has been shown to be more accurate than clinical examination (28). However, in older children and adults who do not require sedation, magnetic resonance (MR) imaging is the preferred imaging modality and has been shown to have a higher sensitivity (84%–96%) and specificity (100%) than US for localization of undescended testes (29,30).

In patients with a nonpalpable testis, 39% will have a testis located distal to the external inguinal ring or in the inguinal canal, 41% will have an atrophic or absent testis, and 20% will have an intra-abdominal testis (31). At US, an undescended testis appears similar in echotexture to the contralateral testis but may be smaller. At MR imaging, an undescended testis will demonstrate signal characteristics similar to those of the contralateral testis and usually is homogeneously hypointense at

T1-weighted imaging and homogeneously hyperintense at T2-weighted imaging (Fig 1).

In men with untreated cryptorchidism, an undescended testicle with secondary malignancy may manifest at imaging as an intra-abdominal mass (Fig 2). Diagnostic clues include an ipsilateral draining vein that empties into the inferior vena cava (if right sided) or left renal vein (if left sided) (32). An empty ipsilateral scrotal sac is a further clue to the diagnosis (32).

Controversy exists regarding the association of microlithiasis and testicular malignancy. Testicular microlithiasis is characterized by calcifications in the seminiferous tubules and appears at US as multiple small echogenic foci within the testicular parenchyma (Fig 3). The calcifications usually are so small that they do not produce posterior shadowing. Classic microlithiasis is defined as at least five microliths per image, whereas limited microlithiasis is characterized by fewer calcifications. The prevalence of microlithiasis is approximately 5% in asymptomatic men aged 18–35 years (33). At presentation, the rate of concomitant testicular malignancy is higher in patients with classic microlithiasis than in those without microlithiasis (34). However, there currently is no definite evidence that testicular microlithiasis is a premalignant condition or causes testicular cancer (35). The results of prospective studies indicate that the vast majority of patients with testicular microlithiasis will not develop testicular cancer (36,37).



**Figure 2.** Seminoma in an undescended testis in a 44-year-old man. (a) Axial nonenhanced T1-weighted MR image shows a 10-cm, lobulated, low-signal-intensity mass (arrow) in the anterior pelvis. (b) Axial contrast-enhanced T1-weighted MR image shows enhancement of the mass (solid arrow) and prominent vessels along the left lateral aspect (dashed arrow). These vessels drain into the left renal vein (not shown). (c) Axial T2-weighted MR image shows low signal intensity in the mass (arrow). (d) Axial T2-weighted MR image shows the right spermatic cord (arrow) but no left spermatic cord.

Regular testicular self-examination or physical examination by a physician would be a reasonable surveillance strategy for individuals with microlithiasis (36), and annual US surveillance for several years after the initial observation of microlithiasis has been suggested (34,38).

### Imaging of Testicular Cancers

The radiologist plays an important role in initial identification of a testicular mass, staging, and imaging surveillance.

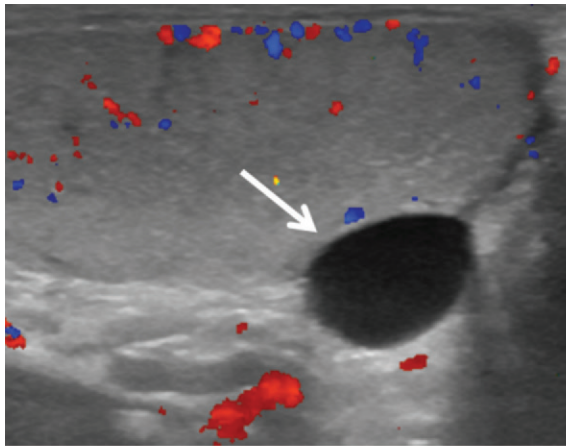
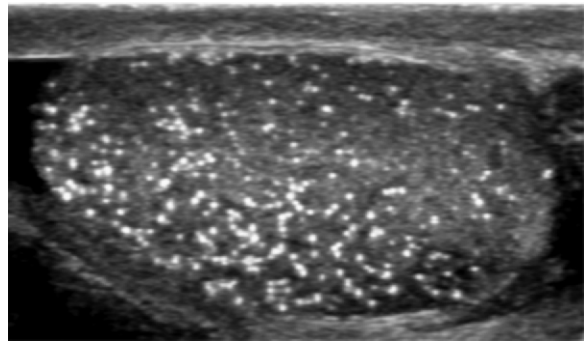
#### Initial Identification

When an individual presents for evaluation of the testes, US performed with a high-frequency (7–10 MHz) transducer with pulsed and color Doppler modes is the preferred imaging study (35). US is used to distinguish between intratesticular masses, which are more commonly malignant, and extratesticular masses, which are more commonly benign (35,39–41). US can also be used to accurately differentiate intratesticular solid

masses, which are often malignant, from cystic lesions, which are usually benign and may include tubular ectasia of the rete testes, simple cysts, and tunica albuginea cysts (Fig 4) (35,42,43). Solid masses usually appear hypoechoic relative to the adjacent testicular parenchyma, and internal vascularity is usually detectable with color Doppler imaging. In comparison, cysts appear anechoic, with no internal vascularity, and usually demonstrate posterior acoustic enhancement.

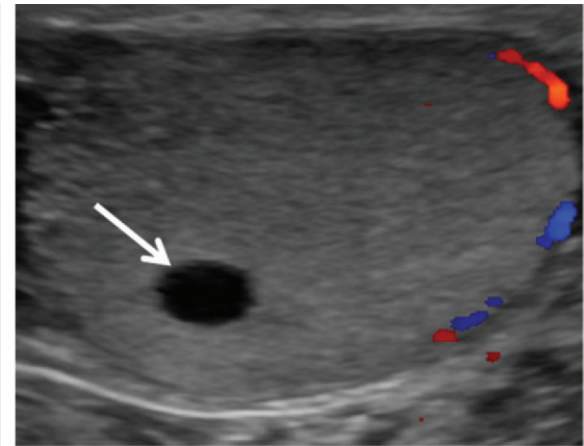
At imaging, a solid intratesticular mass with internal vascularity is suggestive of a testicular tumor in the appropriate clinical setting (44). US has been shown to have a 92%–98% sensitivity and a 95%–99.8% specificity for testicular malignancy (44,45). Although US cannot be reliably used to accurately predict tumor histology, some generalizations can be made (46). Seminomas are often hypoechoic and homogeneous (Fig 5) and infrequently demonstrate calcifications or cystic spaces (46). This homogeneous appearance is reflected at gross pathologic and histologic analysis,

**Figure 3.** Classic testicular microlithiasis in a 24-year-old man. Gray-scale US image shows numerous (>5 per image) echogenic nonshadowing microcalcifications in the testicular parenchyma.

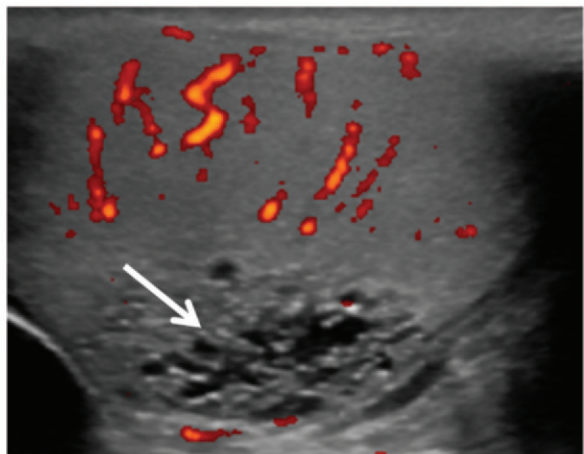


**a.**

**Figure 4.** Benign testicular cystic structures in three different patients. **(a)** Color Doppler US image shows an anechoic tunica albuginea cyst (arrow) with posterior acoustic enhancement and no internal vascularity. **(b)** Color Doppler US image shows an anechoic intratesticular cyst (arrow) with no internal vascularity. **(c)** Color Doppler US image shows multiple clustered anechoic cystic structures (arrow) with no internal vascularity, findings consistent with tubular ectasia of the rete testis.



**b.**

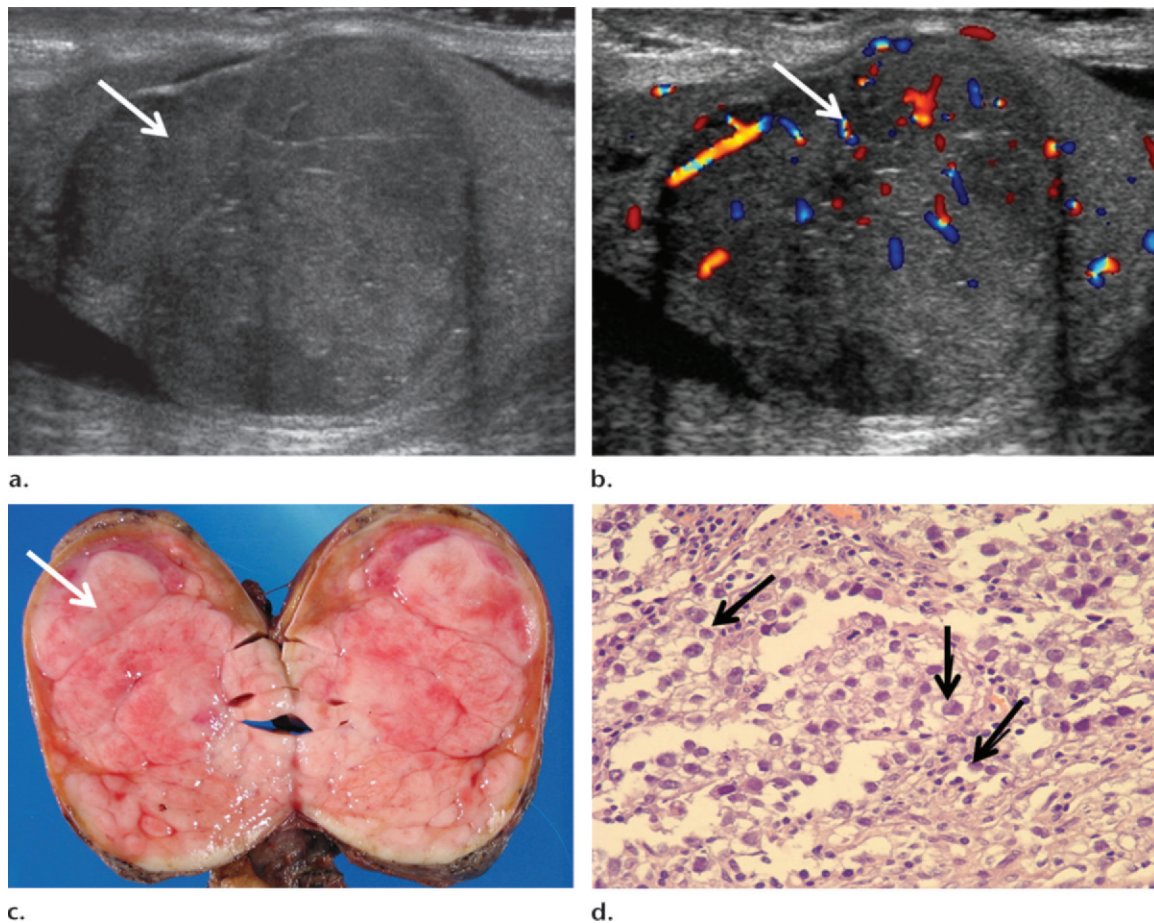


**c.**

where uniform cells are seen (Fig 5). In comparison, NSGCTs are more commonly heterogeneous in echotexture, with most demonstrating cystic spaces (Fig 6) (46). Calcifications are also seen much more frequently in NSGCTs than in seminomas (46). NSGCTs are thought to arise from a totipotential cell line that may undergo varying degrees of differentiation into embryonal, teratoma, yolk sac, or choriocarcinoma components, thus accounting for their heterogeneity (47). In comparison, seminomas are thought to originate from a unipotential cell line (47).

In addition, germ cell tumors may be small or involute, even in the setting of widespread metastatic disease, a phenomenon known as a “burned-out” germ cell tumor. It is thought that some primary testicular malignancies may outgrow their blood supply, which results in regression of the primary tumor (47). All that may be visible in these regressed tumors at US is a small mass or focal calcification (47) (Fig 7).

Age is the most helpful discriminator for testicular lymphoma because lymphoma is the most common testicular malignancy in men older than 60 years (48). At imaging, lymphoma may appear as a diffusely hypoechoic but hyperemic testicle or a focal testicular mass with increased blood flow (Fig 8) (49). Primary testicular lymphoma is most often unilateral but may be bilateral in up to 35% of individuals (48). Secondary testicular involvement with lymphoma may also occur (50). Primary testicular lymphoma is most commonly a B-cell lymphoma (48). Relapsed lymphoma may also occur in the testes (50).



**Figure 5.** Seminoma in a 33-year-old man. (a) Gray-scale US image shows a homogeneous lobular intratesticular mass (arrow). (b) Color Doppler US image shows internal blood flow in the mass (arrow). (c) Photograph of the gross specimen shows a lobular homogeneous mass (arrow). (d) Photomicrograph (original magnification,  $\times 400$ ; hematoxylin-eosin [H-E] stain) of the specimen shows fried egg-like neoplastic cells (arrows). The relative homogeneity of the cell population accounts for the relative homogeneity seen at US.

### Differential Diagnoses

Overlap exists between the imaging appearances of testicular tumors and those of non-tumorous conditions such as focal infarction, hematoma, and infection, which can also appear as hypoechoic masslike areas with variable internal blood flow (35) (Figs 9–11). Therefore, correlation with the patient's clinical history is critical to avoid unnecessary surgery (35,51).

### Infarction and Hematoma

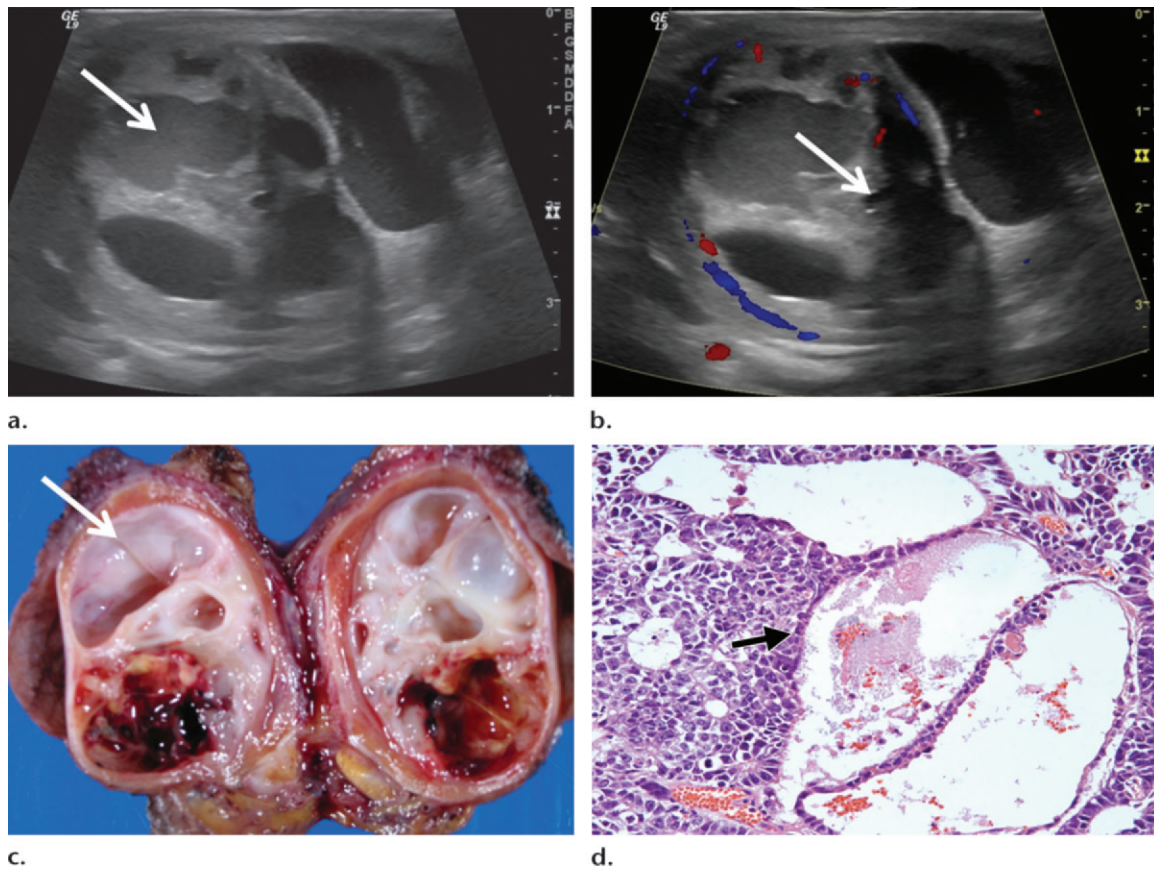
At color Doppler US, infarction (Fig 9) and hematoma (Fig 10) typically have decreased color flow relative to that of the normal testis and may be avascular. Tumors typically have increased color flow relative to that of the normal testis. Patients with testicular infarction usually present with acute pain rather than a painless palpable mass. Patients with an intratesticular hematoma usually present with pain after trauma. If the diagnosis is uncertain on the basis of the imaging features and clinical presentation, short-term follow-up imaging in 2–4 weeks may be helpful because hematomas

usually decrease in size over time, and areas of infarct will become more avascular and more hypoechoic over time (52).

### Infection and Inflammation

Areas of infection often have increased color flow relative to that of the normal testis. Therefore, focal infection could appear similar to a tumor at color Doppler imaging. However, patients with focal orchitis usually present with acute pain and may have a fever and an elevated white blood cell count. Follow-up imaging in 2–4 weeks can help clarify the diagnosis because areas of focal orchitis would be expected to improve with antibiotic therapy (52).

Granulomatous disease (Fig 12) can manifest at US as multiple hypoechoic intratesticular masses with internal vascularity. The recognition that testicular masses could be sequelae of granulomatous disease in a patient with known granulomatous disease (eg, sarcoidosis) may prevent unnecessary orchiectomy because a more conservative approach (eg, close imaging follow-up) may be undertaken.



**Figure 6.** Mixed NSGCT in a 57-year-old man. (a) Gray-scale US image shows a partially cystic and partially solid intratesticular mass (arrow). (b) Color Doppler US image shows internal blood flow in the mass (arrow). (c) Photograph of the gross pathologic specimen shows cystic spaces within the mass (arrow). (d) Photomicrograph (original magnification,  $\times 200$ ; H-E stain) of the specimen shows yolk sac and embryonal cell carcinoma elements (arrow), findings that account for the heterogeneity seen at US.

### Syndromic Lesions

In men with congenital adrenal hyperplasia, bilateral solid testicular masses are likely adrenal rests (53). In men with Cowden disease, multiple randomly distributed, 1–6-mm, hyperechoic, avascular masses are most likely areas of lipomatosis (54).

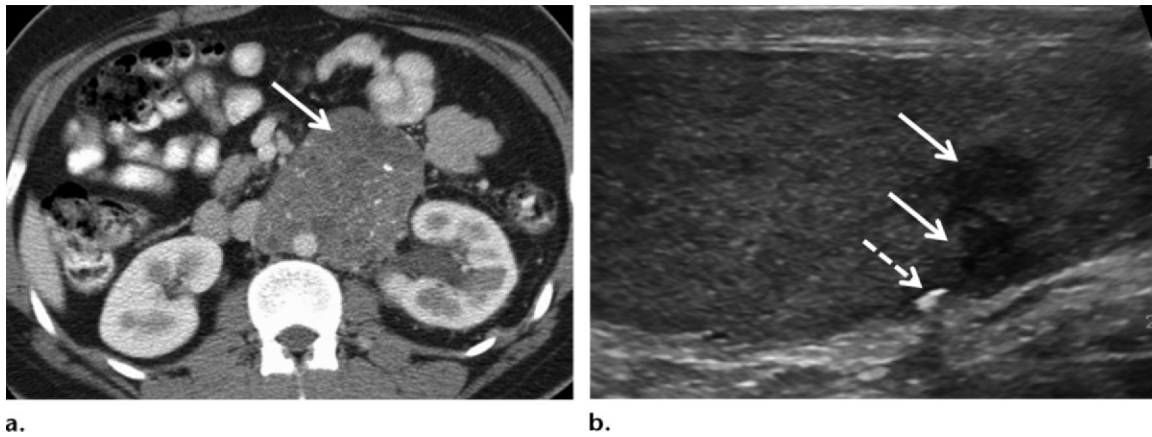
### Epidermoid Cysts

Epidermoid cysts are benign testicular lesions that can sometimes mimic testicular malignancies at US. At histologic analysis, epidermoid cysts appear as unilocular cysts filled with keratin or other desquamated material and are lined with squamous epithelium (55). Because testicular malignancies are much more common than epidermoid cysts, a painless testicular mass, especially in a young man, is more likely a malignancy. However, if a hypoechoic intratesticular mass visible at imaging has an “onion ring” appearance, concentric layers, no internal vascular flow, and a well-defined rim, an epidermoid cyst should be included in the differential diagnosis (Fig 13) (56). This recognition alerts the urologist to the possibility of an epidermoid cyst, which may result in testis-sparing sur-

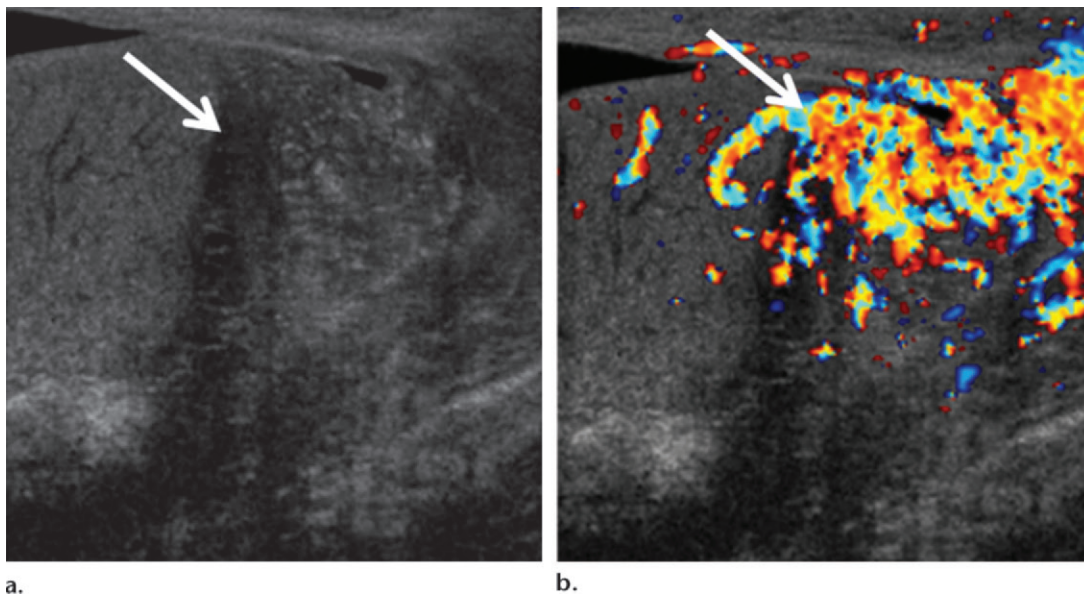
gery, including wedge excision with frozen-section analysis and enucleation, rather than orchiectomy if the lesion is confirmed to be an epidermoid cyst.

### Contrast-enhanced US and MR imaging

Because it is sometimes difficult to distinguish testicular tumors from nontumorous lesions at US, advanced US techniques and MR imaging are being investigated as tools to further characterize testicular lesions. Although it currently is not approved by the U.S. Food and Drug Administration, contrast-enhanced US has shown promise, especially in depicting whether blood flow is present in a testicular lesion (57). Absence of vascularity usually implies a benign lesion, while disordered vascularity implies a malignant lesion (57). In addition, use of real-time sonoelastography may help differentiate between tumorous and nontumorous solid lesions with internal blood flow (58). For example, tumors more typically demonstrate hard elasticity, while nontumorous lesions more typically demonstrate soft elasticity (58).



**Figure 7.** “Burned-out” germ cell tumor in a 43-year-old man. **(a)** Axial contrast-enhanced computed tomographic (CT) image shows a large (>5-cm) retroperitoneal mass (arrow) surrounding the aorta at the level of the kidneys. **(b)** Gray-scale US image shows two adjacent, small, hypochoic structures (solid arrows) and a shadowing calcification (dashed arrow). Histologic analysis showed viable seminoma in the retroperitoneum. In the orchiectomy specimen, no viable tumor was found in the testis.



**Figure 8.** Testicular lymphoma in a 77-year-old man who presented with a swollen left testicle. **(a)** Gray-scale US image shows an ill-defined, heterogeneous, 2-cm mass (arrow). **(b)** Color Doppler US image shows intense blood flow in the mass (arrow).

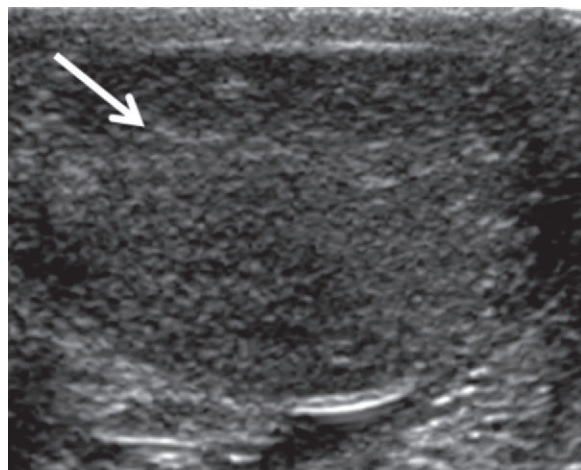
Several recent articles have described the utility of MR imaging in evaluation and characterization of testicular masses (59–62). MR imaging showed a 100% sensitivity and an 88% specificity for differentiation of benign from malignant intratesticular lesions in one series (60). As at US, seminomas typically show homogeneous signal intensity at MR imaging, while mixed germ cell tumors show heterogeneous signal intensity (59,60). Teratomas demonstrate bulk fat with areas of signal loss on fat-saturated MR images (59). Hematomas demonstrate areas of intrinsic signal hyperintensity on T1-weighted images. At contrast-enhanced MR imaging, malignant testicular lesions typically demonstrate enhancement followed by contrast material

washout (62). In comparison, benign lesions demonstrate continuously increasing enhancement or increasing enhancement that plateaus (62).

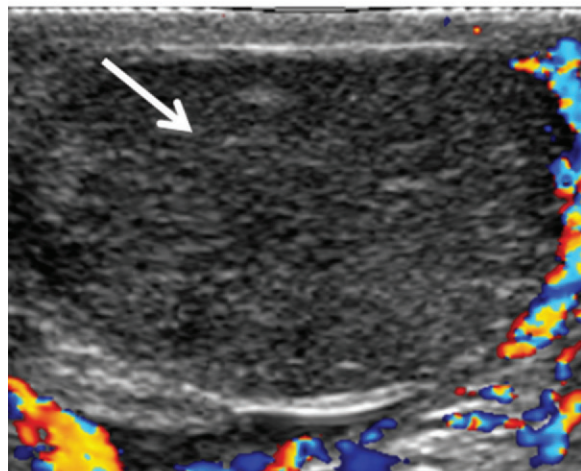
### Staging of Testicular Cancers

Testicular cancer is staged according to the TNMS (tumor, lymph node, metastasis, serum tumor marker) system. The clinical stage is determined on the basis of findings at physical and imaging examinations and laboratory testing (Table 2). The pathologic stage is determined on the basis of histologic evaluation of the resected tissue. The T stage refers to the local extent of the tumor and is determined on the basis of pathologic analysis after orchiectomy (63).





a.



b.

**Figure 9.** Testicular infarction mimicking a testicular mass in a 24-year-old man who presented with a 2-day history of right scrotal pain. (a) Gray-scale US image shows a large hypoechoic area (arrow) in the right testicle. (b) Color Doppler US image shows no internal blood flow in this area (arrow). An infarcted right testicle was confirmed at surgery

## N Stage

The N stage refers to the presence or absence of disease in regional lymph nodes. Abdominal retroperitoneal lymph nodes are considered regional lymph nodes. Tumors involving the left testicle typically spread first to left paraaortic lymph nodes just below the left renal vein. Tumors involving the right testicle typically spread first to paracaval, precaval, and retrocaval lymph nodes.

The sensitivity and specificity of CT in determination of nodal metastases varies depending on the size criteria used (64). In a study by Hilton et al (64) that used a size threshold of 10 mm or more, CT was only 37% sensitive but 100% specific for nodal metastases. Lowering the size threshold to 4 mm or more increased the sensitivity to 93% but decreased the specificity to 58% (64). A CT size threshold of 7–8 mm (short-axis measurement) for retroperito-

**Table 2: Clinical Staging of Testicular Tumors**

### T stage (primary tumor)

- TX: primary tumor cannot be assessed
- T0: no evidence of primary tumor
- Tis: carcinoma in situ (noninvasive cancer cells)
- T1: tumor confined to testicle and epididymis
- T2: tumor breaches tunica vaginalis or has spread to adjacent blood vessels or lymphatics
- T3: tumor growing into the spermatic cord
- T4: tumor growing into the scrotal skin

### N stage (lymph nodes)

- NX: regional lymph nodes cannot be assessed
- N0: no spread to regional lymph nodes visible at imaging
- N1: lymph node disease (<2 cm at greatest dimension)
- N2: lymph node disease (2–5 cm at greatest dimension)
- N3: lymph node disease (>5 cm at greatest dimension)

### M stage (metastasis)

- M0: no distant metastatic disease
- M1a: tumor in distant (nonregional) lymph nodes or lung
- M1b: tumor in other organs (eg, liver, brain, or bone)

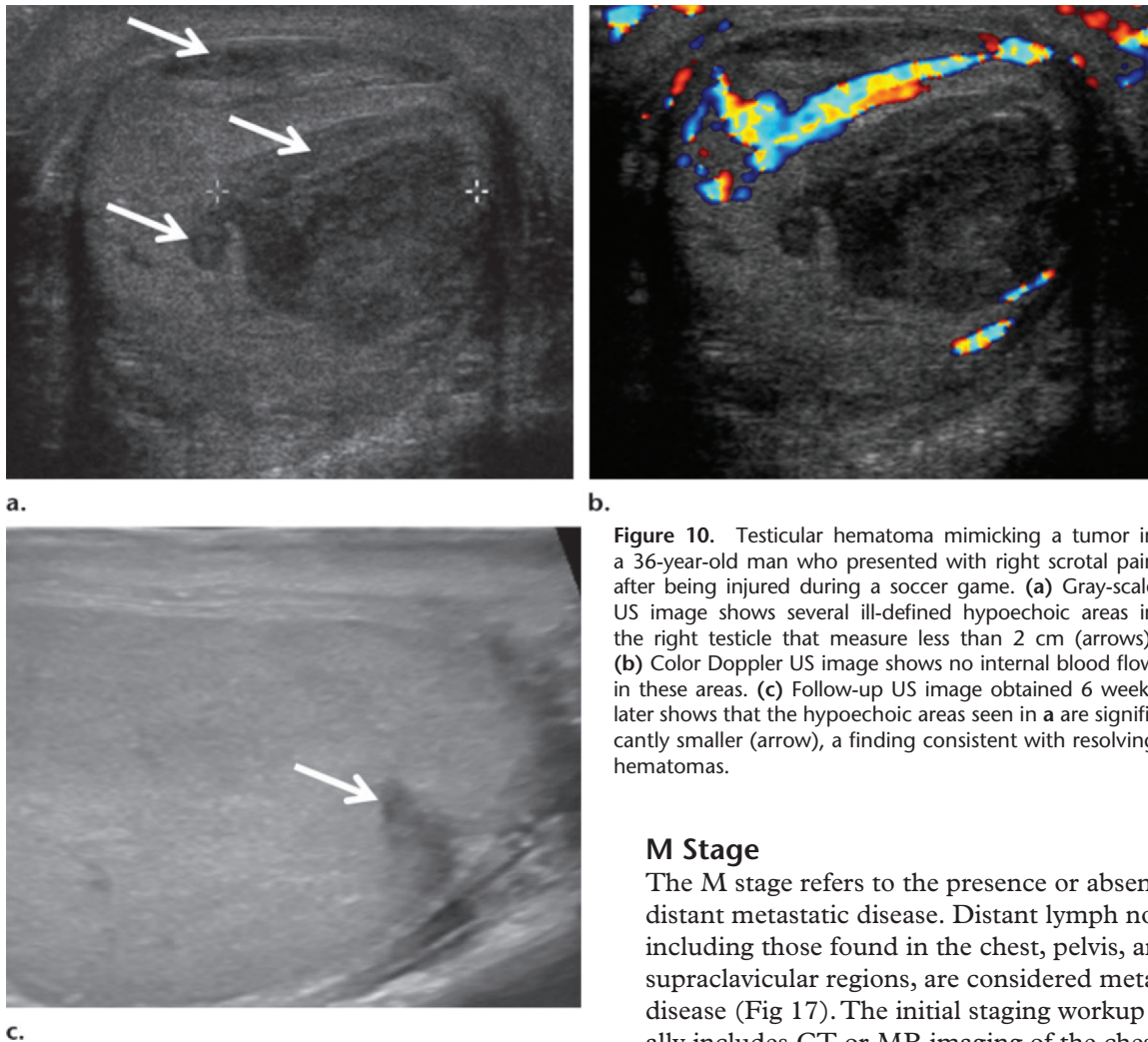
### S stage (serum tumor markers measured after orchiectomy)

- S0: LDH,  $\beta$ -hCG, and AFP values are normal
- S1: LDH < 1.5 times the normal level (measured in units per liter);  $\beta$ -hCG < 5000 mIU/mL; AFP < 1000 ng/mL
- S2: LDH is 1.5–10 times the normal level;  $\beta$ -hCG = 5000–50,000 mIU/mL; AFP = 1000–10,000 ng/mL
- S3: LDH > 10 times the normal level;  $\beta$ -hCG > 50,000 mIU/mL; AFP > 10,000 ng/mL

Note.—AFP =  $\alpha$ -fetoprotein,  $\beta$ -hCG = beta subunit of human chorionic gonadotropin, LDH = lactate dehydrogenase.

neal lymph nodes has been suggested (65,66) and was shown to result in 70% sensitivity and specificity for diagnosis of nodal metastases in patients with testicular cancer in a study by Hudolin et al (66). Morphologic features, including central necrosis and a round or spiculated morphology, are also suggestive of nodal disease (65). It should be noted that although a short-axis measurement of 7–8 mm or more is suggested to distinguish between clinical N0 and N1 disease stages, the greatest diameter of a lymph node is used to distinguish among clinical N1–N3 disease stages (Table 2, Figs 14–17).

The use of MR imaging has been shown to be equivalent to the use of CT for diagnosis of



**Figure 10.** Testicular hematoma mimicking a tumor in a 36-year-old man who presented with right scrotal pain after being injured during a soccer game. **(a)** Gray-scale US image shows several ill-defined hypoechoic areas in the right testicle that measure less than 2 cm (arrows). **(b)** Color Doppler US image shows no internal blood flow in these areas. **(c)** Follow-up US image obtained 6 weeks later shows that the hypoechoic areas seen in **(a)** are significantly smaller (arrow), a finding consistent with resolving hematomas.

### M Stage

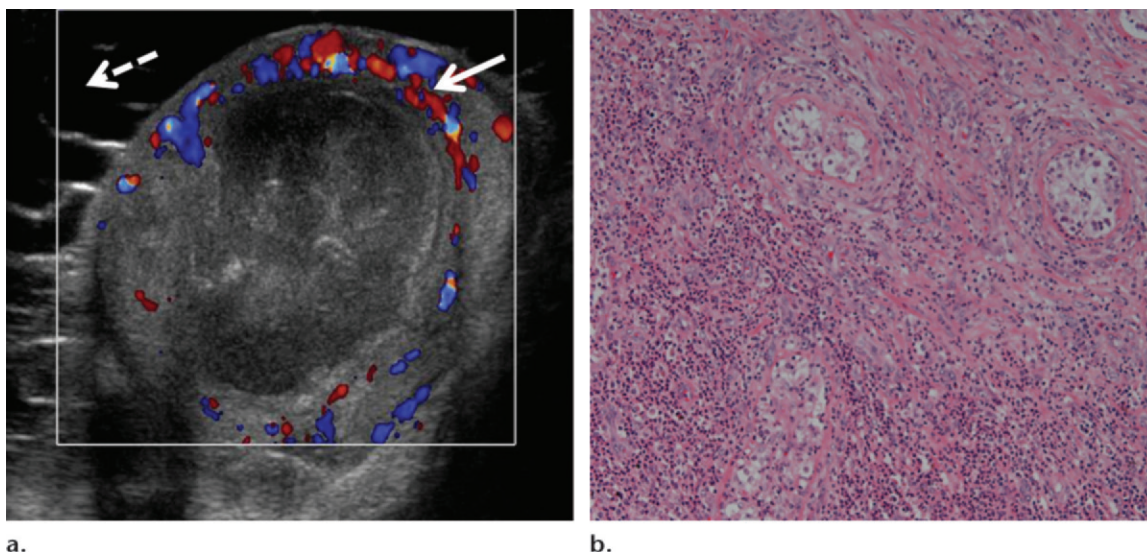
The M stage refers to the presence or absence of distant metastatic disease. Distant lymph nodes, including those found in the chest, pelvis, and supraclavicular regions, are considered metastatic disease (Fig 17). The initial staging workup usually includes CT or MR imaging of the chest, abdomen, and pelvis. Brain imaging may be performed if the patient is symptomatic or if the testicular tumor is a choriocarcinoma, because choriocarcinomas are more likely to metastasize to the brain. The most common sites of solid organ metastatic disease are the lungs, liver, and brain. Testicular metastases to bone may also occur.

### S Stage

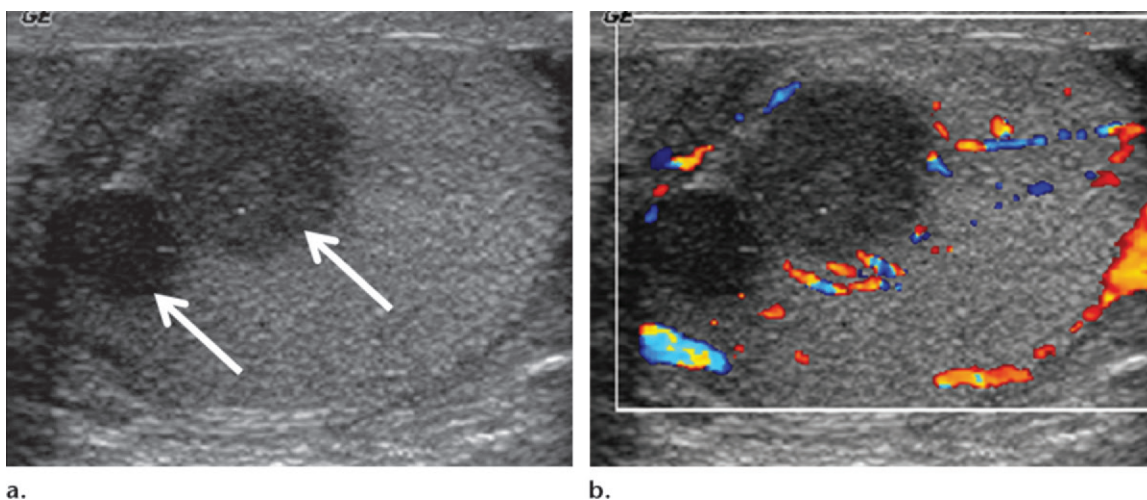
The S stage refers to serum tumor markers. Serum tumor marker levels ( $\beta$ -hCG, AFP, and LDH) are usually checked before and after orchiectomy. For most men with NSGCTs, the serum levels of  $\beta$ -hCG and/or AFP are elevated (69). For men with seminomas,  $\beta$ -hCG serum levels are elevated in a minority of individuals, and AFP levels are almost invariably normal (69). LDH is a less sensitive and less specific marker for both seminomatous germ cell tumors and NSGCTs and is a marker of total tumor burden (69). In general, serum tumor markers are used to monitor the patient's treatment response and to detect recurrence (69).

On the basis of the TNMS staging system, patients are classified as having stage I disease if the tumor is limited to the testis, epididymis,

retroperitoneal lymph node metastases by experienced readers (67). MR imaging is an appealing imaging modality because it does not expose patients to ionizing radiation, and most patients with testicular cancer are young men with a high likelihood of cure. However, the use of MR imaging is currently limited by its lack of availability and relatively high cost. In the future, there may be a role for lymphotropic nanoparticle-enhanced MR imaging in evaluation of lymph nodes in patients with testicular cancer. Macrophages in normally functioning lymph nodes take up these agents such that uptake is increased in benign lymph nodes compared with in lymph nodes with metastatic disease. However, further studies are needed to determine the utility of this technique in staging and surveillance of testicular cancer (18). The use of fluorodeoxyglucose positron emission tomography (PET)/CT currently is not recommended in initial staging of testicular cancer, in part because PET/CT is unable to depict disease less than 5 mm in diameter or any size teratoma (68).



**Figure 11.** Intratesticular abscess mimicking a tumor. **(a)** Color Doppler US image shows a 2-cm intratesticular mass with internal echoes, no definite internal blood flow, and perilesional hyperemia (solid arrow). A complex hydrocele is also visible (dashed arrow). The intratesticular lesion did not resolve after intravenous antibiotic therapy, and the patient underwent orchiectomy. **(b)** Photomicrograph (original magnification,  $\times 100$ ; H-E stain) of the specimen shows purulent debris.



**Figure 12.** Testicular granulomas in a 57-year-old man with an incidental finding of low-attenuating testicular lesions at CT. **(a)** Gray-scale US image shows two testicular masses measuring up to 1.6 cm (arrows). **(b)** Color Doppler US image shows no definite internal blood flow in the masses. The patient underwent orchiectomy, and necrotizing granulomas were seen at histologic analysis.

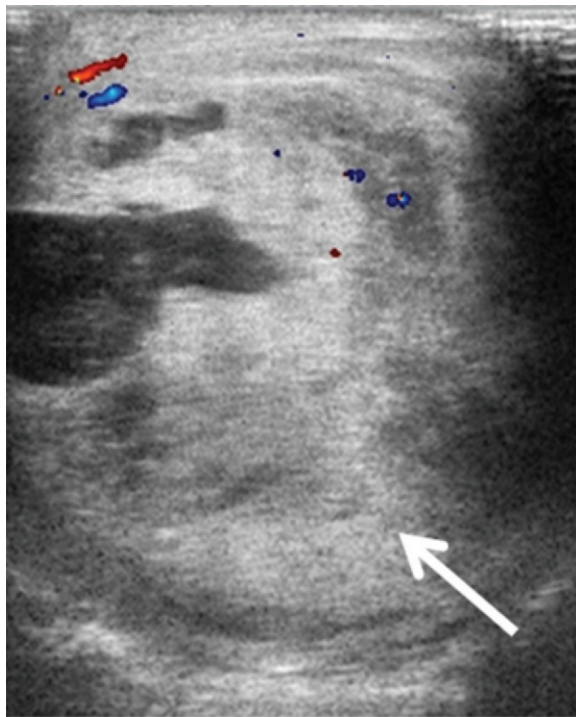
spermatic cord, or scrotal skin (70). Clinical stage II disease is limited to retroperitoneal lymph nodes (stage IIA if the nodes are less than 2 cm in maximal diameter, stage IIB if the nodes are 2–5 cm in maximal diameter, and stage IIC if the nodes are larger than 5 cm in maximal diameter) (70). Clinical stage III disease involves regional lymph nodes with moderately elevated tumor markers or distant nodal or visceral sites (70).

### Management of Testicular Tumors

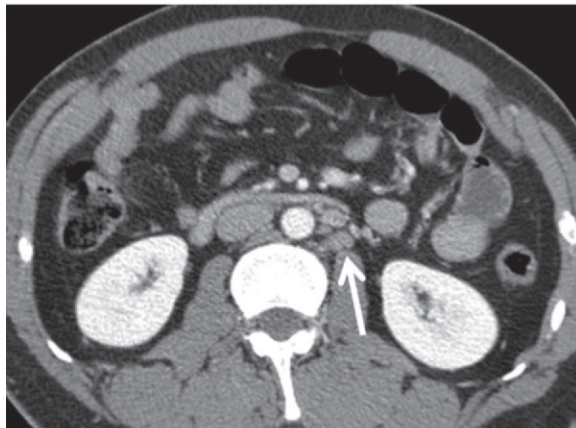
All patients with testicular cancer undergo radical inguinal orchiectomy, which involves removal of the testicle and ligation of the spermatic cord

at the inguinal ring, usually through an inguinal excision (70). In some cases, small, incidentally discovered, nonpalpable testicular tumors with undetectable tumor markers may be treated with inguinal delivery of the testicle and high-frequency US-guided resection (Fig 18) because the prevalence of benign tumors such as Leydig cell tumors may be as high as 50% for these incidentally discovered nonpalpable masses (71–73). Patients who are found to have a testicular malignancy at microsurgical exploration would then undergo radical inguinal orchiectomy.

Accurate clinical staging is critical because further treatment depends on the clinical stage of disease and whether the tumor is a seminomatous



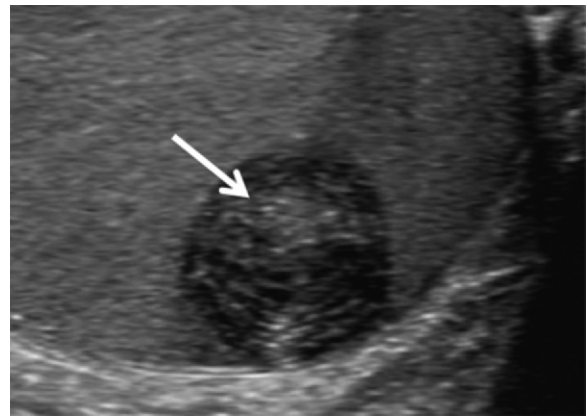
a.



b.

**Figure 14.** Stage IIA testicular disease. (a) Color Doppler US image shows a heterogeneous cystic and solid left testicular mass (arrow) that was proven at histology to be a mixed germ cell tumor (65% embryonal carcinoma, 20% seminoma, 14% yolk sac tumor). (b) Axial staging CT image shows several enlarged left paraaortic lymph nodes (arrow) measuring up to 1.2 cm, findings indicative of clinical stage IIA disease.

germ cell tumor or an NSGCT. For example, after orchiectomy, patients with stage I seminoma may be offered adjuvant radiation therapy, single-agent carboplatin chemotherapy, or active surveillance for at least 5 years (63). Surveillance strategies may vary slightly from practitioner to practitioner. At our institution, a typical surveillance regimen includes (a) a patient history, physical examination, and serum tumor marker check (ie, AFP,  $\beta$ -hCG, and LDH) every 3–4 months for the first 2 years, every 6–12 months for years 3 and 4, and then annually; (b) CT of



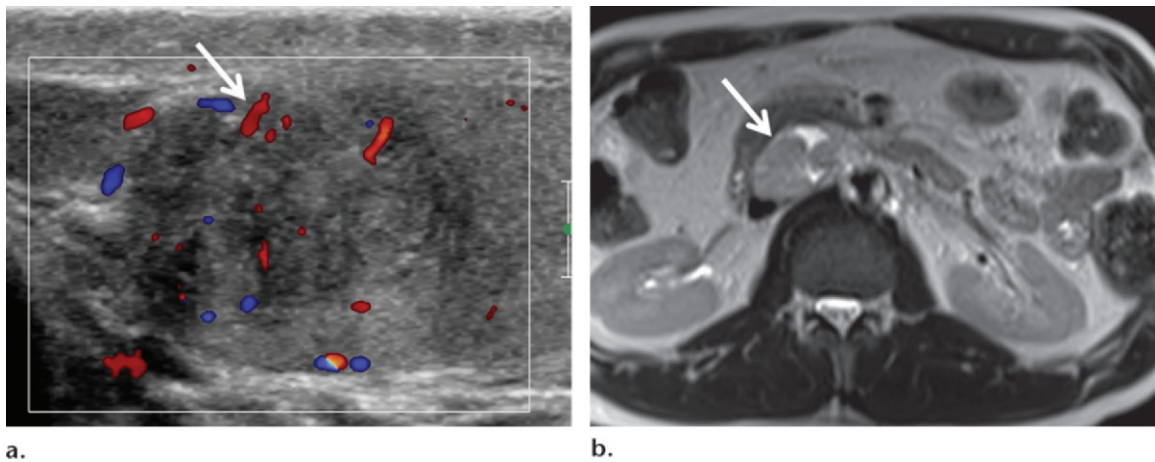
**Figure 13.** Testicular epidermoid cyst in a 26-year-old man with a palpable left scrotal mass. Gray-scale US image shows a primarily hypoechoic mass (arrow) with concentric hyper-echoic rings due to lamellated layers of keratin in the mass. The findings illustrate the “onion ring” appearance of an epidermoid cyst. The mass was enucleated and was confirmed to be an epidermoid cyst. (Courtesy of Matthew Heller, MD, University of Pittsburgh School of Medicine, Pittsburgh, Pa.)

the abdomen and pelvis every 6 months for the first 2 years, every 6–12 months for year 3, and then annually for years 4 and 5; and (c) chest radiography as clinically indicated for years 1–5. In a recent study, there was a 0.2% relapse rate in individuals who received either radiation therapy or carboplatin chemotherapy (74). In comparison, in a series by Warde et al (75), up to 18% of individuals who underwent active surveillance relapsed within 5 years. However, even in patients who relapse, the cure rate is approximately 100% after salvage chemotherapy (76).

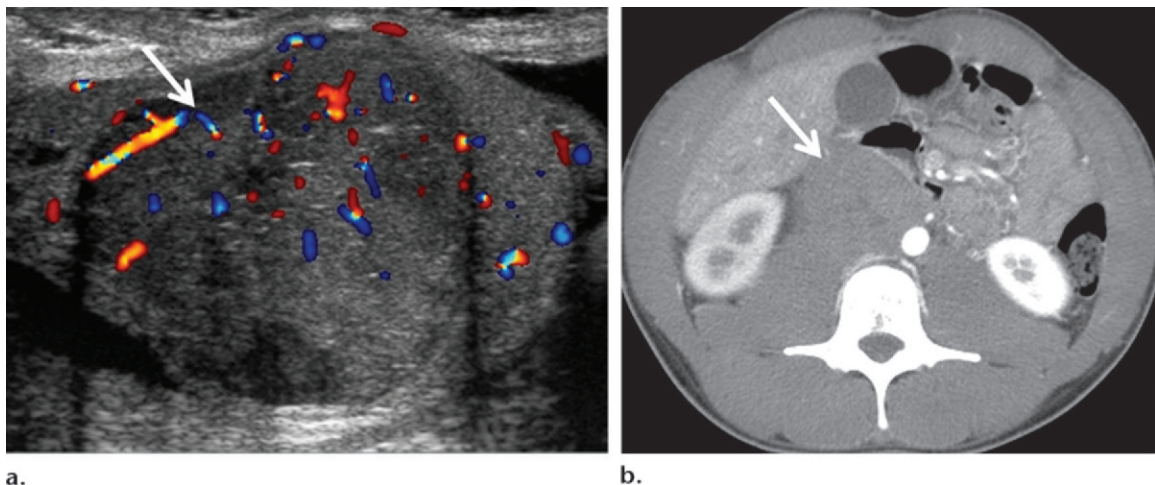
For men with nonseminomatous stage I tumors, chemotherapy (combined bleomycin, etoposide, and cisplatin), at least 5 years of active surveillance, or nerve-sparing retroperitoneal lymph node dissection are options after orchiectomy (63). About 25%–30% of patients will relapse with a surveillance-only strategy, but about 98% of patients who relapse will be cured after salvage chemotherapy (76–78).

For men with stage IIA or IIB seminoma, radiation therapy for the paraaortic region and ipsilateral iliac field, in addition to orchiectomy, is the usual treatment, although chemotherapy is being more widely used (63). The relapse rate is 5%–11%; relapse is treated with salvage chemotherapy and has a high cure rate (79,80). Stage IIA or IIB nonseminomatous tumors are treated with chemotherapy and resection of any residual retroperitoneal tumor measuring 1 cm or larger (63).

Men with seminomatous or nonseminomatous stage IIC or III disease are typically treated with intense chemotherapy regimens (63). Complete surgical resection of any residual disease measuring more than 1 cm is considered the



**Figure 15.** Stage IIB testicular disease. **(a)** Color Doppler US image shows a right testicular mass with internal blood flow (arrow), a finding that was proven at histology to be a mixed germ cell tumor (50% teratoma, 45% embryonal carcinoma, 3% yolk sac tumor, 2% choriocarcinoma). **(b)** Axial T2-weighted staging MR image shows a 3.7-cm aortocaval lymph node (arrow), a finding indicative of stage IIB disease.



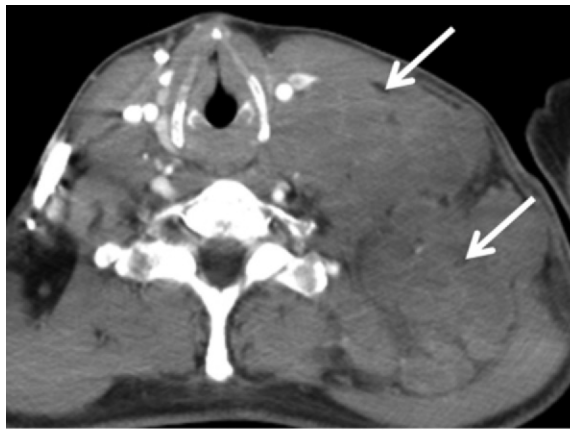
**Figure 16.** Stage IIC testicular disease. **(a)** Color Doppler US image shows a solid right testicular mass with internal blood flow (arrow), a finding that was proven at histology to be a seminoma. **(b)** Axial staging CT image shows a 5.5-cm retroperitoneal mass (arrow), a finding indicative of stage IIC disease.

criterion standard (81). Metastasectomy may be performed for pulmonary and liver metastases (81,82). The optimal treatment of brain metastases (eg, chemotherapy, radiation therapy, or surgical resection) has yet to be determined (63).

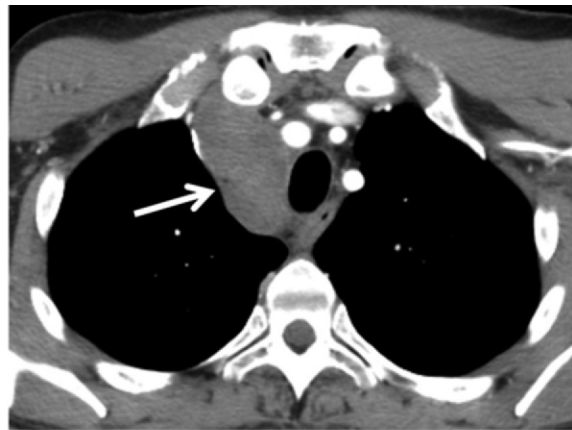When active surveillance, chemotherapy, radiation therapy, and lymph node dissection are treatment options, the treating physician must weigh a number of variables. For example, only compliant patients would be candidates for active surveillance. Although the relapse rate may be higher for patients who undergo active surveillance, most patients will not relapse. Therefore, patients who opt for active surveillance and do not have a recurrence are spared the long-term toxicity of chemotherapy and radiation therapy. Patients who undergo chemotherapy and/or radiation therapy for testicular cancer have a relative risk of 1.8–2.9 for developing a secondary

malignancy (83). The most common secondary malignancies in this population are cancers of the lung, colon, bladder, pancreas, and stomach (83). Increased cardiovascular mortality is an additional late side effect of chemotherapy and radiation therapy (84).

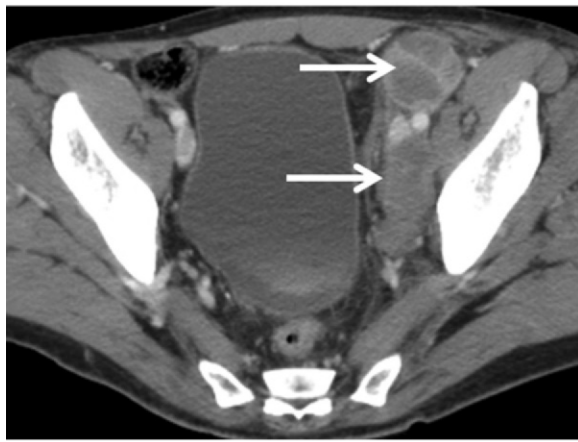
An additional argument for active surveillance is that cure rates are estimated to be 98% for stage I nonseminomatous tumors and 100% for stage I seminomas, even if the individual relapses, because current salvage chemotherapy regimens are so effective (76). The results of recent studies suggest that surveillance with abdominal CT results in the same overall survival rate for stage I disease without exposing patients to the risks of chemotherapy, radiation therapy, or lymph node dissection (85). However, because most patients who undergo active surveillance are young men, radiation exposure due



a.



b.



c.

**Figure 17.** Stage III testicular disease in a 31-year-old man with metastatic seminoma. (a) Axial contrast-enhanced CT image at the level of the lower neck shows marked left neck and left supraclavicular lymphadenopathy (arrows). (b) Axial contrast-enhanced CT image at the level of the chest shows mediastinal lymphadenopathy (arrow). (c) Axial contrast-enhanced CT image at the level of the pelvis demonstrates bulky, deep, left pelvic lymphadenopathy (arrows).

to serial CT scans is of concern. Surveillance recommendations currently being developed include at least three to five CT scans of the abdomen spread over 3–5 years (86). Therefore, active surveillance is performed with MR imaging at some centers. Approximately 60% of recurrences will be in the retroperitoneum, 25% will be in the lungs, and 10% will be diagnosed solely on the basis of elevated serum tumor markers (87).

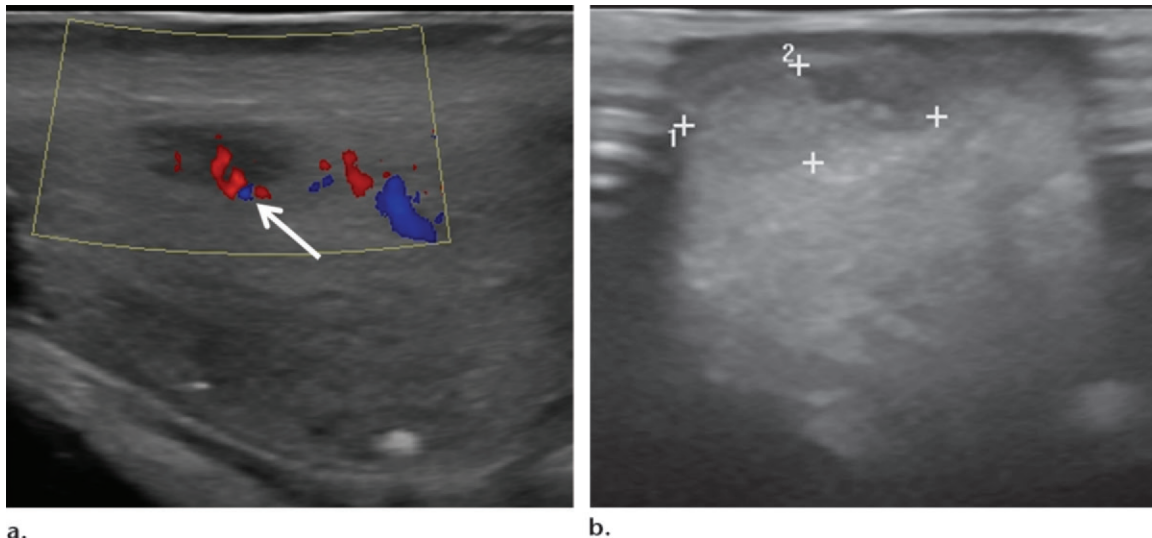
### Conclusion

Testicular cancer is considered an oncologic success story because most individuals will be cured with a combination of surgery and chemotherapy. Radiologists play an important role in identifying tumors at patient presentation, accurately staging disease, and detecting recurrence during imaging surveillance.

### References

1. Einhorn LH. Curing metastatic testicular cancer. *Proc Natl Acad Sci U S A* 2002;99(7):4592–4595.
2. Siegel R, Ma J, Zou Z, Jemal A. Cancer statistics, 2014. *CA Cancer J Clin* 2014;64(1):9–29.
3. Garner MJ, Turner MC, Ghadirian P, Krewski D. Epidemiology of testicular cancer: an overview. *Int J Cancer* 2005;116(3):331–339.

4. Liu S, Wen SW, Mao Y, Mery L, Rouleau J. Birth cohort effects underlying the increasing testicular cancer incidence in Canada. *Can J Public Health* 1999;90(3):176–180.
5. Sampaio FJ, Favorito LA. Analysis of testicular migration during the fetal period in humans. *J Urol* 1998;159(2):540–542.
6. Moore KL, Persaud TVN. The developing human: clinically oriented embryology. 5th ed. Philadelphia, Pa: Saunders, 1993; 281–301.
7. April EW. Clinical anatomy. 3rd ed. Baltimore, Md: Williams & Wilkins, 1997; 453–457.
8. Wang J, Ping Z, Jiang T, et al. Ultrastructure of lymphatic stomata in the tunica vaginalis of humans. *Microsc Microanal* 2013;19(6):1405–1409.
9. De Miguel MP, Arnalich Montiel F, Lopez Iglesias P, Blazquez Martinez A, Nistal M. Epiblast-derived stem cells in embryonic and adult tissues. *Int J Dev Biol* 2009;53(8–10):1529–1540.
10. Mostofi FK, Sesterhenn IA. Histological typing of testis tumors. 2nd ed. Berlin, Germany: Springer, 1998; 7–28.
11. Bahrami A, Ro JY, Ayala AG. An overview of testicular germ cell tumors. *Arch Pathol Lab Med* 2007;131(8):1267–1280.
12. Kregel S, Beyer J, Souchon R, et al. European consensus conference on diagnosis and treatment of germ cell cancer: a report of the second meeting of the European Germ Cell Cancer Consensus Group (EGCCCG). I. *Eur Urol* 2008;53(3):478–496.
13. Krag Jacobsen G, Barlebo H, Olsen J, et al. Testicular germ cell tumours in Denmark 1976–1980: pathology of 1058 consecutive cases. *Acta Radiol Oncol* 1984;23(4):239–247.
14. Ulbright TM. Germ cell tumors of the gonads: a selective review emphasizing problems in differential diagnosis, newly appreciated, and controversial issues. *Mod Pathol* 2005;18(suppl 2):S61–S79.
15. Leite KR, Garicochea B, Srougi M, et al. Monoclonality of asynchronous bilateral lymphoma of the testis. *Eur Urol* 2000;38(6):774–777.
16. Lantz AG, Power N, Hutton B, Gupta R. Malignant lymphoma of the testis: a study of 12 cases. *Can Urol Assoc J* 2009;3(5):393–398.
17. Busto Martin L, Portela Pereira P, Sacristan Lista F, Busto Castañon L. Mesothelioma of the tunica vaginalis: case report. *Arch Esp Urol* 2013;66(4):384–388.
18. Honoré LH, Sullivan LD. Intratesticular leiomyoma: a case report with discussion of differential diagnosis and histogenesis. *J Urol* 1975;114(4):631–635.



**Figure 18.** US-guided microsurgical resection in a 36-year-old man. (a) Color Doppler US image shows a 9-mm hypoechoic intratesticular mass with internal vascularity (arrow). (b) Intraoperative US image used to guide resection shows the mass (calipers).

19. Livolsi VA, Schiff M. Myxoid neurofibroma of the testis. *J Urol* 1977;118(2):341–342.
20. Haupt HM, Mann RB, Trump DL, Abeloff MD. Metastatic carcinoma involving the testis: clinical and pathologic distinction from primary testicular neoplasms. *Cancer* 1984;54(4):709–714.
21. Ulbright TM, Young RH. Metastatic carcinoma to the testis: a clinicopathologic analysis of 26 nonincidental cases with emphasis on deceptive features. *Am J Surg Pathol* 2008;32(11):1683–1693.
22. United Kingdom Testicular Cancer Study Group. Aetiology of testicular cancer: association with congenital abnormalities, age at puberty, infertility, and exercise. *BMJ* 1994;308(6941):1393–1399.
23. Rapley EA, Crockford GP, Teare D, et al. Localization to Xq27 of a susceptibility gene for testicular germ-cell tumours. *Nat Genet* 2000;24(2):197–200.
24. Raman JD, Nobert CF, Goldstein M. Increased incidence of testicular cancer in men presenting with infertility and abnormal semen analysis. *J Urol* 2005;174(5):1819–1822; discussion 1822.
25. Walsh TJ, Croughan MS, Schembri M, Chan JM, Turek PJ. Increased risk of testicular germ cell cancer among infertile men. *Arch Intern Med* 2009;169(4):351–356.
26. Wood HM, Elder JS. Cryptorchidism and testicular cancer: separating fact from fiction. *J Urol* 2009;181(2):452–461.
27. Tasian GE, Copp HL. Diagnostic performance of ultrasound in nonpalpable cryptorchidism: a systematic review and meta-analysis. *Pediatrics* 2011;127(1):119–128.
28. Adesanya OA, Ademuyiwa AO, Evbuomwan O, Adeyomoye AA, Bode CO. Preoperative localization of undescended testes in children: comparison of clinical examination and ultrasonography. *J Pediatr Urol* 2014;10(2):237–240.
29. Yeung CK, Tam YH, Chan YL, Lee KH, Metreweli C. A new management algorithm for impalpable undescended testis with gadolinium enhanced magnetic resonance angiography. *J Urol* 1999;162(3 Pt 2):998–1002.
30. Lam WW, Tam PK, Ai VH, Chan KL, Chan FL, Leong L. Using gadolinium-infusion MR venography to show the impalpable testis in pediatric patients. *AJR Am J Roentgenol* 2001;176(5):1221–1226.
31. Kirsch AJ, Escala J, Duckett JW, et al. Surgical management of the nonpalpable testis: the Children's Hospital of Philadelphia experience. *J Urol* 1998;159(4):1340–1343.
32. Lim YJ, Jeong MJ, Bae BN, Kim SH, Kim JY. Seminoma in undescended testis. *Abdom Imaging* 2008;33(2):241–243.
33. Peterson AC, Bauman JM, Light DE, McMann LP, Costabile RA. The prevalence of testicular microlithiasis in an asymptomatic population of men 18 to 35 years old. *J Urol* 2001;166(6):2061–2064.
34. Ganem JP, Workman KR, Shaban SF. Testicular microlithiasis is associated with testicular pathology. *Urology* 1999;53(1):209–213.
35. Dogra VS, Gottlieb RH, Oka M, Rubens DJ. Sonography of the scrotum. *Radiology* 2003;227(1):18–36.
36. Costabile RA. How worrisome is testicular microlithiasis? *Curr Opin Urol* 2007;17(6):419–423.
37. DeCastro BJ, Peterson AC, Costabile RA. A 5-year followup study of asymptomatic men with testicular microlithiasis. *J Urol* 2008;179(4):1420–1423; discussion 1423.
38. Jungwirth A, Giwercman A, Tournaye H, et al. European Association of Urology guidelines on male infertility: the 2012 update. *Eur Urol* 2012;62(2):324–332.
39. Coret A, Leibovitch I, Heyman Z, Goldwasser B, Itzhak Y. Ultrasonographic evaluation and clinical correlation of intratesticular lesions: a series of 39 cases. *Br J Urol* 1995;76(2):216–219.
40. Carroll BA, Gross DM. High-frequency scrotal sonography. *AJR Am J Roentgenol* 1983;140(3):511–515.
41. Rifkin MD, Kurtz AB, Pasto ME, Goldberg BB. Diagnostic capabilities of high-resolution scrotal ultrasonography: prospective evaluation. *J Ultrasound Med* 1985;4(1):13–19.
42. Brown DL, Benson CB, Doherty FJ, et al. Cystic testicular mass caused by dilated rete testis: sonographic findings in 31 cases. *AJR Am J Roentgenol* 1992;158(6):1257–1259.
43. Akin EA, Khatri NJ, Hill MC. Ultrasound of the scrotum. *Ultrasound Q* 2004;20(4):181–200.
44. Yagil Y, Naroditsky I, Milhem J, et al. Role of Doppler ultrasonography in the triage of acute scrotum in the emergency department. *J Ultrasound Med* 2010;29(1):11–21.
45. Guthrie JA, Fowler RC. Ultrasound diagnosis of testicular tumours presenting as epididymal disease. *Clin Radiol* 1992;46(6):397–400.
46. Schwerk WB, Schwerk WN, Rodeck G. Testicular tumors: prospective analysis of real-time US patterns and abdominal staging. *Radiology* 1987;164(2):369–374.
47. Woodward PJ, Sohaey R, O'Donoghue MJ, Green DE. Tumors and tumorlike lesions of the testis: radiologic-pathologic correlation. *RadioGraphics* 2002;22(1):189–216.
48. Vitolo U, Ferreri AJ, Zucca E. Primary testicular lymphoma. *Crit Rev Oncol Hematol* 2008;65(2):183–189.
49. Mazzu D, Jeffrey RB Jr, Ralls PW. Lymphoma and leukemia involving the testicles: findings on gray-scale and color Doppler sonography. *AJR Am J Roentgenol* 1995;164(3):645–647.

50. Ferry JA, Harris NL, Young RH, Coen J, Zietman A, Scully RE. Malignant lymphoma of the testis, epididymis, and spermatic cord: a clinicopathologic study of 69 cases with immunophenotypic analysis. *Am J Surg Pathol* 1994; 18(4):376–390.
51. Hamm B. Differential diagnosis of scrotal masses by ultrasound. *Eur Radiol* 1997;7(5):668–679.
52. Bertolotto M, Derchi LE, Sidhu PS, et al. Acute segmental testicular infarction at contrast-enhanced ultrasound: early features and changes during follow-up. *AJR Am J Roentgenol* 2011;196(4):834–841.
53. Delfino M, Elia J, Imbrogno N, et al. Testicular adrenal rest tumors in patients with congenital adrenal hyperplasia: prevalence and sonographic, hormonal, and seminal characteristics. *J Ultrasound Med* 2012;31(3):383–388.
54. Woodhouse J, Ferguson MM. Multiple hyperechoic testicular lesions are a common finding on ultrasound in Cowden disease and represent lipomatosis of the testis. *Br J Radiol* 2006;79(946):801–803.
55. Loberant N, Bhatt S, Messing E, Dogra VS. Bilateral testicular epididymoid cysts. *J Clin Imaging Sci* 2011;1:4.
56. Cittadini G, Gauglio C, Pretolesi F, Santacroce E, Derchi LE. Bilateral epididymoid cysts of the testis: sonographic and MRI findings. *J Clin Ultrasound* 2004;32(7):370–372.
57. Jaffer OS, Sidhu PS. Contrast-enhanced ultrasonography of the testes. *Ultrasound Clin* 2013;8(4):509–523.
58. Aigner F, De Zordo T, Pallwein-Pretner L, et al. Real-time sonoelastography for the evaluation of testicular lesions. *Radiology* 2012;263(2):584–589.
59. Mohrs OK, Thoms H, Egner T, et al. MRI of patients with suspected scrotal or testicular lesions: diagnostic value in daily practice. *AJR Am J Roentgenol* 2012;199(3):609–615.
60. Tsili AC, Argyropoulou MI, Giannakis D, Sofikitis N, Tsampoulas K. MRI in the characterization and local staging of testicular neoplasms. *AJR Am J Roentgenol* 2010;194(3):682–689.
61. Tsili AC, Tsampoulas C, Giannakopoulos X, et al. MRI in the histologic characterization of testicular neoplasms. *AJR Am J Roentgenol* 2007;189(6):W331–W337.
62. Tsili AC, Argyropoulou MI, Astrakas LG, et al. Dynamic contrast-enhanced subtraction MRI for characterizing intratesticular mass lesions. *AJR Am J Roentgenol* 2013;200(3):578–585.
63. Winter C, Albers P. Testicular germ cell tumors: pathogenesis, diagnosis and treatment. *Nat Rev Endocrinol* 2011;7(1):43–53.
64. Hilton S, Herr HW, Teitcher JB, Begg CB, Castéllino RA. CT detection of retroperitoneal lymph node metastases in patients with clinical stage I testicular nonseminomatous germ cell cancer: assessment of size and distribution criteria. *AJR Am J Roentgenol* 1997;169(2):521–525.
65. McMahon CJ, Rofsky NM, Pedrosa I. Lymphatic metastases from pelvic tumors: anatomic classification, characterization, and staging. *Radiology* 2010;254(1):31–46.
66. Hudolin T, Kastelan Z, Knezevic N, Goluzo E, Tomas D, Coric M. Correlation between retroperitoneal lymph node size and presence of metastases in nonseminomatous germ cell tumors. *Int J Surg Pathol* 2012;20(1):15–18.
67. Sohaib SA, Koh DM, Barbachano Y, et al. Prospective assessment of MRI for imaging retroperitoneal metastases from testicular germ cell tumours. *Clin Radiol* 2009;64(4):362–367.
68. Albers P, Bender H, Yilmaz H, Schoeneich G, Biersack HJ, Mueller SC. Positron emission tomography in the clinical staging of patients with stage I and II testicular germ cell tumors. *Urology* 1999;53(4):808–811.
69. Gilligan TD, Seidenfeld J, Basch EM, et al. American Society of Clinical Oncology clinical practice guideline on uses of serum tumor markers in adult males with germ cell tumors. *J Clin Oncol* 2010;28(20):3388–3404.
70. Bosl GJ, Motzer RJ. Testicular germ-cell cancer. *N Engl J Med* 1997;337(4):242–253.
71. Hopps CV, Goldstein M. Ultrasound guided needle localization and microsurgical exploration for incidental nonpalpable testicular tumors. *J Urol* 2002;168(3):1084–1087.
72. Rolle L, Tamagnone A, Destefanis P, et al. Microsurgical “testis-sparing” surgery for nonpalpable hypoechoic testicular lesions. *Urology* 2006;68(2):381–385.
73. Powell TM, Tarter TH. Management of nonpalpable incidental testicular masses. *J Urol* 2006;176(1):96–98; discussion 99.
74. Mead GM, Fossa SD, Oliver RT, et al. Randomized trials in 2466 patients with stage I seminoma: patterns of relapse and follow-up. *J Natl Cancer Inst* 2011;103(3):241–249.
75. Warde P, Specht L, Horwich A, et al. Prognostic factors for relapse in stage I seminoma managed by surveillance: a pooled analysis. *J Clin Oncol* 2002;20(22):4448–4452.
76. Groll RJ, Warde P, Jewett MA. A comprehensive systematic review of testicular germ cell tumor surveillance. *Crit Rev Oncol Hematol* 2007;64(3):182–197.
77. Zuniga A, Kakiashvili D, Jewett MA. Surveillance in stage I nonseminomatous germ cell tumours of the testis. *BJU Int* 2009;104(9 Pt B):1351–1356.
78. Choueiri TK, Stephenson AJ, Gilligan T, Klein EA. Management of clinical stage I nonseminomatous germ cell testicular cancer. *Urol Clin North Am* 2007;34(2):137–148; abstract viii.
79. Classen J, Schmidberger H, Meisner C, et al. Radiotherapy for stages IIA/B testicular seminoma: final report of a prospective multicenter clinical trial. *J Clin Oncol* 2003;21(6):1101–1106.
80. Schmidberger H, Bamberg M, Meisner C, et al. Radiotherapy in stage IIA and IIB testicular seminoma with reduced portals: a prospective multicenter study. *Int J Radiat Oncol Biol Phys* 1997;39(2):321–326.
81. Maluccio M, Einhorn LH, Goulet RJ. Surgical therapy for testicular cancer metastatic to the liver. *HPB (Oxford)* 2007;9(3):199–200.
82. Cagini L, Nicholson AG, Horwich A, Goldstraw P, Pastorino U. Thoracic metastasectomy for germ cell tumours: long term survival and prognostic factors. *Ann Oncol* 1998;9(11):1185–1191.
83. Travis LB, Fosså SD, Schonfeld SJ, et al. Second cancers among 40,576 testicular cancer patients: focus on long-term survivors. *J Natl Cancer Inst* 2005;97(18):1354–1365.
84. Fosså SD, Gilbert E, Dores GM, et al. Noncancer causes of death in survivors of testicular cancer. *J Natl Cancer Inst* 2007;99(7):533–544.
85. Kakiashvili DM, Zuniga A, Jewett MA. High risk NSGCT: case for surveillance. *World J Urol* 2009;27(4):441–447.
86. Nichols CR, Roth B, Albers P, et al. Active surveillance is the preferred approach to clinical stage I testicular cancer. *J Clin Oncol* 2013;31(28):3490–3493.
87. Albers P. Management of stage I testis cancer. *Eur Urol* 2007;51(1):34–43; discussion 43–44.