

Epidemiological Survey on the Infection of Intestinal Flukes in Residents of Muan-gun, Jeollanam-do, the Republic of Korea

Shin-Hyeong Cho¹, Pyo-Yun Cho¹, Dong-Min Lee¹, Tong-Soo Kim², In-Sang Kim³, Eun-Jung Hwang³,
Byoung-Kuk Na⁴ and Woon-Mok Sohn^{4,*}

¹Division of Malaria and Parasitic Diseases, National Institute of Health, Centers for Disease Control and Prevention, Seoul 122-701, Korea;

²Department of Parasitology and Inha Research Institute for Medical Sciences, Inha University College of Medicine, Incheon 400-712, Korea;

³Health Center of Muan-gun, Muan 534-804, Korea; ⁴Department of Parasitology and Institute of Health Sciences, Gyeongsang National University School of Medicine, Jinju 660-751, Korea

Abstract: Infection status of intestinal flukes was investigated in residents of Muan-gun, Jeollanam-do, the Republic of Korea. Total 1,257 fecal samples of residents were examined by formalin-ether sedimentation technique and Kato-Katz thick smear method. Helminth eggs were detected from 95 (7.6%) residents, and eggs of heterophyid flukes and *Clonorchis sinensis* were found from 62 (4.9%) and 40 (3.2%) cases, respectively. The larger heterophyid eggs, somewhat dark-brown in color and $37.7 \times 21.5 \mu\text{m}$ in average size, and found in 32 (2.6%) out of 62 egg positive cases of heterophyid flukes. To confirm the adult flukes, we performed worm recovery from 12 cases after praziquantel treatment and purgation with MgSO₄. A total of 1,281 adult flukes, assigned to 7 species, were recovered from 9 cooperative cases. *Heterophyes nocens* (total 981 specimens) was collected from 9 cases, *Stictodora fuscata* (80) from 7, *Gymnophalloides seoi* (75) from 5, *Pygidiopsis summa* (140) from 3, *Stellantchasmus falcatus* (3) from 2, and *Stictodora lari* and *Acanthotrema felis* (each 1 worm) from 1 case each. The intrauterine eggs of *S. fuscata* collected from the recovered worm were identical with the larger heterophyid eggs detected in the stool examination. By the present study, it was confirmed that *A. felis* is a new intestinal fluke infecting humans, and residents in Muan-gun, Jeollanam-do are infected with variable species of intestinal trematodes.

Key words: *Stictodora fuscata*, *Acanthotrema felis*, intestinal trematode, resident, Muan-gun

INTRODUCTION

It has been known that more than 50 million people are infected with intestinal trematodes, and about 70 trematode species are involved in human infections around the world [1]. In the Republic of Korea, 17 species of 5 families, i.e. Heterophyidae, Echinostomatidae, Plagiorchiidae, Neodiplostomidae, Gymnophallidae, have been listed as human-infecting intestinal trematodes. Among them, 10 species are members of Heterophyidae which is regarded as the most important group [2].

Muan-gun, Jeollanam-do, has been known as the endemic focus of heterophyid flukes together with some areas of south and west coasts. Among 10 species of human-infecting heterophyid flukes, 6 species, namely, *Heterophyes nocens*, *Heterophyopsis*

continua, *Pygidiopsis summa*, *Stellantchasmus falcatus*, *Stictodora fuscata*, and *Stictodora lari*, are prevalent among residents who frequently consumed raw flesh of estuarine fish in the south and west coastal areas [1,2].

A Parasite Eradication Program (PEP) has been performed by the Division of Malaria and Parasitic Diseases, National Institute of Health (NIH), Korea Centers for Disease Control and Prevention (KCDCP) since 2005 [3]. The purpose of this program is to make an epoch-making decrease of helminth infections among residents in the city and province which revealed higher prevalence in the 7th report (2004) on the nationwide survey of the Republic of Korea [4,5]. The present study was carried out to investigate helminthic infections in residents of Muan-gun, Jeollanam-do, as a part of PEP-2007. Moreover, we intended worm recovery to know what species of intestinal flukes are infected among the residents in whom larger heterophyid eggs are detected in the stool examination.

• Received 26 April 2010, revised 24 May 2010, accepted 25 May 2010.

* Corresponding author (wmsohn@gnu.ac.kr)

MATERIALS AND METHODS

A total of 1,257 fecal samples were collected from 9 administrative localities of Muan-gun, Jeollanam-do, in March 2007. Collected fecal samples were examined by the formalin-ether sedimentation technique and Kato-Katz method. To identify the adult worms of larger heterophyid eggs detected in the stool examination, we performed worm recovery on 12 out of 32 positive cases for larger heterophyid eggs after praziquantel (Shinpoong Pharmaceutical Co., Seoul, Korea) treatment and purgation with MgSO₄ after obtaining informed consent from each person. Whole stools passed successively 3-5 times were collected from 9 helpful persons. After carrying out the methods generally used in the worm recovery [6], all samples were transported to the Department of Parasitology, Gyeongsang National University School of Medicine, and examined under a stereomicroscope. The recovered worms were fixed with 10% formalin under cover glass pressure, observed and measured under a light microscope using a micrometer. We also carried out questionnaire investigation on 12 residents selected for the worm recovery to know the infection sources of flukes recovered, and some related health problems.

RESULTS

Positive rates of helminth eggs in stool examination

Helminth eggs were detected in 95 (7.6%) of 1,257 fecal samples of residents examined. Among them, 9 people (0.7%) were infected with more than 2 species of helminths. Therefore, the number of cumulative egg positive cases was 104 (8.3%). Eggs of heterophyid flukes were found in 62 (4.9%) fecal samples of residents; *Clonorchis sinensis* in 40 cases (3.2%), and *Trichuris*

trichiura and echinostomatid eggs in 1 person each. The larger heterophyid eggs were found in 32 (2.6%) of 62 heterophyid egg positive cases (Table 1).

Worm recovery from egg positive cases of heterophyid flukes

A total of 1,281 adult flukes, assigned to 7 species, were recovered from 9 cooperative residents after praziquantel treatment and purgation. *H. nocens* (total 981 specimens) was collected from all 9 cases, *S. fuscata* (80) from 7, *G. seoi* (75) from 5, *P. summa* (140) from 3, *S. falcatus* (3) from 2, and *S. lari* (1) and *Acanthotrema felis* (1) from 1 case each (Table 2).

Redescription of *Stictodora fuscata* recovered from humans

Eggs

The larger heterophyid eggs detected in stool examinations were 33-43 (38) × 20-25 (22) μm in size, having a thick and smooth shell, un conspicuous operculum, and miracidium (Fig. 1A, B).

Adults (n = 10)

Somewhat small and slender in shape, 850-1,380 (1,060 in average) μm long and 300-460 (380) μm wide (Fig. 1C). Oral sucker round, 70-88 (78) × 75-95 (87) μm in size. Prepharynx short, 50-70 (62) μm in length. Pharynx muscular, 68-90 (79) × 60-75 (70) μm in size. Esophagus slender, 55-80 (66) μm in length. Ceca somewhat wide, extended to posterior end of body. Ventrogenital sac ovoid, 50-88 (66) × 68-100 (79) μm in size, and armed with 15-18 gonotyl spines (Fig. 1D). Ovary transversely ovoid, 48-93 (57) × 63-138 (90) μm in size, and

Table 1. Helminth egg positive rates in the feces of residents in Muan-gun, Jeollanam-do, Korea

Items and helminth species	No. of cases (%)
No. examined	1,257
No. of helminth egg positive cases	95 (7.6)
No. of cumulative egg positive cases	104 (8.3)
Heterophyids ^{a)}	62 (4.9)
<i>Clonorchis sinensis</i>	40 (3.2)
Echinostome	1 (0.08)
<i>Trichuris trichiura</i>	1 (0.08)
<i>C. sinensis</i> + heterophyids	7 (0.56)
Echinostome + heterophyids	1 (0.08)
<i>T. trichiura</i> + heterophyids	1 (0.08)

^aNo. of larger heterophyid egg positive cases: 32 (2.6%).

Table 2. Results of worm collection from positive cases of larger heterophyid eggs after praziquantel treatment

Resident (Age/sex)	No. of worms collected						
	<i>H. nocens</i>	<i>P. summa</i>	<i>S. falcatus</i>	<i>S. fuscata</i>	<i>S. lari</i>	<i>A. felis</i>	<i>G. seoi</i>
75/M	43	1	-	10	-	-	3
73/M	93	-	-	7	-	-	-
70/F	33	1	-	2	-	-	-
70/F	148	-	1	30	1	1	65
67/M	56	-	-	-	-	-	3
65/F	15	-	-	3	-	-	3
63/M	488	-	2	5	-	-	1
60/F	101	138	-	23	-	-	-
57/F	4	-	-	-	-	-	-
Total	981	140	3	80	1	1	75

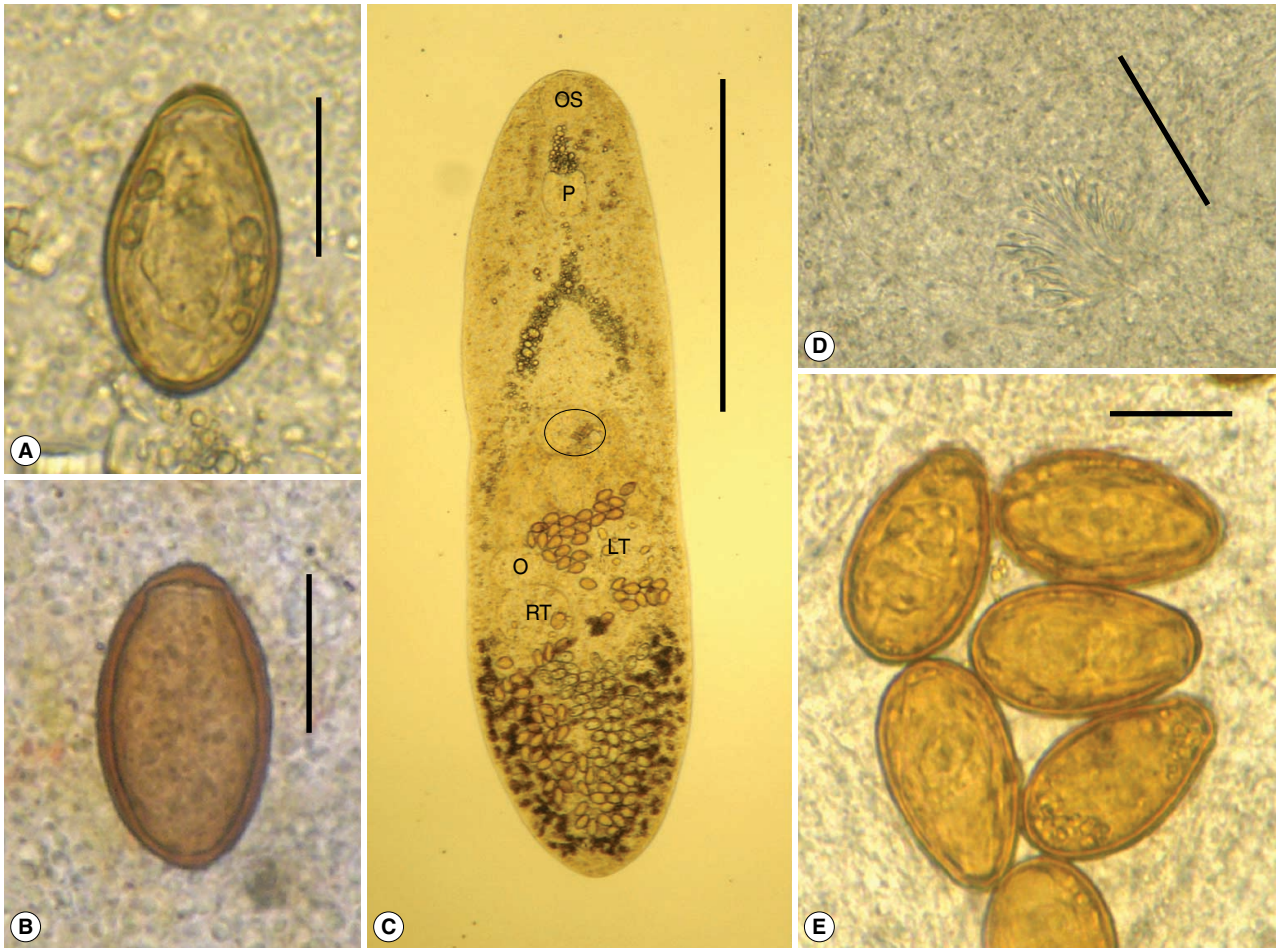


Fig. 1. Eggs and an adult of *Stictodora fuscata* (A, B). Eggs detected in stool examinations by formalin-ether sedimentation technique (A) and Kato-Katz method (B) (scale bar = 20 μ m). They have thick and smooth shells and unobvious operculum. (C) An adult worm recovered from a case positive for larger heterophyid eggs (scale bar = 500 μ m). It is somewhat small and slender in shape, and has round oral sucker (OS), muscular pharynx (P), ventrogenital sac (circle), elliptical ovary (O), and 2 testes (RT: right testis; LT: left testis). (D) Characteristic ventrogenital sac (magnified view of round circle in Fig. 1C) armed with about 16 gonotyl spines (scale bar = 40 μ m). (E) Intrauterine eggs are oval in shape, dark brown color, with thick shell and unobvious operculum (scale bar = 20 μ m).

located just in front of right testis. Testes obliquely tandem and transversely elliptical, 45-125 (82) \times 70-150 (110) μ m in size, and located in posterior 1/3. Seminal vesicle constricted into 3-4 saccules, and located between gonotyl and ovary. Uterus distributed in posterior half of body, with many eggs. Intrauterine eggs oval, dark brown color, with thick shell and unobvious operculum, and 35-47 (39) \times 20-26 (23) μ m in size (Fig. 1E). Vitellaria distributed in peripheral area of post-testicular region.

Acanthotrema felis recovered from a human case

Body small, claviform, 656 \times 287 μ m in size (Fig. 2A). Oral sucker globular, 70 μ m in diameter. Prepharynx short. Pharynx

subglobular, 49 \times 52 μ m in size. Esophagus short, 25 μ m long. Intestinal ceca terminate close to posterior end. Ventrogenital sac muscular, 94 \times 71 μ m in size, with 3 sclerotized pieces (Fig. 2B). The other reproductive organs were not clearly seen in a worm recovered because of it was damaged by praziquantel.

Findings obtained from the questionnaire investigation

Total 9 out of 12 residents selected for the worm recovery usually defecated mushy stools, but they have no other special gastrointestinal symptoms. Almost all enjoyed eating raw flesh of brackish water fish, i.e., common blackish goby, *Acanthogobius flavimanus* (66.7% of people); mullet, *Mugil cephalus* (41.7%); common sea bass, *Lateolabrax japonicus* (25.0%); gizzard shad,

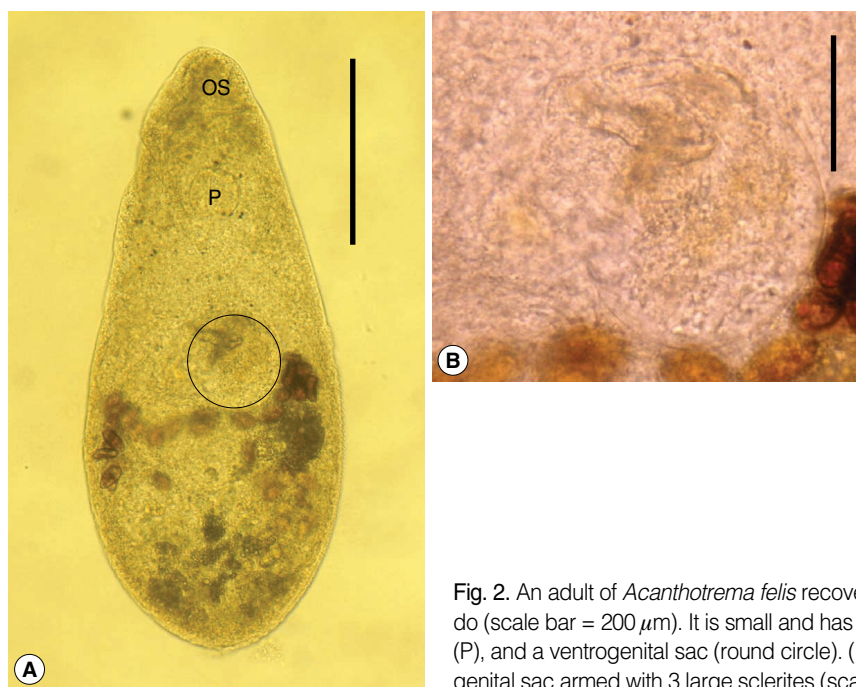


Fig. 2. An adult of *Acanthotrema felis* recovered from a resident of Muan-gun, Jeollanam-do (scale bar = 200 μm). It is small and has a round oral sucker (OS), a muscular pharynx (P), and a ventrogenital sac (round circle). (B) Magnified view of the characteristic ventrogenital sac armed with 3 large sclerites (scale bar = 40 μm).

Konosirus punctatus (16.7%); blue-spotted mud hopper, *Boleophthalmus pectinirostris* (8.3%). Only 2 people (16.7%) answered that they like to eat raw oyster, *Crassostrea gigas*.

DISCUSSION

By the present study, it was confirmed again that Muan-gun in Jeollanam-do is an endemic focus of heterophyid fluke infections. Chai et al. [6] reported 75% egg positive rate of heterophyid flukes in the fecal examination of 108 residents in a small coastal village in Muan-gun. They recovered 4 species of heterophyid flukes, i.e., *H. nocens*, *P. summa*, *H. continua*, *S. fuscata*, and *G. seoi* from 20 heterophyid egg positive cases after praziquantel treatment and purgation [6]. In our study, only 62 (4.93%) out of 1,257 residents examined revealed egg positive results for heterophyid flukes. Six species of heterophyid flukes, i.e., *H. nocens*, *S. fuscata*, *P. summa*, *S. falcatus*, *S. lari*, and *A. felis*, and *G. seoi*, were recovered from 9 residents. The egg positive rate was much decreased, while the number of heterophyid species collected increased from 4 to 6 compared to a previous study [6].

H. nocens was the dominant species among the residents of Muan-gun. This fluke was recovered from all 9 cases examined, although the intensity of infection was a little lower in the present study (average worm burden; 109) than in Chai et al. [6]

Table 3. Comparison of *Stictodora fuscata* eggs with those of previous studies

Authors	Size of eggs (average)
Present study (2010)	
Eggs in fecal specimens (n = 30)	33.8-42.5 (37.7) \times 20.0-25.0 (21.5) μm
Eggs in the uterus of worms (n = 20)	35.0-47.5 (39.1) \times 20.0-26.3 (22.5) μm
Onji and Nishio (1924)	35-37 \times 22-24 μm
Chai et al. (1988)	34-38 \times 20-23 μm
Sohn et al. (1994)	32-38 (35) \times 19-23 (20) μm

(average worm burden; 193). The dominance of *H. nocens* infections has also been shown in the residents of Shinan-gun and Gangjin-gun (Jeollanam-do), Buan-gun (Jeollabuk-do), Sacheon-si (Gyeongsangnam-do), and western and southern coastal islands of the Republic of Korea [7-10].

In the fecal examination of the present study, larger heterophyid eggs were detected in 32 cases. They were 37.7 \times 21.5 μm in average size, larger than eggs of other heterophyid flukes, including *H. nocens*, and their shell was somewhat thick and dark brown in color. *S. fuscata* adults were collected from 7 (77.8%) out of 9 residents in the worm recovery. Their uterine eggs were compatible with the larger heterophyid eggs detected in the fecal examination, and with those in the previously reported papers (Table 3) [11-13]. Therefore, researchers in the endemic areas

of heterophyid flukes should pay attention to these larger eggs of heterophyid fluke, most probably *S. fuscata*.

Eggs of *S. fuscata* are definitely distinguished from similar trematode eggs, such as *Eurytrema pancreaticum* and *Plagiorchis muris*, in some morphological characters. Eggs of *E. pancreaticum* (large sized type; $53.6 \times 33.0 \mu\text{m}$ in average; small sized type; $42.6 \times 31.6 \mu\text{m}$ in average) are somewhat larger than those of *S. fuscata*, and they have thicker and deep dark-brown shells [14]. On the other hand, eggs of *P. muris* ($34 \times 22 \mu\text{m}$ in average) are broadly elliptical and more or less smaller than those of *S. fuscata*, and they have a conspicuous operculum and golden brown shell [15].

S. fuscata adults from a human infection case were described in the Republic of Korea under the name of *Stictodora* sp. by Chai et al. [12]. Worms described by Chai et al. [12] looked like somewhat deformed by drugs. Therefore, we redescribed with completely intact *S. fuscata* adults obtained from human cases in our study. They were more slender in body shape, when we compared with those from experimental cats [13]. Human infections with this fluke have been reported in about 18 cases so far [2,6,8-10]. Our study adds 7 cases confirmed by worm recovery and 25 egg-positive cases. In addition, *G. seoi* (5 cases), *P. summa* (3 cases), *S. falcatus* (2 cases), and *S. lari* (1 case) cases were added by the present study.

A. felis was originally described based on the specimens recovered from the small intestine of stray cats in the Republic of Korea [16]. The common blackish goby, *A. flavimanus*, has been confirmed to act as a second intermediate host [17]. Only the cat has been known as its natural definitive host. Therefore, it was confirmed for the first time that this fluke is a human-infecting species by the present study. In case of the other species of *Acanthotrema*, *A. tanayensis* and *A. tridactyla* were recovered from cats, *A. cursitans* from rodents, and *A. martini*, *A. acanthotrema*, *A. armata*, *A. tridactyla* and *A. hancocki* were found from avian hosts [18-21].

Residents selected for the worm recovery were all aged people in this study. Although they were heavily infected with intestinal flukes, they did not complain any special gastrointestinal symptoms. This phenomenon can be explained as that aged people have more chances to eat raw flesh of estuarine fish, and they are continuously reinfected with intestinal flukes in endemic areas. Some species of estuarine fish, such as *L. japonicus*, *Clupanodon punctatus*, *M. cephalus*, and *A. flavimanus*, have been reported as sources of human infections in endemic areas of heterophyid flukes [2]. Surveys on these fish intermediate hosts

have been performed in southwestern coastal areas [13,22-26]. Nevertheless, more systematic surveys should be done to reveal the variety of fish hosts from endemic areas, especially Muan-gun, Jeollanam-do.

ACKNOWLEDGEMENTS

This study was supported by an Anti-Communicable Diseases Control Program of the National Institute of Health (NIH 348-6111-215), Ministry of Health and Welfare, the Republic of Korea. We thank Miss A-Ra Cho and Hae-In Ryu, Department of Parasitology, Gyeongsang National University School of Medicine, Jinju, Korea, for their help in the worm recovery and questionnaire investigation.

REFERENCES

1. Chai JY. Intestinal flukes. In Murrell KD, Fried B eds. Food-borne parasitic zoonoses: Fish and plant-borne parasites. World Class Parasites, Vol. 11. New York, USA. Springer. 2007, p 53-115.
2. Chai JY, Lee SH. Food-borne intestinal trematode infections in the Republic of Korea. Parasitol Int 2002; 51: 129-154.
3. Cho SH, Lee KY, Lee BC, Cho PY, Cheun HI, Hong ST, Sohn WM, Kim TS. Prevalence of clonorchiasis in southern endemic areas of Korea in 2006. Korean J Parasitol 2008; 46: 133-137.
4. Korea Centers for Disease Control and Prevention, Korea Association of Health Promotion: prevalence of intestinal parasites in Korea. The 7th Report. Seoul, Korea, Art Motion, 2004.
5. Kim TS, Cho SH, Huh S, Kong Y, Sohn WM, Hwang SS, Chai JY, Lee SH, Park YK, Oh DK, Lee JK. A nationwide survey on the prevalence of intestinal parasitic infections in the Republic of Korea, 2004. Korean J Parasitol 2009; 47: 37-47.
6. Chai JY, Kim IM, Seo M, Guk SM, Kim JL, Sohn WM, Lee SH. A new endemic focus of *Heterophyes nocens*, *Pygidiopsis summa*, and other intestinal flukes in a coastal area of Muangun, Chollanam-do. Korean J Parasitol 1997; 35: 233-238.
7. Chai JY, Nam HK, Kook J, Lee SH. The first discovery of an endemic focus of *Heterophyes nocens* (Heterophyidae) infection in Korea. Korean J Parasitol 1994; 32: 157-161.
8. Chai JY, Song TE, Han ET, Guk SM, Park YK, Choi MH, Lee SH. Two endemic foci of heterophyids and other intestinal fluke infections in southern and western coastal areas in Korea. Korean J Parasitol 1998; 36: 155-161.
9. Chai JY, Park JH, Han ET, Shin EH, Kim JL, Guk SM, Hong KS, Lee SH, Rim HJ. Prevalence of *Heterophyes nocens* and *Pygidiopsis summa* infections among residents of the western and southern coastal islands of the Republic of Korea. Am J Trop Med Hyg 2004; 71: 617-622.
10. Park JH, Kim JL, Shin EH, Guk SM, Park YK, Chai JY. A new endemic focus of *Heterophyes nocens* and other heterophyid infec-

- tions in a coastal area of Gangjin-gun, Jeollanam-do. *Korean J Parasitol* 2007; 45: 33-38.
11. Onji Y, Nishio T. A monograph of intestinal trematodes. Chiba Igakkai Zasshi 1924; 2: 113-161.
 12. Chai JY, Hong SJ, Lee SH, Seo BS. *Stictodora* sp. (Trematoda: Heterophyidae) recovered from a man in Korea. *Korean J Parasitol* 1988; 26: 127-132.
 13. Sohn WM, Chai JY, Lee SH. *Stictodora fuscatum* (Heterophyidae) metacercariae encysted in gobies, *Acanthogobius flavimanus*. *Korean J Parasitol* 1994; 32: 143-148.
 14. Jang DH. Study on the *Eurytrema pancreaticum*. II. Life cycle. *Korean J Parasitol* 1969; 7: 178-200 (in Korean).
 15. Hong SJ, Woo HC, Chai JY. A human case of *Plagiorchis muris* (Tanabe, 1922: Digenea) infection in the Republic of Korea: fresh-water fish as a possible source of infection. *J Parasitol* 1996; 82: 647-649.
 16. Sohn WM, Han ET, Chai JY. *Acanthotrema felis* n. sp. (Digenea: Heterophyidae) from the small intestine of stray cats in the Republic of Korea. *J Parasitol* 2003; 89: 154-158.
 17. Sohn WM, Han ET, Seo M, Chai JY. Identification of *Acanthotrema felis* (Digenea: Heterophyidae) metacercariae encysted in the brackish water fish *Acanthogobius flavimanus*. *Korean J Parasitol* 2003; 41: 101-105.
 18. Lafuente M, Roca V, Carbonell E. Description of *Acanthotrema armata* n. sp. (Trematoda: Heterophyidae) from *Larus audouinii* (Aves: Laridae), with an amended diagnosis of the genus *Acanthotrema* Travassos, 1928. *Syst Parasitol* 2000; 45: 131-134.
 19. Roca V, Lafuente M, Carbonell E. Helminth communities in Audouin's gulls, *Larus audouinii* from Chafarinas Islands (western Mediterranean). *J Parasitol* 1999; 85: 984-986.
 20. Velasquez CC. Observations on some Heterophyidae (Trematoda: Digenea) encysted in Philippine fishes. *J Parasitol* 1973; 59: 77-84.
 21. Yamaguti S. Synopsis of Digenetic Trematodes of Vertebrates. Vol. I. Tokyo, Japan. Keigaku Publishing Co. 1971, p 1074.
 22. Seo BS, Hong ST, Chai JY, Cho SY. Studies on intestinal trematodes in Korea. IV. Geographical distribution of *Pygidiopsis* and *Heterophyes* metacercariae. *Seoul J Med* 1981; 22: 236-242.
 23. Chai JY, Park SK, Hong SJ, Choi MH, Lee SH. Identification of *Stictodora lari* (Heterophyidae) metacercariae encysted in the brackish water fish, *Acanthogobius flavimanus*. *Korean J Parasitol* 1989; 27: 253-259.
 24. Sohn WM, Moon BC. Infection status with the metacercariae of heterophyid trematode in mullet and goby collected from western coastal areas of Cholla-do, Korea. *J Biomed Lab Sci* 2001; 7: 31-37.
 25. Kim DG, Kim TS, Cho SH, Song HJ, Sohn WM. Heterophyid metacercarial infections in brackish water fishes from Jinju-man (Bay), Kyongsangnam-do, Korea. *Korean J Parasitol* 2006; 44: 7-13.
 26. Sohn WM, Na BK, Cho SH. *Echinostoma hortense* and heterophyid metacercariae encysted in yellowfin goby, *Acanthogobius flavimanus*, from Shinan-gun and Muan-gun (Jeollanam-do), Korea. *Korean J Parasitol* 2009; 47: 307-310.