



# A rare complication developing after delivery: septic pelvic thromboembophlebitis

Ersin Çintesun<sup>1</sup> , Denizhan Bayramoğlu<sup>1</sup> , Emine Uysal<sup>2</sup> , Çetin Çelik<sup>1</sup> 

<sup>1</sup>Department of Obstetrics and Gynecology, Faculty of Medicine, Selçuk University, Konya, Turkey

<sup>2</sup>Department of Radiology, Faculty of Medicine, Selçuk University, Konya, Turkey

## Abstract

**Objective:** In this case report, we aimed to discuss a septic pelvic thromboembophlebitis (SPT) case detected 20 days later who had the previous history of cesarean section and had an intrauterine still-birth vaginally at 30 weeks of gestation.

**Case:** A 24-year old patient, who admitted to the emergency service with the complaints of fever and pain in the lower right abdomen and was reported to have a 4 cm formation consistent with thrombus on the right ovarian vein wall in the computed tomography (ST), was hospitalized for follow-up and treatment. The patient whose thrombus showed remission in the check-up tomography scan after the broad-spectrum antibiotherapy and anticoagulant treatment was discharged on the 10th day. The treatment of the patient who did not develop any complication in the follow-ups was completed with recover.

**Conclusion:** In conclusion, SPT is a complication which is seen rarely in both obstetric and gynecologic practices. SPT is a disease which may lead to fatal outcomes by late diagnosis but satisfying results with early diagnosis. Abdominal pain and fever symptoms should come to mind in all cases after delivery or operation.

**Keywords:** Septic pelvic thromboembophlebitis, pregnancy, fever.

## Özet: Doğum sonrası gelişen ender bir komplikasyon: Septik pelvik tromboemboflebit

**Amaç:** Bu olgu bildiriminde, geçirilmiş sezaryen öyküsü olan ve vajinal yolla 30. haftada intrauterin ölü doğum yapmış bir hastada, 20 gün sonra tespit edilen septik pelvik tromboemboflebit (SPT) olgusunun tartışılmasını amaçladık.

**Olgu:** 24 yaşında, ateş ve sağ alt karın ağrısı ile acil servise başvuran ve bilgisayarlı tomografi (BT) görüntülemesinde sağ ovaryen ven duvarında 4 cm ebatında segmente trombüs ile uyumlu görünüm raporlanan hasta takip ve tedavi amacıyla yatırıldı. Geniş spektrumlu antibiyoterapi ve antikoagülan tedavisi sonrası kontrol tomografi görüntüsünde trombüsü gerileyen hasta 10. gün taburcu edildi. Takiplerinde komplikasyon gelişmeyen hastanın tedavisi şifa ile sonuçlandı.

**Sonuç:** Sonuç olarak, SPT hem obstetrik hem de jinekoloji pratiğinde oldukça ender rastlanan bir komplikasyondur. SPT, geç tanının ölümcül sonuçlar doğurabileceği ancak erken tanı ile de yüz güldürücü sonuçlar alınabilen bir hastalıktır. Doğum veya operasyon sonrası karın ağrısı ve ateş bulguları olan her olguda mutlaka akla gelmelidir.

**Anahtar sözcükler:** Septik pelvik tromboemboflebit, gebelik, ateş.

## Introduction

Septic pelvic thromboembophlebitis (SPT) is a quite rare but significant complication seen after pelvic infection. While it usually develops after delivery in association with endometritis, it may also occur due to malignancy and pelvic inflammatory diseases.<sup>[1-3]</sup> It has two different clinical forms, which are ovarian vein

thrombophlebitis (OVT) and deep septic pelvic thromboembophlebitis (DSPT). SPT is observed in one out of 3000 deliveries and it is more frequent in cesarean sections.<sup>[4]</sup> Its risk factors are the cesarean section, chorioamnionitis, induced abortions, multiple pregnancies and maternal age being <20.<sup>[3,5]</sup> Most of the cases have pain in the lower right abdomen and fever 48–96 hours after the delivery.<sup>[6]</sup> Rarely, it may have

**Correspondence:** Ersin Çintesun, MD. Department of Obstetrics and Gynecology, Faculty of Medicine, Selçuk University, Konya, Turkey. e-mail: ersincintesun@gmail.com / **Received:** March 5, 2020; **Accepted:** April 10, 2020

**Please cite this article as:** Çintesun E, Bayramoğlu D, Uysal E, Çelik Ç. A rare complication developing after delivery: septic pelvic thromboembophlebitis. Perinatal Journal 2020;28(1):52–55. doi:10.2399/prn.20.0281010

persistent fever and lower abdominal pain despite the antibiotherapy. Although imaging methods are used in the diagnosis of the disease, the success rates are relatively limited. Sometimes, the response to an anticoagulant treatment already initiated may help to diagnose SPT. Today, it can be treated with antibiotics and anticoagulants. The important issue in this disease is to recognize and remember that such a clinic condition may develop. When the diagnosis of the disease is late, it may progress fatally.

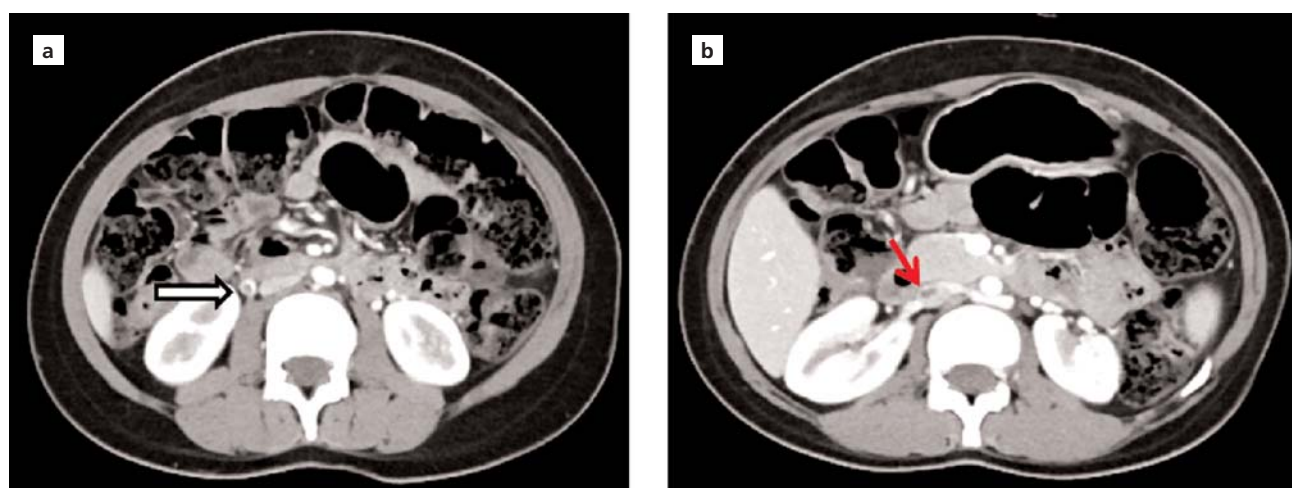
In this case report, we aimed to discuss a SPT case which has the potential for morbidity and mortality in case of late diagnosis but satisfying results can be achieved by the treatment during diagnosis, and to raise awareness on this disease. Therefore, we discussed a SPT case detected 20 days later who had the previous history of cesarean section and had an intrauterine stillbirth vaginally at 30 weeks of gestation in our study.

### Case Report

A 24-year old patient, who admitted to the emergency service with the complaints of fever and pain in the lower right abdomen and was reported to have a 4 cm formation consistent with thrombus on the right ovarian vein wall in the computed tomography (ST), was hospitalized for follow-up and treatment (**Fig. 1**). After checking her history, it was found that the case underwent a cesarean section previously, had a unilateral loss of hearing and had an

intrauterine stillbirth vaginally at 30 weeks of gestation 20 days ago in another center. Sensitivity was observed in the right lower quadrant in the abdominopelvic examination. No pathology was found in the examinations carried out on other systems. The highest temperature during admission was 37.8°C, and arterial pressure and pulse were within normal range. In the laboratory analyses, it was found that Hgb was 12.2 g/dL, WBC was 9.2 K/mm<sup>3</sup>, liver and kidney function tests were normal, and CRP was 8.20 mg/L. It was observed that the procalcitonin was <0.5 µg/L. Samples were collected from the patient for vaginal cervix culture. No formation consistent with thrombus was observed in the lower extremities in the bilateral lower extremity Doppler USG. Antibiotherapy (intravenous [IV] ampicillin-sulbactam 1 g 4×1) and anticoagulant (subcutaneous enoxaparin 4000 IU 2×1) treatments were initiated.

Beginning from the 24th hour of the treatment, the pelvic pain and fever of the hospital regressed to the normal levels. As the venous line could not be seen clearly on the pelvic MRI on the 7th day, computed tomography (CT) was repeated upon the recommendation of the radiology department. It was reported that thrombus regressed at a high level (**Fig. 2**). As WBC and CRP values were within the normal limits and there was no reproduction in the cervix culture according to the laboratory analysis, the patient was discharged on the 10th day by oral antibiotherapy and anticoagulant treatments. It was also recommended to



**Fig. 1.** (a) In the CT image with axial contrast, elevated diameter in the right ovarian vein and thrombus (white/light colored arrow) in it, and (b) the thrombus (red/dark colored arrow) in the inferior vena cava can be seen.

perform the anticoagulant treatment for 6 weeks. The informed consent was received from the patient to use her medical data in scientific studies.

## Discussion

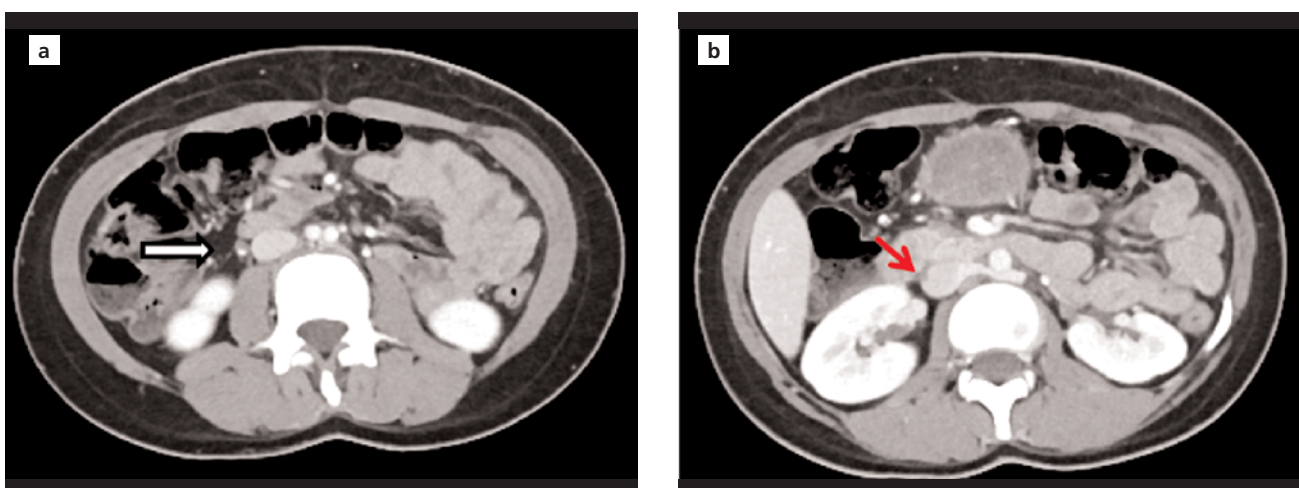
Although SPT develops rarely in the obstetric patient population, its mortality is 4.4%.<sup>[7,8]</sup> The pathogenesis of SPT is explained by Virchow's triad. The venous stasis due to venous dilation during pregnancy and reduced venous pressure or hypercoagulopathy secondary to the pregnancy causes endothelial cell injury which occurs directly or due to infection by delivery or surgical procedures. In addition, SPT is observed most frequently in the right ovary due to the presence of sigmoid colon in the left ovary, right ovarian vein being longer and uterus making more pressure on the right side during pregnancy.<sup>[9]</sup> In our case, we observed thrombus on the right ovarian vein during her admission. Also, observing on the 20th day after delivery make us think that pregnancy-associated impacts have a contribution on this condition.

The two different forms of SPT, which are OVT and DSPT, differ from each other in terms of clinical findings and diagnosis. While there are fever and pain in the right lower quadrant one week after delivery or surgical procedure, the mass can be palpated on the right lower quadrant in some cases. It is possible to observe right ovarian vein thrombus in 20% of the cases

by imaging methods.<sup>[8,10,11]</sup> In DSPT, there is an intense condition manifesting itself with fever resistant to antibiotics a few days after delivery or surgical procedure and mostly before discharge, and usually there is no pain.<sup>[6]</sup> In these cases, thrombus is not observed usually in the screening.<sup>[8,10,11]</sup> While reproduction is not usually observed in the culture in OVT and DPST cases which is an advanced form of SPT, a study conducted on a series of 158 postpartum OVT cases reported that reproduction occurred in the cultures of 22% of the cases, where it was mostly streptococcus.<sup>[12]</sup> Since our case did not have high fever, we did not examine blood culture, and there was no reproduction in the cervix culture. Our case delivering stillbirth vaginally 20 days ago made us think that she had OVT due to an infection after delivery as a risk factor.

Septic pulmonary emboly (SPE) (13%) and metastatic abscess were reported as the two important complications of SPT.<sup>[13]</sup> Also, some studies reported other complications such as the clot clogging iliofemoral or renal vein by reverse flow.<sup>[14,15]</sup> In addition, septic thrombi and embolies are the source of bacteremia and they can be fatal if not treated.<sup>[15]</sup>

In the suspected cases whose fever does not go down despite the antibiotic treatment, receiving fever response 48 hours after anticoagulant treatment can be used for the diagnosis.<sup>[8]</sup> SPT diagnosis can be established specifically by detecting palpable intravenous thrombus and purulent fluid in the exploratory laparo-



**Fig. 2.** (a) It can be seen in the axial CT images with control contrast that the diameter of the right ovarian vein became normal, and the thrombus in the right ovarian vein (white/light colored arrow) and (b) in the inferior vena cava (red/dark colored arrow) regressed partially.

tomy, but it is rarely used. In the treatment of the disease, it seems appropriate to add anticoagulant treatment to the broad-spectrum antibiotherapy which contains potential bacteria.<sup>[16]</sup> Although there is no certain rule for the type and duration of anticoagulant treatment in the relevant literature, unfractionated heparin and low molecular weight heparin are the options used most commonly. In our case, we administered low molecular weight heparin in the dose of 1 mg/kg with 12-hour interval, and observed that the complaints of the patient regressed completely by continuing the treatment for six weeks as the thrombus was confirmed radiologically. As we observed the distinct regression in the check-up tomography scan performed previously, MRI was not effective in the diagnosis of this patient and for the purpose of protecting the patient for re-exposure to the radiation, we considered the full regression of the clinical results as recovery.

## Conclusion

In conclusion, SPT is a complication which is seen rarely in both obstetric and gynecologic practices. SPT is a disease which may lead to fatal outcomes by late diagnosis but satisfying results with early diagnosis. Our case exhibited an atypical progress in general, and her condition was detected by coincidence. As seen in our case, it is essential to remember and rule out SPT diagnosis in the cases with fever and abdominal pain in the postpartum period. Unfortunately, this rare disease has severe outcomes and it should always come to mind in the differential diagnosis.

**Conflicts of Interest:** No conflicts declared

## References

1. Yıldız K, Soyalp C. The cause of persistent fever after the caesarean section: ovarian vein thrombosis. [Article in Turkish] *Van Tıp Dergisi* 2017;24:47-9.
2. Çintesun E, Gül A, Şahin G, Bayramoğlu D, Uysal E, Çelik Ç. Ovarian vein thrombophlebitis after pelvic inflammatory disease: a case report. [Article in Turkish] *Ege Tıp Dergisi* 2019; 58:313-5.
3. Collins CG, MacCallum EA, Nelson EW, Weinstein BB, Collins JH. Suppurative pelvic thrombophlebitis. I. Incidence, pathology, and etiology; a study of 70 patients treated by ligation of the inferior vena cava and ovarian vessels. *Surgery* 1951;30:298-310.
4. Wysokinska EM, Hodge D, McBane RD 2nd. Ovarian vein thrombosis: incidence of recurrent venous thromboembolism and survival. *Thromb Haemost* 2006;96:126-31.
5. Dotters-Katz SK, Smid MC, Grace MR, Thompson JL, Heine RP, Manuck T. Risk factors for postpartum septic pelvic thrombophlebitis: a multicenter cohort. *Am J Perinatol* 2017;34:1148-51.
6. Eser A, Aday G, İnegöl İ, Sürgit Ö, Karataş G, Gonca MO. Septic pelvic thrombophlebitis in differential diagnosis of postpartum acute abdomen: case report. [Article in Turkish] *Türkiye Klinikleri Journal of Clinical Obstetrics & Gynecology* 2015;25:287-91.
7. Cunningham F, Leveno K, Bloom S, Spong CY, Dashe J. *Williams obstetrics*, 24e. New York, NY: McGraw-Hill; 2014.
8. Kır M, Üstün C, Kökçü A, Çokşenim Ş. Septic pelvic thrombophlebitis: a case report. [Article in Turkish] *Journal of Experimental and Clinical Medicine* 1992;9:283-5.
9. Hodgkinson C. Physiology of the ovarian veins during pregnancy. *Obstet Gynecol* 1953;1:26-37.
10. Kadanalı A, Karagöz G. Puerperal enfeksiyonlar. In: Çiçek NM, Akyürek C, Çelik Ç, Haberal A, editörler. *Kadın hastalıkları ve doğum bilgisi*. Vol 1. 3rd ed. Ankara: Atlas Kitapçılık; 2012. p. 323-8.
11. Garcia J, Aboujaoude R, Apuzzo J, Alvarez JR. Septic pelvic thrombophlebitis: diagnosis and management. *Infect Dis Obstet Gynecol* 2006;15614.
12. Dunnihoo DR, Gallaspy JW, Wise RB, Otterson WN. Postpartum ovarian vein thrombophlebitis: a review. *Obstet Gynecol Surv* 1991;46:415-27.
13. Nezhad C, Farhady P, Lemyre M. Septic pelvic thrombophlebitis following laparoscopic hysterectomy. *JLS* 2009;13: 84-6.
14. Hassen-Khodja R, Gillet JY, Batt M, Bongain A, Persch M, Libo L, et al. Thrombophlebitis of the ovarian vein with free-floating thrombus in the inferior vena cava. *Ann Vasc Surg* 1993;7:582-6.
15. Witlin AG, Sibai BM. Postpartum ovarian vein thrombosis after vaginal delivery: a report of 11 cases. *Obstet Gynecol* 1995;85: 775-80.
16. Josey WE, Staggers SR Jr. Heparin therapy in septic pelvic thrombophlebitis: a study of 46 cases. *Am J Obstet Gynecol* 1974;120:228-33.

Bu makalenin kullanım izni Creative Commons Attribution-NoCommercial-NoDerivs 3.0 Unported (CC BY-NC-ND3.0) lisansı aracılığıyla bedelsiz sunulmaktadır. / This work is licensed under the Creative Commons Attribution-NonCommercial-NoDerivs 3.0 Unported (CC BY-NC-ND3.0) License. To view a copy of this license, visit <http://creativecommons.org/licenses/by-nc-nd/3.0/> or send a letter to Creative Commons, PO Box 1866, Mountain View, CA 94042, USA.