

CLINICAL CASE:

“TREATING A PATIENT WITH CHRONIC PERIODONTITIS”

*Eduardo Montero, David Herrera. Posgrado de Periodoncia, Facultad de Odontología
Universidad Complutense de Madrid*

▪ INTRODUCTION

Periodontitis is a set of infectious diseases of the tooth support tissues (periodontal ligament, cementum and alveolar bone), resulting in the progressive destruction of these tissues. This destruction is accompanied by the formation of pockets between teeth and gums, where bacteria responsible for the process, accumulate and organise themselves to form biofilm.

The aim of periodontal treatment is to control the infection in order to stop disease progression and to be able to maintain a healthy periodontium. Mechanical debridement of supra- and subgingival biofilm, together with adequate oral hygiene is the standard periodontal therapy. Subgingival debridement leads to significant reductions in the total subgingival bacterial counts (*Teles et al. 2006*), causing an additional change in flora to one that is less pathogenic and that is characterised by high levels of gram-positive aerobic microorganisms (*Ximenez-Fyvie et al. 2000*). This mechanical subgingival biofilm debridement consists of an initial phase involving scaling and root planing and the elimination of plaque retentive factors, followed by a surgical phase including the elevation of a tissue flap and bone remodelling in cases where deep residual pockets persist, given that a clinician's main objective is to reduce the pocket depth to the greatest extent possible (*Kaldahl et al. 1996*).

The adjunct use of antiseptics has proven to additionally improve periodontal treatment results. Among these, mouthrinses containing 0.12% chlorhexidine have proven to obtain better clinical and microbiological results when used together with

scaling and root planing than studies in which chlorhexidine was not used (*Faveri et al. 2006*).

Moreover, it has been observed that different formulations sharing the same active ingredient, such as 0.12% chlorhexidine, may have very different effects (*Herrera et al. 2003*). In this regard, the addition of cetylpyridinium chloride to an alcohol-free formulation containing chlorhexidine (*Perio-Aid® treatment*) has proven to be an effective anti-plaque agent (*Quirynen et al. 2001*).

The following is a clinical case of a patient with chronic periodontitis who was treated with basic periodontal treatment with an adjunct antiseptic (with cetylpyridinium chloride and with chlorhexidine) and an antibiotic according to his microbiological profile, followed by surgical treatment again using the alcohol-free chlorhexidine cetylpyridinium chloride formulation (*Perio-Aid® treatment*).

▪ CLINICAL CASE

Case History:

48 year old male patient.

Reason for the Consultation:

Comes in for mobility and pain in tooth 2.2, as well as generalised gingival inflammation along with bleeding.

Overall Medical History:

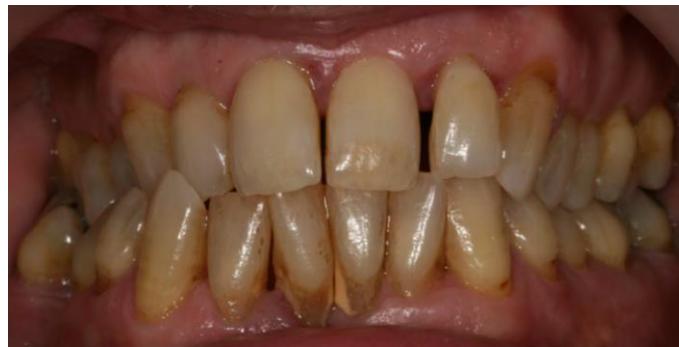The patient does not suffer any systemic disease and is classified as an ASA I type patient.

Family Background:

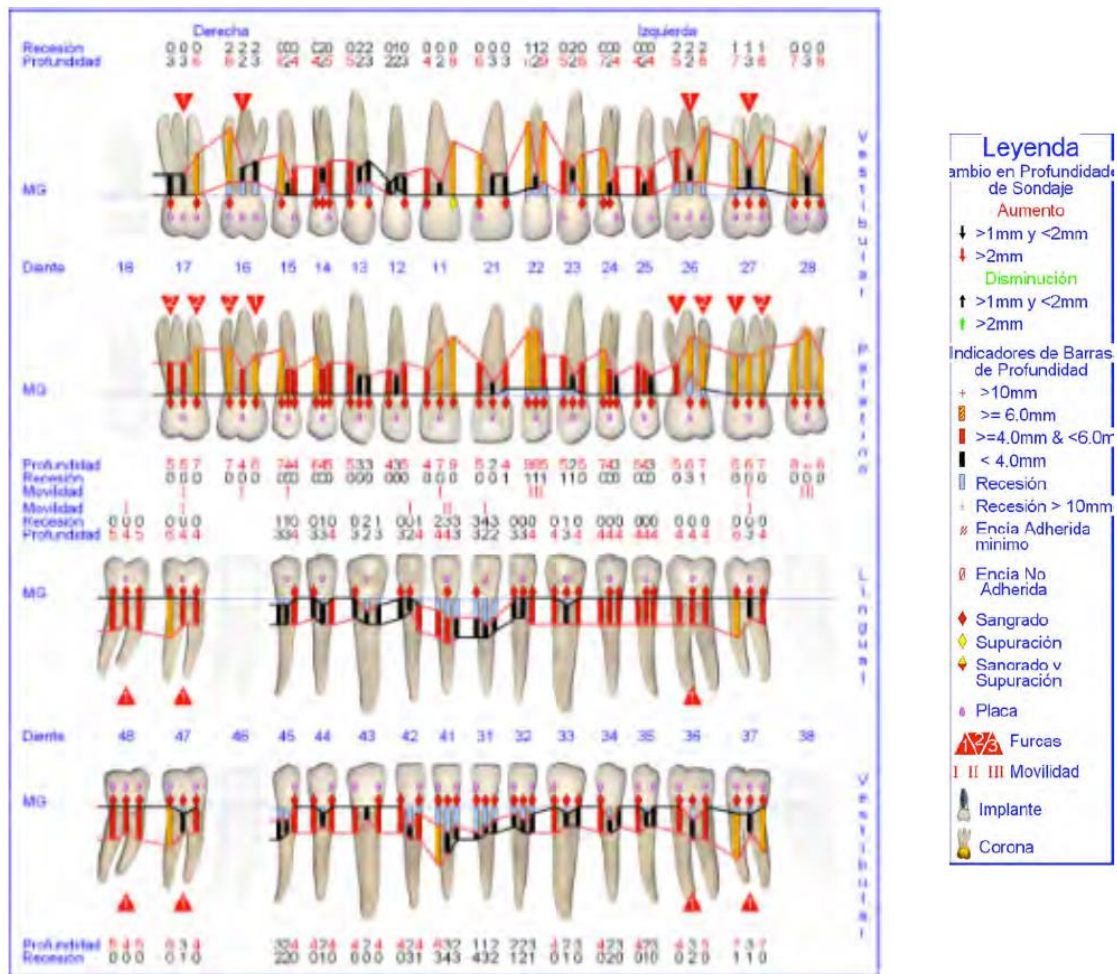
The patient does not report a family history of periodontitis, nor of any other systemic disease.

**Intraoral Examination:**

The intraoral examination reveals marked gingival inflammation as well as plaque accumulation and significant calculus deposits. Numerous poorly positioned teeth and diastemata are also observed.

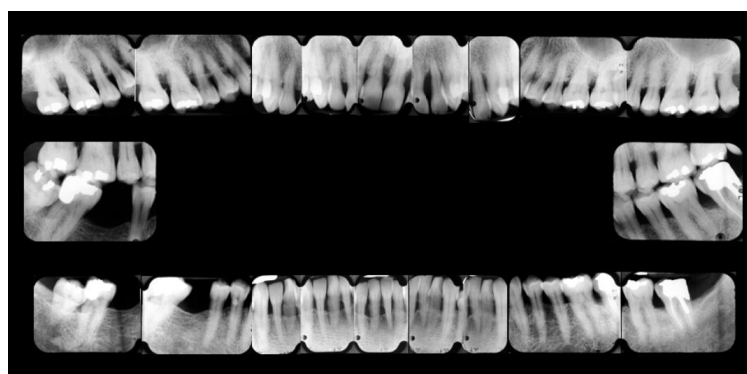
**Periodontal Examination:**

The periodontal examination reveals deep pockets ($\geq 6\text{mm}$) in all sextants, with furcal affection in all of the molars and plaque index and bleeding on probing of 67% y 71%, respectively.



Radiographic Examination:

The radiographic examination revealed moderate, advanced generalised bone loss in sextants I, II, III, and V. Interproximal intraosseous defects were mainly observed in the upper anterior section, as well as images showing furcal affectation in the maxillary molars. This was considered to be a pattern of mainly horizontal bone loss.



Microbiological Diagnosis:

Subgingival microbiological samples were taken from the deepest bleeding pockets of each quadrant, and the patient showed total anaerobic counts of 9.73×10^7 , with proportions of *Porphyromonas gingivalis* and *Tannerella forsythia* over the total subgingival flora of 91,56% and 4,20%, respectively.

Laboratorio de Investigación					CLAVE	1408
Siglas:	E.R.P.				Fumador	
Año nacimiento:						
Clínica:	EDUARDO MONTERO				Antibióticos:	NO
Fecha de toma:						(cuál; hace cuánto)
Causa de toma:						
Salud general:						
Medicamentos:						
Otros comentarios:						
Momento toma:	PRE-RAR				(pre-RAR, post-RAR, post-QCO, MTO, control)	
	1	2	3	4	recuentos	%flora
Localización					total anaerobios	97350000
Profundidad bolsa					<i>A. actinomyc.</i>	0
Recesión					<i>P. gingivalis</i>	79398000
Sangrado					<i>P. intermedia</i>	3762000
Placa					<i>T. forsythia</i>	4092000
Supuración					<i>P. micros</i>	1122000
Movilidad					<i>F. nucleatum</i>	792000
					<i>C. rectus</i>	0
					<i>E. corrodens</i>	0
					<i>Capnocytophaga sp.</i>	0
					<i>Eubacterium sp.</i>	0
Comentario resultados (solo laboratorio)						

DIAGNOSIS

The patient was diagnosed with localised advanced/ generalised moderate chronic periodontitis, in accordance with the 1999 classification (*Armitage et al. 1999*).

STEP-BY-STEP TREATMENT PLAN**1. Patient information.**

Patient was told everything about his disease and the treatment, particularly stressing risk factors and the importance of hygiene.

2. Systemic control phase.

Not necessary.

3. Control of other oral infections.

Not necessary.

4. Oral hygiene instructions.

The Bass brushing technique and how to use the most suitable sized interdental brushes (Interprox®) was explained to the patient.

5. Elimination of retentive factors.

Not necessary.

6. Occlusal adjustment and stabilisation.

Elimination of occlusal trauma in 11 and 22.

7. Supragingival Prophylaxis.

Performed together with the next procedure.

8. Scaling and root planing.

Under local anaesthesia and in two sessions, treating two quadrants on the same side in the same session, each lasting approx. 75 minutes.

9. Adjunct treatment with antiseptics.

Rinse with 15 mL of a 0.12% chlorhexidine + 0.05% cetylpyridinium chloride mouthwash (Perio-Aid® treatment) for 30 seconds, two times per day, for 15 days. After mechanical hygiene, after breakfast and after dinner.

10. Adjunct antibiotic treatment.

Prescription of Metronidazole 500mg/8h/7 days, as per microbiological profile.

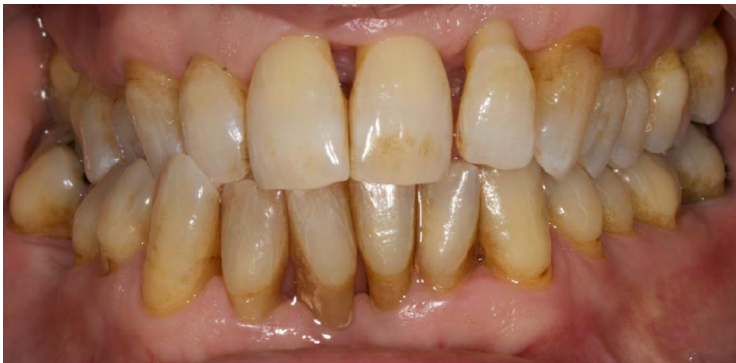11. Surgical removal of pockets.

Pockets were removed surgically in sextants 1 and 3, and distal wedge in tooth #37, as per results observed in the re-assessment described below.


RE-ASSESSMENT

Periodontal re-assessment was performed one month after treatment, with an improvement shown with regard to the following parameters:

- Marked reduction of gingival inflammation and removal of calculus deposits.



- Reduction in plaque and bleeding indexes (14% and 12% respectively).
- Reduction in pocket depth and gain in clinical attachment.



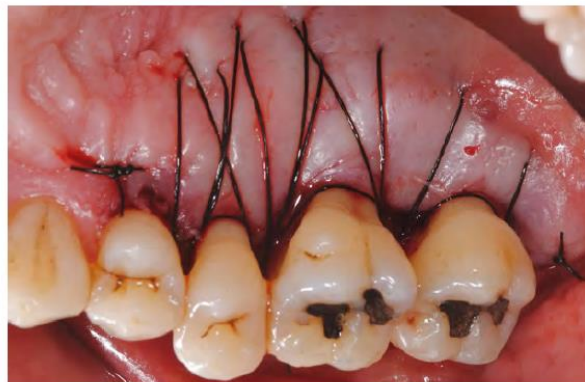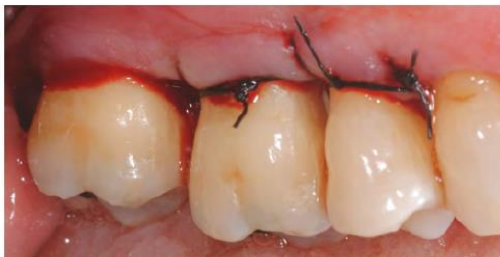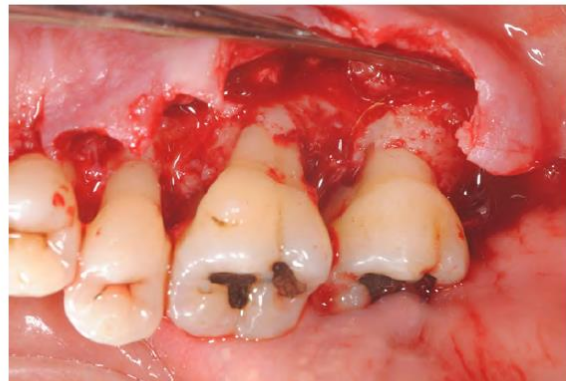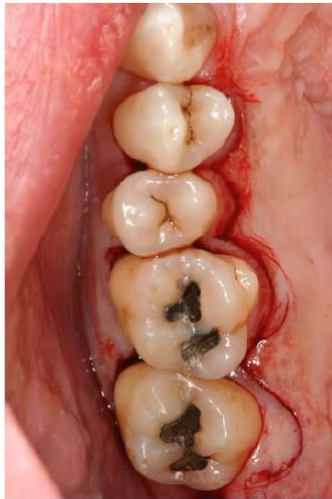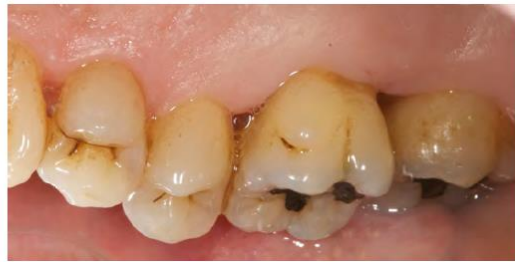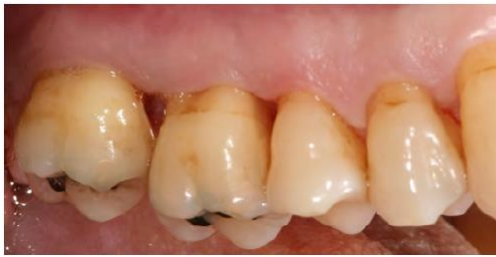- Reduction in total counts of anaerobic microorganisms (4.09×10^5) and of the proportions of periodontal pathogens (below the limit of detection for *Porphyromonas gingivalis* and *Tannerella forsythia*).

Laboratorio de Investigación					CLAVE	1467
Siglas:	E.R.P.				Fumador:	
Año nacimiento:						
Clínica:	EDUARDO MONTERO				Antibióticos:	
Fecha de toma:	28-nov-11					(cuál; hace cuánto)
Causa de toma:						
Salud general:						
Medicamentos:						
Otros comentarios:						
Momento toma:	POST-RAR (pre-RAR, post-RAR, post-QCO, MTO, control)					
	1	2	3	4	recuentos	%flora
Localización					total anaerobios	409200
Profundidad bolsa					<i>A. actinomyc.</i>	0 0,00%
Recesión					<i>P. gingivalis</i>	0 0,00%
Sangrado					<i>P. intermedia</i>	1320 0,32%
Placa					<i>T. forsythia</i>	0 0,00%
Supuración					<i>P. micros</i>	0 0,00%
Movilidad					<i>F. nucleatum</i>	6600 1,61%
					<i>C. rectus</i>	0 0,00%
					<i>E. corrodens</i>	2640 0,65%
					<i>Capnocytophaga sp.</i>	0 0,00%
					<i>Eubacterium sp.</i>	0 0,00%
Comentario resultados (solo laboratorio)						

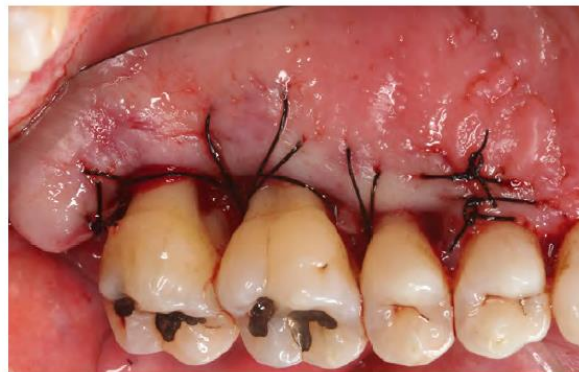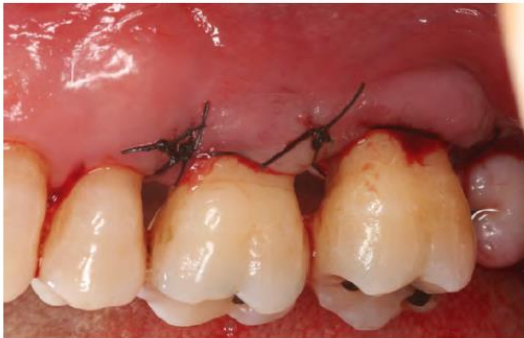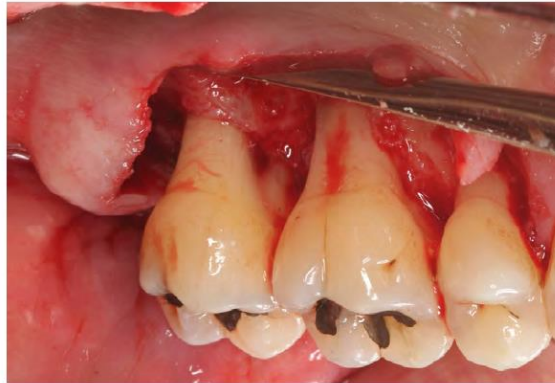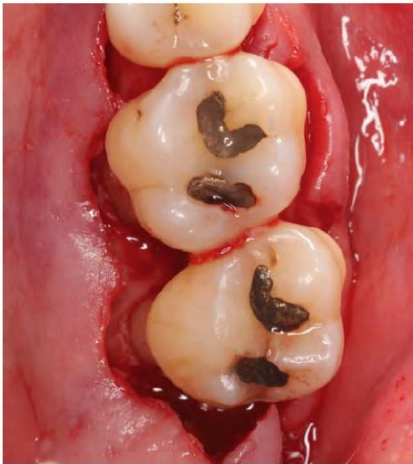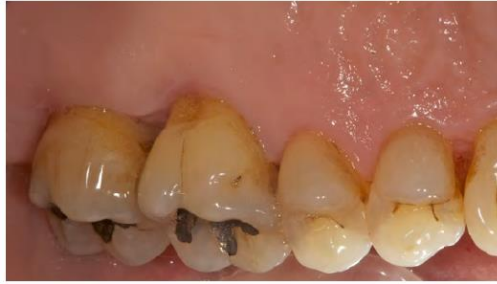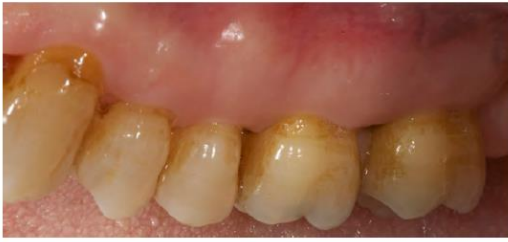ADDITIONAL TREATMENT

Following the basic periodontal treatment, some deep pockets remained (≥ 6 mm) in sextants I and III and in some specific sites of sextant II and in distal 37. Surgery was planned to remove pockets from sextants I and III, distal wedge was planned for tooth #37 and a re-scaling was programmed for sextant II in order to prevent further recession in this aesthetically compromised area. As a form of treatment support, after each surgery, the patient was instructed to rinse with 15ml of 0.12% chlorhexidine + 0.05% cetylpyridinium chloride mouthwash (Perio-Aid® treatment) for 30 seconds, two times per day, for 15 days.

Sextant I:



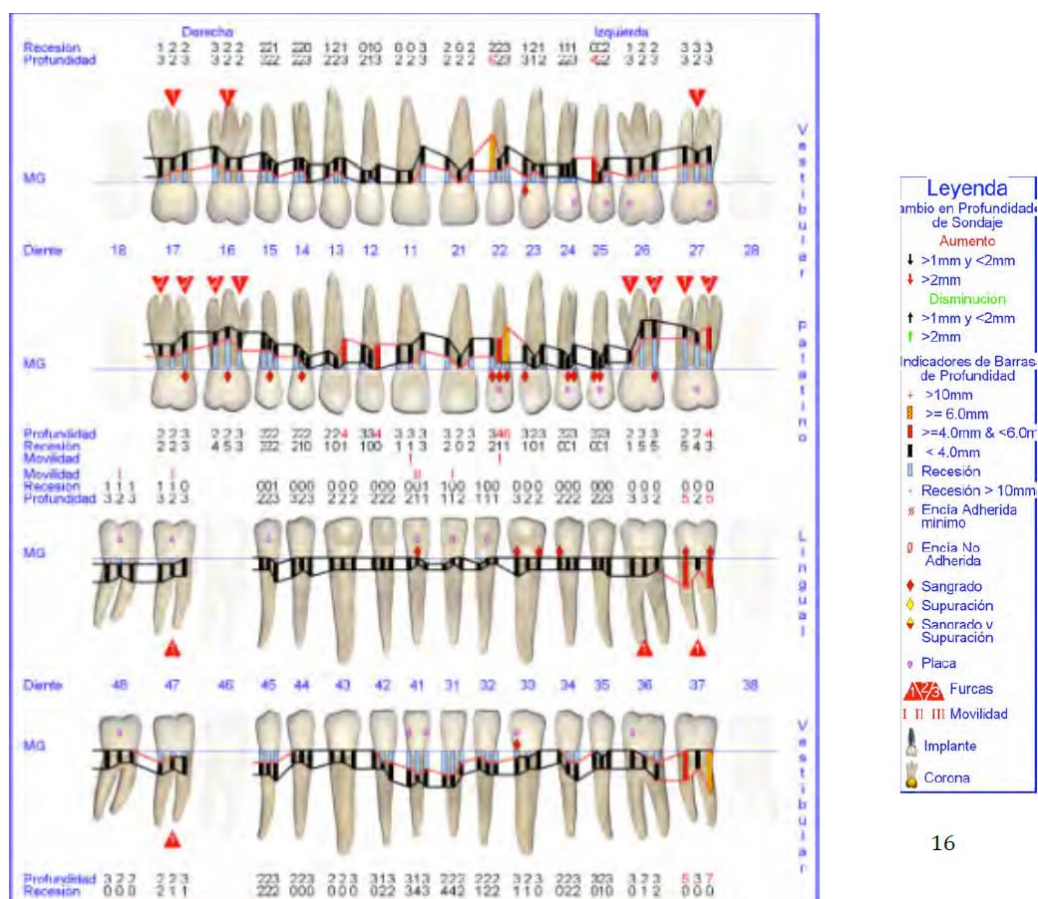
Sextant III:



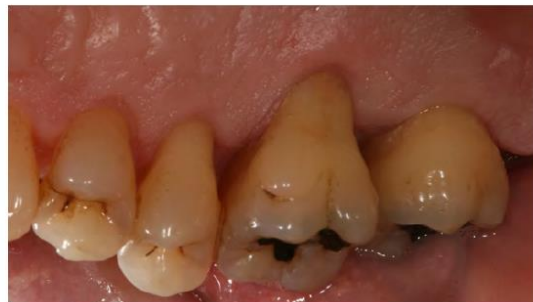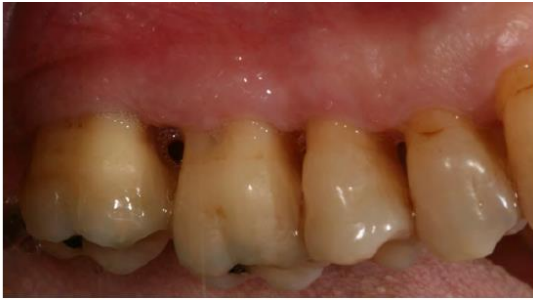RE-ASSESSMENT POST-SURGICAL TREATMENT

Following the surgical removal of pockets from sextants I and III, the distal wedge procedure was performed on tooth #37 (not shown here), and tooth #22 was scaled, ruling out any possible surgical procedure due to the lack of remaining bone support ($\leq 30\%$). Re-assessment of periodontal tissues 6 months after treatment, revealed continuous improvement in the following parameters:

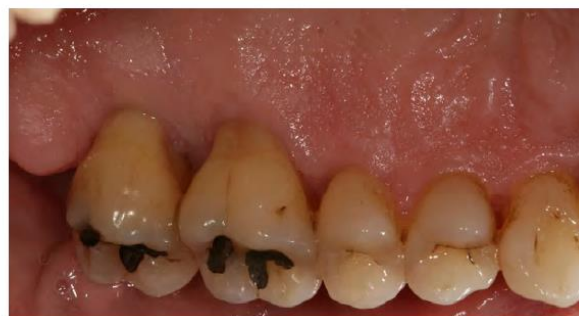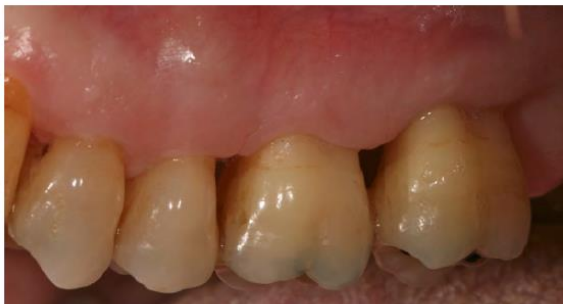- Reduction in plaque and bleeding indexes (10% and 8% respectively).
- Reduction in pocket depths.
- Creation of interdental spaces allowing for improved interproximal hygiene.



Sextant I:



Sextant III:



DISCUSSION

This case illustrates the periodontal treatment of a patient with chronic periodontitis using scaling and root planing and subsequent surgical interventions aimed at reducing residual pockets, with adjunctive use of a mouthrinse containing 0.12% Chlorhexidine and 0.05% Cetylpyridinium chloride (Perio-Aid® treatment) in all procedures.

The treatment of periodontal infections has traditionally been based on removal of supra y subgingival biofilm along with the periodic removal of supragingival plaque (Magnusson et al. 1984). We know that chlorhexidine is the gold standard antiseptic for controlling supragingival plaque, but that it must be formulated correctly within the final product (Herrera et al. 2003). In this regard, the product used adjunctively in this case has proven that the removal of alcohol from its formula does not reduce its antibacterial capacity, and that the addition of cetylpyridinium chloride increases this capacity (Quirynen et al. 2001; Herrera et al. 2003).

In this case, the treatment applied corresponded not only to an improvement of clinical parameters (pocket depth, attachment level, plaque index and bleeding on probing), but also to important changes in the subgingival flora, as observed by other authors (Faveri et al. 2006).

Mouthrinses containing chlorhexidine have not only been suggested to be used immediately after professional removal of supra and subgingival plaque, but it also may be used following oral surgical interventions (including periodontal surgery) given that it reduces the bacterial load in the oral cavity and prevents plaque formation at times when mechanical hygiene is difficult due to pain (Sanz et al. 1989). In fact, in periodontal surgery, the post-operative use of mouthwashes containing chlorhexidine has replaced periodontal dressing, as it improves healing and reduces discomfort (Newman and Addy, 1978).

Furthermore, medically compromised patients and patients with increased susceptibility for oral infections (such as diabetics, but also patients receiving chemotherapy or radiation therapy) can also benefit from using this antiseptic, even for preventing mucositis and infections by *Candida spp.* (Lanzos et al. 2010-2011).

Therefore, it can be concluded that periodontal treatment is effective in treating periodontitis, and that adjunctive use of a mouthrinse containing 0.12% chlorhexidine + 0.05% cetylpyridinium chloride (Perio-Aid® treatment) leads to an improved clinical and microbiological response, also improving post-surgical management of patients needing to undergo periodontal surgery.

REFERENCES

D'Aiuto et al. Oxidative stress, systemic inflammation, and severe periodontitis. *J Dent Res* (2010) vol. 89 (11) pp. 1241-6

Faveri et al. Scaling and root planing and chlorhexidine mouthrinses in the treatment of chronic periodontitis: a randomized, placebo-controlled clinical trial. *Journal of clinical periodontology* (2006) vol. 33 (11) pp. 819-28

Herrera et al. Differences in antimicrobial activity of four commercial 0.12% chlorhexidine mouthrinse formulations: an *in vitro* contact test and salivary bacterial counts study. *Journal of clinical periodontology* (2003) vol. 30 (4) pp. 307-14

Lanzós et al. Mucositis in irradiated cancer patients: effects of an antiseptic mouthrinse. *Med Oral Patol Oral Cir Bucal* (2010) vol. 15 (5) pp. e732-8

Lanzós et al. Microbiological effects of an antiseptic mouthrinse in irradiated cancer patients. *Med Oral Patol Oral Cir Bucal* (2011) vol. 16 (7) pp. e1036-42

Paraskevas et al. A systematic review and meta-analyses on C-reactive protein in relation to periodontitis. *Journal of clinical periodontology* (2008) vol. 35 (4) pp. 277-90

Preshaw et al. Periodontitis and diabetes: a two-way relationship. *Diabetologia* (2012) vol. 55 (1) pp. 21-31

Quirynen et al. Effect of different chlorhexidine formulations in mouthrinses on *de novo* plaque formation. *J Clin Periodontol* (2001) vol. 28 (12) pp. 1127-36