


PHLEBOLOGY

N°45

ISSN 1286-0107



2004 • N°44 • p.268-297

Subdiaphragmatic venous insufficiency PAGE 269
**Embolization treatment using
mixed technique (coils and foam)**

J. LEAL MONEDERO, S. ZUBICOA EZPELETA, M. GRIMBERG,
L. VERGARA CORREA, A. JIMÉNEZ GUTIÉRREZ (MADRID, ESPAÑA)

Rationale for surgery in the PAGE 276
treatment of venous ulcer of the leg

M. PERRIN (CHASSIEU, FRANCE)

The evolution of endovenous PAGE 285
radiofrequency ablation of varicose veins

N. FASSIADIS, A. THEODORIDES (LONDON, UK)

Variants of functional venous disease PAGE 289

C. ALLEGRA, A. CARLIZZA (ROME, ITALY)

LYMPHOLOGY

AIMS AND SCOPE

Phlebology is an international scientific journal entirely devoted to venous disease.

The aim of *Phlebology* is to provide doctors with updated and interesting information on phlebology and lymphology written by well-known specialists from different countries worldwide.

Phlebology is scientifically supported by a prestigious editorial board.

Phlebology has been published four times per year since 1994, and, thanks to its high scientific level, was included in the EMBASE database in 1998.

Phlebology is made up of several sections: editorial, articles on phlebology and lymphology, news, review, and congress calendar.

CITED/ABSTRACTED
IN EMBASE/Excerpta Medica

© 2004 Les Laboratoires Servier -
All rights reserved throughout the world
and in all languages.

Advisory board

PRESIDENT

H. PARTSCH, MD

Past President of the Union Internationale de Phlébologie
Baumeistergasse 85, A 1160 Vienna, Austria

MEMBERS

C. ALLEGRA, MD

Head, Dept of Angiology
President of the Union Internationale de Phlébologie
Hospital S. Giovanni Via S. Giovanni Laterano, 155 - 00184, Rome, Italy

P. COLERIDGE SMITH, MD

Senior Lecturer and Consultant Surgeon, University College London Medical School
The Middlesex Hospital Mortimer Street - London W1N 8AA, UK

M. COSPITE, MD

Head, Dept of Angiology
University Clinic, Palermo, Italy

G. JANTET, MD

Consultant Vascular Surgeon
Past President of the Union Internationale de Phlébologie
14, rue Duroc, 75007 Paris, France

P. S. MORTIMER, MD

Consultant Skin Physician & Senior Lecturer in Medicine (Dermatology)
St George's Hospital - Blackshaw Road, London SW17 0QT, UK

A. N. NICOLAIDES, MD

Institute of Neurology and Genetics
*6, International Airport Avenue - Ayios Dhom Ctios
P. O. Box 3462 CY 1683 Nicosia - Cyprus*

M. PERRIN, MD

Vascular Surgeon
Past President of the Société de Chirurgie Vasculaire de Langue Française
Past President of the Société Française de Phlébologie
Past President of the European Venous Forum
26, Chemin de Décines - 69680 Chassieu, France

L. THIERY, MD

Angiologist & Surgeon
Consultant, University Hospital Gent - Korte Meer 12, 900 Gent, Belgium

V. WIENERT, MD

Head, Dept of Phlebology
University Clinic - Pauwelstrasse, 51000 Aachen, Germany

CONTENTS

Cited/Abstracted in Embase/Excerpta Medica

EDITORIAL

H. PARTSCH (Vienna, Austria)

PHLEBOLOGY

Subdiaphragmatic venous insufficiency **Page 269**

J. LEAL MONEDERO, S. ZUBICOA EZPELETA, M. GRIMBERG,
L. VERGARA CORREA, A. JIMÉNEZ GUTIÉRREZ (Madrid, Spain)

Rationale for surgery in the treatment of venous ulcer of the leg **Page 276**

M. PERRIN (Chassieu, France)

REVIEW

Daflon 500 mg in the management of acute and recurrent hemorrhoidal disease **Page 281**

PHLEBOLOGY

The evolution of endovenous radiofrequency ablation (VNUS Closure) of varicose veins **Page 285**

N. FASSIADIS, A. THEODORIDES (London, UK)

Variants of functional venous disease **Page 289**

C. ALLEGRA, A. CARLIZZA (Rome, Italy)

NEWS

Congress and conference calendar **Page 293**

Saint Peregrine is the patron saint of the venous ulcer. The biography of this medieval monk reports that he developed large varicose veins because he refrained from lying down as a kind of penance. The veins became so large that the leg became ulcerated.

This is the classical description of varicose vein ulceration. Only since we have been using Duplex to investigate our ulcer patients on a regular basis have we are becoming aware of the fact that at least 50% of patients have superficial reflux, many of them without extensive visible varicose veins. At least those without concomitant deep venous insufficiency are therefore potential candidates for venous surgery (and not for amputation, as was proposed to St Peregrine by his doctor).

However, as demonstrated in the review by **Michel Perrin** in this issue of Phlebology there have been no convincing data available until now to show that the removal of incompetent superficial veins promotes ulcer healing in comparison with compression treatment alone. In recent years, the interest has mainly focussed on the eradication of incompetent perforators, and the importance of the “blow down” was probably underestimated. This may change with future studies, which will show that superficial reflux can also be corrected by catheter procedures or by foam sclerotherapy.

On the other hand, evidence-based data medicine demonstrate that ulcer recurrence may be reduced by surgery of the superficial veins.

The article by **Leal Monedero** and coworkers from Madrid, based on an extraordinary experience, directs our interest to the widely ignored fact that many recurrent varicose veins in the lower extremity are associated with reflux originating in the pelvic region. Embolization of refluxing intrapelvic veins, such as the ovarian veins, using coils and foam sclerotherapy, provide very good results, especially concerning the subjective symptoms of pelvic congestion syndrome. This procedure is usually combined with phlebectomy of the varicose veins on the leg.

At the present time the ablation of varicose veins by radiofrequency and by laser is a very fashionable treatment mode. In fact these methods are not so new, as shown to us by **Nicholas Fassiadis** and **Anthony Theodorides** in their historical review.

The last presentation comes from **Professor Claudio Allegra**'s team, describing the broad variety of entities attributable to “functional venous disease.” Following the CEAP classification, C may range between 0 and 4 (C0=no varicose veins, C1=teleangiectasias, reticular veins, C2=large varicose veins, C3=edema, C4=skin changes on the lower leg), the etiology E is primary, anatomy A is classified as zero, and Pathophysiology P as unclassified. About 30% of outpatients fall into this category. Compression therapy and surgery are not successful. Changes in lifestyle, physiotherapy, and venotonic drugs may be helpful.

Enjoy reading!

Hugo Partsch



Subdiaphragmatic venous insufficiency

Embolization treatment using mixed technique (coils and foam)

J. LEAL MONEDERO,
S. ZUBICOA EZPELETA,
M. GRIMBERG,
L. VERGARA CORREA,
J. A. JIMÉNEZ GUTIÉRREZ

*Ruber International Hospital
Madrid-Spain*

SUMMARY

Results are given for treatment administered to 2491 patients with recurrent varicose veins who were cared for in our unit from 1995 to 2003: 64.44% of the recurrences were bilateral and 35.56% unilateral. The average age was 53. These patients were divided into two groups according to the material used for embolization.

The first group of 1500 patients were treated from 1995 to 1999, and 58.3% underwent selective pelvic phlebography. Of these, 80.9% underwent embolization using coils, by which 82% of insufficient venous branches were occluded. Sometimes it was impossible to occlude leakage points in small cascade vessels associated with the hypogastric vein. Additionally embolization varicose vein surgery on the lower limbs was performed in 85.4%. Seventy-six percent of these patients reported an improvement of symptoms in the pelvis and lower limbs after 6 months. The other group of 991 patients were treated from 1999 to 2003. Of these, 55.76% underwent selective pelvic phlebography. From these, 86.59% underwent embolization using a "sandwich" method with the use of coils plus foam and, of these, 83.26% underwent varicose vein surgery on the lower limbs as a complementary treatment. After 6 months, 95.61% of patients reported an improvement in pain, pelvic heaviness, and lower-limb edema.

The aim of this study was to underline the importance of pelvic reflux in the development of recurrent varicose veins and demonstrate that embolization using a sandwich technique with the use of coils plus foam provides better results.

INTRODUCTION

Chronic venous insufficiency is one of the most common chronic diseases which affects mankind. Different studies claim that 25% to 33% of women and 16% to 20% of men suffer from the disease¹⁻³ and varicose veins recur in the lower limbs following surgery in 20% to 80% of cases. In our institution the recurrence rate is between 20% and 30%.⁴⁻⁶

Keywords:

Chronic venous insufficiency - Subdiaphragmatic venous insufficiency - Varicose vein recurrence
Leakage points - Embolization - Foam - Coils - Pelvic veins.

It is essential to treat the infradiaphragmatic venous system as one functional unit, and to understand the hemodynamic behaviour of the normal centripetal venous circulation, and of the centripetal and centrifugal flow patterns in chronic venous insufficiency.⁷

A pressure change in this system leads to the development of pathological collateral connections which act in certain cases as leakage points with retrograde venous flow from the pelvis to the lower sectors. This may be one of the causes which gives rise to the initial onset or recurrence of varicose veins or stasis in the lower limbs.⁸⁻¹³

The most common therapeutic treatments for the control of pelvic leakage points are either surgical ligation or endovascular occlusion (embolization). In our opinion the benefits of embolization make this the method of choice.¹⁴⁻²⁹ We have analyzed the treatment results for 2491 patients who attended our clinics and were treated for recurrence of varicose veins in the lower limbs by our unit from 1995 to 2003, and who were assumed to be suffering from pelvic disease based on clinical symptoms, physical examination, and vascular investigative tests. These patients were divided into two groups according to the material used to occlude the insufficient veins. Gianturco coils were used with the first group of patients, while a sandwich technique using coils plus 2% polidocanol or hydroxypolyethoxydodecane foam was used with the second group.

AIM

To present the results of an analysis performed on two patient groups with recurrent lower-limb varicose veins treated intraluminally by embolization: one group underwent occlusion by means of Gianturco coils, and the other group was treated using a "sandwich" method consisting of Gianturco coils and 2% polidocanol or hydroxypolyethoxydodecane foam (Figure 1).

MATERIAL AND METHODS

Study type: retrospective, selective, and descriptive, conducted from January 1995 to July 2003.

Target population: 2491 patients who attended the angiology and vascular surgery unit from 1995 to 2003 and were treated for recurrent lower-limb varicose veins for whom the clinical symptoms and results of physical examinations and vascular investigative tests suggested pelvic disease. Some of these were treated with embolization: in the first group, Gianturco coils were used for this purpose while the second group underwent a sandwich method using Gianturco coils plus 2% polidocanol or

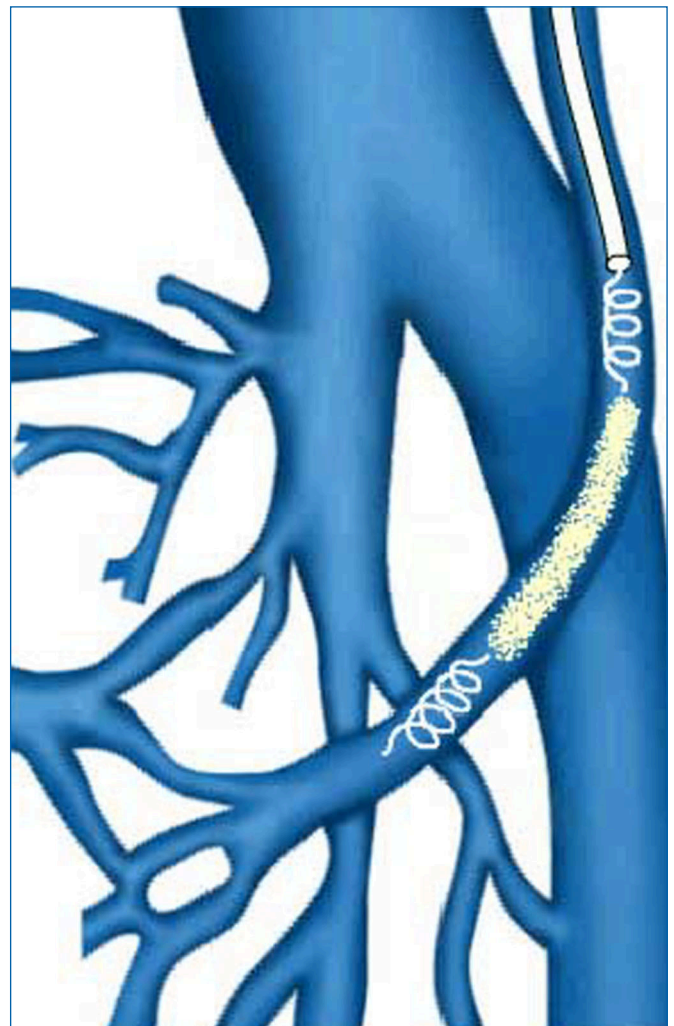


Figure 1. Mixed embolization technique (sandwich). Coils and foam applied alternatively.

hydroxypolyethoxydodecane foam. The recurrence affected both limbs in 64.44% of patients, while 35.56% of patients developed varicose veins on one limb. The average age was 53. The youngest patient was 25 and the oldest patient was 71.

Diagnosis, treatment, and follow-up protocol:

1. Clinical history. History and physical examination. Signs and symptoms of pelvic stasis were recorded in detail, particularly pelvic pain, dyspareunia, hemorrhoids, vulvar varices, varicose veins in the lumbar region, pelvic dilated veins, atypical varicose veins in the posteroexternal region of the thigh, etc.³⁰⁻³³
2. Noninvasive and invasive vascular laboratory examination by means of: photoplethysmography and colour ultrasound imaging of the lower limbs.^{18-34,35} When previous clinical symptoms and examinations were positive for pelvic disease, color ultrasound imaging of

this sector was requested (transparietal and transvaginal),³⁶⁻³⁸ For results to be positive, the following had to be present: gonadal axes measuring more than 8 mm in diameter, pelvic venous lakes, dilation of hypogastric axes, compression and malformation of the ilio caval sector. These signs were considered to be indications for selective pelvic phlebography.

3. Selective pelvic phlebography was used to evaluate the morphology of gonadal axes, the presence of pelvic venous lakes, hypogastric axes, compressions and malformations of the ilio caval sector, whether the direction of flow was centripetal or centrifugal from a hemodynamic view point, development of homo- and contralateral collateral circulation, and leakage points to anterior or posterior regions of the deep or superficial venous system of the lower limbs. The study was performed in an angiography room, with the patient standing on both feet on a tilting table angled at 60°. The examination began with cannulation (Seldinger's method) of a vein in the elbow flexure (*Figure 2*). This was generally the right basilic vein, though some were cannulated through the right femoral vein due to

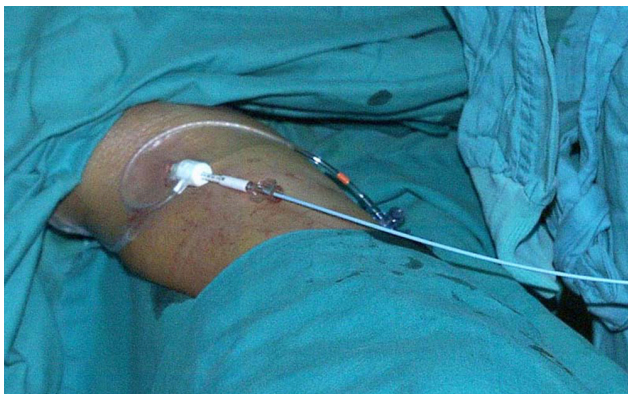

Figure 2. Guide and catheter in elbow flexure for study and embolizing treatment of pelvic escape points.

anatomical variations (*Figure 3*). Under fluoroscopic control, a 5F guide 55 cm long was inserted until reaching the vicinity of the right auricle or inferior cava. Afterwards, a 5F multipurpose catheter 125 cm in length was introduced and the cannula was inserted with the aid of a Terumo guide in the opposite direction to the venous flow, being careful not to damage any valves en route. The hypogastric and gonadal veins were selectively cannulated (*Figure 4*), a nonionic contrast medium was injected manually (average of 89 cc per examination), and the patient was asked to perform the Valsalva maneuver. Throughout the procedure, the patient was fitted with a bladder drain to

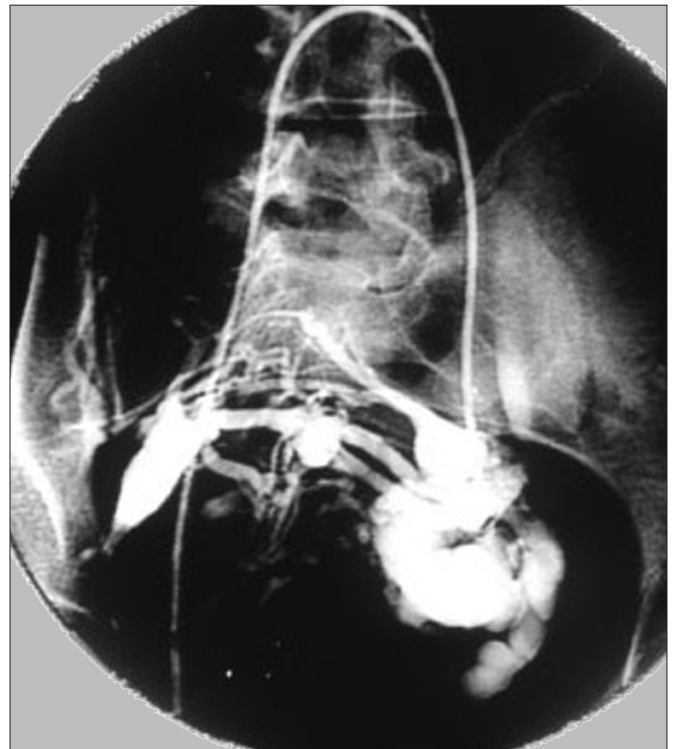


Figure 3. Catheterization through the right femoral vein. Venous lakes associated with the left gonadal vein.

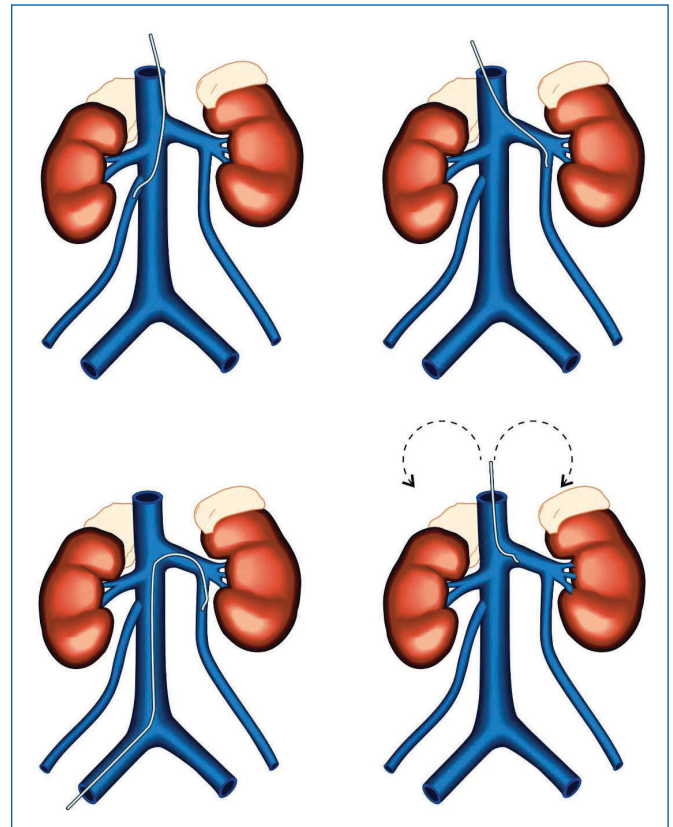


Figure 4. Drawings showing selective catheterization of the gonadal veins from the basilic and femoral vein.

prevent the bladder filling with the contrast medium and thus making imaging of the intrapelvic venous pedicles more difficult.

4. Embolization, if indicated as a complement to pelvic phlebography, was performed by selective occlusion of the affected venous axes. In the first group of patients, Gianturco coils measuring 5, 10, and 15 cm in length and 10 mm in diameter were used for occlusion. In the second group, embolization was performed via a sandwich method using alternatively coils with the same specifications as the previous ones plus 2% polidocanol or hydroxypolyethoxydodecane whipped as foam (Figures 5,6).

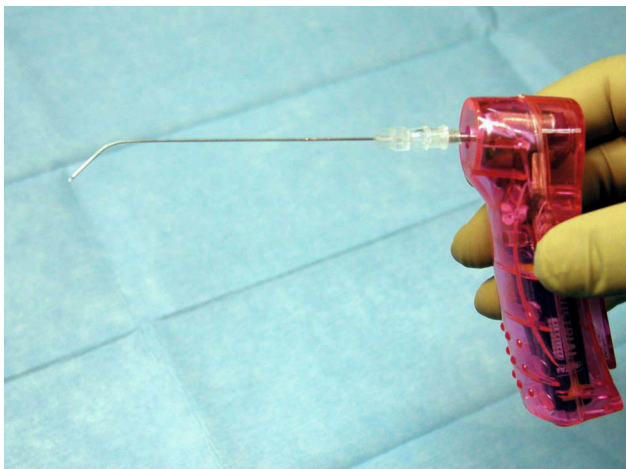


Figure 5. Mixing device with needle for foam production.

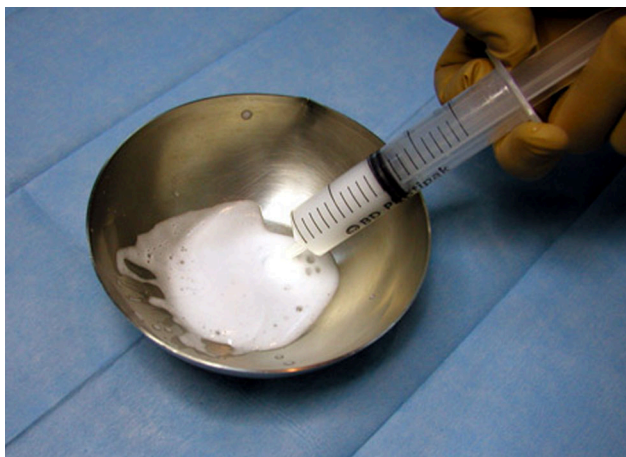

Figure 6. Hydroxypolyethoxydodecane foam being mixed and aspirated in a syringe for perfusion through the catheter.

5. Complementary treatment of recurrent varicose veins in the lower limbs by means of surgery and sclerotherapy.
6. Short-, medium-, and long-term follow-up included evaluation of the condition of the superficial and

venous system of the lower limbs and pelvis by means of a physical examination and color ultrasound after 30, 60, 90, 180, and 360 days and then each year

RESULTS (Table I)

Variables	First group		Second group	
Dates	1995 – 1999		1999 – 2003	
N° of patients	1500		991	
Selective pelvic Phlebography	875	58.3%	552	55.76%
Embolization	708	80.9%	478	86.59%
Material	Coils		Coils plus foam	
N° of coils	17		10.3	
Varicose vein surgery of lower limbs	605	85.4%	410	85.77%
Report of improvement after 6 months	460	76%	362	95.6%

Table I. Summary of results

The first group consisted of 1500 patients treated between January 1995 and April 1999. Eighty hundred and seventy-five (58.3%) patients underwent selective pelvic phlebography of which 708 (80.9%) were embolized. These patients were implanted with Gianturco coils of various thickness and gauges and insufficient venous branches were occluded in 82% of cases.

Sometimes it was impossible to occlude leakage points in small cascade vessels associated with the hypogastric vein. Varicose surgery of the lower limbs was performed complementary to embolization in 605 (85.4%) of patients.

On these patients' follow-up, it was found that after 6 months 76% of patients reported an improvement in the following symptoms: pain and heaviness of the pelvis and lower limbs, an improvement in sexual intercourse and menstrual periods. The relatively low success rate was attributed to the impossibility of approaching certain axes. Each patient required ±17 coils, which makes the procedure very costly compared with others.

The other group consisted of 991 patients (1982 limbs) treated between May 1999 and July 2003. Of these, 552 (1104 limbs) (990/552; 55.76%) underwent selective pelvic phlebography. Of these, 478 were embolized (956 limbs) (552/478; 86.59%) and, of these, 410 (478/410; 85.77%) underwent additional surgery of lower limbs varicose veins after embolization (Figure 7).

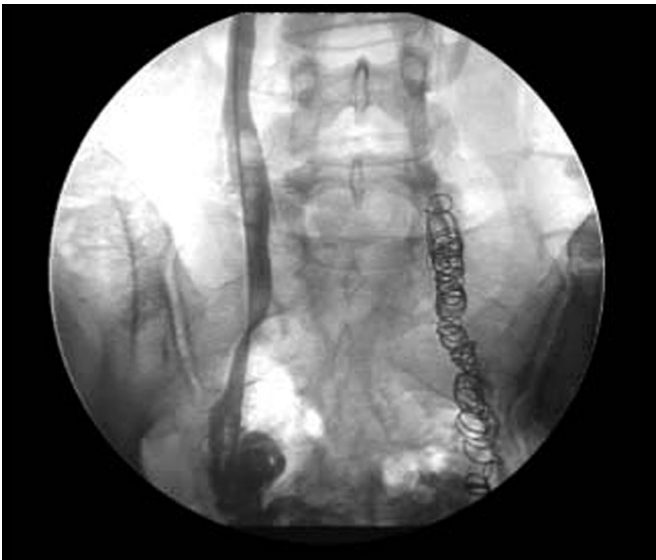

Figure 7. Distal catheterisation of the right gonadal vein during mixed embolization (sandwich technique). Coils visible in the path of the previously embolized left gonadal vein.

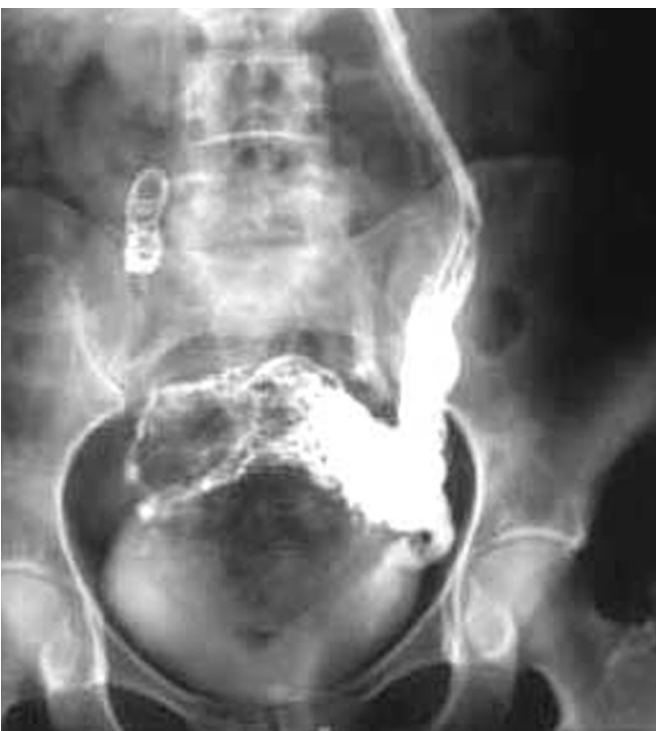

Figure 8. Severe periuterine pelvic varicose veins leading from the left gonadal vein. Coils in the path of the right gonadal vein. Mixed embolization. Sandwich technique.

When selective pelvic phlebography was performed in 552 patients, 310 patients (552/310, 56.16%) displayed 1 or 2 dilated avaluvar gonadal vessels (Figure 8) measuring more than 8 mm in diameter. 446 (552/446; 80.8%) patients presented significant venous lakes or pelvic varices, while 530 (552/530; 96.01%) patients displayed

leakage points from the hypogastric vein to the lower limbs. Escape routes showed as follows: to the great saphenous vein or its tributaries in 66 patients (66/530; 12.45%); to the deep venous system, deep femoral veins in 84 patients (84/530; 15.85%) and to the residual embryonic sciatic veins (Figure 9) in 38 patients (38/530; 7.17%). A high number of patients, 342 (342/530; 64.53%) displayed mixed reflux in both superficial and deep venous systems (Figure 10).

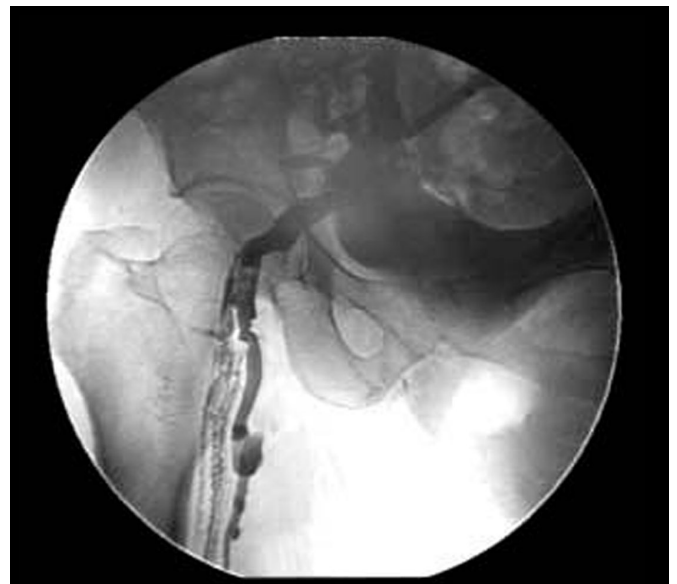

Figure 9. Pelvic escape points from the right gluteal vein to the sciatic veins.

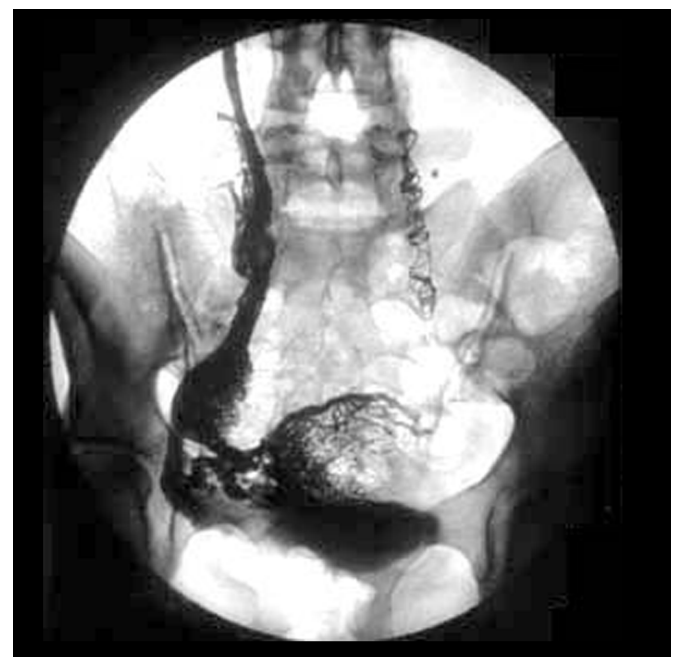

Figure 10. Periuterine pelvic varicose veins associated with the right gonadal vein. Coils in the path of the left gonadal vein. Mixed embolization. Sandwich technique.

Of the 552 patients who underwent selective pelvic phlebography, 478 were embolized (86.59%) with the following notes: 34 patients (7.11%) had previously undergone a hysterectomy which meant that the gonadal veins were not evaluated, embolization of the right gonadal vein was not completed in 2 (0.42%) patients due to technical problems (cannulation difficulty) and the normal gonadal areas displayed a reflux route only to the hypogastric area in one patient (0.21%). For the remaining 438 patients (91.63%) embolization was bilateral, 810 gonadal axes were occluded, and there were 872 leakage points to the lower limbs. The sealed vessels, in order of frequency, were the left gonadal vein and the pudendal hypogastric branches, the inferior gluteus, and the obturator vein.

The coils most commonly used in both axes were 5, 10, and 15 cm, placed beginning with the longest. An average of 10.3 coils were used per patient. Procedure duration was 30 to 40 minutes.

Seventy-four (13.41%) patients were excluded, 6 (1.09%) due to iliac postthrombotic syndrome, 22 (3.99%) due to pelvic venous compression syndrome; 10 (1.81%) due to venous malformations (agenesis of the vena cava, double inferior vena cava etc.) 36 (6.52%) due to the impossibility of identifying veins for embolization.

Complications arising during the procedure were never significant. Some were inherent to the percutaneous method itself: (1.45%) 8 patients showed a slight hematoma at the puncture site, (1.09%) 6 patients displayed minor mechanical phlebitis symptoms, and (0.54%) 3 patients extravasation of the contrast medium. Since the embolizing treatment is designed to achieve controlled thrombosis of the pelvic venous axes, symptoms noted following the technique were those typical of venous thrombosis. We described these as postembolization syndrome in previous studies, and the symptoms and signs disappeared within 1 week of treatment.

This group displayed the following postembolization syndrome symptoms: 258 (46.74%) radiating pain, particularly in the gluteal region, and sciatic-like pain in the posterior surface of the lower limbs radiating in fewer cases to the hypogastric and lumbar region: 122 (22.1%) general malaise with headache; 49 (8.88%) a fever of $\sim 38^{\circ}\text{C}$ - and 23 (4.17%) superficial phlebitis.

The follow-up data refer to the 410 patients who underwent embolization and then varicose vein surgery of the lower limbs after the procedure. A 6-month follow-up revealed that 95.61% (410/392 of patients) reported an improvement in pain, pelvic heaviness and lower-limb edema.

CONCLUSIONS

Our results suggest that the subdiaphragmatic venous system made up of the pelvic and lower-limb veins should be treated as one functional unit. This approach helps to explain the appearance of varicose veins, and stasis and recurrence following surgery. Many normal communication routes are present between the venous systems which make up the subdiaphragmatic venous system, but pathological communications may appear in response to pressure changes which determine changes in blood flow direction and magnitude.

Selective occlusion of insufficient veins with embolization by means of coils plus foam achieved very satisfactory results for the patients in terms of alleviation of clinical symptoms, reduction of pain in the lower limbs and pelvis, edema, pelvic heaviness, and complaints during sexual intercourse. We believe that in cases of pelvic varicose veins with centrifugal collateral circulation without any other morphological changes, embolization using Gianturco coils and 2% polidocanol or hydroxypolyethoxydodecane (foam) is very effective because it allows closure of the small vessels which act as leakage points from the pelvis to the lower limbs.

This method allows us to reach more distal sectors where surgical access is very difficult and may be associated with severe complications.

Embolization using Gianturco coils and 2% polidocanol or hydroxypolyethoxydodecane (foam) has allowed more conclusive treatment and a reduction in the number of recurrences.

In our experience, the embolization technique is simple, can be performed on an outpatient basis, and is well tolerated in most patients. We did not encounter severe complications related to this management. Significant costs currently incur due to the number of coils used.

Two percent polidocanol or hydroxypolyethoxydodecane foam obtained by whipping the sclerosing substance increases its volume up to 300%. Its use allows the number of coils to be reduced and consequently the cost of the procedure.

Embolization is a minimally invasive method and did not lead to significant complications in our hands.

Our results obtained following clinical examination and venous laboratory examination fully support the existence of a functional infradiaphragmatic unit.

We treated the centrifugal leakage points because other collateral connections may supplement the distal to proximal circulation.

We achieved better hemodynamic and clinical results

through embolization via occlusion of cascade leakage points using a mixed method.

In hemodynamic terms, the subdiaphragmatic venous system behaves as one functional unit. It includes different areas which intercommunicate in the form of a network, and the connections may be physiological or pathological depending on flow direction and magnitude (centrifugal or centripetal) in response to changes in venous pressure or anatomical dysfunction.



Address for correspondence

Angiology and Vascular Surgery Unit
Hospital Ruber Internacional

C/La Masó 38 - Mirasierra
28034 Madrid - Spain

Phone: + 34 91 3875157

Fax: + 34 91 3875158

E-mail:

angiovascularlyz@ruberinternacional.es

REFERENCES

1. **Castro Silva M.** Chronic venous insufficiency of the lower limbs and its socio-economic significance. *Phlebologie*. 1995;Suppl 1:23-24.
2. **Abenham L, Kurz X.** the Veines Study (Venous Insufficiency Epidemiologic and Economic Study). An international cohort study on Chronic Venous Disorders of the legs. *Angiology*. 1997;48:59-65.
3. **Wienert V.** The epidemiology and socio-economics of venous disorders in Germany. *Phlebologie*. 1993;46:225-233.
4. **Perrin M, Guex JJ, Ruckley CV, De Palma RG, et al.** Recurrent varices after surgery (REVAS), a consensus document. *REVAS Cardiovas Surg*. 2000; 8:233-245.
5. **Perrin M, Bayon JM, Hiltbrand B, Nicolini P.** Deep venous insufficiency and recurrent varicose vein after surgery of superficial venous insufficiency. *J Mal Vasc*. 1997;22:343-347.
6. **Perrin M, Gobin JP, Nicolini P.** Recurrent varicose veins in the groin after surgery. *J Mal Vasc*. 1997;22:303-312.
7. **Leal Monedero J, Zubicoa Ezpeleta S, et al.** Insuficiencia venosa crónica: definición, fisiopatología y clasificación. *Phlebology Digest*. 1996;1:4-8.
8. **Perrin M.** The contribution of Doppler echography in the diagnosis and therapeutic plan in chronic venous insufficiency surgery.
9. **Norgren L.** Various aspects of phlebology in Sweden. *Phlebologie*. 1997;45:444-446.
10. **Hobbs JT.** Pelvic congestion syndrome. *Br J Hosp Med*. 1990;43:200-206.
11. **Gottlob R, May R.** *Venous Valves*. Vienna: Springer-Verlag; 1986:159-174.
12. **Le Page PA, Villavicencio JL, Gómez ER, Sheridan MN, Rich NM.** The valvular anatomy of the iliac venous system and its clinical implications. *J Vasc Surg*. 1991;14:678-683.
13. **Del Portillo L.** Epidemiología y fisiopatología del varicocele. *III Congreso nacional Andrología*. Asesa, Zaragoza, España, 1987;3-12.
14. **Leal Monedero J, Zubicoa Ezpeleta S, et al.** *Insuficiencia venosa crónica de la pelvis y de los miembros inferiores*. Madrid: Mosby/Doyma Libros; 1997:61-74.
15. **Tulloch WS.** Consideration of sterility. Subfertility in the male. *Edinburgh Med J*. 1952;59:29-36.
16. **Amelar RD, Dubin L.** Therapeutic implications of left, right and bilateral varicocele. *Urology*. 1987;30:53-59.
17. **Leal Monedero J, Zubicoa Ezpeleta S, et al.** Alternativas terapéuticas del varicocele. Paper presented at VII Congreso de Andrología, Bilbao, España, 1995.
18. **Leal Monedero J, Zubicoa Ezpeleta S, et al.** La exploración no invasiva en la insuficiencia venosa crónica. In Leal J, ed. *Insuficiencia venosa crónica de la pelvis y de los miembros inferiores*. Madrid: Mosby/Doyma Libros; 1997:61-74.
19. **Shafik A, Mohi-el-Din M.** Pelvic organ venous communications. Anatomy and role in urogenital diseases; a new technique of cystovaginohysterography. *Am J Obstet Gynecol*. 1988;159:347-351.
20. **Wheatley JK, Bergman WA, Green B, Walther M.** Transvenous occlusion of clinical and subclinical varicoceles. *Fertility Sterility*. 1991;37:362-365.
21. **Herman RJ, Neiman HL, Yao JST.** Descending venography: a method of evaluating lower extremity venous valvular function. *Radiology*. 1980;137:63.
22. **Kistner RL, Ferris EB, Randhawa G.** A method of performing descending venography. *J Vasc Surg*. 1986;4:464.
23. **Leal Monedero J, Zubicoa Ezpeleta S, et al.** Métodos invasivos en el diagnóstico de la insuficiencia venosa crónica: radiología pélvica y de miembros inferiores. In: Leal J, ed. *Insuficiencia venosa crónica de la pelvis y de los miembros inferiores*. Madrid: Mosby/Doyma Libros; 1997:75-88.
24. **Lechter A, Alvarez A.** Pelvic varices and gonadal veins. In Negus D, Jantet G, eds. *Phlebology*. 1985. London: John Libbey; 1986:225-228.
25. **Langeron P.** Stase veineuse pelvienne, varicoceles pelviens: problèmes hémodynamiques, pathogéniques et cliniques. *Phlébologie*. 2000;53:155-160.
26. **Lechter A.** Pelvic varices: Treatment. *J Cardiovasc Surg*. 1985;26:111.
27. **Leal Monedero J, Zubicoa Ezpeleta S, et al.** Embolización en el varicocele pélvico. In Leal J, ed. *Insuficiencia venosa crónica de la pelvis y de los miembros inferiores*. Madrid: Mosby/Doyma Libros; 1997:115-128.
28. **Boomsma JHB, Potocky V, Kievit CEL, Verhulsdonck JCJ.** Phlebography and embolization in women with pelvic vein insufficiency. *Medicamundi*. 1998;42:22-29.
29. **Leal Monedero J.** La pathologie veineuse pelvienne. Traitement embolisant. *Phlébologie*. 1999;52:299-309.
30. **Hargrave TB, Liakatas J.** Physical examination for varicocele. *Br J Urol*. 1991;67:28.
31. **Bassi G.** *Les varices des membres inférieurs*. 10 ed. Edition Doin; 1967.
32. **Lechter A, López G, Martínez C, Camacho J.** Anatomy of the gonadal veins: a reappraisal. *Surgery*. 1991;109:735-739.
33. **Beebe HG, Bergan JJ, Bergqvist D, et al.** Classification and grading of chronic venous disease in the lower limbs. A consensus statement. *Eur J Vasc Endovasc Surg*. 1996;12:487-491; discussion 491-492.
34. **Nicolaides AN, Miles C.** Photoplethysmography in the assessment of venous insufficiency. *J Vasc Surg*. 1987;5:405-412.
35. **Cavezzi A.** Long saphenous vein and perforating veins haemodynamics: new echo colour Doppler patterns *Abstracts of XIII World Congress of Phlebology*. Sydney 1998:109.
36. **Perrin M.** The contribution of Doppler echography in the diagnosis and therapeutic plan in chronic venous insufficiency surgery. *Phlebologie*. 1993;46:655-662.
37. **Selfa S, Diago T, Ricart M, Chulía R, Martín F.** Insuficiencia venosa crónica primaria de los miembros inferiores. Valoración prequirúrgica con Ecodoppler color. *Radiología*. 2000;42:343-348.
38. **Nicolaides AN, Zukowski A, Lewis R, Kyprianou P, Malouf GM.** Venous pressure measurements in venous problems. In: Bergan JJ, Yao JST, eds. *Surgery of the Veins*. Orlando, FL: Grune & Stratton; 1985:111-118.



Rationale for surgery in the treatment of venous ulcer of the leg

Michel PERRIN

Chassieu, France

SUMMARY

Venous ulcer of the leg is the most severe clinical presentation of chronic venous insufficiency. The aim of this article is to review the disease in terms of evidence-based medicine in order to determine the potential of surgery as a component of efficient treatment.

OVERVIEW

In leg ulcer, the venous etiology is more frequent than an arterial, combined (arterial and venous) or nonvascular etiology. A venous etiology accounts for 70% to 80% of cases, depending on whether or not combined ulcers are included.

A venous ulcer (VU) of the leg may be defined as a full thickness defect in the skin most frequently at the ankle that fails to heal spontaneously sustained by chronic venous disease.

VU is the most severe complication of chronic venous disease (CVD). It is therefore not surprising that the CEAP classification system allocates the highest clinical classes (C5-C6). Similarly, in the American Venous Forum's¹ clinical severity score, ulcer contributes almost one third of the severity points (9/30). The prevalence of active venous ulcer is of the order of 0.2% to 0.3% in the adult population of Western countries.² However, if subjects whose ulcers have healed are also taken into account, the C5-C6 prevalence is between 1% and 1.5%. The prevalence is two- to threefold higher in women than in men, and increases with age.

The incidence is less well documented, but is reported to be of the order 0.035% per year in subjects aged over 45 years.

Venous ulcer gives rise to substantial health care expenditures.

PATHOPHYSIOLOGICAL REVIEW

A constant finding in patients presenting with chronic venous insufficiency (CVI) and, particularly, the severe form, VU, consists of elevated venous

pressure in ambulatory settings. The increase in ambulatory venous pressure may be related to two pathophysiological factors: reflux and obstruction, or a combination of those two factors.

The pathophysiological abnormalities may affect one of the three venous systems (superficial, deep, and perforating veins) in isolation or a combination of those systems. The distribution of the various presentations is shown in *Table I*. It can be seen that, in about two thirds of cases, reflux affects several systems. The last important factor to be determined is the etiology. Doppler ultrasound investigation of leg ulcers, if VU only are considered, shows that, in 40% to 50% of cases, the primary etiology is located in the superficial venous network (with or without the perforators), ie, primary varices.⁸ It is thus undeniable that the postthrombotic syndrome (PTS) constitutes a much less frequent etiology than previously believed.

In combined ulcer, the tissue ischemia resulting from arterial disease acts jointly with the permanently increased orthostatic venous pressure.

Precise determination of the anatomical lesions and pathophysiological disorders is essential since the therapeutic indications and, more particularly, the surgical options are based on those data.

CLINICAL PRESENTATION

The diagnosis of ulcer is essentially clinical, but clinical feature does not always enable determination of the etiology or, most importantly, the anatomical lesions and pathophysiological disorders. The latter are determined by investigations, which are scheduled in relation to potential surgical treatment (*Figure 1*).

TREATMENT

Treatment has a dual objective: obtaining ulcer healing, then preventing recurrence. Accordingly, the permanent increase in venous pressure must be reduced or eliminated. In the event of concomitant arterial disease, it is also necessary to increase the arterial tissue perfusion pressure.

The surgical methods may be classified as a function of their aims.

Among the methods used to promote VU healing are excision of the ulcer and its inflammatory base in the hypodermis ie, lipodermatosclerosis, and its variation, such as shave therapy (*Figure 2 a, b, c*).

The methods used to prevent VU recurrence are classified in terms of the venous system to be treated: excision of the

	S	P	D	S+P	S+D	P+D	S+P+D	Reflux-free
Hanrahan (3) 95 legs	16 (17%)	8 (8%)	2 (2%)	18 (19%)	11 (12%)	4 (4%)	30 (3%)	6 (6%)
Labropoulos (4) 34 legs	8 (24%)	-	2 (6%)	2 (6%)	9 (26%)	1 (3%)	12 (35%)	
Labropoulos (5) 112 legs	26 (23%)	3 (3%)	7 (6%)	23 (21%)	13 (12%)	5 (4%)	31 (28%)	4 (4%)
Labropoulos (5) 54 legs	10 (18.5%)	-	3 (5.6%)	12 (22.2%)	10 (18.5%)	-	19 (35.2%)	
Scriven (7) 95 legs	48 (50.5%)	2 (2.1%)	11 (11.6%)	4 (2.2%)	28 (29.5%)	2 (2.1%)	-	
Total legs %	108 28.4%	13 3.4%	25 6.6%	59 15.5%	71 18.7%	12 3.2%	94 24.2%	

Table I. Reflux distribution in the three venous systems of the legs in patients presenting with venous ulcer. Superficial venous insufficiency (SVI) was identified in 86.8% of cases, deep venous insufficiency (DVI) in 52.7% and perforator insufficiency (PI) in 46.3%. SVI and DVI were concomitantly present in 43% of cases, SVI and PI in 39.7% of cases and DVI and PI in 27.4% of cases.

Abbreviations: S: superficial, D: deep, P: perforator

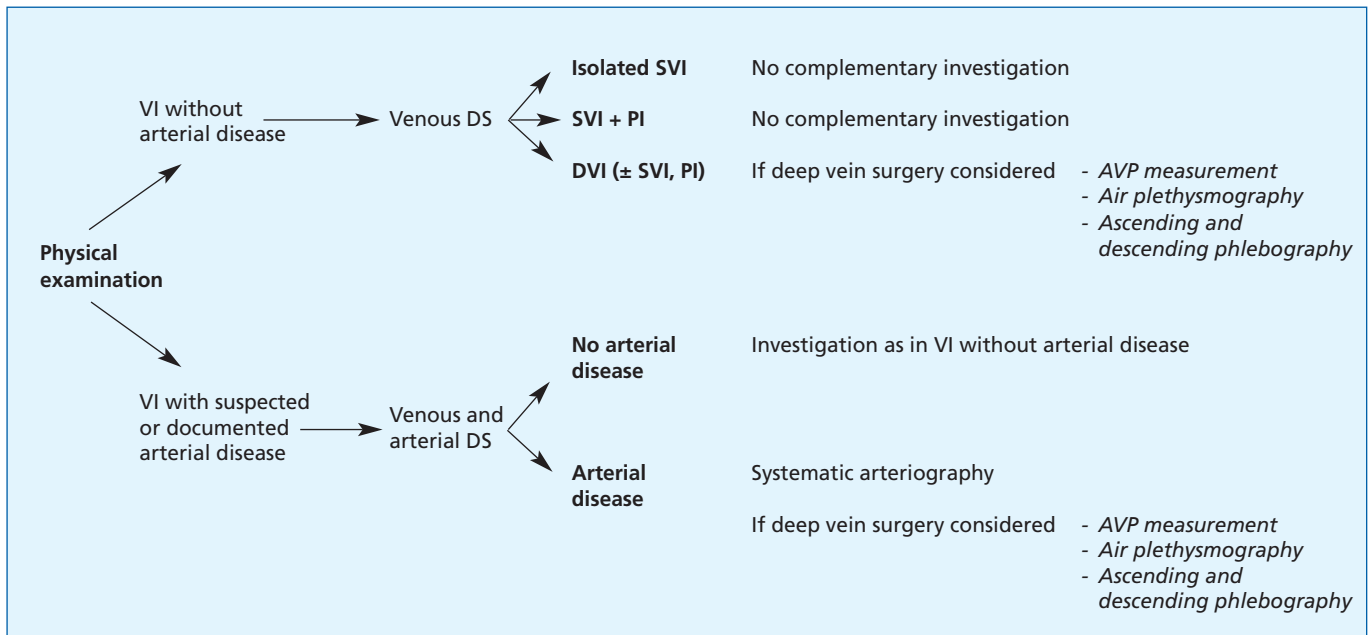


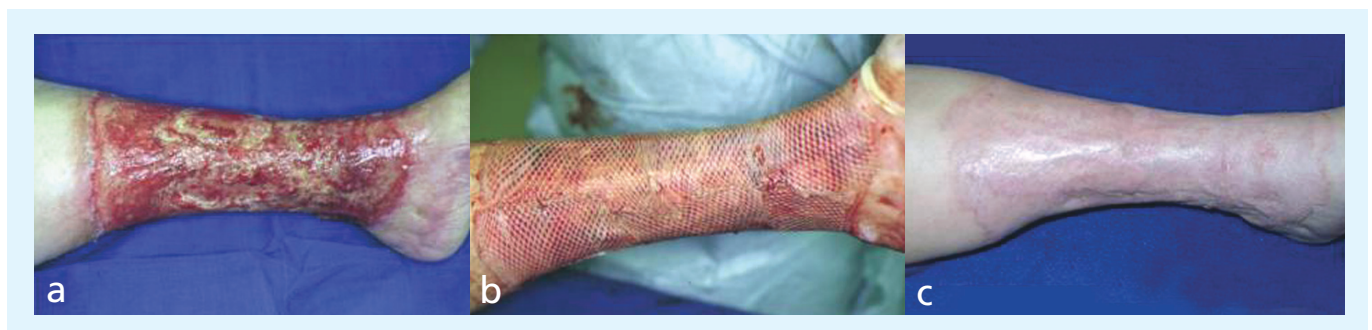Figure 1. Investigation algorithm.

Abbreviations: DS: Duplex scan, VI: venous insufficiency, SVI: superficial venous insufficiency, PI: perforator insufficiency, DVI: deep venous insufficiency, AVP: ambulatory venous pressure.

pathological superficial venous network, ligation of incompetent perforators, and restorative surgery on the deep vein network with the aim of alleviating obstruction and/or reflux. In addition to those direct methods, German

authors recommend fasciotomy.

In combined ulcer, open-wound arterial reconstruction and/or transluminal procedures may be employed.



Figures 2a-c: Shave therapy - Figure 2a: Circular chronic venous ulcer of the lower half of the leg - Figure 2b: Physical feature after shave therapy procedure - Figure 2c: Healed ulcer: Excision of lipodermatosclerotic tissue has enhanced the "champagne bottle" aspect.

The results of surgery

Ulcer healing

A controlled study has shown that surgical treatment of varices associated with compression did not procure any advantage over compression alone with respect to ulcer healing.⁹ In recalcitrant ulcers, resection of the inflammatory base in the hypodermis, and skin grafting enabled ulcer healing on 60% to 80% of cases.

Ulcer recurrence prevention. Surgical treatment of superficial venous insufficiency was compared with compression in a controlled study¹⁰ with 1 year of follow-up. The benefit in terms of absence of ulcer recurrence was only significant ($P=0.008$) in the absence of concomitant deep venous insufficiency (DVI).

It is difficult to assess the results of perforator surgery since analysis of various series reported shows that the procedure was almost always associated with other surgical procedures.

At 2 years' follow-up surgical treatment of deep vein obstructive syndromes had procured 62% recurrence-free ulcer healing in patients who had not experienced healing or presented with recurrence on conservative treatment.¹¹ Surgical treatment of deep vein reflux is credited with

various rates of absence of ulcer recurrence at 5 years' follow-up, depending on the etiology. In primary reflux, the rate is about 70% while in PTS the rate is between 40% and 70%.¹²

In combined ulcer the success of arterial surgery is the decisive factor. In Treiman's series,¹³ the presence of DVI and, particularly, PTS constituted a negative predictive factor.

THE INDICATIONS FOR SURGERY (Figure 3)

It must be borne in mind that concomitant diseases must always be treated, particularly diabetes mellitus and obesity. When the physical examination shows restricted mobility of the ankle, physiotherapy (active and passive joint mobilization) is to be prescribed, as soon as the ulcer is no longer painful or when it has healed.

The surgical indications may be summarized as follows: in venous ulcer, surgery is exceptionally justified in order to obtain ulcer healing. Surgery to eradicate primary varices is indicated in the absence of deep venous insufficiency in order to prevent ulcer recurrence. Conversely, the management of perforator disease is more problematic, but a degree of consensus exists with regard to endoscopic ligation of large-caliber perforators of the legs. The

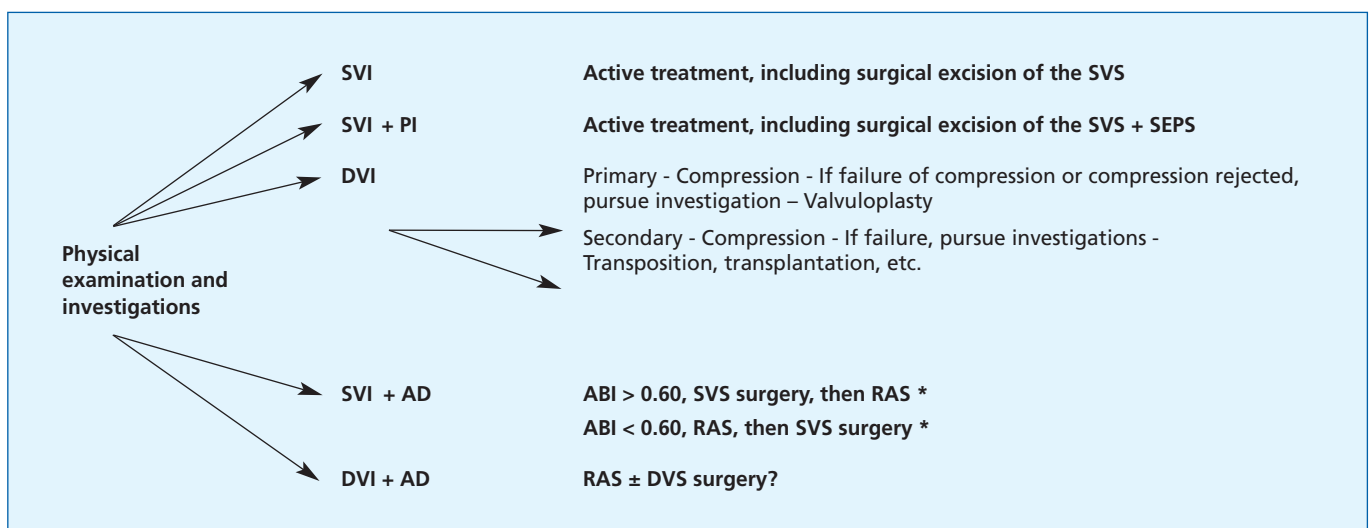


Figure 3. Surgical treatment algorithm for the prevention of ulcer recurrence.

Abbreviations: AD: arterial disease, RAS: restorative arterial surgery, SEPS: subfascial endoscopic perforator surgery, DS: Duplex scan, DVS: deep venous system PI: perforator insufficiency, VI: venous insufficiency, ABI: ankle/brachial index, SVI: superficial venous insufficiency, SVS: superficial venous system

* according to Treiman (13)

indications for reconstructive surgery of the deep vein network remain controversial. Surgery may be envisaged following failure of conservative treatment.

In combined ulcers, reconstructive arterial surgery is necessary, when potentially feasible, in order to obtain ulcer healing and to prevent recurrence.

Acknowledgment: thanks to HJ Hermanns MD for providing the figures on shave therapy




Address for correspondence

Michel Perrin, MD, Vascular Surgery
26 Chemin de Décines
69680 Chassieu, France
Tel: +33 472057266
Fax: +33 472057274
e-mail: m.perrin.chir.vasc@wanadoo.fr

REFERENCES

- Rutherford RB, Padberg FT, Comerota AJ, Kistner RL, Meissner MH, Moneta GL.** Venous severity scoring: an adjunct to venous outcome assessment. *J Vasc Surg.* 2000; 31:1307-1312.
- Fowkes FGR.** Epidemiology of venous ulcer. *Phlébologie.* 1999; 52:377-382.
- Hanrahan LM, Araki, CT, Rodriguez AA, Kechejian JK, LaMorte WW, Menzoian JO.** Distribution of valvular incompetence in patients with venous ulceration. *J Vasc Surg.* 1991;13:805-12.
- Labropoulos N, Giannoukas AD, Nicolaides AN, Ramaswani G, Leon M, Burke P.** New insights into the pathophysiologic condition of venous ulceration with color-flow duplex imaging: implications for treatment. *J Vasc Surg.* 1995;22:45-50.
- Labropoulos N, Leon M, Geroulakos G, Volteas N, Chan P, Nicolaides AN.** Venous hemodynamic abnormalities in patients with leg ulceration. *Am J Surg.* 1995;169:572-574.
- Labropoulos N.** Clinical correlation to various patterns of reflux. *Vasc Surg.* 1997;31:242-248.
- Scriven JM, Harsthorne T, Bell PR, Naylor AR, London NJ.** Single-visit venous ulcer assessment clinic: the first year. *Br J Surg.* 1997;84:334-336.
- Grabs AJ, Wakely MC, Nyamekye I, Ghauri ASK, Poskitt KR.** Colour duplex ultrasonography in the rational management of chronic venous ulcers. *B J Surg.* 1996;83:1830-1832.
- Guest M, Smith JJ, Tripuraneni G, Howard A, et al.** Randomized clinical trial of varicose vein surgery with compression versus compression alone for the treatment of venous ulceration. *Phlebology.* 2003;18:130-136.
- Barwell J, Davies C, Tailor M, Deacon J, Usher DC, Mitchell JJ et al.** The ESCHAR venous ulcer study: a randomised controlled trial assessing venous surgery in 500 leg ulcers (abstract) *B J Surg.* 2003;90:497.
- Raju S, Owen Jr S, Neglen P.** The clinical impact of iliac venous stents in the management of chronic venous insufficiency. *J Vasc Surg.* 2002;38:8-15.
- Perrin M.** Reconstructive surgery for deep venous reflux. *Cardiovasc Surg.* 2000;8:246-255.
- Treiman GS, Copland S, McNamara RM, Yellin AE, Schneider RL, Treiman RL.** Factors influence ulcer healing in patients with combined arterial and venous insufficiency. *J Vasc Surg.* 2001;33:1158-1164.



Daflon 500 mg in the management of acute and recurrent hemorrhoidal disease

GOOD PRACTICES IN HEMORRHOID TREATMENT

Hemorrhoidal illness represents one of the most common medical conditions in man. The most recent statistics indicate a prevalence of about 25% in the adult population, and higher than 50% for those older than 50. However, the prevalence and incidence are most probably higher, considering the fact that, in certain patients, the illness begins in an asymptomatic fashion.

The origin of hemorrhoidal disease can be either mechanical or vascular (hemodynamic):

According to mechanical theory, the supportive structure of the hemorrhoidal plexus undergoes spontaneous involution which includes excessive laxity and leads to displacement of the internal hemorrhoids. Acute intrarectal or abdominal pressure are worsening factors.

Vascular factors are increasingly recognized as playing an important role in the development of hemorrhoidal disease through alterations of the vascular plexuses and dysfunction of the arteriovenous shunts, the effect of which are amplified, as above, by increased abdominal pressure.

Hemorrhoidal disease is often associated with inflammation. Therefore, the treatment of hemorrhoids has to achieve three objectives: to eliminate mechanical and local triggering factors, to reduce the inflammation, always present in acute manifestations and to reestablish optimal hemodynamic and microcirculatory conditions.

Eliminate mechanical and local triggering factors

To achieve the first objective it is necessary to observe certain lifestyle and dietary measures, which represent the basis of the treatment.

The dietary regime, above all, must include fiber-rich food and abundant liquids in order to ensure the regularity of the alvus and to maintain a soft consistency of the stools.

Mechanical laxatives, such as vaseline or liquid paraffin, can be utilized to this end, as well as avoiding consumption of stimulating drinks (tea, coffee), alcohol, and spices. Great care should be paid to personal hygiene and daily habits, avoiding smoking, a sedentary lifestyle, and a sitting position for prolonged periods of time.

There is doubt about the role of local treatment, which can be carried out through agents employed in various combinations: local anesthetics, anti-inflammatory drugs, lubricating substances, and substances with local venous tropism.

All these medicines have a favorable effect on clinical phenomenology, even if, up to now, studies have called into doubt their real effectiveness.

Reduce the inflammation

The second objective to achieve in the treatment of hemorrhoidal attacks is prevention of the inflammation. It has been demonstrated that metabolites of arachidonic acid (in particular prostaglandin and leukotrienes) levels are higher in the acute phase.¹

Therefore, it is necessary to administer, in acute hemorrhoidal disease, substances able to antagonize the actions of the chemical mediators of the inflammation, including the kinins and the lymphokines, and to inhibit enzymatic activation of arachidonic acid.

Reestablish optimal hemodynamic and microcirculatory conditions

Hemodynamic and microcirculatory disorders lead to inflammation of the tissues and decrease of venous tone. The main inflammatory mediators involved are PGE-2 and TXA-2, whose levels are higher during attacks. The clinical manifestations of these disorders are pain and bleeding, which are very disabling in the patient's daily life. The third objective consists therefore in opposing the PGE-2 and TXA-2 synthesis.

Daflon 500 mg IN THE TREATMENT OF HEMORRHOIDS

Daflon 500 mg seems to offer a comprehensive pharmacological answer to all the needs of hemorrhoid treatment. Firstly, the flavonoids, including Daflon 500 mg, have been demonstrated to restrain lysosome enzymes and interfere with enzymes involved in the flow of arachidonic acid, which causes inflammation.²

Daflon 500 mg has also demonstrated an antioxidant activity, which allows it to oppose free radicals,³ as well as a decreasing effect on the synthesis of PGE-2 and TXA-2 by the macrophage.⁴

All these effects result in a reduction of the pericapillar permeability,⁵ and an increase in the capillary resistance to blood extravasation in the interstitium.

The hemodynamic effect manifests itself through an increase in venous tone demonstrated both experimentally⁶ and clinically.⁷

Regarding clinical benefits, two recent studies have demonstrated the outstanding efficacy of Daflon 500 mg, both in acute and recurrent attacks.

Daflon 500 mg provides complete efficacy in acute attacks

All symptoms are significantly improved from the second day of treatment.

A double-blind, placebo-controlled study was performed in 100 patients suffering from hemorrhoidal disease confirmed by proctoscopy, presenting an acute hemorrhoidal attack of up to 3 days, which had not been treated. The treatment lasted 7 days at the dosage of **6 tablets for 4 days and 4 tablets for 3 days.**

A clinical examination was performed at D0 and D7, with an assessment of the symptoms and their improvement using a 4-point scale.

The results of this study demonstrated an overall improvement of the symptoms significantly higher in patients treated with Daflon 500 mg in comparison with the controls ($P<0.001$), which was already evident on the second day of treatment, but more marked at the end. The scores used to evaluate bleeding, pain, and itching resulted in a reduction in both groups on D7, but to a notably greater degree in patients treated with Daflon 500 mg ($P<0.001$); analogous results were observed regarding tenesmus, with a less relevant resolution percentage (Figure 1) and the objective clinical signs (proctitis). Also,

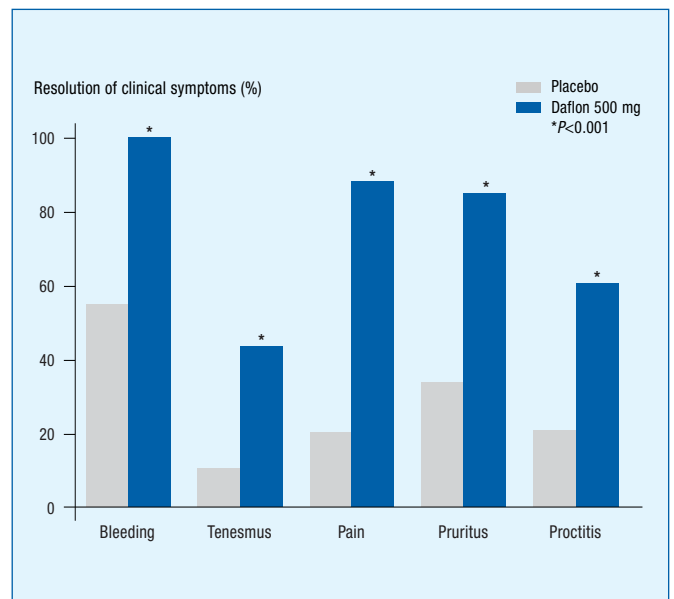


Figure 1. Daflon 500 mg improves all symptoms related to hemorrhoid attacks.

the duration and intensity of the present crisis, compared with previously, were much more reduced in patients treated with flavonoids compared with the placebo group ($P<0.001$) (Figure 2).

Patients themselves experienced a significant improvement from the second day of treatment with Daflon 500 mg. In Prof Misra's study, patients evaluated the efficacy of

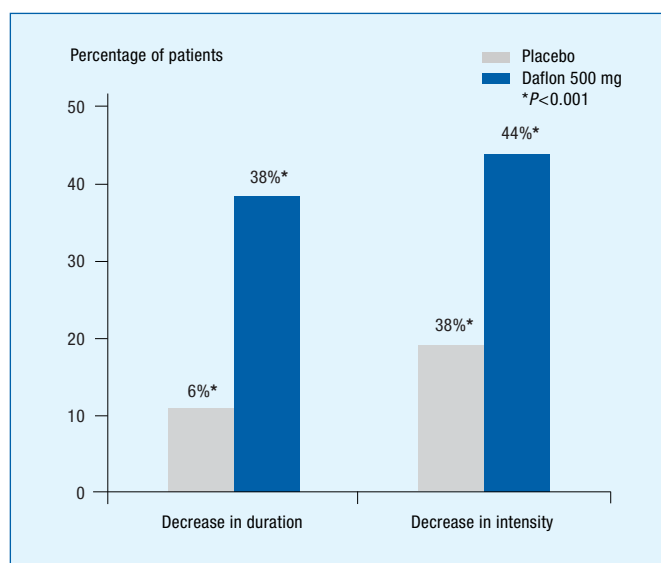


Figure 2. Daflon 500 mg significantly reduces the duration and intensity of attacks compared with previous attacks.

Daflon 500 mg on their quality of life during acute attacks, using a self-evaluation scale.

They therefore evaluated the drug's efficacy on different signs and symptoms occurring during acute attacks such as pain, pruritus, proctitis, and bleeding, as well as general improvement.

Indeed, 100 patients took either Daflon 500 mg during their acute attacks at the dosage of 6 tablets per day for the first 4 days, followed by 4 tablets per day for the following 3 days, or a placebo.⁸

As shown in Figure 3, Daflon 500 mg showed outstanding rapidity of action, as almost half of the patients noticed a

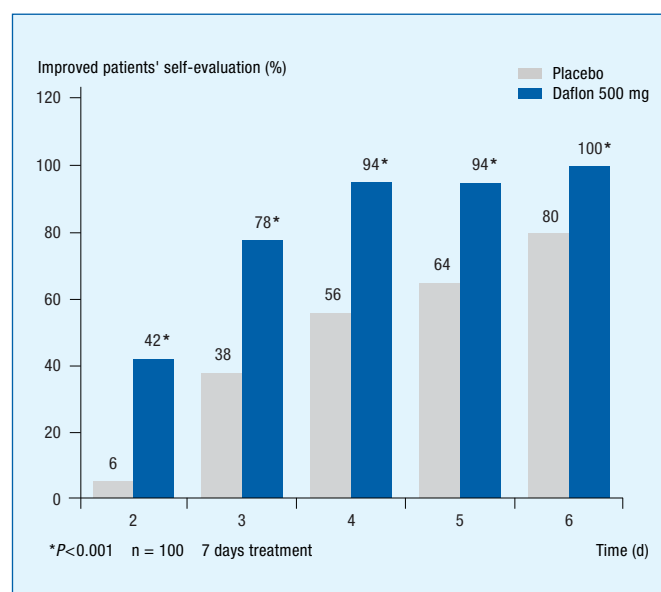


Figure 3. Patients recognize a significant improvement from the second day of treatment with Daflon 500 mg.

significant improvement after only 2 days of treatment, versus only 6% in the placebo group!

This outstanding fast efficacy is attributed to the unique micronized form of Daflon 500 mg.

Therefore, the very small size of Daflon 500 mg particles, as compared with other phlebotropic drugs, (1.7 μm vs 36.5 μm) leads to greater absorption⁹ (twice more), stronger and faster efficacy with Daflon 500 mg.

Daflon 500 mg offers a long-term protection against recurrent attacks

Both the Cospite and the Misra studies have been continued during 2 and 3 months, assessing the frequency and intensity of the attacks versus nonmicronized diosmin and placebo respectively. The dosage was then of 2 to 3 tablets per day. The intention was to see if the treatment with diosmin or placebo was able to modify the number and the duration of the hemorrhoidal attacks. It was also to check if the unique micronized form of Daflon 500 mg presented any advantages compared with the other forms.

The results obtained demonstrated a significant reduction in the number of acute episodes in all groups ($P<0.001$), but more evident and significant ($P=0.02$) in the subjects treated with Daflon 500 mg (Figure 4).

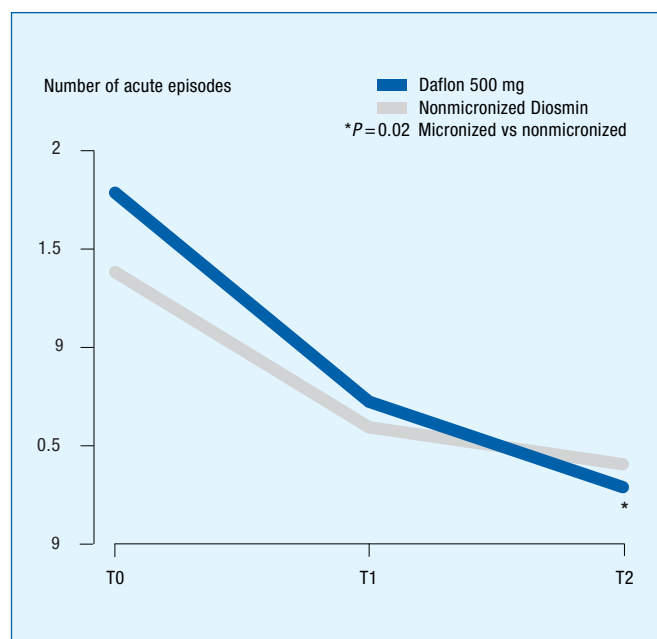


Figure 4. The superior reduction of acute episodes with Daflon 500 mg, thanks to the micronization.

In the Misra study, it appeared that the number of recurrent hemorrhoidal attacks was significantly lower in the patients who took Daflon 500 mg in prevention, with more than 6 out of 10 patients without any recurrent bleeding (Figure 5).

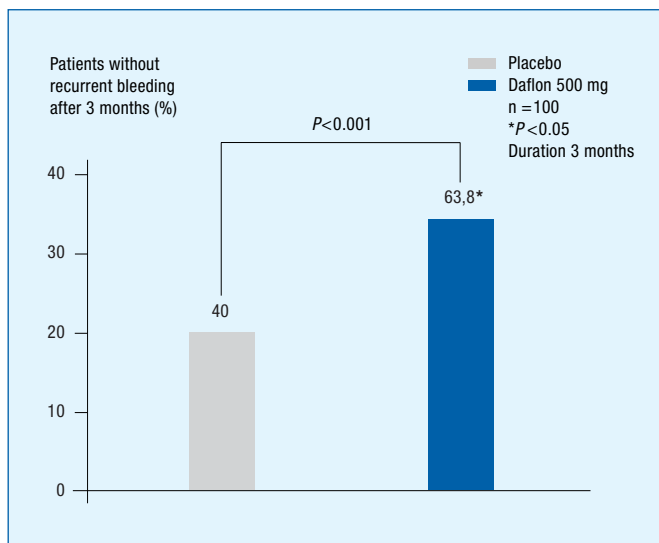


Figure 5. Daflon 500 mg offers a long-term protection against recurrent attacks.

CONCLUSION

Hemorrhoids are very disabling for the patients, and recurrent attacks are frequent.


The inflammation associated with acute crisis, involving enzymatic activity, free radicals, and inflammation mediators lead to pain and bleeding. Thanks to its unique pharmacological properties, Daflon 500 mg meets all the needs of an efficient hemorrhoidal treatment.

The clinical benefits of such properties are now well documented.

These two studies have demonstrated that the unique micronized form and comprehensive mode of action of Daflon 500 mg provide doctors and patients with a faster and stronger efficacy on acute attacks, at the dosage of 6 tablets for the first 4 days, and 4 tablets for the next 3 days. This efficacy allows a lower rate of recurrences, in the long term, and a decreased intensity and duration of the recurrent attacks (dosage of 2 tablets per day).

REFERENCES

1. **Limasset B, Michel F, Rey R, Guarrigues G, Crastes De Paulet A.** Inflammatory factors in the hemorrhoidal plexus. Proceedings of European Congress of the International Union of Phlebology. Budapest. 6-10 Sept 1993.
2. **Baumann J, Bruchhausen F, Wurm G.** Flavonoids and related compounds as inhibitors of arachidonic acid peroxidation. *Prostaglandins*. 1980;20:627-639.
3. **Labrid C.** Flavonoids, inflammatory phenomena, and permeability of capillary vessels. *Medicographia*. 1989;11:32-39.
4. **Damon M, Flandre O, Michel F, Crastes de Paulet A.** Effects of chronic treatment with a purified flavonoid fraction on inflammatory granuloma in the rat. *Arzneimittelforschung/Drug Res*. 1978;37:1149-1153.
5. **Galley P.** Etude de l'activité de Daflon 500 mg sur la résistance capillaire. *J Int Med*. 1987;88:25-26.
6. **Labrid C, Duhault J, Vix C.** Propriétés pharmacologiques de Daflon 500. *J Int Med*. 1987;85:30-36.
7. **Cospite M, Milio G, Amato C, Scrivano V, Ferrara F.** Modificazioni dell'emodinamica venosa trattati con alte dosi di diosmina-flavonoidi. *Farmaci*. 1985;11:451-546.
8. **Cospite M.** Double blind placebo controlled evaluation of clinical activity and safety of Daflon 500 mg in the treatment of acute hemorrhoids. *Angiology*. 1994;45:566-573.
9. **Garner RC, Garner JV, Gregory S, Whattam M, Calam A, Leong D.** Comparison of the absorption of micronized (Daflon 500 mg) and nonmicronized 14C-diosmin tablets after oral administration to healthy volunteers by accelerator mass spectrometry and liquid scintillation counting. *J Pharm Sci*. 2002;91:32-40.



The evolution of endovenous radiofrequency ablation (VNUS Closure) of varicose veins

Nicholas FASSIADIS

*Specialist Registrar
Maidstone Hospital
Department of General and Vascular Surgery
Kent -UK*

Anthony THEODORIDES, MD

*Junior House Officer
Ealing Hospital
Department of General and Vascular Surgery-
Middlesex - UK*

ABSTRACT

Extraluminal and intraluminal devices using monopolar energy have been utilized in the past to treat varicose veins. This report describes the development of these minimally invasive electrosurgical techniques.

Saphenous nerve injury, full-thickness skin burns, and high recurrence rates were the usual complications after such procedures. Radiofrequency ablation (VNUS Closure) is a new endovenous computer-feedback controlled application of bipolar electrothermal energy which reduces thermal spread to neighbouring tissues, thus avoiding the above problems.

Preliminary clinical VNUS Closure results demonstrate that this is a safe and effective minimally invasive alternative to the traditional high saphenous tie and strip.

INTRODUCTION

Great saphenous vein reflux is commonly treated by high ligation of the saphenofemoral junction (SFJ) and stripping of the great saphenous vein (GSV) from groin to below knee level.¹⁻³ Nonetheless, dissatisfaction with the above procedure incited many surgeons to develop alternative ways in treating varicose veins: ambulatory phlebectomy,⁴⁻⁶ injection sclerotherapy^{7,8} and cryotherapy.⁹

Ambulatory phlebectomy and sclerotherapy do not address the underlying reflux, and therefore a significant number of recurrences occur post-procedure.^{10,11}

More recently a new minimally invasive endovenous technique (VNUS Closure Sunnyvale San Jose) has evolved, which obliterates GSV reflux from within the vein as it utilizes bipolar electrothermal energy.^{12,13} Various electrothermal devices have been used in the past employing mainly monopolar energy via an endoluminal or extraluminal route to ablate the GSV. This article describes the evolution of electrosurgical techniques in the treatment of varicose veins since their introduction by Politowski in 1959.¹⁴

Keywords:

Radiofrequency - Ablation - Varicose veins - VNUS Closure

METHODS/DATA BASE

The following search strategy was conducted on the Medline database: I. Varicose veins AND thermal energy II. Varicose veins AND Electrocoagulation III. Varicose veins AND Electrofulguration IV. Varicose veins AND diathermy. All abstracts were reviewed with subsequent analysis of relevant articles and cross-references.

THE EVOLUTION OF ELECTROSURGICAL TREATMENT OF VARICOSE VEINS

Politowski applied endovenous high frequency current via rod-shaped electrodes following ligation of tributaries and ligation of the SFJ. He also utilized a second incision at the ankle in order to advance the electrode from distal to proximal. He also treated the short saphenous vein in the same manner after ligation of the saphenopopliteal junction, which was preoperatively identified by phlebogram. Postoperatively, elastic bandages and splints were applied to immobilize the patient until the 12th postoperative day. Politowski confirms in his animal experiments the efficacy of electrocoagulation of veins, demonstrating the histological changes of vein wall thickening with a closed lumen. His study included 231 patients, of whom 22 underwent the procedure for concomitant leg ulceration and 12 for cosmetic reasons only. Third-degree burns were encountered in 8 patients, requiring subsequent excision, 3 patients developed a wound infection, 4 patients suffered a permanent saphenous nerve injury, and 1 patient developed a pulmonary embolism. Seventy out of the 231 patients were followed up for 4 years, and according to the report, all of them sustained marked regression of their symptoms and only 6 patients developed recurrence of their varicosities. Politowski's conclusion at the time was that his results were encouraging, although 2 years later when he presents the results from 389 patients¹⁵ he admitted that the technique demands a certain dexterity and experience in order to avoid saphenous nerve injury which occurred in 20% of his patients, and skin burns (complication rate not mentioned in his article).

Werner describes the use of percutaneous diathermy in order to ablate varicosities and perforators. In his series the GSV was still treated with a high tie and strip down to the ankle. A timer was used in order to control discharge at the electrode to avoid skin burns. Postoperatively the leg was bandaged and the patient was allowed to walk on the same day. Forty patients were studied in this group with a follow-up of 1 year. Skin burns and paresthesia were

noted, but the author gave no figures. Nevertheless, the author concluded that the operation accomplishes its purpose, with cosmetic results superior to the prevailing method.¹⁶

Schanno¹⁷ utilized a similar high-frequency electric generator with an internal timer in order to treat primary and secondary varicose tributaries of the GSV and short saphenous vein (SSV) by a subcutaneously placed electrode. Again a standard high tie and strip of the GSV and SSV was performed prior to electrocoagulation of the tributaries. In his study group 34 patients had 52 legs treated. He distinguished between excellent (18 patients), good (13), and poor (3) results depending on the necessity of post-operative sclerotherapy. Five skin burns were noted in 4 patients but no peripheral nerve injuries were seen in his study group.

In 1972 Watts¹⁸ used a fluon-coated wire attached to a conventional diathermy machine in order to ablate the GSV from within the lumen introducing the wire at the ankle and advancing it to the SFJ after having the SFJ ligated. The wire is withdrawn at 2.5 cm per second after elevation of the leg. Unfortunately no data is given by the author regarding the number of patients treated and complications encountered. Watt states though that there is no significant difference in the results, comparing it with conventional stripping.

O'Reilly¹⁹ used filiform endovenous diathermy which he passed from the groin distally to below knee after cross-section. Short 1-second bursts of diathermy discharge were used at 1-to 2-cm intervals as the catheter was gradually withdrawn. His report analyzes 68 procedures in 48 patients with a maximum follow-up of 3 years. Two patients developed transient infrapatellar anesthesia. Only one skin burn occurred in his series, and one patient died secondary to a myocardial infarction.

Stallworth used a high-frequency cautery probe to obliterate tributaries and perforators subcutaneously through 1 to 2 mm incisions. He treated 705 patients with a follow-up varying from 6 months to 12 years. He stated that his results have been excellent in patients with primary varicose veins, and estimated a saving of \$385 per patient.²⁰

Gradman²¹ tried in 1994 to determine whether venoscopic electrocautery of saphenous vein tributaries can eliminate reflux into varices and reduce the need for further avulsion or sclerotherapy. All of the 12 patients studied underwent a preoperative duplex scan to identify and mark tributaries of the GSV. Retrograde venoscopy as described in a previous article²² was performed through a transverse venotomy at the proximal GSV. The catheter is advanced into the tributaries and 1-second bursts with 10 to 15W

energy are delivered to the veins and repeated at 1-cm intervals up to its junction to the GSV. In 9 patients (75%) the GSV was completely preserved and in 3 patients (25%) the GSV was partially thrombosed near the cannulated tributaries. Seven patients improved clinically but required further sclerotherapy, and one patient developed a skin burn. However, the follow-up in this series was only 2 months.

Chevru et al, had described previously the use of endovascular coils and balloons under angiographic control to obliterate arteriovenous fistulas intraoperatively at the time of tibial bypass in diabetic patients with in-situ saphenous vein bypass.²³ However, this technique has never been utilized for the treatment of varicose veins.

Recently, endovenous radiofrequency ablation has been used to treat an incompetent GSV (VNUS Closure, developed by VNUS Medical Technologies, Sunnyvale, CA, USA). This catheter-based device delivers bipolar electrothermal energy via electrodes with a temperature feedback loop using a thermocouple, which allows it to be applied in a controlled manner. This ensures transmural heating of the vein wall while minimizing thermal spread to adjacent tissues. The technique is described in greater detail elsewhere.¹² Reports are appearing in the literature of the success of VNUS Closure in treating GSV-reflux

without the previously encountered skin burns and high rates of saphenous nerve paresthesia.²⁴⁻²⁶ The efficacy of this technique has also been confirmed by ultrasound scan surveillance of the permanently closed GSV and surveillance of the SFJ, which does not exhibit any signs of neovascularization.²⁷ This has been proposed as the principal cause of recurrent SFJ incompetence in previous studies.^{28,29} VNUS Closure can also be utilized to treat reflux in side branches of the GSV and recurrent varicose veins where an incompetent GSV³⁰ persists either due to neovascularization at the SFJ or a persisting midhigh perforator.³¹

Boné first described in 1999 the technique of endoluminal laser energy application for the treatment of varicose veins.³² Since then this modality has been further developed at the Cornell University in New York to treat the incompetent GSV.^{33,34} Endovascular laser therapy (EVL) causes nonthrombotic vein occlusion by thermal destruction of the vein wall via 810-nm-wavelength laser energy. Excellent clinical results are observed at 1 to 3 years, with this technique with a low complication rate.^{34,35} Both novel endovenous procedures, VNUS Closure and EVLT, appear to be a safe and effective minimally invasive alternative treatment option for patients with GSV reflux, but both techniques are still subject to ongoing investigations.



Nicholas Fassiadis




Anthony Theodorides

Address for correspondence

Mr Nicholas Fassiadis,
MRCS (Ed)
55 Sheringham Avenue
London N14 4UH
United Kingdom
Tel. 00442083600419
Mobile 00447968037711
E-mail: nfassiadis@doctors.org.uk

REFERENCES

1. **Rutgers PH, Kitslaar PJ.** Randomised trial of stripping versus high ligation combined with sclerotherapy in the treatment of incompetent great saphenous vein. *Ann J Surg.* 1994;168:311-315.
2. **Dwerryhouse S, Davies B, Harradine K, et al.** Stripping of the long saphenous vein reduces the rate of reoperation for recurrent varicose veins. *J Vasc Surg.* 1999;29:589-592.
3. **Walsh JC, Beryan JJ, Beeman S, et al.** Femoral venous reflux abolished by great saphenous vein stripping. *Ann Vasc Surg.* 1994;8:566-570.
4. **Muller R.** Histoire de la phlebectomie ambulatoire. *Médecine Bien-être.* 1989;9-16.
5. **Olivencia JA.** Complications of ambulatory phlebectomies. Review of 1000 cases. *Derm Surg.* 1997;23:51-54.
6. **Alonzo O, Ruffolo I, Leonardi L, et al.** Ambulatory phlebectomy. Literature review and personal experience. *Minerva Cardiologica.* 1997;45:121-129.
7. **Hobbs JT.** Surgery and sclerotherapy in the treatment of varicose veins. A randomised trial. *Arch Surg.* 1974;109:793-796.
8. **Fegan WG.** Injection compression treatment of varicose veins. *Br J Hosp Med.* 1969; 1292.
9. **Cheatle TR, Kayombo B, Perrin M.** Cryostripping of the long and short saphenous veins. *Br J Surg.* 1993;80:1283.
10. **Bishop CCR, Fronck MS, Fronck A, et al.** Real time color-duplex scanning after sclerotherapy of the great saphenous vein. *J Vasc Surg.* 1991;14:505-510.
11. **Jacobsen BH.** The value of different forms of treatment for varicose veins. *BJS.* 1979; 66:182-184.
12. **Fassiadis N, Kianifard B, Holdstock JM, Whiteley MS.** A novel endoluminal technique for varicose vein management: The VNUS Closure. *Phlebology.* 2002;16:145-148.
13. **Sessa C, Pichot O, Perrin M and the closure treatment group.** Treatment of primary venous insufficiency with the VNUS Closure system. Results of a multicentre study. *Int Angiol.* 2001;20(Suppl 1):310.
14. **Politowski M, Szpak E, Masszalek Z.** Varices of the low extremities treated by electrocoagulation. *Surgery.* 1964;56:355-360.
15. **Politowski M, Zelazny T.** Complications and difficulties in electrocoagulation of varices of the lower extremities. *Surgery.* 1966;59:932-934.
16. **Werner G, Harlan AA, McPheeters HO.** Electrofulguration. New surgical method for varicose veins. *Minnesota Medicine.* 1964;47:255-257.
17. **Schanno JF.** Electrocoagulation: A critical analysis of its use as an adjunct in surgery for varicose veins. *Angiology.* 1968;19:288-292.
18. **Watts GT.** Endovenous diathermy destruction of internal saphenous. *BMJ.* 1972;4:53.
19. **O'Reilly K.** Endovenous diathermy sclerosis of varicose veins. *Aust NZ J Surg.* 1977;47:393-395.
20. **Stallworth MJ, Plonk GW.** A simplified and efficient method for treating varicose veins. *Surgery.* 1979;86:765-768.
21. **Gradman WS.** Venoscopic obliteration of variceal tributaries using monopolar electrocautery. *Dermatol Surg Oncol.* 1994;20:482-485.
22. **Gradman WS, Segalowitz J, Grundfest W.** Venoscopy in varicose vein surgery: initial appearance. *Phlebology.* 1993;8:145-50.
23. **Chevru A, Ahn SS, Thomas O, et al.** Endovascular obliteration of in situ saphenous vein arteriovenous fistulas during tibial bypass. *Ann Vasc Surg.* 1993;7:320-324.
24. **Fassiadis N, Holdstock JM, Whiteley MS.** Endoluminal radiofrequency ablation of the long saphenous vein (VNUS Closure) – a minimally invasive management of varicose veins. *Min Invas Ther Allied Technol.* 2003;12:91-94.
25. **Weiss RA, Weiss MA.** Controlled radiofrequency endovenous occlusion using a unique radiofrequency catheter under duplex guidance to eliminate saphenous varicose vein reflux: a 2 year follow-up. *Dermatol Surg.* 2002;28:38-42.
26. **Merchant RF, DePalma RG, Kabnick LS.** Endovenous obliteration of saphenous reflux: a multicentre study. *J Vasc Surg.* 2002;35:1190-1196.
27. **Fassiadis N, Kianifard B, Holdstock JM, Whiteley MS.** Ultrasound changes of the saphenous femoral junction and in the long saphenous femoral vein during the first year after VNUS Closure. *Int Angiol.* 2002;21:272-274.
28. **Nyamekye I, Shephard NA, Davies B, Heather BP, Earnshaw JJ.** Clinicopathological evidence that neovascularisation is a cause of recurrent varicose veins. *Eur J Vasc Endovasc Surg.* 1998;15:412-415.
29. **Jones L, Braithwaite BD, Selwyn D, Looke S, Earnshaw JJ.** Neovascularisation is the principal cause of varicose vein recurrence: results of a randomized trial stripping the long saphenous vein. *Eur J Vasc Endovasc Surg.* 1996;12:442-445.
30. **Fassiadis N, Kianifard B, Holdstock JM, Whiteley MS.** Treatment of difficult varicose veins using endovascular radiofrequency obliteration (VNUS Closure). *J Phlebol.* 2002;2:125-128.
31. **Fassiadis N, Kianifard B, Holdstock JM, Whiteley MS.** A novel approach to the treatment of recurrent varicose veins. *Int Angiol.* 2002;21:275-276.
32. **Boné C.** Tratamiento endoluminal de les varices con laser de diodo: estudio preliminar. *Rev Patol Vasc.* 1999;5:35-46.
33. **Navarro L, Min RJ, Boné C.** Endovenous laser: a new minimally invasive method of treatment for varicose veins – preliminary observations using an 810nm diode laser. *Dermatol Surg.* 2001;27:117-22.
34. **Min R, Zimmet S, Isaacs M, Porrestal M.** Endovenous laser treatment of the incompetent greater saphenous vein. *J Vasc Inter Radiol.* 2001;12:1167-1171.
35. **Min RJ, Khilnani N, Zimmet S.** Endovenous laser treatment of saphenous vein reflux: Long term results. *J Vasc Inter Radiol.* 2003;14:991-996.



Variants of functional venous disease

Claudio ALLEGRA
Anita CARLIZZA

*Department of Angiology,
San Giovanni Hospital,
Rome, Italy*

SUMMARY

In the continuing absence of a consensus definition, functional venous disease (FVD) can be described as encompassing any situation in which, over time, hemodynamic changes in venous drainage transform the risk factors for varicose veins into overt disease. The condition includes patients with primary varicose veins. This description is consistent with epidemiological evidence of incipient reflux, and encompasses functional chronic venous insufficiency (CVI) due to extravenous causes, also described as the functional phase of the prevaricose syndrome. In addition, it includes the syndrome of constitutional functional venous disease (CFVD) in which decreased vein wall tone and stasis microangiopathy are associated with the symptoms (heaviness, tension, and pain) and certain signs (lower-limb edema, cellulite, and permanent acral hypothermia) of venolymphatic hypertension, but without reflux, organic macrovascular disease or progression to overt varicose disease.

INTRODUCTION

In chronic venous insufficiency (CVI), blood flow is impaired by acquired or congenital venous dilatation or obstruction. The hemodynamic common denominator in all venous disease is reflux due to valvular incompetence, obstruction (thrombosis), or congenital venous or extravenous abnormalities.¹ Reflux can be long or short, depending on the junction (saphenofemoral or saphenopopliteal) or perforator involved.

In functional venous disease (FVD), the symptoms of CVI occur in the absence of organic superficial and/or deep venous disease. Classic-variant FVD is due to extravenous impairment of the push-and-pull mechanisms of venous drainage. The push mechanism consists of compression of the venous plexus in the sole of the foot, the calf muscle pump, and the pulsation of the contiguous arterial system. Pull is exerted by the diaphragm and negative mediastinal pressure.

Multiple extravenous factors can impair these mechanisms: sedentary lifestyle, obesity, respiratory and cardiac disease, work in the standing position, repeated pregnancy (inferior vena caval compression, altered endocrine environment, inadequate diaphragmatic excursion), peripheral arterial disease (where low perfusion pressure is combined with low or absent pulsatility), lower-limb disease (nerve root pathology, foot arch deformities), and anatomically inappropriate shoes.

Keywords:

Functional venous disease, microcirculatory stasis, venous reflux, varicose veins.

The consequences range from transient edema to venolymphedema and trophic lesions, without organic venous disease. Significant reflux, whether long or short, is absent. Venous drainage from the periphery is simply impaired, resulting in stasis or slow flow. The relative contributions to the cause of varicose veins by these extrinsic factors and a still putative inherited predisposition remain unknown.² However, the combination of flat feet, obesity, sedentary lifestyle and/or respiratory failure is almost inevitably associated with venolymphedema, even in the absent of a positive family history.

Cloarec et al defined a prevaricose syndrome encompassing intermediate phases between a normal venous system and overt varicose disease.^{3,4} Careful investigation for reflux in symptomatic but apparently healthy subjects revealed incipient hypotonicity of the vein wall, altered venous reactivity, hyperdistensibility, and wall thickening. Cloarec et al argued that subjects at risk required routine screening and prophylactic intervention to avoid progression to overt disease triggered by coexistent extravenous risk factors.

A subsequent prevalence study, the Italian Acireale project, found a prevaricose syndrome (family history, altered venous compliance) in only 22.6% of its population; it was absent in 15.9% of symptomatic subjects, whom the authors classified as having hypotonic venous disease. They concluded that this hypotonic variant of FVD was unlikely to be a prodromic phase of varicose disease, ie, prevaricose syndrome, since their controlled 10-year follow-up showed progression to overt disease only in the 'valvular incompetence without varicose veins' group.⁵ These results were consistent with those of Cloarec et al, who found no progression to overt varicose disease in 75% of their symptomatic population.

In addition to prevaricose syndrome, these studies thus identified a group of patients with the symptoms of CVI (peripheral edema, and heavy, restless, and painful legs), but with no specific risk factors, no evidence of reflux, and no progression to varicose disease.

CONSTITUTIONAL FVD

In 1997 we published our 10-year data on 300 controls and 820 patients with sporadic diffuse and/or regional edema, heavy restless legs, lipodermatosclerosis (cellulite), permanent objective acral hypothermia, subjective diffuse hypothermia, an allergic diathesis, and low-normal systolic blood pressure (100 ± 5 mm Hg; World Health Organization: 90–130 mm Hg). The women in this population also reported menstrual abnormalities (frequency,

quantity, and duration) and benign breast disease.⁶ Investigations included endocrine screening (testosterone, dehydroepiandrosterone, 17β estradiol, progesterone, and prolactin on day 21 of the menstrual cycle) and traditional nailfold capillaroscopy (Wild capillaroscope, magnification x 10; parameters: loop count, morphology, distribution, dimension); 78 consecutive patients underwent dynamic capillaroscopy (capillary red blood cell velocity, relative microhematocrit), microlymphography (microlymphatic loop count, microlymphatic diameter, endolymphatic pressure), laser Doppler (resting flux, venoarterial reflex), and venous echotomography (femoral and popliteal venous diameter ratios between the supine and upright positions). The data (Tables I–V) were analyzed using Student's t test.

COMMENTS

In women, endocrine changes account for many dysfunctional complaints typical of the childbearing years, including idiopathic cyclic edema, menstrual migraine, and premenstrual mastalgia. In women with FVD, they also account for diffuse edema, specific adipose tissue distribution, a menstrual symptom pattern, and cellulite.

	CFV	Controls
Progesterone nv 3.30 nanog/mL	14 ± 10**	26 ± 8
17β - estradiol nv 6 - 200 picog/mL	170 ± 50	140 ± 60
Prolactin nv 2 - 25 nanog/mL	23 ± 8*	14 ± 6
DHEA-5 nv 1.2 - 3.6		nv
Testosterone nv 0.1 - 1.1		nv
**P<0.05 *P<0.5		

Table I. Results

<ul style="list-style-type: none"> ■ Traditional capillaroscopy Normal number of loops (14-17/mm²) Decreased length: 70 ± 20 μ (nv: μ 150-300) Oblique disposition Arrow-like shape, tortuosity ➔ prepuberal capillaroscopic picture

Table II. Results

	CFV	Controls
rCVB (mm/sec.)	0.29 ± 0.13**	0.38 ± 0.07
Rel.Hct	45.27 ± 6.77**	30.80 ± 4.20
Microlymphatic diameters (μ)	72.63 ± 14.74*	62.30 ± 7.40
Meshes no	16.63 ± 11.39*	< 20
Endolymphatic pressure (Mm Hg)	2.70 ± 1.81***	5.30 ± 3.51
***P<0.001 **P<0.01 *P<0.05		

Table III. Constitutional and functional venopathy Dynamic capillaroscopy and microlymphography.

	Patients	Controls
RF (a u)	31.44 ± 10.03**	20.30 ± 5
VAR	25.27 ± 5.71***	43.80 ± 3
***P<0.001 **P<0.01		

Table IV. Constitutional functional venopathy Laser - Doppler.

<ul style="list-style-type: none"> ■ Normal subject: s/o position > 2.5 ± 0.7 no modification after VM ■ Constitutional phlebostasis s/o position > 4.2 ± 0.5 no modification after VM
--

Table V. Changes in large vein diameter during Valsalva manoeuver and in orthostatic position.

The demonstration of venular and endolymphatic hypertension is consistent with postural edema and could be considered the microvascular pathogenesis of cellulite. Our study identified a constitutional FVD syndrome – CFVD – defined by symptoms of venolymphatic hypertension (heavy, restless legs, tension, cramps, pain), decreased venous tone, cellulite, and permanent acral hypothermia, and by the absence of reflux or any evidence of structural macrovascular pathology on clinical examination or standard methods of investigation. The signs differentiating it from the prevaricose patients described by Cloarec et al^{3,4} and the Acireale project⁵ are vein wall hypotonicity without reflux, venular hypertension, altered hormone levels, and cellulite (Table VI); however, the many patients in these two studies who showed no changes in vein wall tone or reflux, and who did not progress to overt disease, are likely to have had the CFVD syndrome we have described, confirming the early studies by Menten.^{7,8} CFVD is a syndrome lying midway between an endocrine

disorder and the stasis microangiopathy possibly responsible for cellulite. In terms of the Clinic-Etiologic-Anatomic-Pathophysiologic (CEAP) classification, it may be difficult to differentiate from the prevaricose syndrome (C: 0-4; E: Ep; A: 0; P: unclassified; clinical score: 1-2; anatomic score: 0; disability score: 1). However, diagnosis is important for several reasons: CFVD is common, accounting for 30% of our referrals (Table VI); the CFVD entity is more than a cosmetic complaint of cellulite; and correct diagnosis avoids inappropriate therapy, whether with compression (which is poorly tolerated) or, worse, surgery. Patients can instead be offered effective venotonics (flavonoids and dihydroergotamine), lifestyle advice (high-protein diet, avoidance of sport involving high sustained mediastinal and/or abdominal pressure), and physiotherapy (heat therapy in iodinated salt water, manual lymph drainage, etc).

<ul style="list-style-type: none"> ■ Venous wall hypotone remarkable but without reflux ■ Decreased or normal venous pressure (Bartolo, 1997, Allegra 1978) ns ■ 100% familiarity ■ Evolution to varicose veins ns ■ Cellulitis
--

Table VI. Constitutional functional venopathy.

<p>CFV 1170</p> <p>Outpatients 3900/year</p>	<p>Mean/year (1988 -1997)</p> <p>Angiology Department S. Giovanni Addolorata Hospital Roma, Italy</p>
--	---

Table VII. Constitutional functional venopathy.

CONCLUSION

FVD includes two major syndromes: 1) a functional prevaricose syndrome of CVI symptoms due to extra-venous causes, with a high risk of progression to overt varicose disease; and 2) a CFVD syndrome of symptomatic venolymphatic hypertension, decreased venous tone, cellulite, and permanent acral hypothermia, with no significant reflux, no organic macrovascular pathology, and no progression to overt varicose disease.

REFERENCES

1. **Nicolaides AN.** Investigation of chronic venous insufficiency. A consensus statement. *Circulation*. 2000; 102:e126–e163.
2. **Agus GB, Allegra C, Arpaia G, et al.** Guidelines for the diagnosis and therapy of diseases of the veins and lymphatic vessels. Evidence-based report by the Italian College of Phlebology. *Int Angiol*. 2001; 20 (2, suppl 2).
3. **Cloarec M, Estryn-Behar M, Griton P, Blanchmaison P, Clement P, Larroque P.** Étude épidémiologique de l'insuffisance veineuse dans une population de l'île de France. *Phlebology*. 1992; 1:242–246.
4. **Cloarec M, Barbe B, Griton P, Vanet F.** Update on functional venous insufficiency. *Phlebolympology*. 1997; 3:3–9.
5. **Andreozzi GM, Signorelli S, Di Pino L, Garozzo S, Cacciaguerra G, Leone A, Martini R.** Varicose symptoms without varicose veins: the hypotonic phlebopathy, epidemiology and pathophysiology. The Acireale project. *Minerva Cardioangiol*. 2000; 48:277–285.
6. **Allegra C, Bonifacio M, Carlizza A.** Constitutional functional venopathy. In *Advances in Vascular Pathology*. International Congress Series 1150, European Congress of Angiology, 1997, Rome, Italy. Nicolaides AN, Novo S, eds. Elsevier, pp. 123–129.
7. **Merlen JF, Curri SB, Sarteel AM.** La cellulite, une mésenchymopathie discutée. *J Sci Med Lille*. 1978; 96:8–9.
8. **Merlen JF.** Microcirculation, artères et veines. *Arteres Veines*. 1982; 1:226.



Address for correspondence

Prof. Claudio Allegra
Ospedale San Giovanni
8, via dell' Amba Aradam
00184 Rome Italy
Tel: (39) 06-7705556
Fax: (39) 06-7705558
e-mail: allegraclaudio@libero.it



Congress and conference calendar

■ VIIIth NATIONAL CARDIO VASCULAR SURGERY CONGRESS

This congress will be held in Cappadocia (Turkey) from September 1 to 5, 2004.

• *For further information, please contact:*

President: Prof. Dr. Cevat YAKUT
 Interium Organization
 Tel: + 90 212 292 8808
 Fax: + 90 212 292 88 07
 e-mail: info@interium.com.tr

■ CONGRES DE LA SOCIETE FRANCAISE DE MEDECINE VASCULAIRE

This congress will be held in France (Lyon) from September 9 to 11, 2004.

• *For further information, please contact:*

President: A. Franco, J. Ninet
 De Vasculis 2004
 Palais des Congrès de Lyon
 50, Quai Charles de Gaulle
 69463 Lyon Cédex 06, France
 Fax: + 33 4 7985 8726

■ XIIth UNITED EUROPEAN GASTROENTEROLOGY FEDERATION (UEGF)

This congress will be held in Madrid (Spain) from September 25 to 30, 2004

■ NATIONAL CONFERENCE OF BULGARIAN SURGERY SOCIETY

This congress will be held in Varna, St. Konstantin (Bulgaria) from October 1-3, 2004.

• *For further information, please contact:*

President: Prof. Damian Damianov
 Hospital " Tzaritza Yoana" Medical University Sofia
 Sofia 1527
 Bialo More No 8 Str
 Hospital " Tzaritza Yoana" Medical University Sofia
 Surgery clinic
 Tel: + 35929432363
 Fax: + 35929432114
 e-mail: secbss@yahoo.com
 Website: www.bss.dir.bg

■ VIIIth CONGRESSO NAZIONALE COLLEGIO ITALIANO DI FLEBOLOGIA – CIF

This congress will be held in Rome (Italy) from October 6-9, 2004.

• *For further information, please contact:*

President: Prof. A.R. Todini
 Ops. C; Camillo Serv. Angiologia
 Circonvallazione Gianicolense
 00155 Rome, Italy
 GC Congressi
 Via Borsieri, 12
 00195 Rome, Italy
 Tel: + 39 (06) 37.00.541
 Fax: + 39 (06) 373.52.337
 Email: md2535clink.it

■ LYMPHO 2004

This congress will be held in Brno (Czech Republic) from October 8 to 9, 2004.

• *For further information, please contact:*

President: Prof Oldrich Eliska
CVUT - SÚZ Kongresové oddelení
Masarykova kolej
Thákurova 1
160 41 Prague 6, Czech Republic
Tel: + 420 233 051 226
Fax: + 420 233 051 155
e-mail: uhrova@suz.cvut.cz
congress@suz.cvut.cz
www.muweb.cz/www/lympho

■ NATIONAL CONFERENCE OF BULGARIAN ASSOCIATION OF ANGIOLOGY AND VASCULAR SURGERY

This congress will be held in Varna (Bulgaria) from October 8-10, 2004.

• *For further information, please contact:*

President: Prof. Todor Zahariev
Adress: Sofia 1309
Koniovitza No 65 Str
University Hospital "St. Ekaterina"
Vascular Surgery clinic
Tel: + 35929202256
Fax: + 35929200126
e-mail: TZAH@intech.bg

■ CONGRESSO NAZIONALE GIUV

This congress will be held in Rome (Italy) from October 14-16, 2004.

• *For further information, please contact:*

President: Prof. P.L. Antignani
GC Congressi
Via Borsieri, 12 Rome, Italy
Tel: + +39 (06) 37.00.541
Fax: + +39 (06) 373.52.337

■ ROMANIAN NATIONAL CONGRESS OF PHLEBOLOGY (8th Edition)

This congress will be held in Romania (Timisoara) from October 20 to 22, 2004.

• *For further information, please contact:*

President: Prof Marius Teodorescu
Bvd. Liviu Rebreanu n° 156
Timisoara, Romania
Tel: + 40 256 46 3001
Fax: + 40 265 462 123
e-mail: flebologie@yahoo.com

■ Vth NATIONAL LYMPHEDEMA NETWORK INTERNATIONAL CONFERENCE

This congress will be held in Sparks/Reno (USA) from October 20 to 24th, 2004.

• *For further information, please contact:*

Director: Joseph L. Feldman
NLN Conference Secretariat
Latham Square
1611 Telegraph avenue, Suite 1111
Oakland, CA 94612-2138, USA
Tel: + 1 510 208 3200
Fax: + 1 510 208 3110
e-mail: conference2004@lymphnet.org
Website: www.lymphnet.org

■ XXIXth PHLEBOLOGICAL DAYS

This congress will be held in Hradec Králové (Czech Republic) from October 21 to 22, 2004.

• *For further information, please contact:*

Congress Business Travel, s.r.o.
Lidická 43/66
150 00 Prague 5, Czech Republic
Tel: + 420 224 942 575-9
Fax: + 420 224 942 550
e-mail: senderova@cbttravel.cz
President: Jaroslav Strejcek, M.D.
Centrum dermatologické angiologie
Na Konvárce 6
160 00 Prague 6, Czech Republic
e-mail: strejcek@ri.ipex.cz

■ **IInd INTERNATIONAL COURSE**
Subdiaphragmatic Chronic Venous Insufficiency:
Abdomino pelvic and lower limbs

This congress will be held in Madrid (Spain) from October 21-22, 2004.

• *For further information, please contact:*

President: Dr J Leal Monedero, Dr S. Zubicoa Ezpeleta

Tel: + 34 91 378 40 01

e-mail: angiovascularlyz@ruberinternacional.es

■ **VIth INTERNATIONAL CONGRESS OF ASIAN VASCULAR SOCIETY and XIth ANNUAL CONFERENCE OF VASCULAR SOCIETY OF INDIA**

This congress will be held in Bangalore (India) from November 4 to 6th, 2004.

• *For further information, please contact:*

President: Dr Malay Patel

Jain Institute of Vascular Science
 Bhagawan Mahaveer Jain Hospital, Millers Road
 Vasanthnagar, Bangalore 560 052

Tel: + 91 80 222 07188

Fax: + 91 80 22208311

e-mail: asianvascular@yahoo.com

■ **XVIIIth ANNUAL CONGRESS OF THE ACP**

This congress will be held in Marco Island (Florida/USA) from November 4-7, 2004.

• *For further information, please contact:*

President: Neil S. Sadick

Organization: Bruce Sanders

Tel: + 1 510 834 6500

Fax: + 1 510 832 7300

e-mail: ACP@amsinc.org

■ **ANNUAL MEETING OF THE AUSTRIAN SOCIETY OF PHLEBOLOGY**

Common Meeting of the Working Groups
Operative Dermatology, Lasertherapy and Woundhealing
and Working Group Phlebology

This congress will be held in Vienna (Austria) from November 5 to 7, 2004.

• *For further information, please contact:*

Organisation: Univ. Prof. Dr. Kornelia Böhler
 Univ. Prof. Dr. Sanja SchullerPetrovic

IFC – Ilona Fuchs Congress

Postfach 6,

1106 Vienna, Austria

Tel: + 43/1/602 25 48

Fax: + 43/1/602 25 48

e-mail: congress@chello.at

■ **XXVIth CONGRESSO NAZIONALE DELLA SOCIETA ITALIANA DI ANGIOLOGIA E PATOLOGIA VASCOLARE (SIAPAV)**

This congress will be held in Messina (Italy) from November 18-21, 2004.

• *For further information, please contact:*

President: Prof N. Longo, Prof C. Allegra

GC Congressi

Via Borsieri, 12

00195 Rome, Italy

Tel: + +39 (06) 37.00.541

Fax: + +39 (06) 373.52.337

Email: md2535@mclink.it

■ **EUROPEAN SOCIETY OF SURGERY – VIIIth ANNUAL MEETING**

This congress will be held in St Julian's (Malta) in November 2004

• *For further information, please contact:*

President: Prof L. Cutajar

Chairman, Organising Committee, ESS Meeting
 Department of Surgery, The Medical School
 G'Mangia, Malta

■ **XIIth INTERNATIONAL CONGRESS OF ANGIOLOGY AND VASCULAR SURGERY**

This congress will be held in Lisbon (Portugal) from December 10 to 11, 2004.

• *For further information, please contact:*

President: Prof. Fernandes e Fernandes

Instituto Cardiovascular de Lisboa
Complexo Hospitalar das Torres de Lisboa
R. Tomás da Fonseca – Torre F – Piso 2
1600-209 Lisboa

Tel: + 21 722 13 90

Fax: + 21 722 13 92

■ **ALL INDIA CONGRESS OF OBSTETRICS AND GYNAECOLOGY (AICOG) 2005**

This congress will be held in Aurangabad (India) from January 6 to 9th, 2005.

• *For further information, please contact:*

President: Dr Kanan Yelikar

Ashwini hospital
12, Samarth Nagar
Aurangabad 431 001
Maharashtra, India

The federation of obstetric and gynaecological societies of India

Cama and Albles Hospital, New Building,
6th floor

Mahapalika Marg
Mumbai 400 001, India

Tel: + 91 22 226 72044

Fax: + 91 22 226 706405

e-mail: aicog2005@indiatimes.com

■ **SOCIETE FRANCAISE D'ANGEIOLOGIE (SFA)**

This congress will be held in France (Paris) from March 18 to 19, 2005.

• *For further information, please contact:*

President: M. Vayssairat, JJ Guex

Fax: + 33 1 5504 8217 / + 33 1 4250 7518

■ **XVth WORLD CONGRESS OF THE UNION INTERNATIONALE DE PHLEBOLOGIE**

This congress will be held in Rio de Janeiro (Brazil) from October 2nd to 7th, 2005.

• *For further information, please contact:*

Chairman: Angelo Scuderi

RIO UIP 2005 Secretary
Rua Santa Clara, 494
Sorocaba
18030-421- SP, Brazil

Tel: + 55 15 231 6619

Fax: + 55 15 221 4074 / 232 9241

e-mail: inspecmoc@dglnet.com.br

angelo.scuderilebologiabrasil.com.br

Website: www.flebologiabrasil.com.br

■ **XIXTH ANNUAL CONGRESS OF THE AMERICAN COLLEGE OF PHLEBOLOGY**

This congress will be held in San Francisco (USA) from November 10-13, 2005.

• *For further information, please contact:*

President: Neil S. Sadick

ACP Headquarters
100 Webster Street, Suite 101
Oakland, California 94607-3724, USA

Tel: + 1 510 834 6500

Fax: + 1 510 832 7300

e-mail: acp@amsinc.org

SERVIER UIP RESEARCH FELLOWSHIP 2005/2007



**\$ 30 000 grant
for an internal project
in the field
of phlebolympology**

✓ **2001 winner:**

Dr URBANEK (Poland)

Project: The role of apoptosis regulatory mechanisms
in the occurrence of primary varicose veins

✓ **2003 winner:**

Dr PASCUAL GONZALEZ (Spain)

Project: Elastin dysregulation in varicose veins

✓ **Next winner awarded at the
2005 UIP World Congress
in Rio de Janeiro and invited
to the 2007 UIP Chapter to present
the project results**



A leading company
in the field of phlebology



At the forefront of research and education in phlebology

Correspondent:

Servier International - 22, rue Garnier, 92578 Neuilly-sur-Seine Cedex - France

Website: www.servier.com