

Phlebology

ISSN 1286-0107

Vol 28 • No. 2 • 2021 • P37-80

No. 104



Iliac vein compression: undervalued or overestimated? 39

Marc Emmanuel VUYLSTEKE (Belgium)

Phlebolympheoedema: an up-to-date review 49

Jorge H. ULLOA, Sebastian CIFUENTES (Colombia)

The transosseous perforator veins of the knee 61

Jean-François UHL, (France)

VEIN STEP: Chronic Venous disorders management and Treatment Effectiveness Evaluation in Chronic Venous Disease, an International Observational Prospective Study. Results from Morocco 68

Tazi Mezalek ZOUBIDA (Morocco), Jorge H. ULLOA (Colombia)



Phlebology

Editorial board

Marianne DE MAESENEER

Department of Dermatology
Erasmus Medical Centre, BP 2040,
3000 CA Rotterdam, The Netherlands

Athanasios GIANNOUKAS

Professor of Vascular Surgery
University of Thessalia Medical School
Chairman of Vascular Surgery
Department,
University Hospital, Larissa, Greece

Marzia LUGLI

Department of Cardiovascular Surgery
Hesperia Hospital Modena, Italy

Oscar MALETI

Chief of Vascular Surgery
International Center of Deep Venous
Reconstructive Surgery
Hesperia Hospital Modena, Italy

Armando MANSILHA

Professor and Director of Unit of
Angiology and Vascular Surgery
Faculty of Medicine,
Alameda Prof. Hernâni
Monteiro, 4200-319 Porto, Portugal

George RADAK

Professor of Surgery
School of Medicine,
University of Belgrade,
Cardiovascular Institute Dedinje,
Belgrade, Serbia

Lourdes REINA GUTIEREZ

Director of Vascular Surgery Unit
Cruz Roja Hospital,
Madrid, Spain

Marc VUYLSTEKE

Vascular Surgeon
Sint-Andriesziekenhuis,
Krommewalstraat 11, 8700 Tiel,
Belgium

Editor in chief

Michel PERRIN

Clinique du Grand Large, Chassieu, France

Aims and Scope

Phlebology is an international scientific journal entirely devoted to venous and lymphatic diseases.

The aim of *Phlebology* is to provide doctors with updated information on phlebology and lymphology written by well-known international specialists.

Phlebology is scientifically supported by a prestigious editorial board.

Phlebology has been published four times per year since 1994, and, thanks to its high scientific level, is included in several databases.

Phlebology comprises an editorial, articles on phlebology and lymphology, reviews, and news.

Correspondence

Editorial Manager

Hurrem Pelin YALTIKIRIK
Servier Affaires Médicales
35, rue de Verdun
92284 Suresnes Cedex, France
Tel: +33 (1) 55 72 38 98
Email: hurrem-pelin.yaltirik@servier.com

Publication Director

Christophe CHARPENTIER
Suresnes, France

Publisher

Les Laboratoires Servier
50, rue Carnot
92284 Suresnes Cedex, France
Tel: +33 (1) 55 72 60 00

Indexed in EMBASE, Index Copernicus, and Scopus.

© 2021 Les Laboratoires Servier - All rights reserved throughout the world and in all languages. No part of this publication may be reproduced, transmitted, or stored in any form or by any means either mechanical or electronic, including photocopying, recording, or through an information storage and retrieval system, without the written permission of the copyright holder. Opinions expressed do not necessarily reflect the views of the publisher, editors, or editorial board. The authors, editors, and publisher cannot be held responsible for errors or for any consequences arising from the use of the information contained in this journal.

ISSN 1286-0107

Contents



Iliac vein compression: undervalued or overestimated? 39

Marc Emmanuel VUYLSTEKE (Belgium)



Phlebolymphe^dema: an up-to-date review 49

Jorge H. ULLOA, Sebastian CIFUENTES (Colombia)



The transosseous perforator veins of the knee 61

Jean-François UHL, (France)



VEIN STEP: Chronic VEnous disorders maNagement and Treatment Effectiveness Evaluation in Chronic Venous Disease, an International Observational Prospective Study. Results from Morocco 68

Tazi Mezalek ZOUBIDA (Morocco), Jorge H. ULLOA (Colombia)

Editorial

Dear Readers,

In this new issue of Phlebology, you will find the articles as below:

M. E. Vuylsteke (Belgium) provides an overview on iliac vein compression—a common anatomic disorder affecting more than 20% of the adult population—by explaining the historical perspective, its clinical presentation, and the methods of treatment.

J. H. Ulloa and S. Cifuentes (Colombia) present an up-to-date review on phlebolympheoedema to raise awareness of this disease, which has been underdiagnosed and poorly treated, and to show the need for new studies that compare treatment and diagnostic methods so that a consensus about treatment approach can be established.

Perforator veins of the knee can be responsible for reticular veins, telangiectases, and varicosities around the knee, but they are frequently underdiagnosed and missed by the phlebologists and the sonographers because of their tiny size. **J. F. Uhl (France)** proposes a systematization of these atypical perforator veins and discusses their possible role in phleboarthrosis.

VEIN STEP is an international, observational, prospective study assessing the effectiveness of conservative treatments for the relief of chronic venous disease (CVD) symptoms and their impact on quality of life (QOL). **T. M. Zoubida (Morocco)** and **J. H. Ulloa (Colombia)** share the study results collected in Moroccan patients, which provide large-scale data from a real-life Moroccan setting using both patient- and physician-reported outcomes.

Enjoy reading this issue!

Editorial Manager

Dr. H. Pelin Yaltirik



Iliac vein compression: undervalued or overestimated?

Marc Emmanuel VUYLSTEKE,
MD, PhD

Vascular Surgeon & Head of Surgical
Department, Sint-Andriesziekenhuis,
Tielt, Belgium;
Visiting professor, Department
of Cardiovascular Science,
University of Leuven, Belgium

Abstract

Iliac vein compression (IVC) is a common anatomic disorder affecting more than 20% of the adult population, especially young females. Most of those patients are asymptomatic. Some of them will develop symptoms in their left leg, such as swelling, pain, and heaviness. But progression to venous claudication, skin changes, and even venous ulceration is possible. Intolerance to exercise is an undervalued symptom. The most feared complication is the development of a deep venous thrombosis (DVT) and pulmonary embolism (PE). In addition to the symptomatology, the diagnosis can be confirmed using duplex ultrasound, computed tomographic (CT) scan, or magnetic resonance (MR) venography. However, for the exact measurement of the degree of stenosis and indication for stenting, intravascular ultrasound (IVUS) is the preferred tool for assessing iliac vein compression. Those patients are, especially in combination with other risk factors, at higher risk for developing DVT and PE. However, it is difficult to identify the patients who will benefit from a treatment (stenting) in terms of symptomatology and quality of life (QOL) or even in effective DVT prevention. Venous stenting is the treatment of choice and seems to be safe and effective. Poststenting antiplatelet medication is most appropriate for patients with nonthrombotic IVC, whereas postthrombotic patients should preferably be treated with oral anticoagulants. Meticulous selection of patients for treatment is necessary to avoid over-treatment.

Keywords:

May-Thurner syndrome; venous disease;
venous stenting

Introduction

Iliac vein compression (IVC) was until recently underestimated as a cause of venous hypertension. However, the awareness of the importance of iliac vein obstruction as a cause of lower extremity symptoms is increasing. Many patients nowadays are screened for IVC with an increasing frequency of iliac stenting as a result. The purpose of this paper is to review the pathophysiology, diagnosis, and treatment results of patients with diagnosed IVC.

History

As early as 1851, Rudolf Virchow (*Figure 1*) first proposed that the increased incidence of deep venous thrombosis (DVT) within the left lower extremity was a result of the right common iliac artery compressing the left common iliac vein (CIV), noting a five-fold left-sided predominance for DVT.¹ In 1957, the researchers May and Thurner described the anatomical variation in the left CIV,² now commonly named the "May-



Figure 1. Rudolf Virchow (1821-1902).

Thumer syndrome" (MTS) (Figure 2). They reported that 22% of 430 cadavers exhibited this anatomical variant with localized intraluminal fibrous bands, referred to as spurs, of the CIV. They postulated that the spurs were acquired from the chronic compression on the left CIV via the overriding right common iliac artery. The pulsatile compression from the right common iliac artery was thought to cause increased irritation of the endothelium, which subsequently caused cell proliferation and the development of spurs within the left CIV.²

It was Cockett and Thomas who first studied living patients presenting with an iliofemoral DVT from IVC syndrome. They used venography to describe the nature of the compression. These patients exhibited pigmentation, induration, and ulceration, as well as swelling and widespread pain of the entire left leg.³

Clinical presentation

IVC includes MTS and other conditions in which iliac veins are compressed, resulting in an impaired venous return from the affected leg to the heart. Most patients with this anatomy have no symptoms, but some can develop blood clots in the vein related to this compression. Compression can also be provoked by other anatomic structures such as

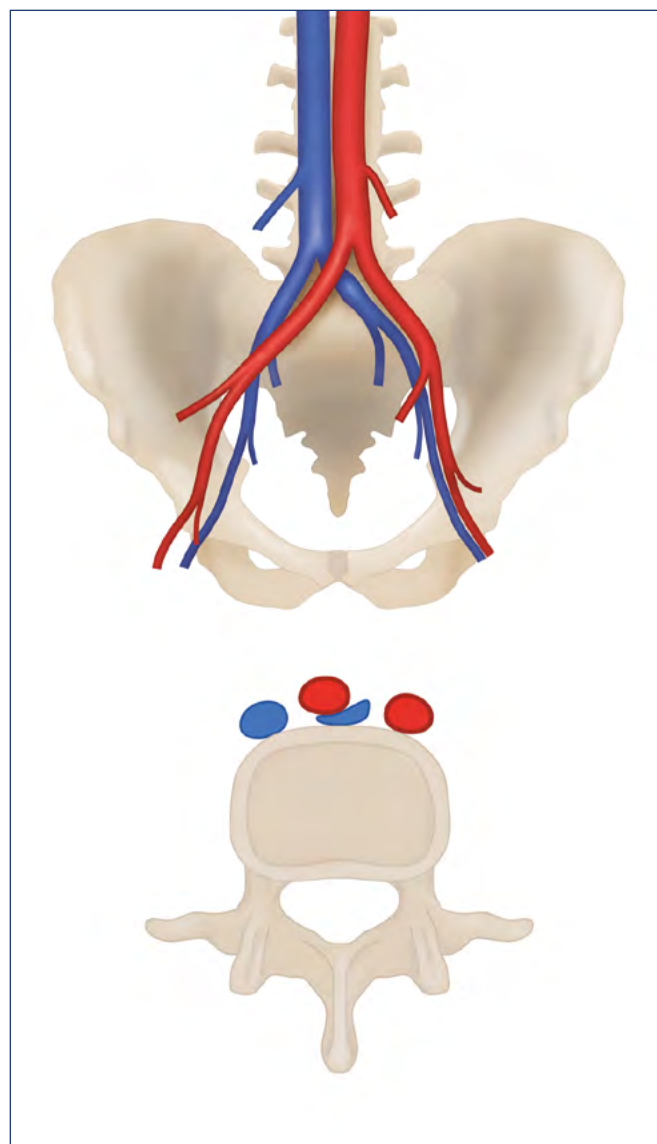


Figure 2. May-Thurner syndrome: compression of the left common iliac vein between the overriding right common iliac artery and the vertebral body.

lymphadenopathy, oncological disorders, arterial aneurysms, retroperitoneal fibrosis, and distended bladder and kidney.^{4,5} The obstruction of the iliac veins or vena cava may thus occur due to a variety of mechanisms, including postphlebotic venous thickening. In a similar manner, pregnancy may be associated with transient compression of the ilio caval venous segment.⁶

This compression is not exclusive to the left CIV; significant stenosis of the CIV can also occur on the right side, although clearly less frequently.

Significant compression of the left CIV is thought to be present in up to one-third of the general population. MTS is primarily

seen in people aged 18-50 years old. Women are five times more likely to have MTS.⁷

Nonthrombotic IVC is often referred to as “nonthrombotic iliac vein lesions” (NIVL). Clinical phases of IVC include a prolonged asymptomatic period followed by the gradual development of an intraluminal fibrous band (ie, spur), which can subsequently progress to an acute unilateral iliofemoral DVT that can be accompanied by a pulmonary embolism (PE).^{8,9} Furthermore, those patients can develop a postthrombotic syndrome (PTS) (Figure 3), which will aggravate their symptomatology and decrease their quality of life (QOL).

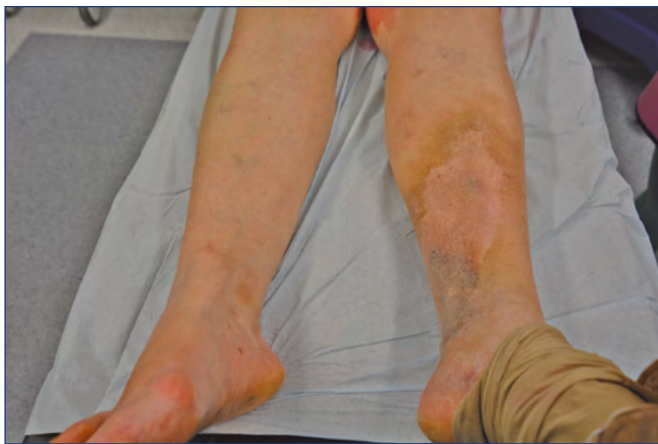

Figure 3. Patient with a postthrombotic syndrome.

Venous compression usually becomes clinically significant when increased venous pressure leads to the formation of venous collaterals, signs, and symptoms of chronic venous disease (CVD).¹⁰ However, the often-silent nature of the lesion precludes accurate assessment of its true prevalence.

Symptomatic IVC most commonly occurs in women in their 20s and 30s, when they develop left leg swelling, heaviness, and pain, also known as venous congestion. Symptoms worsen through the course of the day or after prolonged standing or sitting, causing significant leg swelling or tenderness. Some patients may also experience venous claudication. The occurrence of IVC in adolescents has also been documented. While IVC does occur among men, it occurs more frequently in women, although the reason for this has not yet been completely explained.¹¹ Research suggests that a female's pelvis exhibits more of an accentuation of the lumbar lordosis that pushes the lower lumbar vertebrae anteriorly, thereby compressing the left CIV against the right common iliac artery.^{9,12} In regard to treatment, due to the mechanical pulsatile nature of the obstruction from the right common iliac

artery, patients respond poorly to conservative anticoagulation therapy alone.^{13,14}

Clinical manifestation may be acute, with venous spur development and lower limb DVT, or chronic, including unilateral limb swelling, venous claudication, varicose veins, and ulceration.¹⁵ Patients with limb ulceration and chronic venous insufficiency have a high incidence of iliac vein obstruction. In patients with advanced venous disease (Clinical, Etiological, Anatomical, Pathophysiological classification [CEAP] 5-6), reports of a former deep venous thrombosis have been noted in at least 50% of cases, and 23% had obstruction of >80%.¹⁶

Patients with IVC or even iliac vein occlusion (IVO) have exercise intolerance. Due to the impaired venous return, cardiac preload may decrease. During sustained exercise, the majority of blood flow is directed to the lower limbs, and the splanchnic blood flow is reduced to 5% to 10% of total cardiac output.¹⁷ The increased preload during exercise drives an increase in stroke volume, but obstruction of venous return may significantly limit the cardiovascular response to exercise.¹⁸ The increase in venous return during upright exercise comes predominantly from the lower limbs. Obstruction to the ilio caval veins, including compression and intraluminal pathologies can restrict outflow from lower limbs and impair venous capacitance, limiting the rate of flow back to the heart, in addition to causing venous hypertension and damage to valves in the affected limb. Those patients may present with exertional dyspnea. Kaufman reported an improvement in the cardiovascular fitness test parameters after stent recanalization of chronic ilio caval occlusion after thrombosis (PTS).¹⁹

IVC is more common in women and is at least twice as frequent in women as in men.¹¹ Men tend to have more pain and swelling in the legs, whereas women tend to be younger and are more likely to have a pulmonary embolus on presentation.

Diagnosis

Clinical examination is insufficient to diagnose IVC. Given that most symptoms are rather atypical and could just as easily be due to CVD, the underlying cause may well be overlooked. Patients with signs and symptoms of CVD not responding to conventional management, may well suffer from IVC. Clinical presentations suggestive of IVC also include left lower extremity DVT in the absence of differential causes of iliofemoral thrombosis.

The presence of suprapubic collaterals is a very typical sign indicative of IVO. Especially in combination with other signs such as edema, skin changes, and even venous ulcerations.

IVC/IVO is a frequent and underappreciated contributor to venous hypertension in patients with venous leg ulcers. Patients with a history of DVT or duplex scan–diagnosed deep venous reflux have a higher incidence of outflow obstruction and should also be routinely examined to allow correction in this high-risk group of patients.

Duplex ultrasound has been identified as a sensitive method to identify venous stenosis; a peak velocity ratio of >2.5 across the narrowing was confirmed as the best criterion.¹⁵ However, ultrasound is highly examiner dependent. In many cases, it is technically difficult to capture an image of venous compression and stenosis via ultrasound due to the deep location of the iliac veins. Obesity and the presence of abdominal gas may complicate this examination.

Additionally, it may be overlooked in the investigation of the left iliofemoral DVT and thus underdiagnosed as an etiological factor.

Duplex ultrasound examination of the femoral vein may provide evidence of outflow obstruction with loss of respiratory variation in the femoral tracing or poor augmentation of the signal with distal limb compression.¹⁶ In patients with nonthrombotic IVC, ultrasound should be performed in supine and standing positions to identify whether the obstruction is positional or not.¹⁰

However, a negative duplex scan for outflow obstruction can be unreliable, as shown by Marston et al. In their study, 23% of cases of high-grade IVC on CT or magnetic resonance (MR) had a normal venous duplex.¹⁶

Contrast venography using transvenous pressure measurements has in the past been the gold-standard test used to diagnose IVC; the formation of collateral veins and a pressure gradient that is ≥ 2 mm across the iliofemoral stenosis at rest are landmarks of IVC (Figure 4). Specific findings on angiography are suggested to be associated with significant IVC. These include contrast translucency and lumen deformity, as well as axial, trans pelvic, or ascending lumbar collaterals.²⁰

Standard venography can underestimate the magnitude of stenosis by 15% to 30% compared with intravascular ultrasound (IVUS).²¹⁻²³

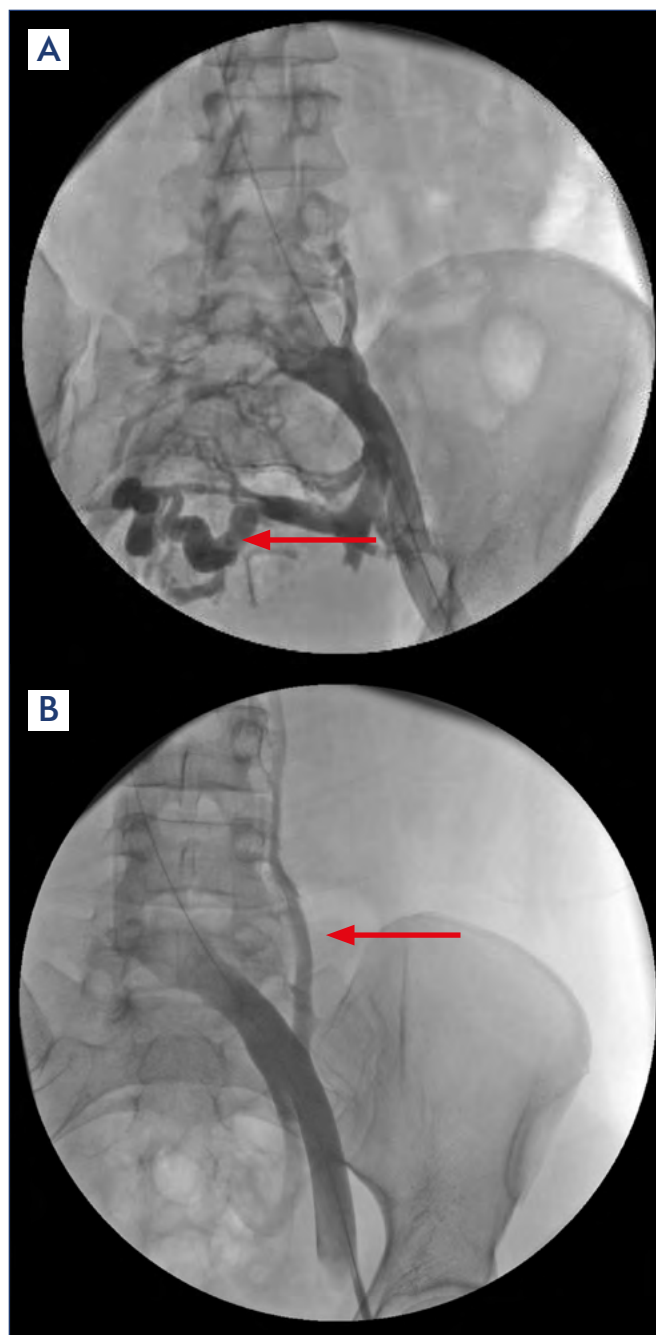


Figure 4. Venography of the left iliac vein, showing contrast translucency, obstruction, and pelvic collaterals (a, arrow) and ascending lumbar collaterals (b, arrow).

The existence of pelvic venous collaterals is a further clue for the presence of pathological IVC, suggestive of left CIV compression reaching hemodynamic significance.¹⁵

Several limitations exist in detecting IVC on CT-angiography. First, the ipsilateral reference CIV may have significant prestenotic dilatation, and this may exaggerate the compression severity. Also, IVC may involve the entire CIV in certain cases, and the

compression severity can therefore be underestimated. Finally, angulation of the CIV can lead to inaccurate measurements.²²

Using the contralateral CIV as a reference vessel assumes that the CIVs bilaterally are equal in size, which may be erroneous.

Because of its known limitations and lack of prospective validation studies, CT is not recommended initially to identify or exclude obstructive IVC.

Neither CT nor MR venography provide useful hemodynamic information to indicate the relevance of anatomic findings for venous function in the lower limb. In addition, CT and MR venography may not identify intraluminal webs or other chronic abnormalities that may contribute to poor venous function (Figure 5,6).¹⁶

IVUS is currently considered the gold standard in diagnosing IVC, whereas, the venography consistently underestimates the severity of the compression.

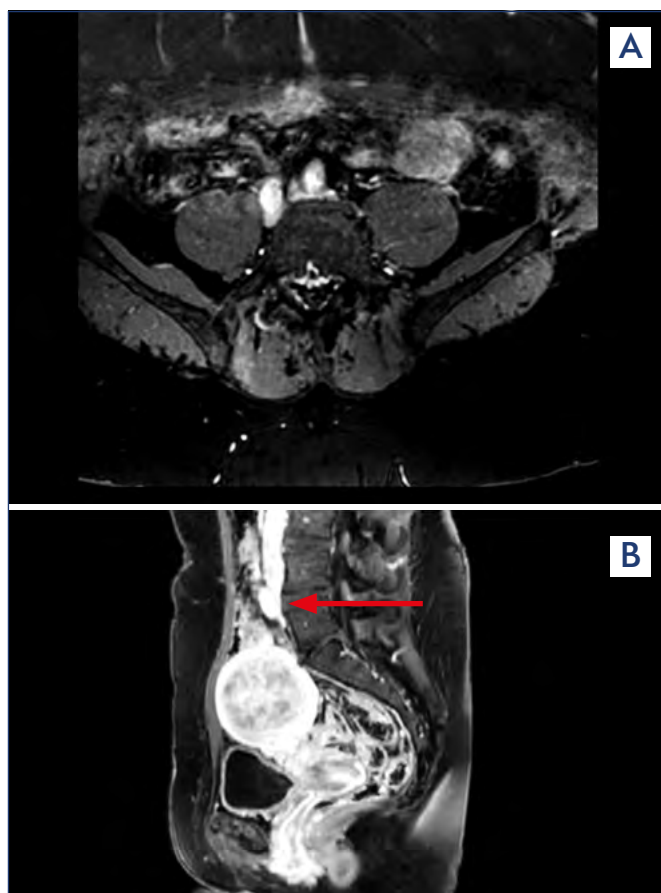


Figure 5. (a) Magnetic resonance (MR) angiography showing a bilateral iliac vein compression. (b) MR angiography showing compression of the left common iliac vein (arrow).

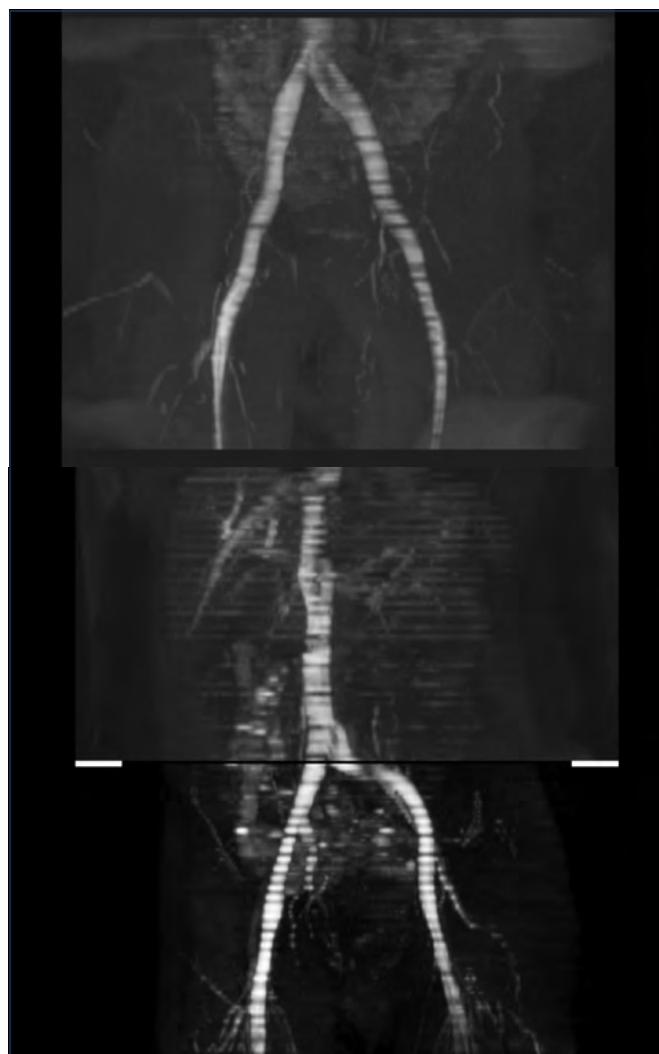


Figure 6. Magnetic resonance (MR) venography reconstruction showing compression of the left common iliac vein.

A minimal lumen area (MLA) of $<100 \text{ mm}^2$ seems to predict the presence of a significant compression in a symptomatic population as seen on IVUS ($>50\%$).²²

It is important to remember that all those anatomical investigations are usually performed in the supine position and may not reflect hemodynamic characteristics exacerbated by the standing position.¹⁵ Although venography and IVUS have been reported to be the gold standard for diagnosis, these are invasive, expensive studies that cannot be used to screen large numbers of patients who are potentially at risk for IVC.^{16,24} However, IVUS is of great value in measuring the degree of stenosis, determining the diameter of the stent required, as well as stenosis location and thus the length of the stent required (Figure 7). Therefore, it should always be used, if available, as preoperative support.

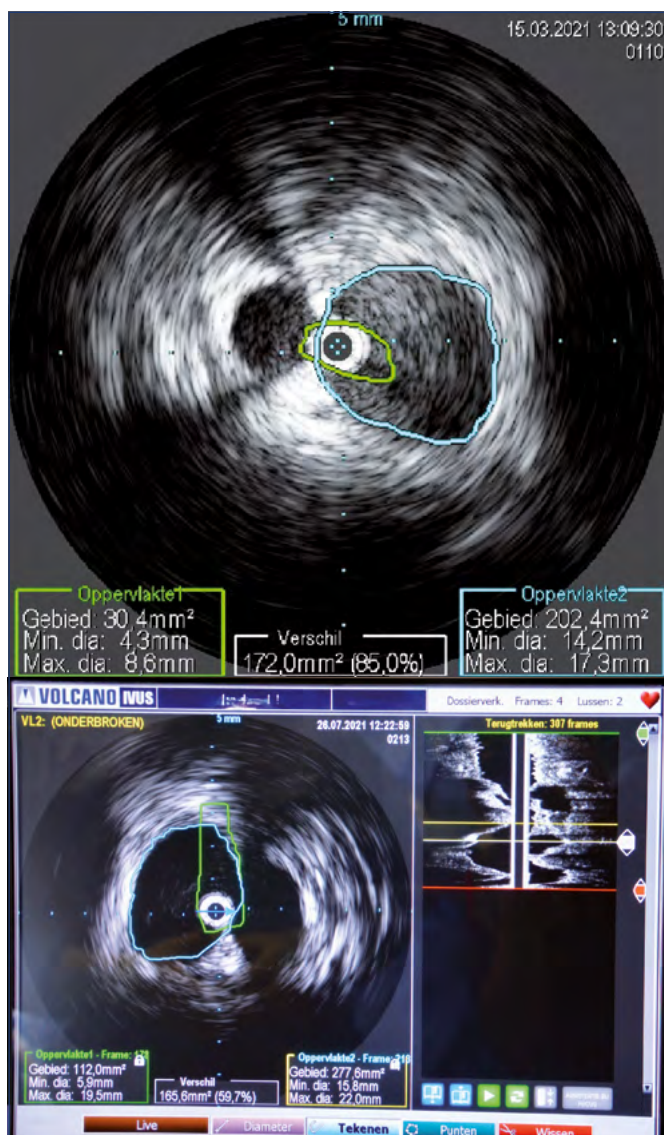


Figure 7. Intravascular ultrasound (IVUS) with measurement of the minimal lumen area and calculation of the degree of stenosis.

In young, healthy adults, a remarkably high percentage of anomalous angiographic examinations of the deep pelvic veins can be found.²⁵ These results therefore expose a potential imbalance between clinical signs and imaging findings in suspected IVC patients, leading to a risk of overtreatment.

With the uncertainty in diagnostic examinations, clinical evaluation of suspected IVC patients becomes increasingly important.

Complications

DVT is the most serious complication of IVC. Clinically, IVC accounts for only 2% to 5% of all DVTs,^{8,26} but it has been

speculated that the percentage of DVTs due to IVC may be much higher than clinically recognized. This suspicion is supported by the disproportionately greater incidence of left-sided DVT.²⁷ Of all patients with isolated DVT of the leg, 55.9% (95% CI, 54.0-57.8) had a left-sided DVT. This predominance of left-sided versus right-sided DVT is not modulated by obesity, age, sex, surgery, injury, or oral contraceptive use.²⁷

Clinical studies report that significant IVC occurs in the majority of patients with left DVT^{12,26} and a presence of fibrous spurs in 22% to 33% of cadavers.^{2,3}

Oguzkurt et al reported an increased average percentage of iliac vein obstruction (mean 74%, range 45%-100%) for patients presenting with left leg DVT compared with asymptomatic controls (mean 28%, range 0%-68%).²⁸ Notably, about 65% of their study population (DVT patients) had risk factors for DVT other than compression. However, Carr et al²⁹ concluded from their studies, in which diameters were measured in patients with DVT and in patients without DVT as a control, that IVC was a strong independent risk factor for development of DVT. Furthermore, using multivariate regression and adjusting for risk factors, the odds of left-sided DVT increased by a factor of 2.08 for each 1-mm decrease in left CIV diameter.

Owing to the potential associated severe consequences, such as PE and death, it may be postulated that preventive treatment in severe cases of asymptomatic IVC is defensible.²⁵

What about IVC without blood clot?

Patients with IVC are usually asymptomatic. The vein narrowing in these cases is often discovered on CT or MRI performed for other reasons. However, patients can develop symptoms.

Due to the high prevalence of IVC, even in asymptomatic patients, the IVC can be considered as a normal anatomic pattern. Kibbe et al³⁰ found that nearly one-fourth of asymptomatic patients had a greater than 50% compression, and two-thirds of patients had a greater than 25% compression. They proposed that some degree of compression of the iliac vein may be a normal anatomic variant that in itself does not place the patient at increased risk for development of DVT.³⁰⁻³² IVC can be found in many patients and many are asymptomatic. Van Vuuren et al have shown that only 63% of patients treated for IVC showed a clinical response to treatment, and 14% showed a minor symptom deterioration.²⁵

The diagnosis lacks a precise definition for the degree of compression that may designate a patient at high risk for developing a DVT.

Carr et al²⁹ reported an average stenosis of 68% among patients with a DVT due to IVC, whereas the age-matched controls had an average stenosis of 52%. The odds of DVT were increased by a factor of 2.18 for each 10% increase in left iliac vein stenosis. This strongly suggests that greater iliofemoral venous stenosis is associated with increased DVT risk. But the wide range of compression between patient groups suggests that the degree of stenosis alone is only one factor determining the development of DVT.⁹ Patients with IVC are more susceptible to developing a DVT, but this is often in combination with other risk factors such as prolonged immobilization, thrombophilia, trauma, etc.

Marston et al showed that nearly one-fourth of limbs that are affected with ulceration have IVC of 80% or more (CT venography).¹⁶ Patients with a history of DVT were positive for high-grade IVC in nearly 40% of the cases.

Studies with IVUS measurements show that IVC with 50% diameter reduction are likely to be hemodynamically significant in nonthrombotic patients. Furthermore, the VIDIO study (Venogram vs IVUS for Diagnosing Iliac vein Obstruction) showed that >54% area reduction was the optimal threshold, whereas a higher threshold of stenosis of >61% diameter stenosis was optimal to indicate significant clinical improvement at 6 months after iliac stenting in nonthrombotic patients.^{23,33}

Treatment

In patients with NIVL, the goal of treatment is to improve venous flow through the compressed iliac vein in order to relieve these symptoms and theoretically prevent future blood clot formation.

In patients with iliac vein thrombosis, treatments are aimed at dissolving blood clots and relieving the compression that caused them to form.⁷ The primary goal of treatment is to restore the normal blood flow in the compressed CIV. This is very often done by thrombolysis or mechanochemical thrombus removal. However, the discussion of these treatment options is beyond the scope of this paper.

Treatment for IVC is generally reserved for patients with symptoms, often those with a new DVT. Conventional surgical

procedures for the treatment of iliofemoral venous obstruction have largely been supplanted by an endovascular approach (Figure 8) relying on the deployment of dedicated venous stents (Figure 9).

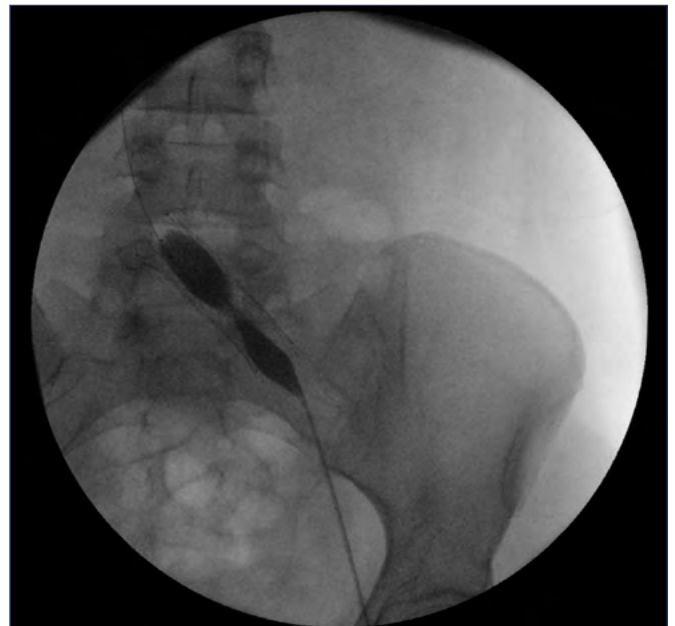


Figure 8. Venous stenting and balloon dilation.



Figure 9. Dedicated venous stent.

Reference	Number of included limbs		Follow-up	Primary patency	Primary assisted patency	Secondary patency
Neglén et al, ³⁴ 2007	464	PTS	6 y	57%	80%	86%
Hartung, ³⁵ 2011	130	PTS	10 y	77%	82%	86%
Hartung et al, ³⁶ 2009	89	NIVL	38 mo (1-144)	83%	89%	93%
Neglén et al, ³⁴ 2007	518	NIVL	6 y	79%	100%	100%
Raju, ³⁷ 2013	1083	NIVL	4-7 y	NA	NA	90%-100%
Raju, ³⁷ 2013	623	PTS	4-7y	NA	NA	74%-89%
Titus et al, ³⁸ 2011	40	PTS	2 y	78.3%	NA	95%

NIVL, nonthrombotic iliac vein lesions; PTS, postthrombotic syndrome.

Table 1. Patency rates for venous stenting, nonthrombotic iliac vein lesions (NIVL), and postthrombotic syndrome (PTS).

Nowadays, many patients diagnosed with NIVL, are treated with endovascular techniques. Despite ongoing controversy about the exact definition of its pathological process,¹⁵ endovascular treatment has been shown to be safe and effective for treatment of acute venous thrombosis or chronic compression (Table 1).³⁴⁻³⁸ Furthermore, Raju has shown that iliac vein stenting is a safe and effective treatment option.³⁷

The primary stent patency rates in the 6-month follow-up were 98.3% in NIVL versus 90.9% in PTS, with a statistical difference showing reduced stent patency in PTS. However, there is no statistical difference when the treatment is conducted in nonthrombotic patients as compared with patients with acute lower-limb DVT. These findings favor the treatment of acute DVT instead of PTS.³⁹

Following treatment, anticoagulation, compression stockings, and stent patency evaluation are recommended.

Anticoagulation

There is currently no consensus on the optimal medical therapy for patients after ilioacaval stenting. Anticoagulant and antiplatelet agents have been used in varying dosages and durations.

In many centers, anticoagulants, such as warfarin or direct oral anticoagulants (DOACs) are prescribed in the posttreatment period, and this is done for a period of 6 months. The rationale is that the reendothelialization of the stented vein segments takes about 6 months. A thrombotic reocclusion of a stent is a nightmare for many interventional vascular surgeons. Furthermore, it has been suggested that antiplatelet therapy

may play a lesser role in the slow-flow, low-shear venous system than in the arterial system.⁴⁰

In a systematic review of venous stent placement trials after DVT, 86% of patients received anticoagulation and 33% received antiplatelet therapy.⁴¹ Stent patency of 98% was observed in patients with NIVL and the occlusion/restenosis rates were similar comparing the patient cohorts with PTS and those with acute DVT (14.2% versus 14.8%). Most reocclusions occurred within the first 3 months, when most patients were still on anticoagulation.⁴⁰ In the studies of Raju and Neglén, only patients with thrombophilia received warfarin.⁴²

Eijgenraam et al⁴¹ conducted a systematic review of 14 venous stent studies after DVT (including PTS). They couldn't find any difference in outcome (reocclusion) comparing antiplatelet therapy (aspirin and/or clopidogrel) and oral anticoagulation. However, most studies were single-arm cohort studies with mostly a small sample size.

The American College of Chest Physicians guidelines recommended at least 3 months of anticoagulation in the setting of iliac vein stenting and thrombolysis for DVT.⁴³

Antiplatelet agents are likely most appropriate for patients with primary NIVL, whereas anticoagulants probably have a greater role in (post)thrombotic disease.⁴⁴

Results

IVC is commonly treated with iliac vein stenting. High patency rates have been reported.

Raju found, in a review of approximately 1500 iliac and caval stent series, a cumulative patency between 90% to 100% for nonthrombotic and from 74% to 89% in postthrombotic disease at 3 to 5 years of follow-up.³⁷

In a systematic review and meta-analysis including 1050 patients and 1169 affected lower limbs, da Silva Rodriguez reported a primary stent patency rate in 6-month follow-up of 98.3% in nonthrombotic IVC versus 90.9% in PTS. Titus et al stress the significance of underlying disease for long-term results, as they reported a significantly better 2-year outcome in patients with MTS than in those with thrombophilia as underlying cause of disease when comparing stenting with external compression.³⁸

Attaran et al⁴⁰ found that stents that occluded had a tendency toward longer length, extension into the common femoral vein, and more hypercoagulable syndromes. Inversely, larger-diameter ilio caval vein stents are associated with improved patency rates.

The degree of iliac vein stenosis does not appear to affect stent patency.⁴⁵ However, patients with a $\geq 90\%$ initial IVC stenosis more frequently experience recurrence of symptoms on long-term follow-up compared with mild and moderate stenosis cohorts. A hypothesis is that this symptom recurrence may be due to reduction in caliber of the stent over time, reflecting greater extrinsic compression from a greater degree of stenosis. The severity of the IVC stenosis grade is not a predictor of initial clinical symptoms.⁴⁵

Venous stenting has been shown to be safe and effective in the treatment of IVC. It has a positive effect on pain, reducing swelling, healing ulcers, and improving QOL.

Conclusion

IVC is a common anatomical finding. In many cases, patients are asymptomatic. However, some of them develop symptoms, such as leg swelling, heaviness, and pain. These can evolve to skin changes and even venous ulcerations. Such patients are, especially when their condition is in combination with other risk factors, at risk of developing a DVT and PE. However, it is difficult to identify those patients who will benefit from a treatment (stenting) in terms of symptomatology and QOL or even in effective DVT prevention. Venous stenting is the treatment of choice and seems to be safe and effective.



Corresponding author

M. E. Vuylsteke, MD, PhD
Sint-Andriesziekenhuis Tiel,
Secr Heelkunde, Bruggestraat 85, 8700 Tiel,
Belgium

Email: marc.vuylsteke@me.com

REFERENCES

- Virchow R. Über die Erweiterung kleinere Befasse. *Arch Path Anat*. 1851;3:1.
- May R, Thumer J. The cause of the predominantly sinistral occurrence of thrombosis of the pelvic veins. *Angiology*. 1957;8:419-427.
- Cockett FB, Thomas ML. The iliac compression syndrome. *Br J Surg*. 1965;52:816-821.
- Hung JB, Hsu CW, Tsai SH. Prostatism and May-Thurner syndrome. *Am J Emerg Med*. 2013;31:445-e12.
- Elsharawy MA, Moghazy KM, Alsaif HS, Al Asiri MM. Unusual case of left iliac vein compression secondary to May-Thurner syndrome and crossed fused renal ectopic. *Saudi Med J*. 2008;29:603-605.
- Humphries A, Mirjalili S, Tarr G, Thompson JMD, Stone P. The effect of supine positioning on maternal hemodynamics during late pregnancy. *J Matern Fetal Neonatal Med*. 2018;3923-3930. doi:10.1080/14767058.2018.1478958
- Liddell RP, Evans NS. May-Thurner syndrome. *Vasc Med*. 2018;23:493-496.
- Mousa AY, AbuRahma AF. May-Thurner syndrome: update and review. *Ann Vasc Surg*. 2013;27:984-995.
- Harbin M, Lutsey P. May-Thurner syndrome: history of understanding and need for defining population prevalence. *J Thromb Haemost*. 2020;18:534-542.
- Esposito A, Charisis N, Kantarovsky A, Uhl JF, Labropoulos N. A comprehensive review of the pathophysiology and clinical importance of iliac vein obstruction. *Eur J Vasc Endovasc Surg*. 2020;60:118-125.
- Kaltenmeier C, Erben Y, Indes J, et al. Systematic review of May-Thurner syndrome with emphasis on gender differences. *J Vasc Surg Venous Lymphat Disord*. 2018;6:399-407.
- Fraser DG, Moody AR, Martel PS. Re-evaluation of iliac compression syndrome using magnetic resonance imaging in patients with acute deep venous thromboses. *J Vasc Surg*. 2004;40:604-611.
- Ibrahim W, Al Safran, Hasan H, Zeid WA. Endovascular management of May-Thurner syndrome. *Ann Vasc Dis*. 2012;5:217-221.
- Meissner MH, Gloviczki P, Comerota, et al. Early thrombus removal strategies for acute deep venous thrombosis. Clinical practice guidelines of the Society for Vascular Surgery and the American Venous Forum. *J Vasc Surg*. 2012;55:1449-1462.

REFERENCES

15. Hameed M, Onida S, Davies A. What is pathological May-Thurner syndrome? *Phlebology*. 2017;32:440-442.
16. Marston W, Fish D, Unger J, Keagy B. Incidence of and risk factors for ilio caval venous obstruction in patients with active or healed venous leg ulcers. *J Vasc Surg*. 2011;53:1303-1308.
17. Harper D, Chandler B. Splanchnic circulation. *Br J Anesthesia Educ*. 2016;16:66-71.
18. Morris R, Sobotka P, Balmforth P, et al. Iliocaval venous obstruction, cardiac preload reserve and exercise limitation. *J Cardiovasc Translat Res*. 2020;13:531-530.
19. Kaufman JA, Dimov IP, Kuehl K, Kanable A, Balin J. Exercise intolerance in patients with chronic ilio caval venous occlusion: initial experience with noninvasive exercise testing before and after intervention. *J Vasc Interv Radiol*. 2021;32:305-308.
20. Raju S, Neglen P. High prevalence of nonthrombotic iliac vein lesions in chronic venous disease: a permissive role in pathogenicity. *J Vasc Surg*. 2006;44:136-143.
21. Neglén P, Raju S. Intravascular ultrasound scan evaluation of the obstructed vein. *J Vasc Surg*. 2002;35:694-700.
22. Shammam N, Shammam B, Miller S, et al. Predicting iliac vein compression with computed tomography and venography: correlation with intravascular ultrasound. *J Invasive Cardiol*. 2018;30:452-455.
23. Gagne PJ, Tahara RW, Fastabend CP. Venography versus intravascular ultrasound for diagnosing and treating iliofemoral vein obstruction. *J Vasc Surg Venous Lymphat Disord*. 2017;5:678-668.
24. Forauer AR, Gemeten JJ, Dasika NL, Cho KJ, Williams DM. Intravascular ultrasound in the diagnosis of iliac vein compression (May-Thurner) syndrome. *J Vasc Interv Radiol*. 2002;13:523-527.
25. Van Vuuren TMAJ, Kurstjens RLM, Wittens CHA, van Laanen JHH, de Graaf R. Illusory angiographic signs of significant iliac vein compression in healthy volunteers. *Eur J Vasc Endovasc Surg*. 2018;56:874-879.
26. Brazeau NF, Harvey HB, Pinto EG, Deipolyi A, Hesketh RL. May-Thurner syndrome: diagnosis and management. *Vasa*. 2013;42:96-105.
27. Thijs W, Rabe KF, Roosdaal FR, Middeldorp S. Predominance of left-sided deep vein thrombosis and body weight. *J Thromb Haemost*. 2010;8:2083-2084.
28. Oguzkurt L, Ozkan U, Ulsan S, Koc Z, Tercan F. Compression of the left common iliac vein in asymptomatic subjects and patient's with left iliofemoral deep vein thrombosis. *J Vasc Interv Radiol*. 2008;19:366-370.
29. Carr S, Chan K, Rosenberg J. Correlation of the diameter of the left common iliac vein with risk of lower-extremity deep venous thrombosis. *J Vasc Interv Radiol*. 2012;23:1467-1472.
30. Kibbe MR, Ujiki M, Goodwin AL, Eskandari M, Yao J, Matsumura J. Iliac vein compression in an asymptomatic patient population. *J Vasc Surg*. 2004;39:937-943.
31. Chen F, Den J, Yuan QW, et al. Compression of the left common iliac vein is independently associated with left-sided deep venous thrombosis. *J Vasc Surg Venous Lymphat Disord*. 2013;1:364-369.
32. Wolpert LM, Rahmani O, Stein B, Gallagher JJ, Drezner AD. Magnetic resonance venography in the diagnosis and management of May-Thurner syndrome. *Vasc Endovascular Surg*. 2002;36:51-57.
33. Gagne PJ, Gasparis A, Black S, et al. Analysis of threshold stenosis by multiplanar venogram and intravascular ultrasound examination for predicting clinical improvement after iliofemoral vein stenting in the VIDIO trial. *J Vasc Surg Venous Lymphat Disord*. 2018;6:48-56.
34. Neglén P, Hollis KC, Olivier J, Raju S. Stenting of the venous outflow in chronic venous disease: long-term related outcome, clinical and hemodynamic result. *J Vasc Surg*. 2007;46:979-990.
35. Hartung O. Results of stenting for postthrombotic venous obstructive lesions. *Perspect Vasc Surg*. 2011;23:255-260.
36. Hartung O, Loundou AD, Barthelemy P, Amoux D, Boufi M, Alimi YS. Endovascular management of chronic disabling ilio-caval obstructive lesions: long-term results. *Eur J Vasc Endovasc Surg*. 2009;38:118-124.
37. Raju S. Best management options for chronic iliac vein stenosis and occlusion. *J Vasc Surg*. 2013;57:1163-1169.
38. Titus JM, Moise MA, Bena J, Lyden SP, Clair DG. Iliofemoral stenting for venous occlusive disease. *J Vasc Surg*. 2011;53:706-712.
39. Da Silva Rodriguez L, Bertanha M, El Dib R, Moura R. Association between deep vein thrombosis and stent patency in symptomatic iliac vein compression syndrome: systematic review and meta-analysis. *J Vasc Surg Venous Lymphat Disord*. 2021;9:275-284.
40. Attaran R, Ozdemir D, Lin I, Mena-Hurtado C, Lansky A. Evaluation of anticoagulant and anti platelet therapy after ilio caval stenting: factors associated with stent occlusion. *J Vasc Surg*. 2019;7:527-534.
41. Eijgenraam P, Ten Cate H, Ten Cate-Hoek AJ. Venous stenting after deep venous thrombosis and anti thrombotic therapy: a systematic review. *Rev Vasc Med*. 2014;2:88-97.
42. Raju S, Neglen P. Percutaneous recanalisation of total occlusions of the iliac vein. *J Vasc Surg*. 2009;50:360-368.
43. Kearon C, Akl EA, Comerota AJ, et al. Antithrombotic therapy for VTE disease: anti thrombotic therapy and prevention of thrombosis, 9th ed: American College of Chest physicians evidence-based clinical practice guidelines. *Chest*. 2012;141(2 suppl):e419S-496S.
44. Meissner MH. Indications for platelet aggregation inhibitors after venous stents. *Phlebology*. 2013;28(suppl 1):91-98.
45. Jayaraj A, Buck W, Knight A, et al. Impact of degree of stenosis in May-Thurner syndrome on iliac vein stenting. *J Vasc Surg Venous Lymphatic Dis*. 2019;7:195-202.



Phlebolymphe­dema: an up-to-date review

Jorge H. ULLOA,¹ MD, FACS;
Sebastian CIFUENTES,² MD;
Valentin FIGUEROA,² MD;
Emelyn Van UDEN,² MD;
Javier A. BRAVO,² MD;
Miguel AMORE,³ MD;
Jairo RAMÍREZ,¹ MD, FACS

¹Vascular Surgery Department, Fundación Santa Fe de Bogotá University Hospital; Universidad de los Andes Medical School, Bogotá, Colombia;

²Universidad de los Andes Medical School, Fundación Santa Fe de Bogotá University Hospital, Bogotá, Colombia;

³Vascular Surgery Department, Fundación Favaloro, Buenos Aires, Argentina

Keywords:

chronic venous insufficiency; intermittent compression device; lymphedema; lymphography; MPFF; phlebolymphe­dema.

Phlebology. 2021;28(2):49-60

Copyright © LLS SAS. All rights reserved

www.phlebology.org

Abstract

Phlebolymphe­dema is a vascular condition in which there is damage of the venous and lymphatic systems in the lower limbs. It is secondary to chronic venous insufficiency, which results in venous hypertension causing fluid leakage into the interstitial space. Under normal conditions, this fluid would be drawn away by the lymphatic system. However, when the capacity of the lymphatic system is exceeded over time, the lymphatic vessels get damaged and the interstitial protein-rich fluid cannot be drained. Current information on the most effective way to diagnose and treat this pathology is incomplete and inconclusive. Nowadays, the diagnosis is based on clinical examination, duplex ultrasound to assess the venous component of the disease, and lymphoscintigraphy to evaluate the lymphatic damage. The treatment commonly consists of complete decongestive therapy and manual lymph drainage. Despite these being the most used management methods, new modalities of diagnosis and treatment are emerging and will be discussed in this article. The purpose of this review is to increase physician knowledge about the epidemiologic aspects, physiopathology, and management of phlebolymphe­dema. We intend to raise awareness of this disease, which has been underdiagnosed and poorly treated, and to show the need for new studies that compare treatment and diagnostic methods to establish a consensus about how to approach this disease.

Introduction

Phlebolymphe­dema is a pathology with damage of the venous and lymphatic systems in the lower limbs. Chronic venous insufficiency (CVI) promotes venous hypertension and fluid leakage that under normal conditions would be drained through the lymphatics; however, in this disease, it cannot be cleared away. This article includes the definition, epidemiology, pathophysiology, classification, diagnosis, and treatment of phlebolymphe­dema based on up-to-date evidence. This narrative review aims to increase physician knowledge and awareness of this commonly neglected disease.

Methods

We used the MeSH terms “Phlebolymphe­dema,” “Chronic Venous Insufficiency,” “Phlebolymphe­dema AND Chronic Venous Insufficiency” and “Lymphedema” to search in PubMed, Google Scholar, and Embase.

Inclusion criteria:

1. "Phlebolympheoema" as a keyword.
2. "Chronic Venous Insufficiency" with "Lymphatic system" and/or "Lymphedema" in the abstract or as a keyword.
3. Articles published in the last 10 years.

Exclusion criteria:

1. Articles not written in English or French.
2. Case reports, case series.

In total, 20 691 articles were found, out of which 53 met the inclusion criteria. To ensure the quality of the article, the Scale for the Assessment of Narrative Review Articles (SANRA)¹ was followed.

Definition

Phlebolympheoema consists in damage of the venous and lymphatic systems, resulting in limb edema. These systems play complementary roles in fluid return from the extremities; hence, if one is overloaded, the other one compensates as long as it can. When one fails (eg, in CVI or lymphedema), their interdependence leads to overloading of the other, leading to a dual system failure, known as phlebolympheoema.^{2,3}

Epidemiology

Phlebolympheoema is an underdiagnosed condition, and its epidemiology is not clear.⁴ A study in Poland in 2003 calculated the incidence of phlebolympheoema as 10%, in 40 095 patients with CVI.⁵ Moreover, Dean et al showed that out of 440 patients with lymphedema, 41.8% of cases were caused by phlebolympheoema, followed by cancer in 33.9% and lipedema in 11.8%.⁶ The lymphatics play a major role in any kind of edema,^{2,7,8} with >300 million people suffering from edema worldwide.⁴ Szyber et al reported that there were approximately 6 million cases of lower-limb lymphedema, and 60% of them had CVI.⁹ Conversely, a more recent study showed that out of 26 902 patients with lymphedema, 10.4% presented phlebolympheoema.¹⁰

Phlebolympheoema is the most important cause of secondary lower-limb lymphedema in industrialized countries. However, the main etiology of lymphedema worldwide is filariasis; a parasitic infection caused by *Wuchereria bancrofti*. It is the second cause of chronic disability worldwide, affecting around 120 million people, 15 million with severe illness.¹¹ Although this infection is eradicated in the United States (US), it is endemic in tropical and subtropical developing countries.¹²

Pathophysiology

The physiology of fluid movement through the body has three major components, the venous, arterial, and lymphatic systems. Normally, the hydrostatic pressure of the precapillary end of the arteriole pulls the fluid out to the interstitial space, and the oncotic pressure at the venule site takes it back to the circulation. Ten percent of the ultrafiltrate is reabsorbed by the lymphatics, which capture, drain, filter, and concentrate this protein-rich fluid in the lymph nodes and take it to the circulation.⁴ Lymphatic flow varies widely according to cardiovascular hemodynamics in exercise or resting state. The lymphatics have a large capacity and usually work at about 10% of their capacity in a healthy individual.^{13,14}

The important function of lymphatic drainage consists of removing proteins, macromolecules, cytokines, and blood elements from the interstitium. Then, the lymph gets concentrated and filtered in the lymphatic nodes. Lymph's flow and impulse are possible owing to mechanisms like the lymphatic pumps, driven by external factors such as muscular contraction, arterial pulsations or stretch bandaging, and internal mechanisms like the lymphangions. These are microscopic one-way bicuspid-valve micropumps, located from the capillary throughout the whole lymphatic system. Lymphangions have their own rhythmic contractility with 1 to 30 contractions per minute preventing fluid backflow.⁴

On the other hand, when there is alteration of the venous return mechanisms, CVI can occur. This might be attributable to age-related loss of valvular competence, surgery, or deep venous thrombosis (DVT). The severely increased venous pressure produces massive hyperemia and accumulation of interstitial fluid that must be drained by the lymphatics. DVT produces a proinflammatory state that leads to vessel fibrosis and long-term destruction of the valve leaflets. The postphlebotic syndrome is characterized by both valvular incompetence and fibrosis of the vessels, resulting in long-term venous hypertension.¹⁵

In phlebolympheoema, the chronic interstitial accumulation of proteins and proinflammatory cytokines such as transforming growth factor beta (TGF- β), tumor necrosis factor alpha (TNF- α), immunoglobulins, and macromolecules with a size <1 μ m, lead to tissue fibrosis and damage of the skin, promoting the entrance of bacteria capable of generating severe cellulitis episodes.¹⁶ Another important function of the lymphatic system is the control of local immune responses. Phlebolympheoema may lead to a particular clinical condition of a locally

altered immune response: an immunocompromised district,¹⁷ a skin zone previously damaged by events such as chronic lymphedema, herpes zoster infections, radiation, burns, and trauma that developed unusual immune behavior.¹⁸ These areas remain vulnerable to frequent opportunistic infections, tumors, and immunity-related disorders.¹⁹

The weakened immune control predisposes patients with phlebolympheidema to suffer from recurrent bacterial and fungal infections (eg, erysipelas and tinea pedis respectively) and to malignancy of the chronic venous ulcers, with squamous cell carcinoma as the most common type.²⁰ Even a multicentric neoplasm like lymphoma could display preferential localization on a chronic venous ulcer.²¹ Moreover, recurrent infections lead to increased scarring and trauma of the vessels, causing further damage and resulting in a worsening lymphedema.⁴

Classification

This disease is classified according to the etiology; primary phlebolympheidema usually presents at birth or during early ages,¹⁷ is caused by congenital malformations like deep-vein dysplasia, lymphatic aplasia or hypoplasia, or defect of both the venous and lymphatic systems, such as Klippel-Trenaunay syndrome (KTS), characterized by hemolympheidatic malformations,^{22,23} capillary abnormalities, and hemorrhagic lymphangiectasia. It might be accompanied by adipose or osseous tissue overgrowth, becoming part of the *PIK₃CA*-related overgrowth syndromes (PROS). The proportion of patients that present lymphedema is low, and is usually mistaken for overgrowth.^{24,25} Primary pure lymphatic malformations represent less than 30% of the causes, and approximately 28 mutations have been described, with a familial component.²⁶

On the other hand, secondary phlebolympheidema is acquired, mostly as a result of CVI but also because of lymphatic injury in vein stripping (saphenectomy), vein-harvesting procedures for coronary bypass, vascular or orthopedic surgery (Figures 1 and 2), or penetrating trauma.^{17,27} All these causes can lead to chronic lymphatic insufficiency (CLI).²⁸ Therefore, secondary phlebolympheidema is limited to the affected portion of the limb and usually takes a long time to debut, whereas primary phlebolympheidema has a diffuse presentation along the whole territory of the truncular malformation.

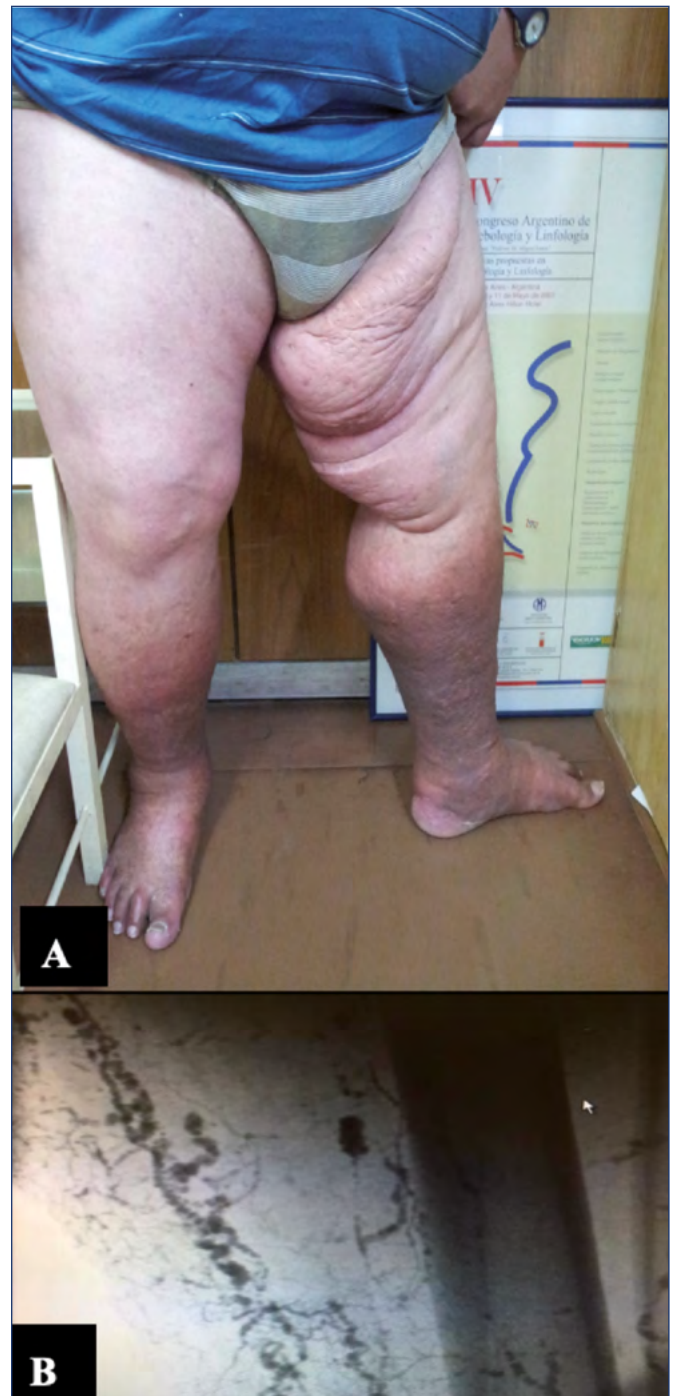

Figure 1. 52-year-old male patient with morbid obesity and chronic venous insufficiency (CVI), with previous history of greater saphenous vein stripping. He has a direct lesion in the canalicular and nodal lymphatics.

A) Predominant thigh lymphedema secondary to the procedure.

B) Contrast lymphography shows ectasia and ruptured lymphatic vessels.

Diagnosis

The diagnosis of phlebolymphe­dema is based on a detailed clinical history and physical examination, looking for signs of both venous and lymphatic malfunction.

Stasis dermatitis

Venous hypertension transmits hydrostatic pressure to the dermal capillaries, increasing their permeability and leading to fibrinogen leakage, producing ulcers and stasis dermatitis.²⁹ Patients report pruritus of insidious onset, followed by a reddish-brown skin discoloration and hyperpigmentation due to the hemosiderin deposits after the extravasation of erythrocytes (hemosiderosis). It often affects the medial ankle but can extend circumferentially.⁴

Lipodermatosclerosis

Lipodermatosclerosis (LDS) corresponds to skin induration, fibrosis, and hyperpigmentation caused by panniculitis

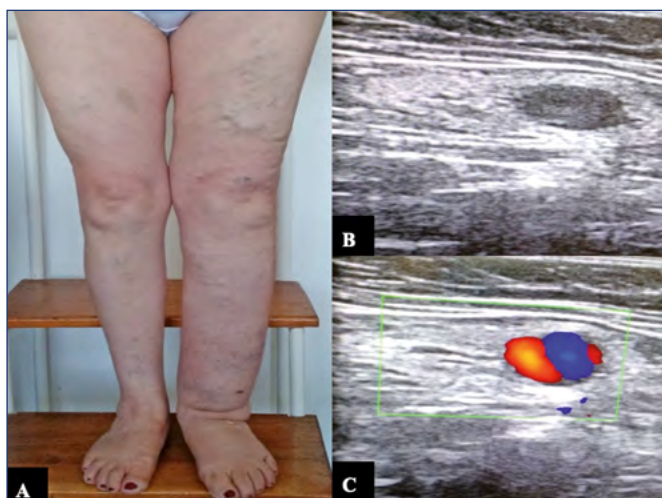


Figure 2. 61-year-old female patient with prior history of great saphenous vein stripping, three months after the procedure the patient started showing clinical signs of lymphedema.

A) Phlebolymphe­dema as a consequence of intranodal venous hypertension.

B,C) Duplex ultrasound that shows ectasia of the subcapsular sinus and intranodal venous hypertension.

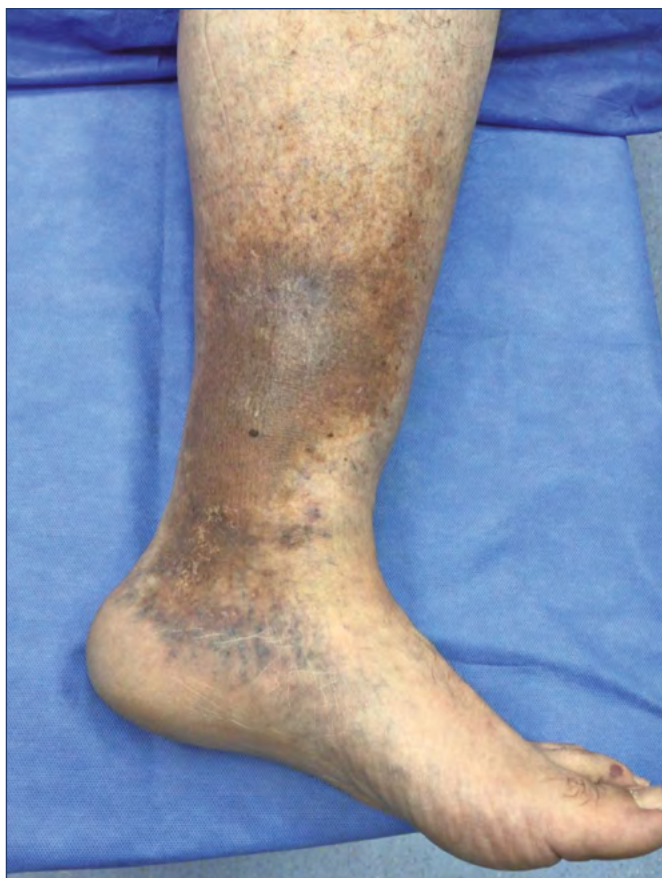

Figure 3. Lipodermatosclerosis. C4 patient (according to CEAP classification [Clinical, Etiologic, Anatomic Pathophysiologic]), with reddish-brown skin discoloration and hyperpigmentation.

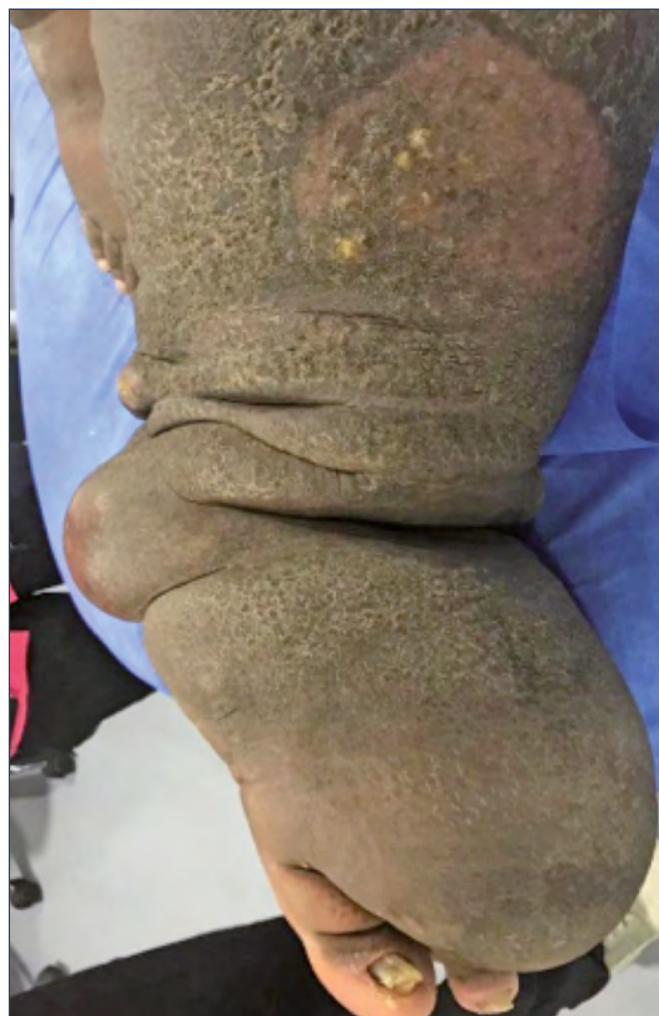

Figure 4. Severe lipodermatosclerosis. Edema with skin fibrosis and hyperpigmentation.

(Figures 3 and 4),³⁰ which may give the leg the "inverted champagne bottle" sign (Figure 5).⁴ Up to 70% of LDS is associated with CVI. Initially, it can mimic cellulitis; however, biopsies would show fibrosis on the dermal layers and thick capillaries surrounded by fibrin and siderophages, but further invasive diagnosis is discouraged because of tissue fragility. Localized patches of atrophy and thickened skin with papillomatosis can also be found.³¹

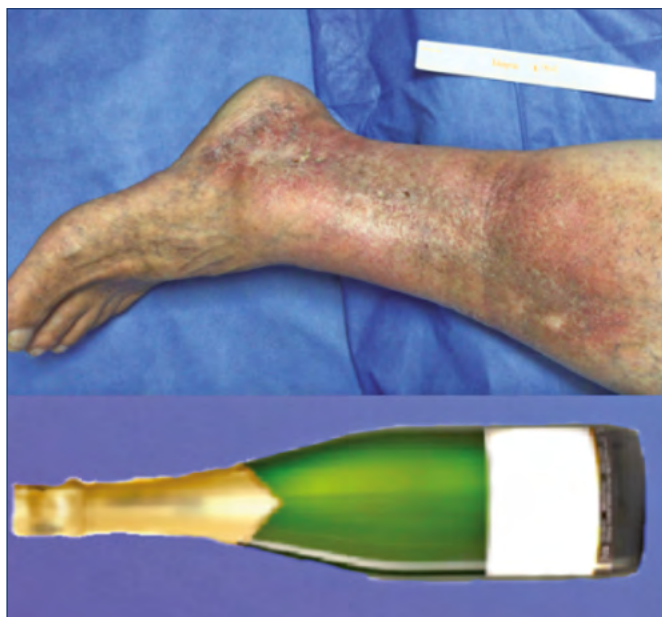

Figure 5. Inverted bottle sign.

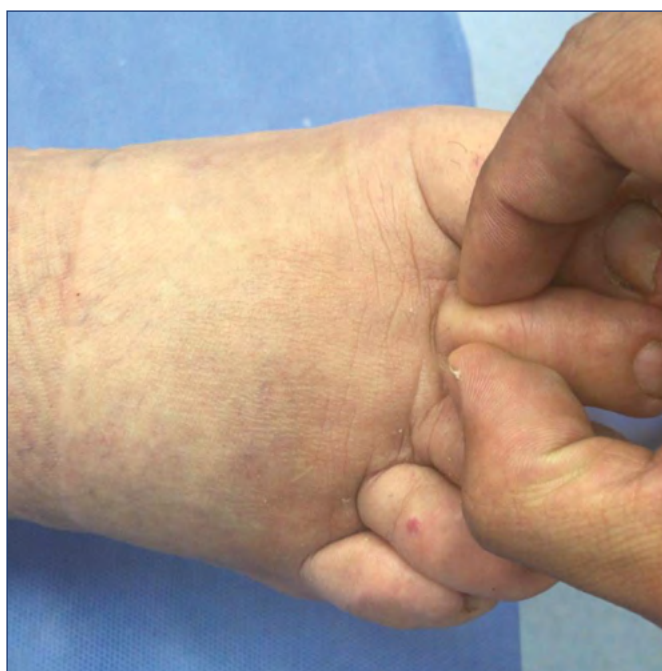

Figure 6. Kaposi-Stemmer sign. Skin of the patient's toes cannot be pinched due to the high protein accumulation.

Kaposi-Stemmer Sign

The Kaposi-Stemmer Sign is pathognomonic of lymphedema and occurs due to the high content of proteins in the interstitium, preventing fluid redistribution. It is positive when it is not possible to pinch the skin fold, typically in the second toe (Figure 6).

"Sausage Toes"

The dorsum of the foot is classically involved in lymphedema. Patients may develop large, swollen, sausage-appearing toes (Figure 7).

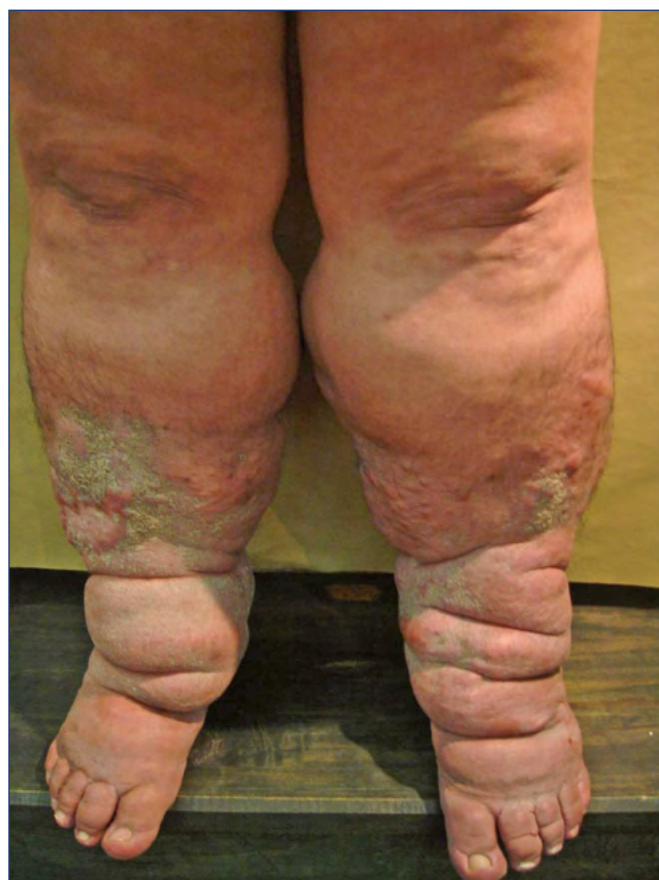

Figure 7. Sausage toes. Severe lipodermatosclerosis with papillomatosis.

Lymphedema rubra

Lymphedema rubra is caused by inflammatory hyperemia, given the proinflammatory changes from protein-rich fluid, and characterized by a blanching redness of affected skin that can mimic cellulitis.⁴ However, it has no signs of infection or response to antibiotics.

After the clinical assessment, the physician should identify modifiable risk factors that can contribute to the edema, like some systemic drugs (nonsteroidal anti-inflammatories,

antihypertensives, calcium channel blockers, beta blockers, clonidine, hydralazine, and corticosteroids among others), myxedema, nephrotic syndrome, congestive heart failure, cirrhosis, etc. Additionally, obesity should be treated because it increases abdominal venous pressure, transmitted to the lower-limb veins and worsening CVI.^{4,32}

Imaging tools can be used to confirm the disease and plan an efficient treatment. Duplex ultrasonography (DUS) is the test of choice to confirm CVI, identifying reflux and occlusions.³ In primary phlebolympheoedema, plethysmographic studies are required to identify the congenital venous malformations,³³ and computed tomography or magnetic resonance venography can be useful to identify iliofemoral occlusions. On the other hand, to assess lymphatic dysfunction, more options are available.

Lymphography

Lymphography consists of intradermally injecting a patent blue dye that outlines the superficial lymphatics for cannulation with a needle under an operating microscope and infusion of an oil-soluble iodinated contrast medium for visual lymphography.³⁴ Due to the technical difficulty and the morbidity associated with the contrast agent, the original technique is rarely used.¹⁷

Duplex ultrasound

DUS is a noninvasive, simple, and widely available tool. It provides indirect signs of severity of the affection based on the degree of thickness and echogenicity of the tissues, and information about the etiology of the edema characterizing the tissue layers (Figure 8).³⁵ It is useful to determine response

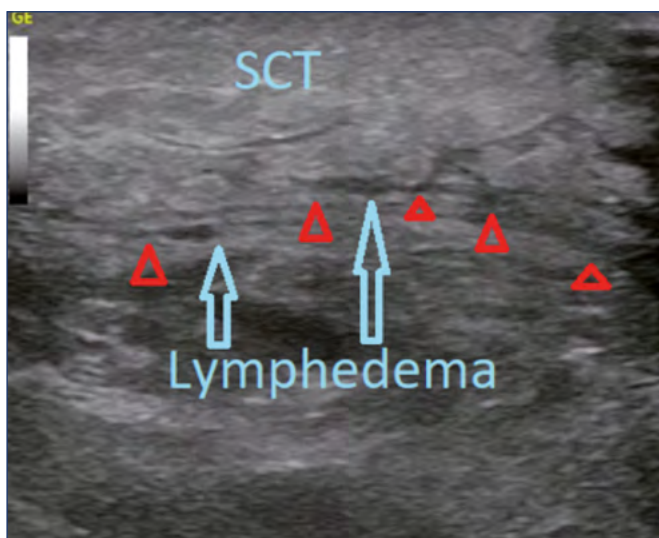


Figure 8. Lower-limb lymphedema Doppler ultrasound. Subcutaneous cellular tissue (SCT). Red triangles show the fascia, blue arrows show the areas with lymphedema.

to therapy by comparing the thickness of tissues before and after interventions. Unfortunately, there is a lack of studies comparing DUS to the gold-standard diagnostic test for lymphedema, lymphoscintigraphy (LSG).¹⁷

Lymphoscintigraphy

First described in 1953 by Sherman and Ter-Pogossian,³⁶ LSG is the examination of choice for functional assessment of lymphedema, as recommended by the American Venous Forum guidelines.¹⁷ However, the International Society of Lymphology Consensus emphasizes that the diagnosis of lymphedema is clinical, and LSG is only required when there is doubt about the lymphatic compromise.³⁷ It consists of intradermal injection of radionuclides in the interdigital space, with examination of the lymphatic transport of the labeled substance. LSG provides qualitative information like presence and caliber of the lymphatic vessels, lymph nodes, collateral networks, and delay in the radionuclide uptake,³⁸ and quantitative interpretation measures such as radionuclide transit and clearance time.

Despite the usefulness of this tool, there is no standardization for the type of radionuclide, dosage, and injection site, and it requires long waiting times.¹⁷ Also, LSG can be negative in early stages of the disease, and give false negative results in lymphedema with dynamic insufficiency (impaired fluid drainage due to exceeded lymphatics maximum transport capacity).⁴ LSG assesses the transport capacity of the vessels; in phlebolympheoedema, the whole lymphatic system is overwhelmed; therefore, the transport capacity will not be directly affected.³⁹

Computed tomography and magnetic resonance imaging

Providing direct and indirect signs of lymphatic dysfunction, computed tomography (CT) and magnetic resonance imaging (MRI) are useful for surveillance. Non-contrast MRI lymphography can identify the location of the edema, seen as subcutaneous soft tissue fibrosis and fluid accumulation, exhibiting a honeycomb distribution, pathognomonic of lymphedema.^{17,40} According to MRI lymphography findings, lymphedema can be classified as aplasia, hypoplasia, and hyperplasia.⁴⁰ Enlarged lymphatic nodules present in neoplasias are more precisely shown with MRI than with LSG.⁴¹

Newer lymphatic imaging modalities

The injection of fluorescent intradermal contrast agents is a radiation-free alternative to visualize the lymphatics. Fluorescein sodium (excited by visible light) and indocyanine green (ICG; excited by near-infrared fluorescence light [NIRF])

are commonly used contrast agents with immediate uptake.¹⁷ Visible light has a wavelength between 300 nm and 760 nm, being easily absorbed by primary tissue constituents, such as blood, water, and melanin, allowing visualization of subepidermal lymphatics in contexts such as microsurgery.^{42,43}

On the other hand, NIRF has a wavelength of 780 nm to 900 nm, penetrating about 3 cm under the tissues with no confounding autofluorescence. NIRF with ICG is useful in peripheral lymphatics with high and immediate sensitivity.⁴⁴ C5 and C6 patients typically exhibit a diffuse dermic reflux pattern in the distal portion of the affected limb, which correlates with the expected signs of CVI and not with the classic lymphedema. Probably, the deep lymphatic circulation

compensates the superficial lymphatic hypertension produced by venous hypertension. (Figure 9).

A normal NIRF image shows well-defined linear lymphatics, whereas, in disease, it exhibits tortuous and dilated lymphatics, dermal backflow, and extravasation (Figure 9A). NIRF also shows the lymphangion function; contractile frequencies of 0.4 ± 0.3 propulsions/min in legs of healthy adults are considered normal, whereas lymphedema shows contractile frequencies of 0.2 ± 0.2 propulsions/min in legs.⁴⁵

Treatment

There are no treatment guidelines or consensus for phlebolympheidema. If possible, the treatment should be etiology specific, eg, manual drainage, neutralization of proinflammatory cytokines, surgical restoration of the lymphatic drainage through lymphovenous anastomosis,¹⁷ or correction of a malformation.

In secondary phlebolympheidema, especially due to CVI, both problems have to be addressed. Treating one system prevents the other from continuing to fail. Occluded veins can be permeated; however, in postthrombotic syndrome, venous reflux without occlusion predominates. In this case, foam sclerotherapy or laser ablation of refluxing segments can be considered.³

Once the venous problem is treated, lymphedema must be handled, aiming to redistribute the proteins and the fluid to the proximal zones of the limb, where reabsorption can take place via the remaining functional lymphatics. The use of diuretics in these patients is contraindicated, as it increases the concentration of proteins and macromolecules in the interstitial space, producing more severe tissue damage.⁴ Furthermore, compression therapy is effective; however, it should not be used alone, as water removal will keep the proteins more concentrated and eventually increase water retention when the compression is released.⁴

Some specialists consider the standard of care to be complete decongestive therapy (CDT).¹⁶ CDT has an acute phase to reduce the lymphedema, and a lifelong maintenance phase to prevent recurrence.⁴ It is based on manual lymph drainage (MLD) by specialized therapists, with gentle limb massages that push the fluid to the competent lymphatic zones. This strategy should be accompanied by skin care and hydration to prevent infections, and careful ambulation to prevent contact lesions. Exercise programs and short-stretch compression bandaging should also be considered, ensuring low pressures in the limb

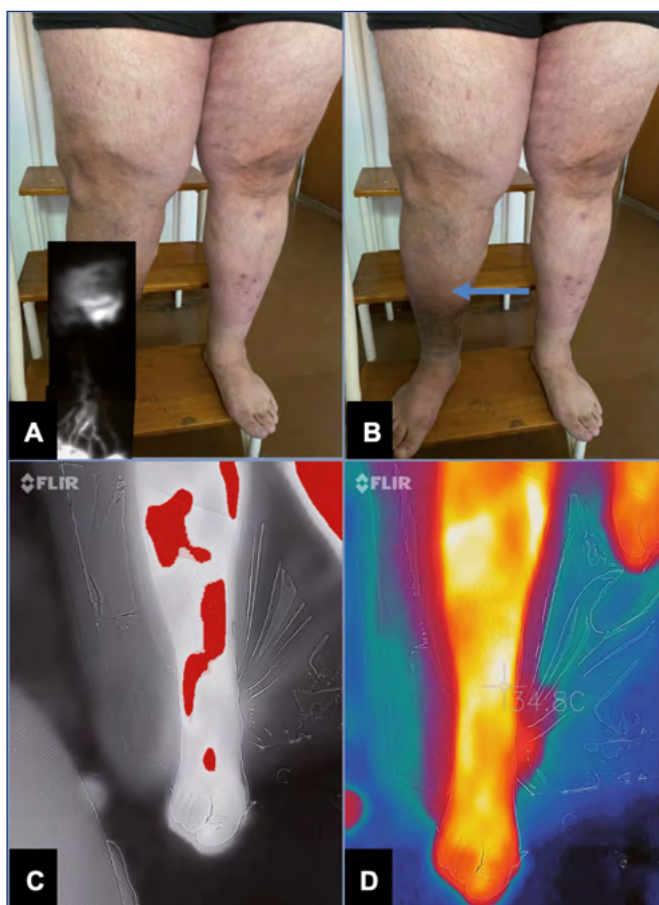


Figure 9. 48-year-old patient with chronic venous insufficiency (CVI).

A) Indocyanine green (ICG) fluorescence lymphography, which shows diffuse dermic reflux pattern in the zone labeled with the arrow in B with normal linear pattern in the distal portion.

B) No visible clinical signs of lymphedema, only trophic skin changes secondary to CVI.

C,D) Thermography of phlebolympheidema indicating greater inflammation in the zones of lymphatic damage, comparable with the findings of A.

while resting and high pressures as soon as the contraction begins.⁴ Due to high cost and low availability, MLD has been replaced with new treatment modalities such as pneumatic intermittent compression (PIC).

A study conducted in Poland in 2015 in phlebolymphe-
dema patients compared MLD performed in rehabilitation units versus PIC at home with 120 mm Hg for 45 minutes daily. Both interventions were applied for 4 weeks. The results showed that PIC was more effective, with marked diminishment of limb diameters and improved mobility.⁴⁶ Additionally, long-term safety and efficacy of PIC was evaluated in patients with chronic lymphedema who were treated for 3 years with an 8-chamber sleeve at 120 mm Hg of pressure applied 50 minutes per day. Results were satisfying and no complications, such as genital edema, were found.⁴⁷

PIC is effective, though whereas this type of compression is suitable for patients with a long history of phlebolymphe-
dema with high presence of fibrotic tissue, it is not as effective for those with a predominant vein component; such patients have better results with lower-pressure compression. Also, the adequate pressure remains to be established. A study in 2015 including 81 patients with phlebolymphe-
dema found that after 4 weeks, patients treated with multilayer bandaging combined with a pressure of 120 mm Hg showed significant improvement compared with patients that received bandaging alone or 60 mm Hg pressures.⁴⁸

Olszewski recommends pressures ranging from 80 to 150 mm Hg for 45 to 60 minutes per day,⁴⁹ because the physiologic hydrostatic lymphatic pressure in the lower limbs is near 12 mm Hg, and the pressure exerted externally toward the skin

Category	Drug	Effect on:					
		Venous tone	Venous wall and valve	Capillary leakage	Lymphatic drainage	Hemorheological disorders	Free radical scavengers
Flavonoids (gammabenzopyrones)	Micronized purified flavonoid fraction	+	+	+	+	+	+
	Nonmicronized or synthetic diosmins*						
	Rutin and rutosides, O-(β-hydroxyethyl)-rutosides (troxerutin, hydroxyethylrutoside)	+		+	+	+	+
	Anthocyanins (<i>Vitis vinifera</i>)						+
	Proanthocyanidins (<i>Vitis vinifera</i>)			+			+
Alphabenzopyrones	Coumarin			+	+		
Saponins	Horse chestnut seed extract; escin	+		+			+
	<i>Ruscus</i> extract	+	+	+	+	+	
Other plant extracts	<i>Ginkgo</i> extracts*						
Synthetic products	Calcium dobesilate	+		+	+	+	+
	Benzarone*						
	Nafazon*						

*No data available

Table I. Evidence-based modes of action of the main vasoactive drugs.

After reference 57: European Venous Forum, International Union of Angiology, Cardiovascular Disease Educational and Research Trust (UK), Union Internationale de Phlébologie; Nicolaides et al, eds. Management of chronic venous disorders of the lower limbs: guidelines according to scientific evidence. Part I. Int Angiol. 2018;37(3):181-254. Reprinted by permission of Edizioni Minerva Medica.

is 40 mm Hg. Only pressures greater than this value will be enough to stimulate lymph drainage. PIC significantly reduces the costs of treatment, occupational therapy, sequela, and the incidence of cellulitis in up to 75% of patients, as compared with conservative management and hospitalizations due to cellulitis.⁵⁰⁻⁵²

At the same time, studies have strongly demonstrated that patients with phlebolymphe'dema secondary to CVI may benefit from venoactive drug therapy (VAD). A number of VADs have been shown to increase lymphatic drainage in animal models (*Table 1*).⁵³⁻⁵⁷ Micronized purified flavonoid fraction (MPFF), an oral VAD (composed of 90% diosmin and 10% active flavonoids), is one of the drugs for which we have more evidence worldwide.

A pilot study on the evolution of microlymphatic parameters in patients with severe CVI showed an increase in the number of functional lymphatic capillaries and decrease in their diameter along with a decrease in endolymphatic pressures, which would improve microlymphatic drainage, after 4 weeks of treatment with MPFF. The benefit was maintained even 2 weeks after treatment was stopped.⁵⁸

More evidence that MPFF contributes to lymphatic drainage is found in its lymphagogue effect, increasing lymphatic flow, as demonstrated in a dose-dependent manner in thoracic duct fistula in mongrel dogs. Increased lymph flow was also described in the hind limb of ewes administered MPFF.^{53,59} Moreover, increased lymph flow could be attained by increasing pulsatility of the lymph vessels. MPFF was shown to increase the frequency of spontaneous isometric contractions of isolated rings of sheep mesenteric lymphatics,⁶⁰ and in isolated bovine lymphatic vessels as well in a concentration-related manner.⁵³

In CVI, venous hypertension triggers initial inflammation, with subsequent red-blood-cell extravasation and release of inflammatory mediators. MPFF works by decreasing the immune response to blood extravasation.⁶¹ There is some evidence that in an experimental inflammatory model in rat, MPFF reduces prostaglandin and thromboxane availability by inhibiting their synthesis. As these are involved in edema formation, this could contribute to a beneficial effect of MPFF on the formation of edema.⁵⁸ A study in hamsters with surgical vein ligation (simulation of DVT) and subsequent inflammatory response and microvascular changes showed significant decrease in leukocyte rolling and adherence and increased

venular diameter when treated with MPFF, as compared with the control group; indicating that MPFF could prevent CVI or slow the disease progression.⁶²

A small pilot study of 10 patients with secondary phlebolymphe'dema following breast cancer treatment demonstrated that with 6-months MPFF treatment, relative edema volume, compared to pretreatment measures, decreased continuously through the study and a decrease in intensity of skin hardness and heaviness were observed.⁶³ A larger controlled trial followed, including 104 women with upper limb lymphedema. In patients with more severe lymphedema, MPFF treatment significantly improved lymphatic migration speed over placebo and improved the half-life of the colloidal compound used as tracers in this procedure over time. Whereas the change in colloidal clearance over time approached significance in those treated with MPFF (and not in the placebo group), this larger study found no significant difference in evolution of lymphedema volume.^{64,65}

Recent evidence suggests that MPFF improves symptomatology with a single dose of 1000 mg daily or 500 mg twice daily after 2 weeks of treatment.^{66,67} This treatment led to recovery from up to 9 different leg symptoms, including swelling, cramps, pain, heaviness, and clinical signs of CVI. For instance, a recent observational study, The VEIN ACT Program (chronic VEIN disorders maNagement and evaluAtion of Chronic venous disease treatment effeCTiveness), included subjects with leg pain and at least one sign of CVI. Treatment with combined VAD, including MPFF, exhibited at least a 50% improvement in symptoms. Similarly, a study conducted in Russia, using only MPFF, evidenced up to a 50% decrease in symptom intensity and frequency, with 95% rate of patient satisfaction.⁶⁸ As well as that, MPFF demonstrated effectiveness in the early stages of the disease by lowering great saphenous vein (GSV) reflux, and it even led to elimination of evening GSV reflux in 76% of patients with C0s or C1s, appearing to be a promising drug.⁶⁹

Finally, the effectiveness of MPFF-based conservative treatment in patients with chronic venous edema (CVE) was assessed as part of a prospective observational program that evaluated the management of patients with CVE caused by the primary forms of CVD in real clinical practice in Russia with a mean study duration of 2.5 ± 0.5 months. MPFF-based conservative treatment, irrespective of addition of surgical intervention, was associated with a significant reduction in ankle volume in patients with CVD of CEAP class C3EpAsPr.⁷⁰

Conclusions

PIC has been shown to be effective, affordable, and reliable for patients with phlebolympheidema. It should be offered as the first-line treatment, together with management of reflux and/or occlusion, keeping in mind that proper pressure will determine the success of the intervention. In addition to a mechanical approach, VADs such as MPPF can help to reduce symptomatology while suggesting a potential prevention for the disease progression.

The treatment strategy should be individualized, keeping in mind special needs, comorbidities, and the etiology of the phlebolympheidema (venous or lymphatic) in each patient. Conservative management should be combined with PIC or VAD in order to achieve best results for the patients. However, there is a need for a consensus in order to create guidelines for physicians to choose the most effective and safe diagnostic and therapeutic management. Thus, more comparative studies on efficacy are needed from which to develop solid recommendations.



Corresponding author

Jorge Hernando ULLOA, MD, FACS,
Vascular Surgery Department,
Fundación Santa Fe de Bogotá,
Carrera 9 No. 116-20, Office 910. 110111,
Bogotá, Colombia.

Email: cirugiavasculard@yahoo.com



Corresponding author

Sebastian CIFUENTES, MD,
Vascular Surgery Department,
Av 7 No. 117-15 Fundación Santa Fe
de Bogotá.
Bogotá, Colombia.

Email: js.cifuentes12@uniandes.edu.co

REFERENCES

- Baethge C, Goldbeck-Wood S, Mertens S. SANRA- a Scale for the quality Assessment of Narrative Review Articles. *Res Integr Peer Rev.* 2019;4(1).
- Lee B. Phlebolympheidema is the ultimate comorbidity/outcome of lymphedema. *J Vasc Surg Venous Lymphat Disord.* 2019;7(5):731.
- Bunke N, Brown K, Bergan J. Phlebolympheidema: usually unrecognized, often poorly treated. *Perspect Vasc Surg Endovasc Ther.* 2009;21(2):65-68.
- Farrow W. Phlebolympheidema—a common underdiagnosed and undertreated problem in the wound care clinic. *J Am Col Certif Wound Spec.* 2010;2(1):14-23.
- Jawien A, Grzela T, Ochwat A. Prevalence of chronic venous insufficiency in men and women in Poland: multicentre cross-sectional study in 40,095 patients. *Phlebology.* 2003;18(3):110-122.
- Dean S, Valenti E, Hock K, Leffler J, Compston A, Abraham W. The clinical characteristics of lower extremity lymphedema in 440 patients. *J Vasc Surg Venous Lymphat Disord.* 2020;8(5):851-859.
- Lee BB, Andrade M, Antignani PL, et al; International Union of Phlebology. Diagnosis and treatment of primary lymphedema. Consensus document of the International Union of Phlebology (IUP)—2013. *Int Angiol.* 2013;32:541-574.
- Lee BB, Antignani PL, Baroncelli TA, et al. IUA- ISVI consensus for diagnosis guideline of chronic lymphedema of the limbs. *Int Angiol.* 2015;34:311-332.
- Szyber P, Szyber P. Lower limb lymphoedema – therapeutic problem. *Therapy.* 2008;2(1):70-72.
- Son A, O'Donnell T, Izhakoff J, Gaebler J, Niecko T, Iafrafi M. Lymphedema associated comorbidities and treatment gap. *J Vasc Surg Venous Lymphat Disord.* 2019;7(5):724-730.
- Dreyer G, Addiss D, Gadelha P, Lapa E, Williamson J, Dreyer A. Interdigital skin lesions of the lower limbs among patients with lymphoedema in an area endemic for bancroftian filariasis. *Trop Med Int Health.* 2006;11(9):1475-1481.
- Centers for Disease Control and Prevention. Parasites – lymphatic filariasis: epidemiology & risk factors. Updated March 5, 2019. Accessed May 20, 2020. Available from: <https://www.cdc.gov/parasites/lymphaticfilariasis/epi.html>
- Guyton AC. *Textbook of Medical Physiology.* 8th ed. Philadelphia, PA: WB Saunders; 1991.
- Földi M, Földi E, Kubik S. Deficiency and insufficiency of the lymphatic system. In: *Textbook of Lymphology for Physicians and Lymphedema Therapists.* Munich, Germany: Urban and Fisher; 2003:209-215.
- Földi E, Földi M. Chronic venous insufficiency and venous-lymphostatic insufficiency. In: *Földi's Textbook of Lymphology.* 2nd ed. Munich, Germany: Elsevier; 2006:434-447.
- O'Donnell T, Rasmussen J, Sevick-Muraca E. New diagnostic modalities in the evaluation of lymphedema. *J Vasc Surg Venous Lymphat Disord.* 2017;5(2):261-273.
- Ruocco E, Brunetti G, Brancaccio G, Lo Schiavo A. Phlebolympheidema: disregarded cause of immunocompromised district. *Clin Dermatol.* 2012;30(5):541-543.
- Ruocco V, Brunetti G, Puca RV, Ruocco E. The immunocompromised district: a unifying concept for lymphoedematous, herpes-infected and otherwise damaged sites. *J Eur Acad Dermatol Venereol.* 2009;23:1364-1373.
- Ruocco V, Ruocco E, Brunetti G, Sangiuliano S, Wolf R. Opportunistic localization of skin lesions on vulnerable areas. *Clin Dermatol.* 2011;29:483-488.
- Smith J, Mello LF, Nogueira Neto NC, et al. Malignancy in chronic ulcers and scars of the leg (Marjolin's ulcer): a study of 21 patients. *Skeletal Radiol.* 2001;30:331-337.

REFERENCES

21. Cendras J, Sparsa A, Bedane C, Delage M, Touati M, Bonnetblanc JM. Lymphome B primitif à grandes cellules CD20-, CD79a+ apparus sur un ulcère veineux chronique de jambe. *Ann Dermatol Venerol*. 2007;134:357-361.
22. Klippel M, Trenaunay J. Du noevus variqueux et osteohypertrophique. *Arch Gén Méd*. 1900;3:641-672.
23. Gloviczki P, Driscoll DJ. Klippel-Trenaunay syndrome: current management. *Phlebology*. 2007;22:291-298.
24. Vahidnezhad H, Youssefian L, Uitto J. Klippel-Trenaunay syndrome belongs to the *PIK3CA*-related overgrowth spectrum (PROS). *Exp Dermatol*. 2015;25(1):17-19.
25. Mirzaa G, Timms A, Conti V, et al. *PIK3CA*-associated developmental disorders exhibit distinct classes of mutations with variable expression and tissue distribution. *JCI Insight*. 2016;1(9):e87623.
26. Jones G, Mansour S. An approach to familial lymphoedema. *Clin Med (Lond)*. 2017;17(6):552-557.
27. Brodell JD, Brodell RT. Recurrent lymphangitic cellulitis syndrome. *Contemp Orthop*. 1992;25:461-468.
28. Szuba A, Razavi M, Rockson SG. Diagnosis and treatment of concomitant venous obstruction in patients with secondary lymphedema. *J Vasc Interv Radiol*. 2002;13(8):799-803.
29. Flugman SL, Clark RA. Stasis dermatitis. *Medscape*. Updated March 27, 2020. Accessed January 16, 2020. Available at: <http://emedicine.medscape.com/article/1084813-overview>
30. Falanga V, Moosa HH, Nemeth AJ, Alstadt SP, Eaglstein WH. Dermal pericapillary fibrin in venous disease and venous ulceration. *Arch Dermatol*. 1987;123(5):620-623.
31. Bruce AJ, Bennett DD, Lohse CM, Rooke TW, Davis MDP. Lipodermatosclerosis: review of cases evaluated at the Mayo Clinic. *J Am Acad Dermatol*. 2002;46(2):187-192.
32. Goldman MP. Lipodermatosclerosis: review of cases evaluated at the Mayo Clinic. *J Am Acad Dermatol*. 2002;46:187-192.
33. Weber J, Daffinger N. Congenital vascular malformations: the persistence of marginal and embryonal veins. *Vasa*. 2006;35:67-77.
34. Kinmonth JB. Lymphangiography in man; a method of outlining lymphatic trunks at operation. *Clin Sci*. 1952;11:13-20.
35. Suehiro K, Morikage N, Murakami M, Yamashita O, Samura M, Hamano K. Significance of ultrasound examination of skin and subcutaneous tissue in secondary lower extremity lymphedema. *Ann Vasc Dis*. 2013;6:180-188.
36. Sherman AI, Ter-Pogossian M. Lymph-node concentration of radioactive colloidal gold following interstitial injection. *Cancer*. 1953;6:1238-1240.
37. Executive Committee. The diagnosis and treatment of peripheral lymphedema: 2016 Consensus Document of the International Society of Lymphology. *Lymphology*. 2016;49(4):170-184.
38. Patel KM, Manrique O, Sosin M, Hashmi MA, Poysofion P, Henderson R. Lymphatic mapping and lymphedema surgery in the breast cancer patient. *Gland Surg*. 2015;4:244-256.
39. Mihara M, Hara H, Araki J, et al. Indocyanine green (ICG) lymphography is superior to lymphoscintigraphy for diagnostic imaging of early lymphedema of the upper limbs. *PLoS One*. 2012;7:e38182.
40. Arrivé L, Derhy S, El Mouhadi S, Monnier-Cholley L, Menu Y, Becker C. Noncontrast magnetic resonance lymphography. *J Reconstr Microsurg*. 2016;32(1):80-86.
41. Liu N, Zhang Y. Magnetic resonance lymphangiography for the study of lymphatic system in lymphedema. *J Reconstr Microsurg*. 2016;32:66-71.
42. Bollinger A, Jager K, Sgier F, Seglias J. Fluorescence microlymphography. *Circulation*. 1981;64:1195-1200.
43. Ayestary B, Bekara F. Fluorescein sodium fluorescence microscope-integrated lymphangiography for lymphatic supermicrosurgery. *Microsurgery*. 2015;35:407-410.
44. Sevick-Muraca EM, Kwon S, Rasmussen JC. Emerging lymphatic imaging technologies for mouse and man. *JCI*. 2014;124:905-914.
45. Rasmussen JC, Tan IC, Marshall MV, et al. Human lymphatic architecture and dynamic transport imaged using near-infrared fluorescence. *Transl Oncol*. 2010;3:362-372.
46. Śmitowska A, Skorupińska A, Gromek K. Does intermittent compression therapy in home care program more reduce phlebolympheoedema than manual lymph drainage applied in physical therapy outpatient unit? Practical reference guide for GPs. *Fam Med Prim*. 2015;3:219-224.
47. Zaleska M, Olszewski W, Durlik M. The effectiveness of intermittent pneumatic compression in long-term therapy of lymphedema of lower limbs. *Lymphat Res Biol*. 2014;12(2):103-109.
48. Dymarek R, Taradaj J, Rosinczuk J, Halski T, Schneider W. Comparison of efficacy of the intermittent pneumatic compression with a high- and low-pressure application in reducing the lower limbs phlebolympheoedema. *Ther Clin Risk Manag*. 2015;11:1545-1554.
49. Olszewski WL. The "third" circulation in human limbs tissue fluid, lymph and lymphatics. *Phlebologie*. 2012;41(6):297-303.
50. Lemman M, Gaebler J, Hoy S, et al. Health and economic benefits of advanced pneumatic compression devices in patients with phlebolympheoedema. *J Vasc Surg*. 2019;69(2):571-580.
51. Karaca-Mandic P, Hirsch A, Rockson S, Ridner S. The cutaneous, net clinical, and health economic benefits of advanced pneumatic compression devices in patients with lymphedema. *JAMA Dermatology*. 2015;151(11):1187.
52. Tay EY, Fook-Chong S, Oh CC, Thirumoorthy T, Pang SM, Lee HY. Cellulitis Recurrence Score: a tool for predicting recurrence of lower limb cellulitis. *J Am Acad Dermatol*. 2015;72(1):140-145.
53. Labrid C. A lymphatic function of Daflon 500 mg. *Int Angiol*. 1995;14(3 suppl 1):36-38.
54. Casley-Smith JR. Modern treatment of lymphoedema. II The bezopyrones. *Australas J Dermatol*. 1992;33(2):69-74.
55. Casley-Smith JR, Morgan RG, Piller NB. Treatment of lymphedema of the arms and legs with 5,6-benzo-+AFs-alpha+AFO-pyrone. *N Engl J Med*. 1993;329(16):1158-1163.
56. Piller NB. The lymphogogue action of calcium dobesilate on the flow of lymph from the thoracic duct of anesthetized and mobile guinea pigs. *Lymphology*. 1988;21(2):124-127.
57. European Venous Forum, International Union of Angiology, Cardiovascular Disease Educational and Research Trust (UK), Union Internationale de Phlébologie. Nicolaidis A, Kakkos S, Baekgaard N, et al, eds. Management of chronic venous disorders of the lower limbs: guidelines according to scientific evidence. Part I. *Int Angiol*. 2018;37(3):181-254.
58. Allegra C, Bartolo M Jr, Carioti B, Cassiani D, Besse Botti MG. Microlymphography: assessment of Daflon 500 mg activity in patients with chronic venous insufficiency. *Lymphology*. 1998;31(suppl):12-16.
59. Labrid C. Pharmacologic properties of Daflon 500 mg. *Angiology*. 1994;45(6 pt 2):524-530.
60. McHale NG, Hollywood MA. Control of lymphatic pumping: interest of Daflon 500 mg. *Phlebology*. 1994(suppl 1):23-25.
61. Ulloa J. Micronized purified flavonoid fraction (MPFF) for patients suffering from chronic venous disease: a review of new evidence. *Adv Ther*. 2019;36(S1):20-25.

REFERENCES

62. das Graças C, de Souza M, Cyrino FZ, Carvalho JJ, Blanc-Guillemaud V, Bouskela E. Protective effects of micronized purified flavonoid fraction (MPFF) on a novel experimental model of chronic venous hypertension. *Eur J Vasc Endovasc Surg.* 2018;55(5):694-702.
63. Pecking AP. Evaluation by lymphoscintigraphy of the effect of a micronized flavonoid fraction (Daflon 500 mg*) in the treatment of upper limb lymphedema. *Int Angiol.* 1995;14(3 suppl 1):39-43.
64. Pecking AP, Février B, Wargon C, Pillion G. Efficacy of Daflon 500 mg in the treatment of lymphedema (secondary to conventional therapy of breast cancer). *Angiology.* 1997;48(1):93-98.
65. Pecking AP, Floiras JL, Rambert P, et al. Effect of Daflon 500 mg on lymphedema secondary to breast cancer treatment. *Lymphology.* 1998;31(suppl):25-28.
66. Kirienco A, Radak D. Clinical acceptability study of once-daily versus twice-daily micronized purified flavonoid fraction in patients with symptomatic chronic venous disease: a randomized controlled trial. *Int Angiol.* 2016;35(4):399-405.
67. Carpentier P, van Bellen B, Karetova D, et al. Clinical efficacy and safety of a new 1000-mg suspension versus twice-daily 500-mg tablets of MPFF in patients with symptomatic chronic venous disorders: a randomized controlled trial. *Int Angiol.* 2017;36(5):402-409.
68. Lishkov DE, Kirienco AI, Larionov AA, Chernookov AI. Patients seeking treatment for chronic venous disorders: Russian results from the VEIN Act program. *Phlebology.* 2016;23(1):44.
69. Tsukanov YT, Tsukanov AY. Diagnosis and treatment of situational great saphenous vein reflux in daily medical practice. *Phlebology.* 2017;24(3):144-151.
70. Bogachev V. Effectiveness of MPFF-based conservative treatment in chronic venous edema. *Phlebology.* 2020;27(2):70-80.



The transosseous perforator veins of the knee

Jean-François UHL,¹ MD;
Marios VALSAMIS,² MD;
Claude GILLOT,³ MD

¹Research Director, UNESCO Chair of Digital Anatomy – Paris University, Paris, France

²Phlebologist & Surgeon (private practice), Athens, Greece

³Laboratory of Anatomy – Paris University, Paris, France

Abstract

The perforator veins (PVs) of the knee can be responsible for reticular veins, telangiectases, and varicosities around the knee, but they are frequently underdiagnosed and missed by the phlebologists and the sonographers because of their tiny size. These PVs are frequently located around the patella and connected with transosseous perforators, well-demonstrated in the anatomical part of this work. This could explain why sclerotherapy of cosmetic lesions around the knee frequently leads to poor results and recurrence. This article proposes a systematization of these atypical PVs and discusses their possible role in phleboarthrosis.

Introduction

The anatomical part of this work constitutes the last work carried out with Professor Claude Gillot who passed away in his 92nd year. Thus, in a way, this article is a tribute to his talent as an anatomist, his sagacity as a researcher, and his outstanding qualities as a teacher.

Keywords:

anatomy; chronic venous insufficiency; color duplex; CT venography; perforating veins; phleboarthrosis; osteoarthrosis; transosseous perforators; venous disease.

In fact, while studying anatomical sections that he had prepared more than 20 years ago, he discovered the bone perforators of the knee. "In anatomy, the most difficult task is to see what is happening below your own eyes," he liked to repeat. It was through noting the presence of green latex inside the spongy bone of the knee that Claude Gillot discovered these tiny perforating veins that perforate the cortex of the tibia and the femur.

Background

In the knee, the spongy bone of the tibial and femoral epiphyses is an important source of production of red blood cells, even more so than the lumbar spine. The red cells produced there go on to join the venous network. They do so via the femoropopliteal venous axis through small veins that perforate the cortical bone. The deep, unusual location of these veins and their tiny size explain why they are often unrecognized and missed by the sonographers during color duplex investigations.

Materials and methods

This anatomical study is based on 40 series of layered anatomical sections of the lower limbs prepared 20 years ago. These are axial sections of the lower limbs taken every 0.5 cm, work carried out in the anatomy laboratory of the Faculty of Medicine at Descartes University.

Before sections were taken, the venous system of the limb was washed and injected with latex preparations. Veins were injected with green latex and arteries with red latex. More

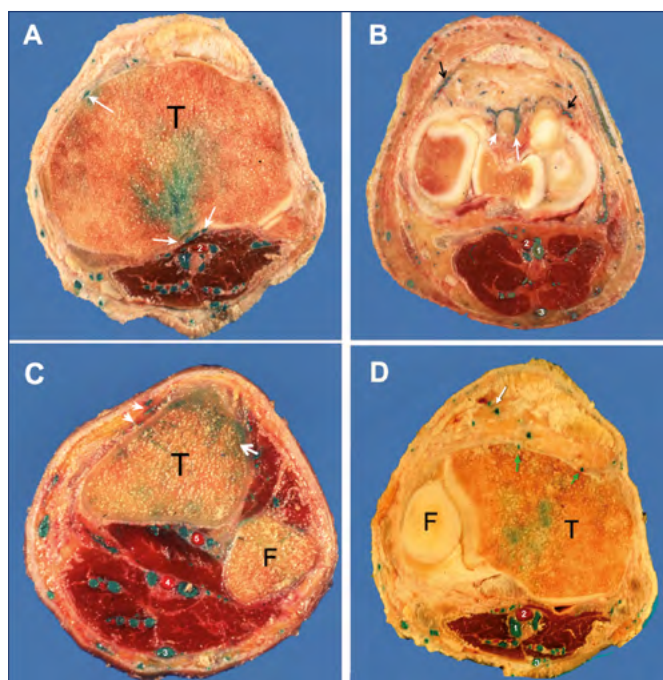


Figure 1. Transosseous perforator veins (PVs) of the knee.

Axial sections obtained after latex injection of the limb. Sections were made at the level of the tibial tuberosity (A), lower condyles (B), and upper leg just below the knee joint (C-D).

A) The green latex has reached the spongy bone. Posterior transosseous PVs perforate the cortical line of the tibia (white arrows).

B) Transfascial PVs are visible anteriorly, indicated by black arrows. Additional trans-synovial perforators are visible, passing between the tibial condyles (white arrows).

C) At the level of the tibial tuberosity, the anterior transosseous PVs (white arrows) drain into the cancellous bone.

D) Small transfascial PVs are visible anteriorly, lateral to the rotulian tendon (white arrow); a small TOPK is shown with a hole in the cortical bone of the tibial tuberosity (green arrows).

Abbreviations: 1, popliteal vein (green circle); 2, popliteal artery (red circle); 3, small saphenous vein; 4, posterior tibial artery surrounded by its two veins; 5, anterior tibial artery surrounded by its two veins; T, tibia bone; F, fibula.

From the collection of Professor C. Gillot.

information about this technique is available in the *Atlas of Venous Anatomy*.¹

In addition to the study of those sections, color duplex investigation was carried out before treatment in about 25 000 patients with varicose veins. Preoperative investigation was carried out via computed tomographic (CT)-venography²⁻⁴ in about 1200 venous patients and magnetic resonance (MR) angiography in a few.

Results of our anatomical study

According to our anatomical documents,⁵ the transosseous PVs of the knee (TOPKs) can be categorized into two subgroups: (i) anterior, around the patella (Figure 1 A-C); and (ii) posterior, in the condylar groove and deep popliteal fossa (Figure 2).

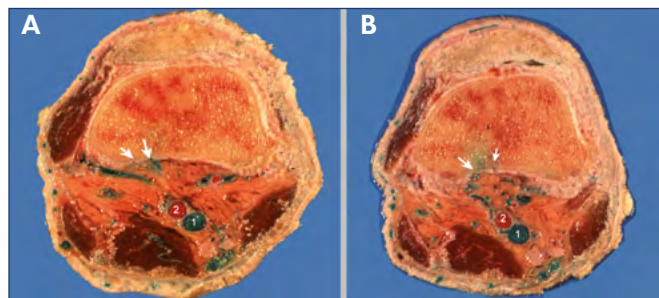


Figure 2. Transosseous perforator veins (PVs) of the high popliteal fossa.

Axial anatomical sections of the lower femur obtained above the knee joint after latex injection of the limb.

The white arrows show the holes of the cortical bone and the posterior perforators joining the spongy bone. They gather at the popliteal fossa, then bypass the popliteal artery (2) to connect the popliteal vein (1). No perforator is seen at the anterior aspect of the knee.

From the collection of Professor C. Gillot.

The first connects to the peripatellar superficial reticular venous network and to the lateral faces of the knee. The second group of perforators crosses the intercondylar space and the deep popliteal fossa bypassing the two sides of the popliteal artery to join the popliteal vein.

Clinical presentations

Reticular venous networks and varicose veins around the knee are quite common in clinical practice. They are usually located anteriorly, around and below the patella (Figures 3-4), connected with a varicose network of the anteromedial and lateral aspects of the upper leg.

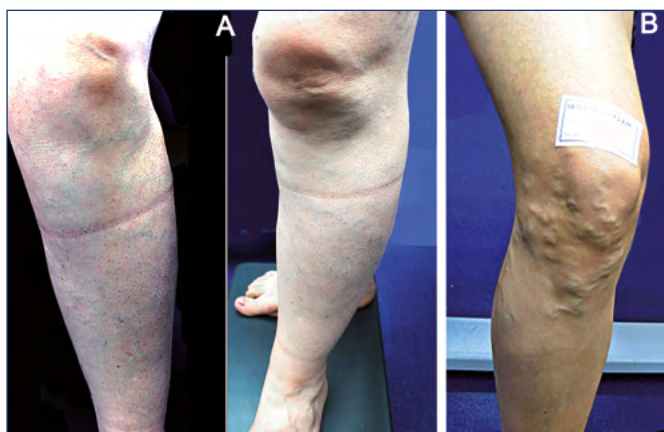


Figure 3. Clinical presentations.

A) Clinical case 1: reticular vein network of the anterolateral aspect of the knee and upper leg.

B) Clinical case 2: varicose vein network of the anterior knee below the patella.

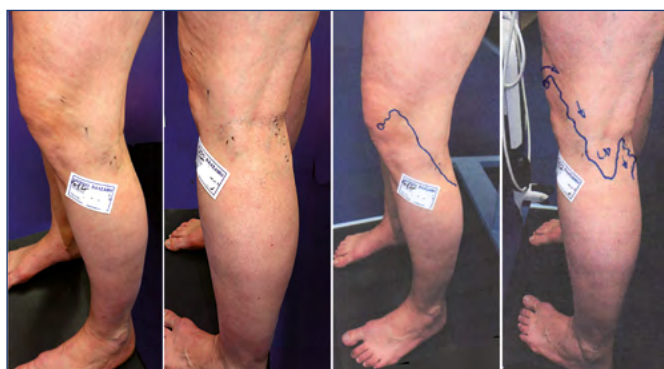

Figure 4. Clinical case 3: popliteal varix fed by a suprapatellar perforator vein.

Skin mapping is shown on the right.

Telangiectases of the medial or lateral aspect of the knee and lower thigh are also very common in chronic venous disease (CVD) patients (Figure 5).

Color duplex assessment

The PVs can be seen on ultrasound surrounding the patella. They are difficult to detect because of their small caliber. They are connected to the superficial reticular network, then perforate the fascia and the aponeurosis around the patella (Figures 6-8). Although no direct image of their transosseous connection is seen in the case reports, we know such PVs exist within the anterior tuberosity of the tibia (Figure 1A,C) and within the intercondylar groove (Figure 1B).

CT-venography

CT-venography with 3D reconstruction by volumetric rendering technique (VRT) is useful for obtaining a complete 3D map of

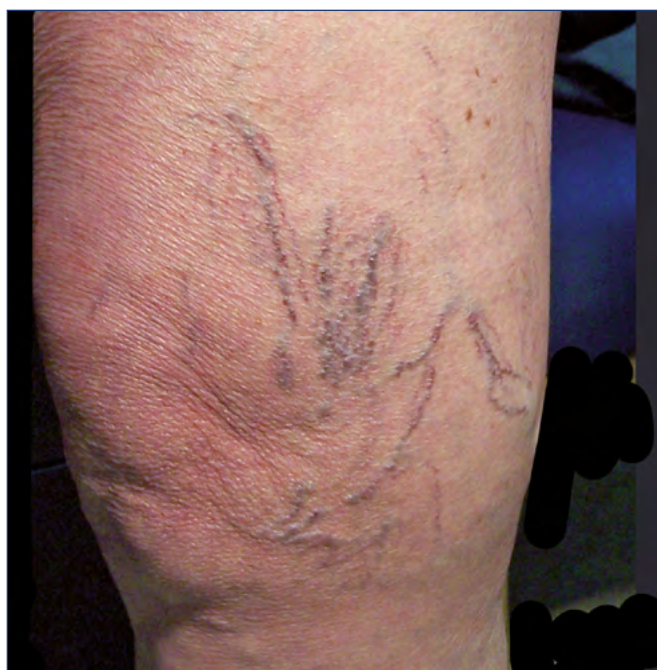

Figure 5. Telangiectases of the medial aspect of the knee.

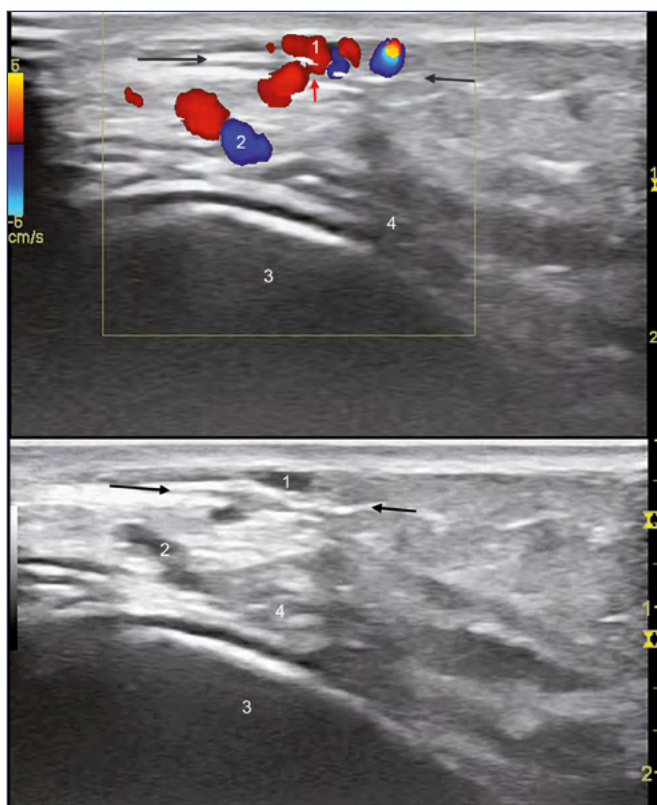


Figure 6. Color duplex assessment of case 2.

The superficial reflux (1) is fed by a perforator vein (PV, red arrow) perforating the fascia (black arrows).

The subfascial refluxing network (2) is close to the bone periosteum (4,) not injected here.

1, superficial network refluxing; 2, subfascial veins; 3, bone.

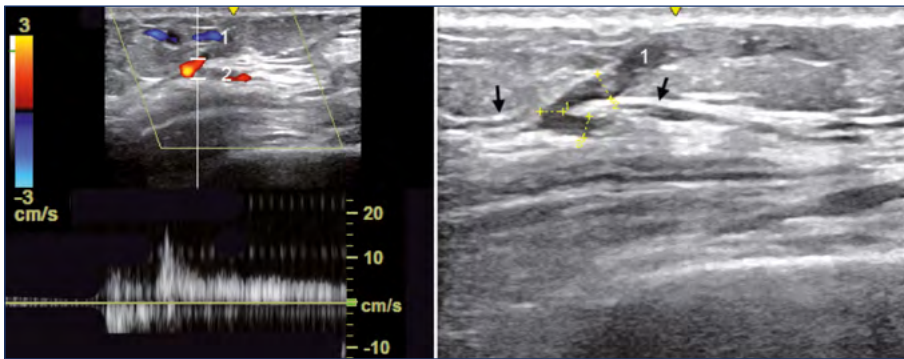


Figure 7. Color duplex assessment of case 3.

Perforator vein (PV) located at the lateral aspect of the patella.

The superficial reflux (1) is fed by a PV (red colored) perforating the fascia (black arrows). The subfascial refluxing network (2).

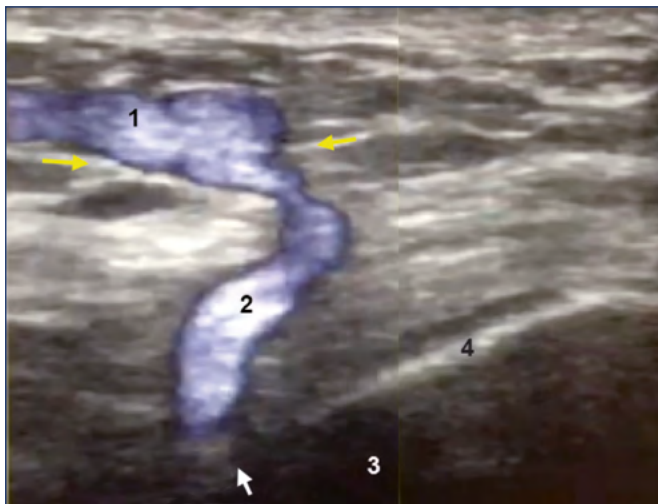

Figure 8. Color duplex assessment of a tibial transosseous perforator vein of the knee.

Ultrasound showing a transosseous perforating vein of the anterior knee. The superficial reflux (1) is fed by a PV (2) perforating the fascia (yellow arrows) and then the cortical bone (4) at the level of the white arrow.

3, tibia bone.

Image courtesy of V. Crebassa, MD.

the venous network. The TOPKs are especially visible around the patella (Figure 9).

MR-Angiography

MR angiography investigation is a good method to obtain more anatomical details about the posterior TOPK and around the patella (Figures 10-11). It is also useful for investigating knee arthrosis, frequently associated with severe chronic venous insufficiency (CVI), which will be touched on later in the Discussion.

In many cases, TOPK are an excellent explanation for the difficulty with telangiectasia sclerosis of the knee region and their high recurrence rate. Thus, they should be carefully considered when targeting treatment, as they are often the

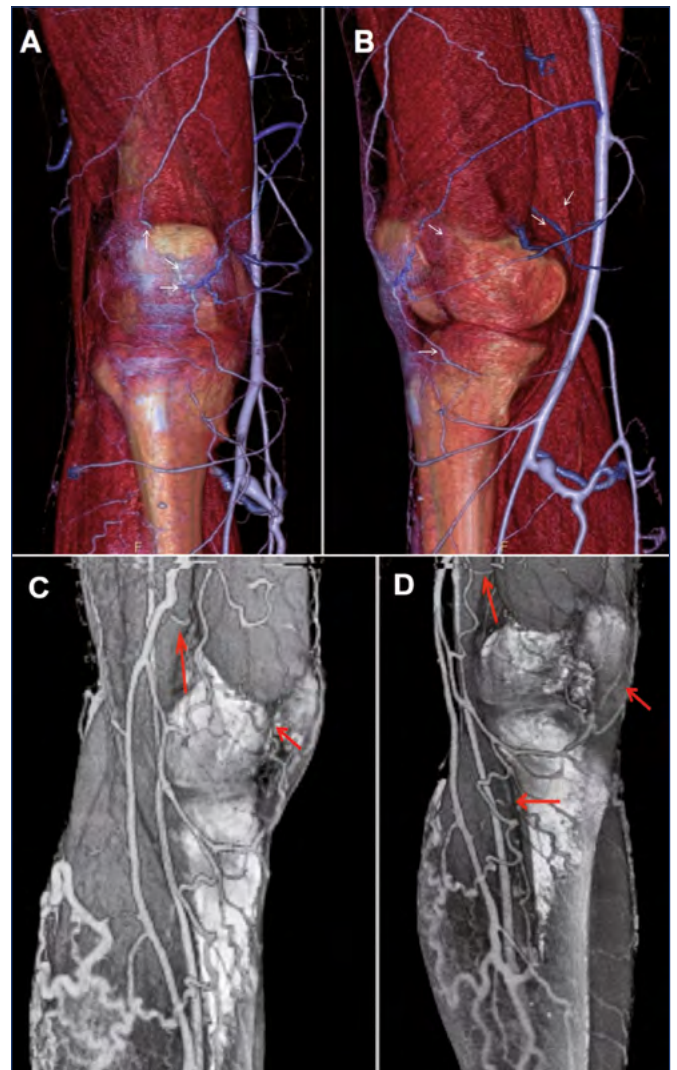


Figure 9. Transosseous perforator veins of the knee surrounding the knee. Three-dimensional reconstruction from veno-computed tomography (CT) by volume rendering (VRT).

A,B) The white arrows show small perforator veins of the knee surrounding the patella connected to the tributaries of the great saphenous vein.

C,D) The red arrows show small tributaries around the knee, mainly at the medial aspect.

Courtesy of Professor J. Ovelar and J. Merino - CIMED - La Plata, Argentina.

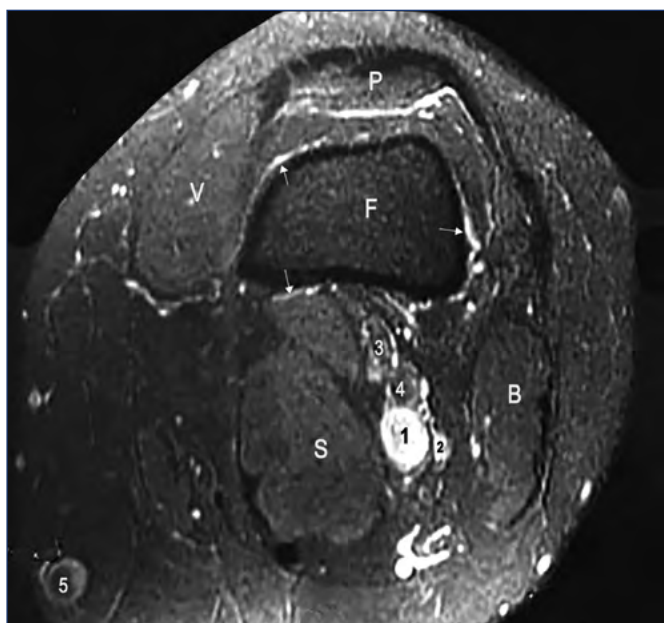


Figure 10. Axial angioMR, slice at the patella level. No PV is shown through the cortical bone, but we see a venous network surrounding the bone (arrows), connected to the superficial network. 1, popliteal vein; 2, collateral canal; 3, tibial nerve; 4, fibular nerve; 5, great saphenous vein; F, femur; P, patella; V, vastus medialis; B, biceps; S, semimembranosus.

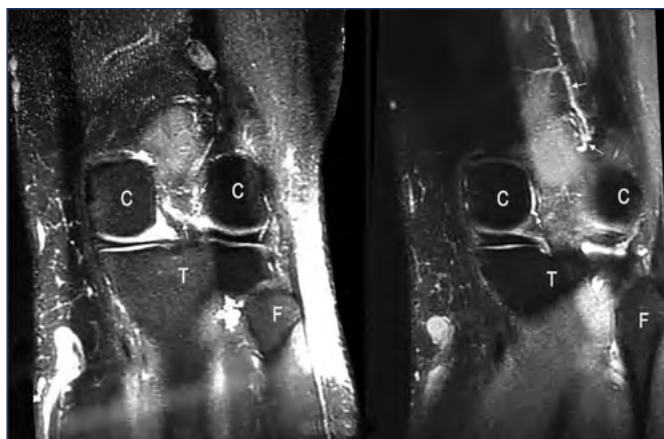


Figure 11. Coronal angioMR: slice taken at the condyles level. Venous network located in the intercondylar groove (arrows). Abbreviations: C, femoral condyles, T, tibia; F, fibula head.

source of reflux responsible for telangiectasias and reticular veins around the knee.

Differential diagnosis

These TOPK must be distinguished from the rare and large transosseous perforators of the tibial diaphysis, which can feed anterior varicose veins of the leg, described by Ramelet et al⁶

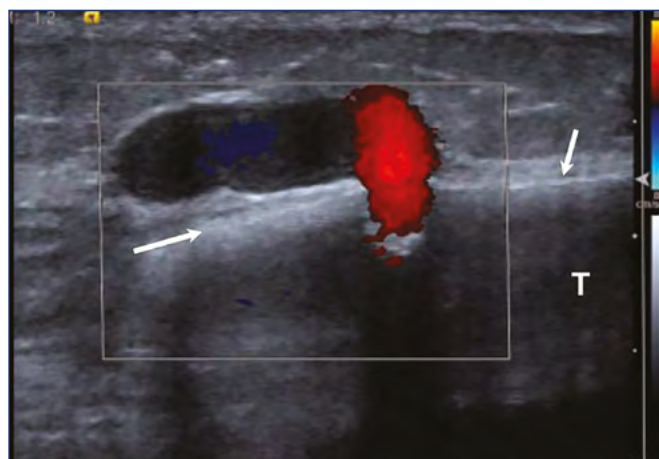


Figure 12. PV of the tibial diaphysis (Color Duplex). Arrows indicate cortical bone. Abbreviation: T, tibia bone.

(Figure 12). These are located in the middle part of the tibia; note the bony hole of the perforator visible on a standard x-ray of the tibia, as well as by duplex ultrasound investigation.

Discussion

The close relationship between severe CVI and knee arthrosis was emphasized many years ago by several German authors⁷⁻¹⁹ and described as “Das arthrogene Stauungssyndrom” and called “phlebo-arthrosic syndrome” or “phleboarthrosis.” These features could also be linked to regional dermato-lipo-fasciosclerosis observed in the framework of severe CVI. Conversely, gonarthrosis²⁰ is a cause of impairment of joint mobility and thus of the venomuscular pumps, worsening CVI.

The case-control study of Mazieres²¹ reported an 18% to 64% prevalence of varicose veins in gonarthrosis patients and a 12% to 68% prevalence of gonarthrosis in varicose vein patients. The simultaneous existence of such arthrosis and varices in the same lower limb has also been reported in 48%, by Gies,²² and 20% by Robecchi.¹²

More evidence of the role of venous stasis in lower limb arthrosis is brought by several case reports of improvement of the inflammatory component of osteoarthritis of the knee,^{18-20,23-38} hip,^{39,40} or ankle after treatment of varicose veins. The recent study by Varghese et al⁴¹ also brings new perspective to the understanding of the pathophysiology of osteoarthritis, for which venous stasis is an underlying cause.

Clinical diagnosis of phleboarthrosis is the most important aspect in planning the treatment protocol. Once the venous reflux is treated, knee joint inflammation shifts toward normality. Pain decreases noticeably and arthrosis begins to calm. The orthopedic surgeon can enhance this healing by conservative measures. In this study, over a period of 6 months, all patients improved and were able to resume normal activities despite long-term history of osteoarthritis.

We hypothesize that the TOPK play an important role in this "phlebo-arthrosic syndrome" by transmitting venous hypertension to the knee joint structures. So, general practitioners and phlebologists should take into account the role played by CVI in the genesis of knee osteoarthritis: these small TOPKs probably play a role in the "phleboarthrosis" described in the literature. In fact, poor nourishment of the bone marrow and every structure around the knee joint occurs when there is venous hypertension and stasis related to severe CVI. Conversely, osteoarthritis of the knee or ankle limits movement and impedes walking, and thus could be responsible for impairment of venous pumps, worsening CVI. In practice, more practitioners should be aware of this frequent cause of osteoarthritis.

In patients suffering from disabling knee arthritis associated with severe venous insufficiency of varicose origin, the varicose veins should be treated first, before proposing surgery of the knee. In most cases, the inflammatory component of the knee arthritis will improve significantly, and the surgery can be postponed.

Conclusion

Phlebologists should be aware of the existence of PVs of the knee, mainly around the patella, in order to target sclerotherapy of telangiectasias and reticular veins under echoguidance.

They should also keep in mind that these subfascial PVs are frequently fed by transosseous PVs, even if they cannot be seen easily with duplex color imaging.

Echoguided elective treatment of the knee PVs by foam sclerotherapy works well. This should improve cosmetic results and avoid recurrence, too frequent in this area.

Moreover, regarding phleboarthrosis, it's important that phlebologists and rheumatologists be aware that severe CVI is a common cause of osteoarthritis of the knee and ankle and that they should, therefore, be treated in priority, before the treatment of arthrosis.



Corresponding author

Jean-François UHL,
Descartes University,
45 rue des saints Pères,
75006 - Paris

Email: jeanfrancois.uhl@gmail.com

REFERENCES

- Uhl JF *Atlas anatomique du système veineux*. 2020. Book available from Uhl JF: jeanfrancois.uhl@gmail.com.
- Uhl JF. Three-dimensional modeling of the venous system by direct multislice helical CT venography: technique, indications and results. *Phlebology*. 2012;27:270-288.
- Uhl JF, Caggiati A. Three-dimensional evaluation of the venous system in varicose limbs by multidetector spiral CT. In: Catalano C, Pasariello R, eds. *Multidetector-Row CT Angiography. Medical Radiology (Diagnostic Imaging)*. Springer, Berlin, Heidelberg. Available at: https://doi.org/10.1007/3-540-26984-3_15.
- Uhl JF, Verdeille S, Martin-Bouyer Y. Three-dimensional spiral CT venography for the pre-operative assessment of varicose patients. *VASA*. 2003;32:91-94.
- Gillot C, Uhl JF, Ovelar J, Merino J. Anatomy of the bony perforators veins of the knee. *Ann Med*. 2019;51(suppl 1):60-60. doi:10.1080/07853890.2018.1561943.
- Ramelet AA, Crebassa V, Alotto CD, et al. Anomalous intraosseous venous drainage: bone perforators? *Phlebology*. 2016;32(4):241-248.
- Adler VG. Diagnosis and treatment of phlebo-arthrotic syndrome. *Med Klin*. 1956;51(34):1407-1409.
- Annas T. The phlebo-arthrotic syndrome in orthopedics (in German). *Med Welt*. 1980;31(14):523-524.
- Hach W, Langer C. Schirmers u das arthrogene stauungssyndrom. *VASA*. 1983;12:109-115.
- Hach W. Das arthrogene stauungssyndrom. *Gebässchirurgie*. 2003;8:227-233.
- Hach W. *VenenChirurgie*. 2nd ed. Schattauer, Germany: Stuttgart; 2006;304-306.
- Robecchi A, Einaudi A, Impallomeni G. Osservazioni e ricerche sui fattori eziopatogenetici dell'artrosi del ginocchio, con particolare riguardo ai disturbi della circolazione venosa. *Minerva Med*. 1952;43(101):1366-1376.
- Krieg E. The phlebo-arthrotic complex. *Med Welt*. 1970;42:1832-1834.
- Giovanni B, Agus MA. Phleboarthrosis. *Acta Phlebologica*. 2017;18(3):63-64.

REFERENCES

15. Schmeller W. *Das Arthrogene Stauungssyndrom. Sprunggelenksveränderungen bei Chronischer Veneninsuffizienz*. Berlin, Germany: Diesbach Verlag; 1990.
16. Noppeney T, Nüllen H. Arthrogenes stauungssyndrom. In: Noppeney T, Nüllen H, eds. *Diagnostik und Therapie der Varikose*. Heidelberg, Germany: Springer Medizin Verlag; 2010;S 213-214.
17. Frenzel A, Hamper C, Kahle B, et al. Das arthrogene stauungssyndrom. *Phlebologie*. 2015;44:215-217.
18. Arnoldi CC. Vascular aspects of degenerative joint disorders a synthesis. *Acta Orthop Scand*. 1994;65(suppl 261):3-82. doi:10.3109/17453679409155226.
19. Marshall M. *Praktische Phlebologie "Phlebarthrotischer Symptomenkomplex"*. Springer-Verlag; 1987:81. doi:10.1007/978-3-642-70468.
20. Kugler C, Strunk M, Rudofsky G. Effect of impaired joint mobility on venous pump function of the healthy lower limb, a phlebodynamic analysis. *Phlebologie*. 1999;28(1):16-22.
21. Mazieres B, Andrieu S, Subreville C, et al. Knee osteoarthritis and varicose veins: a case-control study of 600 patients. *Ann Rheum Dis*. 2001;60:A175-A176.
22. Gies J, Maugeis De Bourguesdon J. Value of the presentday treatments of gonarthrosis [in French]. *Rev Rhum Mal Osteoartic*. 1961;28:255-258.
23. Imhof H, Breitenseher M, Kainberger F, Trattig S. Degenerative joint disease: cartilage or vascular disease? *Skeletal Radiol*. 1997;26(7):398-403. doi:10.1007/s002560050254. PMID: 9259096.
24. Lejoyeux R. Study of a case of phleboarthritis. Treatment with strapping and sclerosing injections [in French]. *Phlebologie*. 1972;25(1):35-37.
25. Doerler M, Altmeyer P, Stücker M. Venous leg ulcer caused by obesity-associated dependency syndrome Case report and discussion of the pathogenesis and treatment. *Phlebologie*. 2013;42:205-208.
26. Lentner A. Beweglichkeit im oberen und unteren Sprunggelenk bei fortgeschrittener chronischer veneninsuffizienz. *Phlebologie*. 1994;23:149-155.
27. Ludwig M, Rieger J, Ruppert V. *Gefäßmedizin in Klinik und Praxis - Leitlinienorientierte Angiologie, Gefäßchirurgie und interventionelle Radiologie*. 2nd edition. Stuttgart, Germany: Thieme; 2010:283-284.
28. Uhl JF, Chakim M, Allaert FA. Static foot disorders: a major risk factor for chronic venous disease? *Phlebologie*. 2012;27:13-18.
29. Lesnyak OM, Zubareva EV, Goncharova MG, Maksimov DM. Lower extremity venous diseases in primary knee osteoarthritis [in Russian]. *Ter Arkh*. 2017;89(5):53.
30. Arnoldi CC, Lempert K, Linderholm H. Intraosseous hypertension and pain in the knee. *J Bone Joint Surg Br*. 1975;57(3):360-363.
31. Rabe E, Berboth G, Pannier F. Epidemiology of chronic venous diseases [in German]. *Wien Med Wochenschr*. 2016;166(9-10):260-263. doi:10.1007/s10354-016-0465-y.
32. Helal B. The pain in primary osteoarthritis of the knee. Its causes and treatment by osteotomy. *Postgrad Med J*. 1965;41(474):172-181. doi:10.1136/pgmj.41.474.172.
33. Dodd H, Cockett FB. *The Pathology and Surgery of Veins of the Lower Limb*. London, UK. E. & S. Livingstone; 1956.
34. Ciubotaru V. Phlebogonarthrosis: a clinical and physiopathological reality. *Phlebology*. 2018;25(1):1-120.
35. Findlay DM. Vascular pathology and osteoarthritis. *Rheumatology*. 2007;46(12):1763-1768. https://doi.org/10.1093/rheumatology/kem191.
36. Bernstein MA. Experimental production of arthritis by artificially produced passive congestion. *J Bone Jt Surg*. 1933;15:661.
37. Ageeva AI, Kulikov AG, Volovets SA, Gerasimenko MY, Yarustovskahya OV. Gonarthrosis concurrent with chronic venous insufficiency: a new look at therapy [in Russian]. *Vopr Kurortol Fizioter Lech Fiz Kult*. 2019;96(5):29.
38. Reinhartz D. Effect of chronic venous insufficiency in gonarthrosis [in French]. *Phlebologie*. 1981;34(1):187.
39. Pedersen NW, Kiaer T, Kristensen KD, Starklint H. Intraosseous pressure, oxygenation, and histology in arthritis and osteonecrosis of the hip. *Acta Orthop Scand*. 1989;60(4):415-417. doi:10.3109/17453678909149309.
40. Arnoldi CC, Linderholm H, Müssbichler H. Venous engorgement and intraosseous hypertension in osteoarthritis of the hip. *J Bone Joint Surg Br*. 1972;54(3):409-421.
41. Varghese R, Patel M, Rajarshi M. Association of chronic venous disease and arthrosis of the lower limbs. Clinic-based Indian experience of phleboarthritis and treatment protocol. *Circulation*. 2021. In press.



VEIN STEP: Chronic Venous Disorders Management and Treatment Effectiveness Evaluation in Chronic Venous Disease, an International Observational Prospective Study. Results from Morocco

Tazi Mezalek ZOUBIDA, MD^{1,2}
 Jorge Hernando ULLOA, MD,
 FACS³

¹Faculty of Medicine and Pharmacy,
 Mohammed V University, Rabat, Morocco;

²Clinical Hematology Department, Ibn
 Sina University Hospital, Rabat, Morocco;

³Fundacion Santa Fe de Bogota, Bogota,
 Colombia

Keywords:

MPFF; quality of life; venoactive drugs;
 VEIN ACT; VEIN Consult; VEIN STEP

Abstract

Aim: VEIN STEP is an international, observational, prospective study assessing the effectiveness of conservative treatments for the relief of chronic venous disease (CVD) symptoms and their impact on quality of life (QOL). This article presents results collected in Moroccan patients. **Method:** Adult outpatients consulting for symptomatic CVD were categorized via the Clinical, Etiological, Anatomical, Pathophysiological (CEAP) classification system. Intensity of symptoms and their improvement with treatment was assessed using both patient-reported (10-cm Visual Analog Scale [VAS], Patient Global Impression of Change [PGIC], and 14-item Chronic Venous Insufficiency Questionnaire [CMIQ-14]) and physician-reported outcomes (Venous Clinical Severity Score [VCSS]) on the first day of enrollment and after 4 weeks. **Results:** A total of 3425 patients were recruited by 122 general practitioners. Mean (\pm SD) age was 49.5 ± 13.3 years, and 83.1% were women. CEAP classifications were C0 (2.5%), C1 (23.0%), C2 (31.7%), C3 (34.8%), and C4-C6 (8%). Conservative therapy comprised: venoactive drugs (VADs) in 98.9% of patients, mainly micronized purified flavonoid fraction (MPFF) (75.7%); compression therapy (38.2%), and topical treatment (30.1%). These therapies were prescribed alone or in combination. At 4 weeks, VAS mean global severity score decreased from 4.6 ± 2.1 to 2.2 ± 1.5 with any VAD alone, and from 4.7 ± 2.0 to 2.2 ± 1.3 with MPFF alone. When used in combination with compression, the score was reduced from 5.1 ± 1.9 to 2.7 ± 1.6 with any VAD and from 5.0 ± 2.0 to 2.5 ± 1.5 with MPFF. Overall, conservative therapy reduced VAS symptom intensity by 50.3% for pain, 51.8% for heaviness, 51.0% for cramps, and 50.4% for swelling. PGIC showed an improvement for 97.8% of patients at 4 weeks. Improvements in QOL were observed across all three CMIQ-14 dimensions (pain, physical, and

Phlebology. 2021;28(2):68-78

Copyright © LLS SAS. All rights reserved

www.phlebology.org

psychological) ($P \leq 0.001$). Physician-reported VCSS showed conservative treatment led to a significant decrease in CVD severity at week 4 from 5.6 ± 3.7 to 3.1 ± 2.4 for all CEAP classes combined. Both patients and physicians reported a high level of satisfaction with conservative treatments and no adverse events. **Conclusion:** This observational study provides large-scale data from a real-life Moroccan setting using both patient- and physician-reported outcomes. Conservative treatment, mainly in the form of VADs, and in particular MPFF, was associated with improvements in symptoms and QOL.

Introduction

Chronic venous disease (CVD) affects a significant proportion of populations worldwide and can be associated with considerable morbidity with adverse effects on quality of life (QOL).^{1,2} Before the introduction of the Clinical, Etiological, Anatomical, Pathophysiological (CEAP) classification system, diagnosis of chronic CVDs lacked precision. CEAP classification provided a universally understandable description and has become an instrument to standardize diagnosis and allow better communication about CVD between health care professionals worldwide. There is a strong link between increasing CEAP clinical grades and deterioration in disease-specific QOL, and demonstrable morbidity has been observed even with uncomplicated venous disease.³ The most severe CEAP grades have been associated with a level of physical impairment comparable to that seen in patients with congestive cardiac failure and/or chronic lung disease.³

The large, international VEIN Consult program used the same questionnaire and same classification method in all participating countries and reported CVD prevalence rates of 52% in Asia, 70% in Eastern Europe, 68% in Latin America, and 62% in Western Europe.² Risk factors for the development and progression of CVD are prevalent in most populations and include advancing age, excess body weight, sedentary lifestyles, and occupations, and a family history of the disease.⁴ Many of these are associated with lifestyle and nutrition habits typical of industrial economies and are in common with a number of other noncommunicable diseases. Thus, the burden of CVD-related morbidity, disability, and socioeconomic costs looks set to increase in coming decades,⁵ including in developing countries such as Morocco.

The consequences of CVD are far more than cosmetic, as even those with low CEAP classifications (C0-C2) may experience associated symptoms such as aching or heaviness in their legs.^{6,7} At these early stages, interventions may not even be sought or prescribed, yet effective treatment may provide

immediate symptom relief⁸ and has the potential to delay or prevent the progression of the disease and the development of severe complications.^{9,10} QOL and impact on productivity only worsen with more severe stages of CVD, and represents a substantial burden on health care systems.¹¹⁻¹³

A wide range of treatment options is available for the management of CVD, both conservative and invasive.¹⁴ Conservative approaches aim mainly to restore the altered physiological functions of the venous system. They incorporate the following: advice on lifestyle changes including weight loss, exercise, and leg elevation; use of compression therapy to decrease ambulatory venous hypertension; and pharmacotherapy. The latter, in the form of venoactive drugs (VAD), has assumed an increasingly important role since the recognition of inflammation and primary venous valve failure as important pathogenetic mechanisms in CVD.^{15,16} Subsequent updates to international guidelines also acknowledged that the beneficial effects of VAD were not just due to their effects on venous tone.^{17,18}

Micronized purified flavonoid fraction (MPFF), in particular, via its ability to attenuate various elements of the inflammatory cascade,¹⁹ has been shown to be a highly effective agent,²⁰ which is associated with a series of grade A recommendations in recent guidelines in relation to beneficial effects on CVD symptoms, skin changes, and QOL.¹⁴

In order to ensure optimal treatment practices and outcomes, there is a need to assess the characteristics of CVD in representative samples of the general population and to examine the way it is managed in everyday clinical practice. The aim of the VEIN STEP program (Chronic Venous Disorders maNagement and Treatment Effectiveness Evaluation in Chronic Venous Disease, an International Observational Prospective Study) was to obtain up-to-date data on the conservative treatments that patients are being prescribed in routine clinical practice and the effectiveness of these treatments for the relief of CVD signs and symptoms. VEIN STEP is being conducted in a number of countries around the world. This article describes the findings from Morocco.

Methods

Study design

The VEIN STEP program in Morocco is part of an international, observational, prospective study. It was conducted between June 2020 and December 2020 to gather nationally representative data on the conservative treatment of patients with venous disorders in routine clinical practice. General

Practitioners were asked to select consecutive patients, whenever possible, who met the following minimal set of inclusion criteria: aged ≥ 18 years old; consulting spontaneously or referred for treatment of symptomatic CVD; having a diagnosis of CVD according to physician's judgment; and existence of written, informed patient consent. Noninclusion criteria comprised the following: undergoing current treatment for CVD either with a VAD or compression hosiery; presence of lower-limb arterial disease; presence of concomitant disease or treatment that may interfere with lower-limb pain or edema; having any procedure or surgery planned during the study for CVD; and, if female, being pregnant or breastfeeding.

The primary objective of the study was to assess, in a real-life setting, the effectiveness of conservative treatments on CVD signs and symptoms and QOL using a combination of patient-reported outcomes and physician assessments. Data were collected from ambulatory patients who were eligible for inclusion via a standardized electronic case-report form.

At the initial inclusion visit (visit 0 [V0]), patients underwent a clinical examination of the lower limbs and were assigned a CEAP clinical classification.²¹ Patients were asked to indicate the global intensity of their symptoms (pain, heaviness, cramps, sensation of swelling) with the use of a 10-cm visual analog scale (VAS). The intensity of paresthesia (tingling), itching, and burning sensation symptoms was assessed using a 4-point scale. Patient QOL was assessed using the validated 14-item Chronic Venous Insufficiency Questionnaire (CMIQ-14).²²

Following examination of the patient, the physicians completed the Venous Clinical Severity Score (VCSS).²³ The score includes 10 clinical parameters (pain, varicose veins, venous edema, skin hyperpigmentation, inflammation, induration, number of ulcers, durations of ulcers, size of ulcers, and adherence to compression therapy). Each item is graded from 0 to 3 depending on severity (None = 0, Mild = 1, Moderate = 2, Severe = 3). At V0, patients were prescribed conservative treatment according to the physicians' usual practice. This

	V0	V1 (2 weeks) (Phone call)	V2 (4 weeks)	V3 (8 weeks) (Phone call, optional)
Informed consent	X			
Inclusion/noninclusion criteria	X			
Patient's profile	X			
History of CVD	X			
CEAP classification	X			
VCSS	X		X	
Patient-reported symptoms	X		X	
CMIQ-14 questionnaire	X		X	
Recommendations and treatments	X			
PGIC score		X ¹	X	X
Adherence to treatment and/or recommendations		X ²	X	
Evaluation of patient and physician satisfaction			X	
Adverse events		X	X	X
Patient follow-up and drug prescription recommendation			X	X ³
Study discontinuation		X	X	X

Table 1. Summary of assessments performed according to visit.

CEAP, Clinical, Etiological, Anatomical, Pathophysiological classification; CMIQ-14, 14-item Chronic Venous Insufficiency Questionnaire; CVD, chronic venous disease; PGIC, Patient Global Impression of Change; VCSS, Venous Clinical Severity Score.

¹ At V1, the patient will be asked to indicate which symptoms have improved and time to improvement, if any.

² At V1, abbreviated compliance without providing details.

³ At V3, the investigator will record treatment and follow-up without providing details.

could include pharmacological or nonpharmacological treatment (such as compression therapy, oral VAD, painkillers, topical treatment). Provision of lifestyle advice was optional and dependent on the physician’s usual practice.

Visit 1 (V1) took place approximately 2 weeks later by telephone, at which point global symptom improvement was determined by questioning the patient and completing the Patient Global Impression of Change (PGIC) questionnaire. PGIC is a 7-point scale depicting a patient’s rating of overall improvement. Patients rate their change as “very much improved,” “much improved,” “minimally improved,” “no change,” “minimally worse,” “much worse,” or “very much worse.”

Visit 2 (V2) took place approximately 4 weeks after inclusion and assessed global and individual symptom intensity (VAS), symptom improvement (PGIC), QOL (CMIQ-14), and physician-reported symptom severity (VCSS). Patients’ satisfaction with treatment was a secondary end point and assessed at V2 using a 5-item scale (very unsatisfied, unsatisfied, neutral, satisfied, very satisfied). An additional, optional telephone follow-up (visit 3 [V3]) could be conducted around 8 weeks after inclusion. Patients were questioned about adherence to treatment and lifestyle recommendations and about adverse events at each contact with the physician. A summary of the assessments performed at each visit is provided in *Table I*.

VEIN STEP was a noninterventional study according to the European Regulation EU No. 536/2014. Physicians were instructed to continue management and treatment of participants according to their usual practice. No specific investigations or therapies were prescribed as part of this study, and therefore patient care was not influenced. All data were collected anonymously. As this was not an investigation of clinical outcomes with any particular intervention, neither Ethics Committee approval nor clinical trial registration was required.

Statistical analysis

Statistical analyses were mainly descriptive and performed in included patients with complete data for the main variables. Quantitative data were represented by the number of patients and expressed as the mean value and standard deviation; qualitative data were expressed as the number and percentage of patients. All statistical analyses were performed with the SAS® software version 9.4 or higher. Statistical significance was assumed when *P*<0.05 (2-sided).

Results

Patient characteristics

In the Moroccan arm of VEIN STEP, a total of 3425 patients were enrolled by 122 investigators. Data were available for 2929 patients at V1, 3285 at V2, and 1554 at the optional 8-week follow-up visit (V3). Mean age was 49.5 ± 13.3 years, mean body mass index was 28.5 ± 4.7 kg/m², and the majority had never smoked (90.5%). In the overall population, there was a higher proportion of women than men (83.1% versus 16.9%), but the proportion of women to men differed for the individual CEAP classes, with a higher proportion of women than men in the C1 class, and a higher proportion of men than women in classes C4-C6 (*Figure 1*). Patients’ baseline characteristics by CEAP class are shown in *Table II*.

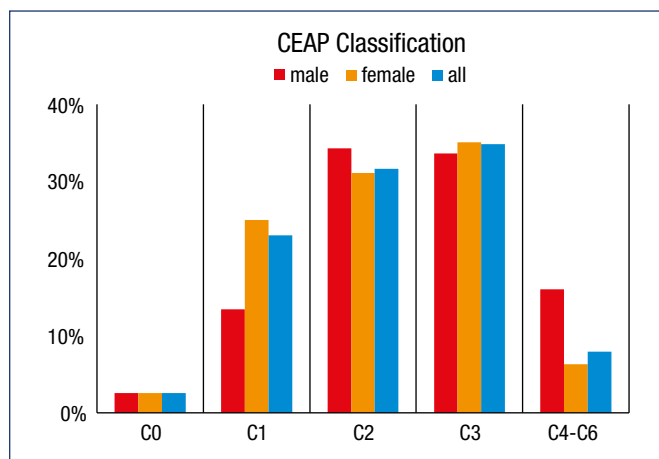


Figure 1. Clinical, Etiological, Anatomical, Pathophysiological (CEAP) classification.

Among the women in the study, two-thirds (65.5%) had given birth at least once, and the mean number of births was 3.4 ± 1.7 with a mean time since last delivery of 17.8 ± 12.5 years. A sedentary lifestyle was reported for 42.8% of patients, just over a quarter (26.5%) reported their occupation required spending more than 5 hours standing per day, and 11.3% more than 5 hours sitting. A family history of CVD was reported in 23.0%. In 24.9%, the first signs or symptoms of CVD appeared before the age of 30 years. Among the 18.2% of patients who reported suffering from other venous disorders: 91.8% had previously had hemorrhoidal disease, 7.2% deep vein thrombosis, 1.4% pelvic congestion syndrome, and 1.0% post-thrombotic syndrome. A quarter (25.8%) had received previous treatment for venous leg disorders: 82.8% had received an oral agent (68.9% VAD, 50.4% analgesic, 7.1% other), 57.3% had received a topical agent, and 21.2% a prescription for compression therapy (38.0% bandages,

		C0 N=87	C1 N=789	C2 N=1084	C3 N=1193	C4a N=193	C4b N=29	C5 N=29	C6 N=21	All N=3425
Sex	N	87	789	1084	1193	193	29	29	21	3425
Male	n (%)	15 (17.2%)	78 (9.9%)	199 (18.4%)	195 (16.3%)	63 (32.6%)	9 (31.0%)	11 (37.9%)	10 (47.6%)	580 (16.9%)
Female	n (%)	72 (82.8%)	711 (90.1%)	885 (81.6%)	998 (83.7%)	130 (67.4%)	20 (69.0%)	18 (62.1%)	11 (52.4%)	2845 (83.1%)
Age (years)	N	87	789	1084	1193	193	29	29	21	3425
	Mean (SD)	50.0 (16.4)	44.9 (13.2)	49.2 (12.5)	51.6 (13.0)	53.9 (13.8)	55.6 (11.4)	58.0 (13.3)	55.1 (12.4)	49.5 (13.3)
Age range (years)	N	87	789	1084	1193	193	29	29	21	3425
18-35	n (%)	15 (17.2%)	183 (23.2%)	131 (12.1%)	127 (10.6%)	18 (9.3%)	0 (0.0%)	1 (3.4%)	2 (9.5%)	477 (13.9%)
35-50	n (%)	29 (33.3%)	329 (41.7%)	432 (39.9%)	386 (32.4%)	55 (28.5%)	7 (24.1%)	7 (24.1%)	3 (14.3%)	1248 (36.4%)
50-65	n (%)	28 (32.2%)	206 (26.1%)	389 (35.9%)	474 (39.7%)	77 (39.9%)	15 (51.7%)	11 (37.9%)	12 (57.1%)	1212 (35.4%)
> 65 years	n (%)	15 (17.2%)	71 (9.0%)	132 (12.2%)	206 (17.3%)	43 (22.3%)	7 (24.1%)	10 (34.5%)	4 (19.0%)	431 (14.2%)
Body Mass Index (BMI) (kg/m²)	N	87	789	1084	1193	193	29	29	21	3425
	Mean (SD)	28.30 (3.97)	27.70 (4.44)	28.18 (4.95)	29.08 (4.54)	28.78 (4.34)	30.21 (5.67)	29.46 (3.92)	31.42 (4.01)	28.46 (4.67)
Is there a known family history of CVD?	N	87	789	1084	1193	193	29	29	21	3425
No	n (%)	42 (48.3%)	397 (50.3%)	538 (49.6%)	591 (49.5%)	63 (32.6%)	9 (31.0%)	10 (34.5%)	7 (33.3%)	1657 (48.4%)
Yes	n (%)	29 (33.3%)	198 (25.1%)	259 (23.9%)	210 (17.6%)	64 (33.2%)	12 (41.4%)	9 (31.0%)	8 (38.1%)	789 (23.0%)
Unknown	n (%)	16 (18.4%)	194 (24.6%)	287 (26.5%)	392 (32.9%)	66 (34.2%)	8 (27.6%)	10 (34.5%)	6 (28.6%)	979 (28.6%)
Sedentary lifestyle	n (%)	46 (52.9%)	331 (42.0%)	433 (39.9%)	523 (43.8%)	82 (42.5%)	17 (58.6%)	22 (75.9%)	11 (52.4%)	1465 (42.8%)
Is the patient occupationally active?	N	87	789	1084	1193	193	29	29	21	3425
No	n (%)	30 (34.5%)	172 (21.8%)	223 (20.6%)	244 (20.5%)	29 (15.0%)	12 (41.4%)	9 (31.0%)	2 (9.5%)	721 (21.1%)
Normal tasks	n (%)	27 (31.0%)	354 (44.9%)	459 (42.3%)	426 (35.7%)	72 (37.3%)	8 (27.6%)	17 (58.6%)	5 (23.8%)	1368 (39.9%)
Prolonged standing (>5 h/day)	n (%)	20 (23.0%)	173 (21.9%)	279 (25.7%)	363 (30.4%)	58 (30.1%)	8 (27.6%)	1 (3.4%)	7 (33.3%)	909 (26.5%)
Prolonged sitting (>5 h/day)	n (%)	10 (11.5%)	86 (10.9%)	112 (10.3%)	147 (12.3%)	23 (11.9%)	1 (3.4%)	2 (6.9%)	7 (33.3%)	388 (11.3%)
Heavy lifting	n (%)	0 (0.0%)	4 (0.5%)	11 (1.0%)	12 (1.0%)	11 (5.7%)	0 (0.0%)	0 (0.0%)	0 (0.0%)	38 (1.1%)
Has the patient ever received treatments for venous leg disorders?	N	87	789	1084	1193	193	29	29	21	3425
No	n (%)	55 (63.2%)	619 (78.5%)	701 (64.7%)	736 (61.7%)	78 (40.4%)	8 (27.6%)	7 (24.1%)	4 (19.0%)	2208 (64.5%)
Yes	n (%)	23 (26.4%)	122 (15.5%)	280 (25.8%)	320 (26.8%)	82 (42.5%)	18 (62.1%)	20 (69.0%)	17 (81.0%)	882 (25.8%)
Unknown/not determined	n (%)	9 (10.3%)	48 (6.1%)	103 (9.5%)	137 (11.5%)	33 (17.1%)	3 (10.3%)	2 (6.9%)	0 (0.0%)	335 (9.8%)
Oral	N	23	122	280	320	82	18	20	17	882
No	n (%)	3 (13.0%)	37 (30.3%)	54 (19.3%)	47 (14.7%)	10 (12.2%)	0 (0.0%)	0 (0.0%)	1 (5.9%)	152 (17.2%)
Yes	n (%)	20 (87.0%)	85 (69.7%)	226 (80.7%)	273 (85.3%)	72 (87.8%)	18 (100.0%)	20 (100.0%)	16 (94.1%)	730 (82.8%)

		C0 N=87	C1 N=789	C2 N=1084	C3 N=1193	C4a N=193	C4b N=29	C5 N=29	C6 N=21	All N=3425
If yes, Type	N	20	85	226	273	72	18	20	16	730
VAD	n (%)	8 (40.0%)	55 (64.7%)	151 (66.8%)	182 (66.7%)	61 (84.7%)	14 (77.8%)	18 (90.0%)	14 (87.5%)	503 (68.9%)
Analgesic	n (%)	10 (50.0%)	32 (37.6%)	117 (51.8%)	139 (50.9%)	39 (54.2%)	11 (61.1%)	13 (65.0%)	7 (43.8%)	368 (50.4%)
Other	n (%)	8 (40.0%)	12 (14.1%)	8 (3.5%)	12 (4.4%)	5 (6.9%)	0 (0.0%)	4 (20.0%)	3 (18.8%)	52 (7.1%)
Topical	N	23	122	280	320	82	18	20	17	882
No	n (%)	18 (78.3%)	57 (46.7%)	119 (42.5%)	147 (45.9%)	28 (34.1%)	3 (16.7%)	3 (15.0%)	2 (11.8%)	377 (42.7%)
Yes	n (%)	5 (21.7%)	65 (53.3%)	161 (57.5%)	173 (54.1%)	54 (65.9%)	15 (83.3%)	17 (85.0%)	15 (88.2%)	505 (57.3%)
Has the patient ever received compression therapy?	N	23	122	280	320	82	18	20	17	882
No	n (%)	21 (91.3%)	112 (91.8%)	211 (75.4%)	265 (82.8%)	54 (65.9%)	14 (77.8%)	9 (45.0%)	9 (52.9%)	695 (78.8%)
Yes	n (%)	2 (8.7%)	10 (8.2%)	69 (24.6%)	55 (17.2%)	28 (34.1%)	4 (22.2%)	11 (55.0%)	8 (47.1%)	187 (21.2%)
Has the patient ever had a procedure/surgery for venous disease?	N	87	789	1084	1193	193	29	29	21	3425
No	n (%)	85 (97.7%)	771 (97.7%)	1060 (97.8%)	1172 (98.2%)	185 (95.9%)	27 (93.1%)	22 (75.9%)	19 (90.5%)	3341 (97.5%)
Yes	n (%)	2 (2.3%)	18 (2.3%)	24 (2.2%)	21 (1.8%)	8 (4.1%)	2 (6.9%)	7 (24.1%)	2 (9.5%)	84 (2.5%)

CEAP, Clinical, Etiological, Anatomical, Pathophysiological classification; CVD, chronic venous disease; VAD, venoactive drug.

Table II. Patient demographics and baseline characteristics according to Clinical, Etiological, Anatomical, Pathophysiological (CEAP) class.

65.2% stockings). The proportion who had received previous treatment ranged from 26.4% of C0 patients to 81.0% of C6 patients. Only 2.5% of patients had previously had a procedure/surgery for venous disease.

CEAP clinical classification

Following a clinical examination of the lower legs by the physician, 2.5% of subjects were classed as C0, 23% were C1 (telangiectasies or reticular veins), 31.6% were C2 (varicose veins), 34.8% were C3 (edema), and 7.9% were C4-C6 (skin and subcutaneous tissue changes and/or healed or active ulcers) (Figure 1). At baseline, the mean number of symptoms across CEAP classes was 5.5 ± 1.8. Across CEAP classes C0 to C3, symptoms were more likely to be experienced after prolonged standing or at the end of the day (reported by 27% and 37% of patients). However, in classes C4 and above, symptoms were more likely to be reported all the time (reported by 22% [C4a] to 71% [C6] of patients).

Lifestyle advice and conservative treatments prescribed

At V0, 95.4% of patients received lifestyle advice. This included recommendations to exercise regularly and lose

weight if necessary, avoid periods of prolonged standing or sitting, wear comfortable footwear, improve venous return by leg elevation, regular leg movement, and massage, and also addressed the importance of skin hygiene. The majority of patients were prescribed a conservative treatment that included a VAD (98.9%). Among the VADs, MPFF was the most widely prescribed agent (75.7%); other VADs included diosmin (21.5%), ruscus extract (1.2%), and proanthocyanidins (1.1%). Analgesics, either oral or topical, were prescribed in 44.5% of patients. Conservative treatments prescribed at V0 were: oral VAD alone (31.7%), oral VAD and analgesic (16.0%), oral VAD and compression (12.9%), oral VAD and compression and topical treatment and analgesic (11.7%), oral VAD and compression and analgesic (8.8%), oral VAD and topical treatment and analgesic (6.5%), oral VAD and topical treatment (6.1%), oral VAD and compression and topical treatment (4.1%), other treatment (1.6%), topical treatment alone (0.3%), compression alone (0.1%), and analgesics alone (0.1%) (Table III).

At week 4, adherence to lifestyle advice was 97.3%. Among the patients prescribed conservative treatment, 97.7% of patients

Conservative treatment	Proportion of patients
Oral VAD monotherapy	31.7%
Oral VAD + analgesic	16.0%
Oral VAD + compression	12.9%
Oral VAD + compression + topical + analgesic	11.7%
Oral VAD + compression + analgesic	8.8%
Oral VAD + topical + analgesic	6.5%
Oral VAD + topical	6.1%
Oral VAD + compression + topical	4.1%
Topical monotherapy	0.3%
Compression monotherapy	0.1%
Analgesic monotherapy	0.1%
Other	1.6%

VAD, venoactive drug

Table III. Conservative treatments for chronic venous disease prescribed at baseline.

were described as adherent to VAD and 85% to compression therapy. The main reasons for nonadherence to compression were described as discomfort (55.2%), skin irritation (33.3%), and sweating (32.2%).

Patient-reported outcomes

Global symptom intensity assessed with Visual Analog Scale
 At V0, mean VAS global symptom intensity across the CEAP classes was 5.2 overall, but ranged from 4.2 to 7.7, increasing in intensity with CEAP class. Following 4 weeks of conservative treatment, mean overall score was 2.6 and had decreased significantly in each CEAP class ($P < 0.001$).

VAD-based treatments led to significant reductions in global symptom intensity at week 4. For VAD treatment alone, VAS scores decreased from 4.6 ± 2.1 at V0 to 2.2 ± 1.5 at V2 ($P < 0.01$) (Figure 2). Statistically significant reductions in symptom intensity were also observed when VAD treatment was combined with compression therapy or topical treatment, with slightly greater reductions in intensity for MPFF versus other VAD combinations (Figure 2). When analyzed individually, the greatest reductions in intensity were observed for the symptoms of pain, heaviness, cramps, and swelling with reductions in intensity of 46% to 57% (Figure 3). Reductions were slightly less (27%-39%), but still significant for the symptoms of paresthesia, itching, and burning (Figure 3). These reductions in symptom intensity were achieved whether treatment was with VAD alone or combined with compression or topical therapy. For all symptoms, a slightly greater reduction in

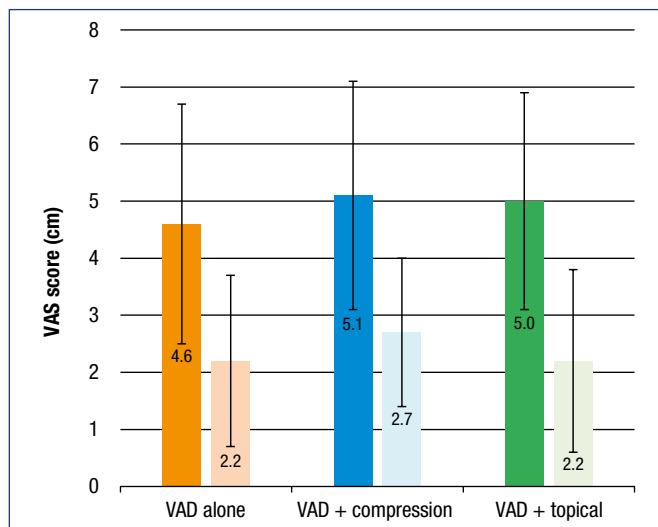


Figure 2. Mean global symptom intensity score at week 4 (light colors) vs week 0 (dark colors).

Abbreviations: VAD, venoactive drug, VAS, Visual Analog Scale.

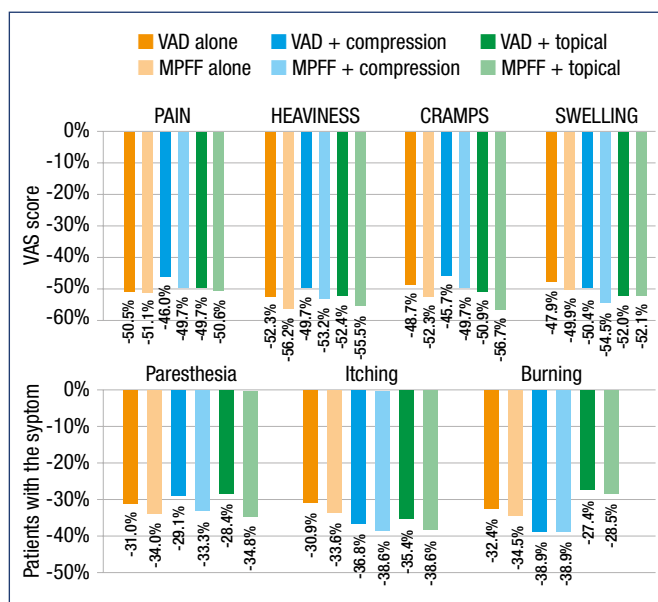


Figure 3. Mean individual symptom intensity score at week 4.

Abbreviations: MPFF, micronized purified flavonoid fraction; VAD, venoactive drug, VAS, Visual Analog Scale.

intensity was observed with MPFF compared with all VADs combined (Figure 3).

Global symptom improvement assessed with Patient Global Impression of Change

For all patients combined, regardless of conservative treatment prescribed, improvement was already noted in 92.8% of patients at V1 (week 2) and had increased to 97.8% by V2 (week 4); only 6.8% and 2.1% of patients reported no change at V1 and V2, respectively. Improvement was noted for 98.6% of patients at the optional 8-week follow-up visit (V3).

Similar results were observed for VAD treatment, either alone or in combination with other conservative therapies. Across all CEAP classes, the symptoms improved the most by conservative therapy were pain (improved in 88.6% patients), heaviness (69.3%), cramps (52.1%), and sensation of swelling (38.4%). At baseline, the mean number of symptoms across CEAP classes was 5.5 ± 1.8 . At visit V2, this had decreased to 3.8 ± 2.0 ($P < 0.001$). Improvements in these symptoms were observed within a mean of 8.4 ± 2.8 days.

Quality of life assessed with 14-item Chronic Venous Insufficiency Questionnaire

Conservative treatment was also associated with a significant improvement in patients' QOL after only 4 weeks, assessed using CIVIQ-14 (14-item Chronic Venous Insufficiency Questionnaire). This was observed across all 3 CIVIQ-14 dimensions (pain, physical and psychological) ($P < 0.001$), in the overall population and in the patients who received treatment with VAD, either alone or in combination with compression or topical therapy (Figure 4).

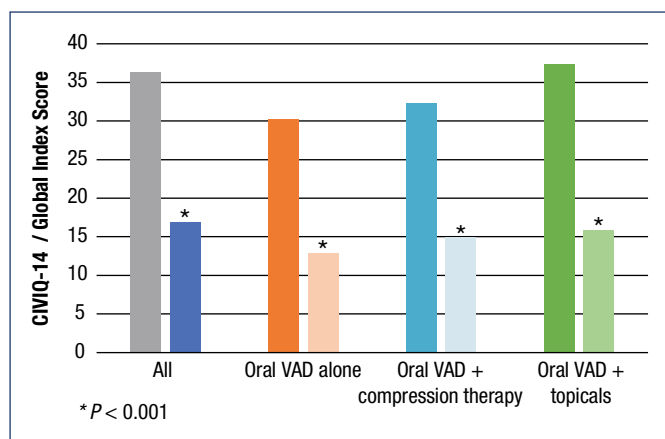


Figure 4. CIVIQ-14 assessed patient quality of life at week 4.

Abbreviations: CIVIQ-14, 14-item Chronic Venous Insufficiency Questionnaire; VAD, venoactive drug.

Physician-assessed CVD severity

Physician-assessed VCSS data at V0 and V2 were available for approximately two-thirds of patients (67.3% at V0 and 64.9% at V2). There was a strong association between the severity of CVD measured by the VCSS and the CEAP clinical classification, with baseline scores ranging from 3.2 ± 3.0 for C1 to 16.8 ± 3.6 for C6. The only exception was for patients in the C0 class in whom baseline VCSS score was 6.2 ± 6.0 , which was similar to the score for C3 patients (6.0 ± 2.7). Nevertheless, regardless of CEAP clinical class at V0, conservative treatment led to a significant decrease in CVD severity at V2 (week 4) ($P < 0.001$) (Figure 5).

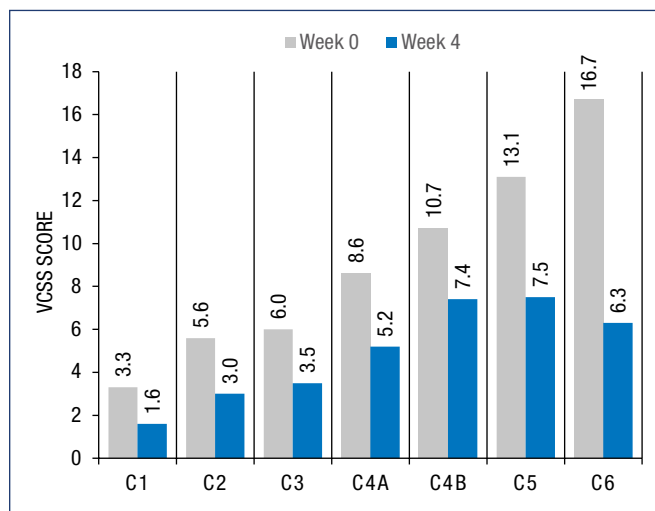


Figure 5. Venous clinical severity score at week 4.

Abbreviations: VCSS, Venous Clinical Severity Score.

Patient and physician satisfaction with treatment prescribed

Overall, 87.8% of the subjects and 89.6% of physicians were satisfied or very satisfied with the treatment prescribed. The proportions of patients and physicians satisfied or very satisfied with VAD treatment alone were 89.2% and 92.6%, respectively. Rates of patient satisfaction were similar when VAD was combined with compression (88.9% satisfied or very satisfied). High rates of satisfaction were observed whether VAD treatment, including MPFF, was prescribed alone or in combination with other conservative therapy.

Safety and tolerability

No adverse events were reported.

Discussion

The results of this observational research describe the patterns of CEAP classification of patients presenting with CVD and how they are managed in routine Moroccan clinical practice. In agreement with findings from other large, international, observational studies, including the VEIN Consult¹ and VEIN ACT (Chronic Venous Disorders maNagement and evaluAtion of Chronic venous disease treatment effecTiveness) programs,⁷ the majority of patients (75%) were already classed with a CEAP grade of C2 or higher, despite three-quarters of them never having received a treatment for CVD. In VEIN STEP, patients were enrolled by general practitioners. The fact that patients were presenting for treatment only at these later CEAP stages suggests that venous disorders are not being recognized or considered serious enough for treatment in their early stages, and therefore not referred to specialists, and/or that patients do not consult until visible signs are present.

As in most CVD observational studies of this type, there was a greater proportion of women than men overall. However, when analyzed by CEAP class, the female majority was apparent in CEAP C1, sex distribution was approximately equal in C2 and C3, but thereafter in C4-C6, there was a greater prevalence in men than women. A greater predominance of trophic changes in men has also been observed in other studies.²⁴

Current guidelines recognize the importance of VADs as part of conservative treatment for CVD.¹⁴ This was reflected in the treatments received with almost all patients (98.9%) being prescribed a VAD, alone or in combination with compression and topical treatment, as part of their conservative treatment. MPFF made up the largest proportion of VAD treatment (75.7%), and while it shares some of its benefits on CVD symptoms with other VADs, it is the only agent in the class to also receive an A grade recommendation for improvements in skin changes and QOL.¹⁴ VAD treatments including MPFF were associated with a high level of adherence with 97.7% of patients taking their medication as prescribed. Compression therapy using bandaging or graduated compression hosiery is an integral part of the management of CVD, but poor adherence to compression is well documented in the literature.^{7,25,26} In the VEIN ACT program, 65.2% of patients were adherent to the required duration of therapy for VADs, but only 29.1% wore their compression therapy as prescribed,⁷ with patients often citing discomfort as the main reason for nonadherence. Even when there is a strong indication for compression therapy, such as patients with venous leg ulcers, complete adherence has been reported to be as low as 40%.²⁷ In the current report, compression adherence was lower than for VAD, but still higher than in other studies with a rate of 85% at 4 weeks.

Conservative treatment, whether it comprised VAD alone or in combination with compression or topical therapy, was effective at reducing the global intensity of CVD symptoms across all CEAP classes after only 4 weeks of treatment, with VAS scores approximately halved compared with baseline. Significant reductions in symptom intensity were also observed when the CVD symptoms were considered individually. Whereas reductions were greatest for the symptoms of pain, heaviness, cramps, and swelling (in the region of 46%-57%), important reductions in intensity for paresthesia, itching, and burning were also observed (in the region of 27%-39%). All of these symptoms can be present from the outset, before any clinical signs of the disease are evident. Previous data have shown that QOL can be affected by even "mild-" or "moderate-intensity" CVD symptoms,²⁸ further highlighting the importance of an early CVD diagnosis. The current study assessed QOL via CIVIQ-14, a validated international scale specific to

CVD. At 4 weeks, conservative treatment had resulted in a significant improvement in the CIVIQ-14 Global Index Score (which includes physical, psychological, and social functioning components of QOL) whether VADs were prescribed alone or in combination with other conservative treatments.

The self-reported PGIC measure, which reflects a patient's belief about the efficacy of treatment, was performed at 2 and 4 weeks. It requires patients to calculate the difference between their current and previous health state based on a Likert scale. Patients experienced the benefits of conservative treatment rapidly with 92.7% already reporting they were improved at 2 weeks, and almost all patients noting a change for the better at 4 weeks (97.8%). The benefits of treatment were also reflected in the secondary end point of patient and physician satisfaction, with around 90% reporting they were satisfied or very satisfied with treatment at 4 weeks, regardless of whether VAD was administered alone or in combination with compression or topical therapy.

To supplement the patient-reported outcome data, the effects of treatment were also assessed by physicians using the VCSS. The VCSS was designed to complement the CEAP classification by providing a method for physicians to assess changes over time and in response to an intervention and thereby provide a standard clinical language to report and compare differing approaches to CVD management.²³ As expected, baseline VCSS was mostly correlated with baseline CEAP class. The exception was for patients classified as C0, who had a similar mean VCSS score to C3 patients. A potential explanation is that a proportion of C0 patients may be suffering from valvular incompetence at the microvascular level, which while not sufficient to cause visible venous signs can nevertheless trigger the release of inflammatory mediators and stimulate nociceptive fibers.^{29,30} Significant reductions in VCSS were observed for patients in each CEAP class after 4 weeks of conservative treatment.

The results from VEIN STEP confirm that conservative therapy, which mainly comprised VAD, was effective at reducing the intensity of CVD symptoms and improving patient QOL at all stages of the disease. Nevertheless, there are a number of advantages to early diagnosis and treatment. First, lifestyle changes and avoidance measures can be introduced, for example by reducing excess body mass, implementing exercise routines, and raising the legs at rest. Second, appropriate management of patients with early stage venous disease can relieve symptoms and improve QOL, which can already be seriously affected even in patients in low CEAP classes.^{20,31} Third, by targeting the causes of CVD, namely

inflammation and retrograde venous flow, early treatment can help limit the number of patients who progress to more severe CVD stages and avoid the need for expensive and invasive treatment. This not only improves the QOL of patients, but will also provide economic advantages for a disease that has significant costs, particularly in its later stages.¹⁴


This observational study is potentially limited by the possibility of sample bias, incomplete survey response data, as well as the inaccuracy of self-reported behavior. To minimize variability and ensure results were representative of the general Moroccan population with CVD, efforts were taken to recruit as wide a range of participants as possible from practices distributed throughout the country in both urban and rural areas and from a variety of practice types.

The results of this observational research capture important large-scale data on the management of patients with CVD in routine Moroccan clinical practice, a country for which there is a sparsity of data on the management of CVD. VEIN STEP is an international program, and the results for Morocco will soon be complemented by those from other countries to provide an up-to-date overview of treatment practices and

their efficacy across the globe. It is hoped that enhanced awareness among physicians will result in more patients receiving effective treatment earlier in the course of CVD to alleviate symptoms and delay or prevent disease progression and the development of severe complications.

Conclusions

VEIN STEP provides large-scale data from a real-life setting on the current management of CVD with conservative treatments. Results from Morocco reinforce that treatment with VADs and in particular MPFF, is associated with improvements in symptom intensity and QOL at all stages of the disease.



Corresponding author

Tazi Mezalek ZOUBIDA, MD,
Service Médecine Interne / Hématologie
Clinique - Hôpital Ibn Sina - Rabat
Maroc

Email: ztazimezalek@gmail.com

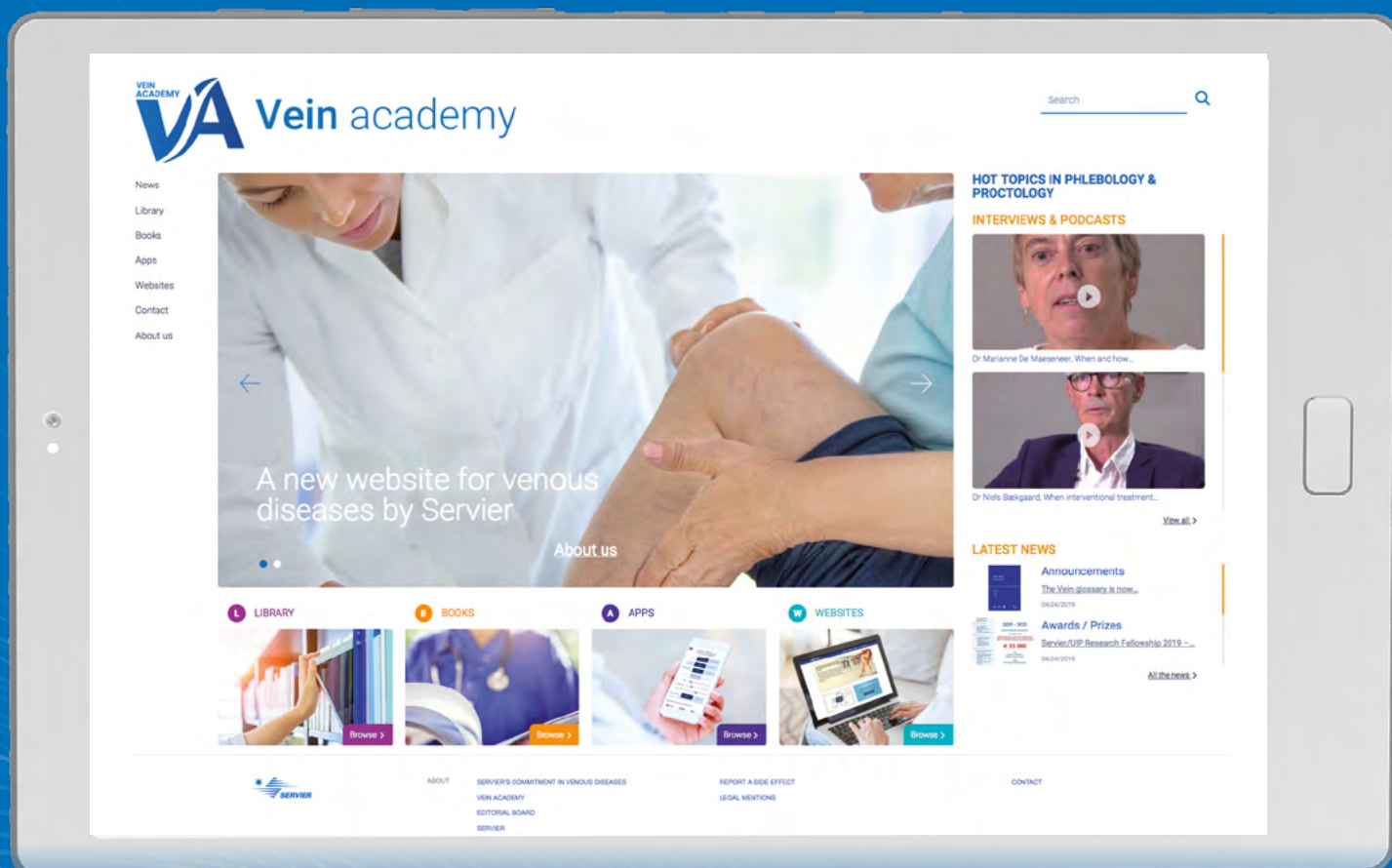REFERENCES

- Rabe E, Guex JJ, Puskas A, Scuderi A, Fernandez Quesada F; VCP Coordinators. Epidemiology of chronic venous disorders in geographically diverse populations: results from the Vein Consult Program. *Int Angiol.* 2012;31(2):105-115.
- Vuylsteke ME, Colman R, Thomis S, Guillaume G, Van Quickenborne D, Staelens I. An epidemiological survey of venous disease among general practitioner attendees in different geographical regions on the globe: the final results of the Vein Consult Program. *Angiology.* 2018;69(9):779-785.
- Carradice D, Mazari FA, Samuel N, Allgar V, Hatfield J, Chetter IC. Modelling the effect of venous disease on quality of life. *Br J Surg.* 2011;98(8):1089-1098.
- Labropoulos, N. How does chronic venous disease progress from the first symptoms to the advanced stages? A review. *Adv Ther.* 2019;36:13-19.
- Nicolaides AN, Labropoulos N. Burden and suffering in chronic venous disease. *Adv Ther.* 2019;36:1-4.
- Benigni JP, Bihari I, Rabe E, et al; UIP - Union Internationale de Phlébologie. Venous symptoms in C0 and C1 patients: UIP consensus document. *Int Angiol.* 2013;32(3):261-265.
- Bogachev V, Arribas JMJ, Baila S, Ulloa Dominguez J, Walter J. Management and evaluation of treatment adherence and effectiveness in chronic venous disorders: results of the international study VEIN Act Program. *Drugs Ther Perspect.* 2019;35:396-404.
- Tsoukanov YT, Tsoukanov AY, Nikoiaychuk A. Great saphenous vein transitory reflux in patients with symptoms related to chronic venous disorders, but without visible signs (COs), and its correction with MPFF treatment. *Phlebology.* 2017;22(1):3-11.
- Labropoulos N, Leon L, Kwon S, et al. Study of the venous reflux progression. *J Vasc Surg.* 2005;41(2):291-295.
- Mansilha A. Early stages of chronic venous disease: medical treatment alone or in addition to endovenous treatments. *Adv Ther.* 2020;37:13-18.
- Kuet ML, Lane TR, Anwar MA, Davies AH. Comparison of disease-specific quality of life tools in patients with chronic venous disease. *Phlebology.* 2014;29(10):648-653.
- Launois R. Health-related quality-of-life scales specific for chronic venous disorders of the lower limbs. *J Vasc Surg Venous Lymphat Disord.* 2015;3(2):219-227.
- Rabe E, Pannier F. Societal costs of chronic venous disease in CEAP C4, C5, C6 disease. *Phlebology.* 2010;25(suppl 1):64-67.
- Nicolaides A, Kakkos S, Baekgaard N, et al. Management of chronic venous disorders of the lower limbs. Guidelines according to scientific evidence part I. *Int Angiol.* 2018;37(3):181-254.
- Takase S, Pascarella L, Bergan JJ, Schmid-Schonbein GW. Hypertension-induced venous valve remodeling. *J Vasc Surg.* 2004;39:1329-1334.
- Pascarella L, Schmid-Schonbein GW, Bergan J. An animal model of venous hypertension: the role of inflammation in venous valve failure. *J Vasc Surg.* 2005;41:303-311.
- Nicolaides AN, Allegra C, Bergan J, et al. Management of chronic venous disorders of the lower limbs: guidelines according to scientific evidence. *Int Angiol.* 2008;27:1-59.
- Kearon C, Kahn SR, Agnelli G, et al; American College of Chest Physicians. Antithrombotic therapy for venous thromboembolic disease: American College of Chest Physicians Evidence-Based Clinical Practice Guidelines (8th Edition). *Chest.* 2008;133(6 suppl):454S-545S.

REFERENCES

19. Mansilha A, Sousa J. Pathophysiological mechanisms of chronic venous disease and implications for venoactive drug therapy. *Int J Mol Sci.* 2018;19(6):1669.
20. Kakkos SK, Nicolaidis AN. Efficacy of micronized purified flavonoid fraction (Daflon®) on improving individual symptoms, signs and quality of life in patients with chronic venous disease: a systematic review and meta-analysis of randomized double-blind placebo-controlled trials. *Int Angiol.* 2018;37(2):143-154.
21. Eklöf B, Rutherford R, Bergan J, Carpentier P, Głowiczki P. Revision of the CEAP classification for chronic venous disorders: consensus statement. *J Vasc Surg.* 2004;40:1248-1252.
22. Launois R, Le Moine JG, Lozano FS, Mansilha A. Construction and international validation of CIMQ-14 (a short form of CIMQ-20), a new questionnaire with a stable factorial structure. *Qual Life Res.* 2012;21(6):1051-1058.
23. Vasquez MA, Rabe E, McLafferty RB, et al. Revision of the venous clinical severity score: venous outcomes consensus statement: special communication of the American Venous Forum Ad Hoc Outcomes Working Group. *J Vasc Surg.* 2010;52(5):1387-1396.
24. Criqui MH, Jamosos M, Fronck A, et al. Chronic venous disease in an ethnically diverse population: the San Diego Population Study. *Am J Epidemiol.* 2003;158(5):448-456.
25. Raju S, Hollis K, Neglen P. Use of compression stockings in chronic venous disease: patient compliance and efficacy. *Ann Vasc Surg.* 2007;21(6):790-795.
26. Moffatt C, Kommala D, Dourdin N, et al. Venous leg ulcers: patient concordance with compression therapy and its impact on healing and prevention of recurrence. *Int Wound J.* 2009;6(5):386-393.
27. Heinen MM, van der Vleuten C, de Rios MJM, Uden CJT, Evers AWM, van Achtenberg T. Physical activity and adherence to compression therapy in patients with venous leg ulcers. *Arch Dermatol.* 2007;143(10):1283-1288.
28. Branisteanu DE, Feodor T, Baila S, Mitea IA, Vittos O. Impact of chronic venous disease on quality of life: results of vein alarm study. *Exp Ther Med.* 2019;17(2):1091-1096.
29. Lugli M, Maletti O, Iabichella ML, Perrin M. Investigation of non-saphenous veins in COS patients. *Int Angiol.* 2018;37(2):169-175.
30. Vital A, Carles D, Serise JM, Boisseau MR. Evidence for unmyelinated C fibres and inflammatory cells in human varicose saphenous vein. *Int J Angiol.* 2010;19:e73-77.
31. Davies AH. The seriousness of chronic venous disease: a review of real-world evidence. *Adv Ther.* 2019;36(suppl 1):5-12.

Discover the new website on Venous Diseases by SERVIER



- One point of access to evidence-based medical education in Phlebology and Proctology.
- Recent scientific news, interviews, and podcasts on hot topics by international experts.
- Library with videos, books, slide sets on anatomy, epidemiology, and pathophysiology, treatments, and surgical techniques.
- Links to a selection of articles, practical applications, and relevant websites on venous diseases.

... go to

vein-academy.servier.com





*At the forefront of research
and education in phlebology*

www.servier.com

Correspondent:

Servier Affaires Médicales - 35, rue de Verdun - 92284 Suresnes Cedex - France
Website: www.servier.com