

# PHOTOFRIN® (porfimer sodium) for Injection

## CASE STUDY: Advanced Obstructing, Bleeding Esophageal Adenocarcinoma

Courtesy of Omar Awais, MD  
Chief of Thoracic Surgery, Mercy Hospital  
University of Pittsburgh Medical Center

### PHOTOFRIN® (porfimer sodium) IS INDICATED FOR

Palliation of patients with completely obstructing esophageal cancer, or of patients with partially obstructing esophageal cancer who, in the opinion of their physician, cannot be satisfactorily treated with Nd:YAG laser therapy.

Treatment of microinvasive endobronchial non-small cell lung cancer (NSCLC) in patients for whom surgery and radiotherapy are not indicated.

Reduction of obstruction and palliation of symptoms in patients with completely or partially obstructing endobronchial NSCLC.

PHOTOFRIN® (porfimer sodium) is indicated for the ablation of high-grade dysplasia (HGD) in Barrett's esophagus patients who do not undergo esophagectomy.

### IMPORTANT SAFETY INFORMATION ABOUT PHOTOFRIN FOR INJECTION

Photodynamic therapy (PDT) with PHOTOFRIN is a two-stage process requiring administration of both drug and light in a properly equipped facility. Refer to the OPTIGUIDE™ instructions for use for complete instructions concerning the fiber optic diffuser.

PHOTOFRIN is contraindicated in patients with porphyria. PDT is contraindicated in patients with an existing tracheoesophageal or bronchoesophageal fistula and patients with tumors eroding into a major blood vessel. PDT is not suitable for emergency treatment of patients with severe acute respiratory distress caused by an obstructing endobronchial lesion because 40 to 50 hours are required between injection with PHOTOFRIN and laser light treatment. PDT is not suitable for patients with esophageal or gastric varices, or patients with esophageal ulcers >1 cm in diameter. Tracheoesophageal or bronchoesophageal fistula can occur if esophageal tumor is eroding into trachea or bronchial tree. Gastrointestinal perforation can occur. There is a high risk of bleeding in patients with esophageal varices and for fatal massive hemoptysis with endobronchial tumors that are: large, centrally located; cavitating; extensive, extrinsic to the bronchus. After treatment of high-grade dysplasia (HGD) in Barrett's esophagus (BE), monitor endoscopic biopsy every three months, until four consecutive negative evaluations for HGD have been recorded. Photosensitivity can be expected; ocular sensitivity is possible. Allow 2-4 weeks between PDT and subsequent radiotherapy. Substernal chest pain may occur after treatment. Treatment-induced inflammation can cause airway obstruction. Administer with caution to patients with tumors in locations where treatment-induced inflammation can obstruct the main airway. Esophageal stenosis occurs frequently after treatment of HGD in BE. Patients with hepatic or renal impairment may need longer precautionary measures for photosensitivity (possibly more than 90 days). Thromboembolic events can occur following photodynamic therapy with PHOTOFRIN.

**MOST COMMON ADVERSE REACTIONS** reported during clinical trials are:

**Esophageal Cancer:** Anemia, pleural effusion, pyrexia, constipation, nausea, chest pain, pain, abdominal pain, dyspnea, photosensitivity reaction, pneumonia, vomiting, insomnia, back pain, pharyngitis.

**Obstructing Endobronchial Cancer:** Dyspnea, photosensitivity reaction, hemoptysis, pyrexia, cough, pneumonia.

**Superficial Endobronchial Tumors:** Exudate, photosensitivity reaction, bronchial obstruction, edema, bronchostenosis.

**High-Grade Dysplasia in Barrett's Esophagus:** Photosensitivity reaction, esophageal stenosis, vomiting, chest pain, nausea, pyrexia, constipation, dysphagia, abdominal pain, pleural effusion, dehydration.

Inform patients to report adverse reactions. All patients who receive PHOTOFRIN will be photosensitive for at least 30 days and should be warned about this and counselled to take appropriate precautions. Laser treatment should not be given if an overdose of PHOTOFRIN is administered.

**FOR MORE INFORMATION ABOUT PHOTOFRIN** visit [www.Photofrin.com](http://www.Photofrin.com) or call Concordia Laboratories Inc. at 1-866-248-2039. You are encouraged to report negative side effects of prescription drugs to the FDA. Visit [www.fda.gov/medwatch](http://www.fda.gov/medwatch), or call 1-800-FDA-1088.

Please see full prescribing information for PHOTOFRIN.



## PATIENT HISTORY

This 73-year-old female complained of worsening heartburn and dysphagia with both solid and soft foods for a period of three to four months. Additionally, she was admitted to a local hospital with recent 13-pound weight loss and anemia. The patient had a history of hypertension, COPD, hyperlipidemia, depression, and GERD, and smoked two packs of cigarettes per day for the past 60 years. She did not use alcohol.

## EXAMINATION

The patient presented with stable vital signs and a body mass index of 28 kg/m<sup>2</sup>. She was clinically well and in no acute distress. Upon examination she had no palpable adenopathy, a soft abdomen, and normal neurologic and pulmonary exam.

## DIAGNOSTIC EVALUATION

Initial EGD examination revealed a partial obstructing bleeding esophageal tumor from 30-34, with extension to the gastric cardia. A moderate-sized hiatal hernia was also observed. PET Computed Tomography showed multiple lung masses:

1. A 6.3 x 6.1 cm mass in the posterior right lower lung with a Standardized Uptake Value (SUV) of 7.9 and extension to the right posterior pleural surface
2. A 2.66 x 2.1 cm mass in the superior segment left lower lung with an SUV of 3.5
3. A 1.2 cm mass in the upper lung with an SUV of 4.5
4. A 1.6 x 1.7 cm mass in the right lower lung with an SUV of 5.5
5. A 5 x 3.7 cm mass in distal esophagus extending into the fundus of the stomach with an SUV of 7.0

The Pet CT prompted additional biopsy of large right lung mass which were also positive for a second primary non-small cell lung carcinoma. There was no evidence of liver, adrenal, or osseous metastases. Pulmonary function tests were poor, with an FEV\* of 69-73% and a DLCO† of 35% (Figure 1).

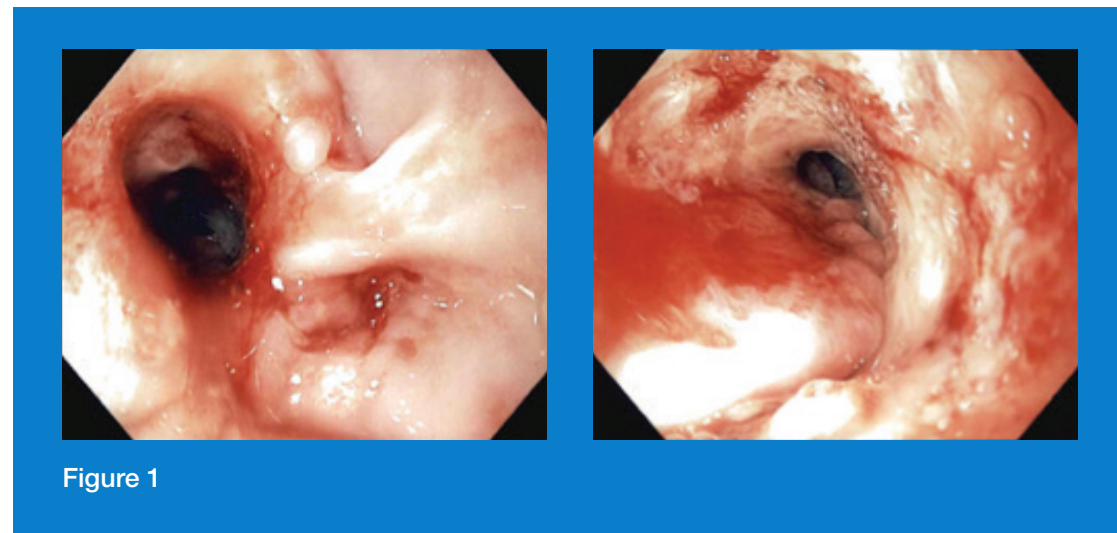


Figure 1

Figure 1 Endoscopy before PHOTOFRIN® (porfimer sodium) treatment.

## COURSE OF TREATMENT

During clinical staging, the patient was diagnosed with a bleeding, obstructing esophageal mass and a separate advanced lung primary. In the opinion of the treating physician, the patient could not be satisfactorily treated with Nd:YAG laser therapy. The patient was given PDT as a local modality to help improve her dysphagia and to control bleeding prior to initiating systemic therapy. The standard 2 mg/kg of PHOTOFRIN® (porfimer sodium) was administered intravenously. Forty-eight hours later, using a 5 cm diffusing fiber, the near obstruction bleeding distal esophageal tumor was treated at the energy setting of 300 Joules/cm<sup>2</sup> for 12.5 minutes with a nominal wavelength of 630 nm ± 3 nm. The same location was re-treated at 300 Joules/cm<sup>2</sup> two days later and the patient was discharged with a stable hemoglobin tolerating a soft diet (Figure 2).

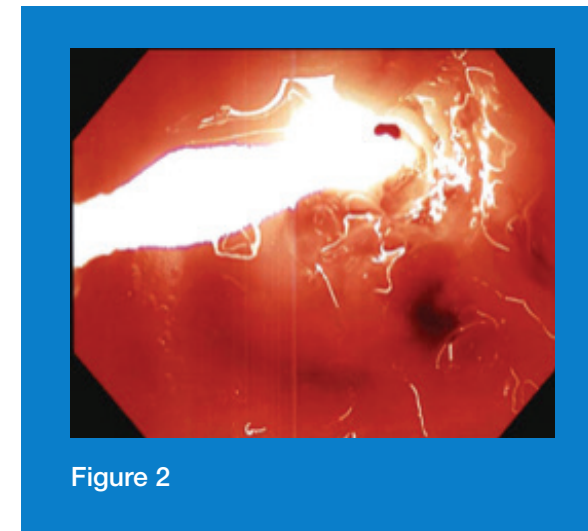


Figure 2

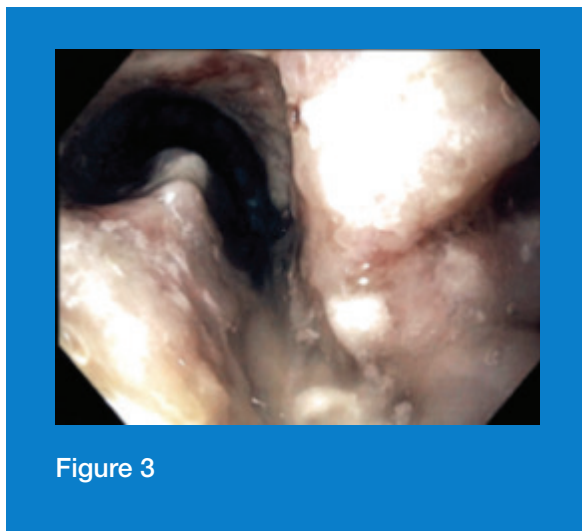
Figure 2 Endoscopy during PHOTOFRIN® (porfimer sodium) treatment.

\* FEV = Forced expiratory volume.

† DLCO = Diffusion lung capacity for carbon monoxide.

## CLINICAL OUTCOMES

During clinical follow-up two weeks after PDT treatment, the patient reported that her dysphagia was markedly improved. She was able to tolerate soft and hard solids without any difficulty and did not require the need for enteral access for nutritional supplementation. In addition, her hemoglobin and hematocrit was stable. The patient was subsequently referred to medical oncology for systemic treatment of her esophageal and lung carcinoma.



**Figure 3** Endoscopy after PHOTOFRIN® (porfimer sodium) treatment.

## DISCUSSION

This case provides a good demonstration of how PDT can be used as a local modality for advanced esophageal cancer. As in this patient, PDT can serve as a bridge to eventual definitive or palliative systemic therapy. Local treatment with PDT resulted in significant improvement in dysphagia and control of bleeding, and avoided a feeding tube in an otherwise nonsurgical candidate. Improvement of dysphagia and control of bleeding from both an obstructing and friable tumor is fairly rapid with PDT. This allows the patient to resume adequate oral intake to remain nutritionally sound. Proper patient selection is a critical step to help achieve optimal patient outcome.

The information contained in this case study has been supplied by the medical professional whose name appears here. The advice, opinion, statements, materials and other information expressed and contained in this case study are from the authors and reflect their personal experience with the specific patient. Results may vary. Pinnacle Biologics, Inc. makes no claim that similar treatment will result in a similar outcome.

**Please see accompanying Important Safety Information within sales aid and full Prescribing Information for PHOTOFRIN® (porfimer sodium).**

**FOR MORE INFORMATION ABOUT PHOTOFRIN** visit [www.Photofrin.com](http://www.Photofrin.com) or call Concordia Laboratories Inc. at 1-866-248-2039. You are encouraged to report negative side effects of prescription drugs to the FDA. Visit [www.fda.gov/medwatch](http://www.fda.gov/medwatch), or call 1-800-FDA-1088.

PHOTOFRIN® (porfimer sodium) and OPTIGUIDE™ are registered trademarks of Concordia Laboratories Inc. Pinnacle Biologics™ and the logo of Pinnacle Biologics™ are trademarks of Pinnacle Biologics, Inc. PHOTOFRIN® is manufactured by Jubilant Hollisterstier General Partnership for Concordia Laboratories Inc. and distributed in the United States by Pinnacle Biologics, Inc.

Concordia Laboratories Inc. St. Michael, Barbados BB11005

See more at: <http://www.photofrin.com/healthcare-professional-home/#sthash.FlnUv0e7.dpuf>

PINMAR003 7/2015 All rights reserved.

