

Histopathological Observation In Liver And Gill Of *Tachysurus sona* From Kuduvaayar Estuary At Nagapattinum.

G. Vanthana# and A.S. Paul Ravindran*

#Research Scholar, Department of Zoology, T. B.M.L College, Porayar, Nagapattinum
District, Tamil Nadu, India

*Associate Professor, Department of Zoology, T. B.M.L College, Porayar, Nagapattinum
District, Tamil Nadu, India

Abstract:

Histology is that the microscopic study of animal and plant cell and tissues through staining and sectioning and examining them below a magnifier (electron or lightweight microscope). There square measure numerous ways won't to study tissue characteristics and microscopic structures of the cells. Microscopic anatomy studies square measure utilized in rhetorical investigations, autopsy, and diagnosis and in education. Additionally, microscopic anatomy is employed extensively in medication particularly within the study of pathological tissues to help treatment. The aim of this work was to attempt to assess the histological lesions in the gills and liver of *Tachysurus sona*.

Keywords: *Tachysurus sona*, Liver, Gill, Histology

INTRODUCTION

Histology is that branch of anatomy that studies tissues of animals and plants. In its broader facet, the word microscopic anatomy is employed as if it were a equivalent word for anatomy, as a result of its subject material encompasses not solely the microscopic structure of tissues however conjointly that of the cell, organs, and organ systems (Au, 2004). The body is composed of cells, intercellular matrix, and a fluid substance, extracellular fluid (tissue fluid), which bathes these components (Rocha and Monteiro, 1999). Extracellular fluid, which is derived from plasma of blood, carries nutrients, oxygen, and signaling molecules to cells of the body. Conversely, signaling molecules, waste products, and carbon dioxide released by cells of the body reach blood and lymph vessels by way of the extracellular fluid. Extracellular fluid and much of the intercellular matrix are not visible in routine histological preparations, yet their invisible

presence must be appreciated by the student of histology (Selvanatha *et al.*, 2012). In this study evaluated the histological lesions in the gills and liver of *Tachysurus sona*.

MATERIALS AND METHODSD

Study area:

The study was carried out at in carried out at in Kuduvaaiyar estuary at Nagapattinum (Lat 10.45'N; Long 79.51'E) located along the Southeast coast of India in Nagapattinum district, Tamil Nadu, Southern India. The fish *Tachysurus sona* collected from this area

Histological study:

The important organs as gill and liver of *Tachysurus sona* were removed and fixed in aqueous bruins fixativefor 10-12 hours. For block making parafix –wax of melting point 58-0°C was used. The sections were cut at 5µ thickness and stained in haemotoxylin. It was counter stained with eosin for microscopic observations.

RESULT AND DISCUSSION

Aquatic ecosystems are exposed to excessive input of pollutants and contaminants from various sources like domestic and industrial sewage, agricultural processes, heavy metals and others. The uncontrolled discharge of these compounds into the water directly affects aquatic organisms, including fish, which are considered a bioindicator of environmental pollution or contamination (Lins *et al.*, 2010) Bioindicators are sentinel species used as primary indicators of abiotic or biotic changes presented by a certain environment in the presence of pollutants (Ramade *et al.*, 1998). Changes in organs of fish, such as the gills and liver are good biomarkers of water contamination. Biomarkers are biological indicators showing the effects resulting from exposure to a stressor, and can be identified by biochemical, cellular, histological and behavioral changes. Gills and liver of fish are extremely sensitive to chemical and physical modifications in the environment, mainly because of the large surface of the respiratory epithelium, high perfusion rate and detoxification that facilitate the entry of pollutants into this tissue (Hinton *et al.*, 1992; Poleksic *et al.*, 1994; Arellano *et al.*, 1994; Cerqueira *et al.*, 2002)

Additionally, histological biomarkers provide powerful tools to detect and characterize the biological end points of toxicant and carcinogen exposure. One of the highest advantage of using histopathological biomarkers in biological monitoring is that they permit examining exact target organs that are responsible for energetic functions,

such as respiration, excretion, accumulations and biotransformation of xenobiotic (Velkova-Jordanoska and Kotoski, 2005). Numerous xenobiotics stimulate the action of definite enzymes that modify metabolism, further leading to apoptosis initially demonstrating as necrosis with inflammatory protective reactions (Velkova-Joudanoska, 2005; Roganovic-Zafirova and Jordanova, 1998; Roganovic-Zafirova *et al.*, 2003).

Liver and gills are the main organs for metabolism and respiration and these organs are also target organs for contaminant accumulation resulting in structural damage to organs and tissues. Untreated sewage effluents are reported to increase significantly the impact on aquatic ecosystems, decreasing the species diversity in different regions of the world (Adams *et al.*, 2002). The tolerance of wild organisms to toxicants in domestic effluents may vary among species and their integrative effects may lead to reproductive failure or reduction of the fish species number. Many researchers have reported the degenerative changes in selected tissues of the fishes in response to different kinds of toxicants (Afifi *et al.*, 2014; Vasanthi *et al.*, 2013) . In the present study showed the gills of fish from contaminated areas showed secondary lamellar disorganization, rupture of lamellar epithelium and hemorrhage (Fig 1).

Histological changes observed in various studies in liver taken from the fishes exposed to pollutants include increased vacuoles in the cytoplasm, changes in nuclear shapes, focal area of necrosis (death of cells in a localized area), ischemia (blockage of capillary circulation), hepatocellular shrinkage, and regression of hepatocytic microvilli at the bile canaliculi, fatty degeneration and loss of glycogen. In the present study showed that the hepatocytes lose their normal boundaries. There were cellular and nuclear degeneration cytoplasmic vaculation and inflammatory infiltration (Fig 2).

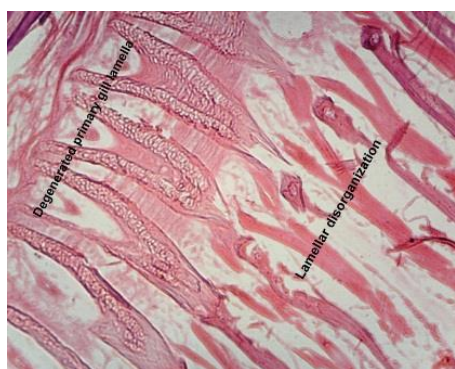


Fig 1 Gill

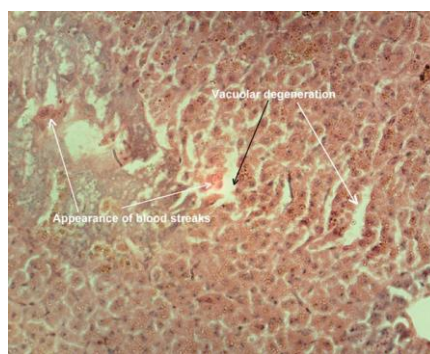


Fig 2 Liver

CONCLUSION

In the present study concluded that the environmental contamination of Kuduvaayar estuary induced several histopathological alterations in gill and liver tissues of *Tachysurus sona*. This study showed that contamination of Kuduvaayar estuary directly affects fish health.

References

Adams SM, *Biological indicators of aquatic ecosystem stress. American Fisheries Society.* 2002; 3:104-112.

Afifi M, Alkaladi A, Abu-Zinada O, Zahed Z. *Histopathological and ultrastructural alterations in skin, gills, liver and muscle of *Siganus canaliculatus* and *Epinephelus morio* caught from Jeddah and Yanbu coast as bioindicators of oil hydrocarbon pollution. Life Science Journal.* 2014; 11(8):880-888.

Arellano, J.M.; Storch, V.; Sarasquete, C. *Histological changes and copper accumulation in liver and gills of the Senegales Sole, *Solea senegalensis*. Ecotoxicol. Environ. Safety* 1999, 44, 62–72.

Arellano, J.M.; Storch, V.; Sarasquete, C. *Histological changes and copper accumulation in liver and gills of the Senegales Sole, *Solea senegalensis*. Ecotoxicol. Environ. Safety* 1999, 44, 62–72.

Au DWT. *The application of histo-cytopathological biomarkers in marine pollution monitoring; A review. Mar. Poll. Bull.,* 2004; 48: 817-834.

Cerqueira, C.C.C.; Fernandes, M.N. *Gill tissue recovery copper exposure and blood parameter responses in the tropical fish *Prochilodus scrofa*. Ecotoxicol. Environ. Safety* 2002, 52, 83–91.

Cerqueira, C.C.C.; Fernandes, M.N. *Gill tissue recovery copper exposure and blood parameter responses in the tropical fish *Prochilodus scrofa*. Ecotoxicol. Environ. Safety* 2002, 52, 83–91

Hinton, D.E. *Histopathological biomarkers. In Biomarkers: Biochemical, Physiological and Histological Markers of Anthropogenic Stress; Huggett, R.J., Kimerli, R.A., Mehrle, P.M., Bergman, H.L., Eds.; Lewis Publishers: Boca Raton, FL, USA, 1992; pp. 155–210.*

Hinton, D.E. *Histopathological biomarkers. In Biomarkers: Biochemical, Physiological and Histological Markers of Anthropogenic Stress*; Huggett, R.J., Kimerli, R.A., Mehrle, P.M., Bergman, H.L., Eds.; Lewis Publishers: Boca Raton, FL, USA, 1992; pp. 155–210.

Lins, J.A.P.N.; Kirschnik, P.G; Queiroz, V.S.; Cirio, S.M. *Uso de peixes como biomarcadores para monitoramento ambiental aquático. Rev. Acad. Ciên. Agrár. Ambient.* 2010, 8, 469–484.

Poleksic, V.; Mitrovic-Tutundzic, V. *Fish gills as a monitor of sublethal and chronic effects of pollution. In Sblethal and Chronic Effects of Pollutants on Freshwater Fish*; Muller, R., Lloyd, R.,Eds.; Oxford, Fishing News Books: Osney, England, 1994; pp. 339–352.

Poleksic, V.; Mitrovic-Tutundzic, V. *Fish gills as a monitor of sublethal and chronic effects of pollution. In Sblethal and Chronic Effects of Pollutants on Freshwater Fish*; Muller, R., Lloyd, R., Eds.; Oxford, Fishing News Books: Osney, England, 1994; pp. 339–352.

Ramade, F. *Dictionaire Encyclopédique Des Sciences De L' Eau, 2nd ed.*; Ediscience International: Paris, France, 1998.

Rocha E, Monteiro RAF. *Histology and cytology of fish liver: A review.*In: Saksena, D.N. (ed.) *ichthyology: Recent research advances. Science publishers, Enfield, New Hampshire.* 1999; 321-344.

Roganovic-Zafirova D, Jordanova M. *Histopathological analyses of liver from ohrid roach (Rutilus rubilio ohridanus) collected in Grasnica a contaminated site of Lake Ohrid. Special Issues of Macedonian Ecological Society,* 1998; 5(1-2): 530-544.

Roganovic-Zafirova D, Jordanove M, Panov S, Velkova-Jordanozka L. *Hepatic capillariasis in the Meiterranean barbell Barbus meridionalis petenyi (Heek) form lake ohrid. Folia Veterinaris.* 2003; 47(1): 35-37.

Selvanathan J, Vincent S, Nirmala A. *Histopathology changes in freshwater. Fish Clarias batrachus (Linn.) exposed to mercury and cadmium. International Journal of life Science and Pharma Research.* 2012; 3: 11-21.

Vasanthi LA, Revathi P, Mini J, Natesan MN. Integrated use of histological and ultrastructural biomarkers in Mugil cephalus for assessing heavy metal pollution in Ennore estuary, Chennai, Chemosphere. 2013; 91:1156-1164

Velkova-Jordanoska L, Kotoski G. Histopathologic analysis of liver in fish (Barbus meridionalis petenyi Heckel) in reservoir Trebenista. Nat. Crout., 2005; 14(2): 147-153.