

CLINICAL VIGNETTE

A Slow and Quiet Day on the Block: A Case of Third-Degree Heart Block Presenting as Asymptomatic Bradycardia

Jonathan R. Young and Eric T. Cheng, M.D.

Learning Objectives

1. Recognize asymptomatic bradycardia as a rare presentation of third-degree heart block in adults
2. Review the various presentations and underlying etiologies of third-degree heart block
3. Understand the indications for pacemaker placement in patients with third-degree heart block

Case Presentation

An 89-year-old male presents for a second opinion after his outside cardiologist had recommended the placement of a pacemaker. The patient's past history was remarkable for hypertension and he denied any

chest pain, palpitations, dizziness, syncope, or shortness of breath. His medications included baby aspirin, an unknown anti-hypertensive medication, and potassium chloride. He was a lifelong non-smoker and denied any alcohol consumption or illicit drug use.

On physical examination, blood pressure was 131/65 mmHg, his pulse was 47 beats/min, and there were no significant orthostatic changes. In addition to the bradycardia, the cardiac examination revealed a regularly irregular heart rhythm that skipped every third beat. There were no murmurs or gallops. Thyroid examination was normal. Laboratory testing revealed potassium 4.3 mmol/L, creatinine 0.73 mg/dL, calcium 8.7 mg/dL, total cholesterol 176 mg/dL, triglycerides 68 mg/dL, HDL 62.6 mg/dL, LDL 100 mg/dL, glucose 103 mg/dL, HbA1C 6.2%, and TSH 3.16 uIU/L. A 12-lead electrocardiogram (**Figure 1**) revealed third-degree heart block with complete atrioventricular dissociation. The QRS complexes were narrow (128 ms) with a right bundle branch block morphology and poor R wave progression in the precordial leads. There was an occasional premature ventricular contraction, but no signs of acute ischemia. The QT/QTc interval was prolonged at 608 ms/486 ms.

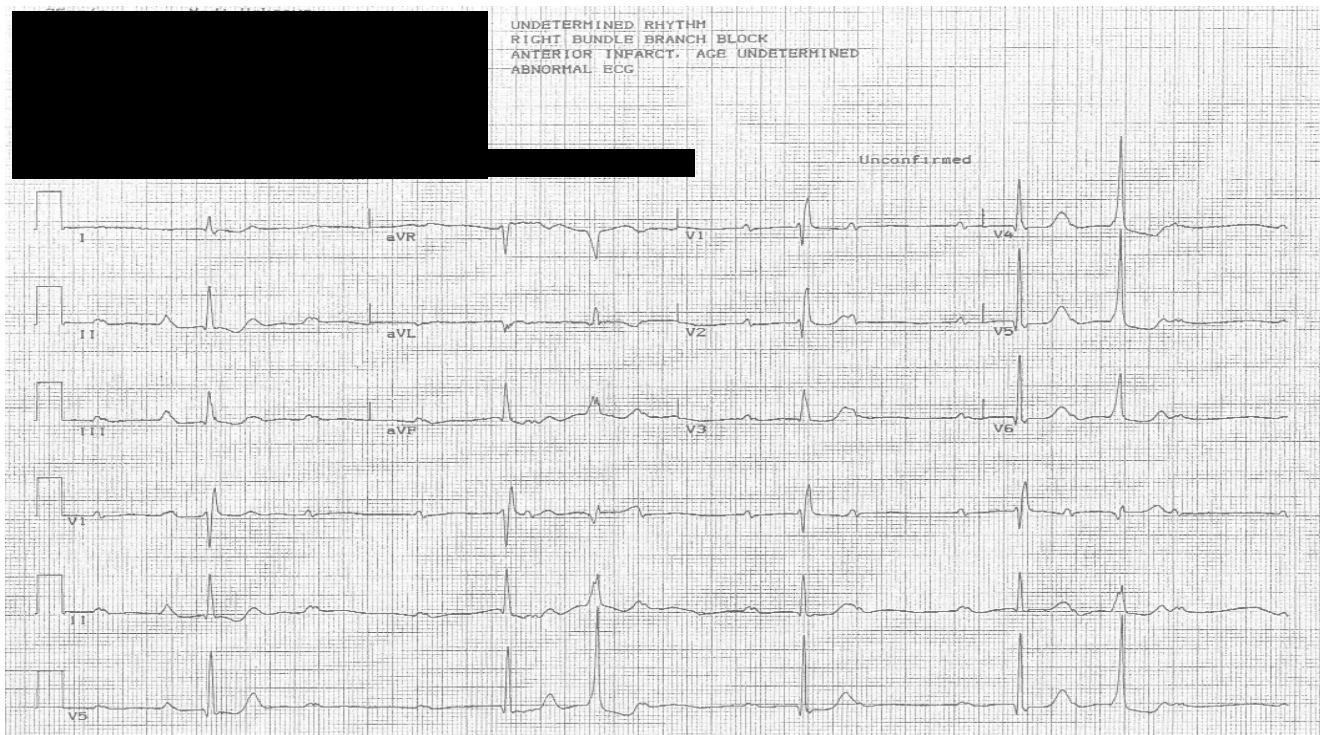


Figure 1.

Discussion

Third-degree heart block is also known as complete atrioventricular dissociation. Because of a conduction block in either the atrioventricular node or the His-Purkinje system, electrical impulses are not transmitted from the atria to the ventricles. On an electrocardiogram, the P waves do not correlate with the QRS complexes.¹ Thus, the PR interval is inconsistent.

Since electrical signals are not transmitted from the atria to the ventricle, an escape rhythm is required for ventricular contraction. In junctional escape, the QRS complexes are narrow, and the pulse rate is between 40 and 60 beats per minute.¹ With a ventricular escape rhythm, the QRS complexes are wide, and the pulse rate is between 20 and 40 beats per minute.¹

Patients with complete atrioventricular dissociation typically experience hypotension, palpitations, dizziness, syncope, dyspnea, or angina.^{1,2} Third-degree heart block is dangerous because of the potential for degeneration to an unstable ventricular rhythm, such as ventricular tachycardia or ventricular fibrillation.

Asymptomatic third-degree heart block in adults is extremely rare. Kojic et al. found that the prevalence of complete atrioventricular dissociation among adults² between the ages of 33 and 79 is 0.04%. Furthermore, all of the patients in their study with complete atrioventricular dissociation were symptomatic. Because it is so rarely reported, the precise percentage of adults with third-degree heart block who remain asymptomatic is unknown. We conducted an extensive literature search using PubMed in an attempt to answer to this question, using the following search terms: "asymptomatic complete atrioventricular block," "symptomatic complete atrioventricular block," "asymptomatic third-degree heart block," "symptomatic third-degree heart block," "asymptomatic third-degree AV block," "symptomatic third-degree AV block," "asymptomatic third-degree AV dissociation," and "symptomatic third-degree AV dissociation." We were unable to locate any studies reporting the percentage of adults with third-degree heart block without symptoms.

The causes of complete atrioventricular dissociation are presented in **Figure 2**. Third-degree heart block can result from infections, drugs, toxins, autoimmune

Causes of Complete Atrioventricular Dissociation	
Transient, Reversible	Persistent Causes
Metabolic abnormalities	Autoimmune disorders
Hyperkalemia	Sarcoidosis
Hypothyroidism	Amyloidosis
Infection	Rheumatic fever
Lyme disease	Kawasaki disease
Bacterial infection	Dermatomyositis
Viral infection	Reactive arthritis
Drugs	Ankylosing spondylitis
Calcium channel blockers	Ischemia/infarction
Beta-blockers	Neuromuscular disorders
Clonidine	Myotonic muscular dystrophy
Digitalis	Becker muscular dystrophy
Procainamide	Kearns-Sayre syndrome
Quinidine	Erb dystrophy
Cocaine	Peroneal muscular atrophy
Organophosphates	Toxins
Phenytoin	Alcohol
Anti-psychotics	Congenital complete heart block
Tricyclic anti-depressants	

Figure 2.

disorders, ischemia/infarction, metabolic disorders, neuromuscular disorders, and congenital disorders.^{2,3} Congenital complete heart block, which has an incidence of 1 in every 20,000 live births, is a diagnosis of exclusion in adults.^{3,4} Sudden death can be the first manifestation of congenital complete heart block, particularly in older patients.⁴ In the elderly, the most common cause of complete atrioventricular dissociation is fibrous degeneration of the conducting system.² Fibrous degeneration typically occurs as a result of normal aging, hypertension, diabetes, and atherosclerosis.^{5,6}

The American College of Cardiology, the American Heart Association, and the Heart Rhythm Society published guidelines in 2008 regarding the placement of pacemakers in patients with third-degree heart block.⁷ A pacemaker is clearly indicated for all symptomatic patients and all patients with a ventricular tachyarrhythmia. For asymptomatic patients, a pacemaker is indicated if they have documented periods of asystole greater than or equal to 3 seconds, if they have a resting heart rate less than 40 beats per minute, or if they have a ventricular escape rhythm.⁷ Pacemaker placement is also indicated for asymptomatic patients with atrial fibrillation and bradycardia with periods of asystole greater than or equal to 5

seconds. Other indications for a pacemaker include catheter ablation of the atrioventricular junction, third-degree heart block as a result of a neuromuscular disorder, cardiomegaly, left ventricular dysfunction, exercise-induced atrioventricular block in the absence of myocardial ischemia, and postoperative third-degree heart block that is not expected to resolve after cardiac surgery.

The current guidelines also state that it is reasonable to place a pacemaker in asymptomatic patients with persistent third-degree heart block who have a resting heart rate greater than 40 beats per minute and no cardiomegaly. The guidelines do not make any recommendations regarding electrophysiologic studies prior to pacemaker placement. When managing asymptomatic patients, it is important to consider risk factors for sudden death. These risk factors include age, wide QRS complexes, and long QT intervals.^{3,4}

Conclusion

Our patient is an 89-year-old male with hypertension and asymptomatic third-degree heart block. There are several possibilities for the etiology of his complete atrioventricular dissociation. The most likely cause is fibrous degeneration of the electrical conduction system as a result of normal aging and hypertension. Another possible cause is his unknown anti-hypertensive medication. Beta-blockers, calcium channel blockers, and clonidine can sometimes lead to complete atrioventricular dissociation. However, we believe the patient's outside cardiologist had already taken the patient off of any potentially offending agents. A far less likely cause is congenital complete heart block. He may have been asymptomatic his entire life. Congenital complete heart block, however, is unlikely because 90% of children with this disorder become symptomatic within 30 years.⁸

According to the guidelines published by the American College of Cardiology, the American Heart Association, and the Heart Rhythm Society, it is reasonable to place a pacemaker in this patient. Furthermore, he has 2 risk factors for sudden cardiac death: his advanced age and a prolonged QT interval. Taking these risk factors into consideration, pacemaker placement is appropriate for this patient. We concurred with his cardiologist's recommendation for a pacemaker and encouraged the patient to follow up promptly.

REFERENCES

1. **Jacobson C.** Understanding atrioventricular blocks, part II: high-grade and third-degree atrioventricular blocks. *AACN Adv Crit Care.* 2009 Jan-Mar;20(1):112-6.
2. **Kojic EM, Hardarson T, Sigfusson N, Sigvaldason H.** The prevalence and prognosis of third-degree atrioventricular conduction block: the Reykjavik study. *J Intern Med.* 1999 Jul;246(1):81-6.
3. **Sherman SC, Holmes M.** Third degree heart block in a young man. *J Emerg Med.* 2005 Nov;29(4):479-81.
4. **Gobeil F, Labbé AC, LePage S.** Congenital complete atrioventricular block: asymptomatic at 38 years. *Can J Cardiol.* 1996 Mar;12(3):297-9.
5. **Panja M, Dutta AL, Kar AK, Panja S, Chhetri MK.** Cardiac changes implicated in chronic heart block. *J Assoc Physicians India.* 1991 Sep;39(9):698-701.
6. **Sims BA.** The pathogenesis of chronic heart block. *Ir J Med Sci.* 1971; 140:479-490.
7. **Epstein AE, DiMarco JP, Ellenbogen KA, Estes NA 3rd, Freedman RA, Gettes LS, Gillinov AM, Gregoratos G, Hammill SC, Hayes DL, Hlatky MA, Newby LK, Page RL, Schoenfeld MH, Silka MJ, Stevenson LW, Sweeney MO, Smith SC Jr, Jacobs AK, Adams CD, Anderson JL, Buller CE, Creager MA, Ettinger SM, Faxon DP, Halperin JL, Hiratzka LF, Hunt SA, Krumholz HM, Kushner FG, Lytle BW, Nishimura RA, Ornato JP, Page RL, Riegel B, Tarkington LG, Yancy CW; American College of Cardiology/American Heart Association Task Force on Practice Guidelines (Writing Committee to Revise the ACC/AHA/NASPE 2002 Guideline Update for Implantation of Cardiac Pacemakers and Antiarrhythmia Devices); American Association for Thoracic Surgery; Society of Thoracic Surgeons. ACC/AHA/HRS 2008 Guidelines for Device-Based Therapy of Cardiac Rhythm Abnormalities: a report of the American College of Cardiology/American Heart Association Task Force on Practice Guidelines (Writing Committee to Revise the ACC/AHA/NASPE 2002 Guideline Update for Implantation of Cardiac Pacemakers and Antiarrhythmia Devices) developed in collaboration with the American Association for Thoracic Surgery and Society of Thoracic Surgeons. *J Am Coll Cardiol.* 2008 May 27;51(21):e1-62. Erratum in: *J Am Coll Cardiol.* 2009 Jan 6;53(1):147. *J Am Coll Cardiol.* 2009 Apr 21;53(16):1473.**
8. **Michaëlsson M, Jonzon A, Riesenfeld T.** Isolated congenital complete atrioventricular block in adult life. A prospective study. *Circulation.* 1995 Aug 1;92(3):442-9.

Submitted on October 19, 2009.