

Treatment of Cervicothoracic Pain and Cervicogenic Headaches with Regenerative Injection Therapy

by

Felix S. Linetsky, MD
Rafael Miguel, MD
Francisco Torres, MD

Reprinted from

Current Pain and Headache *Reports*

Published by Current Science, Inc., Philadelphia
Volume 8, Number 1, February 2004, pp. 41-48

Editor: Stephen D. Silberstein
Co-Editor: Lawrence C. Newman

Treatment of Cervicothoracic Pain and Cervicogenic Headaches with Regenerative Injection Therapy

Felix S. Linetsky, MD, Rafael Miguel, MD, and Francisco Torres, MD*

Address

Assistant Professor, Department of Anesthesiology, University of South Florida, Tampa, Florida

Clinical Associate Professor, Department of Osteopathic Principles, Nova Southeastern College of Osteopathic Medicine

Private Practice

34672 US 19 N, Palm Harbor, FL, USA.

E-mail: prolopain@aol.com

Current Pain and Headache Reports 2004, 8:1, 41-48

Current Science Inc. ISSN 1531-3433

Copyright © 2004 by Current Science Inc.

Significant progress has been made in interventional pain management. Despite this progress, patients continue to present a diagnostic and therapeutic challenge. Steroidal and nonsteroidal anti-inflammatory medications have limited use in degenerative painful conditions of connective tissue. Regenerative injection therapy, also known as prolotherapy, is a viable, type-specific treatment for such pathology. Several placebo-controlled studies, together with uncontrolled studies, indicate the effectiveness of regenerative injection therapy in treating painful ligament and tendon pathology. As stated in July 2003 by Mooney, this treatment has advanced "from the fringe to the frontier of medical care".

Introduction

Advances in interventional pain management have been largely based on fluoroscopically guided diagnostic and therapeutic procedures. Many of the newly devised therapeutic techniques are a variety of heat-emitting devices producing thermomodulation of collagen. Their common limitations are the size of the probe, difficulty to navigate the probe to all areas of pathology, and the danger of raising the temperature in proximity to vital structures. Injection of solution that can chemomodulate collagen and penetrate the areas of pathology is a viable alternative or adjunct to thermomodulation. Regenerative injection therapy (RIT) meets these requirements. The published pain patterns in the cervicothoracic region from ligaments, muscles, intervertebral discs, and synovial joints overlap significantly [1-10]. Despite the progress made, patients continue to be differential diagnostic and

therapeutic challenges. RIT, also known as prolotherapy, is an interventional technique for chronic pain caused by connective tissue diathesis [11]. This article addresses the diagnostic and therapeutic approaches to cervicothoracic pain and cervicogenic headaches related to the pathology of fibrous collagenous connective tissue such as ligaments and tendons that could benefit from RIT.

Evolution of Terminology

Before the 1930s, this treatment was called "injection treatment" with the addition of a pathologic descriptor, such as injection treatment of hydrocele [12] or injection treatment of varicose veins. Biegeleisen [13] coined the term "sclerotherapy" in 1936.

Concluding that sclerotherapy implied scar formation, Hackett [3] coined the term prolotherapy as "the rehabilitation of an incompetent structure by the generation of new cellular tissue." Understanding of basic science and the healing process is such that regeneration and repair extend beyond the proliferative stage. The regenerative/repairative healing process consists of three overlapping phases: inflammatory, proliferative with granulation, and remodeling with contraction.

Regenerative injection therapy was coined because it is a more appropriate nomenclature for the treatment modality that induces natural healing [11,14-16,17••].

Regenerative injection therapy induces chemomodulation of collagen by repetitive stimulation of inflammatory and proliferative stages that lead to tissue regeneration and repair. This process is mediated by hormones and numerous growth factors, thus increasing tensile strength, elasticity, mass, and load-bearing capacity of collagenous connective tissues. This renders RIT a type-specific treatment for painful chronic tendinosis, ligamentosis, enthesopathy, and ligament laxity [11,14-16,17].

Local Anesthetics in Differential Diagnosis

Differential diagnosis of musculoskeletal pain based on infiltration of procaine at the fibro-osseous junctions was pioneered in the 1930s by Leriche [11,14,17], Steindler and Luck [18], and Soto-Hall and Haldeman [19]. They understood that posterior primary rami provide sensory supply to muscles, tendons, thoracolumbar fascia,

ligaments, aponeuroses, and their origins and insertions. No definite diagnosis could be made based on clinical presentation alone. The following criteria were established to prove a causal relationship between the structure and pain symptoms: reproduction of local and referral pain by needle contact, suppression of local tenderness, and referral/radiation pain by procaine infiltration [18].

The same basic principles have been employed over all of the anatomic areas since the inception of RIT. Local anesthetic diagnostic blocks are the best available objective confirmation of the precise source of pain in clinical diagnosis [4-11,17••,18-20].

Pathophysiologic Considerations

Ligaments and tendons are fibrous collagenous tissue that has a crimped, wave-like appearance under a light microscope. This crimped pattern unfolds during the initial loading of collagen [17••,21,22]. When elongated up to 4% of original length, ligaments and tendons return to their original crimped wave appearance. Beyond 4% elongation, they lose elasticity and become permanently lax, causing joint hypermobility. In degenerated ligaments, subfailure was reported at earlier stages of elongation. At best, natural healing may restore connective tissue to its pre-injury length, but only 50% to 75% of its pre-injury tensile strength [17•,22,23,24].

Three types of nerve terminals in posterior spinal ligaments have been confirmed microscopically. They are the free nerve endings, the Pacini and the Ruffini corpuscles. A sharp increase in the quantity of free nerve endings at the spinous processes attachments (enthesis) were documented [24].

Collagenous tissues are deleteriously affected by nonsteroidal anti-inflammatory drugs (NSAIDs), steroid administrations, inactivity, and denervation. The administration of even a single dose of corticosteroids directly into the ligaments or tendons can have debilitating effects on their strength [22,25-27]. In the presence of repetitive microtrauma with insufficient time for recovery, the use of NSAIDs and steroids, tissue hypoxia, metabolic abnormalities and other less defined causes, connective tissue diverts toward a degenerative pathway [22,23,25-28]. Therefore, a judicious use of anti-inflammatory therapy continues to be a useful, albeit adjunctive, therapy [26].

Collagenous tissue response to trauma is inflammatory/regenerative/reparative and varies with the degree of injury. In the presence of cellular damage, regenerative pathway takes place; in the case of extracellular matrix damage, a combined regenerative/reparative pathway takes place. Both are controlled by hormones and chemical and growth factors [22,23••,25-28]. Central denervation, such as in quadriplegia, leads to a statistically high, accelerated degeneration [27]. Radiofrequency procedures may not be an exception. Corticosteroids do not arrest or slow the course of degenerative process.

Neoneurogenesis and neovasculogenesis are integral components of degeneration. Nerve and vascular tissue ingrowth into degenerated intervertebral discs, posterior spinal ligaments, and hard nodules of fibromyalgia, together with neuropeptides in the facet joint capsules, have been documented [29-31].

Rationale

The rationale for RIT in chronic painful pathology of ligaments and tendons evolved from clinical, experimental, and histologic research performed for injection treatment of hydrocele and hernia. In hydrocele, hypertrophied subserous connective tissue layer reinforced capillary walls and prevented further exudate formation. The same principle is employed in the treatment of chronic bursitis. In hernias, proliferation and subsequent regenerative/reparative response leads to fibrotic closure of the defect [12-16,17••]. A similar ability to induce a proliferative regenerative repetitive response in ligaments and tendons was demonstrated in experimental and clinical studies, with a 65% increased diameter of collagen fibers [3,13,32,33,34].

Clinical Anatomy in Relation to Regenerative Injection Therapy

The shape of a human body is irregularly tubular. This shape, cross-sectionally and longitudinally, is maintained by continuous compartmentalized fascial stacking that incorporates, interconnects, and supports various ligaments, tendons, muscles, and neurovascular and osseous structures. Collagenous connective tissues, despite slightly different biochemical content, blend at their boundaries and at the osseous structures, functioning as a single unit [11,17••,21,35]. This arrangement provides bracing and a hydraulic amplification effect to the muscles, increasing contraction strength up to 30% [36••].

Movements of the spine and cranium are accomplished through various well-innervated joints, which are located in the anterior, middle, and posterior columns. These joints are syndesmotomic, synovial, and symphyseal. Syndesmotomic joints are anterior and posterior longitudinal ligaments, anterior and posterior atlanto-occipital membranes, supraspinous and interspinous ligaments, and ligamentum flavum. Symphyseal joints are intervertebral discs. Synovial joints are atlanto-axial (AA), atlanto-occipital (AO), zygapophyseal (z-joint), costovertebral and costovertebral [21]. Differential diagnosis is based on understanding of the regional and segmental anatomy, pathology, and segmental innervation of the compartments and their contents around the spine, which is provided by ventral and dorsal rami [6,11,17••,21,35,36••]. Prevailing trends in diagnostic efforts address discogenic, facetogenic, and neurocompressive components of spinal pain. Consequently, therapy is directed toward neuromodulation or neuroablation with radiofrequency generators or corticosteroid injections [20]. Cervical z-

joints are responsible for 54% of chronic neck pain after whiplash injury; the prevalence may be as high as 65% [37]. In patients with headaches after whiplash, more than 50% of the headaches stem from the C2-C3 z-joint [20,37]. Intra-articular corticosteroid injections are ineffective in relieving chronic cervical z-joint pain [38]. The previous data strongly suggest that there is a presence of nociceptors other than z-joints and intervertebral discs [17••,20,37,38]. For unexplained reasons, syndesmotic joints are excluded from the differential diagnosis by the interventional pain community.

Pain patterns from synovial joints at the craniocervical junction overlap with pain patterns from lower z-joints and suboccipital soft tissues [3-7,17••]. Their contribution to nociception requires confirmation with intra-articular blocks under fluoroscopic guidance by a practitioner with a significant amount of experience [7,17••,39,40].

In the mid-cervical area, putative medial branches of dorsal rami (MBDRs) are blocked at the waist of the articular pillars as the initial step in the differential diagnosis for z-joint pain [6,20,37]. This trend is based on the assumption that the anatomy and course of the MBDR is constant. [6,20]. However, ongoing research and microdissections of Willard indicate that bifurcations into medial and lateral branches are not consistent in their location and may originate in the intertransverse space or the projection of lateral or posterior aspects of articular pillars. The course of the medial (MBDR) and lateral branches (LB) often is parallel at the waists of the articular pillars, with the medial branch (MBDR) being proximal to the osseous structure [17••,35]. The MBDR furnishes twigs to z-joint capsules and continues along the lamina and spinous process toward its apex, innervating structures inserting or originating at the lamina and the spinous process on its course [17••,35]. Therefore, MBDR block at the waists of the articular pillars may be misleading as the initial step in the differential diagnosis because it interrupts orthodromic and antidromic transmission at its proximal segment, excluding other putative nociceptors located distally on its course [17••,35]. Floating dorsal rami frequently are present in the cervical and thoracic regions, sometimes descending from the level of C2-C3 to C6-C7 and from C6-C7 to the level of T4-T5, the latter "so-called" causes of thoracic pain of cervicogenic origin [17••,35].

Musculature of the suboccipital region (rectus capitis posterior minor and major, inferior and superior oblique, semispinalis capitis, and synovial articulations) are supplied by the first dorsal ramus (DR), which has an ascending branch connecting with the greater and lesser occipital nerves [17••,21,35]. The second cervical DR also supplies the inferior oblique, connecting with the first cervical DR. The second MBDR is the greater occipital nerve, which pierces the semispinalis capitis and trapezius at their insertion to the occipital bone and then connects with branches from the third occipital nerve, supplying the skin of the skull up to the vertex. All of them may

contribute to occipital and suboccipital headaches [17••,21,30,35].

Cervical MBDRs, beginning from C2-C3, caudally supply the semispinalis cervicis and capitis, multifidi, interspinalis, splenius, trapezius, supraspinous, interspinous ligaments, ending in the skin [17••,21].

Lateral branches supply the iliocostalis, longissimus cervicis, and longissimus capitis. Similar innervation patterns are observed in the thoracic region [21,35].

Variations in individual innervation makes anesthetization of the structures or their components an easier task than blocking the nerve supply because both are accomplished with the same injection. The actual technique and safe injection sites are described further in this article.

The proposed and postulated RIT mechanism of action is complex and multifaceted [3,15,17••,23,36,41,42••,43] (Table 1). Indications for RIT are listed in Table 2.

The syndromes and conditions representing a multietiological connective connective tissue diathesis with common pathogenesis treated with RIT are listed in Table 3 [3,10-16,17••,23,36,39-41,42••,43].

General contraindications are those that are applicable to all of the injection techniques. A list of these general contraindications is presented in Table 4.

Clinical Presentation and Evaluation

There is a wide variety of presenting complaints from headaches, neck pain, pain between the shoulders, occipital and suboccipital pain, and any combination of these symptoms. The intensity, duration, and quality of pain is variable and the onset may be sudden or gradual. The evaluation may reveal postural abnormalities, functional asymmetries, combinations of kyphoscoliosis, flattening of cervical and lumbar lordosis, arm, or leg length discrepancies. A wide range of increased or restricted passive and active range of motion may be present. Contractions against resistance usually reproduce pain.

The most reliable objective clinical finding is tenderness at the fibro-osseous junction (enthesis). The areas of tenderness are identified and marked and become the subject of needle probing "needling" and infiltration with local anesthetic. Initial needle placement at the fibro-osseous junction usually reproduces the pain that becomes worse on infiltration of local anesthetic, which usually subsides within 15 seconds after infiltration. Abolishment or persistence of tenderness or local or referred pain concludes the clinical examination and becomes the basis for clinical diagnosis [4,17••,23,36,42••,44].

Radiologic Evaluation Prior to Regenerative Injection Therapy

Plain radiographs are of limited diagnostic value in painful pathology of the connective tissue, but may detect structural or positional osseous abnormalities, such as anterior or posterior listhesis on flexion/extension lateral

views and degenerative changes in general with deformity of z-joints [45].

Magnetic resonance imaging may detect the pathology of intervertebral disc, ligamentous injury, interspinous bursitis, enthesopathy, z-joint disease, sacroiliac joint pathology, neural foraminal pathology, bone contusion, infection, fracture, or neoplasia. Magnetic resonance imaging may exclude or confirm spinal cord disease and pathology related to extramedullary, intradural, and epidural spaces [45,46].

Computed tomography scans may detect small avulsion fractures of facets, laminar fracture, fracture of vertebral bodies and pedicles, neoplasia, or degenerative changes [45].

Bone scans are useful in assessing entire skeleton to rule out metabolically active disease processes [45].

Injection Sites and Technical Considerations

Painful connective tissue pathology proximal to entheses in the craniocervicothoracic region affect the following sites most commonly: apices of spinous processes, occipital bone at inferior and superior nuchal lines, mastoid processes, anterior and posterior tubercles of transverse processes, posterior tubercles and angles of the ribs, proximal and distal portions of the clavicle, superomedial margin and spine of the scapula, sternum, and xyphoid, capsular ligaments of the cervical and thoracic synovial joints such as AA, AO, z-joints, costovertebral, and costotransverse joints.

There is a significant pain maps overlap in the craniocervicodorsal area, in which any structure that received innervation is a potential pain generator. The question is, "How do we navigate in this sea of the unknown?". For the purpose of RIT, the following approach is implemented.

Initially, pain generators are identified by reproducible tenderness and the areas are marked. Tenderness of the posterior structures is an objective finding, especially in the midline [3,17••,36,42••,43-47]. Confirmation is obtained by needling and local anesthetic blocks of the tissue at the entheses, taking the nerve supply into account.

In experienced hands, using palpable landmarks for guidance, the following posterior column elements innervated by the dorsal rami may be safely injected without fluoroscopic guidance: entheses at the spinous process, supraspinous and intraspinal ligaments, lamina, posterior zygoapophyseal joint capsule, transverse process, and cervico-dorsal fascia insertions.

The dextrose/lidocaine solution is an effective initial diagnostic and therapeutic option for pain arising from posterior column elements when used in increments of 0.2 to 1.0 mL injected at each bone contact, initially blocking the terminal filaments of the MBDRs with the sequence as follows:

1. In the presence of midline pain and tenderness, the interspinous ligaments are blocked initially in the midline at the entheses.

2. If tenderness remains at the lateral aspects of the spinous processes, injections are carried out to the lateral aspects of the apices of the spinous processes, thus continuing on the course of MBDR.

3. Persistence of paramedial pain dictates blocks of the facet joint capsules, costotransverse joints, or posterior tubercle of the transverse processes in the cervical region with their respective tendon insertions.

4. Perseverance of lateral tenderness dictates investigation of the structures innervated by the lateral branches of the dorsal rami (*ie*, iliocostalis tendon insertions to the ribs).

In this fashion, all of the potential nociceptors on the course of MBDR are investigated from its periphery to the origin. Using the previously described sequence, a differential diagnosis of pain developing from vertebral and paravertebral structures innervated by MBDRs and lateral branches of the dorsal rami is made (Fig. 1 and 2).

Pain from the upper cervical synovial joints presents a diagnostic and a therapeutic challenge. Because pain patterns overlap, it usually is a diagnosis of exclusion.

Intra-articular, atlanto-axial, and atlanto-occipital joint injections of 6% phenol have secured a long-lasting therapeutic effect in selected patients [40]. A positive therapeutic effect with intra-articular injections of 25% dextrose to the same joints and mid-cervical synovial joints also were reported to relieve persistent pain after radiofrequency and capsular injection failure [39]. All of the synovial intra-articular injections of the spine should be performed under fluoroscopic guidance.

Solutions for Injections

The most common solutions are dextrose-based. To achieve a 12.5% concentration, dilution is made with local anesthetic in 1:3 proportion (*ie*, 1 mL of 50% dextrose mixed with 3 mL of 1% lidocaine). A 1:2 proportion (*ie*, 1 mL of 50% dextrose with 2 mL of 1% lidocaine) will equal 16.5% dextrose. Furthermore, a 1:1 dilution makes a 25% dextrose solution [3,17••,23,36,42••]. For intra-articular injections, a 25% dextrose solution is used, although a recent double-blind study suggests that 10% dextrose solution may be equally effective [48].

If this proves to be ineffective, gradual progression to a stronger solution such as sodium morrhuate full strength has been described [3,13,17••,36]. Sodium morrhuate 5% is a mixture of sodium salts of saturated and unsaturated fatty acids of cod liver oil and 2% benzyl alcohol, which acts as a local anesthetic and a preservative. Benzyl alcohol chemically is very similar to phenol [3,13,17••,36].

Dextrose/phenol/glycerine solution consists of 25% dextrose, 2.5% phenol, and 25% glycerine. It is diluted in concentrations of 1:2; 1:1, or 2:3 with a local anesthetic before the injection [3,17••,34,41,49].

The 6% phenol in glycerine solution is advocated by Wilkinson [43]. After gaining sufficient experience with intrathecal use of this solution, he began injecting it at

donor harvest sites of iliac crests for neurolytic and proliferative responses.

Conclusions

Double-blind, placebo-controlled, and retrospective studies clearly indicate the effectiveness of RIT in painful degenerative post-traumatic conditions of fibrous connective tissue [3,14-16,17••,34,36,44,48-50].

Literature suggests that degenerative cascade is a multietiologic disease process. NSAIDs and steroid preparations have limited use in chronic painful overuse conditions and degenerative painful conditions of ligaments and tendons. Microinterventional regenerative techniques and proper rehabilitation up to 6 months or 1 year supported with mild opioid analgesics are more appropriate [17••,25-28,38,42••,43].

Cervical and thoracic discogenic pain continues to be a therapeutic challenge. Encouraging positive results were published after regenerative injections for lumbar discogenic pain with dextrose-based solutions. It appears that cervical and thoracic discogenic pain may be addressed similarly in the near future [50,51•,52•].

The future is such that, instead of indirect stimulation of growth factors through inflammatory cascade, specific growth factors will be available. The challenge will continue to be determining which specific growth factors should be used. The other viable possibility is injection of engineered, type-specific tissue derived from stem-cell research [53-55].

The ideas of regeneration and controlled proliferation are slowly moving from the fringe to the frontier of medical care [50].

A physician versatile in diagnostic and therapeutic injection techniques may have ample opportunity to implement RIT in the practice of pain management. More information regarding.

Acknowledgments

The authors would like to extend their special thanks to Dianne Zalewski and Carolyn Lower for their invaluable help in the preparation of this manuscript and Tracey James for preparation of the illustrations.

References and Recommended Reading

Papers of particular interest, published recently, have been highlighted as:

- Of importance
- Of major importance

1. Kellgren J: On the distribution of pain arising from deep somatic structures with charts of segmental pain areas. *Somatic Pain* 1939, Volume 4, 35-46.

2. Feinstein B, Langton J, Jameson R, et al.: Experiments on pain referred from deep somatic tissues. *J Bone Joint Surg* 1954, 36A:981-996.
 3. Hackett G, Hemwall G, Montgomery G: *Ligament and Tendon Relaxation: Treated by Prolotherapy*, edn 5. Springfield, IL: Charles C. Thomas; 1991.
 4. Simons DG, Travell JG, Simons LS: *Myofascial Pain and Dysfunction: The Trigger Point Manual*, vol 1. Baltimore: Williams & Wilkins; 1991.
 5. Bonica J, Loeser J, Chapman C, et al.: *The Management of Pain*, vol 1, edn 2. Malvern, PA: Lea & Febiger; 1990; 7:136-139.
 6. Aprill C, Dwyer A, Bogduk N: Cervical zygapophyseal joint pain patterns: a clinical evaluation. *Spine* 1990, 15:458-461.
 7. Dreyfuss P, Michaelsen M, Fletcher D: Atlanto-occipital and lateral atlanto-axial joint pain patterns. *Spine* 1994, 19:1125-1131.
 8. Dreyfuss P, Tibiletti C, Dreyer S: Thoracic zygapophyseal joint pain patterns: a study in normal volunteers. *Spine* 1994, 19:807-811.
 9. Dussault R, Kaplan P: Facet joint injection: diagnosis and therapy. *Appl Radiol* 1994, JUNE 35-39.
 10. O'Neill C, Kurgansky M, Derby R, et al.: Disc stimulation and patterns of referred pain. *Spine* 2002, 27:2776-2781.
 11. Linetsky F, Willard F: Use of regenerative injection therapy for low back pain. *Pain Clin* 1999, 1:27-31.
 12. Linetsky F: History of sclerotherapy in urology. *SURGICAL PHYSICIAN ASSISTANT*, Volume 5, #2 1999, 30-32.
 13. Biegeleisen H: *Varicose Veins, Related Diseases, and Sclerotherapy: A Guide for Practitioners*. Fountain Valley, CA: Eden Press; 1994.
 14. Linetsky F, Mikulinsky A, Gorfine L: Regenerative injection therapy: history of application in pain management: Part I 1930s-1950s. *Pain Clin* 2000, 2:8-13.
 15. Linetsky F, Botwin K, Gorfine L, et al.: Position paper of the Florida Academy of Pain Medicine on regenerative injection therapy: effectiveness and appropriate usage: *Pain Clin* 2002, 4:38-45.
 16. Linetsky F, Saberski L, Miguel R, et al.: A history of the applications of regenerative injection therapy in pain management: Part II 1960s-1980s. *Pain Clin* 2001, 3:32-36.
 17. Linetsky F, Miguel R, Saberski L: Pain management with regenerative injection therapy (RIT). In *Pain Management: A Practical Guide for Clinicians*. Edited by Weiner R. Boca Raton, London, NY, Washington DC: CRC Press; 2002:381-402.
- A comprehensive review of the literature on the subject, mechanism of action, and technique.
18. Steindler A, Luck J: Differential diagnosis of pain low in the back: allocation of the source of pain by the procaine hydrochloride method. *JAMA* 1938, 110:106-113.
 19. Haldeman K, Soto-Hall R: The diagnosis and treatment of sacroiliac conditions by the injection of procaine (Novocain). *J Bone Joint Surg* 1938, 3:675-685.
 20. Bogduk N: Post-traumatic cervical and lumbar spine zygapophyseal joint pain. In *Neurology and Trauma*. Edited by Evans RW. Philadelphia: WB Saunders; 1996:363-375.
 21. *Gray's Anatomy, 38th British edition* 1995, Churchill Livingstone, Pearson Professional Limited., Chairman of Editorial Board: Peter Williams.
 22. Best T: Basic science of soft tissue. In *Orthopedic Sports Medicine Principles and Practice*, vol 1. Edited by DeLee J, Drez D Jr. Philadelphia: WB Saunders; 1994.
 23. Reeves D: Prolotherapy: present and future applications in soft-tissue pain and disability. *Phys Med Rehabil Clin N Am* 1995, 6:917-926.
 24. Yahia H, Newman N: A light and electron microscopic study of spinal ligament innervation. *Z Mikrosk Anat Forsch* 1989, 102:664-674.
 25. Leadbetter W: Cell-matrix response in tendon injury. *Clin Sports Med* 1992, 11:533-578.
 26. Leadbetter W: Anti-inflammatory therapy and sport injury: the role of non-steroidal drugs and corticosteroid injections. *Clin Sports Med* 1995, 14:353-410.

27. Jozsa L: *Human Tendons, Anatomy, Physiology, and Pathology*. Champaign, IL: Human Kinetics; 1997.
 28. Cotran R, Vinay K, Collins T, et al.: *Robbins Pathologic Basis of Disease*. Philadelphia: WB Saunders; 1999.
 29. Freemont A: Nerve ingrowth into diseased intervertebral disc in chronic back pain. *Lancet* 1997, 350:178-181.
 30. Ashton I, Ashton B, Gibson S, et al.: Morphological basis for back pain: the demonstration of nerve fibers and neuropeptides in the lumbar facet joint capsule but not in the ligamentum flavum. *J Orthop Res* 1992, 10:72-78.
 31. Tuzlukov P, Skuba N, Gorbatovskaya N: The morphological characteristics of fibromyalgia syndrome. *Arkh-Patol* 1993 Volume 4, #2, pp 47-50
 32. Liu Y, Tipton C, Matthes R, et al.: An in situ study of the influence of a sclerosing solution in rabbit medial collateral ligaments and its junction strength. *Connect Tissue Res* 1983, 11:95-102.
 33. Maynard J, Pedrini V, Pedrini-Mille A, et al.: Morphological and biochemical effects of sodium morrhuate on tendons. *J Orthop Res* 1985, 3:234-248.
 34. Klein R, Dorman T, Johnson C: Proliferant injections for low back pain: histologic changes of injected ligaments and objective measurements of lumbar spine mobility before and after treatment. *J Neuro Ortho Med Surg* 1989, 10:2.
 35. Willard F: Gross anatomy of the cervical and thoracic regions: understanding connective tissue stockings and their contents. Presented at the 20th AAOM Annual Conference and Scientific Seminar. Orlando, FL: April 30-May 3, 2003.
 36. •• Linetsky F, Eek B, Parris W: Regenerative injection therapy. In *Low Back Pain*. Edited by Manchikanti L. Paducah KY: ASIPP Publishing; 2002:519-420.
- Comprehensive review of the literature, mechanism of action, and technique.**
37. Lord S: Chronic cervical zygapophyseal joint pain after whiplash: a placebo-controlled prevalence study. *Spine* 1996, 21:1737-1745.
 38. Barnsley L, Lord S, Walis B, et al.: Lack of effect of intra-articular corticosteroids for chronic pain in the cervical zygapophyseal joints. *N Engl J Med* 1994, 330:1047-1050.
 39. O'Neill C: Intra-articular dextrose/glucosamine injections for cervical facet syndrome, atlanto-occipital and atlanto-axial joint pain, combined ISIS AAOM approach. Presented at the 20th AAOM Annual Conference and Scientific Seminar. Orlando, FL: April 30-May 3, 2003.
 40. Stanton-Hicks M: Cervicocranial syndrome: treatment of atlanto-occipital and atlanto-axial joint pain with phenol/glycerine injections. Presented at the 20th AAOM Annual Conference and Scientific Seminar. Orlando, FL: April 30-May 3, 2003.
 41. Klein R: Prolotherapy: an alternative approach to managing low back pain. *J Musculoskel Med* 1997, VOL 14, # 5, 45-59.
 42. •• Reeves D: Prolotherapy: basic science clinical studies and technique. In *Pain Procedures in Clinical Practice*. Philadelphia: Hanley & Belfus Inc; 2000, Editor: TED A. LENNARD, pp 57-70
 43. • Wilkinson H: *The Failed Back Syndrome Etiology and Therapy*, edn 2. New York: Springer-Verlag; 1992. Comprehensive review of technique and mechanism of action .
 44. Kayfetz D, Blumenthal L, Hackett G, et al.: Whiplash injury and other ligamentous headache: its management with prolotherapy. *Headache* 1963, 3:1.
 45. Resnick D: *Diagnosis of Bone and Joint Disorders*, vol 1-6, edn 3. Philadelphia: WB Saunders; 1995.
 46. Stark DD, Bradley WG, Bradley WG: *Magnetic Resonance Imaging*, vol 1 and 2, edn 3. St. Louis: Mosby; 1999.
 47. Broadhurst N, Wilk V: Vertebral mid-line pain: pain arising from the interspinous spaces. *J Orthop Med* 1996, 18:2-4.
 48. Reeves K, Hassanein K: Randomized, prospective, double-blind, placebo-controlled study of dextrose prolotherapy for knee osteoarthritis with or without ACL laxity. *Altern Ther Health Med* 2000, 6:68-74, 77-80.
 49. Klein R, Eek B, DeLong W, et al.: A randomized, double-blind trial of dextrose-glycerine-phenol injections for chronic, low back pain. *J Spinal Disord* 1993, 6:23-33.
 50. Mooney V: Prolotherapy at the fringe of medical care, or is it the frontier? *Spine J* 2003, 3:253-254.
 51. • Mathews R, Miller M, Bree S: Treatment of mechanical and chemical lumbar discopathy by dextrose 25%. *J Minimal Invasive Spinal Tech* 2001, 1:58-61.
- Initial trial published on intradiscal injections.**
52. • Klein R, Eek B, O'Neill C, et al.: Biochemical injection treatment for discogenic low back pain: a pilot study. *Spine J* 2003, 3:220-226.
- A more comprehensive study on intradiscal injections using a complex injectate with a 2-year follow-up.**
53. Kang H, Jung K, Eung S: Ideal concentration of growth factors in rabbit's flexor tendon culture. *Yonsei Med J* 1999, 40:26-29.
 54. Berven S: Tissue engineering, strategies in regeneration of the intervertebral disc presented at *Soft Tissue Injuries of the Spine: New Concepts in Diagnosis and Treatment*. San Francisco: July 18-19, 2003
 55. Herthel D: Injection of stem cells from bone marrow aspirate into damaged ligaments and tendons presented at *Soft Tissue Injuries of the Spine: New Concepts in Diagnosis and Treatment*. San Francisco: July 18-19, 2003.

Figure 1

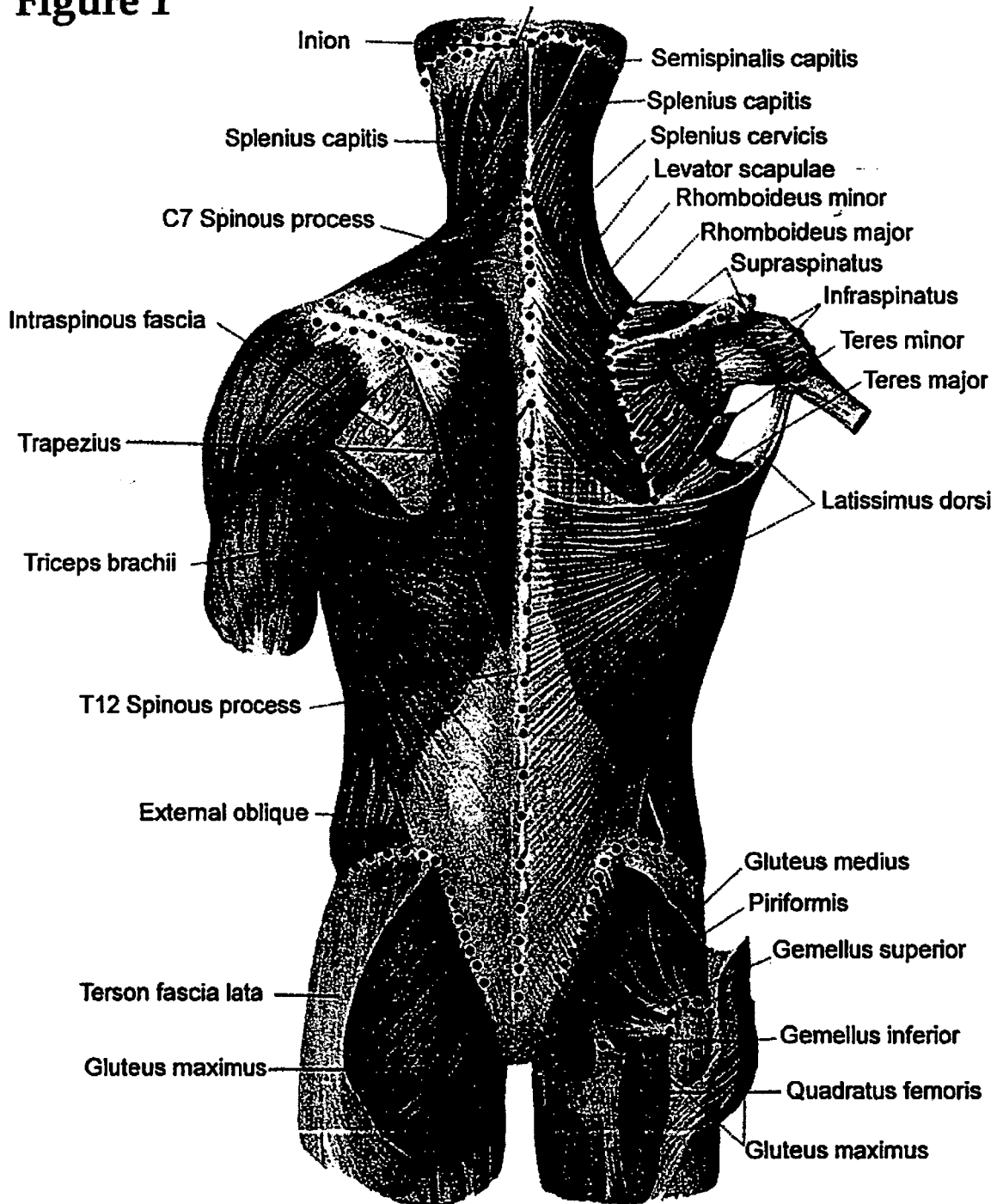


Figure 1: Dots represent some of the most common enthesopathy areas at the fibro-osseous insertions (enthesis) in the occiput, humerus, trochanter, iliac crest and spinous processes. Dots also represent most common location of needle insertions and infiltrations during RIT (Please note: not all of the locations must be treated in each patient.)

From Sinelnicov Atlas of Anatomy, Volume 1, Meiditsina Moskow, 1972.

Modified and prepared for publication by Tracey James.

Figure 2

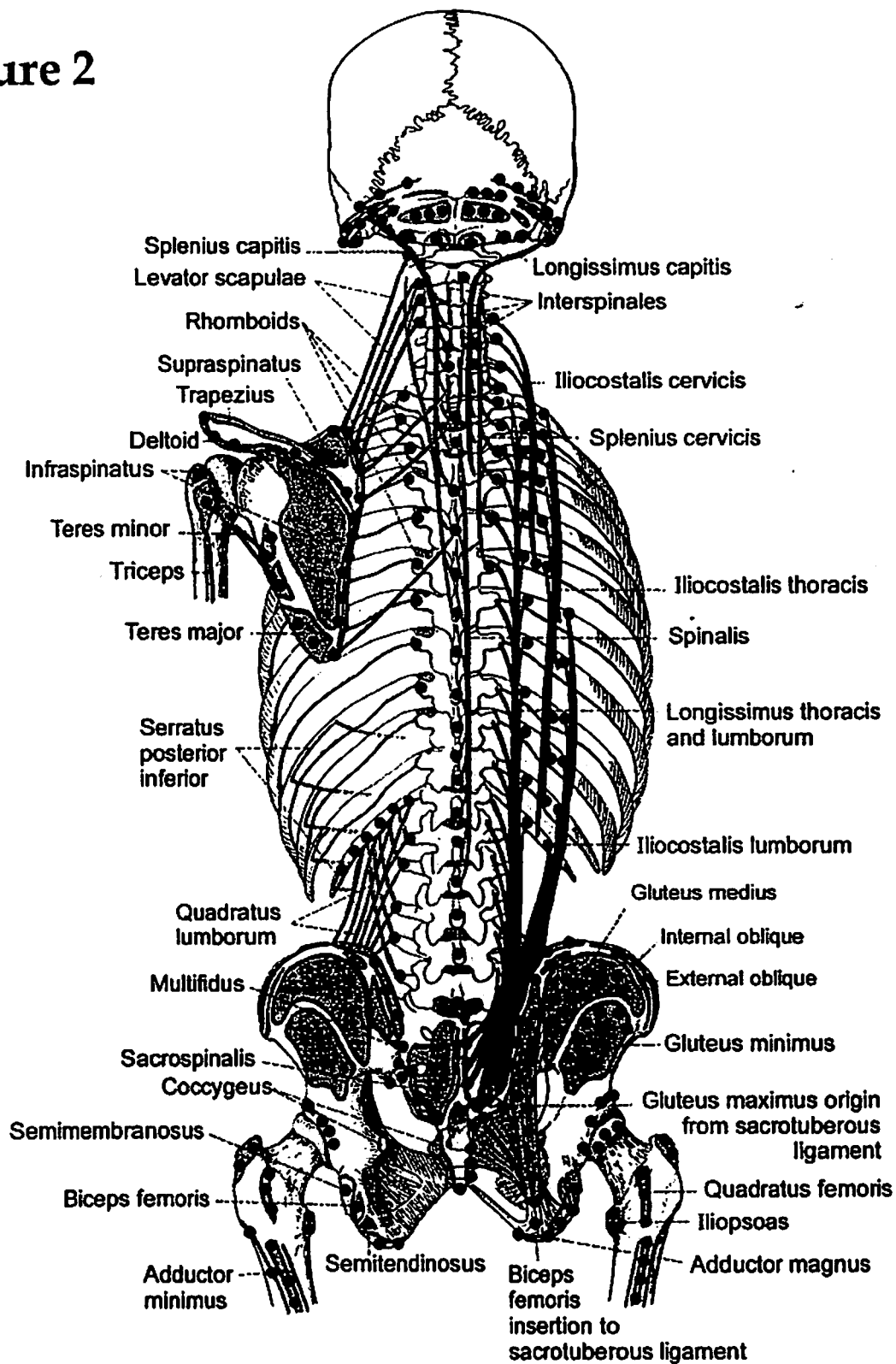


Figure 2: Dots represent some of the most common enthesopathy areas at the fibro-osseous insertions of ligaments and tendons (enthesis) at the occiput, humerus, trochanter, iliac crest and spine, ichial tuberosity, sacrum and spinous processes. Dots also represent most common location of needle insertions and infiltrations during RIT (Please note: not all of the locations must be treated in each patient.)

From Sinelnicov *Atlas of Anatomy*, Volume 1, Meiditsina Moskow, 1972.

Modified and prepared for publication by Tracey James.

TABLE 1. RIT MECHANISM OF ACTION

- **Cellular damage induced by mechanical transection with the needle stimulates inflammatory cascade and release of growth factors.**
- **Compression of cells by volume of the injected solution and cell expansion or constriction due to osmotic properties of injectate stimulates the release of intracellular growth factors.**
- **Chemomodulation of collagen through inflammatory, proliferative, regenerative/repairative response is induced by the chemical properties of the proliferants and mediated by cytokines and multiple growth factors.**
- **Chemoneuromodulation of peripheral nociceptors provides stabilization of antidromic, orthodromic, sympathetic and axon reflex transmissions.**
- **Modulation of local hemodynamics with changes in intra-osseous pressure leads to reduction of pain. Empirical observations suggest that a dextrose/lidocaine combination has a much more prolonged action than lidocaine alone.**
- **Temporary repetitive stabilization of the painful hypermobile joints, induced by inflammatory response to the proliferants, provides a better environment for regeneration and repair of the affected ligaments and tendons.**

TABLE 2. SYNDROMES AND CONDITIONS TREATED WITH RIT

- Temporomandibular pain and dysfunction syndrome
- Cervicocranial syndrome (cervicogenic headaches, atlanto-axial, atlanto-occipital joint and mid-cervical z-joint sprains)
- Barré Lieou Syndrome
- Torticollis
- Cervical and thoracic segmental dysfunctions
- Cervical and thoracic midline spinal pain "of unknown origin"
- Cervicobrachial syndrome (shoulder/neck pain)
- Hyperextension/hyperflexion injury syndromes
- Cervical and thoracic facet syndromes
- Cervical and thoracic sprain/strain syndrome
- Costovertebral arthrosis and joint pain
- Costotransverse ligament sprain/strain and joint pain
- Slipping rib syndrome
- Sternoclavicular arthrosis and repetitive sprain
- Tietze's Syndrome/costochondritis/chondrosis
- Costosternal arthrosis
- Intercostal arthrosis
- Xiphoidalgia syndrome
- Acromioclavicular sprain/arthrosis
- Scapulothoracic crepitus
- Myofacial pain syndromes
- Ehlers-Danlos Syndrome
- Marie-Strumpell disease
- Failed back syndrome
- Laxity of ligaments

TABLE 3. INDICATIONS FOR RIT

1. Painful tendinosis or ligamentosis secondary to sprains or strains
2. Painful enthesopathies from overuse, occupational and postural conditions known as Repetitive Motion Disorders
3. Painful hypermobility, instability and subluxation of the joints secondary to ligament laxity accompanied by restricted range of motion at reciprocal segment(s) that improve temporarily with manipulation
4. Vertebral compression fractures with a wedge deformity that exert additional stress on the posterior ligamento-tendinous complex
5. Recurrent painful rib subluxations at the costotransverse, costovertebral, sternochondral, costochondral articulations, unstable costochondral fractures
6. Osteoarthritis, spondylolysis and spondylolisthesis
7. Post surgical (with or without instrumentation) cervicothoracic pain
8. Pain refractory to steroid injections and radiofrequency procedures
9. Soft tissue sources of nociception i.e. ligament, tendons, synovial joints, refractory to anti-inflammatory therapy
10. Enhancement of manipulative treatment and physiotherapy
11. Internal disc derangement

TABLE 4. CONTRAINDICATIONS TO RIT

General contraindications are those that are applicable to all injection techniques such as:

- a) Allergy to anesthetic solutions
- b) Paraspinal neoplastic lesions involving the musculature and osseous structures
- c) Recent onset of a progressive neurologic deficit including but not limited to severe intractable cephalgia, unilaterally dilated pupil, bladder dysfunction, bowel incontinence, etc.
- d) Requests for large quantity of sedation and/or narcotics before and after treatment,
- e) Severe exacerbation of pain or lack of improvement after local anesthetic blocks,
- f) Fear of the procedure

Specific contraindications are:

- a) Allergy to proliferants or their ingredients such as dextrose, sodium morrhuate or phenol
- b) Acute non-reduced subluxations or dislocations
- c) Acute arthritis (septic, gout, rheumatoid or post-traumatic with hemarthrosis)
- d) Acute bursitis or tendinitis