

Spinal arteriovenous malformation associated with spinal metameric syndrome: a treatable cause of long-term paraplegia?

Case report

ITALO LINFANTE, M.D.,^{1,4} FRANCESCA TARI CAPONE, M.D.,² GUILHERME DABUS, M.D.,^{1,4}
SERGIO GONZALEZ-ARIAS, M.D., PH.D.,^{3,4} PATRICIO E. LAU, B.S.,⁴
AND EDGAR A. SAMANIEGO, M.D., M.S.¹

¹Department of Interventional Neuroradiology, Baptist Cardiac and Vascular Institute, Miami, Florida; ²Department of Neurosciences and Mental Health, II Faculty of Medicine, “La Sapienza” University of Rome, Italy; ³Department of Neurological Surgery, Baptist Hospital Neuroscience Center; and ⁴Herbert Wertheim College of Medicine, Florida International University, Miami, Florida

Cutaneomeningospinal angiomas, or Cobb syndrome, is a rare metameric developmental disorder presenting as an extradural-intradural vascular malformation that involves bone, muscle, skin, spinal cord, and nerve roots.

A 14-year-old girl with a red nevus involving the T6–9 dermatomes on the left side of her back presented with a 5-year history of bowel and bladder incontinence, paraplegia, and lower-extremity sensory loss. Magnetic resonance imaging demonstrated a hemangioma in the T-8 and T-9 vertebral bodies and a spinal cord AVM nidus extending from T-6 to T-9. The AVM was successfully embolized and the patient regained lower-extremity strength, ambulation, and normal sphincter functions after 5 years of having been wheelchair bound.

The authors report the restoration of ambulation after endovascular embolization of a large spinal AVM in a patient with long-standing paraplegia due to Cobb syndrome.
(<http://thejns.org/doi/abs/10.3171/2011.12.SPINE11636>)

KEY WORDS • angiomas • Cobb syndrome • embolization •
myelopathy • Onyx • spinal angiography • spinal arteriovenous malformation

CUTANEOMENINGOSPINAL angiomas, also known as Cobb syndrome, is a rare, noninherited disorder characterized by a spinal AVM and a vascular skin lesion affecting the corresponding dermatome. Spinal involvement may include the vertebral bodies, dura mater, spinal cord, and nerve roots.¹⁰ Adult and young patients typically present with sudden onset of radicular pain in the lower extremities and associated numbness. Less commonly, sudden onset of weakness or rectal/and bladder dysfunction is the presenting symptom.⁸ The clinical course may also progress over several years to paraplegia and sphincter dysfunction.⁴ Rupture of the AVM may result

in a potentially fatal subarachnoid hemorrhage and/or hematomyelia.

Current treatment options aim for obliteration of the AVM, usually by a combination of endovascular embolization, resection, and in selected cases, radiotherapy. The endovascular approach has been successfully used in spinal vascular malformations mostly as preoperative embolization.^{7,8} An angiographically documented cure resulting in reversal of paraplegia after endovascular embolization alone has been described mostly in Type I spinal dural fistulas.^{1,21} We report the case of a 14-year-old, wheelchair-bound girl with paraplegia and bowel and bladder incontinence due to a large spinal AVM who, after endovascular embolization, regained lower-extremity strength and sphincter control.

Abbreviation used in this paper: AVM = arteriovenous malformation.

Endovascular treatment of Cobb syndrome

Case Report

History. When the patient was 9 years of age, she developed progressive numbness and tingling in her right leg. Over the next year, lower-extremity paraplegia, hypesthesia, dysesthesia, constipation, and a neurogenic bladder developed. The patient underwent evaluation at an outside hospital where thoracic MR imaging revealed a large spinal vascular malformation. At the time of the diagnosis, the treating physicians did not offer surgical or endovascular treatments. The patient was wheelchair bound from the age of 10 to 14 years, when she was referred to our institution. In addition to the paraplegia, the patient reported that during the last year she had developed progressive upper-extremity weakness and shortness of breath upon mild exertion.

Examination. At the time of the referral to our institution, physical examination revealed a birthmark characterized by a pigmented nevus in the left T6–9 dermatomes of her torso measuring approximately 28 × 12 cm. The nevus exhibited a thrill on palpation and was warm. Neurologically, the patient had Grade 4/5 bilateral deltoid and biceps weakness with brisk deep tendon reflexes in the upper extremities. She had spastic lower-extremity paraplegia (Grade 0/5 in all muscle groups), sustained clonus of the patellar and ankle reflexes, and a bilateral Babinski sign. On sensory examination, she had hypesthesia to light touch and pinprick up to the dermatomal level of T-7. She had intermittent bladder incontinence and episodes of constipation. Her Aminoff-Logue disability scale score for gait and micturition was 7 (scale range 1–8, where 8 signifies an inability to stand and complete incontinence).²

Thoracic MR imaging revealed numerous intramedullary serpiginous flow voids from T-6 to T-9, suggestive of a spinal cord AVM. Perimedullary flow voids could be traced from T-4 to T-12 representing possible enlarged perimedullary veins. Hyperintense T1-weighted lesions within the T-8 and T-9 vertebral bodies were suggestive of hemangioma (Fig. 1A).

Spinal angiography revealed that the AVM nidus extended from T-5 to T-8 (Figs. 2–5). The arteria radicularis magna arose from the left T-9 intercostal artery (Fig. 3A) and provided arterial inflow to the AVM nidus. Angiography revealed markedly engorged perimedullary and dural venous plexus veins throughout the length of the thoracic and lumbar spinal cord. The azygos vein and inferior vena cava were also visualized on late-phase angiograms from selective catheterization of the left T-8 intercostal artery that supplied the main radiculomedullary feeder of the AVM (Fig. 2).

Endovascular Embolization. To reach the AVM nidus, superselective catheterization of the radiculomedullary arteries arising from the right T-8, left T-9, and right T-7 arteries was performed using Marathon and UltraFlow microcatheters (ev3 Inc.). Once the microcatheter was stably positioned into the AVM nidus, Onyx liquid embolic agent (ev3) was injected. Because of the large size of the AVM nidus, we opted for a staged approach. Therefore, the superior section of the nidus (Fig. 5) was embolized 2

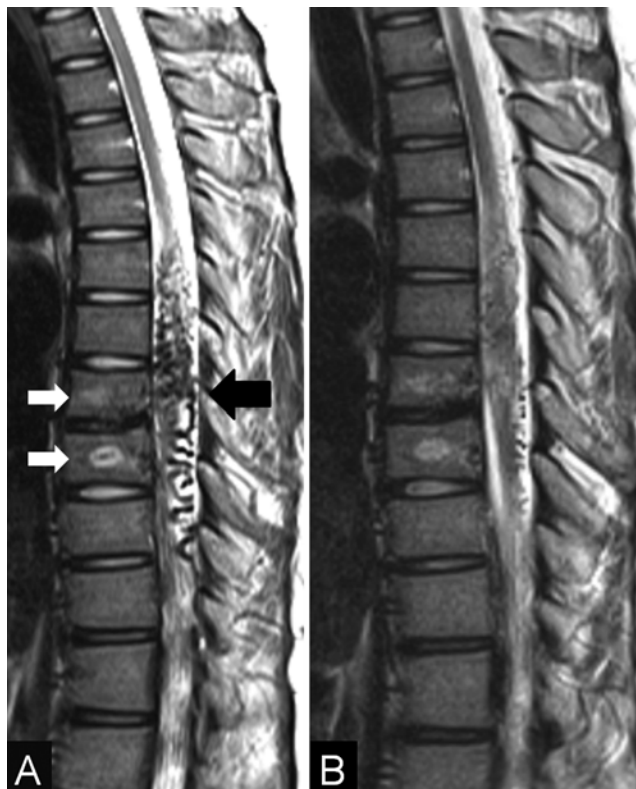


Fig. 1. A: Sagittal thoracic T2-weighted MR image demonstrating an intramedullary AVM between T-6 and T-9 (black arrow) and hyperintense signal in the T-8 and T-9 vertebrae (white arrows), suggestive of a vertebral angioma. **B:** Postembolization sagittal T2-weighted MR image revealing substantial reduction of the AVM-related flow voids.

months later via the left T-6 intercostal artery. Final selective spinal angiography 2 months after the last embolization demonstrated an angiographic cure at each level with no residual contrast opacification of the nidus.

Posttreatment. Postembolization spinal MR imaging showed only few perimedullary flow voids and the presence of intramedullary Onyx-induced signal artifact (Fig. 1B). Neurologically, after the first embolization, the patient started to regain strength of her proximal leg muscles (Grade 3/5). She then progressively improved to the point of being able to stand unassisted and ambulate with a walker. She also regained complete bladder and bowel control, corresponding to an Aminoff-Logue Scale score of 4. At 10 months after the intervention, the patient gained even more lower-extremity strength and was able to stand up more firmly. Unfortunately, because the patient currently lives in a remote village in Bolivia, we were not able to obtain an angiographic follow-up.

Discussion

To our knowledge, this is the first report of a reversal of paraplegia after endovascular embolization without resection of a large intramedullary AVM in a patient with Cobb syndrome.

In 1915 Stanley Cobb⁵ described 1 case of “hemangioma” of the spine associated with a skin nevi. The diagno-

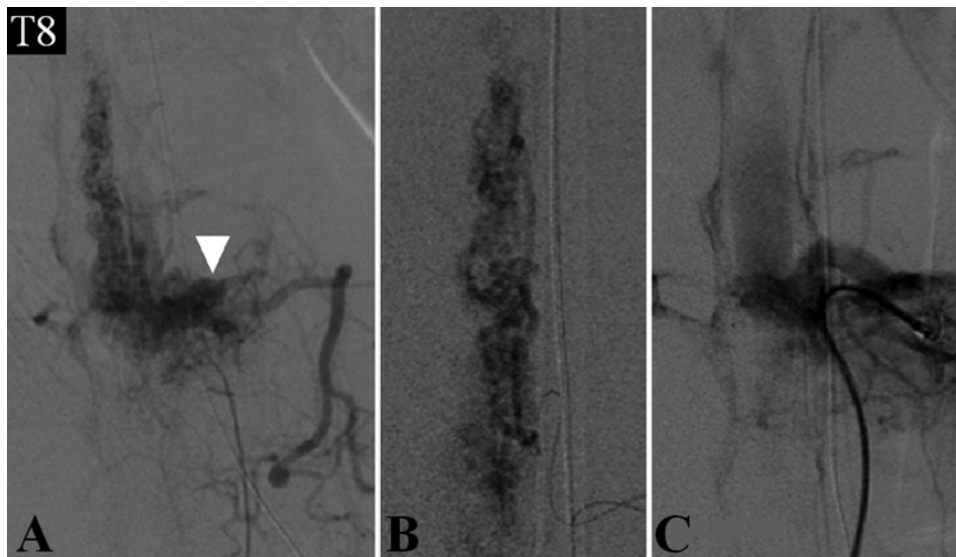


FIG. 2. A: Superselective left T-8 radiculomedullary angiogram demonstrating the AVM nidus. Vascular involvement of soft tissues surrounding the AVM in a metameric distribution (*arrowhead*, A). B: Microcatheter injection proximal to the AVM nidus. C: Postembolization angiogram demonstrating no residual contrast opacification of the AVM nidus.

sis was made after laminectomy of the thoracic spine and dural exposure with visualization of tense bulging vessels in the canal. Several reports with inaccurate descriptions of the spinal vascular lesion have followed.¹¹ This lack of consensus was most likely due to the absence at that time of the modern angiographic and imaging capabilities currently used to accurately visualize the vascular lesion, its angio-architecture, and relationship to the spinal cord.²² Only in 1972 did Kissel and Dureux¹³ propose a diagnostic criteria for Cobb syndrome that included a skin nevus in the same segment of the spinal angioma, sometimes accompanied by visceral angiomatosis. More recently in 2006, Kim and colleagues¹² classified Cobb syndrome as an extradural-intradural AVM, which involved bone, muscle, skin, spinal cord, and nerve roots in the same dermatome distribution.

With these limitations, the number of documented cases of Cobb syndrome in the literature is approximately 45.^{8,9,25,32}

With regard to neurological symptoms, cord ischemia due to steal syndrome and cord compression due to venous hypertension are the proposed mechanisms that would explain the myelopathy observed in unruptured spinal malformations in general, and in the large AVMs often described in Cobb syndrome.⁴

Treatment modalities reported in the literature include surgical resection, endovascular embolization, and radiation therapy. In particular, surgical intervention with or without radiation therapy was performed in 20 (45%) of 45 cases,^{9,25,32} embolization with or without medical therapy in 9 (20%) (Table 1),^{11,14,15,17-19,23,26,31} combined surgical and endovascular approaches in 10 (22%),^{3,16,24,27,29,30} and conser-

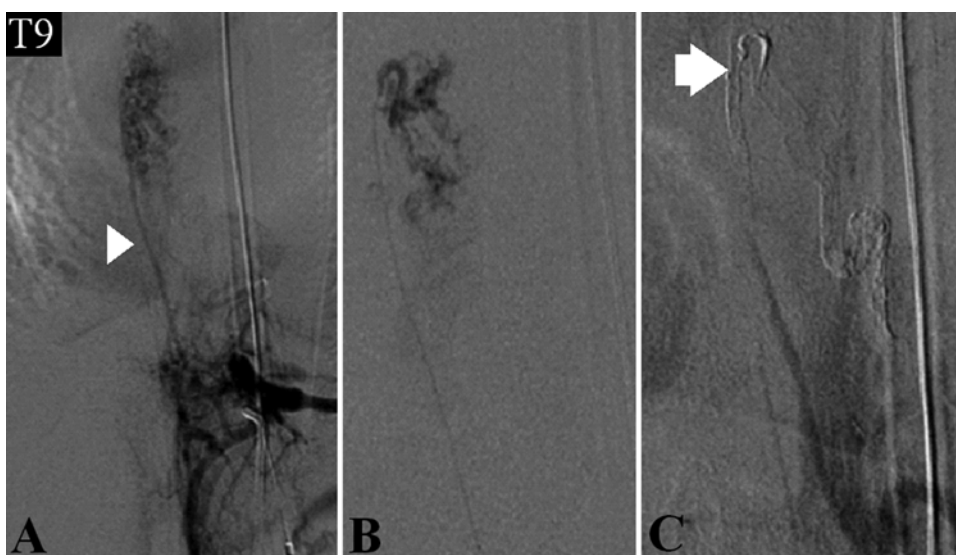

FIG. 3. A: Hyperplastic arteria radicularis magna (*arrowhead*) arising from the left T-9 intercostal artery and providing arterial inflow to the AVM nidus. B: Microcatheter injection proximal to the AVM nidus through the arteria radicularis magna. C: Postembolization angiogram demonstrating the Onyx cast (*arrow*) and no residual contrast opacification of the AVM nidus.

Endovascular treatment of Cobb syndrome

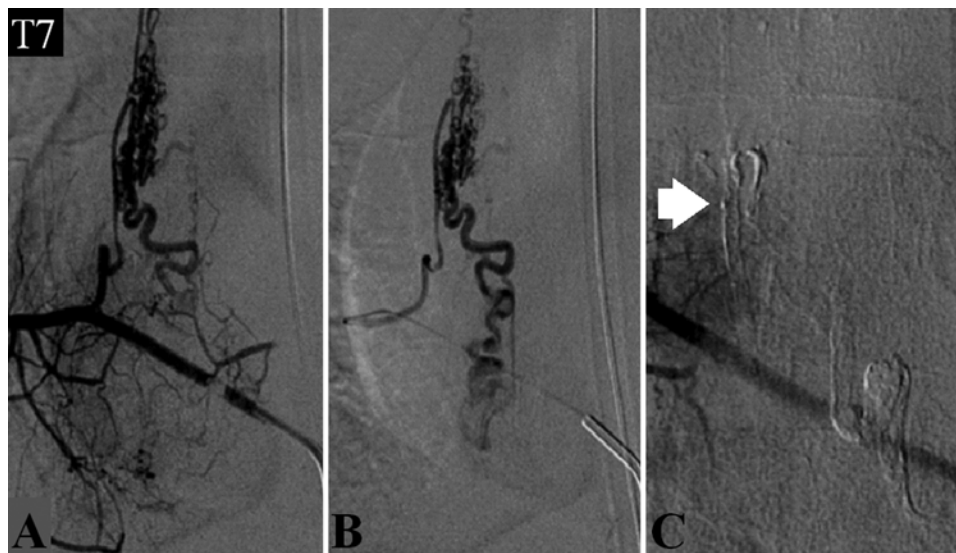

FIG. 4. **A:** Superselective spinal angiogram of the right T-7 radiculomedullary branch demonstrating the AVM nidus. **B:** Microcatheter injection proximal to the AVM nidus. **C:** Postembolization angiogram demonstrating the Onyx cast (arrow) and no residual nidus.

vative management with medical treatment only in 6 cases (13%).^{8,20} Martin and coworkers¹⁶ described a 15-year-old boy with an intramedullary AVM who presented with lower-extremity spasticity. He underwent endovascular embolization of 2 arterial feeders and resection of the residual AVM. He had an excellent neurological outcome. However, he developed delayed kyphosis because the AVM involved

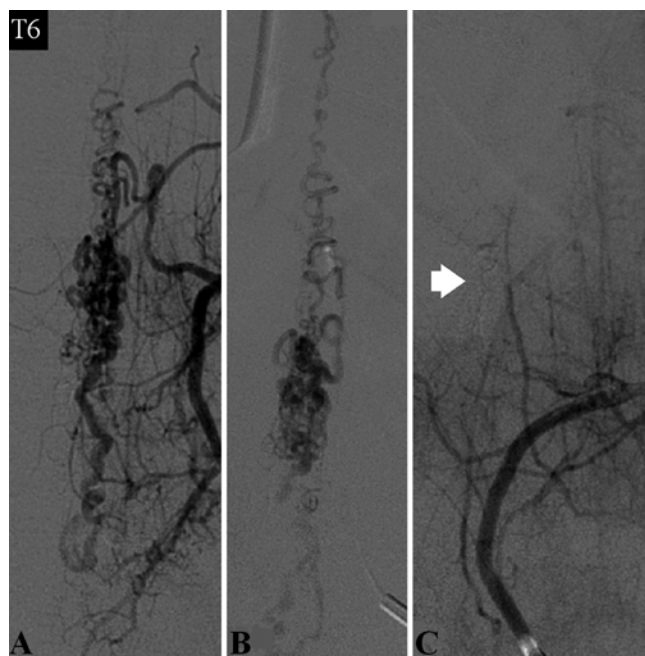


FIG. 5. Two months after the first embolization, the remaining portion of the AVM nidus arising from the left T-6 radiculomedullary artery was selected. **A and B:** Angiograms from the guide catheter and the microcatheter demonstrating residual AVM nidus. **C:** Postembolization angiogram demonstrating an Onyx cast (arrow) and no residual AVM nidus.

multiple vertebral bodies. It was not reported if the patient regained movement of his lower extremities. Spetzler and collaborators²⁸ reported on a patient with a Type III AVM that was completely obliterated using a combination of pre- and intraoperative embolization with staged resection. The patient had mild upper-extremity weakness before the intervention; 6 weeks later she had recovered full strength and returned to her normal activities. Touho and associates³⁰ also described improvement in a patient who was paraparetic for 14 years and not able to walk without assistance. After intraoperative embolization and excision of a Type III AVM, the patient was able to stand and walk short distances with the aid of parallel bars.

The endovascular approach has been used successfully in spinal vascular malformations mostly as preoperative embolization.^{7,8} An angiographically documented cure after endovascular embolization alone has been described mostly in cases of Type I spinal dural fistulas.^{1,21} With regard to spinal AVMs, Corkill and collaborators⁶ described an overall improvement in neurological status in 14 of 17 patients after endovascular Onyx-based embolization. However, only 1 patient included in their series had severe lower-extremity motor impairment, which did not improve after complete obliteration of the AVM. Da Costa and colleagues⁷ reported on 47 spinal cord AVMs treated endovascularly. Excellent outcome (improvement in neurological status or AVM obliteration) was achieved in 49% of cases, but none of the patients with a fixed neurological deficit returned to their baseline neurological status.

In the case described in this report, we were able to achieve an excellent angiographic result using embolization alone. Moreover, the patient had a remarkable clinical recovery. Her neurological improvement suggests that her symptoms were most likely due to venous hypertension, similarly to what has been reported after endovascular embolization of patients with paraplegia secondary to spinal dural arteriovenous fistulas.¹

TABLE 1: Endovascular treatments of Cobb syndrome reported in the literature*

Authors & Year	Age at Tx (yrs)	Symptoms	Level	Lesion	Procedure	Outcome
Miyatake et al., 1990	15	paraparesis	T10–L1	fistula	ethylene vinyl alcohol & calibrated-leak balloon	increased pain & disuria
Krolak-Salmon et al., 1999	20	sharp back pain & paraplegia w/ SAH	C6–T11	perimedullary AVM	embolization	normal gait
Soeda et al., 2003	0.4	paraparesis	T8–L3	spinal & paravertebral angioma	embolization w/ NBCA	improved strength
Maramattom et al., 2005	17	neck pain, quadriplegia, areflexia, & C-4 sensory loss	C5–7	AVM	coiling of venous outflow	mild improvement of strength
Matullo et al., 2007	11	back pain, bladder & bowel dysfunction, paraplegia	T8–S1	AVM & leaking aneurysm	embolization	improved strength, but wheelchair dependent
Wetter et al., 2008	17	sudden quadriplegia	C5–7	AVM	coil embolization	moderate improvement
Johnson & Petrie, 2009	34	progressive myelopathy	T9–11	AVM	coiling embolization of aneurysm	lost to follow-up
Palanca Arias et al., 2010	13	rt hemiparesis & hypesthesia	C6–7	AVM	embolization	no improvement
BCVI	14	paraplegia, bladder & bowel dysfunction	T6–9	AVM	Onyx embolization	significant improvement

* BCVI = Baptist Cardiac and Vascular Institute; NBCA = *N*-butyl cyanoacrylate; SAH = subarachnoid hemorrhage; Tx = treatment.

Conclusions

We suggest that endovascular embolization of large spinal AVMs should be considered both as a preoperative treatment and possibly as a definite treatment. Similar to what has been reported in Type I spinal dural fistulas,¹ remarkable clinical improvement of severe myelopathy may also occur in spinal AVMs.

Disclosure

Dr. Linfante is a consultant for Codman Neurovascular and Concentric Medical. Dr. Dabus is a consultant for Codman Neurovascular.

Author contributions to the study and manuscript preparation include the following. Conception and design: Linfante, Tari Capone, Samaniego. Acquisition of data: Linfante, Tari Capone, Dabus, Lau, Samaniego. Analysis and interpretation of data: Linfante, Tari Capone, Samaniego. Drafting the article: Linfante, Tari Capone, Samaniego. Critically revising the article: all authors. Reviewed submitted version of manuscript: all authors. Approved the final version of the manuscript on behalf of all authors: Linfante. Administrative/technical/material support: Samaniego. Study supervision: Linfante, Samaniego.

Acknowledgments

The authors acknowledge Beverly Smith and Project Rafa; Drs. Palacio Mercado, Tonia Seng, and Sonia Seng; and Mr. Enoel Suarez for their exceptional missionary work and care of people in need in Bolivia.

References

1. Aghakhani N, Parker F, David P, Lasjaunias P, Tadie M: Curable cause of paraplegia: spinal dural arteriovenous fistulae. *Stroke* **39**:2756–2759, 2008
2. Aminoff MJ, Logue V: The prognosis of patients with spinal vascular malformations. *Brain* **97**:211–218, 1974

3. Bao YH, Ling F: Classification and therapeutic modalities of spinal vascular malformations in 80 patients. *Neurosurgery* **40**:75–81, 1997
4. Clark MT, Brooks EL, Chong W, Pappas C, Fahey M: Cobb syndrome: a case report and systematic review of the literature. *Pediatr Neurol* **39**:423–425, 2008
5. Cobb S: Haemangioma of the spinal cord: associated with skin naevi of the same metamere. *Ann Surg* **62**:641–649, 1915
6. Corkill RA, Mitsos AP, Molyneux AJ: Embolization of spinal intramedullary arteriovenous malformations using the liquid embolic agent, Onyx: a single-center experience in a series of 17 patients. *J Neurosurg Spine* **7**:478–485, 2007
7. da Costa L, Dehdashti AR, terBrugge KG: Spinal cord vascular shunts: spinal cord vascular malformations and dural arteriovenous fistulas. *Neurosurg Focus* **26**(1):E6, 2009
8. Dilmé-Carreras E, Iglesias-Sancho M, Márquez-Balbás G, Sola-Ortigosa J, Umberto-Millet P: Cobb syndrome: case report and review of the literature. *Dermatology* **221**:110–112, 2010
9. Gordon-Firing S, Purriel JA, Pereyra D, Brodbek I: [Report of a new case of Cobb syndrome. Meningo-spinal cutaneous angiomatosis.] *Acta Neurol Latinoam* **27**:99–111, 1981 (Span)
10. Jessen RT, Thompson S, Smith EB: Cobb syndrome. *Arch Dermatol* **113**:1587–1590, 1977
11. Johnson WD, Petrie MM: Variety of spinal vascular pathology seen in adult Cobb syndrome. Report of 2 cases. *J Neurosurg Spine* **10**:430–435, 2009
12. Kim LJ, Albuquerque FC, Spetzler RF, McDougall CG: Postembolization neurological deficits in cerebral arteriovenous malformations: stratification by arteriovenous malformation grade. *Neurosurgery* **59**:53–59, 2006
13. Kissel P, Dureux B: Cobb syndrome. Cutaneomeningospinal angiomatosis, in Vinken PJ, Bruyn GW (eds): *The Phakomatoses. Handbook of Clinical Neurology*. Amsterdam: North Holland Publishing, 1972, Vol 14, p 459
14. Krolak-Salmon P, Moreau T, Bouhour F, Bascoulergues Y, Secchi T, Confavreux C: Simultaneous medullar and cutaneous revelation of a cutaneomeningospinal angiomatosis. *Eur Neurol* **41**:170–171, 1999
15. Maramattom BV, Cohen-Gadol AA, Wijidicks EF, Kallmes D:

Endovascular treatment of Cobb syndrome

- Segmental cutaneous hemangioma and spinal arteriovenous malformation (Cobb syndrome). Case report and historical perspective. **J Neurosurg Spine** 3:249–252, 2005
16. Martin NA, Khanna RK, Batzdorf U: Posterolateral cervical or thoracic approach with spinal cord rotation for vascular malformations or tumors of the ventrolateral spinal cord. **J Neurosurg** 83:254–261, 1995
 17. Matullo KS, Samdani A, Betz R: Low-back pain and unrecognized Cobb syndrome in a child resulting in paraplegia. **Orthopedics** 30:237–238, 2007
 18. Miyatake S, Kikuchi H, Koide T, Yamagata S, Nagata I, Minami S, et al: Cobb's syndrome and its treatment with embolization. Case report. **J Neurosurg** 72:497–499, 1990
 19. Palanca Arias D, Rius Gordillo N, García Fructuoso G, Candela Cantó S, Sola Martínez T, Palomeque Rico A: [Cobb syndrome or cutaneomeningospinal angiomatosis.] **An Pediatr (Barc)** 73:109–111, 2010 (Span)
 20. Pascual-Castroviejo I, Frutos R, Viaño J, Pascual-Pascual SI, Gonzalez P: Cobb syndrome: case report. **J Child Neurol** 17:847–849, 2002
 21. Prieto R, Pascual JM, Gutiérrez R, Santos E: Recovery from paraplegia after the treatment of spinal dural arteriovenous fistula: case report and review of the literature. **Acta Neurochir (Wien)** 151:1385–1397, 2009
 22. Rodesch G, Hurth M, Alvarez H, Tadié M, Lasjaunias P: Classification of spinal cord arteriovenous shunts: proposal for a reappraisal—the Bicêtre experience with 155 consecutive patients treated between 1981 and 1999. **Neurosurgery** 51:374–380, 2002
 23. Sardana K, Sehgal VN, Mahajan S, Bhushan P: Cobb syndrome in an Indian girl. **Skinmed** 5:51–53, 2006
 24. Sayuthi S, Moret J, Pany A, Sobri A, Shafie M, Abdullah J: COBB syndrome treated by staged intravascular embolisation and surgery. **Med J Malaysia** 61:239–241, 2006
 25. Shim JH, Lee DW, Cho BK: A case of Cobb syndrome associated with lymphangioma circumscriptum. **Dermatology** 193:45–47, 1996
 26. Soeda A, Sakai N, Iihara K, Nagata I: Cobb syndrome in an infant: treatment with endovascular embolization and corticosteroid therapy: case report. **Neurosurgery** 52:711–715, 2003
 27. Spetzler RF: Cavernous angiomas and AVM's. **J Neurosurg** 70:500–501, 1989 (Letter)
 28. Spetzler RF, Zabramski JM, Flom RA: Management of juvenile spinal AVM's by embolization and operative excision. Case report. **J Neurosurg** 70:628–632, 1989
 29. Spiotta AM, Hussain MS, Masaryk TJ, Krishnaney AA: Combined endovascular and surgical resection of a giant lumbosacral arteriovenous malformation in a patient with Cobb syndrome. **J Neurointervent Surg** 3:293–296, 2011
 30. Touho H, Karasawa J, Shishido H, Yamada K, Shibamoto K: Successful excision of a juvenile-type spinal arteriovenous malformation following intraoperative embolization. Case report. **J Neurosurg** 75:647–651, 1991
 31. Wetter DA, Davis MD, Hand JL: Acute paralysis in a 17-year-old man with subtle cutaneous vascular malformations: an unusual case of Cobb syndrome. **J Eur Acad Dermatol Venereol** 22:525–526, 2008
 32. Zala L, Mumenthaler M: [Cobb syndrome: association with verrucous angioma, ipsilateral hypertrophy of the extremities and café-au-lait spots.] **Dermatologica** 163:417–425, 1981 (Ger)

Manuscript submitted August 9, 2011.

Accepted December 5, 2011.

Please include this information when citing this paper: published online January 6, 2012; DOI: 10.3171/2011.12.SPINE11636.

Address correspondence to: Italo Linfante, M.D., Interventional Neuroradiology, Endovascular Neurosurgery, Baptist Cardiac and Vascular Institute, 8900 North Kendall Drive, Miami, Florida 33176. email: italol@baptisthealth.net.