

Genital Examination Findings

An update
VFPMS Seminar May 2016
Bindu Bali & Andrea Smith

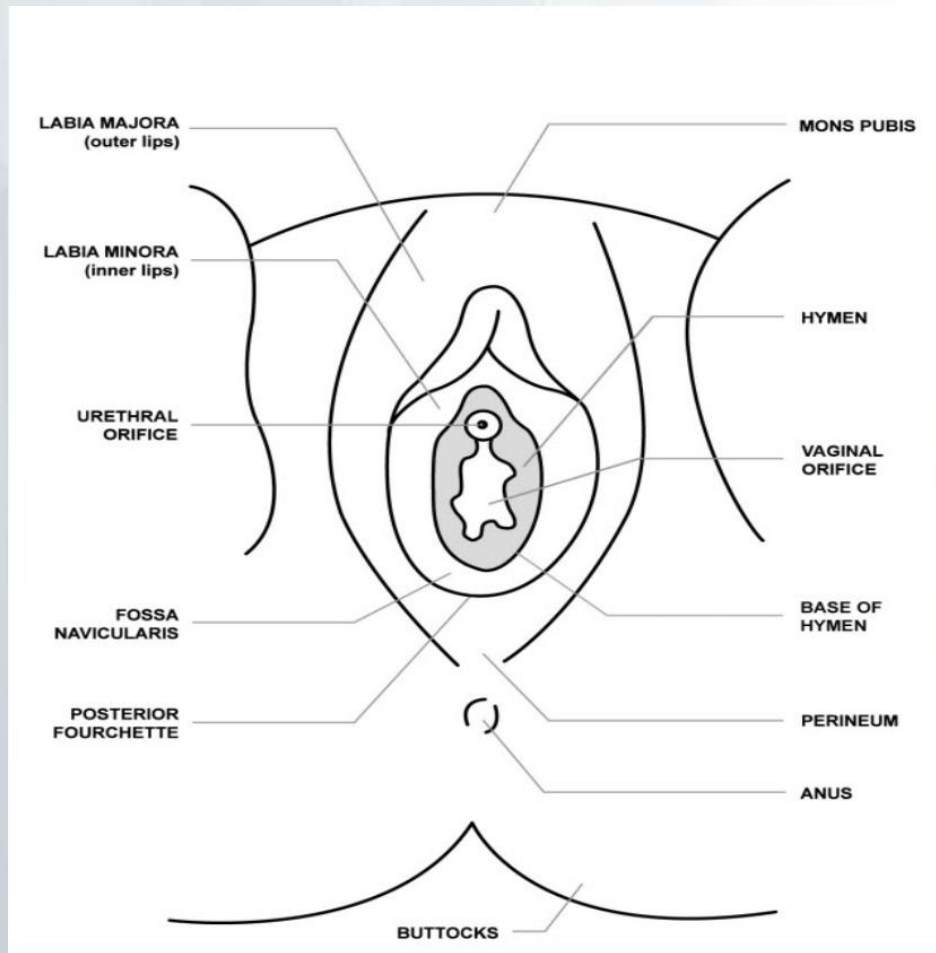
Outline

- It's normal to be normal
- What is normal?
- What is debatable?
- What is abnormal?

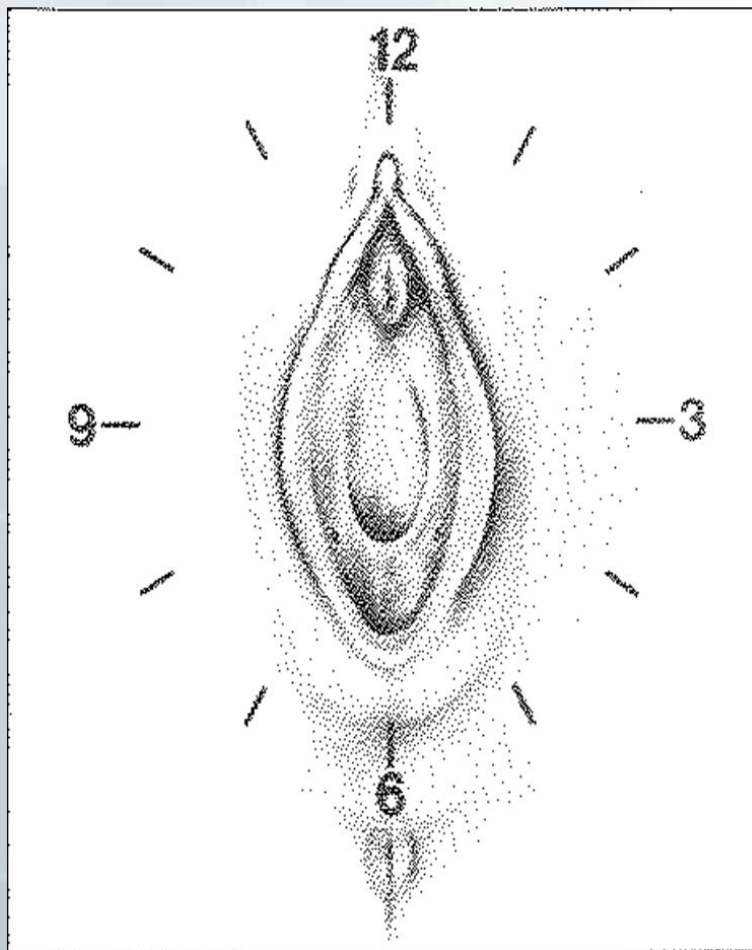
Anatomy

- Lower abdomen, thighs, vulva, inguinal area, mons pubis, labia majora, labia minora, clitoris, urethral opening, hymen, posterior fourchette, perineum, perianal area.
- Look for foreign material/ collect it
- Swab any discharge/blood – forensic + medical

Anatomy



Clock face



Normal anatomy



Melbourne Children's

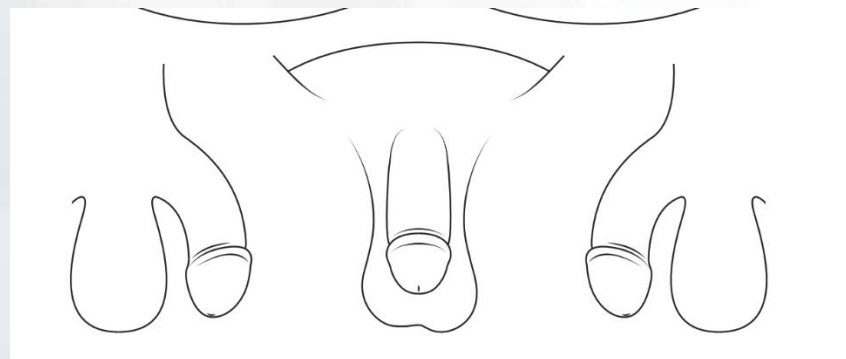
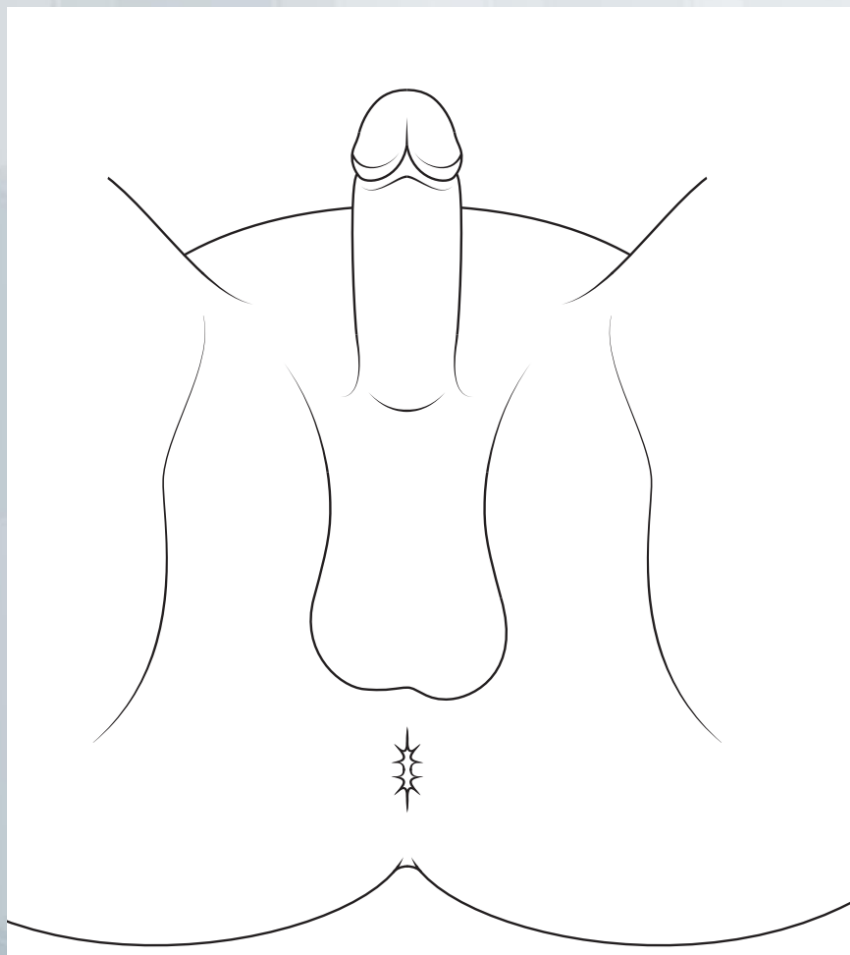
Excellence in clinical care, research and education



Murdoch Childrens Research Institute



Male genitalia



- Trauma
- Bruising
- Skin discolouration / abnormality
- Urethral discharge / bleeding
- Urethral FB

Anal area

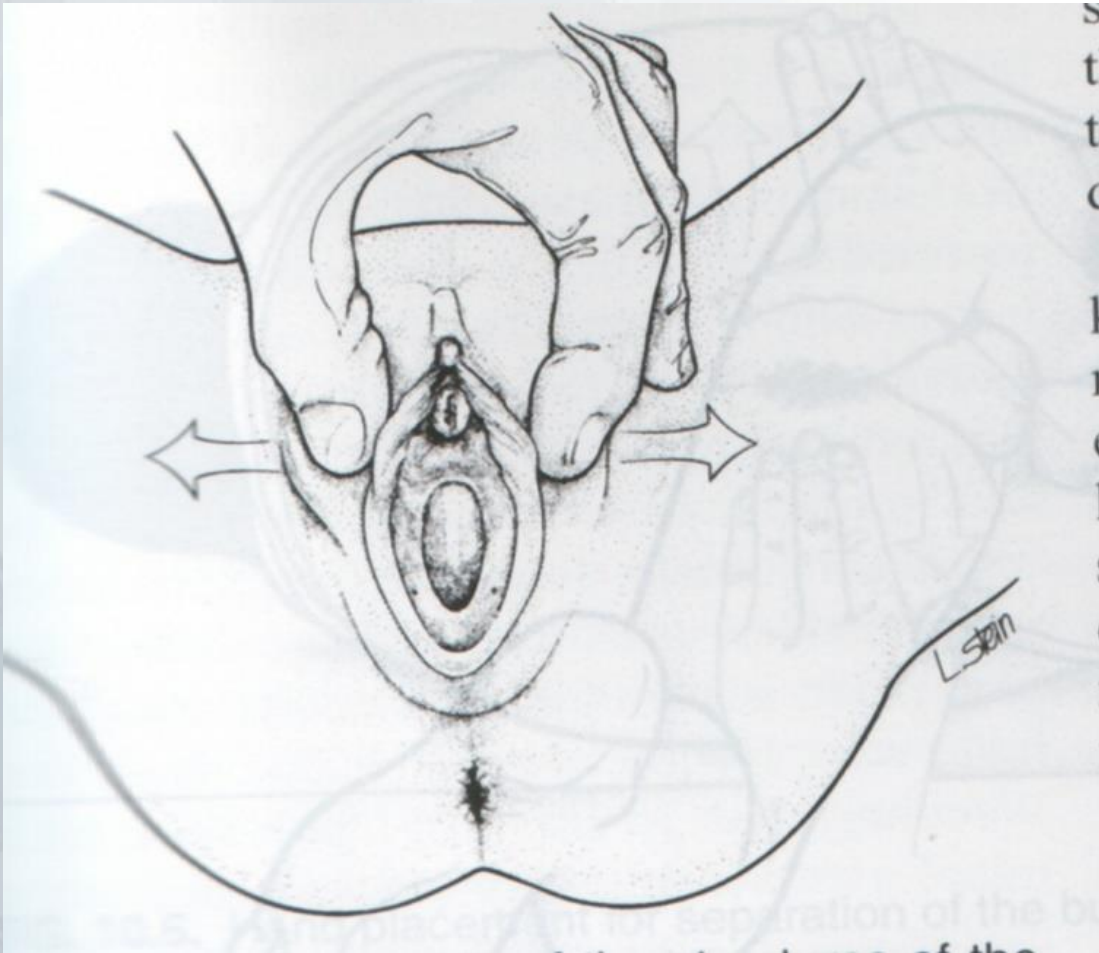
- Can examine in supine position
- Many non specific findings debatable
- Acute trauma
- Signs of sperm / STI

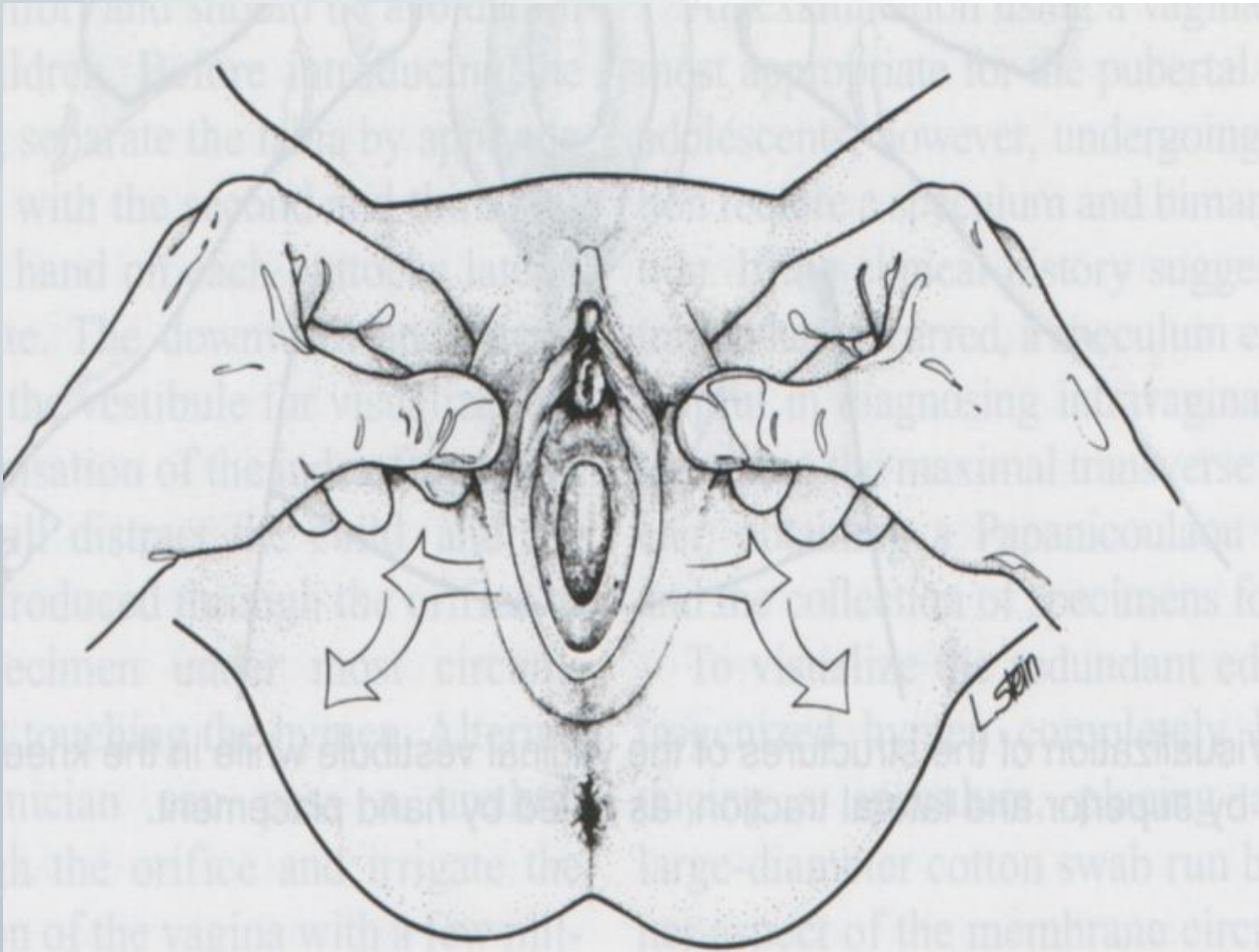
Position

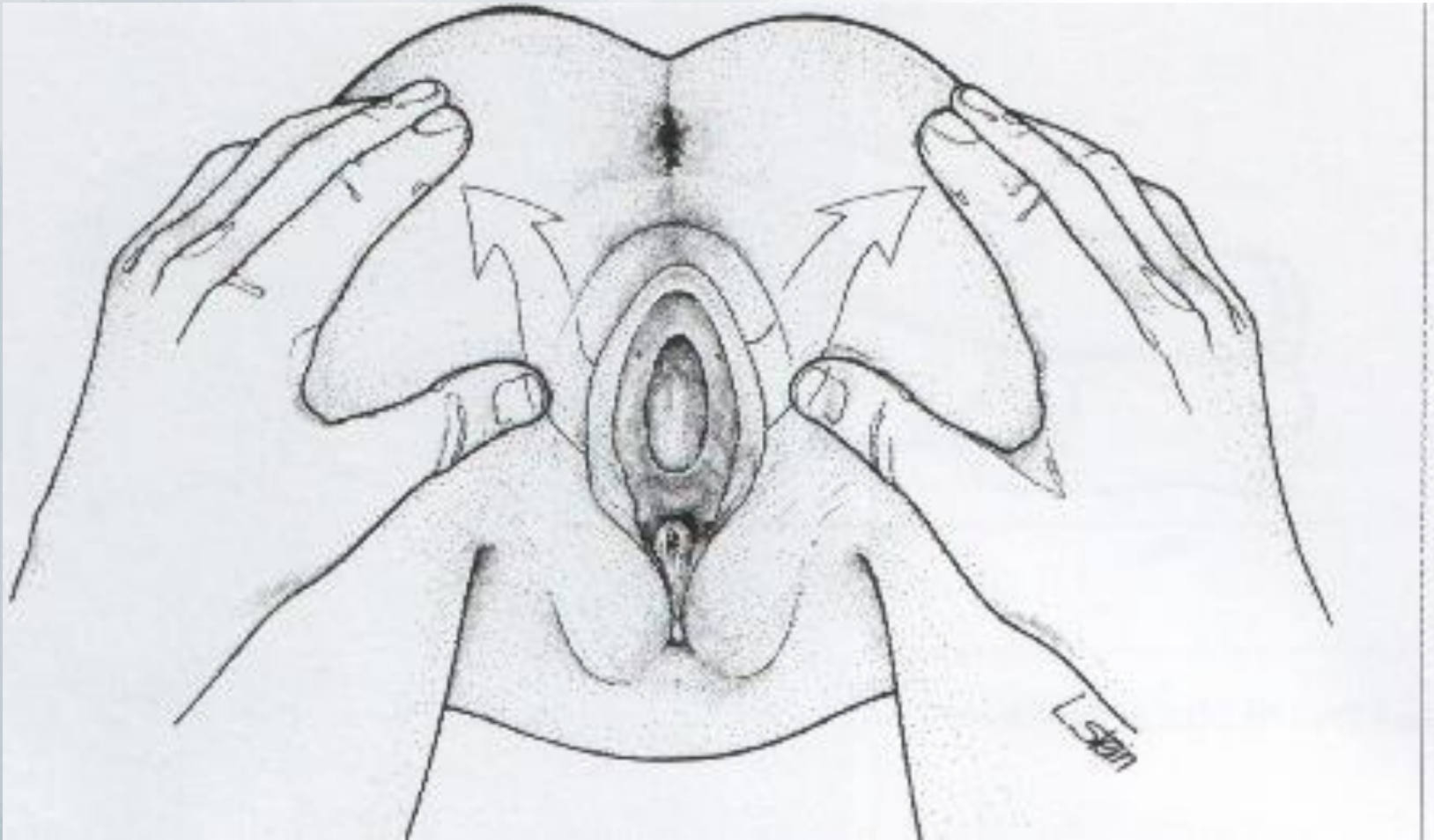
- Supine (parent's lap)
- Frog leg
- Prone (knee-chest)
- Lateral

Extra tips

- Labial traction (posterior fourchette)
- Hands under bottom / Cough
- Reclose / Re-examine (“curtains”)
- Sterile water / moistened cotton swab







Remember

- It's not all about the hymen
- Hymen changes over time
- Correlates with Tanner staging
- Hymen shape (crescentic / annular)

System

- Tanner Stage
- Mons Pubis
- Labia Majora
- Labia Minora
- Clitoral Hood
- Fossa Navicularis / Posterior Fourchette
- Urethral Orifice
- Vaginal Vestibule
- Hymen

Hymenal Stages

- Newborn (swollen, oedematous) – thickened / sleeve like until 2-3 years
- Prepubertal (least oestrogen)
- Early puberty
- Adolescent (thick, high elastic, extra folds)

Court Accessory



What's normal or abnormal?

- AAP Guidelines / Recent Article
“Updated Guidelines for the Medical Assessment and Care of Children who may have been Sexually Abused”

Joyce et al

Journal of Pediatric and Adolescent
Gynecology

April 2016: 29 (2) pp81-87

Free Online Access

Mini-Review

Updated Guidelines for the Medical Assessment and Care of Children Who May Have Been Sexually Abused



Joyce A. Adams MD ^{1,*}, Nancy D. Kellogg MD ², Karen J. Farst MD ³, Nancy S. Harper MD ⁴,
Vincent J. Palusci MD, MS ⁵, Lori D. Frasier MD ⁶, Carolyn J. Levitt MD ⁷, Robert A. Shapiro MD ⁸,
Rebecca L. Moles MD ⁹, Suzanne P. Starling MD ¹⁰

Other publications

Physical signs of child sexual abuse (2015)

This evidence-based review and guidance for best practice is a revision of the 2008 Royal College of Paediatrics and Child Health (RCPCH) publication, *The Physical Signs of Child Sexual Abuse*. Find out more and how to receive a copy.

About

Based on the best available evidence, this guidance has been produced in collaboration with the American Academy of Pediatrics (AAP), the Royal College of Physicians of London (RCP) and The Faculty of Forensic and Legal Medicine (FFLM).


The 2015 book updates the evidence of the physical signs of child sexual abuse from the 2008 publication and includes three new reviews on:

- anogenital signs of accidental injuries in girls and boys
- genital bleeding in prepubertal girls
- healing in anogenital injuries.

Additional information

[Additional information](#) - includes a copy of the searches, list of included studies, quality standards forms, and summary of changes

[Access other RCPCH child protection publications](#)



Normal Variants

Findings Documented in Newborns or Commonly Seen in Nonabused Children*

Normal Variants

1. Normal variations in appearance of the hymen
 - a. Annular: Hymenal tissue present all around the vaginal opening including at the 12 o'clock location
 - b. Crescentic hymen: hymenal tissue is absent at some point above the 3 to 9 o'clock locations
 - c. Imperforate hymen: hymen with no opening
 - d. Microperforate hymen: hymen with one or more small openings
 - e. Septate hymen: hymen with one or more septae across the opening
 - f. Redundant hymen: hymen with multiple flaps, folding over each other
 - g. Hymen with tag of tissue on the rim
 - h. Hymen with mounds or bumps on the rim at any location
 - i. **Any notch or cleft of the hymen (regardless of depth) above the 3 and 9 o'clock locations**
 - j. **Superficial notches of the hymen at or below the 3 and 9 o'clock locations**
 - k. Smooth posterior rim of hymen that appears to be relatively narrow along the entire rim
2. Periurethral or vestibular band(s)
3. Intravaginal ridge(s) or column(s)
4. External ridge on the hymen
5. Linea vestibularis (midline avascular area)
6. Diastasis ani (smooth area)
7. Perianal skin tag(s)
8. Hyperpigmentation of the skin of labia minora or perianal tissues in children of color
9. Dilation of the urethral opening

Embryonic Remnants

- Imperforate
- Microperforate
- Cribriform
- Septate

Notches, bumps and tags

- Notch / Cleft (indentation / concavity in the edge of hymenal margin)
- Bump
- Tag
- Discuss Transections later..

Bands

- Periurethral
- Vestibular
- Hymenal
- External hymenal band

Other normals

- Papillomatosis / Feathering
- Linea Alba
- Lymphoid follicles

Findings commonly caused by medical conditions other than trauma or sexual contact



10. Erythema of the genital tissues
11. increased vascularity of vestibule and hymen
12. Labial adhesion
13. Friability of the posterior fourchette
14. Vaginal discharge
15. **Molluscum contagiosum**
16. Anal fissure(s)
17. Venous congestion or venous pooling in the perianal area
18. Anal dilatation in children with predisposing conditions, such as current symptoms or history of constipation and/or encopresis, or children who are sedated, under anesthesia or with impaired neuromuscular tone for other reasons, such as post-mortem

Conditions mistaken for abuse

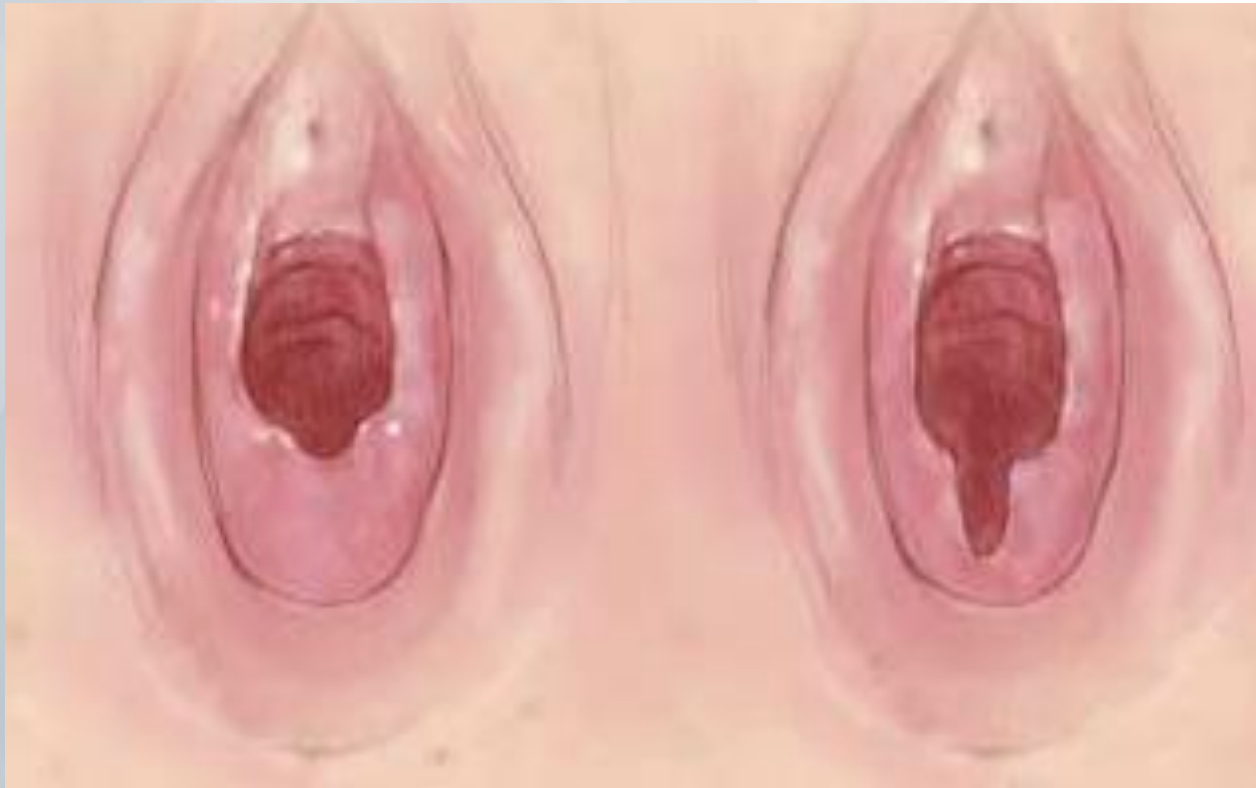19. Urethral prolapse
20. Lichen sclerosus et atrophicus
21. Vulvar ulcer(s)
22. Erythema, inflammation, and fissuring of the perianal or vulvar tissues due to Infection with bacteria, fungus, viruses, parasites, or other infections that are not sexually transmitted
23. Failure of midline fusion, also called perineal groove
24. Rectal prolapse
25. **Visualization of the pectinate/dentate line at the juncture of the ano-derm and rectal mucosa**
26. **Partial dilatation of the external anal sphincter, with the internal sphincter closed, causing the appearance of deep creases in the perianal skin**
27. **Red/purple discoloration of the genital structures (including the hymen) from lividity post-mortem, confirmed by histological analysis.**

Findings with no expert consensus or interpretation with respect to sexual contact or trauma



28. Complete anal dilatation with relaxation of both the internal and external anal sphincters, in the absence of other predisposing factors such as constipation, encopresis, sedation, anesthesia, and neuromuscular conditions
29. **Notch or cleft in the hymen rim, at or below the 3 or 9 o'clock location, which is deeper than a superficial notch and may extend nearly to the base of the hymen, but is not a complete transection. Complete clefts/transsections at 3 or 9 o'clock are also findings with no expert consensus in interpretation.**
30. Genital or anal condyloma acuminatum in the absence of other indicators of abuse; **lesions appearing for the first time in a child older than 5 years may be more likely to be the result of sexual transmission**²²
31. Herpes type 1 or 2, confirmed by culture or PCR testing, in the genital or anal area of a child with no other indicators of sexual abuse²²

Notch / Cleft / Transection



Findings caused by Trauma and/or sexual contact

Acute trauma to external genital/anal tissues, which could be accidental or inflicted

32. Acute laceration(s) or bruising of labia, penis, scrotum, perianal tissues, or perineum

33. Acute laceration of the posterior fourchette or vestibule, not involving the hymen

Residual (healing) injuries to external genital/anal tissues (These rare findings are difficult to diagnose unless an acute injury was previously documented at the same location.)

34. Perianal scar

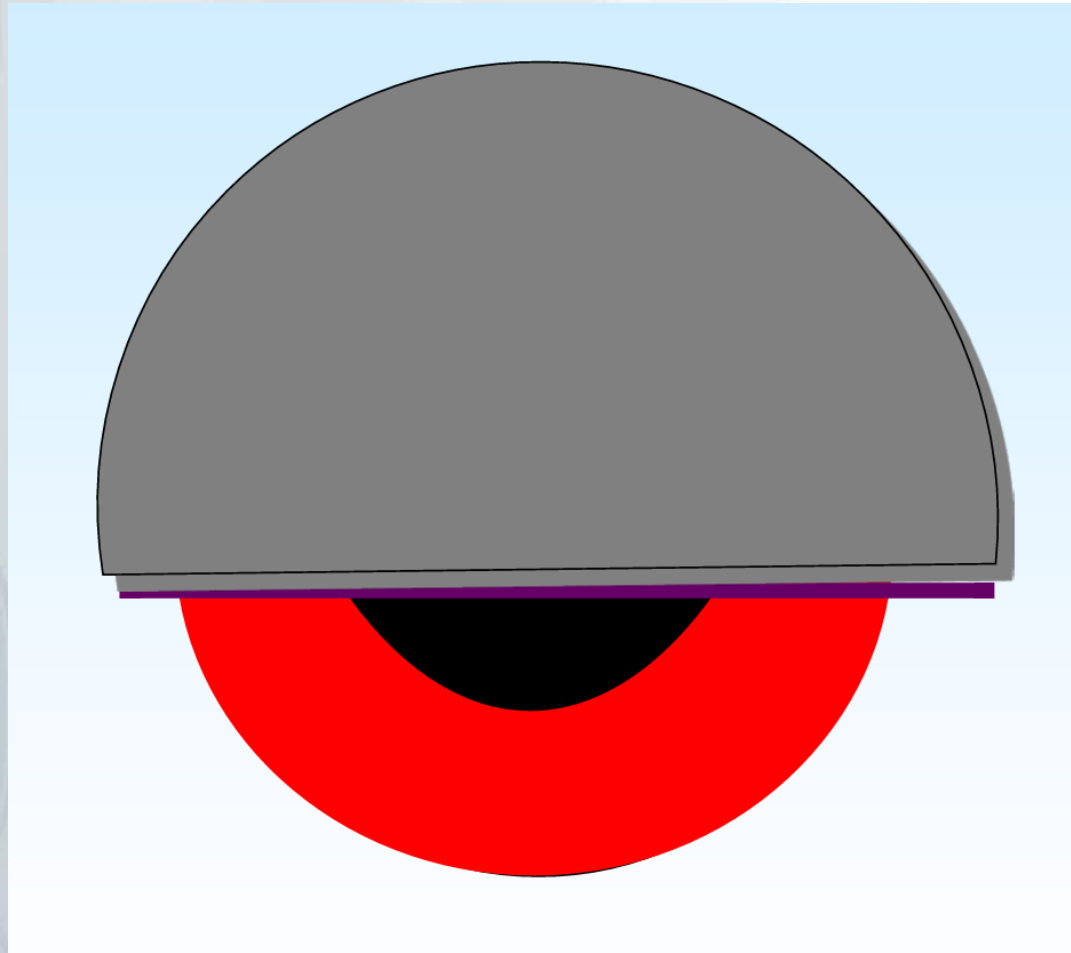
35. Scar of posterior fourchette or fossa

Injuries indicative of acute or healed trauma to the genital / anal area



36. Bruising, **petechiae, or abrasions** on the hymen
37. Acute laceration of the hymen, of any depth; partial or complete
38. **Vaginal laceration**
39. **Perianal laceration with exposure of tissues below the dermis**
40. **Healed hymenal transection/complete hymen cleft- a defect in the hymen between 4 o'clock and 8 o'clock that extends to the base of the hymen, with no hymenal tissue discernible at that location.**
41. A defect in the posterior (inferior) half of the hymen wider than a transection with an absence of hymenal tissue extending to the base of the hymen.

Clock Face Reference



Summary

- Acute
 - Bruising
 - Lacerations (acute tears, partial or complete)
- Chronic
 - Complete hymenal clefts from 4 to 8 o'clock
 - Absence of hymen in the posterior 180 degrees
 - Except in serious congenital anomalies
 - Scarring (rare)
- Other findings
 - Sexually transmitted infection, semen, pregnancy

Infections transmitted by sexual contact



Infections transmitted by sexual contact, unless there is evidence of perinatal transmission or clearly, reasonably and independently documented but rare nonsexual transmission

- 42. Genital, rectal or pharyngeal *Neisseria gonorrhoeae* infection
 - 43. Syphilis
 - 44. Genital or rectal *Chlamydia trachomatis* infection
 - 45. *Trichomonas vaginalis* infection
 - 46. HIV, if transmission by blood transfusion has been ruled out
- Diagnostic of sexual contact
- 46. Pregnancy
 - 47. Semen identified in forensic specimens taken directly from a child's body

“It’s normal to be normal”

History important and examine ASAP after alleged assault but be sensitive to child and family about timing

Examine in different positions – “multi-method”:

- Supine / labial separation
- Supine / labial traction
- Prone-knee-chest / gluteal lift

Photodocumentation, peer review

Injuries unlikely – examination findings often ***normal***

Few residual abnormalities after injuries heal – examination findings ***indistinguishable from normal, except***

- Transection of posterior hymen clear indicator of past trauma
- Jury out on deep clefts

Thank you



Excellence in
clinical care,
research and
education

