

# Reactive arthritis: a clinical review

Ameen Jubber<sup>1</sup>, Arumugam Moorthy<sup>1,2</sup>



Reactive arthritis (ReA) is a form of inflammatory arthritis triggered by a remote antecedent infection, usually in the genitourinary or gastrointestinal tract. It is part of the spondyloarthropathy (SpA) spectrum, an umbrella term for a group of distinct conditions with shared clinical features. Typically, it presents with an asymmetric oligoarthritis of the lower limb joints, and patients may also have sacroiliitis, enthesitis and dactylitis. Other features

often seen include anterior uveitis, urethritis and skin manifestations such as pustular lesions on the plantar areas. Although ReA was characterised initially as a sterile arthritis, the detection of metabolically active *Chlamydia* species in the joint fluid of some affected patients has generated further questions on the pathophysiology of this condition. There are no formal diagnostic criteria, and the diagnosis is mainly clinical. HLA-B27 can support the diagnosis in the correct clinical context, and serves as a prognostic indicator. The majority of patients have a self-limiting course, but some develop chronic SpA and require immunomodulatory therapy.

## Correspondence to:

Ameen Jubber  
Department of  
Rheumatology  
University Hospitals of  
Leicester NHS Trust  
Leicester  
LE1 5WW  
UK

## Email:

ameenjubber1@hotmail.  
co.uk

**Keywords:** reactive arthritis, seronegative arthropathy, spondyloarthropathy

**Financial and Competing Interests:** No conflict of interests declared.

## Introduction

Reactive arthritis (ReA) is an inflammatory arthritis triggered by a distant infection, with no cultivable microbes in the affected joints.<sup>1,2</sup> The antecedent infection most commonly occurs in the gastrointestinal or genitourinary tract, although other sources of infection have also been described. Identifying the inciting infection can be difficult as the rheumatic symptoms usually emerge after the infection has been cleared. Symptoms of a preceding infection may be elicited on history taking, but genital *Chlamydia trachomatis*, the most common cause of reactive arthritis, is asymptomatic in at least 70% of women and 50% of men at the time of diagnosis.<sup>3,4</sup>

In most patients, the disease resolves spontaneously. However, it is important to diagnose ReA early for the following reasons. In the acute phase, it frequently mimics other conditions and this often leads to a delayed diagnosis. Depending on the causative agent and other factors, some patients can develop a chronic inflammatory arthritis necessitating long-term immunomodulatory therapy. Early diagnosis and therapy means a lower burden of disease-related organ and joint damage and better patient outcomes. An example described in our review is that a proportion of patients with post-*Chlamydia* ReA developed ankylosing spondylitis. Moreover, new cases of ReA are emerging from the global COVID-19 pandemic. This will be relevant as many

cases of post-COVID-19 ReA will require specific therapy and may be misdiagnosed as post-COVID fatigue and myalgia or long COVID syndrome. In addition to these reasons, the diagnosis of ReA presents an opportunity to perform contact tracing and implement infection control measures, helping limit the spread of the infection to the wider population.

Reactive arthritis is part of the spondyloarthropathy spectrum. This umbrella term also encompasses psoriatic arthritis, enteropathic arthritis and ankylosing spondylitis. The overlapping features that characterise these distinct conditions include enthesitis, dactylitis and sacroiliitis, as well as extra-articular manifestations such as psoriasis, uveitis and inflammatory bowel disease. There is also a strong association with HLA-B27.<sup>2</sup>

## Search strategy

We searched PubMed and Scopus (1980–2021) for articles and abstracts published in English using the following keywords: 'reactive arthritis', 'Reiter's' and 'Reiter's syndrome'. The criteria for eligibility included case reports, case series, cohort studies, systematic reviews, meta-analysis and letters to the editor. The titles and abstracts were screened before reviewing the articles.<sup>5</sup> We also reviewed guidance from the European League Against Rheumatism on the diagnosis and management of spondyloarthropathies, as well as guidance from Arthritis Research UK.

<sup>1</sup>Department of Rheumatology, University Hospitals of Leicester NHS Trust, Leicester; <sup>2</sup>College of Life Sciences, University of Leicester, Leicester

## Epidemiology

The main challenge of ReA epidemiological studies is a lack of diagnostic criteria. Studies reveal a wide variation in the incidence and prevalence, and are likely influenced by the proportion of the study population positive for HLA-B27, as well as the local incidence of certain infections. Depending on the attack rate of an infection, local outbreaks can lead to a rise in the incidence of reactive arthritis during a specified time. In addition to some organisms being more arthritogenic than others, this likely also applies to different species of the same organism.<sup>6</sup>

A systematic review in 2013 found that the mean incidence of reactive arthritis was 9, 12 and 12 cases per 1,000 of *Campylobacter*, *Salmonella* and *Shigella* infections respectively.<sup>7</sup> The majority of cases of *Chlamydia trachomatis* are asymptomatic, but the attack rate is estimated to be around 5%.<sup>8</sup> One review found that despite a rise in the number of *Chlamydia* diagnoses over 20 years, the rate of reactive arthritis diagnoses declined over time.<sup>8</sup> Whereas postvenereal ReA most commonly affects men in the third decade of life (male to female ratio 9:1), postenteric ReA affects men and women equally.<sup>6</sup>

## Causative agents

The most common infections associated with ReA are listed in Table 1. This list is not exhaustive and has expanded in recent years to include respiratory pathogens and viruses.

### Mycobacterial infection

Poncet's disease is a non-erosive inflammatory arthritis that follows mycobacterial infection. Unlike tuberculous arthritis, mycobacteria are not isolated from the affected joint. Most commonly, it follows pulmonary TB, although it can occur with extrapulmonary TB infection.<sup>11</sup> Reactive arthritis has also been reported following intravesical BCG therapy for bladder cancer.<sup>12</sup> It is important to note, however, that Poncet's disease and postintravesical BCG ReA are considered entities different from classical ReA. Unlike classical ReA, Poncet's disease is not associated with extra-articular manifestations or axial involvement, there is no tendency to chronicity and it improves with anti-TB therapy.<sup>11</sup>

### Streptococcal infection

Poststreptococcal ReA (PSRA) is considered a different entity to classical ReA and is usually classified as an infection-related arthritis. Although both conditions present as arthritis secondary to an extra-articular infection, they have different clinical characteristics.<sup>13</sup> Unlike classical ReA that presents as an oligoarthritis, PSRA typically causes a polyarthritis. HLA-B27 is present in under 10% of cases of PSRA. Axial involvement and extra-articular manifestations are rarer in PSRA when compared with classical ReA, there is less tendency to chronicity, and antibiotic therapy does improve outcome.<sup>13</sup> PSRA is also different to acute rheumatic fever, which is discussed further under 'differential diagnosis'.

**Table 1** Infections associated with ReA<sup>3,9,10</sup>

Common
<i>Chlamydia trachomatis</i>
<i>Salmonella</i> (several species)
<i>Shigella</i> (especially <i>S flexneri</i> )
<i>Campylobacter jejuni</i>
<i>Yersinia</i> (especially <i>Y enterocolitica</i> and <i>Y pseudotuberculosis</i> )
Uncommon
B-haemolytic <i>Streptococci</i>
<i>Mycoplasma genitalium</i>
<i>Ureaplasma urealyticum</i>
<i>Chlamydia pneumonia</i>
<i>Chlamydia psittaci</i>
<i>Mycoplasma pneumoniae</i>
HIV
<i>Clostridium difficile</i>
<i>Escherichia coli</i>
Intravesical <i>Bacillus Calmette-Guerin</i> (BCG)
<i>Neisseria gonorrhoea</i>
<i>Staphylococcus aureus</i>
<i>Staphylococcus epidermis</i>
<i>Mycobacterium tuberculosis</i> (Poncet's disease)

### HIV

HIV has been linked to reactive arthritis. Patients can develop an oligoarthritis of the lower limbs, accompanied by enthesitis. Patients can also develop cutaneous manifestations.<sup>14</sup> Since HIV can be contracted by sexual contact, it is important to exclude subclinical *Chlamydia* infection. In the case of intravenous drug use, it would be important to exclude septic arthritis and bacterial endocarditis.

### COVID-19

Since the COVID-19 pandemic began in 2019, new information continues to emerge on its rheumatic manifestations. Similar to other viral illnesses, COVID-19 can cause patients to experience joint and muscle aches. However, at the time of this writing we have identified 16 case reports in the literature describing a post-COVID-19 illness with the hallmarks of reactive arthritis (please see the Table in supplementary online-only material).

Of the 16 cases identified, two required tracheal intubation. The rheumatic presentations ranged from arthralgia to mono-, oligo- and polyarthritis. Dactylitis and enthesitis were also observed. Four patients developed cutaneous manifestations including new onset psoriatic patches and a vasculitic rash. C-reactive protein can be normal or elevated. Of the eight patients where HLA-B27 was reported, only one was positive. Of the four patients where synovial fluid was analysed for COVID PCR, all were negative. All cases resolved with supportive therapy, non-steroidal anti-inflammatory drugs (NSAIDs) and prednisolone. One patient required an intra-articular injection after his symptoms recurred.

One case series<sup>15</sup> described four patients developing acute inflammatory arthritis post-COVID-19. All four were proven on synovial fluid analysis to be crystal arthropathies. All four had a history of either gout or recurrent arthritis. This highlights the important diagnostic role of synovial fluid analysis in the evaluation of these patients. Crystal arthropathies are commonly precipitated by acute medical illness.

It also remains a possibility that the post-COVID-19 inflammatory arthritis is a viral arthritis rather than a reactive arthritis. The use of COVID PCR testing on synovial fluid is not a validated test. However, when crystal and septic arthritis is excluded, reactive arthritis is a reasonable diagnostic consideration.

## Clinical manifestations

The clinical manifestations of reactive arthritis include articular and periarticular features, mucocutaneous, genitourinary and ocular features.

### Articular and periarticular features

Reactive arthritis typically causes an acute asymmetrical oligoarthritis of the large joints of the lower limbs, although a small joint polyarthritis in the upper limbs can occur.<sup>32</sup> Axial involvement can occur at the cervical, thoracic and lumbosacral spine. Sacroiliitis typically presents with lower back pain that is worse at night, as well as alternating buttock pain. Sacroiliitis occurs in approximately one third and one tenth of patients with urogenital and enteric reactive arthritis respectively.<sup>33,34</sup>

Enthesitis is inflammation at the point where tendons and ligaments insert into bone, giving rise to localised pain, swelling and tenderness. Common sites include the Achilles tendon and plantar aponeurosis insertions into the calcaneus, leading to pain on walking. Enthesitis is highly characteristic of the spondyloarthropathies, and may be associated with adjacent osteitis on magnetic resonance imaging.<sup>35</sup>

Dactylitis, also known as sausage digit, is diffuse swelling of a whole toe or finger. It is thought to be due to digital tendonitis, interphalangeal joint synovitis and multiple enthesal lesions.<sup>35</sup> It is common in the spondyloarthropathies,<sup>3</sup> and can occur in up to 40% of some populations with reactive arthritis.<sup>32</sup>

### Mucocutaneous features

Mucocutaneous lesions are seen in up to half of patients. Keratoderma blennorrhagicum is highly characteristic of reactive arthritis. These pustular lesions, typically found on plantar areas, may turn scaly and hyperkeratotic and coalesce into psoriatic plaques. Circinate balanitis is characterised by painless, shallow psoriasiform lesions over the glans or shaft of the penis.<sup>34,35</sup> Oral ulceration can also occur.<sup>3</sup> Furthermore, nails can become dystrophic and thickened, resembling psoriatic onychodystrophy.<sup>9</sup>

### Genitourinary features

Genitourinary symptoms may be due to the underlying infection (for example, *Chlamydia*), but can also be an extra-articular manifestation of reactive arthritis, including postenteric ReA. Symptoms include urethritis, cervicitis, salpingo-oophoritis, cystitis and prostatitis.<sup>34</sup>

### Ocular features

Ocular manifestations include conjunctivitis, keratitis, episcleritis and anterior uveitis. Conjunctivitis and acute anterior uveitis occur in about 50% and 75% of men with urogenital and enteric reactive arthritis respectively.<sup>10</sup> These typically occur early in the disease, and can often precede the arthritis by a few days.<sup>34</sup>

## Pathophysiology

### Is reactive arthritis a sterile arthritis?

Although reactive arthritis is often considered to be a post-infectious sterile arthritis, the identification of intracellular, metabolically active *Chlamydia* in the synovium of reactive arthritis patients has challenged this notion.<sup>36</sup> It is thought that following the primary *Chlamydia* infection, the pathogens are incorporated intracellularly into monocytes and transported to the synovium.<sup>37</sup> In contrast to septic arthritis, these pathogens are non-culturable.<sup>38</sup> These small numbers of intra-articular microbes with attenuated virulence may be the cause of some cases of chronic reactive arthritis.<sup>39</sup>

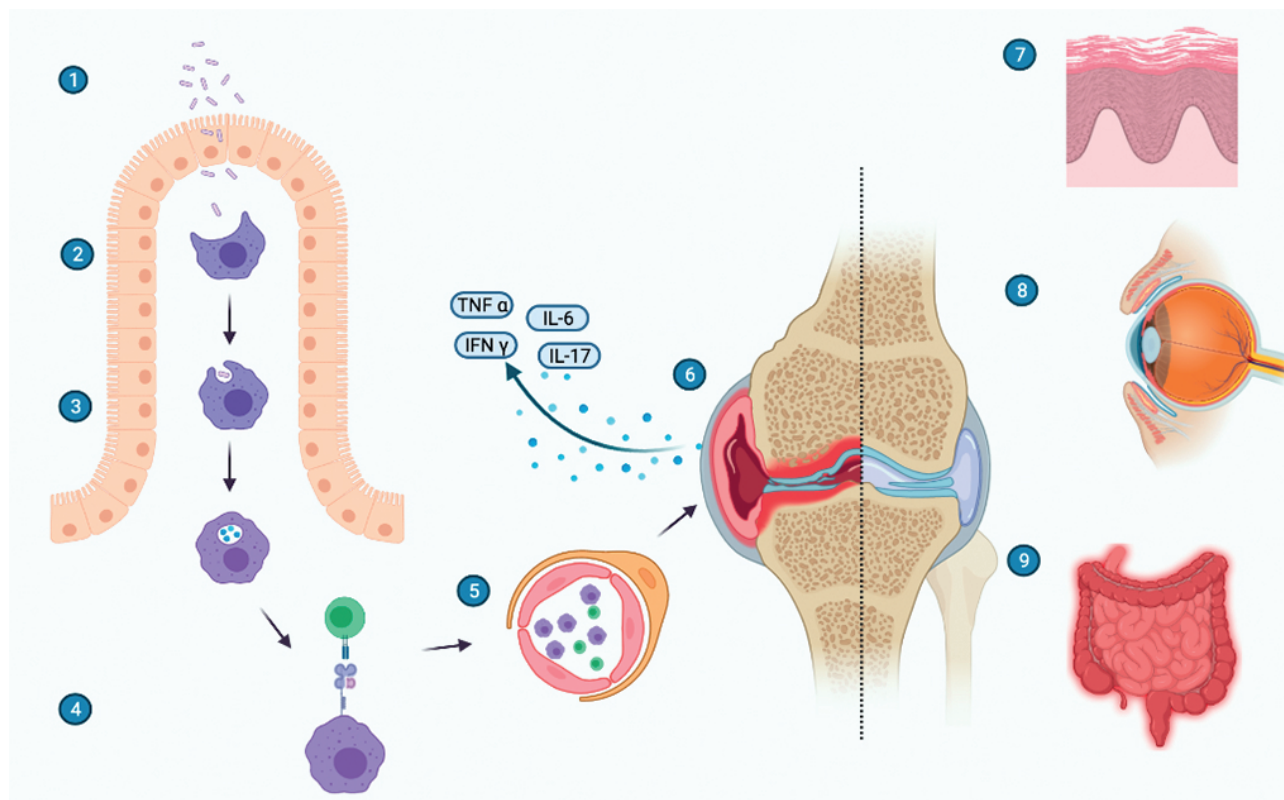
### The trafficking of organisms

In reactive arthritis induced by enterobacteria, it may be that the bacteria survive at an extra-articular site, especially the mucous membranes and lymphatic ganglions, and are trafficked to the joint by monocytes.<sup>40</sup> There, bacterial antigens such as lipopolysaccharides and heat shock proteins may induce inflammation.<sup>39</sup>

### Role of HLA-B27

The role of HLA-B27 in reactive arthritis is a topic of ongoing discussion. HLA-B27, a class 1 surface antigen, presents antigenic peptides to T-cells. HLA-B27-positive patients not only have a 50-fold increased risk of developing reactive arthritis, their disease is more likely to be severe, have a longer duration and be associated with mucocutaneous, ocular and axial features.<sup>35</sup>

The arthritogenic peptide hypothesis states that microbial antigens mimic certain self-antigens, causing reactivity of HLA-B27-specific CD8 T lymphocytes and leading to inflammation.<sup>41</sup> This would be an instance of molecular mimicry, a state where there is structural similarity between foreign and self-peptide sequences that can lead to foreign peptides inducing a B- or T-cell-derived auto reaction.<sup>42</sup> The HLA-B27 misfolding hypothesis states that since HLA-B27 folds slowly during assembly in the endoplasmic reticulum, it is prone to instability and the accumulation of homodimers. This causes activation of inflammatory pathways.<sup>43</sup> Bas et al. suggest that the cytokine profile in HLA-B27 patients

**Figure 1** Proposed mechanism for reactive arthritis (created with BioRender.com)

1 Pathogenic bacteria invade the epithelium; 2 antigen presenting cell (e.g. macrophage); 3 phagocytosis; 4 antigen presenting cells present the arthritogenic peptide to a CD8+ T-cell using HLA-B27; 5 the antigen presenting cells and T-cells travel through the circulation to reach the synovium; 6 in the joint they release cytokines and trigger an inflammatory response; 7 extra-articular manifestations include psoriasis; 8 anterior uveitis; 9 colitis

may have a role in impaired pathogen clearance, which may potentiate more severe or chronic arthritis.<sup>44</sup>

### Role of gut microbiome

The gut microbiome may also play a vital role in the pathogenesis of spondyloarthropathy. This refers to the vast range of microbes that inhabit the intestine; microbes that outnumber the host cells by a factor of ten. There exists a complex relationship between the host immune system and the gut microbiome.<sup>45</sup> One study looked at the intestinal microbes in patients with reactive arthritis and found a greater abundance of *Erwinia* and *Pseudomonas* and a higher prevalence of typical enteropathogens associated with ReA.<sup>46</sup> This remains an evolving field and may hold the key to new therapeutic interventions in future (Figure 1).

### Cytokine network

The complex network of cytokines that mediate the disease process will differ depending on the stage of the disease. In the acute phase, bacterial clearance may be favoured by the production of IL-12, IL-23 and IL-6, as well as IFN gamma and IL-17. Regulatory T-cells may produce IL-10, which could lead to bacterial persistence in the mucosa. If the disease becomes chronic, IL-6, IL-17, IFN gamma and TNF alpha can lead to chronic inflammation in the joint. This inflammation may be increased with the persistence of bacterial antigens in the joint.<sup>47</sup>

## Diagnosis

### History

Diagnosis relies on evidence of a preceding infection in a patient presenting with a compatible clinical picture. A full history should be elicited, including sexual history. A family history of spondyloarthropathy can support the diagnosis.

### Examination

Patients should be examined for joint effusions, dactylitis and enthesitis, as well as extra-articular manifestations such as oral ulcers, ocular inflammation, skin rashes and urethral discharge.

### Genitourinary infection

It is important to note that many patients with *Chlamydia trachomatis* infection are asymptomatic.<sup>4</sup> Nucleic acid amplification testing can be performed on a urine sample or urethral swab and this is the investigation of choice.<sup>48</sup> Antibody testing for *Chlamydia trachomatis* is limited by cross-reactivity with *Chlamydia pneumoniae*, a prevalent infection in the general population.<sup>34</sup> The patient should be reviewed by a genitourinary medicine specialist to help exclude other coexisting sexually transmitted infections and assist with contact tracing.

## Gastrointestinal infection

In patients presenting with postdysenteric reactive arthritis, the gastrointestinal symptoms have often completely resolved by the time the rheumatic features develop, and the microbe may not be detectable in the stool.<sup>1</sup> Some gastrointestinal infections such as *Salmonella* and *Yersinia* induce a strong antibody response,<sup>48</sup> and enzyme immune-assay can be used to serologically diagnose *Yersinia*, *Salmonella* and *Campylobacter*.<sup>1</sup> *Clostridium difficile* infection is most frequently diagnosed by stool PCR.<sup>3</sup>

## Blood tests

ESR and CRP are elevated during the acute phases of the disease, and these usually normalise during the chronic stages.<sup>34</sup> Patients with spondyloarthritis tend to have higher acute phase reactants when enthesitis is present.<sup>3</sup> HLA-B27 has been reported to be positive in up to 90% of patients with reactive arthritis.<sup>49</sup> However, a significant minority of the healthy population are also positive. Therefore, it has no role as a diagnostic tool, but it does predict more severe arthritis and a longer disease course.<sup>50</sup> HIV testing should be considered as reactive arthritis occurs with a higher prevalence in HIV-positive patients.<sup>35</sup>

## Synovial fluid analysis

To exclude septic and crystal arthritis, synovial fluid analysis should be performed where possible.

## Imaging

Radiographs of affected joints may show joint space narrowing, soft tissue swelling, erosions and periosteal new bone formation.<sup>6</sup> Bony spurs may form at sites of enthesitis.<sup>35</sup> In the acute phase, radiographs are unlikely to show syndesmophytes or features of sacroiliitis. Spinal MRI findings in the acute phase include bone marrow oedema and sacroiliac joint erosions.<sup>51</sup>

## Ophthalmic examination

Patients reporting eye discomfort and signs of inflammation require an ophthalmology review with slit-lamp examination.

## Classification criteria

Although there are no validated diagnostic criteria, classification criteria were introduced in the 4th International Workshop on Reactive Arthritis (Table 2).<sup>52</sup>

## Differential diagnosis

When evaluating the patient, the pattern of joint involvement and any extra-articular manifestations can help direct the clinician to further investigations (Table 3). Patients presenting with mono- or oligoarthritis require synovial fluid analysis to exclude septic or crystal arthritis.

## Spondyloarthropathies

Reactive arthritis is part of the spondyloarthritides (SpA), including ankylosing spondylitis, psoriatic arthritis and enteropathic arthritis. Patients presenting with peripheral

**Table 2** Classification criteria for reactive arthritis (adapted from Braun et al.)<sup>52</sup>

Major criteria
<ol style="list-style-type: none"> <li>Arthritis with 2 or 3 of the following: <ul style="list-style-type: none"> <li>Asymmetric</li> <li>Mono- or oligoarthritis</li> <li>Predominantly affecting the lower limbs</li> </ul> </li> <li>Preceding symptomatic infection with 1 or 2 of the following: <ul style="list-style-type: none"> <li>Enteritis (diarrhoea for at least 1 day, 3 days to 6 weeks before onset of arthritis)</li> <li>Urethritis (dysuria or discharge for at least 1 day, 3 days to 6 weeks before the onset of arthritis)</li> </ul> </li> </ol>
Minor criteria, at least one of the following
<ol style="list-style-type: none"> <li>Evidence of triggering infection: <ul style="list-style-type: none"> <li>Positive nucleic acid amplification test in the morning urine or urethral/cervical swab for <i>Chlamydia trachomatis</i></li> <li>Positive stool culture for enteric pathogens associated with ReA</li> </ul> </li> <li>Evidence of persistent synovial infection (positive immunohistology or PCR for <i>Chlamydia</i>)</li> </ol>
Definition of reactive arthritis
<ul style="list-style-type: none"> <li>Definite ReA: both major criteria and a relevant minor criterion</li> <li>Probably ReA: (a) both major criteria, but no relevant minor criteria or (b) major criterion 1 and one or more of the minor criteria</li> </ul>
Exclusion criteria
Other causes for acute arthritis

arthritis, enthesitis, dactylitis and uveitis may have a syndrome indistinguishable from ReA. However, there would be no evidence of a preceding infection. Progression to chronicity can occur in ReA and long-term immunomodulatory therapy may be required.

## Disseminated gonococcal infection

Disseminated gonococcal infection (DGI) must be considered. It can present with purulent mono- or oligoarthritis, or a triad of polyarthralgia, dermatitis and tenosynovitis. A recent history of urogenital infection is commonly absent. Diagnosis is established by identifying *Neisseria gonorrhoeae* and requires microbiological testing of synovial fluid, skin, rectal, pharyngeal, urethral and cervical specimens, and blood cultures.<sup>53</sup>

## Acute rheumatic fever

Acute rheumatic fever (ARF) also requires consideration. Arthritis commonly occurs in this condition and diagnosed patients require secondary prophylactic therapy. Although poststreptococcal reactive arthritis has been described, some authors have identified features to differentiate it from ARF, including the absence of carditis, poor response to aspirin and NSAIDs and extra-articular features such as tenosynovitis and renal abnormalities.<sup>54</sup>

**Table 3** Differential diagnoses

Differential diagnosis	Distinguishing features
Other spondyloarthropathies such as ankylosing spondylitis, psoriatic arthritis, enteropathic arthritis	Absence of preceding infection. <i>Note: patients with ReA can develop a chronic spondyloarthropathy</i>
Septic arthritis	Synovial fluid analysis is usually positive for gram stain $\pm$ culture. If microbiology is negative, but index of suspicion high, patients are treated as for septic arthritis, with antibiotics and joint wash-out.
Crystal arthritis	Synovial fluid analysis may show needle-shaped crystals negatively birefringent under polarised light in gout, or rhomboid-shaped crystals that are positively birefringent under polarised light in pseudogout.
Disseminated gonococcal infection <sup>53</sup>	Diagnosis requires microbiology testing to identify <i>Neisseria gonorrhoea</i> . Blood cultures, synovial fluid analysis, and pharyngeal, urethral, cervical, rectal and skin specimens should be tested.
Acute rheumatic fever <sup>54</sup>	Poststreptococcal ReA is recognised, but unlike ARF is not associated with carditis. Cardiac imaging may be required.
Inflammatory bowel disease (IBD) Behçet's disease Coeliac disease Whipple's disease Parasitic infections	These conditions may present in a similar manner to ReA due to the presence of diarrhoea with arthritis. These conditions tend to be more chronic and diagnosis may require serology, cultures, biopsy etc.
Viral infection (e.g. enteroviruses, HIV, hepatitis B and C, parvovirus B19, dengue fever, chikungunya) <sup>55</sup>	A relevant travel history and risk factors may be present on history taking. Viral infections may be accompanied by fever, myalgia, headache, rash. Microbiology investigations can help to diagnose.

### Disorders affecting the gastrointestinal tract

Diarrhoea and arthritis together can occur with inflammatory bowel disease (IBD), Behçet's disease, coeliac disease, Whipple's disease and parasitic infections. These can be differentiated from ReA by their chronicity and distinct extra-articular manifestations. For example, Behçet's syndrome can present with oligoarthritis, diarrhoea, uveitis and oral ulceration, but may also have vascular and neurological manifestations not seen in ReA.

### Viral infections

Viral infections can present with multisystem features, making them important differentials of ReA. Viral arthritides are usually self-limiting and do not require a specific treatment. It is important to take a detailed history including a travel history and history of any unwell contacts.

Viruses that can present with arthritis include enteroviruses such as Coxsackie and echovirus. These can cause arthritis as well as diarrhoea, fever, myalgias, rash, sore throat and conjunctivitis.<sup>55</sup> Patients with parvovirus B19 can have a rash and symmetric polyarthritis, necessitating the exclusion of rheumatoid arthritis as well as ReA.<sup>56</sup> Chronic hepatitis C can cause polyarthralgias, and less commonly oligo- or polyarthritis. Acute hepatitis B can also present with a rash and polyarthritis in the pre-icteric phase.<sup>57</sup>

Dengue fever, also known as 'break-bone fever', is an acute febrile illness transmitted by mosquitoes. It is endemic in many countries and risk of exposure tends to be higher in urban areas. During the acute phase, patients may have arthralgias and myalgias. Although there are case reports of

patients developing sacroiliitis during<sup>58</sup> and after<sup>59</sup> resolution of the acute febrile illness, dengue fever has not traditionally been considered a cause of reactive arthritis.

Chikungunya is an alphavirus transmitted by mosquitoes. It is characterised by an acute febrile polyarthralgia, fever and rash. It is a global public health concern and is endemic in many parts of West Africa. Outbreaks have occurred in many parts of the world, including Europe, the Americas and Australia.<sup>60</sup> Chikungunya is strongly associated with postviral rheumatic manifestations. The most frequent is symmetrical polyarthralgia. Some patients can develop a rheumatoid arthritis-like picture with synovitis, erosions and positive serology for anti-CCP and rheumatoid factor. However, the prevalence of these features greatly varies in the literature. Some patients can develop enthesitis, tenosynovitis and a psoriatic arthritis-type picture. Prevalence of HLA-B27 tends to be lower when compared with the spondyloarthropathies.<sup>61</sup>

## Management

### The role of antibiotics

Antibiotics do not have a role in the treatment of the arthritis itself, but may be required for the triggering infection. Patients with an acute diarrhoeal illness generally do not require antibiotic therapy, unless they are systemically unwell, immunocompromised or have significant comorbidities.<sup>62</sup> The course of postdysentery reactive arthritis is unlikely to be altered by antibiotic therapy.<sup>3</sup> When *Chlamydia trachomatis* is identified, antibiotic therapy is indicated for the patient and their partner. Although some studies demonstrated a shorter duration of reactive arthritis with long-term antibiotic

therapy, overall results are mixed<sup>63,64,65</sup> and this practice has not become standardised.

### Initial therapy

In the majority of patients, reactive arthritis is self-limited. The initial goals of therapy are therefore symptomatic. NSAIDs are usually first line, but are usually contraindicated in patients with renal, cardiac or gastrointestinal disease. Patients should be counselled on potential side effects. If responses are inadequate or NSAIDs are contraindicated, patients may benefit from intra-articular glucocorticoid injections. If a large number of joints are involved, systemic glucocorticoids can be used. The choice of dose and tapering regime depends on the number of joints involved and severity of inflammation, aiming to taper to the lowest effective dose. Owing to the significant adverse effects associated with long-term steroid use, consideration should be given to giving stomach and bone-protection therapy.

### Disease-modifying antirheumatic drugs (DMARDs)

If the above measures are unsuccessful, or the disease has lasted longer than six months, disease-modifying antirheumatic drugs (DMARDs) are indicated. Sulfasalazine and methotrexate can be used, although sulfasalazine is the preferred first-line agent due to its stronger evidence base in reactive arthritis.<sup>66</sup> An attempt at weaning from the DMARD can be made three to six months after the patient enters remission.

### Biologic therapy

If the disease persists despite DMARDs, anti-tumour necrosis factor (TNF) agents can be used. Etanercept, a soluble TNF receptor immunoglobulin fusion protein, has shown therapeutic benefit.<sup>67</sup>

### Therapy for skin disease

Skin lesions may not require treatment if mild. If treatment is required, topical corticosteroid preparations can be used, as well as topical salicylic acid ointments and vitamin D3 analogues. More severe lesions may require methotrexate, retinoids or TNF inhibitors.<sup>68</sup>

### Prognosis

The duration of acute ReA is typically three to five months.<sup>69</sup> Chronic disease refers to a disease duration longer than six months.<sup>48</sup> Overall, around 25% of patients develop chronic SpA of varying severity.<sup>1</sup> One study showed that *Chlamydia*-induced ReA and HLA-B27 positivity are two factors associated with an increased risk of developing sacroiliitis or ankylosing spondylitis.<sup>70</sup> In addition to these, progression to chronicity is also predicted by the presence of chronic gut inflammation and a family history of spondyloarthropathy.<sup>1</sup> Patients may also develop secondary osteoarthritis of peripheral joints (e.g. the hip or knee), even if the ReA was self-limited. This

**Table 4** Tips for the non-specialist

- Patients may not volunteer a history of any preceding infection. Ask the patient specifically about any recent gastrointestinal or genitourinary symptoms.
- Elicit any history of travel or unwell contacts. Viral illnesses such as HIV, hepatitis B and C, dengue fever and chikungunya can often have multisystem presentations similar to ReA.
- The pattern of joint involvement and extra-articular manifestations can help to narrow the differential diagnosis. Therefore, enquire about cutaneous, ocular and genitourinary symptoms etc.
- The list of causative infections has expanded beyond gastrointestinal and genitourinary agents. Consider also respiratory pathogens, streptococcal throat infection, tuberculosis and intravesical BCG.
- Patients with mono- or oligoarthritis need joint aspiration and synovial fluid analysis to exclude septic or crystal arthritis. Septic arthritis can be present in more than one joint.
- Multidisciplinary input is required. Rheumatology, ophthalmology and dermatology input may be required. If a sexually transmitted infection (STI) is suspected, a genitourinary medicine review is indicated to diagnose and manage the STI, exclude other STIs and assist with contact tracing.
- Antibiotics may help with active infection, but are not indicated for the arthritis once the infection has resolved.
- NSAIDs are usually effective, but consider the patient's comorbidities and any contraindications such as asthma, gastrointestinal, renal, cardiac disease etc., and consider stomach protection therapy.

form of osteoarthritis can develop because of joint damage accrued during previous inflammation.<sup>35</sup>

### Conclusion

ReA should be considered in the differential diagnosis of any acute inflammatory arthritis (Table 4). The initial infection may go unnoticed by the patient, especially in the case of *Chlamydia trachomatis* infection. The list of causative infections has expanded in recent years, and now includes respiratory pathogens, viruses and intravesical BCG. An understanding of the pathophysiology has evolved and dispensed with the characterisation of ReA as a 'sterile arthritis'. Further work may reveal how the disease progresses to chronicity, and lead to enhanced disease-modifying therapies. A lack of formal diagnostic criteria presents a challenge in the review of epidemiological studies.

## Case 1

An 18-year-old man presents with a two-week history of pain and swelling affecting his left ankle and right knee. There were no preceding symptoms. He denies any fever, rashes, ocular symptoms and genitourinary symptoms. On examination, his temperature is 37.6 degrees Celsius. His left ankle is warm and tender. His right knee is warm and swollen with a detectable effusion. Both joints have a markedly reduced active range of motion. There is no joint erythema. His CRP is 58 mg/L (normal 0–5 mg/L), white cell count is 11.5 (normal 4.5 to 11.0 × 10<sup>9</sup>/L). Joint X-rays are unremarkable.

What is the next most appropriate step?

- A Urethral swab for nucleic acid amplification test
- B Contact tracing
- C Stat dose intravenous ceftriaxone
- D Right knee aspiration
- E Prednisolone 30 mg

The correct answer is D. In a patient presenting with a recent onset hot swollen joint, it is imperative to exclude septic arthritis. This can present with more than one joint affected. The joint fluid would be analysed for microscopy, culture and sensitivity as well as crystals. A sexual health history and evaluation would also be important in view of his presentation. An acute oligoarthritis is the classic presentation of reactive arthritis. Therefore, A and B may become important later. Prednisolone would not be the first line of treatment, especially given that a diagnosis has not yet been established.

## Case 2

A 36-year-old woman presents with an eight-month history of pain and swelling in her knees, left ankle and right wrist. Two weeks prior to this she was unwell with diarrhoea and abdominal pains lasting one week. These symptoms settled but the joint symptoms have persisted. She works as a chef. She has been managing her symptoms with naproxen 500 mg BD. This reduces the pain severity score from 7/10 to 3/10. Whenever she misses a dose, she has to miss work.

Which of the following is the most appropriate intervention?

- A Prednisolone 30 mg once a day
- B Ciprofloxacin
- C Sulfasalazine
- D Continue naproxen
- E Etanercept

The correct answer is C. This case of postenteric reactive arthritis has evolved into a chronic spondyloarthropathy. Sulfasalazine is a DMARD that will help to control the disease process. Prednisolone is not a long-term treatment due to its side effects. It is effective as a bridging therapy and can be used for short periods alongside the sulfasalazine. Long-term naproxen may cause side effects, especially gastrointestinal, renal and cardiovascular. Ciprofloxacin is not indicated because the gastrointestinal infection has resolved. Etanercept is a biologic medication and classed as a tumour necrosis factor alpha inhibitor. It is a soluble fusion protein that inhibits TNF alpha. It has a role in spondyloarthropathy but would not be used as a first-line intervention. Its use would be reserved for cases where conventional DMARDs have been unsuccessful. ①

### Online supplementary material

Supplementary data are available with the online version of this paper, which can be accessed at <https://www.rcpe.ac.uk/journal>.

## References

- 1 Hannu T, Inman R, Granfors K et al. Reactive arthritis or post-infectious arthritis? *Best Pract Res Clin Rheumatol* 2006; 20: 419–33.
- 2 Colmegna I, Cuchacovich R, Espinoza LR. HLA-B27-associated reactive arthritis: pathogenetic and clinical considerations. *Clin Microbiol Rev* 2004; 17: 348–369.
- 3 Schmitt SK. Reactive arthritis. *Infect Dis Clin North Am* 2017; 31: 265–277.
- 4 Detels R, Green AM, Klausner JD et al. The incidence and correlates of symptomatic and asymptomatic *Chlamydia trachomatis* and *Neisseria gonorrhoeae* infections in selected populations in five countries. *Sex Transm Dis* 2011; 38: 503–9.
- 5 Gasparyan AY, Ayvazyan L, Blackmore H et al. Writing a narrative biomedical review: considerations for authors, peer reviewers, and editors. *Rheumatol Int* 2011; 31: 1409–17.
- 6 Carter JD, Hudson AP. Reactive arthritis: clinical aspects and medical management. *Rheum Dis Clin North Am* 2009; 35: 21–44.
- 7 Ajene AN, Fischer Walker CL, Black RE. Enteric pathogens and reactive arthritis: a systematic review of *Campylobacter*, *Salmonella* and *Shigella*-associated reactive arthritis. *J Health Popul Nutr* 2013; 31: 299–307.
- 8 Mason E, Wray L, Foster R et al. Reactive arthritis at the Sydney Sexual Health Centre 1992–2012: declining despite increasing *Chlamydia* diagnoses. *Int J STD AIDS* 2016; 27: 882–9.
- 9 Stavropoulos PG, Soua E, Kanelleas A et al. Reactive arthritis. *J Eur Acad Dermatol Venereol* 2015; 29: 415–24.
- 10 Selmi C, Gershwin ME. Diagnosis and classification of reactive arthritis. *Autoimmun Rev* 2014; 13: 546–9.
- 11 Rueda JC, Crepy MF, Mantilla RD. Clinical features of Poncet's disease. From the description of 198 cases found in the literature. *Clin Rheumatol* 2013; 32: 929–35.
- 12 Bernini L, Manzini CU, Giuggioli D et al. Reactive arthritis induced by intravesical BCG therapy for bladder cancer: our clinical experience and systematic review of the literature. *Autoimmun Rev* 2013; 12: 1150–9.



- 13 Taniguchi Y, Nishikawa H, Yoshida T et al. Expanding the spectrum of reactive arthritis (ReA): classic ReA and infection-related arthritis including poststreptococcal ReA, Poncet's disease, and iBCG-induced ReA. *Rheumatol Int* 2021 May 1: 1–12.
- 14 Adizie T, Moots RJ, Hodkinson B et al. Inflammatory arthritis in HIV positive patients: a practical guide. *BMC Infect Dis* 2016; 16: 100.
- 15 López-González M, Peral-Garrido ML, Calabuig I et al. Case series of acute arthritis during COVID-19 admission. *Ann Rheum Dis* published online first: 29 May 2020.
- 16 Waller R, Price E, Carty S et al. EP01. Post COVID-19 reactive arthritis. *Rheumatol Adv Pract* 42020: rkaa052.
- 17 Sidhu A, Selvan S, Alkutobi Z. EP02. A rare case of reactive arthritis secondary to COVID-19. *Rheumatol Adv Pract* 2020: rkaa052.001.
- 18 Schenker HM, Hagen M, Simon D et al. Reactive arthritis and cutaneous vasculitis after SARS-CoV-2 infection. *Rheumatology (Oxford)* 2021; 60: 479–480.
- 19 Danssaert Z, Raum G, Hemtasilpa S. Reactive arthritis in a 37-year-old female with SARS-CoV2 Infection. *Cureus* 2020; 12: e9698.
- 20 Houshmand H, Abounoori M, Ghaemi R et al. Ten-year-old boy with atypical COVID-19 symptom presentation. *Authorea* 2020.
- 21 Werner SG, Langer HE. The first case of reactive arthritis associated with SARS-CoV-2-infection in a 4-year-old child. *Am J Clin Case Rep* 2020; 1: 1019.
- 22 Saricaoglu EM, Hasanoglu I, Guner R. The first reactive arthritis case associated with COVID-19. *J Med Virol* 2020: 10.1002/jmv.26296.
- 23 Liew IY, Mak TM, Cui L, et al. A case of reactive arthritis secondary to coronavirus disease 2019 infection. *J Clin Rheumatol* 2020; 26: 233.
- 24 Ono K, Kishimoto M, Shimasaki T, et al. Reactive arthritis after COVID-19 infection. *RMD Open* 2020; 6: e001350.
- 25 Salvatierra J, Martínez-Peñalver D, Salvatierra-Velasco L. COVID-19 related dactylitis. *Joint Bone Spine* 2020; 87: 660.
- 26 De Stefano L, Rossi S, Montecucco C et al. Transient monoarthritis and psoriatic skin lesions following COVID-19. *Ann Rheum Dis* 2020 Aug 4: annrheumdis-2020–218520.
- 27 Hønge BL, Hermansen MF, Storgaard M. Reactive arthritis after COVID-19. *BMJ Case Rep* 2021; 14: e241375.
- 28 Gasparotto M, Framba V, Piovella C et al. Post-COVID-19 arthritis: a case report and literature review. *Clin Rheumatol* 2021; 1–6.
- 29 Sureja NP, Nandamuri D. Reactive arthritis after SARS-CoV-2 infection. *Rheumatol Adv Pract* 2021; 5: rka001.
- 30 Parisi S, Borrelli R, Bianchi S et al. Viral arthritis and COVID-19. *Lancet Rheumatol* 2020; 2: e655–e657.
- 31 Yokogawa N, Minematsu N, Katano H et al. Case of acute arthritis following SARS-CoV-2 infection. *Ann Rheum Dis* 2020 Jun 26: annrheumdis-2020–218281.
- 32 Collantes E, Zarco P, Muñoz E et al. Disease pattern of spondyloarthropathies in Spain: description of the first national registry (REGISPONSER) extended report. *Rheumatology (Oxford)* 2007; 46: 1309–15.
- 33 Leirisalo-Repo M, Sieper J. Reactive arthritis: epidemiology, clinical features, and treatment. In: Weisman M, van der Heijde D, Reveille J (eds). *Ankylosing Spondylitis and the Spondyloarthropathies*. Philadelphia: Mosby Elsevier; 2006. p.53–64.
- 34 Kim PS, Klausmeier TL, Orr DR. Reactive arthritis: a review. *J Adolesc Health* 2009; 44: 309–15.
- 35 Hamdulay SS, Glynne SJ, Keat A. When is arthritis reactive? *Postgrad Med J* 2006; 82: 446–53.
- 36 Kuipers JG, Köhler L, Zeidler H. Reactive or infectious arthritis. *Ann Rheum Dis* 1999; 58: 661–4.
- 37 Gracey E, Inman R. Chlamydia-induced ReA: immune imbalances and persistent pathogens. *Nat Rev Rheumatol* 2012; 8: 55–59.
- 38 Zeidler H, Hudson AP. New insights into *Chlamydia* and arthritis. Promise of a cure? *Ann Rheum Dis* 2014; 73: 637–644.
- 39 Sibilija J, Limbach FX. Reactive arthritis or chronic infectious arthritis? *Ann Rheum Dis* 2002; 61: 580–7.
- 40 Kirveskari J, He Q, Holmström T et al. Modulation of peripheral blood mononuclear cell activation status during *Salmonella*-triggered reactive arthritis. *Arthritis Rheum* 1999; 42: 2045–2054.
- 41 Sieper J. Disease mechanisms in reactive arthritis. *Curr Rheumatol Rep* 2004; 6: 110–6.
- 42 Kohm AP, Fuller KG, Miller SD. Mimicking the way to autoimmunity: an evolving theory of sequence and structural homology. *Trends in Microbiology* 2003; 11: 101–105.
- 43 Colbert RA, Tran TM, Layh-Schmitt G. HLA-B27 misfolding and ankylosing spondylitis. *Mol Immunol* 2014; 57: 44–51.
- 44 Bas S, Kvien TK, Buchs N et al. Lower level of synovial fluid interferon-gamma in HLA-B27-positive than in HLA-B27-negative patients with *Chlamydia trachomatis* reactive arthritis. *Rheumatology (Oxford)* 2003; 42: 461–7.
- 45 Gill T, Asquith M, Rosenbaum JT et al. The intestinal microbiome in spondyloarthritis. *Curr Opin Rheumatol* 2015; 27: 319–25.
- 46 Manasson J, Shen N, Garcia Ferrer HR et al. Gut microbiota perturbations in reactive arthritis and postinfectious spondyloarthritis. *Arthritis Rheumatol* 2018; 70: 242–254.
- 47 Eliçabe RJ, Di Genaro MS. Immunopathogenesis of reactive arthritis: role of the cytokines. *World J Immunol* 2014; 4: 78–87.
- 48 Hannu T. Reactive arthritis. *Best Pract Res Clin Rheumatol* 2011; 25: 347–57.
- 49 Keat A. Reiter's syndrome and reactive arthritis in perspective. *N Engl J Med* 1983; 309: 1606–15.
- 50 Leirisalo M, Skylv G, Kousa M et al. Followup study on patients with Reiter's disease and reactive arthritis, with special reference to HLA-B27. *Arthritis Rheum* 1982; 25: 249–59.
- 51 van der Heijde D, Landewé R. Imaging in spondylitis. *Curr Opin Rheumatol* 2005; 17: 413–7.
- 52 Braun J, Kingsley G, van der Heijde D et al. On the difficulties of establishing a consensus on the definition of and diagnostic investigations for reactive arthritis. Results and discussion of a questionnaire prepared for the 4th International Workshop on Reactive Arthritis, Berlin, Germany, July 3–6, 1999. *J Rheumatol* 2000; 27: 2185–92.
- 53 Bardin T. Gonococcal arthritis. *Best Pract Res Clin Rheumatol* 2003; 17: 201–8.
- 54 Barash J, Mashiach E, Navon-Elkan P et al. Pediatric Rheumatology study group of Israel. Differentiation of post-streptococcal reactive arthritis from acute rheumatic fever. *J Pediatr* 2008; 153: 696–9.
- 55 Zeichhardt H, Grunert HP. Enteroviruses. In: Armstrong D, Cohen J (eds). *Infectious Disease Textbook*. 1st ed. London: Mosby; 1999. p.8212.
- 56 Woolf AD, Champion GV, Chishick A et al. Clinical manifestations of human parvovirus B19 in adults. *Arch Intern Med* 1989; 149: 1153–1156.
- 57 Hsu HH, Feinstein SM, Houfnagle JH. Acute viral hepatitis. In: Mandell GL, Bennett JE, Dolin R, editors. *Mandell, Douglas, and Bennett's Principles and Practices of Infectious Diseases*. 4th ed. New York: Churchill Livingstone; 1995. p.1100.
- 58 Umakanth M. Dengue complicated with sacroiliitis in a pregnant woman. *Int J Health Sci Res* 2018; 8: 373–376.
- 59 Jayamali WD, Herath HMMTB, Kulatunga A. A young female presenting with unilateral sacroiliitis following dengue virus infection: a case report. *J Med Case Rep* 2017; 11: 307.
- 60 Caglioti C, Lalle E, Castilletti C et al. Chikungunya virus infection: an overview. *New Microbiol* 2013; 36: 211–27.
- 61 Runowska M, Majewski D, Niklas K et al. Chikungunya virus: a rheumatologist's perspective. *Clin Exp Rheumatol* 2018; 36: 494–501.

- 62 NICE. Gastro-intestinal system infections, antibacterial therapy. 2021. <https://bnf.nice.org.uk/treatment-summary/gastro-intestinal-system-infections-antibacterial-therapy.html> (accessed 22/02/2021).
- 63 Carter JD, Espinoza LR, Inman RD et al. Combination antibiotics as a treatment for chronic *Chlamydia*-induced reactive arthritis: a double-blind, placebo-controlled, prospective trial. *Arthritis Rheum* 2010; 62: 1298–1307.
- 64 Lauhio A, Leirisalo-Repo M, Lähdevirta J et al. Double-blind, placebo-controlled study of three-month treatment with lymecycline in reactive arthritis, with special reference to *Chlamydia* arthritis. *Arthritis Rheum* 1991; 34: 6–14.
- 65 Kvien TK, Gaston JS, Bardin T et al. Three-month treatment of reactive arthritis with azithromycin: a EULAR double blind, placebo-controlled study. *Ann Rheum Dis* 2004; 63: 1113–1119.
- 66 Clegg DO, Reda DJ, Weisman MH et al. Comparison of sulfasalazine and placebo in the treatment of reactive arthritis (Reiter's syndrome). A Department of Veterans Affairs Cooperative Study. *Arthritis Rheum* 1996; 39: 2021–2027.
- 67 Flagg SD, Meador R, Hsia E et al. Decreased pain and synovial inflammation after etanercept therapy in patients with reactive and undifferentiated arthritis: an open-label trial. *Arthritis Rheum* 2005; 53: 613–617.
- 68 Carlin EM, Ziza JM, Keat A et al. 2014 European Guideline on the management of sexually acquired reactive arthritis. *Int J STD AIDS* 2014; 25: 901–912.
- 69 Leirisalo-Repo M. Prognosis, course of disease, and treatment of the spondyloarthropathies. *Rheum Dis Clin North Am* 1998; 24: 737–8.
- 70 Leirisalo-Repo M, Suoranta H. Ten-year follow-up study of patients with *Yersinia* arthritis. *Arthritis Rheum* 1988; 31: 533–537.