

Cervical herpes zoster: an unusual cause of headache

Lauren Fratalia¹, Andrew J Larner¹

Keywords: herpes zoster, C2 root, headache, classification

Informed Consent: Written informed consent for the paper to be published (including images, case history and data) was obtained from the patient for publication of this paper, including accompanying images.

Financial and Competing Interests: No conflict of interests declared

Correspondence to:

AJ Larner
Walton Centre for Neurology
and Neurosurgery
Lower Lane
Liverpool L9 7LJ
UK

Email:

a.larner@thewaltoncentre.
nhs.uk

Introduction

Neurological syndromes associated with varicella zoster virus (VZV) infection may occur with the primary (chickenpox) infection (e.g. encephalitis) or, more commonly, with reactivation of latent infection in sensory ganglia neurones (shingles).^{1,2} Herpes zoster reactivation is more likely to occur in any condition predisposing to decreased cell-mediated immunity (e.g. cancer, immunosuppressive drug treatment, AIDS) and usually manifests as a painful vesicular rash in a unilateral dermatomal distribution, most often affecting truncal dermatomes. Involvement of cranial nerves, especially trigeminal and nervus intermedius,³ may prompt clinical presentation to headache specialists. Involvement of cervical spinal roots by VZV, as shown in the following case, is less commonly described.

A 58-year-old woman developed severe holocranial pulsatile headache radiating to the neck. This was followed after a few days by sharp stabbing pains affecting the right hemicranium, lasting up to five seconds and recurring every 15 seconds or so. The pain mostly affected the right jaw and ear with some radiation to the top of the head. There were no autonomic symptoms, and no triggers such as tactile stimuli. The patient was otherwise in good health, with no prior history of headache or immunocompromise.

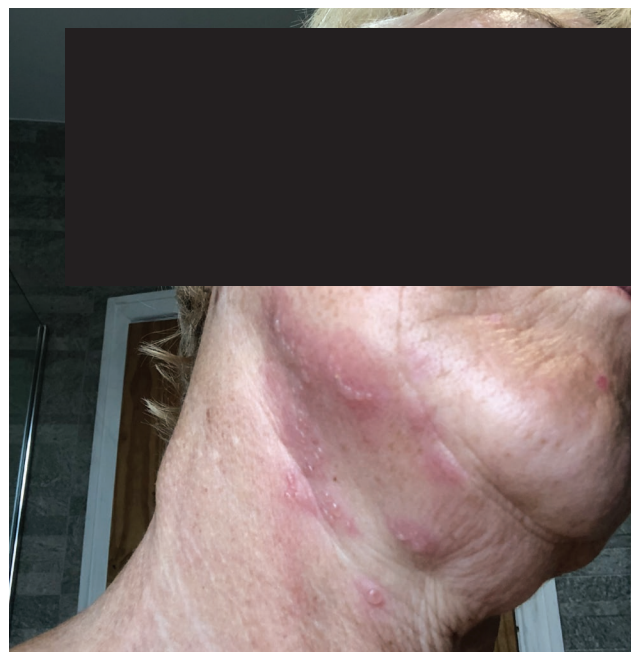About one week later, a painful vesicular rash, typical of varicella zoster, developed, conforming to the distribution of the right C2 dermatome, specifically the pinna, back of the head, and under the jaw line (Figure 1). The patient had a history of chickenpox at eight years of age.

A diagnosis of shingles affecting the right C2 root, or herpes zoster occipitocollaris, was made. VZV antibody (IgM) was

not sent because the patient was not seen acutely and, moreover, the vesicles made the diagnosis clear. Magnetic resonance imaging of the brain was normal. The patient was given a course of oral aciclovir and the rash settled after 2–3 weeks. Her neuropathic stabbing pains were treated with gabapentin and amitriptyline. Eighteen months later she still had occasional right C2 neuralgic pain occurring in clusters, but less severe than at presentation.

This case raises a number of interesting issues. Firstly, it provides a nice clinic-anatomical correlation illustrating

Figure 1 Submental vesicular rash in distribution of right C2 dermatome




¹Consultant Neurologist, Walton Centre for Neurology and Neurosurgery, Liverpool, UK

the neuroanatomy of the C2 nerve root. Generally, C2 root lesions are covered only briefly, if at all, in most neurology textbooks. VZV in the C2 distribution, sometimes known as herpes zoster occipitocollaris, is rarely reported, usually as single cases,^{4,5} although multidermatomal zoster including involvement of cervical dermatomes has also been presented on occasion.⁶

Secondly, perhaps as a consequence of this rarity, C2 herpes zoster is not specifically recognised in the current International Classification of Headache Disorders (ICHD-3), unlike painful trigeminal neuropathy and painful nervus intermedius neuropathy attributed to herpes zoster (sections 13.1.2.1 and 13.3.2.1, respectively).⁷ The ICHD-3 Appendix has a section on 'headache attributed to upper cervical radiculopathy' (A11.2.4). This requires clinical, electrodiagnostic or radiological evidence of C2 (or C3) radiculopathy (criterion B) and evidence of causation (criterion C) demonstrated by both headache ipsilateral to the radiculopathy and at least two of three other factors (viz.: pain developed in temporal relation to onset of radiculopathy, or led to its discovery; pain has significantly improved or significantly worsened in parallel with improvement in or worsening of the radiculopathy; pain is temporarily abolished by local anaesthesia of the relevant nerve root), and symptoms not better accounted for by another ICHD-3 diagnosis (criterion D).⁷ Our patient fulfils these criteria, with clinical evidence of C2 involvement, pain developing in temporal relation to the onset of radiculopathy, and significant improvement in pain in parallel with improvement in the radicular involvement. The ICHD-3 definition makes no comment regarding the pathogenesis of C2 radiculopathy.

Thirdly, as is evident from the current case, the pre-eruptive pain of C2 shingles may be mistaken for other causes of headache, such as primary stabbing headache or possibly trigeminal neuralgia. Although post-herpetic neuralgia is a well-recognised complication of herpes zoster infection, pre-herpetic or pre-eruption pain has attracted less attention. It is known that severe neuralgic pain due to VZV may occur several days before the development of skin lesions,² as in this case. Pain may sometimes occur without a rash developing, as in the phenomenon of zoster sine herpette (ZSH) or occult herpetic infection, such that it has been recommended that clinicians suspect ZSH in any patient with persistent unexplained radicular pain.¹

Fourthly, the pathogenesis of headache pain in this case is of interest. The pain associated with migraine is thought to be the consequence of activation of the trigeminovascular system. The nociceptive innervation of the intracranial vasculature and meninges is through branches of the trigeminal nerve, mainly the ophthalmic (V1) division, but there is also innervation of the dura mater from the cervical dorsal root ganglia. All nociceptive information from craniovascular structures is relayed through the trigeminocervical complex (TCC), comprising neurones in the trigeminal nucleus caudalis and the C1 and C2 regions of the cervical spinal cord.⁸ We would therefore suggest that VZV reactivation causing herpes zoster occipitocollaris might activate the TCC via C2 inputs, producing the holocranial and then hemicranial pain experienced by our patient.

In summary, involvement of the C2 root in VZV reactivation, herpes zoster occipitocollaris, may present as a headache syndrome. This is currently a lacuna in ICHD-3. 

References

- 1 Kennedy PGE, Gershon AA. Clinical features of varicella-zoster virus infection. *Viruses* 2018; 10: 609.
- 2 Schmader K. Herpes zoster. *Ann Intern Med* 2018; 169: ITC19-31.
- 3 Tsau PW, Liao MF, Hsu JL et al. Clinical presentations and outcome studies of cranial nerve involvement in herpes zoster infection: a retrospective single-center analysis. *J Clin Med* 2020; 9: 946.
- 4 Oliveira E, Alexandre J. A 27-year-old woman with painful vesicular lesions. *Int J Infect Dis* 2013; 17: e213-e214.
- 5 Mounsey SJ. Two types of varicella zoster in one patient. *BMJ Case Rep* 2017; 2017: bcr2017221669.
- 6 Beuerlein KG, Strowd LC. Multidermatomal herpes zoster: a pain in the neck? *Dermatol Online J* 2019; 25: 13030/qt9kz407dx.
- 7 The International Headache Society. *The International Classification of Headache Disorders* (3rd edition); 2018.
- 8 Goadsby PJ, Holland PR, Martins-Oliveira M et al. Pathophysiology of migraine: a disorder of sensory processing. *Physiol Rev* 2017; 97: 553-622.