



Acta Scientiarum. Health Sciences
ISSN: 1679-9291
eduem@uem.br
Universidade Estadual de Maringá
Brasil

de Andrade Lima, Saulo André; de Oliveira, Amílcar Viana; Silveira Gonçalves Lima, Luciana;
Paranhos, Luiz Renato; Pilli Jóias, Renata; Furquim Siqueira, Danilo
Characteristics of regional odontodysplasia: A case report
Acta Scientiarum. Health Sciences, vol. 34, núm. 2, julio-diciembre, 2012, pp. 215-219
Universidade Estadual de Maringá
Maringá, Brasil

Available in: <http://www.redalyc.org/articulo.oa?id=307226631014>

- How to cite
- Complete issue
- More information about this article
- Journal's homepage in redalyc.org

redalyc.org

Scientific Information System
Network of Scientific Journals from Latin America, the Caribbean, Spain and Portugal
Non-profit academic project, developed under the open access initiative



Characteristics of regional odontodysplasia: A case report

Saulo André de Andrade Lima¹, Amílcar Viana de Oliveira¹, Luciana Silveira Gonçalves Lima², Luiz Renato Paranhos^{3*}, Renata Pilli Jóias⁴ and Danilo Furquim Siqueira⁵

¹Curso de Odontologia, Universidade Ceuma, São Luís, Maranhão, Brazil. ²Programa de Pós-graduação em Ortodontia, Universidade Cidade de São Paulo, São Paulo, São Paulo, Brazil. ³Programa de Pós-graduação em Biologia Oral, Universidade Sagrado Coração, Rua Irmã Armanda, 10-50, 17011-160, Bauru, São Paulo, Brazil. ⁴Clinica Particular, São Bernardo do Campo, São Paulo, Brazil. ⁵Programa de Pós-graduação em Odontologia, Universidade Sagrado Coração, Bauru, São Paulo, Brazil. *Author for correspondence. E-mail: paranhos@ortodontista.com.br

ABSTRACT. Regional odontodysplasia is an uncommon, nonhereditary developmental dental disorder of unknown etiology, which should be early detected. This paper compares a regional odontodysplasia case with the clinical and radiographic characteristics reported in the literature, showing a 1y6m follow up and the limitations of performing a multidisciplinary esthetic and functional treatment.

Keywords: diagnosis, maxillofacial abnormalities.

Características da odontodisplasia regional: relato de um caso clínico

RESUMO. A odontodisplasia regional é uma anomalia de desenvolvimento dental de etiologia desconhecida, que apesar de pouco frequente na população, deve ser detectada o quanto antes. Assim, o presente estudo teve por objetivo comparar um caso clínico de odontodisplasia regional com as características clínicas e radiográficas relatadas na literatura, mostrando o acompanhamento de um caso por 1a6m e as limitações da realização de um tratamento multidisciplinar visando estética e função.

Palavras-chave: diagnóstico, anomalias maxilofaciais.

Introduction

The regional odontodysplasia, first reported in 1947, is a nonhereditary and rare dental developmental anomaly of unknown etiology (PORTELA; GONÇALVES, 1988; ROSA et al., 2006; SANNOMIYA et al., 2002). In this anomaly, the dental tissues derived from mesoderm (dentin, pulp, cement) and ectoderm (enamel) show alterations (PORTELA; GONÇALVES, 1988; ROSA et al., 2006; SANNOMIYA et al., 2002).

Both dentitions could be affected by the regional odontodysplasia (REDMAN et al., 1979) and it is more frequently found in maxilla than in mandible (PORTELA; GONÇALVES, 1988), and on the anterior teeth (PANDIS et al., 1991; ZEGARELLI et al., 1963). This anomaly is more common in women (CHO, 2006; ROSA et al., 2006; SANNOMIYA et al., 2002), but its incidence does not tend to be higher in any ethnic group (NICODEMO et al., 1990; VOLPATO et al., 2008).

In general, the regional odontodysplasia treatment imposes esthetic and functional limitations and it should be preferred a conservative dentistry management always as possible. There are some cases in which the extraction of the damaged teeth, irrupted or not, and prosthodontic rehabilitation is required, in

other ones, an endodontic treatment is indispensable (LUSTMANN; ULMANSKY, 1976; PANDIS et al., 1991; PORTELA; GONÇALVES, 1988; ROSA et al., 2006; SANNOMIYA et al., 2002; VOLPATO et al., 2008).

This case report aimed to compare the characteristics of a regional odontodysplasia case with the clinical, radiographic and histological aspects found in the literature.

Material and methods

Case report

A female patient, aged 5 years 8 months, come to a private dental office for orthodontic treatment. The parents signed an informed consent form, agreeing to the use of her records for study and research purposes.

On physical examination, the patient presented a healthy appearance, harmonious face, convex profile, and passive lip sealing. Intraoral examination and analysis of dental casts revealed absence of the mandibular right deciduous central incisor, all maxillary teeth on the left side, and atrophy of the alveolar bone at the sites of anodontia (Figure 1).

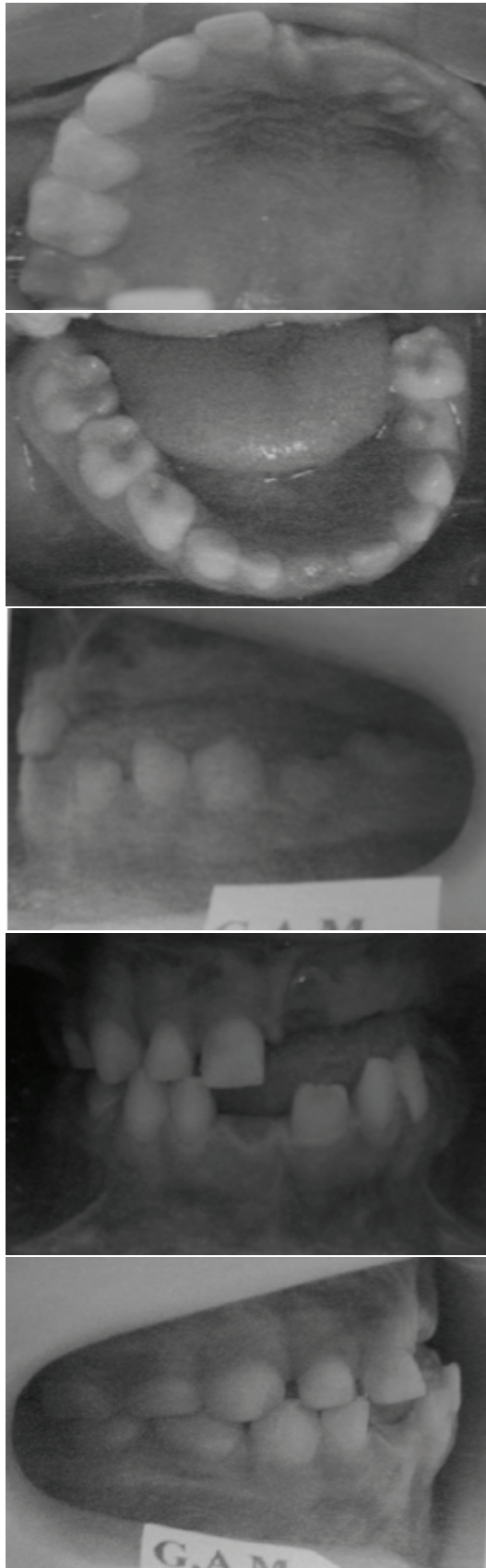


Figure 1. Intraoral photographs of patient with regional odontodysplasia.

Evaluation of the panoramic radiograph (Figure 2) included in the orthodontic records revealed the presence of a permanent mandibular right central incisor and some low-density images of enamel and dentin, similar to “ghost teeth”. The latter, characteristic of regional odontodysplasia, were observed in the region from the permanent right central incisor to the deciduous left second molar/left second bicuspid, yet without a homogeneous aspect.

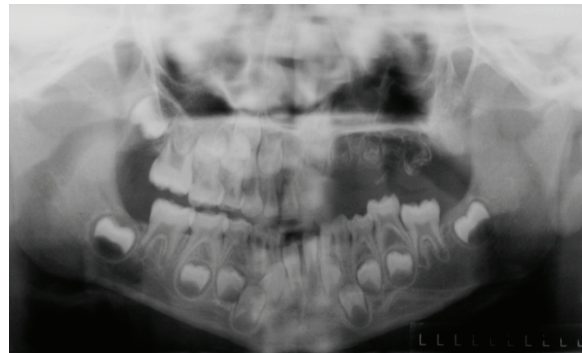

Figure 2. Panoramic radiograph of patient with regional odontodysplasia.

The patient returned to the office at age 7 years 2 months. Supplementary records were requested for follow-up, including full-mouth periapical radiographs and cone-beam computed tomography (CT) (Figures 3 and 4).

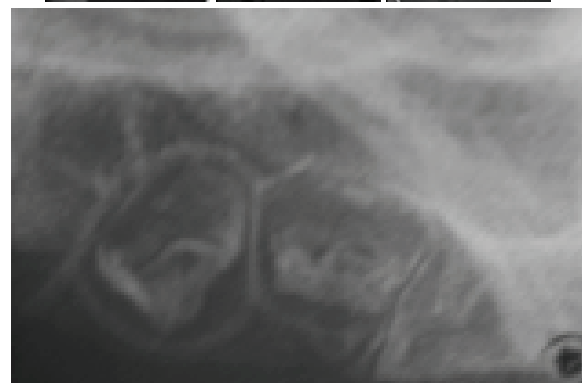
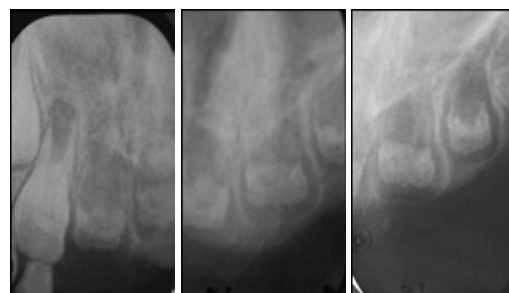


Figure 3. Periapical radiographs of patient with regional odontodysplasia.

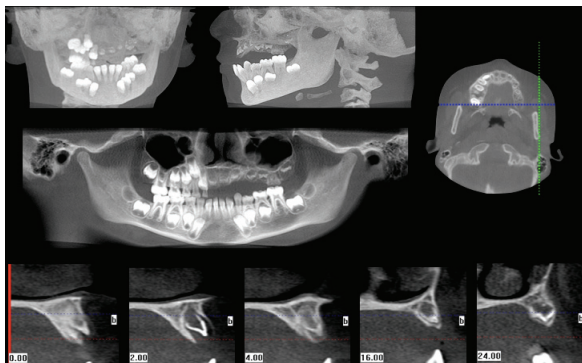


Figure 4. Computed tomography of patient with regional odontodysplasia.

Results and discussion

Both the periapical radiographs and CT sections confirmed the absence of intact tooth buds in the right side of the maxilla, as previously reported, confirming the diagnosis of regional odontodysplasia.

Panoramic radiographs of the patient’s father (Figure 5) and mother (Figure 6) did not show this disorder. The patient treatment consisted of a placement of a removable appliance with an expansion screw at the midpalatal suture and plastic teeth placed in the edentulous region to establish esthetics and function.

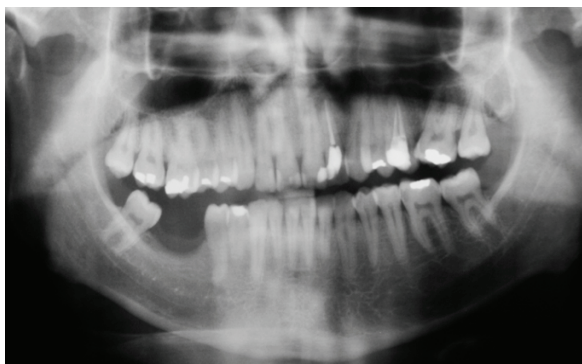

Figure 5. Panoramic radiograph of the father of the affected patient with regional odontodysplasia.

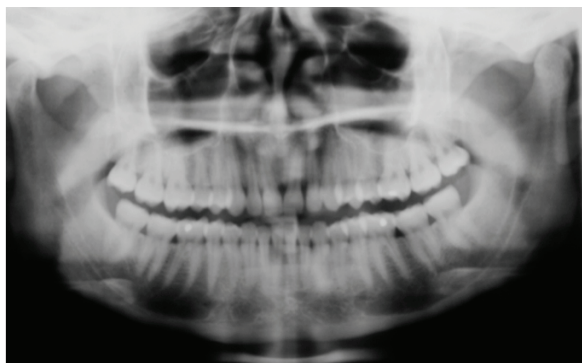


Figure 6. Panoramic radiograph of the mother of the affected patient with regional odontodysplasia.

Regional odontodysplasia, a developmental dental disorder of unknown etiology, affects the ectodermal (enamel) and mesodermal (dentin, pulp, and cementum) tissues (PORTELA; GONÇALVES, 1988; ROSA et al., 2006; SANNOMIYA et al., 2002). The term, “regional odontodysplasia,” is the most widely employed, yet other terms, such as odontogenesis imperfecta, odontogenic dysplasia, nonhereditary amelogenesis imperfecta, and ghost teeth are also found in the literature (REDMAN et al., 1979; ZEGARELLI et al., 1963).

It was not possible to identify the etiology of this anomaly in the present case. The literature mentions several hypotheses for the etiology of regional odontodysplasia such as trauma, local ischemia, viral infection, vascular defect, irradiation, vitamin deficiency, metabolic and nutritional disorders, Rh incompatibility, local somatic mutation, hyperpyrexia, manifestation of latent virus in the odontogenic epithelium during dental development, genetic mutation of odontoblasts, premature degeneration of the enamel organ, and idiopathic factors (ALEVA et al., 1996; NEUPERT; WRIGHT, 1989; REZENDE et al., 1998; VOLPATO et al., 2008). Ectodermal dysplasia, vascular nevus, and hydrocephaly can occur concomitantly with regional odontodysplasia (ALEVA et al., 1996).

The literature does not list the heredity among the several possible etiologies of regional odontodysplasia (CHO, 2006). In the present case, the panoramic radiographs of the parents allowed ruling out the possibility of familial history. Neither were cases of this anomaly perceived in other relatives.

Due to the early diagnosis, the affected teeth had not erupted yet, and so it was not possible to clinically observe any teeth with severe enamel and dentin hypoplasia (CHO, 2006) or alterations described by other authors (CHO, 2006; ROSA et al., 2006; VOLPATO et al., 2008), such as yellowish or brownish enamel.

Diagnosis is mainly radiographic (CHO, 2006) as in the present case, in which the affected teeth were still unerupted. The radiographs revealed the altered aspects of the teeth: reduced radiopacity of enamel and dentin. These tissues exhibited thin layers, with a less evident contour of the tooth structures, explaining the use of the term ‘ghost teeth’ to describe the disorder. For teeth in more advanced stages of development, the literature describes short roots with wide pulp chambers and open apices (PORTELA; GONÇALVES, 1988; REZENDE et al., 1998; VOLPATO et al., 2008),

possibly with dystrophic pulp calcification (PORTELA; GONÇALVES, 1988; REZENDE et al., 1998). A CT was requested in an attempt to complement the diagnosis; however, no additional information was obtained inasmuch as the CT showed the same images observed on the panoramic and periapical radiographs. Thus, considering that CT generates panoramic images of specific areas, when a CT is requested, panoramic and periapicals are not necessary and vice versa.

Even though the diagnosis of regional odontodysplasia is mainly radiographic, the literature reports that histological analysis-not feasible in all cases-could complement it (CHO, 2006) (NEUPERT; WRIGHT, 1989; NICODEMO et al., 1990; REZENDE et al., 1998; VOLPATO et al., 2008). Since it was possible to remove a piece of the diseased tissue for histopathological examination, we observed thin areas of hypocalcified enamel with irregularly arranged enamel prisms (CHO, 2006; NICODEMO et al., 1990; REZENDE et al., 1998; VOLPATO et al., 2008).

According to previous studies, this anomaly is more frequent in the maxilla (ALEVA et al., 1996) and among females (LUSTMANN; ULMANSKY, 1976; PANDIS et al., 1991; ROSA et al., 2006) and it can affect only one tooth (SHADESHI; ASHRAFI, 1981), a group of teeth (ALEVA et al., 1996; SHADESHI; ASHRAFI, 1981) or all teeth (ALEVA et al., 1996; SHADESHI; ASHRAFI, 1981). In agreement with the literature, the patient evidenced regional odontodysplasia in the maxilla, the most common bone to be affected. However, although there are more reports of this disorder in anterior teeth (CHO, 2006; NEUPERT; WRIGHT, 1989; NICODEMO et al., 1990; REZENDE et al., 1998; VOLPATO et al., 2008), our patient exhibited the dysplasia in both her anterior and posterior teeth.

As in other disorders, patients with regional odontodysplasia are more susceptible to dental caries and fractures (REZENDE et al., 1998; ROSA et al., 2006). This anomaly is differentiated from amelogenesis imperfecta and dentinogenesis imperfecta because it appears unilaterally (PANDIS et al., 1991) and is not generalized.

In general, the treatment of regional odontodysplasia has esthetic and functional limitations. More conservative approaches in the field of restorative dentistry should be selected whenever possible. Another option is the extraction of the affected teeth, either erupted or unerupted, followed by prosthetic rehabilitation. Endodontic treatment may also be necessary (NEUPERT;

WRIGHT, 1989; NICODEMO et al., 1990; REZENDE et al., 1998; VOLPATO et al., 2008).

Conclusion

The patient is still in a period of craniofacial growth and development, and then no irreversible treatment such as extractions was performed. Her craniofacial and occlusal development was followed with an effort to maintain the intraosseous teeth buds so that alveolar bone height and width can be preserved as much as possible. The removable expansion appliance was placed to improve the esthetics of the edentulous region and enhance the patient's self-esteem while the expansion screw allows for transverse maxillary growth. After completion of growth, treatment should involve a multispecialty team in order to protect and restore tooth structure, maintain or restore the vertical dimension, and reestablish esthetics and function.

References

- ALEVA, N. A.; ROCHA, W. C.; LORANDI, C. S.; YURGELL, L. S. Odontodysplasia regional associada a cisto odontogênico. **Revista Odonto Ciência**, v. 21, n. 21, p. 49-57, 1996.
- CHO, S. Y. Conservative management PF regional odontodysplasia: case report. **Journal of the Canadian Dental Association**, v. 72, n. 8, p. 735-738, 2006.
- LUSTMANN, J.; ULMANSKY, M. Strutral changes in odontodysplasia. **Oral Surgery**, v. 41, n. 2, p. 193-202, 1976.
- NEUPERT, E. A.; WRIGHT, J. M. Regional odontodysplasia presenting as a soft tissue swelling. **Oral Surgery, Oral Medicine, Oral Pathology**, v. 67, n. 2, p. 193-196, 1989.
- NICODEMO, R. A.; MORAES, L. C.; MÉDICI FILHO, E. Odontodysplasia regional - apresentação de um caso. **Revista Paulista de Odontologia**, v. 12, n. 2, p. 39-43, 1990.
- PANDIS, N.; POLIDO, C.; BELL, W. H. Regional odontodysplasia - a case associaed with asymmetric maxillary and mandibular development. **Oral Surgery, Oral Medicine, Oral Pathology**, v. 72, n. 4, p. 492-496, 1991.
- PORTELA, W.; GONÇALVES, B. C. Odontodysplasia regional - relato de um caso e revisão da literatura. **Revista Brasileira de Odontologia**, v. 45, n. 1, p. 40-46, 1988.
- REDMAN, R. S.; COHEN, I. M.; GRE, R. O. Focal odontogenesis of the maxillary second premolars in a child. **Oral Surgery**, v. 47, n. 4, p. 349-353, 1979.
- REZENDE, M. T. L.; PIRES, M. J. M.; ARRUDA, M. Odontodysplasia regional em dentes permanentes. **Revista Brasileira de Odontologia**, v. 46, n. 4, p. 212-214, 1998.
- ROSA, M. C. T.; MARCELINO, G. A.; BELCHIOR, R. S.; SOUZA, A. P. P.; PARIZOTTO, S. C. O. L. Regional odontodysplasia: report of a case. **Journal of Clinical Pediatric Dentistry**, v. 30, n. 4, p. 333-336, 2006.

SANNOMIYA, E. K.; FURUKAWA, S.; ARITA, E. S. Odontodysplasia regional - relato de dois casos clínicos em dentes permanentes. **Revista Brasileira de Odontologia**, v. 6, n. 59, p. 424-426, 2002.

SHADESHI, G. M.; ASHRAFI, M. I. Regional odontodysplasia - Clinical pathologic and therapeutic considerations. **Journal of the American Dental Association**, v. 102, n. 3, p. 336-339, 1981.

VOLPATO, L.; BOTELHO, G.; CASELA, L.; BORGES, A.; SILVA, K. Regional odontodysplasia: report of a case in the mandible crossing the midline. **Journal of Contemporary Dental Practice**, v. 9, n. 3, p. 1-7, 2008.

ZEGARELLI, E.; KUTSCHER, A. H.; APPLEBAULM, E.; ARCHARD, H. O. Odontodysplasia. **Oral Surgery, Oral Medicine, Oral Pathology**, v. 16, n. 2, p. 187-193, 1963.

Received on May 10, 2011.

Accepted on July 21, 2011.

License information: This is an open-access article distributed under the terms of the Creative Commons Attribution License, which permits unrestricted use, distribution, and reproduction in any medium, provided the original work is properly cited.