



## Epulis Fissuratum

Acevedo Ocana R<sup>1</sup>, Amez Descalzo S<sup>1</sup>, Cortes-Breton Brinkmann J<sup>2\*</sup>, Delgado Gregori J<sup>1</sup> and Sanchez Jorge MI<sup>1</sup>

<sup>1</sup>Department of Oral Surgery and Implantology, Alfonso X El Sabio University, Spain

<sup>2</sup>Department of Oral Surgery and Implantology, Hospital Virgen de la Paloma, Spain

### Clinical Image

A female patient aged 78 years attended the clinic pertaining to the Master's Program in Oral Surgery, Implant Dentistry, and Periodontics at the Alfonso X El Sabio University (Madrid, Spain), presenting a tumor over the mandibular alveolar ridge at the midline (Figure 1). The patient did not report any family or personal antecedents of relevance. The development of the tumor appeared to be related to recent rehabilitation with implant retained overdentures retained with locator attachments (Figure 2).

During intraoral exploration, a pedunculated lesion was found of fibrous consistency and whitish color with an ulcerated surface, which the patient found painful during function. It was decided to perform excisional biopsy.

After obtaining informed consent from the patient, local anesthesia was applied with a supraperiosteal and perilesional infiltration technique, excision of the lesion by cold knife cone technique was performed, followed by cauterization with an electric scalpel (Figure 3 and 4). The sample was placed in a 10% formal saline for histopathological analysis.

The anatomopathological report described the entity microscopically as a lesion with densely fibrous paucellular connective stroma around a vascular axis. The polypoid structure showed a covering of non-keratinized mature squamous epithelium. No signs of malignancy were observed. The pathologist's diagnosis was of traumatic (fibroepithelial polyp) fibroma/epulis fissuratum.

The prosthesis was adjusted immediately, loosening the vestibular skirt and shortening the vestibular labial frenum to avoid trauma in the area of the lesion. The patient returned for check-

### OPEN ACCESS

#### \*Correspondence:

Cortes-Breton Brinkmann J,  
Department of Oral Surgery and  
Implantology, Alfonso X El Sabio  
University, Madrid, Spain,  
E-mail: brinkmann55@hotmail.com

Received Date: 23 Nov 2018

Accepted Date: 28 Nov 2018

Published Date: 03 Dec 2018

#### Citation:

Acevedo Ocana R, Amez Descalzo S,  
Cortes-Breton Brinkmann J, Delgado  
Gregori J, Sanchez Jorge MI. Epulis  
Fissuratum. World J Oral Maxillofac  
Surg. 2018; 1(4): 1017.

**Copyright** © 2018 Cortes-Breton  
Brinkmann J. This is an open access  
article distributed under the Creative  
Commons Attribution License, which  
permits unrestricted use, distribution,  
and reproduction in any medium,  
provided the original work is properly  
cited.

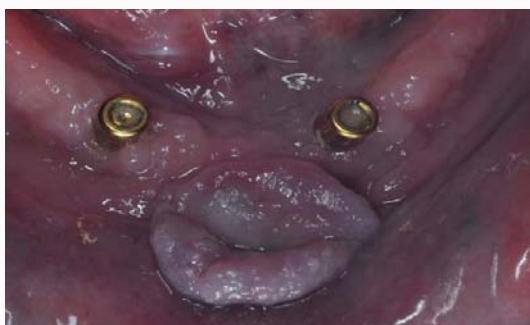

Figure 1:

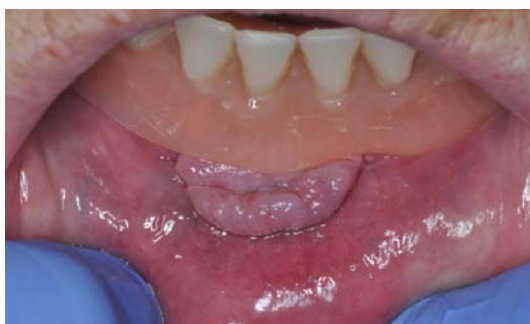

Figure 2:

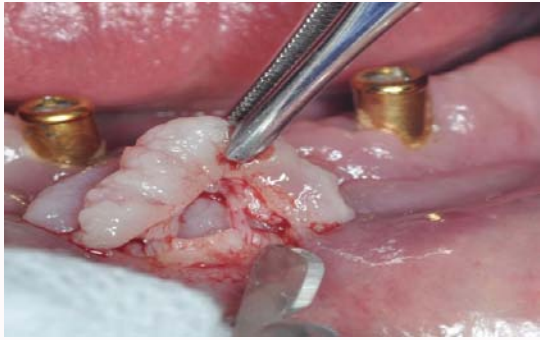


Figure 3:

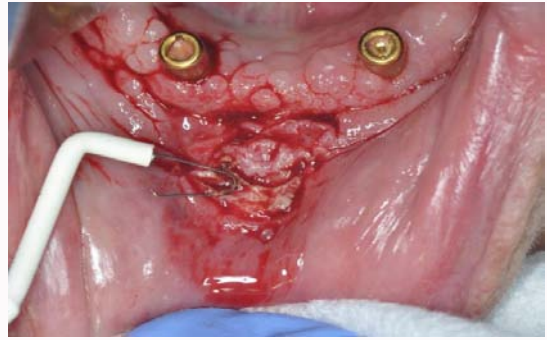


Figure 4:

ups 7 days, 15 days, and 30 days after surgery to monitor healing and the evolution of the wound and thereafter 3 months, 6 months, and 12 months later to check for relapse.