



# Paroxysmal Supraventricular Tachycardia Induced by a Mediastinal Mass in Elderly Patients

Yuewu Zhao and Dongye Li\*

Department of Cardiology, Xuzhou Medical University, China

## Abstract

**Objective:** To summarize the clinical features of paroxysmal supra ventricular tachycardia (PSVT) caused by the formation of a mediastinal mass (MM) to investigate possible mechanisms and to deepen the understanding of the inherent relationship between MM formation and PSVT.

**Methods:** The clinical features of three patients with frequent PSVT episodes after the appearance of MM were summarized and analyzed.

**Results:** None of the three cases had a history of apparent heart disease or PSVT, and all experienced recurrent PSVT after the appearance of MM, which became more frequent with the progression of MM.

**Conclusions:** These findings suggest a causal correlation between PSVT and MM, which should be considered when diagnosing such cases.

**Keywords:** Elderly; Mediastinal mass; Paroxysmal supraventricular tachycardia

## Introduction

In a broad sense, paroxysmal supraventricular tachycardia (PSVT) mainly includes sinoatrial reentry tachycardia (SART), intraatrial reentrant tachycardia (IART), atrioventricular nodal reentrant tachycardia (AVNRT), and atrioventricular reentrant tachycardia (AVRT). Because of the relatively distinct P waves, it is easy to differentiate SART and IART from AVNRT and AVRT. In a more narrow sense, PSVT includes only AVNRT and AVRT[1,2]. The mechanism underlying AVNRT and AVRT is considered to be a circular congenital cardiac pathway in cases not accompanied by organic heart disease [1-4]. We encountered three cases in which the frequency of PSVT increased after the appearance of a mediastinal mass (MM). Here, we report these three cases and discuss possible mechanisms.

## OPEN ACCESS

### \*Correspondence:

Dongye Li, Department of Cardiology,  
Institute of Cardiovascular Disease,  
Xuzhou Medical University, Xuzhou,  
China,

E-mail: dongyeli@medmail.com.cn

Received Date: 09 Oct 2016

Accepted Date: 21 Nov 2016

Published Date: 02 Dec 2016

### Citation:

Zhao Y, Li D. Paroxysmal  
Supraventricular Tachycardia Induced  
by a Mediastinal Mass in Elderly  
Patients. *J Heart Stroke*. 2016; 1(2):  
1009.

**Copyright** © 2016 Dongye Li. This is an open access article distributed under the Creative Commons Attribution License, which permits unrestricted use, distribution, and reproduction in any medium, provided the original work is properly cited.

## Case Presentation

The basic clinical feature and materials of all these patients are presented in (Table 1).

Case 1 was a 72-year-old man who was admitted to the Department of Pneumology on 08 October, 2010, because of repeated episodes of coughing and a 2-year history of asthma, which became aggravated over the span of 2 months before presentation. The patient denied a history of PSVT or other cardiovascular diseases. A physical examination revealed a barrel chest, low breath sounds, heart rate (HR) of 80 beats per minute (bpm), and no murmur or premature beats. Electrocardiography (ECG) on admission showed a sinus rhythm with frequent premature atrial beats. Chest computed tomography (CT) revealed a soft tissue tumor in the left front of the mediastinum, measuring about 9.8×6.0 cm, with an inhomogeneous density. The esophagus and heart were displaced because of compression by the tumor (Figure 1A).

Diagnosis on admission was chronic obstructive pulmonary disease with acute exacerbation and a post-mediastinum tumor with an undetermined etiology. The symptoms of this patient were relieved after treatment with anti-infective agents, which reduced sputum production and relieved the symptoms of asthma. However, on the afternoon of October 23, 2010, the patient experienced palpitations with sudden onset of persistent chest pain. An emergency ECG indicated PSVT with a HR of 174 bpm (Figure 1B). After injection of the antiarrhythmic agent propafenone (50 mg), heartbeat and sinus rhythm recovered suddenly to 90 bpm. Meanwhile, the symptoms disappeared. On November 8, 2010, the patient again experienced sudden palpitations, which was confirmed as an additional episode of PSVT by ECG. Again, propafenone was administered and the heart regained sinus rhythm.

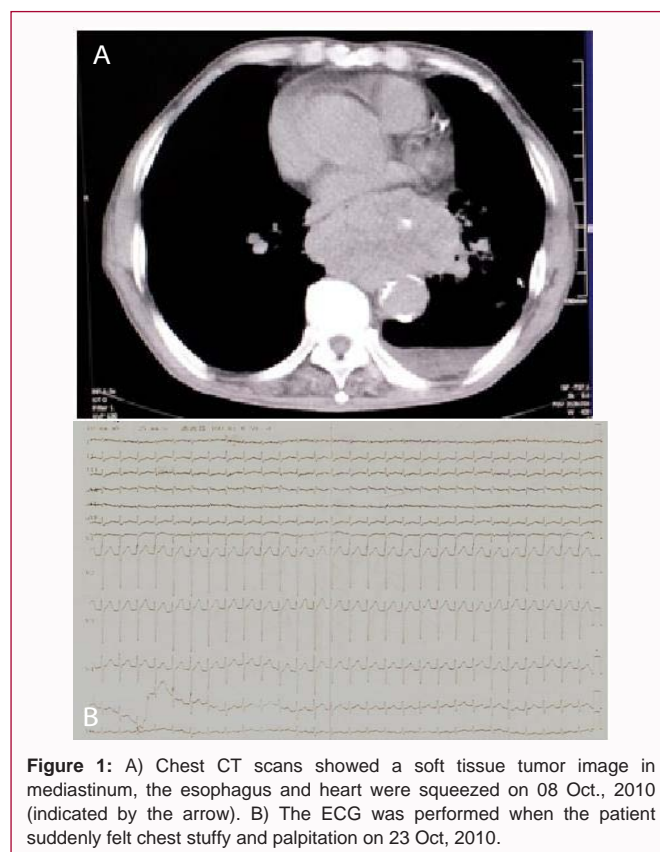
**Table 1:** The basic clinical feature and materials of all these patients.

No.	Sex	Age	Previous History of cardiovascular diseases	Diagnosis	Image Feature of Tumor	ECG During Episode	“PSVT” Duration	React to Propafenone
Case 1	male	72	no	COPD AE; post-mediastinum tumor (the nature undetermined); PSVT	a soft tissue tumor image in left front of the mediastinum, diameter about 11*6.0 cm, There were a displacement of the esophagus and heart because of compression by tumor	PSVT, HR:174 bpm	Initial attack after this admission	positive
Case 2	female	82	no	mediastinum tumor (the nature undetermined); PSVT	a soft tissue tumor at the left front of the mediastinum, diameter about 5.0*7.4cm, which was adjacent to the ascending aorta, pulmonary artery, left atrium	PSVT, HR:165 bpm	1 year	Not used
Case 3	male	70	no	Postoperative cardiaccarcinoma, gastric stump carcinoma. PSVT	Upper gastrointestinal radiography showed postoperative cardiac carcinoma, about 50% of the gastric body was behind of the heart in the chest cavity, adjacent to left atrium and left ventricle	PSVT, HR:188 bpm	more than years	positive

Afterward, PSVT occurred frequently and propafenone tablets (100 mg) were prescribed at three times a day from 29 November, 2010. However, this treatment was not effective and PSVT occurred more frequently. From November 8, 2010 to December 10, 2010, intravenous injection of propafenone for cardioversion was administered 18 times. On November 10, 2010, a chest CT reexamination showed that the mass had grown to 11.0× 6.0 cm. Because of severe body-wasting and disordered cardiac structure, no cardiac electrophysiological examination or radiofrequency ablation was performed. Finally, on December 10, 2010, the patient was discharged against medical advice and died at home.

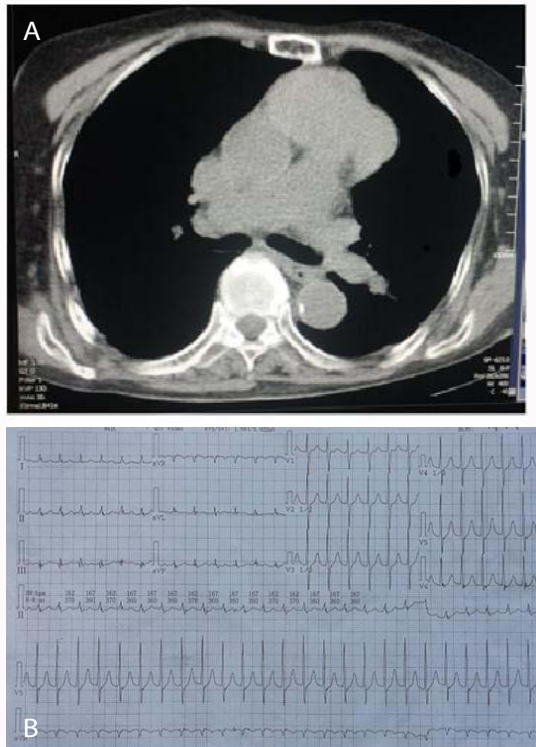
Case 2 was an 82-year-old female with a MM that was observed by CT when she was hospitalized because of gastroenteritis in a local hospital 2 years before, but no special treatment regimen was started on account of her advanced age. A year later, symptoms of paroxysmal palpitation appeared, which were characterized by short attacks that terminated spontaneously. On the night of August 4, 2014, the patient suddenly developed ongoing palpitations. The next morning, ECG was performed which showed uniform supraventricular tachycardia, no P waves, and HR of 165 bpm (Figure 2B). Before a doctor could visit, the palpitations suddenly disappeared. A second ECG showed normal sinus rhythms. She denied a medical history of PSVT or other related diseases.

On August 5, 2014, she was hospitalized for further diagnosis and treatment. A physical examination found no obvious abnormality. However, a chest CT revealed a soft tissue tumor at the left front of the mediastinum, measuring about 5.0 × 7.4 cm, adjacent to the ascending aorta, pulmonary artery, and left atrium with enlarged mediastinal lymph nodes (Figure 2A). Echocardiography showed generally normal atrial and ventricular structure and function. She refused further treatment because of her advanced age, so no cardiac electrophysiological or other medical examinations were performed to clarify the nature of the mass. During hospitalization, metoprolol tablets (12.5 mg) twice daily were prescribed to prevent further tachycardia attacks. She left the hospital on August 8, 2014. Over the next 2 months, tachycardia occurred occasionally and all events spontaneously terminated.

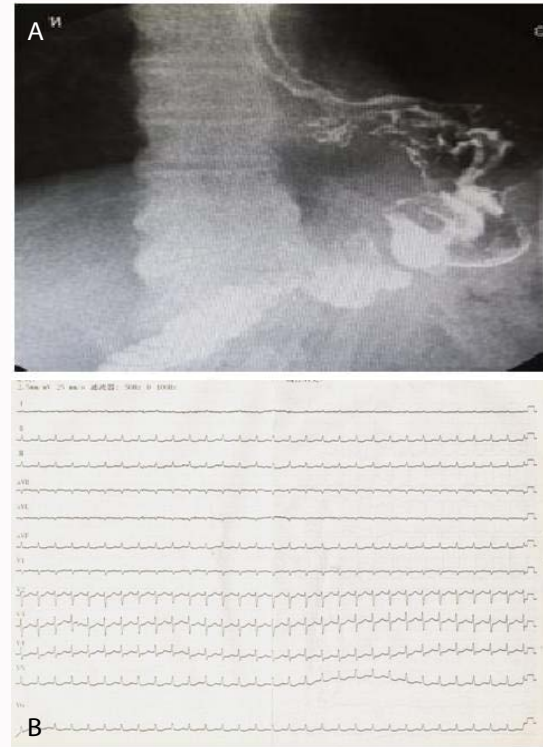


**Figure 1:** A) Chest CT scans showed a soft tissue tumor image in mediastinum, the esophagus and heart were squeezed on 08 Oct., 2010 (indicated by the arrow). B) The ECG was performed when the patient suddenly felt chest stuffy and palpitation on 23 Oct, 2010.

Case 3 was a 70-year-old male with no history of PSVT or other cardiac diseases. He was diagnosed with cancer of the gastric cardia 6 years before that was treated by routine chemotherapy and surgical resection with thoracotomy, for which the gastric body was lifted into the chest. About 1 year after surgery, the patient experienced frequent episodes of paroxysmal palpitation that lasted for minutes to several hours each time. Although symptoms rarely occurred at first, the onset of attacks became more frequent and spontaneously terminated every time. He was hospitalized on July 25, 2013 because of 6-month history of malnutrition and a 1 month history of aggravation of



**Figure 2:** A) CT scans showed a soft tissue mass in the left front of mediastinum, which was adjacent to the ascending aorta and pulmonary artery on 05 Aug, 2014 (indicated by the arrow). B) The ECG was performed when the palpitation attacked on 04 Aug, 2014.



**Figure 3:** A) Gastrointestinal angiography showed the image of postoperative cardiac carcinoma and, 50% of the gastric body was in the chest cavity and behind the heart (indicated by the arrow). B) The ECG was recorded when the patient felt palpitation suddenly on 07 Aug, 2013.

paroxysmal palpitation with abdominal pain.

A physical examination on admission showed that he was emaciated, but there were no other abnormal physical signs. ECG on admission showed a sinus rhythm, HR of 78 bpm, and a premature ventricular beat. Holter monitoring showed 112 instances of premature atrial beats, 336 premature ventricular beats, and three episodes of transient atrial tachycardia. Upper gastrointestinal radiography showed postoperative cardiac carcinoma and about 50% of the gastric body located behind the heart in the chest cavity, adjacent to the left atrium and left ventricle (Figure 3A). An upper abdomen CT showed postoperative cardiac carcinoma with an unclear boundary between the gastric antrum and surrounding tissue, suggesting recurrence of gastric cancer. Echocardiography showed normal atrioventricular structure and function. Diagnosis on admission was postoperative cardiac carcinoma and gastric stump carcinoma. Symptomatic treatment and analgesic agents were administered.

At 09:00 on 07 August, 2013, the patient experienced sudden palpitations again. An emergent ECG verified PSVT with HR of 188 bpm (Figure 3B). After intravenous injection of propafenone, the sinus rhythm was abruptly restored. Afterward, several episodes of PSVT occurred for which the sinus rhythm was maintained by intravenous propafenone. In consideration of the advanced stage of cancer, the patient left the hospital on September 11, 2013 and died at home.

## Discussion

All patients in this study had clinical manifestations of tachycardia that began and ended abruptly, and ECG examinations showed characteristics of PSVT without P waves, so PSVT was an appropriate

diagnosis from a clinical perspective. In this group of patients, all episodes of PSVT occurred after the appearance of MM and PSVT onset became more frequent with the progression of MM, which suggested a relationship between PSVT and MM. However, there exists a contradiction between this phenomenon and the existing theory of an inherent circular pathway.

It is well known that tachycardia relative to reentry activity can be induced so long as a circular pathway is activated by some inducing factors. Such tachycardia include atrial tachycardia, junctional tachycardia (JT), and ventricular tachycardia (VT). According to current viewpoints, atrial tachycardia and VT are mainly induced by organic heart diseases. As an example of VT, a no depolarization zone of myocardial infarction is enclosed by vast ischemic myocardium tissue, which form a new circularelectrocardiological pathway, while the pathological basis of JT is an inherent circular pathway. Now, the issue is if the circular JT pathway can be formed by organic diseases.

JT mainly includes AVNRT and AVRT with a circular pathway located at the atrioventricular junction. Research of the circular pathway has so far failed to identify a separate anatomical basis for such a circular pathway, as none can be explicitly confirmed by electrophysiology and used to effectively guide diagnosis and treatment [5-7]. So, it is speculated that there is no specific histology relative to a circular pathway and the only change is the conduction direction of the bioelectric pathway. In theory, since an acquired organic disease may induce a circular pathway in the atrium and ventricle, it would be equally reasonable for such a pathway to appear at the atrioventricular junction. For example, if the "insulated region" of the atrioventricular junction is damaged, the current passes through the injured parts of atrioventricular node, which slows

conduction. Each of these factors participates in the formation of a circular pathway. Considering the clinical and ECG features of these three cases, this possibility could not be excluded.

Besides some distinct acquired pathological cause, obesity, change in body type, change in chest cavity tension, growth, and development could also produce the same result. In clinical practice, an initial PSVT attack is sometimes encountered in late-term pregnancy [8,9]. To explain such a phenomenon, besides hormonal changes [10], perhaps the main cause is raising of the diaphragm and subsequent heart compression, which promotes subtle structural damage and induces current leakage so as to form a circular pathway. Of course, congenital dysplasia may play an important role in subtle structural damage. Unfortunately, cardiac electrophysiological examinations were not performed for all three cases to further confirm the type of PSVT. Nonetheless, based on clinical observations, the phenomenon of acquired anatomic abnormalities may have promoted PSVT in these patients.

## References

1. Salerno JC, Seslar SP. Supraventricular tachycardia. *Arch Pediatr Adolesc Med.* 2009; 163: 268-274.
2. Jihong Guo. Sinoatrial reentrant tachycardia. *Chinese Journal of Cardiac Pacing and Electrophysiology.* 1999; 13: 240-244.
3. Page RL, Joglar JA, Caldwell MA, Calkins H, Conti JB, Deal BJ, et al. 2015 ACC/AHA/HRS Guideline for the Management of Adult Patients With Supraventricular Tachycardia: A Report of the American College of Cardiology/American Heart Association Task Force on Clinical Practice Guidelines and the Heart Rhythm Society. *J Am Coll Cardiol.* 2015; 13:715-177.
4. The Chinese medical association branch of cardiovascular disease. Guideline for the treatment of supraventricular tachyarrhythmia. *Chinese Journal of Cardiology.* 2005; 33:2-15.
5. Pappone C, Vicedomini G, Manguso F, Saviano M, Baldi M, Pappone A, et al. Wolff-parkinson-white syndrome in the era of catheter ablation: Insights from a registry study of 2169 patients. *Circulation.* 2014; 130: 811-819.
6. Mirella M, Hemanth R, Theo H, Wittkamp F, Hauer R, Derksen R, et al. Catheter ablation of incisional atrial tachycardia using a novel mapping system: Localisa. *Pacing Clin Electrophysiol.* 2001; 24: 1616-1622.
7. Blafox AD, Numan M, Knick BJ, Saul JP. Sinoatrial nodal reentrant tachycardia in infants with congenital heart disease. *Am J Cardiol.* 2001; 88: 1050-1054.
8. Shotan A, Ostrzega E, Mehra A, Johnson JV, Elkayam U. Incidence of arrhythmias in normal pregnancy and relation to palpitations, dizziness, and syncope. *Am J Cardiol.* 1997; 79: 1061-1064.
9. Ghosh N, Luk A, Derzko C, Dorian P, Chow CM. The acute treatment of maternal supraventricular tachycardias during pregnancy: a review of the literature. *J Obstet Gynaecol Can.* 2011; 33: 17-23.
10. Tawam M, Levine J, Mendelson M, Goldberger J, Dyer A, Kadish A. Effect of pregnancy on paroxysmal supraventricular tachycardia. *Am J Cardiol.* 1993; 72: 838-840.