



Salmonella Typhi Vertebral Osteomyelitis Misdiagnosed as Tuberculosis in Thoracic Spine: Case Report and Literature Review

Liu-Xue Du^{1,2}, Jia-Ming Liu¹, Ai-Fen Peng³, Shan-Hu Huang¹ and Zhi-Li Liu^{1*}

¹Department of Orthopedic Surgery, The First Affiliated Hospital of Nanchang University, China

²Department of Orthopedic Surgery, Jiangxi Provincial People's Hospital, China

³Department of Humanities, Jiangxi University of Traditional Chinese Medicine, China

Abstract

Vertebral osteomyelitis caused by *Salmonella* Typhi is a rare disease, especially when it occurs in the thoracic spine. In this article, we reported a rare case of a 62-year-old male patient who had upper back pain after recurrent fever for one and a half months. He lost 8 kg of weight and the thoracic spine tenderness (T5-10) was presented according to physical examination. Combined with the CT and MRI, the patient was initially diagnosed as thoracic vertebral Tuberculosis (TB) and surgery was carried out for focus debridement by posterior approach. However, tissue and wound culture indicated that the infection was caused by *Salmonella* Typhi. After 3 weeks of intravenous moxifloxacin, the patient recovered and discharged without fever and back pain.

Keywords: Osteomyelitis; Tuberculosis; Salmonella Typhi; Vertebrae

Introduction

Salmonella Typhi is a gram negative bacterium which usually causes systemic infections and typhoid fever in humans. Typhoid fever is an acute intestinal infectious disease, which is an important reason for people's death in Africa, Asia and Latin America [1]. The common complications of typhoid fever are intestinal bleeding and perforation, but vertebral osteomyelitis is rare. Khan et al and Abdullah et al reported that vertebral osteomyelitis due to *Salmonella* Typhi infection accounted only 1-4% of all bone infections [2,3]. In this study, we reported a rare case with *Salmonella* Typhi thoracic vertebral osteomyelitis, who was misdiagnosed as thoracic vertebral tuberculosis.

Case Presentation

This study was approved by the ethical committee of the hospital and informed consent was got from the patient. A 62-year-old male patient presented recurrent low fever one and a half months ago, without any inducement. The maximum temperature of him was 38.5 degrees Celsius. After the fever, the patient had upper back pain, and the pain got serious when he forward bent. All the symptoms continued and the patient lost 8 kg weight before admitting to our hospital. Physical examination showed that spinous process tenderness was existed from T5 to T10, but no neurological deficit was noted. The laboratory test indicated both of C-Reactive Protein (CRP) and Erythrocyte Sedimentation Rate (ESR) were significantly increased (CRP: 142 mg/L, ESR: 110mm/h) in the patient. *T-SPOT* test of the patient for tuberculosis was positive.

Additionally, the X-ray film showed there was a small curve in the thoracic spine. Computed Tomography (CT) indicated there was bone lesion between T7 and T8, which resulted in the T7/8 intervertebral space narrowed and paraspinal soft tissue swollen (Figure 1a). Enhanced magnetic resonance imaging (MRI) showed spondylodiscitis was occurred at T7/8, accompanying with paravertebral and epidural abscess and spinal cord compression (Figure 1b).

Based on the symptoms, signs, laboratory tests and radiologic findings, the patient was initially diagnosed as thoracic vertebral tuberculosis. And anti-tuberculosis treatments (isoniazid, rifampicin, ethambutol and streptomycin) were given to him for one week firstly. After the CRP and ESR decreased, the patient underwent one-staged posterior thoracic vertebral focus debridement, autogenous bone grafting and instrumentation. During the surgery, we found that lots of granulation tissue and dead bone chips located between T7 and T8, with small amount of

OPEN ACCESS

*Correspondence:

Zhi-Li Liu, Department of Orthopedic Surgery, The First Affiliated Hospital of Nanchang University, China, Tel: 0086-791-88693201; Fax: 0086-791-88693201;

E-mail: zgm7977@163.com

Received Date: 21 Sep 2018

Accepted Date: 05 Oct 2018

Published Date: 15 Oct 2018

Citation:

Du L-X, Liu J-M, Peng A-F, Huang S-H, Liu Z-L. *Salmonella* Typhi Vertebral Osteomyelitis Misdiagnosed as Tuberculosis in Thoracic Spine: Case Report and Literature Review. *Ann Orthop Musculoskelet Disord*. 2018; 1(3): 1014.

Copyright © 2018 Zhi-Li Liu. This is an open access article distributed under the Creative Commons Attribution License, which permits unrestricted use, distribution, and reproduction in any medium, provided the original work is properly cited.

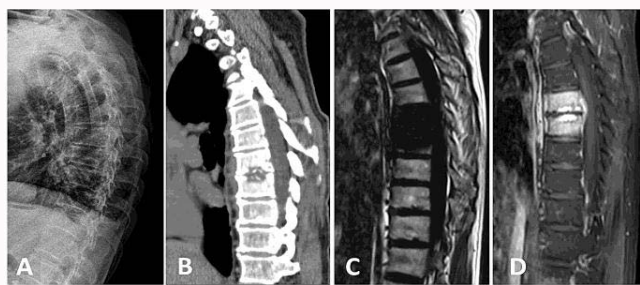


Figure 1: Preoperative radiological films of the patient's thoracic spine. A) X-ray of the thoracic spine. B) Sagittal image of CT displayed bone destruction of lower endplate of T7 and upper endplate of T8, and the loss of the intervertebral disc height of T7/8. C) Sagittal T1-weighted image of MRI showed the height of the intervertebral disc decreased and the vertebral body of T7 and T8 were destroyed. D) Sagittal T2-weighted enhanced image of MRI showed there was paravertebral and epidural abscess at the T7/8 level.

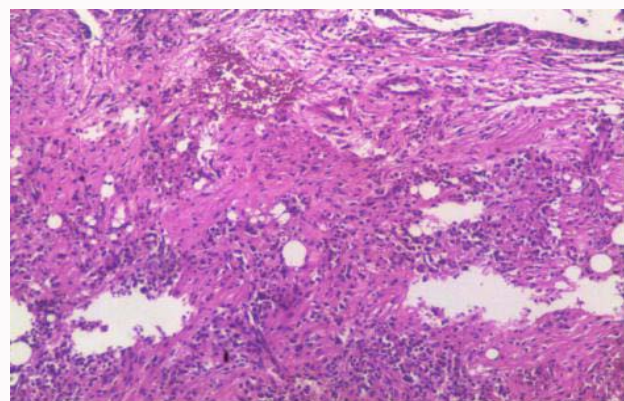


Figure 2: The histopathologic examination of the tissue showed there was chronic suppurative inflammation at the focus of T7/8.

paravertebral abscess. The low endplate of T7, up endplate of T8 and T7/8 intervertebral disc were completely destroyed. The focus tissue and specimen were harvested for culture and histopathologic examination. All the necrotic tissue and dead bone were resected and abscess was debrided. After rinsing with saline, the autogenous bone graft was implanted into the interspace of T7/8 with instrumentation from T6-T9. Postoperatively, anti-tuberculosis therapy was continued for the patient. On the postoperative day 3, tissue culture reported the infection of thoracic spine was caused by *Salmonella* Typhi, which was sensitive to moxifloxacin. Thus, the patient further underwent Widal reaction test to confirm the diagnosis, and the result was positive. The histopathologic examination indicated there was chronic suppurative inflammation in the tissue (Figure 2). Therefore, the patient's was finally diagnosed as typhoid spondylitis, and intravenous moxifloxacin was given to him. After 3 weeks treatment, both of the CRP and ESR were significantly decreased. The blood culture for *Salmonella* Typhi in the patient was negative for three times. The fever was relived and the patient discharged with on neurological deficit. Eight months later, the patient was followed up at the clinic, with no back pain and fever. He can walk by himself without brace supporting.

Discussion

Salmonella Typhi infection usually causes typhoid fever and paratyphoid. Recently, the incidence of typhoid fever is gradually declined, but the incidence of paratyphoid and atypical symptoms of typhoid fever are increasing [4,5]. Pyogenic spondylodiscitis and spondylitis due to *salmonella* Typhi are the rare complications of typhoid fever. Although studies have reported *Salmonella* Typhi osteomyelitis in spine, most of the lesions were located at lumbar [6-9] and cervical regions [10,11]. Vertebral osteomyelitis due to *salmonella* Typhi in thoracic spine is rare. And it is difficult to differentiate it with spinal tuberculosis because of the similar symptoms. Currently, the main treatment for typhoid vertebral osteomyelitis is given antibiotics according to drug sensitivity test. If necessary, spinal focus debridement surgery will be performed.

In this case, the patient firstly presented with recurrent low fever, and then followed by upper back pain. Laboratory tests showed that both of CRP and ESR were significantly increased and the MRI indicated a spondylodiscitis located at T7-T8 level (Figure 1c-d). However, it's difficult to distinguish typhoid osteomyelitis with tuberculosis by MRI [11]. In addition, the T-SPOT test, which was

a specific diagnosis method for tuberculosis, was positive in this patient. Thus, we initially misdiagnosed the patient as thoracic spinal tuberculosis and anti-tuberculosis treatment was administered to him until the tissue culture coming out.

Typhoid vertebral osteomyelitis is easy misdiagnosed as neoplasm, Guillain-Barre, atypical borreliosis, atypical pneumonia, scrub typhus and tuberculosis [11]. Because these diseases have similar image findings on X-ray, CT and MRI. Currently, the accepted diagnostic methods for *Salmonella* Typhoid infection are tissue culture, blood culture and Widal reaction test. However, the blood culture maybe negative in typhoid vertebral osteomyelitis. For this patient, the tissue culture of the focus tissue indicated it was infected by *Salmonella* Typhoid and the Widal reaction test was positive. In addition, we asked the patient's past history again after the surgery, and he told us he used to work in Kampuchea and had taken contaminated water before developing fever. We believed this was the reason why he got thoracic typhoid osteomyelitis. Once the diagnosis is confirmed, the antibiotics should be given according to the drug sensitivity test.

In summary, we reported a rare case of thoracic vertebral osteomyelitis caused by *Salmonella* Typhi in a 62-year-old male patient. It is easy to be misdiagnosed as tuberculosis and the focus tissue culture is helpful for the diagnosis. Spine surgeons should pay attention to the spinal vertebral osteomyelitis and give right antibiotics according to the drug sensitivity test.

Conflicts of Interest

No benefits in any form have been or will be received from any commercial party related direct and indirect to the subject of this manuscript.

References

1. Crump JA, Mintz ED. Global trends in typhoid and paratyphoid Fever. *Clin Infect Dis*. 2010;50(2):241-6.
2. Khan FY, El-Hiday AH, Kamel HA. Typhoid osteomyelitis of the lumbar spine. *Hong Kong Med J*. 2006;12(5):391-3.
3. Abdullah SH, Ata OA, El-Adwan N. Thoracic spinal epidural abscess caused by *Salmonella* typhi. *Neurol Med Chir (Tokyo)*. 2008;48(3):140-2.
4. Woods CW, Murdoch DR, Zimmerman MD, Glover WA, Basnyat B, Wolf L, et al. Emergence of *Salmonella* enterica serotype ParaTyphi A as a major cause of enteric fever in Kathmandu, Nepal. *Trans R Soc Trop Med Hyg*. 2006;100(11):1063-7.

5. Ochiai RL, Wang X, von Seidlein L, Yang J, Bhutta ZA, Bhattacharya SK, et al. Salmonella paratyphi A rates, Asia. *Emerg Infect Dis.* 2005;11:1764-6.
6. Amritanand R, Venkatesh K, Sundararaj GD. Salmonella spondylodiscitis in the immunocompetent: our experience with eleven patients. *Spine (Phila Pa 1976).* 2010;35(23):E1317-21.
7. Choi YS, Cho WJ, Yun SH, Lee SY, Park SH, Park JC, et al. A case of back pain caused by Salmonella spondylitis - A case report. *Korean J Anesthesiol.* 2010;59:S233-7.
8. Kurşun E, Turunç T, Ozkan U, Demiroğlu YZ. Endovascular treatment of an iliac artery rupture caused by invasive Salmonella spondylodiscitis. *Acta Orthop Traumatol Turc.* 2014;48(4):459-62.
9. Fukuda T, Bouchi R, Minami I, Ohara N, Nakano Y, Nishitani R, et al. Retrograde pyelonephritis and lumbar spondylitis as a result of Salmonella typhi in a type 2 diabetes patient with neurogenic bladder. *J Diabetes Investig.* 2016;7(3):436-9.
10. Falavigna A, Ferraz FA. [Spontaneous cervical spondylodiscitis caused by Salmonella typhi in an immunocompetent patient]. *Arq Neuropsiquiatr.* 2002;60(4):1034-7.
11. Zhi-Yun Feng, Fang Guo, Zhong Chen. Literature Review and Clinical resentation of Cervical Spondylitis Due to Salmonella Enteritidis in Immunocompetent. *Asian Spine J.* 2014;8(2):206-10.